
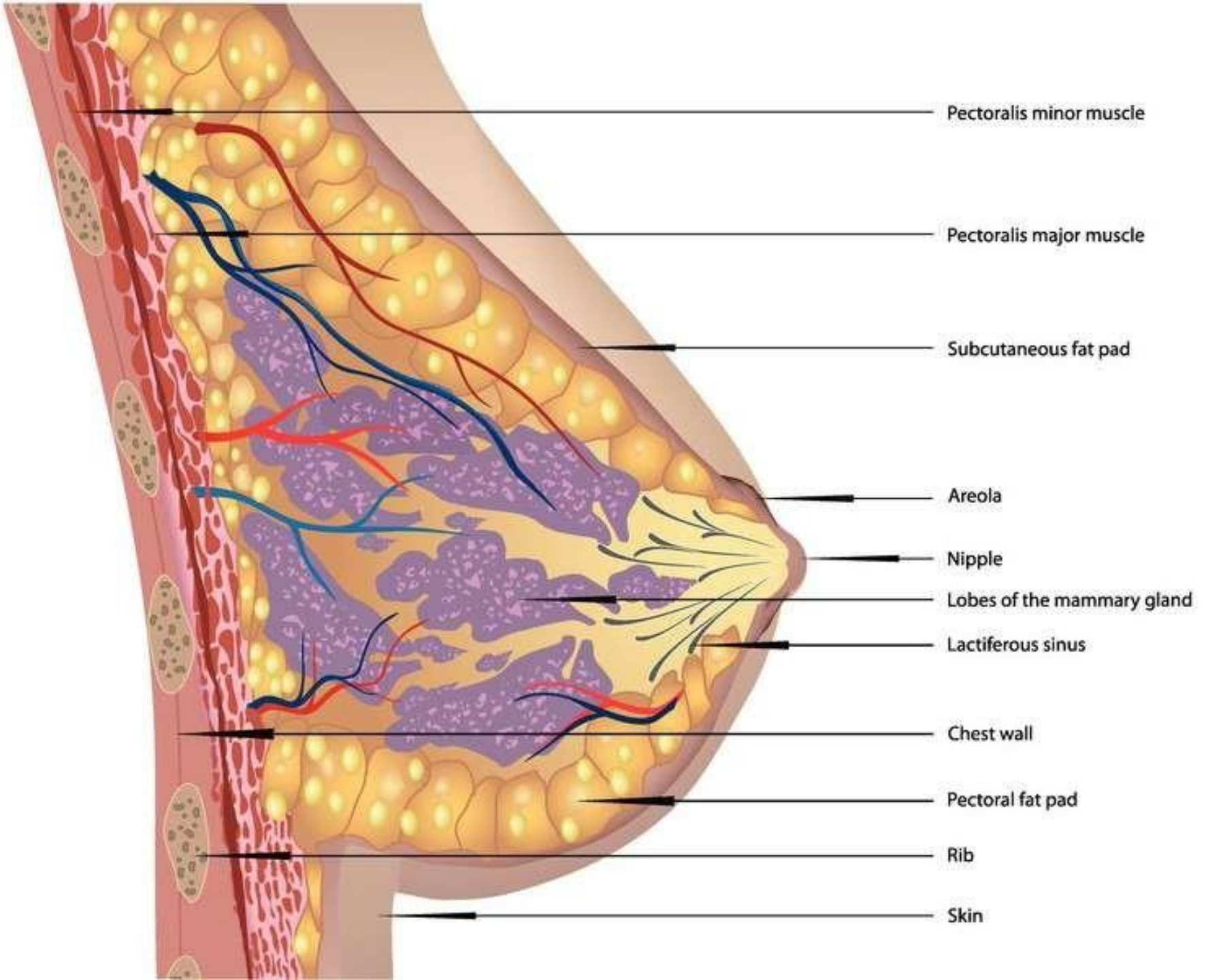


# MAMMOGRAPHY- PHYSICS AND TECHNIQUE



- There are several breast imaging modalities available such as Ultrasound, CT, Digital Mammography, MRI and scintimammography .
- Mammography remains the cornerstone of breast imaging .
- Only mammography when correctly performed and interpreted offers the necessary reliability to diagnose the curable forms of breast cancers.
- Ultrasound, MRI, CT are useful adjuncts once a lesion has been detected by physical examination or by radiographic mammography .



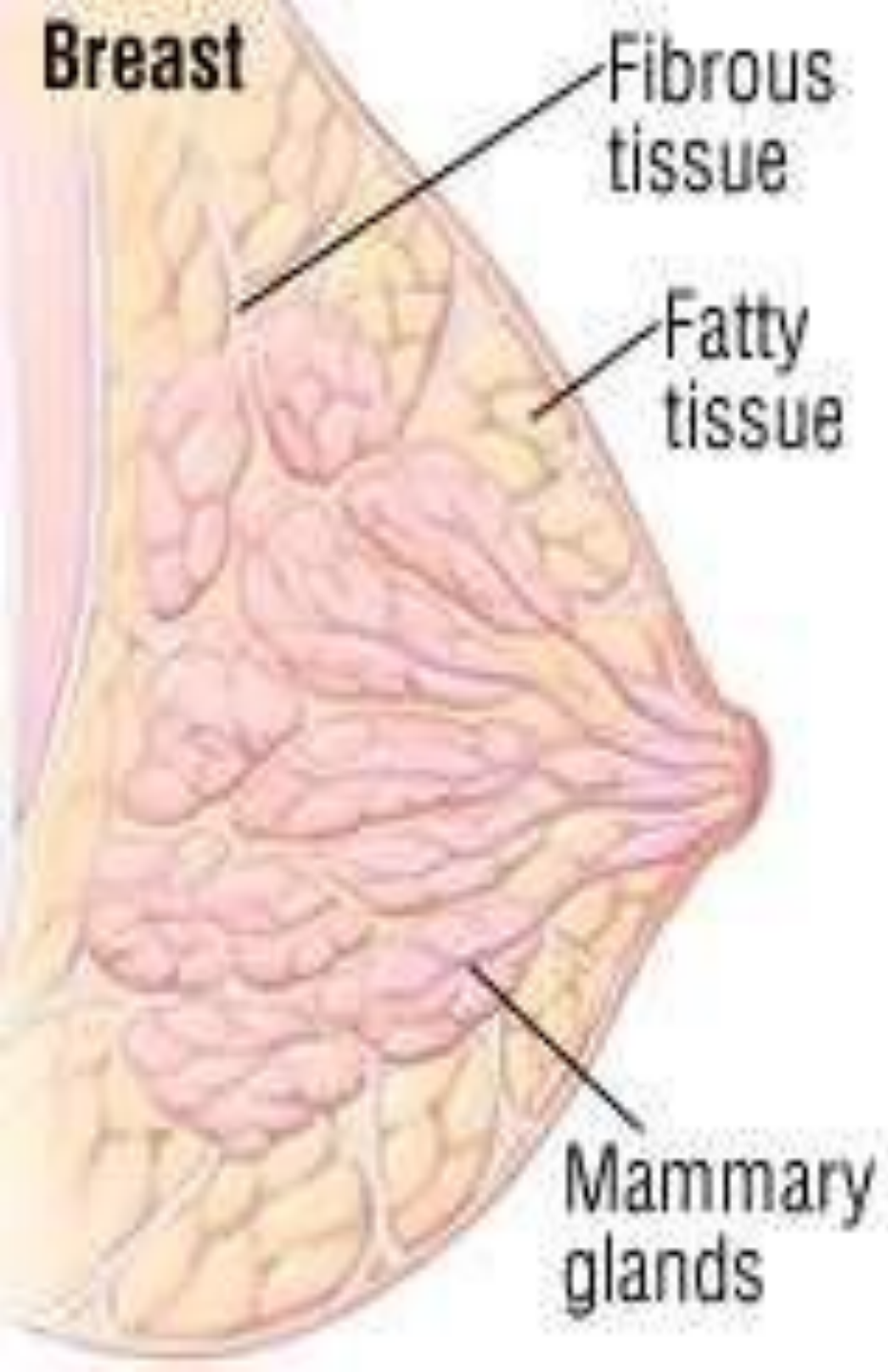

# Breast

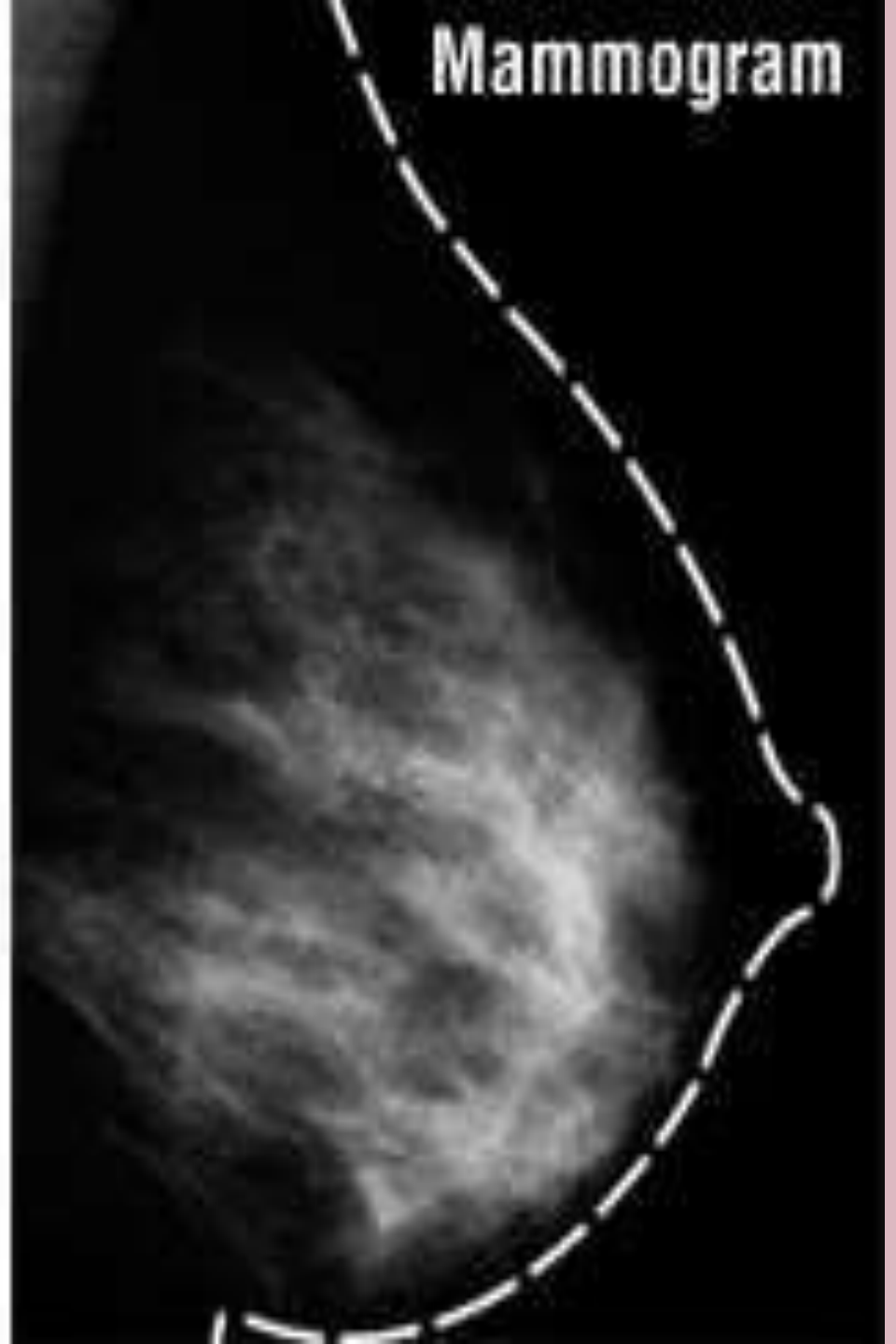
Fibrous tissue

Fatty tissue

Mammary glands




# Mammogram



# XEROMAMMOGRAPHY

- -X-rays strike an electronically charged plate of selenium-coated aluminum.
- The loss of charge at sites of X-ray interactions leads to latent image formation which is converted to visible image by reading the charge pattern.
- This technique gives a very sharp but low contrast image.



# INDICATIONS

- Screening of asymptomatic women
- Screening of high risk women
- Follow up of patients after mastectomy of same and opposite breast / same breast with implant .
- Investigations of benign breast diseases with eczematous skin, nipple discharge , skin thickening .
- Investigation of a breast lump
- Investigation of occult primary with secondaries .
- Male breast evaluation .



# PHYSICS



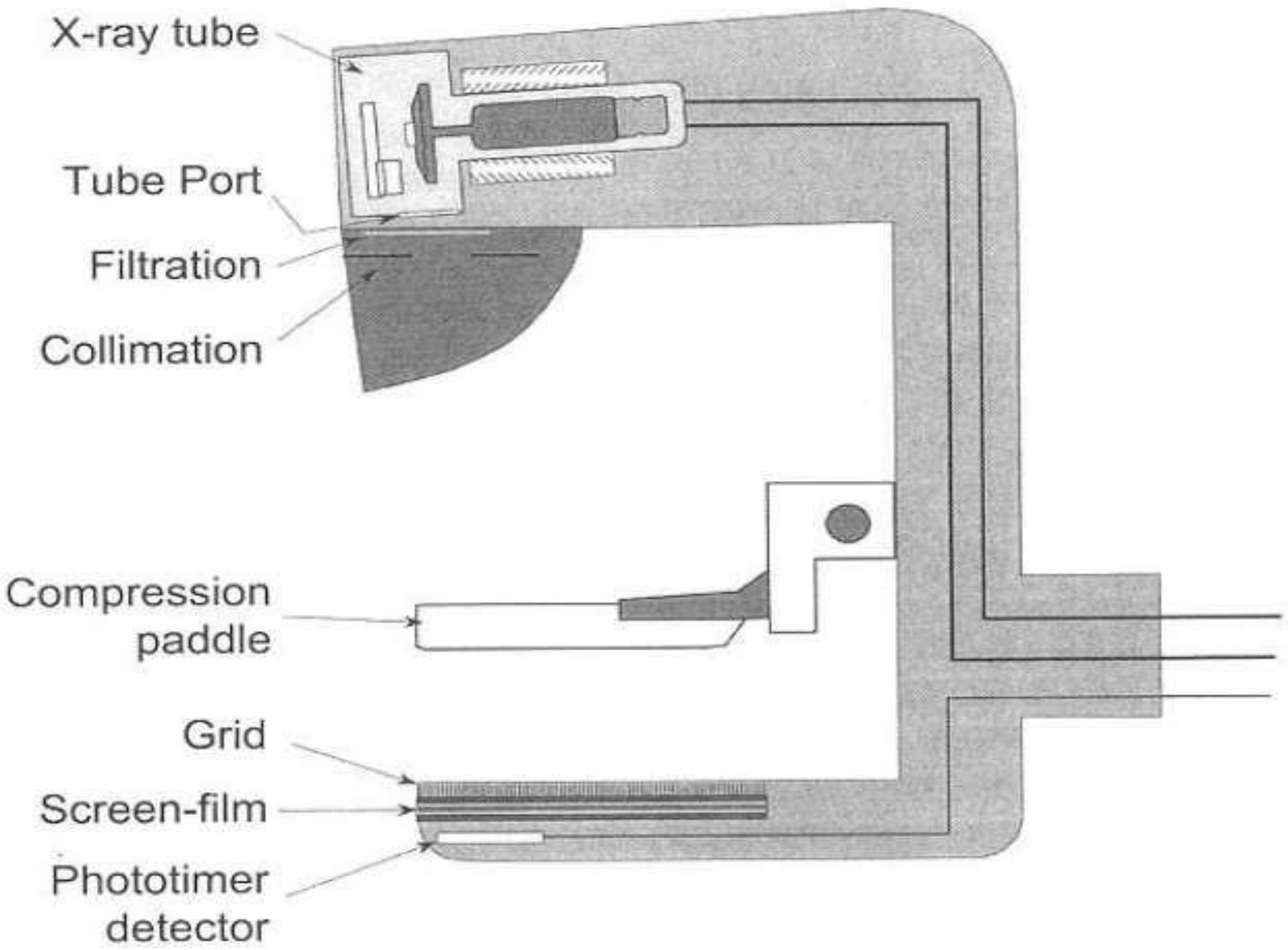


# MAMMOGRAPHY EQUIPMENT

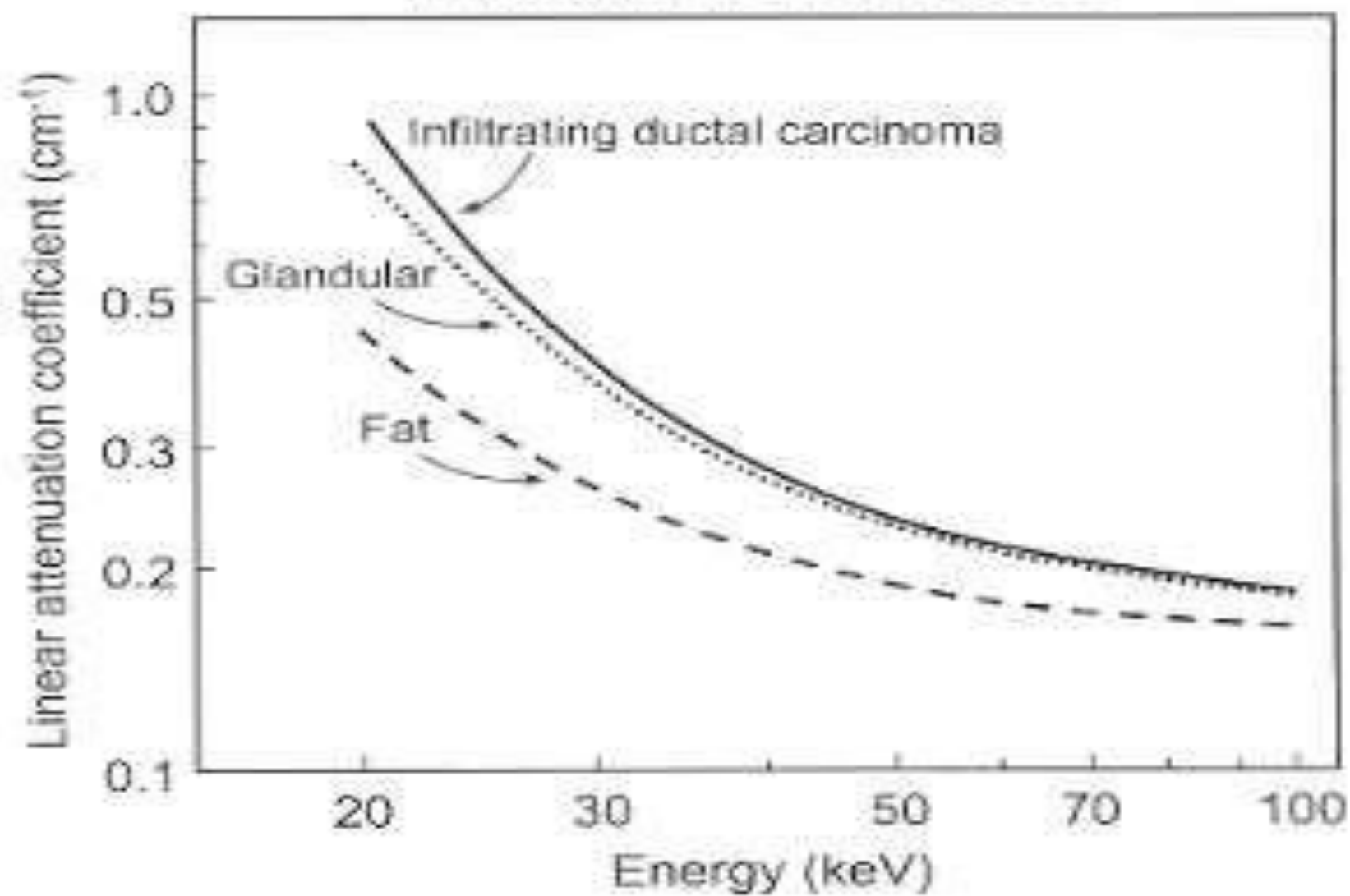
- Generator
- Xray tube – fine focus of 0.2-0.5 mm with an additional 0.1 mm focus for magnification .
- Target – Molybdenum and Rhodium
- Beryllium window – Minimises absorption of radiation within the tube .
- Molybdenum filter – By transmitting only characteristic radiation ,absorbs unwanted radiation and forms a monoenergetic beam.
- Compression device : 1-4 mm thick plastic plate







# Attenuation of breast tissues



A

# TARGET

- The xray tubes are designed with Tungsten ,molybdenum,Rhodium targets .
- Tungsten target is operated under 30 kVp with a 0.5 mm Al filter – Brehmsstrahlung and 12 keV L-shell characteristic xrays .
- Molybdenum target with Mo/Rh filter is more suitable for mammography .
- Rhodium target filtered with Rh filter gives a similar spectrum as molybdenum .
- Since the atomic number is higher , the brehmsstrahlung radiation is also higher than molybdenum .



# FILAMENT

- Positioned within a focussing cup with two focal spot sizes .
- Filament types are either double wound/flat ribbon/circular filament .
- Focal spot size is very critical in mammography where high spatial resolution is required .
- Small focal spot is used with small anode angle , which permits the use of high mA factors .
- Usually the cathode is positioned towards the chest wall , which makes patient positioning easy and takes care of the heel effect .



# FILTERS

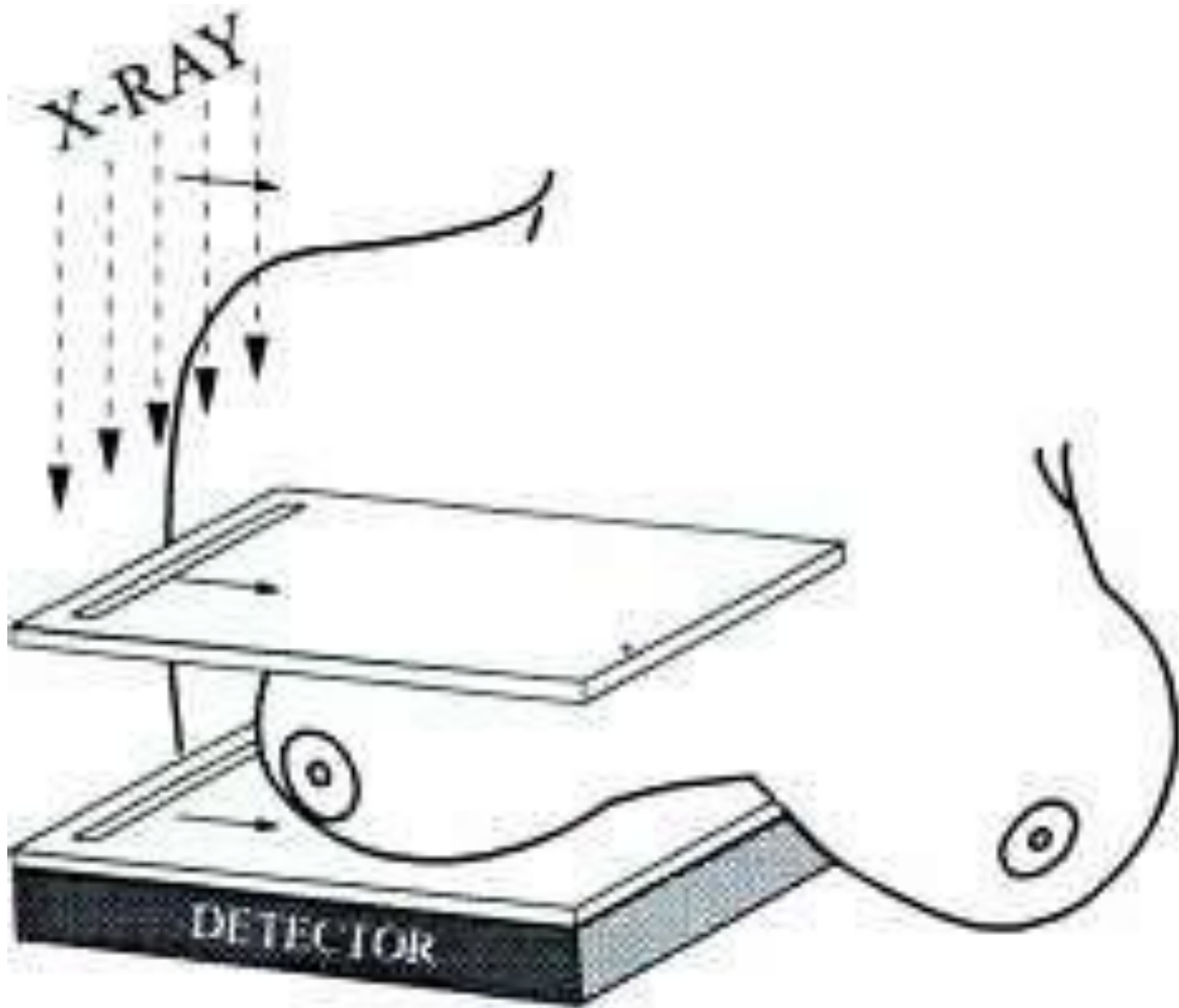
- Thin beryllium window or borosilicate glass window is used to reduce inherent filtration , since it offers low attenuation .
- For a tungsten target Xray tube , Mo or Rh filter is recommended .
- In case of Rhodium target Xray tube , Rhodium filter of 0.025 mm is used which gives high quality xrays with higher penetration .
- Combination is suitable for thicker and dense breast imaging .



# GRIDS

- Stationary grids or grids placed in between the screen and the film are no longer used as the thin grid lines compromised on the quality of the image .
- Covered tiny details such as microcalcifications
- Hence oscillating grids are used
- Grid ratio of 4:1 or 5:1
- The grid lines are eliminated by the motion of the grid .
- Grids improve the image quality and cause a significant reduction

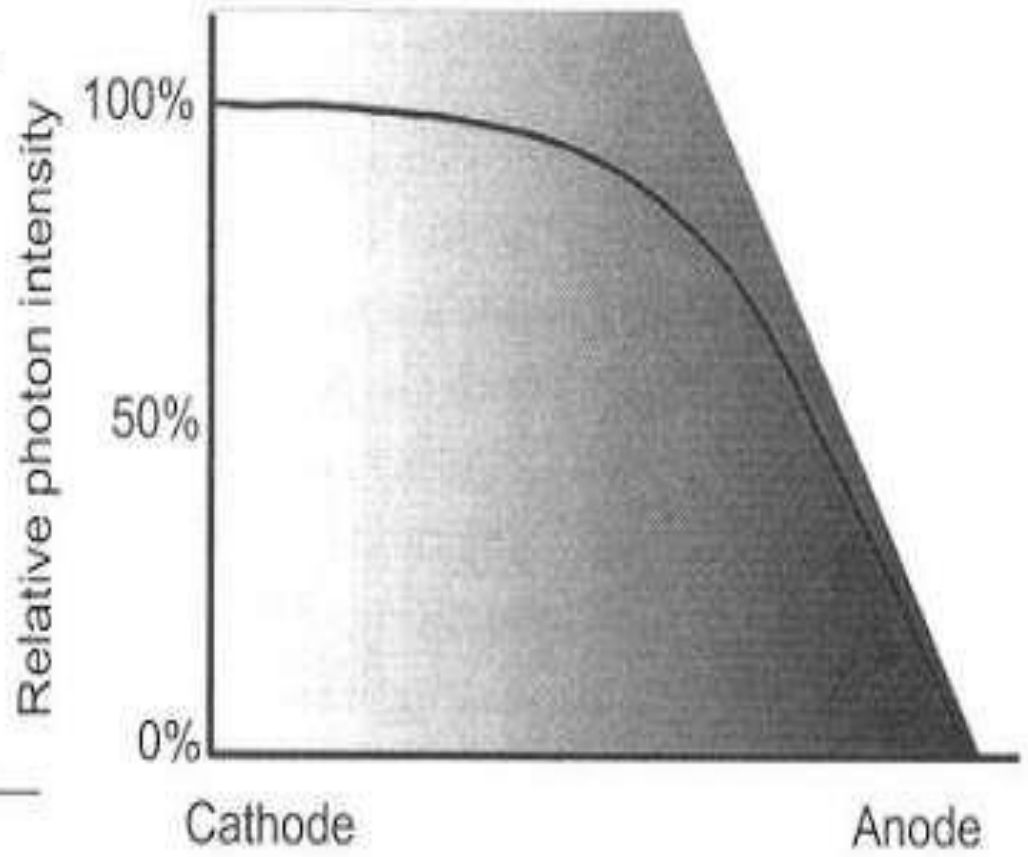
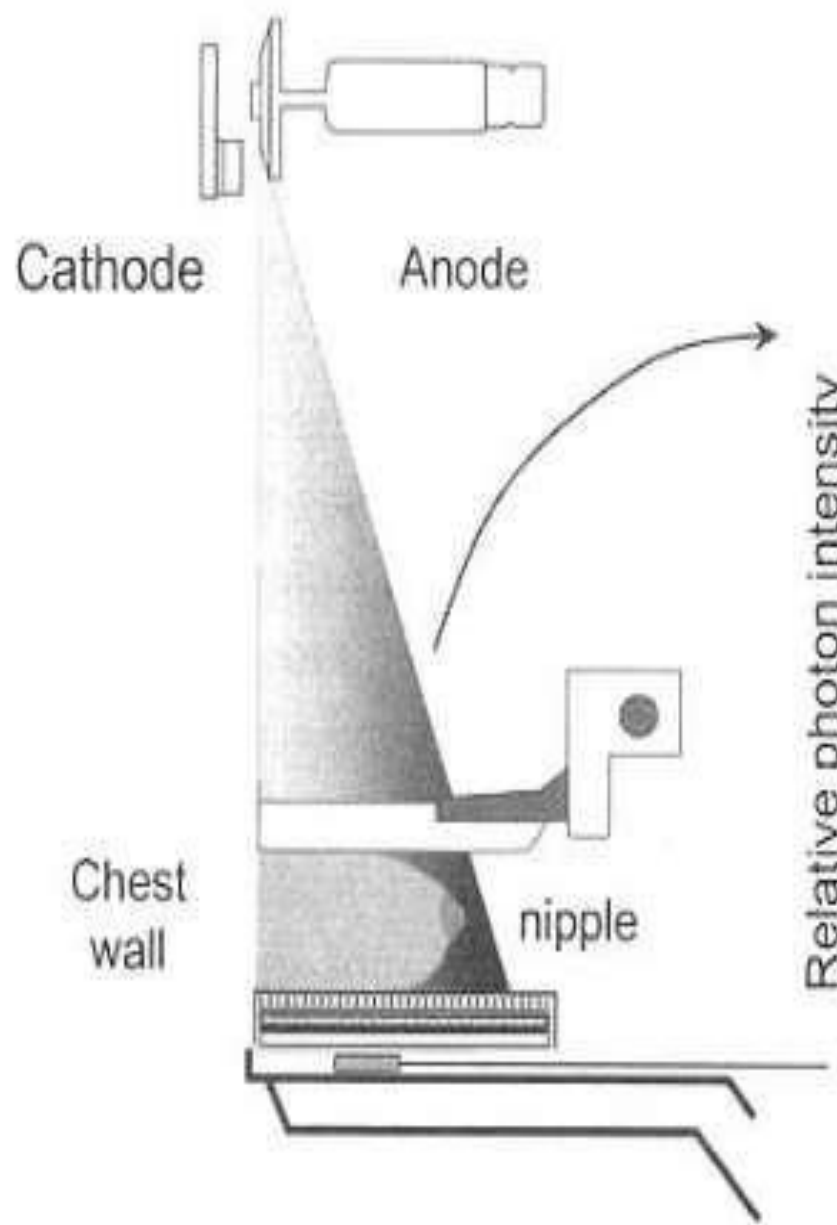






## HEEL EFFECT

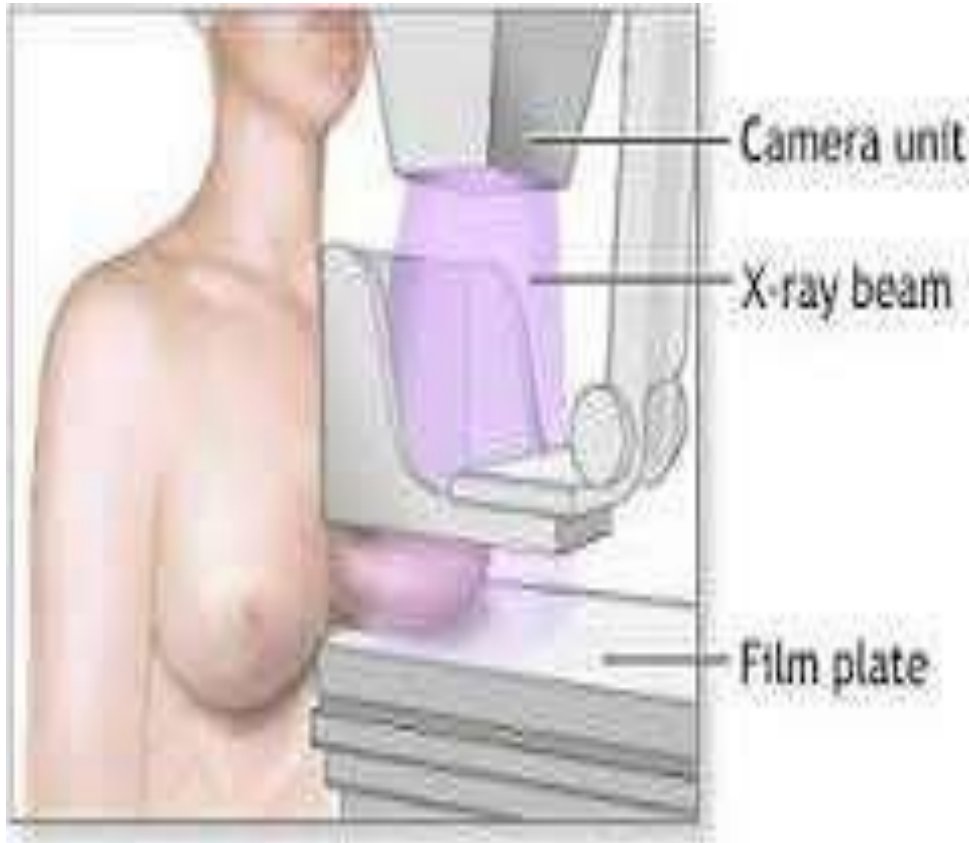
- Shape of the breast requires higher intensity of radiation near the chest wall, to create uniform exposure to the screen-film .
- The cathode is positioned toward the chest wall and the anode is toward the nipple .
- Permits easy positioning of the patient .
- Increases the intensity of radiation near the chest wall, where greater penetration is needed .
- The anode is often grounded with zero potential and the cathode is given higher potential .



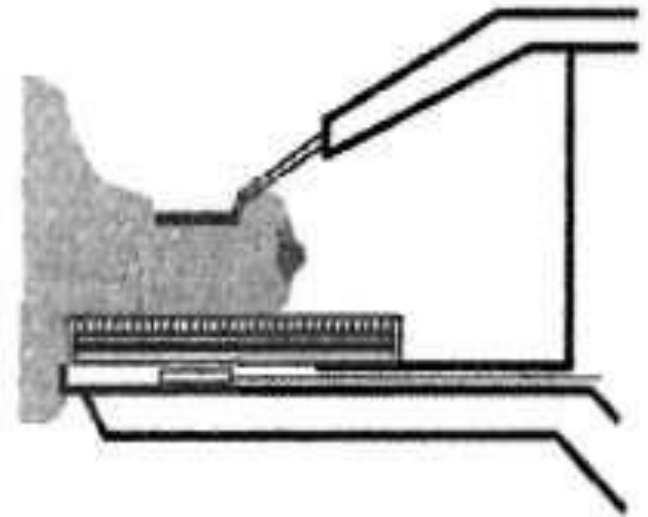
# COMPRESSION PEDDLE

- (i) Decreases the thickness of the breast , thus reduces the scattered radiation –improves the contrast .
- (ii) Decreases the kinetic blur .
- (iii) Reduces geometric unsharpness by homogenously bringing the object close to the film .
- (iv) Makes breast thickness uniform in film density.
- (v) Differentiates the easily compressible cysts and fibro-glandular tissue from the more rigid carcinomas
- (vi) Separates the super imposed breast lesions .
- (vii) Reduces radiation dose to the breast tissue .





## Spot compression



Spot compression paddle:  
Better compression over small area

- The compression device is parallel to the receptor surface .
- Radiolucent plate that is flat and parallel to the support table .
- Should match the cassette size



# AUTOMATIC EXPOSURE CONTROL

- AEC system employs phototimers to measure the Xray intensity and quality .
- Kept closer to the image receptor , to minimize the object to image distance – improves spatial resolution .

TWO TYPES :

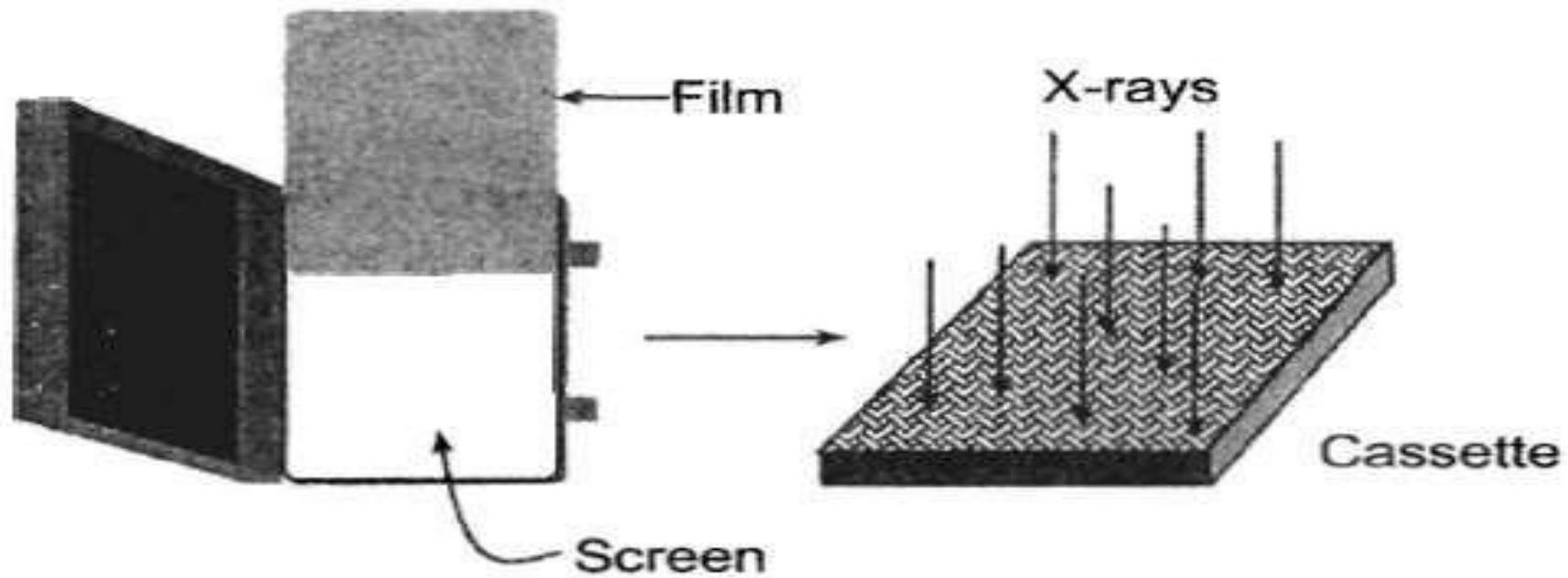
- (i) Ionization chamber type
- (ii) Solid state diode type



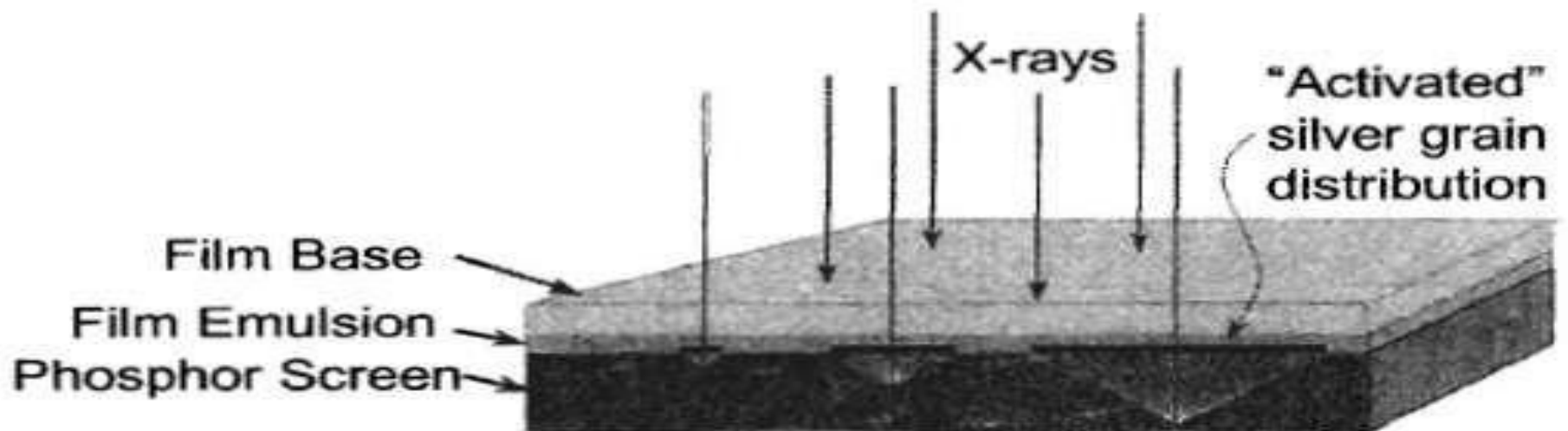
## SCREEN FILM SYSTEM

- The Xray film should have high resolution and small grain size and used along with single intensifying screen .
- The emulsion surface of the film must face the screen .
- Prevents loss of resolution due to light diffusion in the screen .
- **Gadolinium Oxysulfide activated with terbium is used as screen phosphor .**




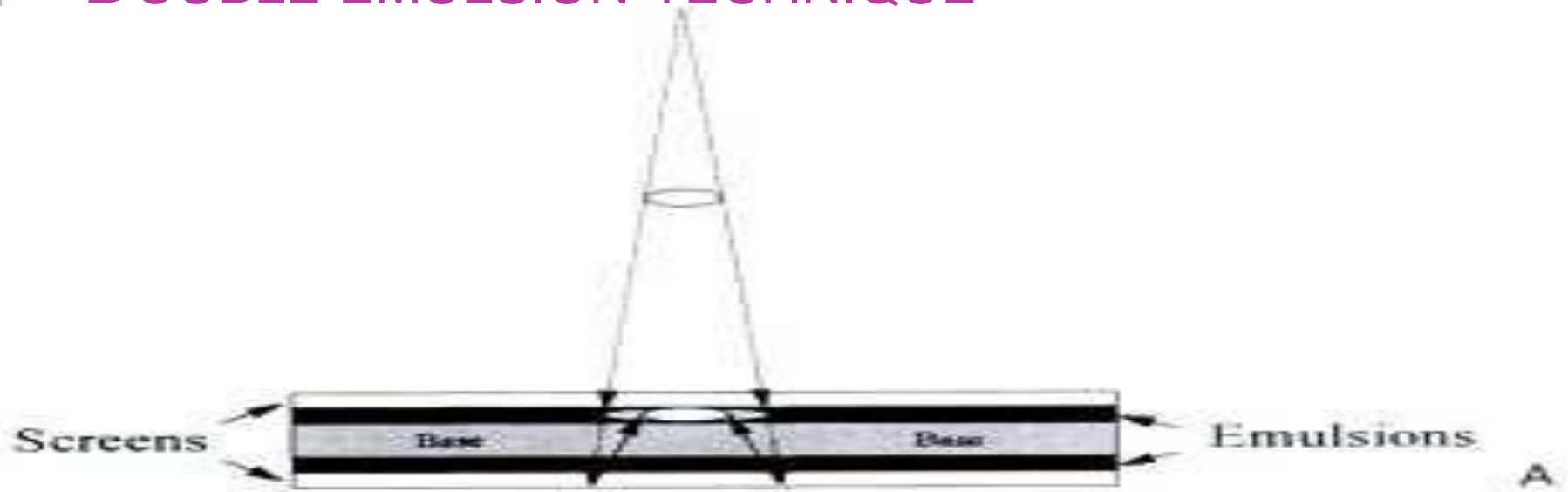


Single emulsion Film & Single phosphor screen



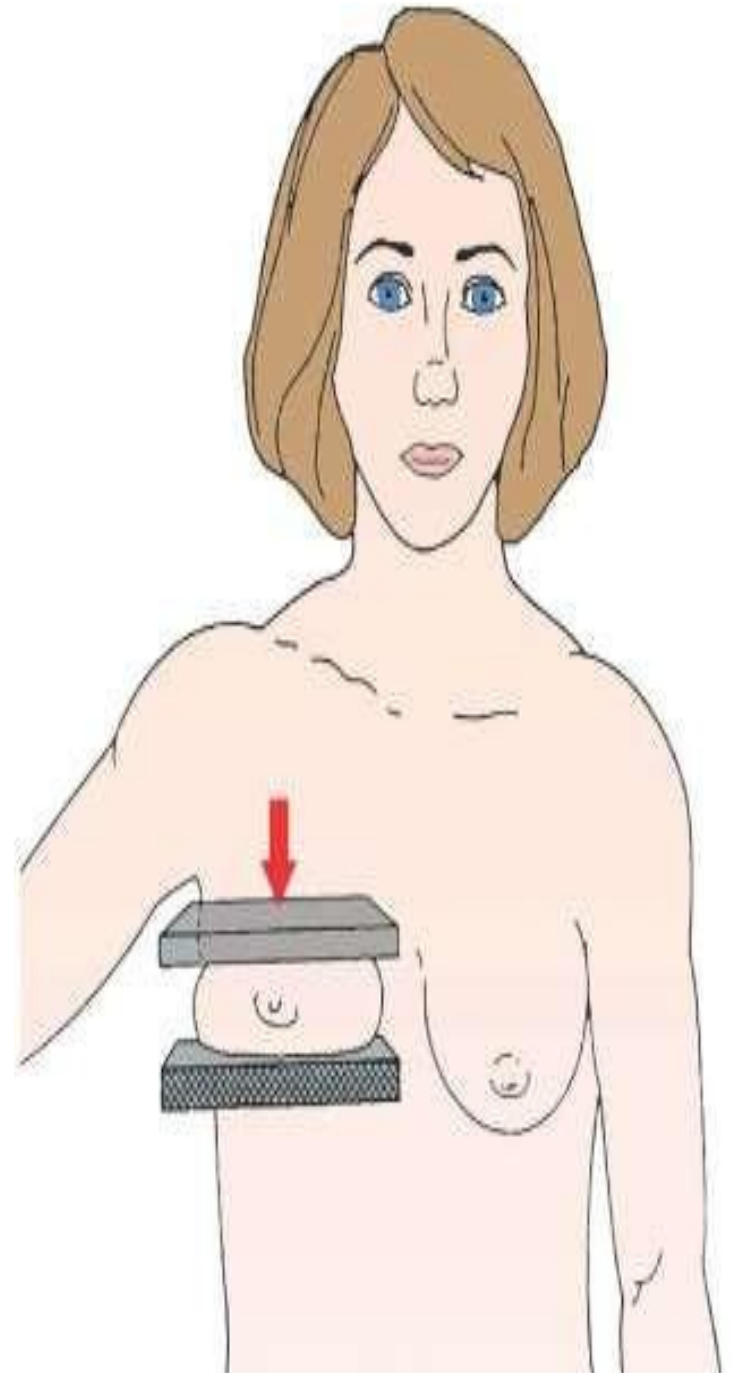

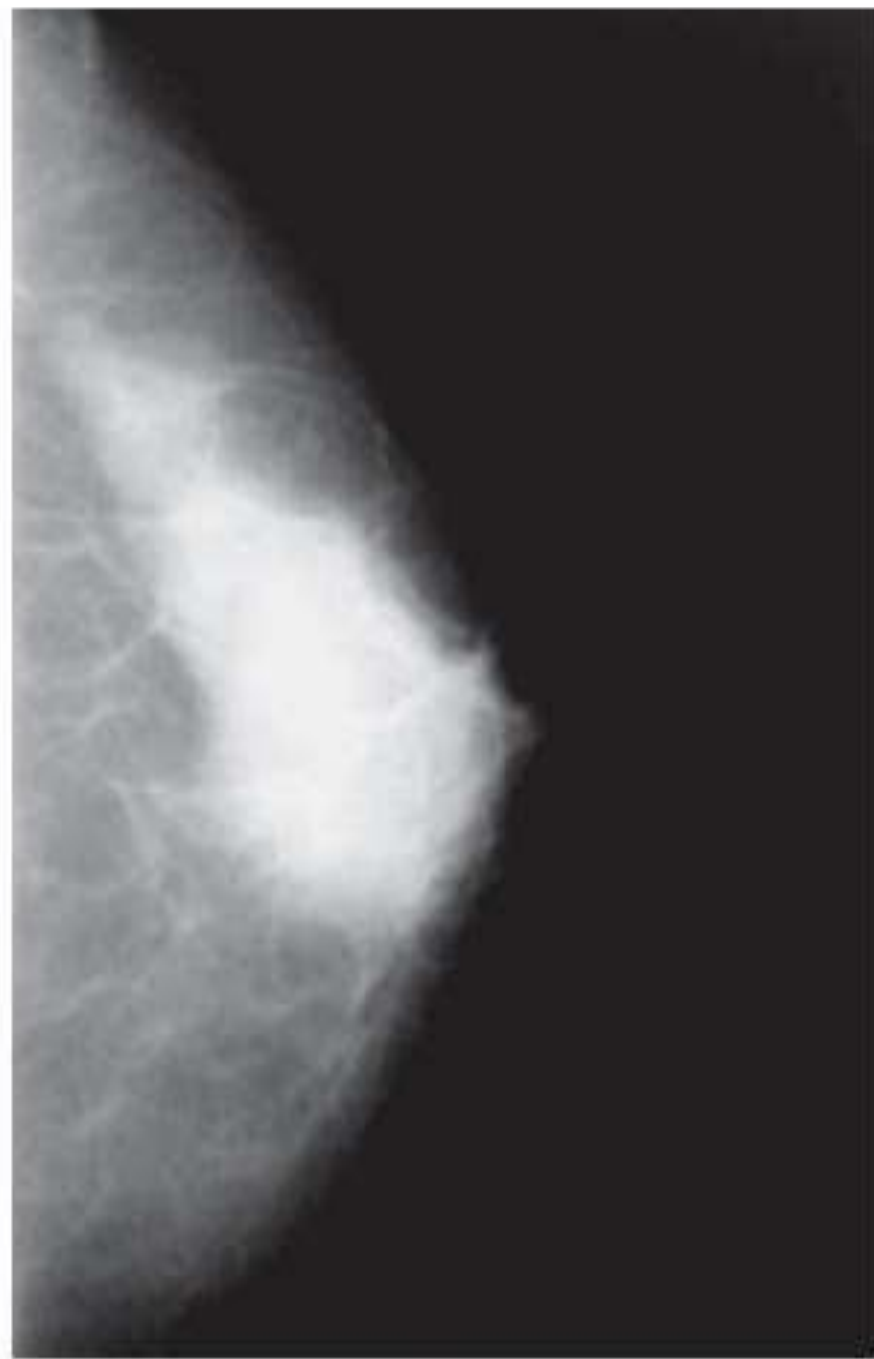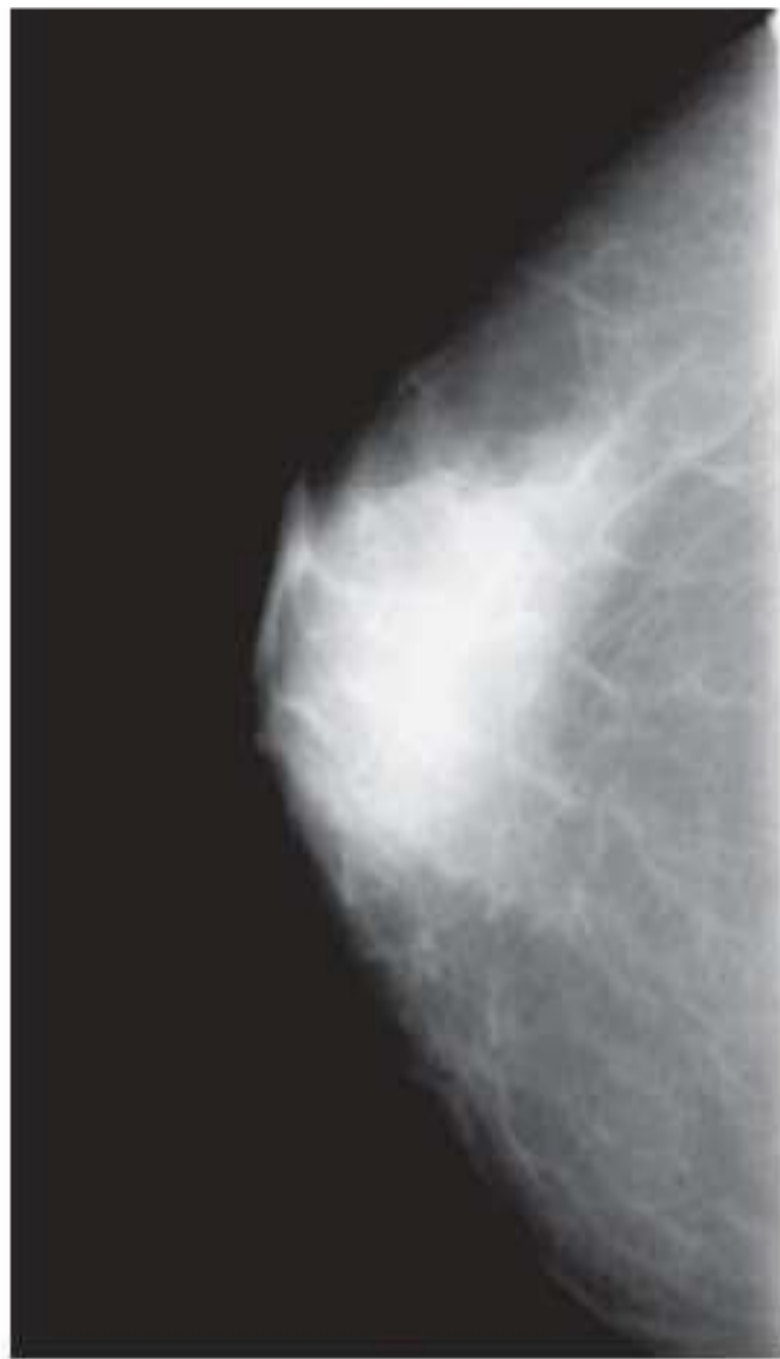# DOUBLE EMULSION TECHNIQUE



# CRANIO-CAUDAL VIEW

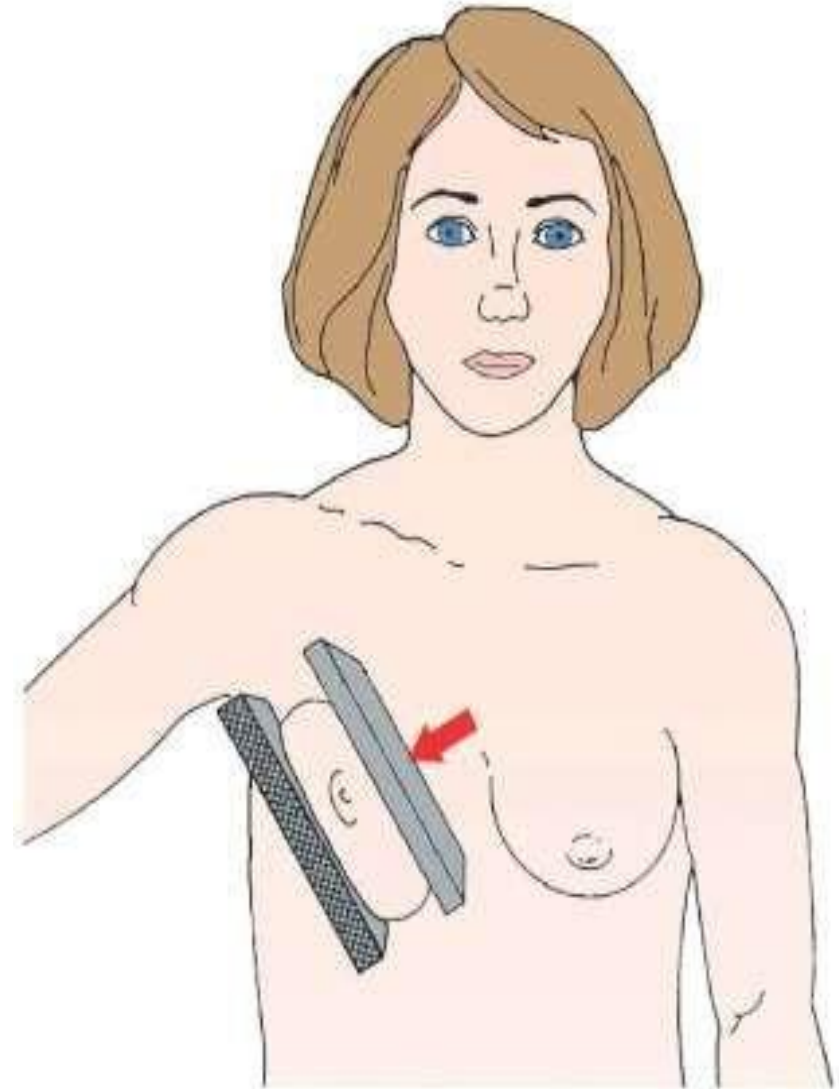
- The cassette is placed under the breast at the level of the inframammary fold .
- The breast is then pulled until the inframammary fold is taut .
- Compression is applied and Xray beam is directed vertically from above .
- Postero medial aspect should also be included .

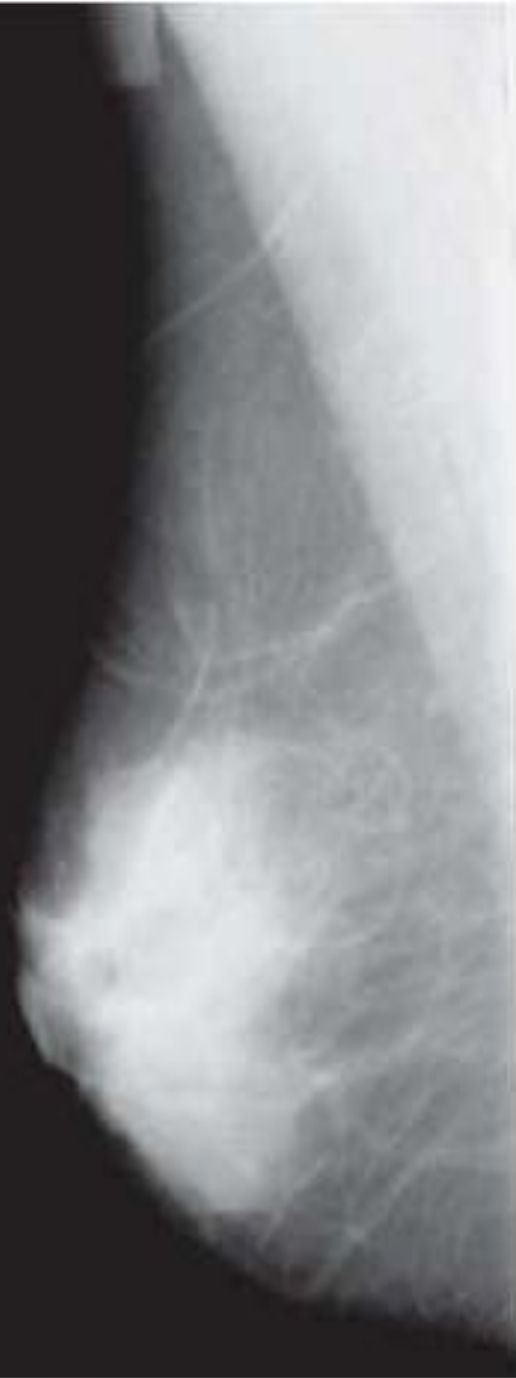



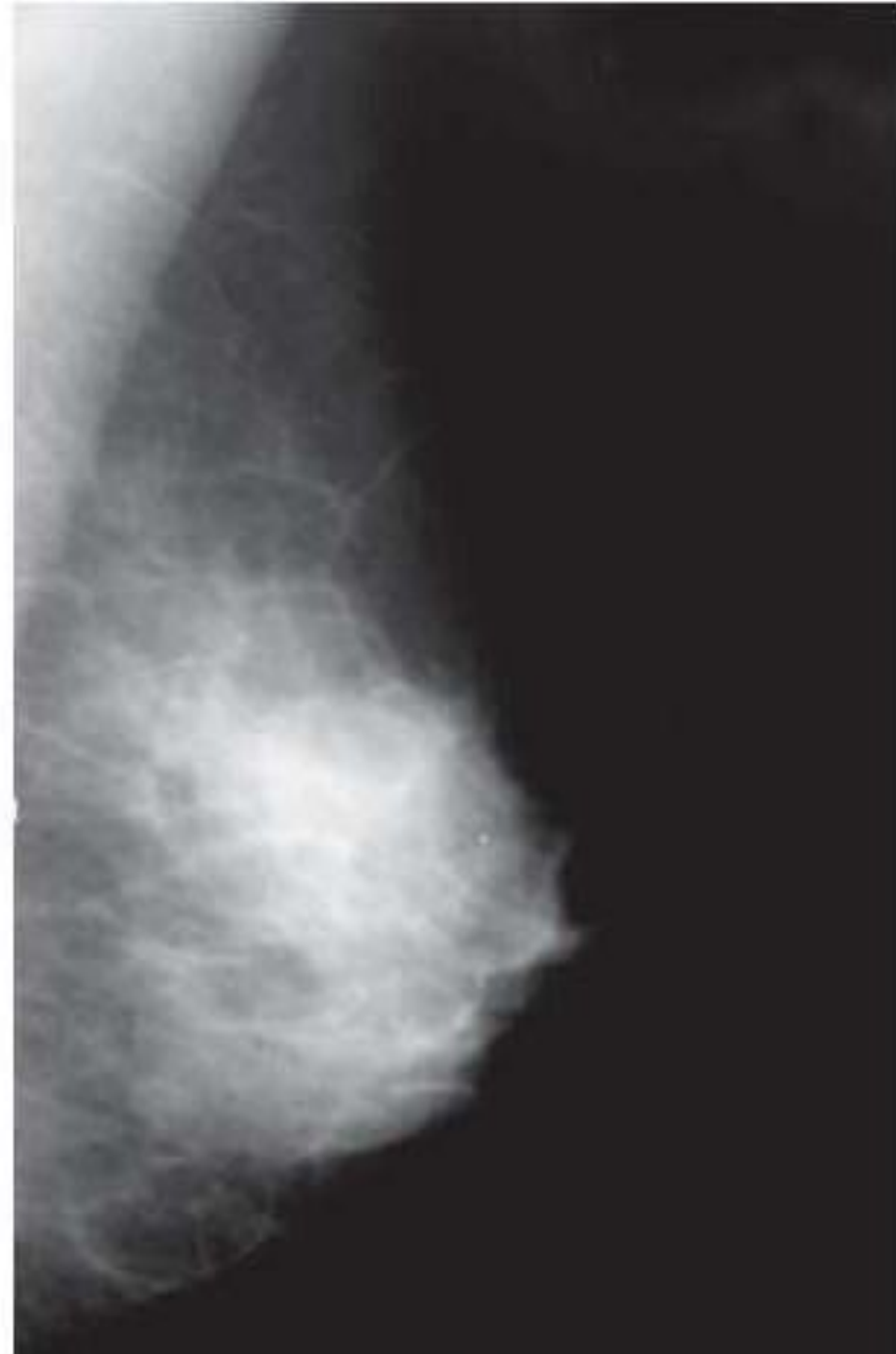
# MEDIOLATERAL OBLIQUE VIEW

- Best view to image all of the breast tissue and the pectoral muscle .
- The C-arm of the mammographic unit is rotated to 45 degree so that the cassette is parallel to the pectoral muscle .
- The film holder is kept high up in the axillary fossa and the patient s arm is abducted at the elbow by 80degrees.
- The xray beam enters the breast from the medial side –compression is applied to the pectoralis major muscle .





A



B

# SUPPLEMENTARY VIEWS

1. Lateral projections (mediolateral/lateromedial)
2. Extended craniocaudal projection
3. Cone down compression view
4. 90 degrees lateral view and angled craniocaudal views
5. Tangential views in palpable masses
6. Spot and magnification views
7. Cleavage view
8. Modified compression technique .



- Adipose tissue comprises a large portion of most breasts and is radiolucent.
  
- The radiographically visible densities include:
  - (i) varying degree of ducts
  
  - (ii) lobular elements
  
  - (iii) fibrous connective tissues structures.
  
- The supportive connective tissue is highly cellular and richly vascularised with significant water density-constitutes the essence of breast opacity in mammography.





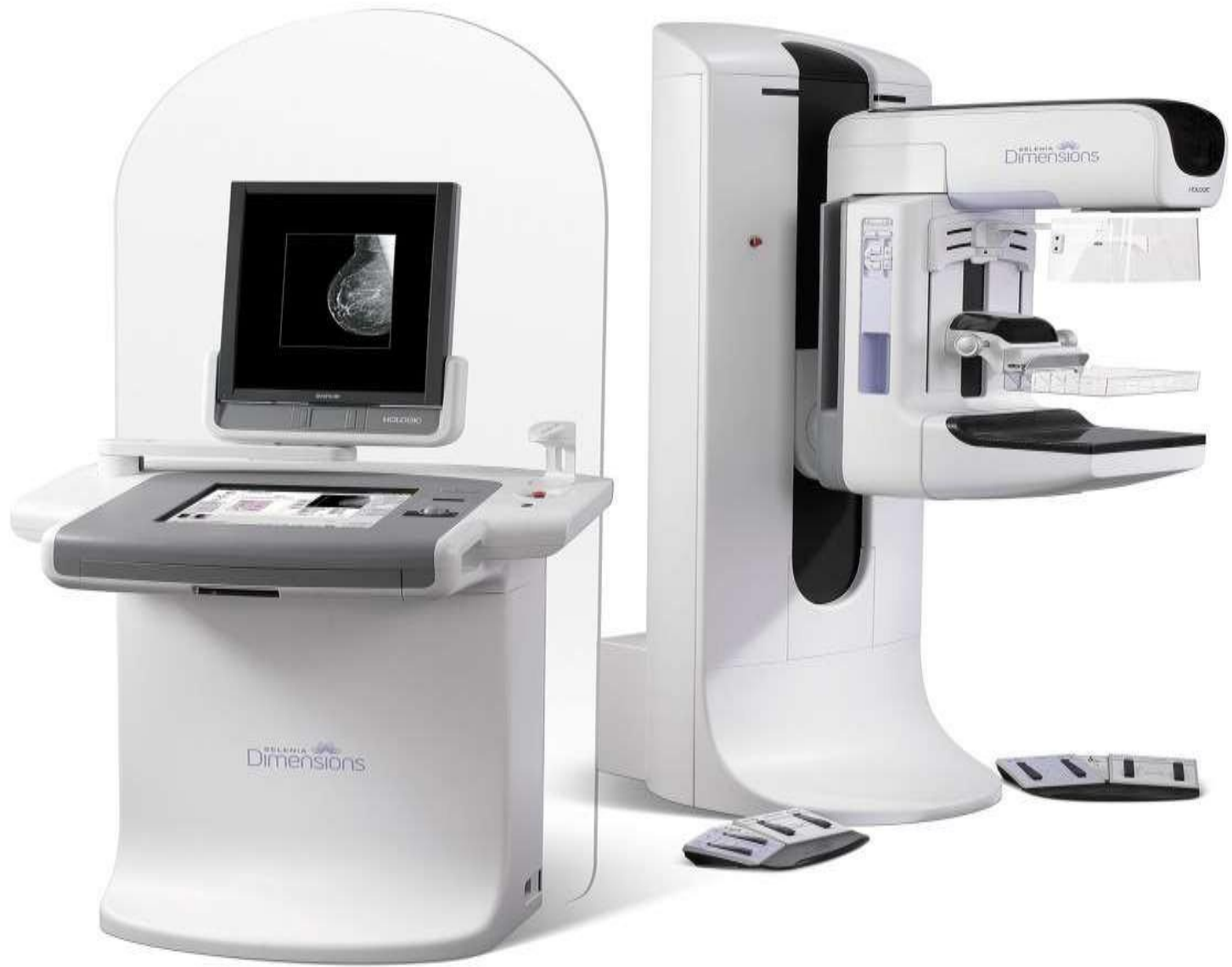- Sexual hormones influence the degree of hydration of the adult breast.
- The breast is more radiolucent and better contrasted in the first part of the menstrual cycle
- Pregnancy and lactation make the glandular and connective tissue structures hypertrophic and more hydrated which leads to diffuse increase in breast density.



# DIGITAL MAMMOGRAPHY

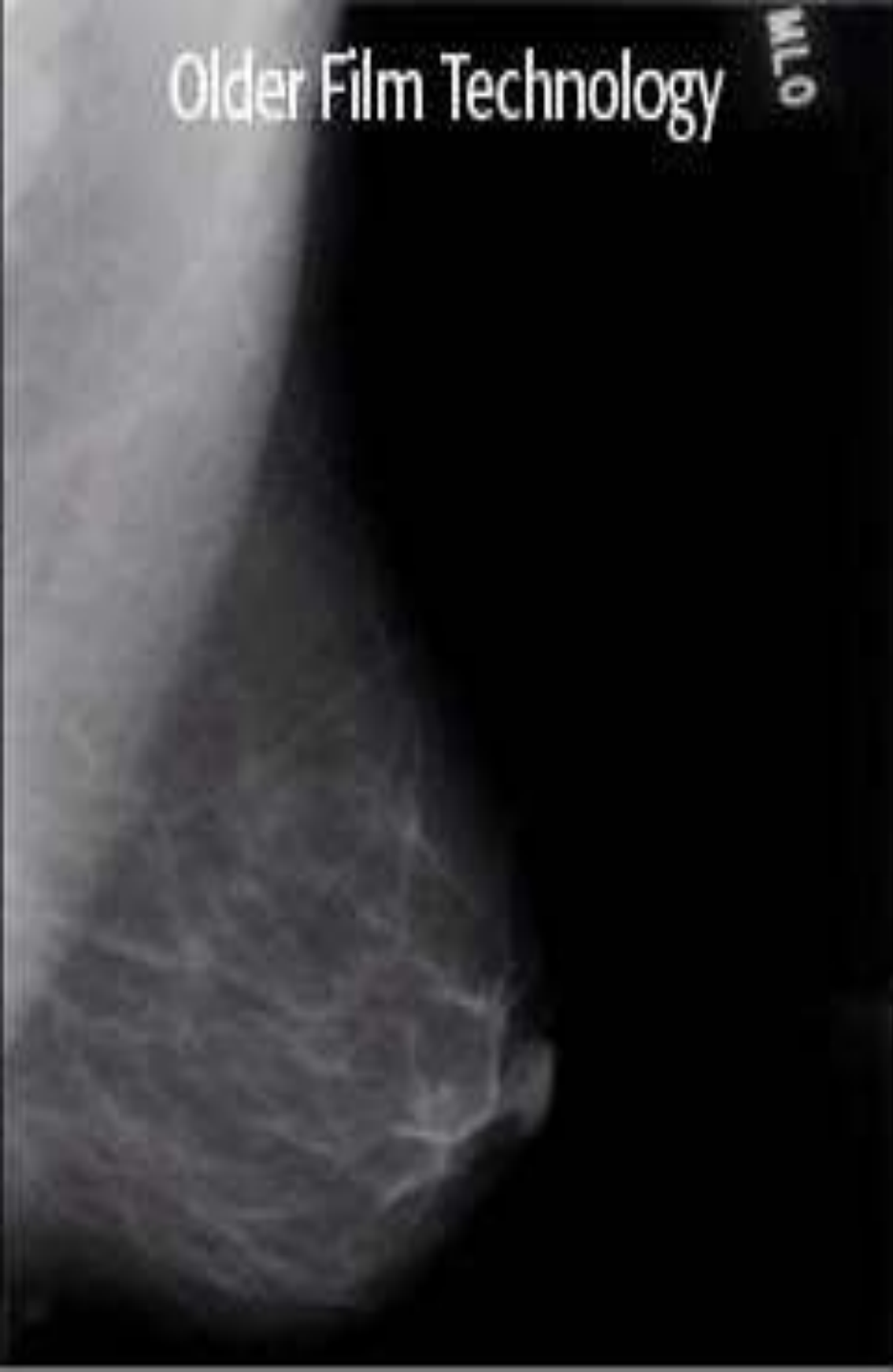- The stages in digital imaging :
  1. Image capture by digital detector
  2. Conversion of latent image into digital data set
  3. Processing of image data
  4. Display of processed image
  5. Transmission and archival of data set





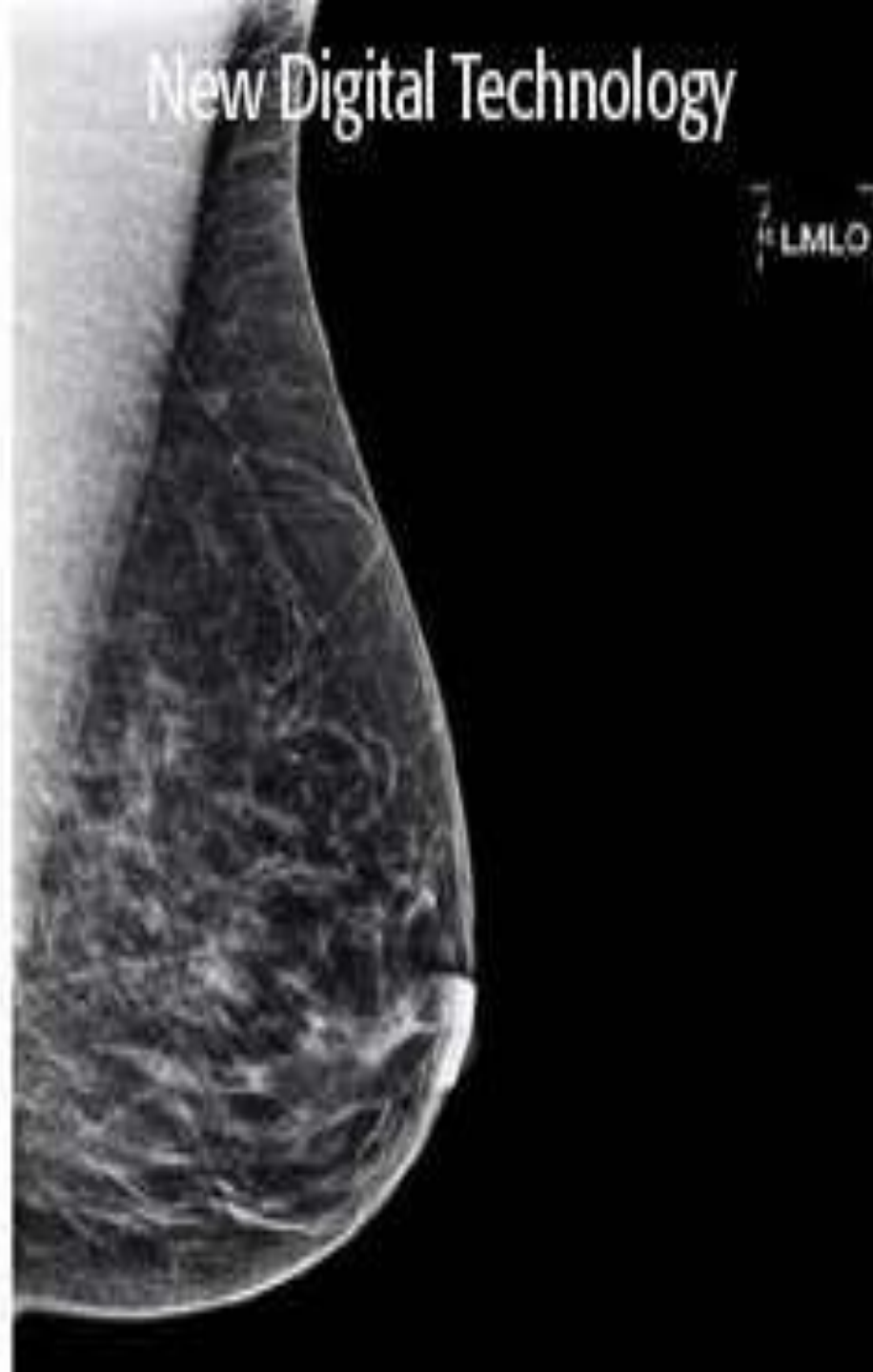Older Film Technology

ML0



New Digital Technology

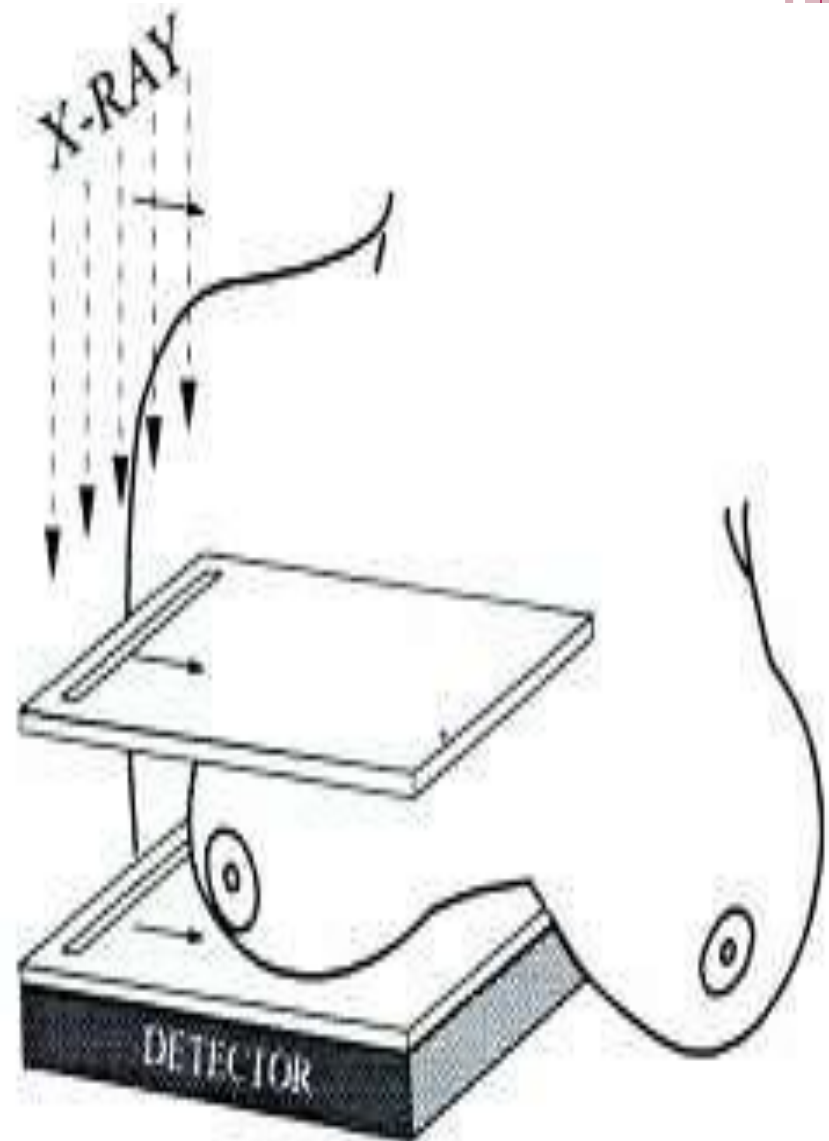
LMLO



# IMAGE ACQUISITION DEVICES

## ❖ CHARGE COUPLE DEVICE TECHNOLOGY

- Digital detectors consist of a phosphor, which is optically coupled to the CCD.
- ADVANTAGE- The slit collimation of the X-ray beam results in a significant reduction in scatter.
- This eliminates the need for a grid, leading to potential dose savings .



# SELENIUM-BASED DETECTORS

- Selenium based detectors consist of a thin layer of amorphous selenium deposited on the imaging plate.
- A uniform positive charge is built up on the surface of the selenium.
- When X-ray photons strike the surface of the selenium, electrons are freed.
- This leads to a partial discharge of the uniform surface charge pattern.
- The degree of discharge reflects the local radiation exposure, leading to a latent image in the form of a charge distribution pattern.
- This charge pattern is then “read” and the resultant electrical signal digitised.



# ADVANTAGES OF DIGITAL MAMMOGRAPHY

1. Acquired in less than a minute as compared to conventional mammography .
2. Spot view digital systems are available to help guide breast biopsy .
3. Superior contrast resolution especially in dense breast tissues
4. Offers the possibility of three dimensional breast tomography using relatively low doses .



# DRAWBACKS

- Until ways are found to increase the spatial resolution of digital mammography, conventional film mammography will remain better able to detect subtle tissue changes such as microcalcifications.
- In dense breast tissues even digital mammography may overlook some lesions that are masked by overlying structures





Thank  
You



# BI-RADS

- CATEGORY 0 -Need additional Imaging evaluation\
- CATEGORY 1 - Negative
- CATEGORY 2-Benign finding
- CATEGORY 3-Probably benign findings
- CATEGORY 4-Suspicious abnormality
- CATEGORY 5 -Highly suggestive of a malignancy

