



The Technical Aspects of Mammography

Robert L. Egan, M.D.

Mammography is the technique for examination of the breast using soft-tissue radiography. Although absorption of radiation by the tissues of the breast does not vary widely, there is sufficient variation in absorption of low-energy radiation between normal and abnormal soft-tissue structures to provide contrast on the radiograph. Soft-tissue radiography makes it possible to study minute details of gross anatomic structures or disease processes in relation to surrounding tissue.

Mammography demands excellent delineation of fine structures, not only for evaluating a lesion, but also for studying surrounding structures in the breast.^{1,2} All the well-established principles of soft-tissue radiography must be applied to achieve the needed radiographic detail: low peak kilovoltage; sufficient milliamperere seconds to provide adequate exposure at low kilovoltage; minimal filtration of the X-ray beam; collimation of the X-ray beam; short object-film distance; fine-grain, high-contrast, direct-exposure film; and careful processing of exposed film. Since successful mammography depends on excellence of radiographic technic, none of these principles can be compromised. Because the radiologist is concerned with gross pathology as

shown on a mammogram viewed with ordinary illumination and a hand magnifying lens, there is a practical limit to the amount of radiographic detail required in the mammogram.

A safe, simple, highly accurate, and reproducible technic using equipment found in any ordinary department of radiology will be outlined in this article. Pertinent roentgenographic factors are summarized in the table. The technic is of necessity a compromise with others that produce even better detail, but physical factors, life of the X-ray tube, radiation dose to the patient, and ability of the patient to cooperate must be considered.

It is agreed that roentgenograms of high technical quality are mandatory because without high quality the radiologist's ability to interpret mammograms suffers. Accordingly, mammography requires supervision by the radiologist. Departures from the technic to be described that result in sacrifice of radiographic detail cannot be recommended.

Positioning

A mammographic examination routinely includes two views of each breast — craniocaudad and mediolateral — and one view of each axilla. Radiographing the breast in two planes at right angles assures good delineation of its quadrants and makes possible localization of nonpalpable structures. The axillary projection permits study of the

Dr. Egan is Chief, Mammography Section, Department of Radiology, Emory University Clinic, Atlanta Georgia.

Reprinted from Medical Radiography and Photography. Volume 42, Number 1, 1966.

tail of the breast and the axillary lymph nodes.

Only one size film, 8 by 10 inches, is needed for mammography. Cranio-caudad and mediolateral radiographs of most breasts can be made on a 5 by 8-inch portion of the film. (The portion not being exposed is covered by a sheet of lead.) Large breasts and axillary radiographs require a full 8 by 10-inch sheet of film.

Markers indicating right or left breast, date, and identification number are placed on the exposure holder face upward and toward the axilla. (See chart, opposite page.) If a mammogram is viewed so that the marker is legible, it is easy to identify the projection and the breast and its quadrants.

It is extremely important that motion be minimized during radiography. To accomplish this, the patient must be relaxed and the breast must be supported and stabilized as though it were not attached to the chest wall. To prevent the exposure holder from moving, sand bags are placed on the portion not being exposed. (See chart.) Breathing is suspended during exposure.

CRANIOCAUDAD PROJECTION. The patient is seated on an adjustable stool at the end of the radiographic table. The exposure holder is inserted beneath the breast and elevated as high as comfort allows, with the undersurface of the breast flat against the exposure holder and the nipple in profile. Care must be taken to avoid wrinkles in the skin of the undersurface of the breast. The shoulder is relaxed, which removes the clavicle and supraclavicular tissue from the path of the X-ray beam. (See chart.) Because of the convexity of the chest wall, the retromammary space is not entirely visualized in the cranio-caudad projection.

MEDIOLATERAL PROJECTION. The patient lies on the radiographic table in an oblique position. The exposure holder is placed beneath the breast against the

chest wall. A block of wood, about 3 inches high, supports that portion of the holder not being exposed. The patient is then rotated to the lateral position until the nipple is in profile; the exposure holder bends and assumes the contour of the chest wall. (See chart.)

Extreme care should be exercised to avoid wrinkles of skin on the undersurface of the breast and along the chest wall. The patient gently retracts the opposite breast with her fingertips. A portion of the rib cage should be included in the radiograph to ensure complete coverage of the base of the breast. (See chart.)

AXILLARY PROJECTION. The patient is rotated about 30 degrees from the supine toward the lateral position. The exposure holder is centered approximately 5 cm. below the apex of the axilla, with the long axis of an 8- by 10-inch sheet of film oriented in the cranio-caudad direction. The breast is not supported but is allowed to hang loose; the humerus is at right angles to the body. (See chart.) The central ray is directed toward the center of the film. The patient was positioned correctly if the radiograph shows the lateral border of the scapula, near its angle, blending with the lateral boundary of the rib cage.

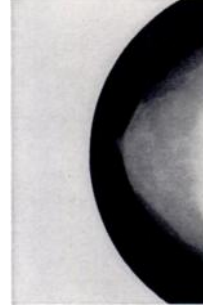
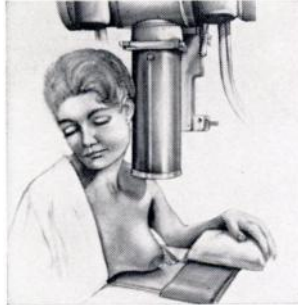Kilovoltage

Adequate radiographic contrast between various structures of the breast is achieved between 20 and 30 KVP; knowledge of the exact kilovoltage is unimportant, since the mammographic technic can be readily established for any X-ray unit. However, at any given setting, X-ray units vary in both quality and quantity of output. For this reason, when standardizing the technic, it is best to make test exposures of an aluminum stepped wedge with the following technical factors: target-film distance, 36 inches; panel control setting, 300 ma.; timer setting, 6 sec-

Radiographic Projections and Technical Factors

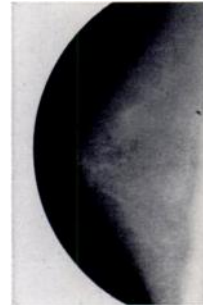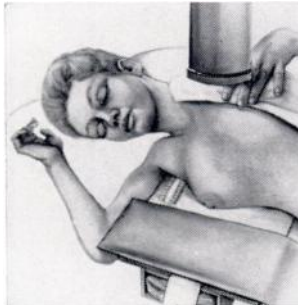Craniocaudad

Ma—300
KvP—26
Time—6 seconds
Target-Film Distance—
22 to 40 inches



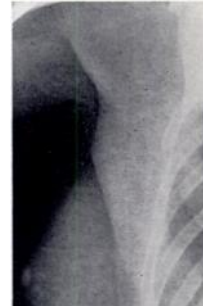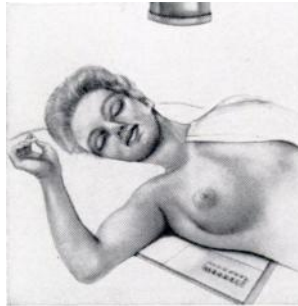Mediolateral

Ma—300
KvP—28
Time—6 seconds
Target-Film Distance—
22 to 40 inches



Axillary

Ma—300
KvP—54
Time—3½ seconds
Target-Film Distance—
Average Patient,
40 inches
Obese Patient,
30 inches



Film — KODAK Industrial X-ray Film, Type M (ESTAR Base), most satisfactory. KODAK Medical X-ray Film for Mammography (ESTAR Base) may be used.

Exposure Holder — Cardboard, with lead back.

Processing — KODAK Industrial X-ray Film, Type M. Process manually in fresh solutions. Development—5 to 8 minutes at 68 F, acid stop bath—30 seconds, fixation—12 to 15 minutes at 68 F, washing—20 minutes in running water.

KODAK Medical X-ray Film for Mammography. Designed to be processed in a KODAK X-OMAT Processor for medical x-ray film using KODAK X-OMAT chemicals.

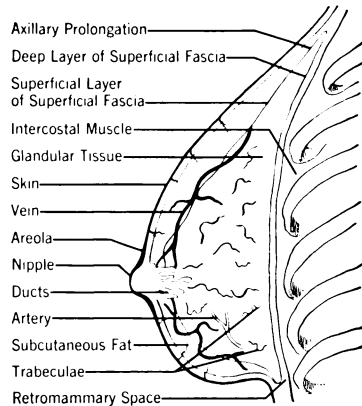
Collimation — Extension cylinder, 4 by 12 inches.

Filtration — Inherent tube filtration only.

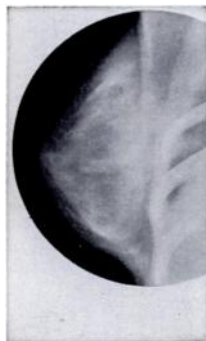INDICATIONS FOR MAMMOGRAPHY

- Signs, Questionable Signs, or Symptoms of Disease of Breast
- Previous Radical Mastectomy
- High Familial Occurrence of Cancer of Breast
- Cancerphobia
- Previous Biopsy (Breast)
- Lumpy or Pendulous Breast
- Adenocarcinoma, Primary Site Undetermined
- Basis for Future Comparison

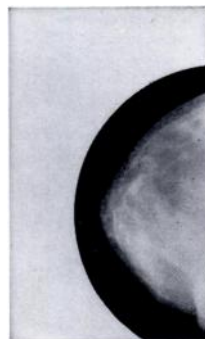
Normal Radiographic Anatomy



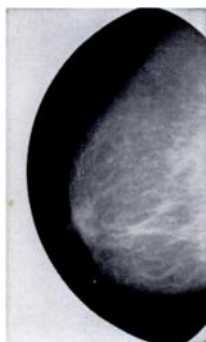
**Anatomic Structures
of Breast That Can Be Identified
on Mammograms**



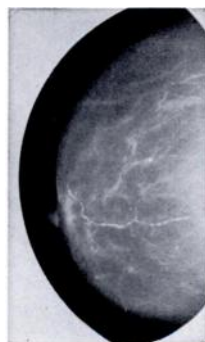
**Adolescent
Breast**



**Young Adult
Breast**



**Menopausal
Breast**



**Postmenopausal
Breast**

onds; film, Kodak Industrial X-ray, Type M (Estar Base), in cardboard exposure holder; collimation and filtration of the X-ray beam and processing of film, as described later in this article.

The kilovoltage is varied until 15 mm. of aluminum are faintly penetrated. The first test exposure of the stepped wedge should be made at the lowest kilovoltage setting on the X-ray unit for three seconds to avoid overloading the X-ray tube.

The kilovoltage required to penetrate 15 mm. of aluminum becomes the standard kilovoltage (peak) setting for the craniocaudal projection; standard plus 2 kv. is used for the mediolateral projection. It may be necessary to add or subtract 2 kv. depending on the desired radiographic density in the mammograms. Axillary mammograms are made at 54 KVP.

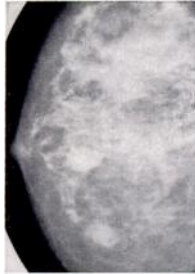
If the kilovoltage meter tends to drift, reproduction of the kilovoltage setting is best accomplished by advancing the necessary major and minor "clicks" from the "0" station.

Milliamperage

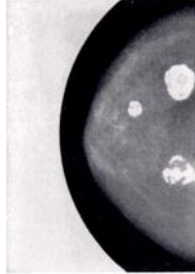
When fine-grain films are exposed without intensifying screens, radiographic detail is enhanced, but more exposure is required per unit of film. High milliamperage and an exposure of several seconds provide the necessary radiation. A milliampere setting of 300 is employed for all three projections, with an exposure time of 6 seconds for the craniocaudal and mediolateral projections and 3½ seconds for the axillary projection. At low kilovoltage, most X-ray units deliver 240 to 260 ma. at a panel setting of 300 because of the space charge effect at the tube filament. Altering the controls for the full output of 300 is unnecessary.

The safety factor for the tube is sufficient provided heating and cooling calculations are based on the full output of milliamperes.

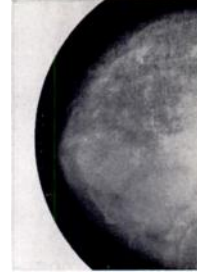
Benign Masses



**Noncalcifying
Fibroadenomata**

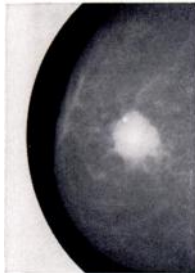


**Calcifying
Fibroadenomata**



**Fibrocystic
Disease**

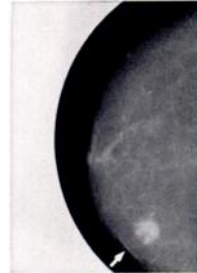
Malignant Masses



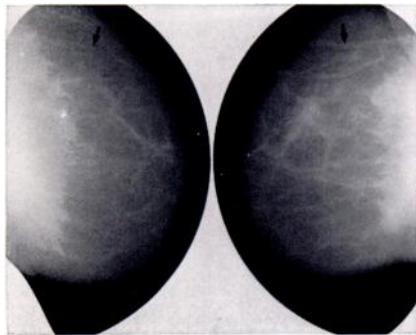
**Infiltrative
Carcinoma**



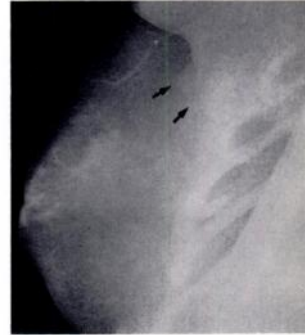**Calcifications
of Carcinoma**



**Changes in Skin
Associated with
Carcinoma**



**Increased Vascularity Because
of Carcinoma (Breast at Right)**



**Metastatic Axillary Nodes
Because of Carcinoma of Breast**

DIFFERENTIAL CRITERIA OF BREAST MASSES

	Benign	Malignant
Shape	Round, Oval, Lobulated	Variable, Ragged, Spiculated, Tentacled
Border	Regular, Smooth, Well Circumscribed	Irregular, Poorly Circumscribed
Size	Same as Palpable Mass	Smaller than Palpable Mass
Density	Homogeneous	Nonhomogeneous
Surrounding Tissue	Displaced, Not Infiltrated	Infiltrated, Retracted
Calcifications	Few, Isolated or Widely Scattered, Coarse	Numerous, Uncountable, Confined to Area of Lesion
Secondary Signs	None	Frequently Present

At the higher kilovoltage used for the axillary radiograph, the calculated output of 1050 Ma.S. (300 Ma.S. at $3\frac{1}{2}$ seconds) is a true value and results in a greater load on the X-ray tube than when craniocaudal or mediolateral radiographs are made (300 ma. at 6 seconds and 26 or 28 kv.)

Time

In mammography, it is far more important to minimize motion than it is to reduce the recommended exposure time of 6 seconds. Motion is the greatest deterrent to good radiographic detail; rhythmic or gross motion is as disadvantageous with an exposure of 1 second as with an exposure of 6 seconds. It is only when exposure time is reduced to 1/20 second or less that the time factor is of real importance in stopping motion.

Exposure time can be readily reduced from 6 to 4 seconds by an increase of 2 kv., but radiographic contrast is sacrificed without reducing motion. Exposure time can be reduced from 6 seconds to 3 if a cone 6 inches in diameter and a target-film distance of 26 inches are used rather than a 4-inch cone at 36 inches. However, blurring of the radiographic image as a result of motion is not reduced and the poorer collimation of the beam results in a greater dose of radiation to the skin and a loss of radiographic detail. Coarse-grain films are faster and require less exposure than Type M Film, but radiographic detail is sacrificed.

Filtration

The inherent filtration of X-ray tubes varies widely but is generally equivalent to about 1 mm. of aluminum. Additional filtration by the equivalent of 0.1 mm. of aluminum only minutely affects radiation dose to the skin. However, if more than 0.2 mm. of aluminum is added to the inherent filtration, radiographic detail suffers appreciably.

Lighting devices for localizing the X-ray beam produce additional filtration equivalent to about 1 mm. of aluminum and must be removed.

Collimation

Proper collimation of the X-ray beam is mandatory for good radiographic detail and for reduction of X-ray dose to the patient. An extension cylinder, 12 inches long with an inside diameter of 4 inches, is employed for mammography, since it provides excellent coning of the beam at the recommended target-film distances of from 22 to 40 inches.

When the average breast is radiographed at distances of less than 20 inches, geometric unsharpness causes loss of radiographic detail. At target-film distances of less than 20 inches, the aperture of the tube housing may be the only collimator affecting the beam.

Target-film distances of less than 22 inches are not sufficient for good collimation, nor is it easy to position either the patient or the cone. Differences in target-film distances automatically adjust exposure for the wide variations in the shapes and sizes of breasts encountered in practice; shaped cones preclude these compensations to a very large degree. Compression cones do not allow for exposure of the entire breast and, because of the sloping contour of the breast, they compress unevenly. They do, however, improve detail of "spot" radiographs.

Minor alterations in the tube housing make it easy to replace an adjustable collimator with an extension cylinder. Metal strips should be welded to the face of the X-ray tube housing to accommodate the extension cylinder. Corresponding metal strips should be welded to the adjustable collimator so that it can be replaced on the altered tube housing. An aluminum filter for use with techniques other than mammography could be incorporated in the base

of the adjustable collimator; thus, the filter would be removed with the collimator.

Target-Film Distance

Target-film distance, the only variable factor in mammography, is adjusted so that the X-ray beam extends half to one inch beyond the periphery of the breast; depending on the size of the breast, the target-film distance for craniocaudad and mediolateral projections may vary from 22 to 40 inches. However, there is no appreciable loss in radiographic detail if the target-film distance is at least 20 inches. For the axillary projection, the target-film distance for the average patient is 40 inches; for the obese, it is reduced to 30 inches.

Variations in the structure of the breast usually compensate for the adjustment of exposure required when the target-film distance is changed. Large breasts contain more fat, lie flatter, and require less exposure than average-sized breasts. Small breasts, which are radiographed at short distances, usually contain less fat and require more exposure.

With subdued room lighting, the glow from the filament is an excellent light localizer for establishing the distance; intensity of light from the filament may be increased by momentarily starting the rotor.

The longer the target-film distance, the less the distortion of anatomic structures (particularly those farthest from the film) and the shorter the object-film distance relatively. The farther the anode is from the patient, the more effective is the collimation of the X-ray beam and the less noticeable the penumbral effect on mammograms made with a 2 mm. focal spot.

Object-Film Distance

Increases in object-film distance reduce radiographic detail more than

abuses of all the other radiographic factors except motion. This is true regardless of the size of the focal spot.

The craniocaudad and mediolateral projections require that the breast be positioned flat against the exposure holder. These projections permit the necessary short object-film distance and eliminate positions embarrassing to the patient.

Several hundred properly positioned breasts were measured at the midpoint; the average thickness was 6 cm.

Film

The aim of mammography is excellent delineation of minute structures. Experience has shown that trabeculae as thin as a spider's web must be identified on a mammogram and that any distortions must be recognized. Minute calcifications, less than 0.1 mm. in size, may be present in the breast but only visible on the mammogram when it is viewed through a hand magnifying lens. The graininess of the film therefore becomes the determining factor, since it is essential that film graininess not interfere with the detection of minute structures under the same magnification. A direct-exposure film must be used to avoid screen mottle and unsharpness.

Kodak Industrial X-ray Film, Type M (Estar Base), has proved the most satisfactory film for mammography. This extremely fine grain, double-coated film records detail optimally and has sufficient exposure factors recommended in this article. It is strongly recommended that broad experience be gained with Type M Film, because familiarity with good mammograms enhances appreciation of any compromise of detail when films such as Kodak Industrial X-ray Film, Type AA (Estar Base), or Kodak Medical X-ray Film for Mammography (Estar Base) are used. Furthermore, with the exposure latitude of Type M Film and with the

compensation for various sizes of breasts made by changing the one variable of target-film distance, double-loading technics offer no advantage over the single film. It is well to remember that one good mammogram is far superior to several inadequate ones.

Kodak Industrial X-ray Film, Type M (Estar Base), may be used in a cardboard exposure holder with lead backing, or in the convenient Ready Pack. The somewhat stiffer cardboard holder is easier to position. If the Ready Pack

is used for the craniocaudad projection, it should be placed on a sheet of lead because the X-ray beam is directed toward the gonads.

Processing

Regardless of the care with which an exposure is made, detail can be lost if the radiographic film is not processed properly. Because the emulsion layer of industrial X-ray film is thicker than that of conventional medical X-ray film, processing is somewhat slower and is

ROENTGENOGRAPHIC FACTORS FOR MAMMOGRAPHY	
Projections	Craniocaudad, mediolateral, and axillary.
Central Ray	Craniocaudad and mediolateral — base of breast. Axillary — 5 cm. below apex of axilla.
Kilovoltage	Craniocaudad and mediolateral — 20 to 30 KVP (exact setting determined by use of aluminum stepped wedge). Axillary — 54 KVP.
Milliamperage	Setting of 300 on X-ray unit.
Time	Craniocaudad and mediolateral — 6 seconds. Axillary — 3½ seconds.
Filtration	Inherent tube filtration only.
Collimation	Extension cylinder, 4 by 12 inches.
Target-Film Distance	To provide coned beam half to one inch beyond periphery of breast. Craniocaudad and mediolateral — 22 to 40 inches. Axillary — average patient, 40 inches; obese patient, 30 inches.
Film	Kodak Industrial X-ray Film, Type M (Estar Base), most satisfactory. Kodak Medical X-ray Film for Mammography (Estar Base) may be used.
Exposure Holder	Cardboard, with lead back.
Processing	Kodak Industrial X-ray Film, Type M. Process manually in fresh solutions. Development — 5 to 8 minutes at 68 F.; acid stop bath — 30 seconds; fixation — 12 to 15 minutes at 68 F.; washing — 20 minutes in running water. Kodak Medical X-ray Film for Mammography. Designed to be processed in a Kodak X-Omat Processor for medical X-ray film using Kodak X-Omat chemicals.

best done by manual technics. Kodak Medical X-ray Film for Mammography (Estar Base) is designed to be processed in a regular Kodak X-Omat Processor for medical X-ray film with Kodak X-Omat chemicals.

The exposed industrial-type film is developed in a fresh solution for 5 minutes at 68 F. with frequent agitation. The film is next agitated in an acid stop bath for 30 seconds to stop development and prevent streaking. It is then fixed in a fresh solution for 12 to 15 minutes at 68 F., with frequent agitation, following which it is washed in running water for approximately 20 minutes.

Automatic processors adjusted for processing medical X-ray films are not suitable for industrial-type films.

Dose

As in all roentgenographic procedures, dose to the patient should be kept as low as possible without sacrificing radiographic detail. The half-value layer of the X-ray beam recommended

is about 1.4 cm. in fat and 1.25 cm. in glandular tissue of the breast. With the craniocaudal projection, the skin receives about 2.4 rads at the central ray of the X-ray beam; with the medio-lateral projection about 2.8 rads are delivered. The center of an average breast receives a total of 3.3 rads when all three projections are used. This does not appear excessive considering that the maximum permissible occupational dose to an extremity is $18\frac{3}{4}$ roentgen equivalents man (REM) each quarter of a year. There is no significant scatter to the eyes or to the gonads.

Note: Illustrations in this article are available in a new chart entitled "Mammography," by Robert L. Egan, M.D., published by the Eastman Kodak Company. The large version (Mk-7) measures 24 by 34 inches and is designed for wall mounting. The small version (Mk-7A) measures 11 by 16 inches. It is folded and has universal punching along the left margin for insertion in an 8½ by 11-inch notebook. These charts may be obtained from your Kodak Technical Sales Representative, Radiography Markets Division, or on request to the Radiography Markets Division, Eastman Kodak Company, Rochester, New York 14650. When ordering, please specify title and code number.

References

1. Seemann, H. E., and Lubberts, G.: *Physical considerations in soft tissue radiography. Med. Radiogr. Photogr.* 40: 20-28, 1964.
2. Seemann, H. E., and Lubberts, G.: *Films for soft-tissue radiography. Med. Radiogr. Photogr.* 41: 18-20, 1965.

ESTABLISHMENT OF SOUTHEASTERN REGIONAL CENTER FOR TROPHOBLASTIC NEOPLASMS

The Department of Obstetrics and Gynecology, Duke University Medical Center, has announced the establishment of the Southeastern Regional Center For Trophoblastic Neoplasms. The Center is sponsored by a Health Service Project Grant Award from the Department of Health, Education, and Welfare, Division of Chronic Disease.

This project in Cancer Control provides urinary gonadotropin assays and consultative assistance to physicians, to aid in evaluating patients who have or are suspected of having abnormalities in trophoblastic tissue growth.

Physicians desiring gonadotropin assays for patients with placental abnormalities as molar degeneration, hydatidiform mole, syncytial endometritis, choriadenoma destruens and choriocarcinoma may call or write the Center at Duke University Medical Center, Durham, North Carolina (Area Code 919-684-8111).

Roy T. Parker, M.D.
C. D. Christian, M.D.
Charles B. Hammond, M.D.