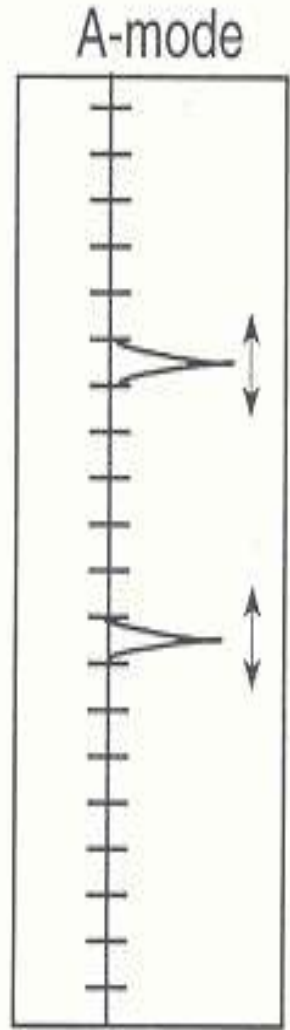
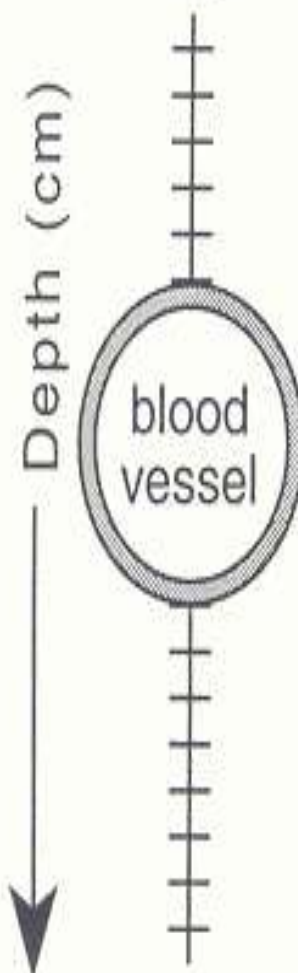
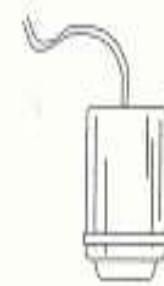

# Image Display Mo

Transducer

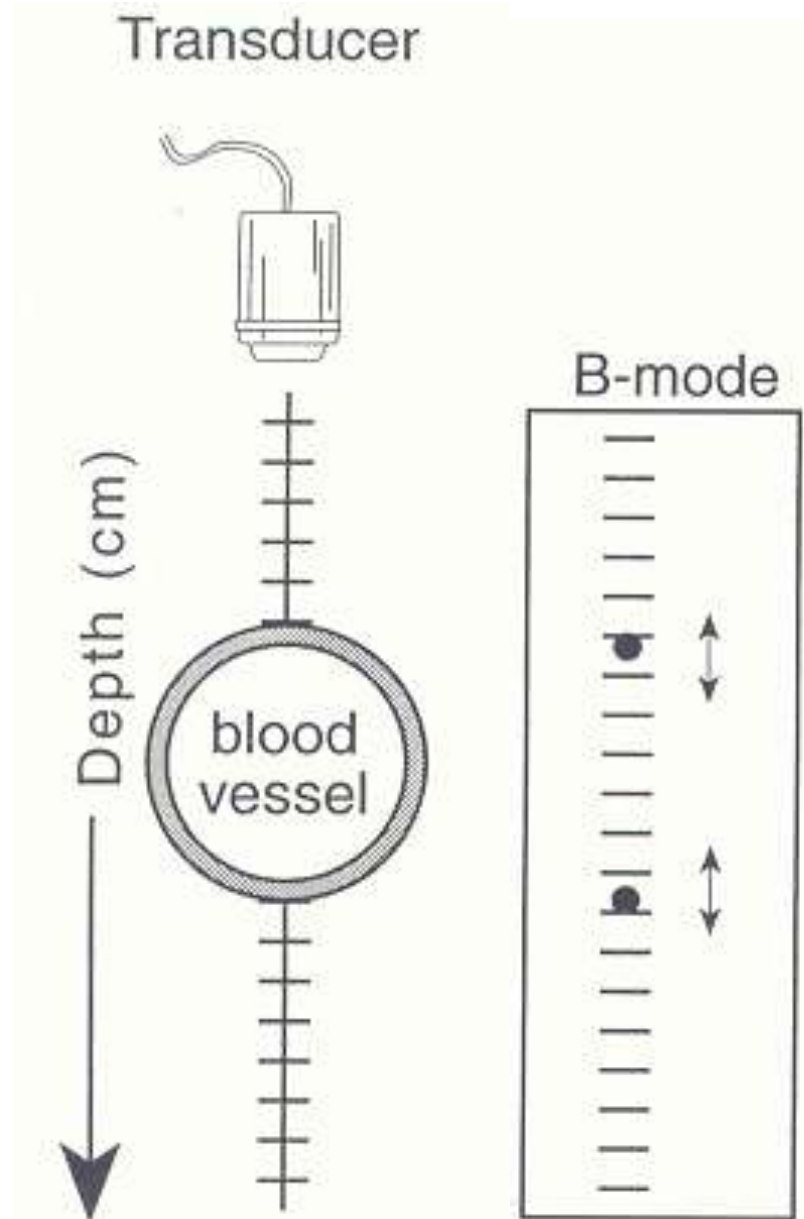


## A-Mode (Amplitude mode)

- Single Ultrasound beam is used
- The returning echoes are shown as peaks along the horizontal axis.
- The height of the peak is directly proportional to the strength of the echo.
- Gives information about the organ boundaries.

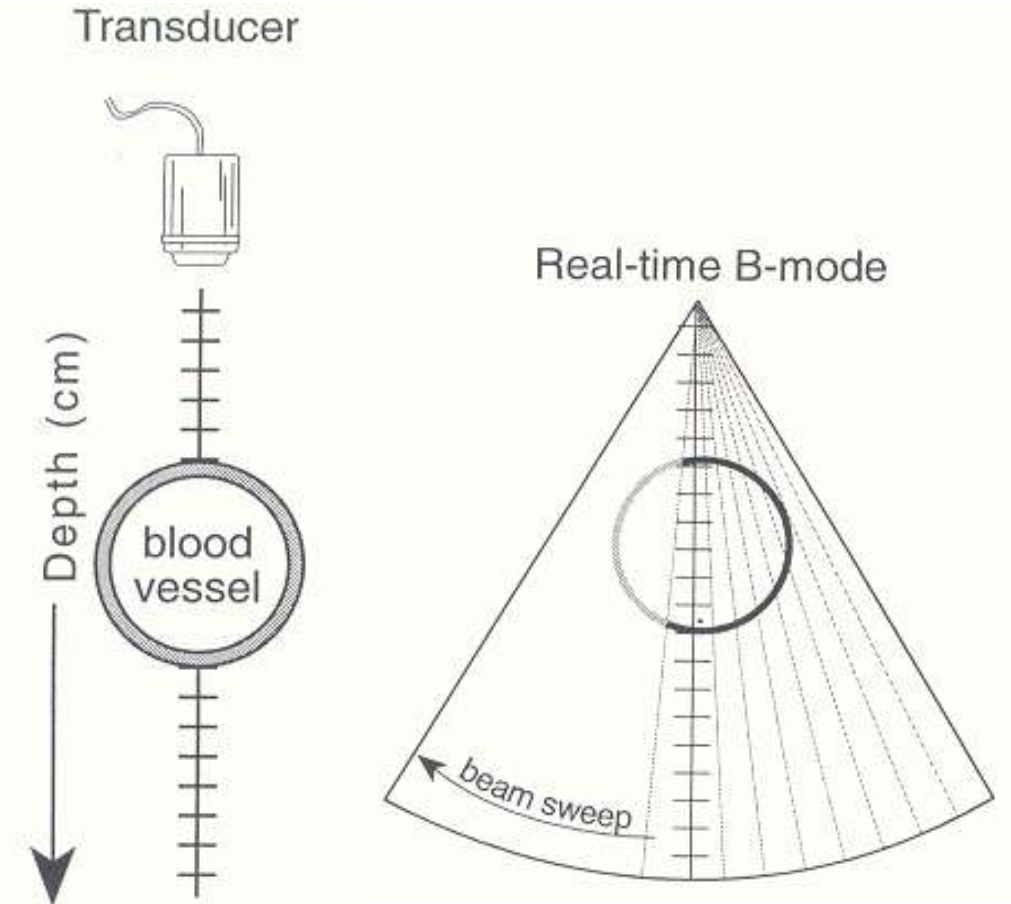
# B-Mode (Brightness mode):

- Multiple Ultrasound beams are used.
- Returning echo is depicted as the dots.
- Brightness of the dot is directly proportional to the strength of the echo.
- So, is also called as the “Grey- Scale imaging”.
- 2D image –
- most popular mode of display



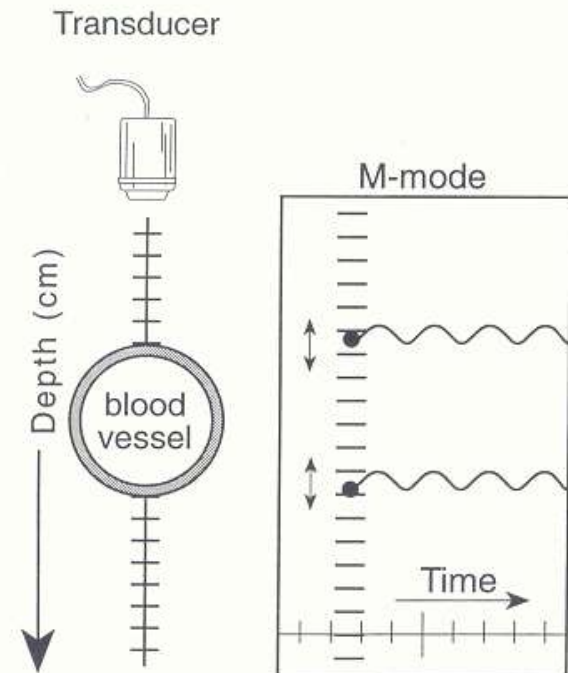
# Real-Time B- Mode Ultrasonography

- Real-time B-mode scanners display a moving gray scale image of cross-sectional anatomy



# M- Mode (Time-Motion mode)

- Single Ultrasound beam is used.
- Returning echoes depicted as dots.
- Position of dot will denote depth of organ -- along the vertical axis.
- Moving structure (Time) on horizontal axis.
- Brightness of dot denote the strength of echo.
- It is used
  - Echocardiography-



# SCANNING PROCEDURE

- **First the organ to be scanned is decided- case history, complaint, symptoms, clinical examination, lab examination, radiological examination etc**
- **With the knowledge of the topographic anatomy, use the 'acoustic window' (Easiest and the nearest site for passing the ultrasound wave into the desired organs)**

# PATIENT PREPARATION

- ✍ **Clip Hairs**
- ✍ **Remove surface dirt/debris with soap / water**
- ✍ **Apply coupling gel liberally**
- ✍ **Massage it on the part to be sonographed with help of the scanner to eliminate air pockets**
- ✍ **Sedation / anesthesia is rarely required except for some small target biopsy procedures**

# POSITIONING OF THE PATIENT

## LATERAL RECUMBENCY

Oblique and frontal scanning of abdomen

Cardiac and pleural imaging

## **DORSAL RECUMBENCY** - abdomen

## STERNAL RECUMBENCY

eye, brain, cranial mediastinum, pleural space, transrectal scanning

## STANDING

Compromised patients, cardiac, thoracic, transrectal, musculoskeletal imaging,  
Diaphragm

# Selection of transducer

- It depends on
  - Size of animals
  - Depth of organ.
- Objective : Choose the highest frequency that will penetrate to the depth needed for the particular examination and gives highest resolution.
- Small dog, cats → 7.5 to 10.0 MHz
- Medium dogs → 5 MHz
- Large dogs → 3.5 to 5.0 MHz
- Large animals → 2.0 to 3.5 MHz



# SCANNING PLANES AND ORIENTATION

SAGITTAL  
PARASAGITTAL  
MIDSAGITTAL



Longitudinal axis of the organ

TRANSVERSE

Divides body or organ into cranial and caudal segments

FRONTAL  
DORSAL  
CORONAL



Perpendicular to the sagittal and transverse planes and divides the body longitudinally into dorsal and ventral segments

# TRANSDUCER MOVEMENTS



**SLIDING**



**ROTATING**



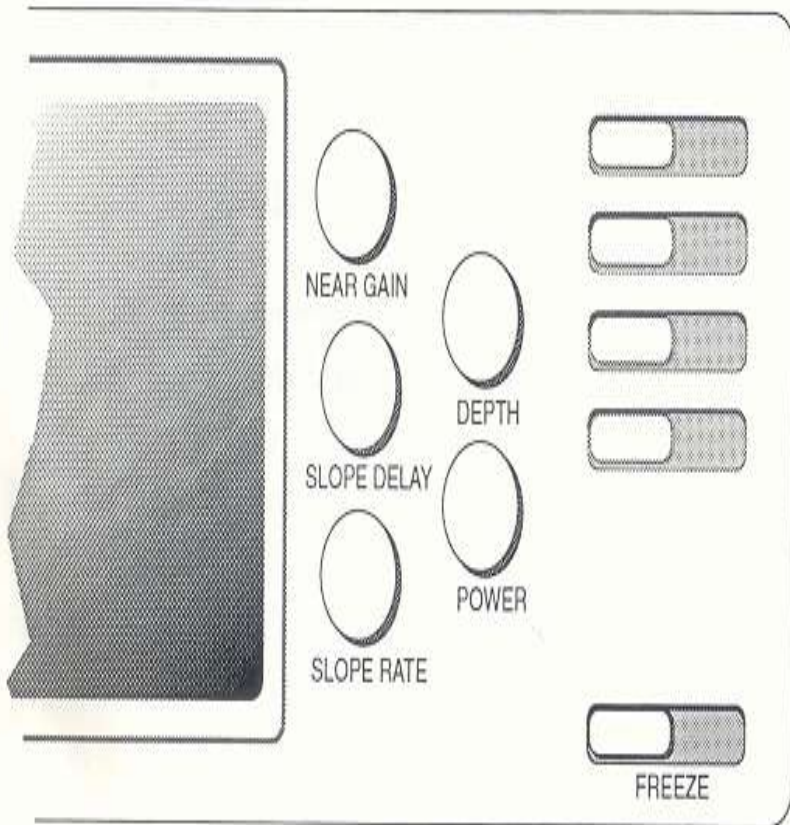
**FANNING**



**ROCKING / ROLLING**

# Scanning controls

## Basic set of controls



- **Near /Far Gain:-** alter amplification of returning echoes
- **Time compensation gain:**
- **Depth-** determine the depth of US image
- **Freeze-** real time image can be temporarily frozen

# IMAGE INTERPRETATION

- **Hyper-echoic / Echogenic /Echo Rich- WHITE AREAS**
  - **Given by highly reflective interface such as bone or air.**
- **Hypo- Echoic / Echo poor- GREY AREAS**
  - **Given by interface of moderate reflection.**
- **Anechoic/echo lucent/echo free- BLACK AREAS**
  - **Denotes the complete transmission of the sound as through the fluids.**
- **Iso echoic-**

**THE STRUCTURE OF TISSUE  
RATHER THAN TISSUE TYPE.**

**•TISSUES IN ORDER OF  
INCREASING ECHOGENECITY**

- Bile, urine**
- Renal medulla**
- Muscle**
- Renal cortex**
- Liver**
- Storage fat**
- Spleen**
- Prostate**
- Renal sinus**
- Structural fat, vessel walls**
- Bone, gas, organ boundaries, calculi**

**● Interpretation based on  
texture of organ**

- **Uniform/ regular  
/homogenous**
- **Non-uniform/ irregular/  
non-homogenous**
- **Fine Granular / Coarse  
Granular**

# **IMAGING OF REPRODUCTIVE TRACT**

## **objectives**

- Presence or absence of a pregnancy**
- Identify the location of the pregnancy –  
intrauterine or extrauterine.**
- Assess the growth and development of the fetus.**
- Placental localization-**
- Assess the amount of liquor amnii.**
- Assess the fetal age.**

# Time of Sonographic recognition of canine fetal structures

Fetal Structure	Days Post-LH Surge	Days Before Parturition (65 ± 1) Based on LH Surge
Gestational sac	20	45
Embryo	23–25	40–42
Cardiac activity	23–25	40–42
Yolk sac, U-shaped	25–28	37–40
Yolk sac, tubular	27–31	34–38
Fetal orientation (head and body)	28	37
Limb buds, fetal movement	35	30
Fetal skeleton	33–39	26–32
Stomach, urinary bladder	35–39	26–30
Lungs — hyperechoic vs. liver	38–42	23–27
Kidneys, eyes	39–47	18–26
Cardiac chambers	40	25
Intestines	57–63	2–8

# 3.TESTES

- **Topography:**
  - Testicles are superficial structures- high freq. transducer used.
  - Non scrotal testicles search should begin in inguinal region.
- **NORMAL APPEARANCE**
  - well circumscribed, smooth outline, oval in shape
  - parenchyma moderately echogenic

**Sagittal image**

**Transverse image**



# IMAGING OF THE THORACIC CAVITY

- Dis advantages: Not easy to image.
  - the rib cage
  - air within the lungs
- Transducer is placed
  - on Inter costal Spaces,
  - behind the xiphisternum
  - at the thoracic inlet.

# DUPLEX DOPPLER ULTRASONOGRAPHY

- Involves the simultaneous use of real time B-Mode imaging and pulsed doppler ultrasound

**PRINCIPLE OF DOPPLER:** Blood cells moving towards transducer give bright echoes & which move away from transducer give weak echoes.

- Towards transducer – red / yellow / orange
- Away from transducer – blue/green

## **FORMS OF DOPPLER**

- **Pulsed Doppler:**
- **Continuous Doppler:**

### **Uses:**

- to identify structures by the presence or absence of blood flow to organ
- to detect thrombus or clot in blood vessel
- to study direction of blood flow & associated abnormality

# **Advantages of ultrasound**

- **It is a non- invasive diagnostic technique**
- **Differentiation of soft tissue abnormalities**
- **Visualization of intra- organ anomaly**
- **Technique can be performed on any patient i.e., old, dyspnoeic and comatose patients**
- **No known harmful effects**
- **Visualiztion of Biopsy being taken.**

# Constraints

- **Ultrasound imaging is not suitable**
  - Examination of tissues lying below bones
  - Air containing organs – lungs, intestine etc
- **Clipping / shaving of hairs –aesthetic value**
- **Application of coupling medium such as mineral oil, aqueous gel - desquamation of cells leading to metastasis.**
- **High capital investment involved**
- **Technical expertise**