

# The IACLE Contact Lens Course

## MODULE 8

### **Special Contact Lens Fitting**

First Edition



*Published in Australia by  
The International Association of Contact Lens Educators*

*First Edition 2006*

© *The International Association of Contact Lens Educators 2006*  
*All rights reserved. No part of this publication may be reproduced, stored in a retrieval system, or transmitted, in any form or by any means, without the prior permission, in writing, of:*

The International Association of Contact Lens Educators

*IACLE Secretariat  
PO Box 6328 UNSW  
SYDNEY NSW 1466  
Australia*

*Tel: (612) 9385 7466  
Fax: (612) 9385 7467  
Email: [iacle@iacle.org](mailto:iacle@iacle.org)*



## Table of Contents

	Page
Acknowledgments.....	v
Contributors .....	vi
Educators' Guide to the IACLE Contact Lens Course.....	ix
Symbols, Abbreviations, and Acronyms Used in the IACLE Contact Lens Course .....	x
Summary of Module 8: Special Contact Lens Fitting .....	xiii
Request for Feedback.....	After xiii
<b>Unit 8.1</b>	<b>1</b>
<b>Course Overview</b>	<b>2</b>
<b>Lecture 8.1 Keratoconus and Contact Lenses</b>	<b>3</b>
<b>Practical 8.1 Keratoconus Fitting</b>	<b>71</b>
<b>Tutorial 8.1 Keratoconus Fitting and Assessment</b>	<b>75</b>
<b>Unit 8.2</b>	<b>81</b>
<b>Course Overview</b>	<b>82</b>
<b>Lecture 8.2 Presbyopia and Contact Lenses</b>	<b>83</b>
<b>Unit 8.3</b>	<b>145</b>
<b>Course Overview</b>	<b>146</b>
<b>Lecture 8.3 Children and Contact Lenses</b>	<b>147</b>
<b>Unit 8.4</b>	<b>179</b>
<b>Course Overview</b>	<b>180</b>
<b>Lecture 8.4 Aphakia and Contact Lenses</b>	<b>181</b>
<b>Practical 8.4 Aphakic Contact Lens Fitting and Assessment</b>	<b>207</b>
<b>Unit 8.5</b>	<b>209</b>
<b>Course Overview</b>	<b>210</b>
<b>Lecture 8.5 Refitting PMMA Lens Wearers</b>	<b>211</b>
<b>Unit 8.6</b>	<b>231</b>
<b>Course Overview</b>	<b>232</b>
<b>Lecture 8.6 Refractive Surgery and Contact Lenses</b>	<b>233</b>

<b>Unit 8.7</b>		<b>317</b>
	<b>Course Overview</b>	<b>318</b>
<b>Lecture 8.7</b>	<b>Therapeutic Contact Lenses</b>	<b>319</b>
<b>Unit 8.8</b>		<b>347</b>
	<b>Course Overview</b>	<b>348</b>
<b>Lecture 8.8</b>	<b>Tinted Contact Lenses</b>	<b>349</b>
<b>Unit 8.9</b>		<b>389</b>
	<b>Course Overview</b>	<b>390</b>
<b>Lecture 8.9</b>	<b>Orthokeratology</b>	<b>391</b>

## Acknowledgments

The IACLE Curriculum Project is the result of a desire to raise the standard of eye-care education, to make contact lens wear safer and more successful, and to develop the contact lens business by creating the educational infrastructure that will produce the teachers, students, and practitioners of the future.

The concept of the world's best educators making available their most creative educational contributions for the common good without any compensation, other than a sense of satisfaction, was born out of IACLE's idealism.

The Curriculum Project could not be successful without the assistance and generosity of a large number of talented and dedicated people. To all those contributors of lectures, laboratory notes, videos, slides, etc, we say *thank you*. Your generosity of spirit will benefit many educators, hundreds of thousands of students, and millions of patients throughout the world.

The Vice President of IACLE, Professor Desmond Fonn, has made a tremendous contribution since the inception of IACLE, and has provided his considerable expertise in the final editing stage of the Curriculum. This project was commenced under Professor Brien Holden's leadership. The original plan and layout for the Curriculum was prepared by Sylvie Sulaiman, IACLE's then Director of Education. Sylvie's dedication and excellent understanding of practitioner and community requirements have given the Project focus and depth.

More recently, the Project has benefited from the work of Dr Lewis Williams, IACLE's Manager of Educational Development. Lewis has also been assisted by Rob Terry's considerable experience and understanding of the contact lens field.

Peter Fagan as Project Editor, and Debbie McDonald as Desktop Publisher, have done excellent jobs on this project. To complement the efforts of the editors, layout coordinators Barry Brown and Shane Parker have done an admirable job, as have the rest of the graphics team. The CCLRU and more recently the Institute for Eye Research, have contributed substantially to this project through the donation of time, resources, and editorial support.

The IACLE global staff, including Executive Secretary Gail van Heerden and, until recently, Special Projects Officer Pamela Capaldi, have managed expertly the considerable tasks of production and distribution.

No acknowledgments page in an IACLE document would be complete without a reference to IACLE's sponsors. Bausch & Lomb have been a major corporate sponsor since 1990, providing the original stimulus for IACLE's growth by contributing both financial support and the involvement of individuals from their International Division. It was Dr Juan Carlos Aragon (when he was at Bausch & Lomb) who first suggested that for IACLE to be taken seriously by industry, it needed a global plan to address the educational requirements for the safe, effective growth of the contact lens business. CIBA Vision and Johnson & Johnson Vision Care are our other major, long-term corporate sponsors. AMO (formerly Allergan) and Ocular Sciences Inc. (now a CooperVision company) have contributed generously as corporate donors, with CooperVision, Alcon Laboratories, and Menicon Europe contributing as IACLE donors.

IACLE is a cooperative effort, and none of its activities is more collective than the Curriculum Project. The IACLE Contact Lens Course that resulted from this project is provided to assist educators in accredited institutions to impart eye-care and contact lens knowledge. All the contributors deserve recognition for their selflessness and talent.

Deborah Sweeney

President of IACLE

## Contributors

### **Desmond Fonn Dip Optom, MOptom**

Professor  
School of Optometry  
University of Waterloo  
Waterloo, Ontario N2L 3G1  
CANADA

### **Robert Terry BOptom, MSc**

Principal Research Optometrist  
Institute for Eye Research  
Sydney NSW 2052  
AUSTRALIA

### **Lewis Williams AQIT (Optom), MOptom, PhD**

Manager: Educational Development  
IACLE Secretariat  
PO Box 6328  
UNSW Sydney NSW 1466  
AUSTRALIA

### **Sonja Cronjé BOptom, MPhil(Optom)**

Director of Education  
IACLE Secretariat  
PO Box 6328  
UNSW Sydney NSW 1466  
AUSTRALIA

### **Ma. Meredith Reyes OD, MA (College Teach.)**

IACLE Secretariat  
PO Box 6328  
UNSW Sydney NSW 1466  
AUSTRALIA

### **Christopher Snyder OD, MS**

Professor  
School of Optometry  
University of Alabama at Birmingham  
Birmingham Alabama 35294  
USA

### **Gina Sorbara OD, MS**

Head, Contact Lens Clinic  
School of Optometry  
University of Waterloo  
Waterloo, Ontario N2L 3G1  
CANADA

### **Editor-In-Chief**

- **Keratoconus and Contact Lenses**
- **Presbyopia**
- **Children and Contact Lenses**
- **Aphakia and Contact Lenses**
- **Refitting PMMA Lens Wearers**
- **Refractive Surgery and Contact Lenses**
- **Therapeutic Contact Lenses**
- **Tinted Contact Lenses**
- **Orthokeratology**

- **Keratoconus and Contact Lenses**
- **Presbyopia**
- **Aphakia and Contact Lens**
- **Refractive Surgery and Contact Lenses**
- **Tinted Contact Lenses**
- **Orthokeratology**

- **Keratoconus and Contact Lenses**
- **Children and Contact Lenses**
- **Orthokeratology**

- **Children and Contact Lenses**
- **Aphakia and Contact Lens**
- **Therapeutic Contact Lenses**

- **Aphakia and Contact Lenses**
- **Refitting PMMA Lens Wearers**
- **Therapeutic Contact Lenses**
- **Tinted Contact Lenses**

- **Aphakia and Contact Lenses**
- **Presbyopia and Contact Lenses**
- **Orthokeratology**

**David Pye BOptom MOptom**

Director of Clinics  
School of Optometry and Vision Science  
UNSW Sydney NSW 2052  
AUSTRALIA

- **Keratoconus and Contact Lenses**
- **Tinted Contact Lenses**

**John Meyler BSc, DCLP**

Director of Professional Affairs  
Johnson & Johnson Vision Care Europe  
Hanworth Road  
Sunbury on Thames  
Middlesex TW16 5LN  
UNITED KINGDOM

- **Presbyopia and Contact Lenses**

**Christine L K Astin MPhil, BSc, DCLP**

Optometrist  
Reading (formerly: Moorfields Eye Hospital &  
Aston University)  
UNITED KINGDOM

- **Aphakia and Contact Lenses**

**Prashant Garg MB BS MS (Ophthalmol)**

Associate Ophthalmologist  
LV Prasad Eye Institute  
Hyderabad 500 034  
INDIA

- **Refractive Surgery and Contact Lenses**
- **Therapeutic Contact Lenses**

**Patrick Caroline COT**

Associate Professor, College of Optometry  
Pacific University  
Forest Grove Oregon  
USA

- **Orthokeratology**

**Russell Lowe BSc(Optom)**

Optometrist  
99 Grattan Street  
Carlton VIC 3053  
AUSTRALIA

- **Orthokeratology**

**Randy Kojima**

Precision Technology Services  
Vancouver BC  
CANADA

- **Orthokeratology**

**Richard Lindsay BScOptom, MBA**

Richard Lindsay & Associates  
5th Floor, 376 Albert Street  
East Melbourne VIC 3002  
AUSTRALIA

- **Keratoconus and Contact Lenses**
- **Aphakia and Contact Lenses**

**Judith Morris BSc (Hons), MSc**

Director  
The Institute of Optometry  
56-62 Newington Causeway  
London SE1 6DS  
UNITED KINGDOM

- Children and Contact Lenses
- Aphakia

**Lyndon Jones BSc, DipCLP, Dip Orth, PhD**

Associate Professor  
School of Optometry  
University of Waterloo  
Waterloo, Ontario N2L 3G1  
CANADA

- Children and Contact Lenses
- Orthokeratology

**Jennifer Choo OD**

Graduate Student  
The Vision Cooperative Research Centre  
UNSW Sydney NSW 2052  
AUSTRALIA

- Orthokeratology

**Alan Saks Dip Optom (SA)**

Optometrist  
Level 1, 280 Queen Street  
Auckland Central 1001  
NEW ZEALAND

- Keratoconus and Contact Lenses
- Refitting the PMMA Lens Wearer

**Rènée du Toit Dip Optom, MPhil(Optom)**

Cornea and Contact Lens Research Unit  
School of Optometry and Vision Science  
UNSW Sydney NSW 2052  
AUSTRALIA

- Presbyopia and Contact Lenses

**Moneisha Gokhale BScOptom**

Optometrist  
LV Prasad Eye Institute  
Hyderabad 500 034  
INDIA

- Children and Contact Lenses

**Les Donovan BOptom**

Senior Research Optometrist  
The Vision Cooperative Research Centre  
UNSW Sydney NSW 2052  
AUSTRALIA

- Refractive Surgery and Contact Lenses

**Kodikullam 'Avudai' Avudainayagam MSc, PhD**

Lecturer  
School of Optometry and Vision Science  
UNSW Sydney NSW 2052  
AUSTRALIA

- Presbyopia and Contact Lenses (Partial)

## Educators Guide to the IACLE Contact Lens Course

### Overview

The IACLE Contact Lens Course is a comprehensive package of educational materials and other resources for teaching the subject of contact lenses. This package was designed to encompass *The IACLE Contact Lens Course Syllabus* and consists of 360 hours of lectures, practicals, and tutorials in 10 modules. It contains material for presentation at basic, intermediate and advanced levels.

The teaching resources have been designed for flexibility. They allow the educator to select the materials appropriate to the students' knowledge and the educational requirements of the class, school, institution, or country.

The English language reference used for the IACLE Contact Lens Course is: Brown L (Ed.). *The New Shorter Oxford English Dictionary*. 1993 ed. Clarendon Press, Oxford (UK). The only spelling exception is *mold* and *mould*. The Oxford dictionary suggests *mould* in all contexts. We chose to use *mold* for manufacturing-related matters and *mould* for fungi since both meanings and spellings appear regularly in the contact lens literature. This differentiation is based on common usage. Where words are 'borrowed' from a language other than English, they are reproduced in their native form where possible.

Where standards have been ratified by the International Organization for Standardization (ISO), or where draft ISO standards are at an advanced stage, their relevant terminology and symbology are used. Système International (SI) units of measure are used wherever possible.

Many major contact lens textbooks from around the world, and some important journal articles, are referenced in the Course, and copyright illustrations are reproduced with permission of the original publishers and/or copyright owners. The References section at the end of each lecture details the information sources used.

### Teaching Resources - Module 8

Module 8 of the IACLE Contact Lens Course consists of the following materials:

#### 1. Contact lens manual

The contact lens manual, containing:

- Course overviews
- Lecture outlines and notes
- Practical outlines, exercises and notes\*
- Tutorial exercises and notes\*

\* *Not all units contain all these sections.*


The recommended allocation of time for the lecture, practical and tutorial components of the module are outlined in the Summary of Module 8 on page xii. The manual provides recommended activities, references, textbooks and evaluation techniques in the interests of standardization. Ultimately, however, the design and methodology of the course is left to the discretion of the contact lens educator.

#### 2. Slides for lectures, practicals, and tutorials

The slides have been numbered according to the sequence in which they appear in each lecture, practical and tutorial. Single or dual slide projection can be accommodated. Each slide has an identification code. This code is based on a cataloguing system in use at the IACLE Secretariat and should be used in any communication with IACLE regarding slides.

#### For example:

To re-order this slide, please quote its identification code



8L8DCP-1

## Symbols, Abbreviations and Acronyms Used in the IACLE Contact Lens Course

SYMBOLS			
↑	increase, high	{	collectively produced by
↓	decrease, low	}	collectively produces
→	produces, towards	Σ	sum of
←	produced by, from	±	plus or minus the value of
↔	no change, not obvious	+	plus, add, include, and
↑↑	significant/great increase	−	minus, reduce
↓↓	significant/great decrease	≈	approximately
%	percentage	=	equal to, the same as
<	less than	&	and, as well as
>	greater than	°	degrees: e.g. 45°
≥	equal to or greater than	@	in the meridian of
≤	equal to or less than	D	dioptries
?	unknown, questionable	X	axis: e.g. −1.00 X 175. −1 D cylinder, axis in 175°
$n, n_{sub}, n_{sub}'$	refractive indices	Δ	prism dioptries or difference
∞	proportional		

ABBREVIATIONS			
μg	microgram (.001 mg)	min	minute, minutes
μL	microlitre (.001 mL)	mL	millilitre (.001L)
μm	micrometre (.001 mm)	mm	millimetre
μmol	micromole, micromolar	mmol	millimole, millimolar
cm	centimetre (.01m)	mOsm	milliosmole
d	day, days	nm	nanometre (10 <sup>-9</sup> m)
Endo.	endothelium	Px	patient
Epi.	epithelium	Rx	prescription
h	hour, hours	s	second, seconds
Inf.	inferior	Sup.	superior
kg	kilogram	t	thickness
L	litre		



ACRONYMS			
ADP	adenosine diphosphate	LPS	levator palpebrae superioris
ATP	adenosine triphosphate	NADPH	nicotinamide adenine dinucleotide phosphate
ATR	against-the-rule	NIBUT	non-invasive break-up time
BS	best sphere	OD	right eye (Latin: <i>oculus dexter</i> )
BUT	break-up time	OO	orbicularis oculi muscle
CCC	central corneal clouding	OS	left eye (Latin: <i>oculus sinister</i> )
CCD	charge-coupled device	OU	both eyes (Latin: <i>oculus uterque</i> - each eye, or <i>oculi uterque</i> - both eyes)
cf.	compared to/with	PD	interpupillary distance
CL	contact lens	PMMA	poly(methyl methacrylate)
Dk	oxygen permeability	R	right
DW	daily wear	R&L	right and left
e.g.	for example (Latin: <i>exempli gratia</i> )	RE	right eye
EW	extended wear	RGP	rigid gas permeable
GAG	glycosaminoglycan	SCL	soft contact lens
GPC	giant papillary conjunctivitis	SL	spectacle lens
HCL	hard contact lens	TBUT	tear break-up time
HVID	horizontal visible iris diameter	TCA	tricarboxylic acid
i.e.	that is (Latin: <i>id est</i> )	UV	ultraviolet
K	keratometry result	VVID	vertical visible iris diameter
L	left	WTR	with-the-rule
LE	left eye		

## Summary of Module 8: Contact Lens Fitting

### Course Program

Lecture			Practical Session			Tutorial (Small Group Teaching)		
Title	Hrs	Level*	Title	Hrs	Level*	Title	Hrs	Level*
L8.1 Keratoconus and Contact Lenses	2	3	P.8.1 Keratoconus Fitting	2	3	T8.1 Keratoconus Fitting and Assessment	1	3
L8.2 Presbyopia and Contact Lenses	2	2						
L8.3 Children and Contact Lenses	2	3						
L8.4 Aphakia and Contact Lenses	2	3	P8.4 Aphakic Contact Lens Fitting and Assessment	2	3			
L8.5 Refitting PMMA Lens Wearers	1	2						
L8.6 Refractive Surgery and Contact Lenses	2	3						
L8.7 Therapeutic Contact Lenses	2	3						
L8.8 Tinted Contact Lenses	2	3						
L8.9 Orthokeratology	1.5	3						

\* Level 1 = Basic: essential knowledge  
 Level 2 = Intermediate: desirable knowledge  
 Level 3 = Advanced: useful knowledge

### Course Time Allocation

Level	Lecture	Practical (Laboratory)	Tutorial (Small Group Teaching)	Total Hours
Basic	0	0	0	0
Intermediate	3	0	0	3
Advanced	13.5	4	1	18.5
<b>TOTAL</b>	<b>16.5</b>	<b>4</b>	<b>1</b>	<b>21.5</b>

## Request for Feedback

This is the first edition of the IACLE Contact Lens Course, and it is our intention to revise and update it periodically. To ensure each revision is an improvement on its predecessor, we request your help. We invite you to provide feedback in the form of comments, corrections, or suggestions that you believe will enhance the accuracy or quality of the Course. Such feedback may then be incorporated in subsequent revisions. We are particularly interested in receiving corrections to, and suggestions for improvements in, the text and slides of the lecture.

To facilitate this feedback process, a *pro forma* is included on the next page. This can be photocopied. Please complete your contact details as the team may wish to discuss your suggestions in greater detail, or seek your assistance with any revision resulting from your input.



# The IACLE Contact Lens Course Feedback / Corrections / Suggestions Form

Name: \_\_\_\_\_ Date: \_\_\_\_\_  
(yy-mm-dd)

Institution: \_\_\_\_\_

Address: \_\_\_\_\_  
\_\_\_\_\_  
\_\_\_\_\_  
\_\_\_\_\_  
\_\_\_\_\_

Module: \_\_\_\_\_ Unit: \_\_\_\_\_ Page Number: \_\_\_\_\_

Slide Code: \_\_\_\_\_ Section: \_\_\_\_\_

Comments:

Thank you

Please return to: IACLE Secretariat  
PO Box 6328  
UNSW SYDNEY NSW 1466  
AUSTRALIA

Office Use Only:  
Response #:  
Forward to:  
Action:



# Unit 8.1

(5 Hours)

**Lecture 8.1:** Keratoconus and Contact Lenses

**Practical 8.1:** Keratoconus Fitting

**Tutorial 8.1:** Keratoconus Fitting and Assessment

## Course Overview

### Lecture 8.1: Keratoconus and Contact Lenses

- I Introduction to Keratoconus
- II Aetiology of Keratoconus and Associated Conditions
- III Symptoms and Signs
- IV Contact Lens Fitting
- V Surgery for Keratoconus
- VI Miscellaneous 'Treatments' for Keratoconus
- VII Conclusions

### Practical 8.1: Keratoconus Fitting

- Lens Types
- Lens Fitting and Assessment
- Acceptability of Fit Achieved

### Tutorial 8.1: Keratoconus Fitting and Assessment

- Video Case Analysis



# Lecture 8.1

(2 Hours)

## Keratoconus and Contact Lenses

## Table of Contents

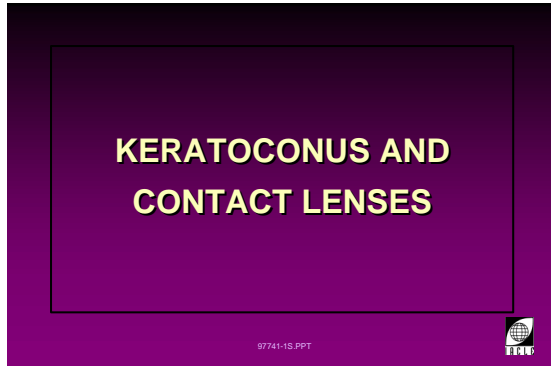
<b>I</b>	<b>Introduction to Keratoconus .....</b>	<b>5</b>
<b>II</b>	<b>Aetiology and Associated Conditions .....</b>	<b>11</b>
<b>III</b>	<b>Symptoms and Signs.....</b>	<b>24</b>
<b>IV</b>	<b>Contact Lens Fitting .....</b>	<b>36</b>
<b>V</b>	<b>Surgery for Keratoconus .....</b>	<b>52</b>
<b>VI</b>	<b>Miscellaneous ‘Treatments’ for Keratoconus .....</b>	<b>60</b>
<b>VII</b>	<b>Conclusions .....</b>	<b>61</b>

Many of the more interesting images in this lecture were contributed by Mr David Pye, Director of Clinics, School of Optometry and Vision Science, the University of New South Wales, Sydney, AUSTRALIA. His slides are identified by the slide ID: 8L1DCP # # #.

Their inclusion has contributed to this lecture significantly and made available to a much wider audience a series of illustrations that few will ever see in routine contact lens practice.

## I Introduction to Keratoconus

1



8L197741-1

### Introduction

Keratoconus, a.k.a. conical cornea, is an interesting, complex, and challenging condition for both the patient and contact lens practitioner alike.

The aetiology of keratoconus is still not well understood, but it would seem to include both genetic and environmental factors. Around the second decade of life (between 12 and 20 but cases have been reported at birth and as late as 51 years of age [Heverly and Lowther, 2005]), the cornea of a keratoconic patient begins to thin and protrude, producing irregular corneal astigmatism.

Despite our ability to detect and document keratoconus, especially in the era of videokeratoscopy, there is still no early treatment or cure, and individual prognosis is highly variable (after Zadnik, 1997). Optimal treatment depends on the severity of the disease process, requires accurate diagnosis, and may require the use of a number of therapeutic alternatives.

Keratoconus can be an inherited corneal abnormality with about 6% (Kennedy *et al.*, 1986), 7% (<http://www.nei.nih.gov/health/cornealdisease/index.asp>) or 10% (Malcaze, 2004) of patients having a family history of the condition. However, because *forme fruste* keratoconus (see later) is not included in most statistical data, the prevalence of familial keratoconus is believed to be higher (Owens and Gamble, 2003; Malecaze, 2004).

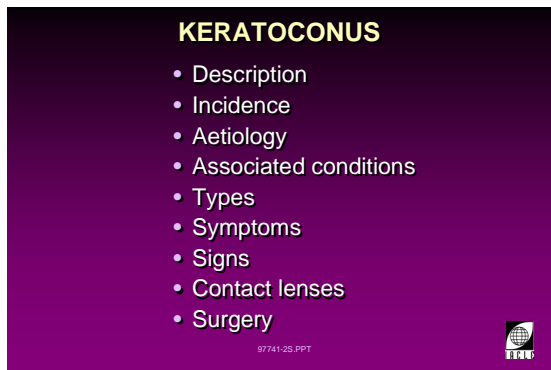
The early stages of keratoconus are usually managed with spectacles and/or contact lenses. Rigid gas permeable (RGP) contact lenses are the correction of choice in most cases, as they give good vision by providing the keratoconic eye with a new, regular, albeit man-made, 'anterior' optical surface. The challenge for the contact lens practitioner is to provide good vision, wearer comfort, and lens tolerance despite the fact that the cornea may be changing shape frequently. The progression of the disease, as well as the fit of the contact lenses, must be monitored closely at regular, scheduled after-care examinations because symptomless adverse responses are possible (McMonnies, 2004).

Compared with the normal eye, the keratoconic eye exhibits greater diurnal variation in refraction as measured by an autorefractor (Rubin *et al.*, 2004).

If the progress of the disease is marked by the following issues, surgical options may have to be considered:

- Increased RGP lens intolerance.
- The development of stromal opacities.
- Corneal hydrops.
- Significant lens decentration and/or an inability to retain lenses on the eyes.
- Increased astigmatism/irregular astigmatism.

2




8L197741-2

3

**REASONS FOR PKs**

Cursiefen *et al.*, 1998 Germany    Liu & Slomovic, 1997 Canada    Aust Corneal Graft Register, 1993

Keratoconus	Bullous keratopathy (pseudophakic)	Keratoconus
Corneal scars (keratitis or trauma)	Regrafts	Bullous keratopathy (pseudophakic, aphakic)
Bullous keratopathy (pseudophakic, aphakic)	Keratoconus	Regrafts
Regrafts	Fuchs' dystrophy	Corneal scars/opacities
Fuchs' dystrophy	Bullous keratopathy (aphakic)	Corneal dystrophies
Necrotizing ulcerative keratitis	Herpetic keratopathy	Corneal ulcers
Corneal dystrophies	Bacterial infection	Herpetic infections

97741-65S.PPT 


8L197741-65

4

**REASONS FOR PKs**

The Merck Manual, 2005 USA    Chen *et al.*, 2001 Taiwan    Al-Yousuf *et al.*, 2004 UK

Bullous keratopathy (pseudophakic, Fuchs', aphakic)	Corneal scars	Regrafts
Keratoconus	Regrafts	Keratoconus
Regrafts	Acute necrotizing & ulcerative keratitis	Fuchs' dystrophy
Keratitis/postkeratitis (viral, bacterial, fungal, Acanthamoeba, perforation)	Bullous keratopathy (pseudophakic, aphakic)	Bullous keratopathy (pseudophakic)
Stromal dystrophies	Fuchs' dystrophy	Viral keratitis
	Keratoconus	

97741-64S.PPT 

8L197741-64

Keratoconus is a leading indication for corneal transplantation (Penetrating Keratoplasty [PK]). The reasons for performing a PK according to several sources appear in descending order in slides 3 and 4. It is noteworthy that the data's country of origin influences the rankings but that generally, the same basic reasons appear in all sources. Other rankings of the indications for PK exist, e.g. see Mamalis *et al.*, 1992 and the references used therein.

The position of keratoconus within these rankings (top three for all sources except Taiwan) is at least partially due to racial differences. Chen *et al.* (Taiwan) reported 'an extremely low frequency of keratoconus compared with previous reports'.

Due largely to newer, often genetic, technologies developed over the last quarter of the 20th Century, our understanding of this complex condition has improved (see review in Kenney and Brown, 2003). Ultimately, a greater understanding may lead to measures that retard the onset or progression of this disease. Given that genetic factors are implicated in at least 70% of European familial keratoconus and that the *region* of the human genome harbouring the mutated keratoconus gene has been identified (the actual gene itself is still to be identified but in some Down Syndrome [trisomy 21] cases, it is believed to be located on chromosome 21 [Rabinowitz *et al.*, 1999, 2000]) (Malcaze, 2004), it is probable that progress on the genetic keratoconus front will be tied to progress on the genetic 'engineering' front generally.

In addition to chromosome 21, other chromosomes have been shown to be involved in cases of keratoconus and include:


- 2p24 (McKusick *et al.*, 1986 to 2004, Hutchings *et al.*, 2005).
- 3p14 to q13 (Brancati *et al.*, 2004).
- 16q22.3 to q23.1 (Tynynmaa *et al.*, 2002).
- 18p, 20q12 and 2p24 (see Hutchings *et al.*, 2005).
- 17 (along with Leber's Congenital Amaurosis) and 13 (see Heaven, 2000, Kenney and Brown, 2003).
- Mutations (R166W, L159M, D144E, G160D [questionable], P247R, and L17P) of the *VSX1* (homeobox) gene (Héon *et al.*, 2002, Bisceglia *et al.*, 2005).

5

**DESCRIPTION**

Keratoconus is a benign, usually bilateral, non-inflammatory thinning and ectasia of the cornea, resulting in a high degree of irregular myopic astigmatism

97741-03.PPT



8L197741-3

**Description of Keratoconus**

Not only is keratoconus one of the most common corneal dystrophies, it is also among the most disabling visually. It is a non-inflammatory, progressive thinning of the cornea that results in apical protrusion (ectasia) driven at least partly by intraocular pressure (IOP).

Based on calculations that suggest a conservation of corneal surface area (at around 120 mm<sup>2</sup>), Smolek and Klyce (2000) argue that keratoconus is not a true ectasia but a specialized type of corneal warpage, at least in mild to moderate forms of the disease. Keratoglobus was shown to probably be a true ectasia.

The protrusion usually develops in the infero-central zone of the cornea (slide 6) that results in a cone-like anterior protrusion exhibiting a high degree of irregular, myopic astigmatism, and marked visual impairment (data in slide 7 comes from the Collaborative Longitudinal Evaluation of Keratoconus Study [CLEK]).

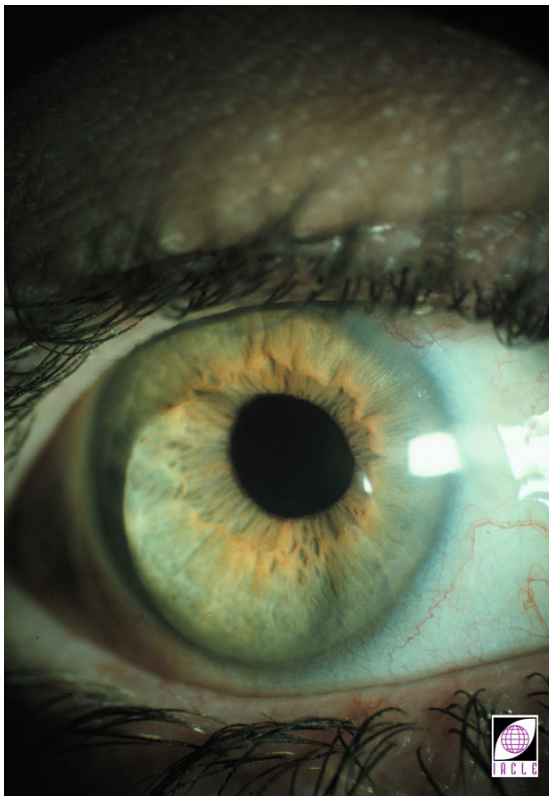
The condition typically, though not always, affects young people in the second or third decades of their lives (see earlier).

Classically, these signs are not accompanied by any apparent corneal inflammation. While the early stages of the disease usually involve irregular corneal astigmatism with inferior corneal steepening, later stages may involve a cornea that is relatively flat centrally but very steep inferiorly. This can result in hyperopic rather than myopic astigmatism.

Although keratoconus usually occurs bilaterally, the onset of the disease may occur at different times in each eye, i.e. the onset is staggered chronologically and the condition is seldom symmetrical (e.g. slide 8). However, true monocular keratoconus is rare and the cases reported appear to represent variable gene expression (Phillips, 2003). The possibility that all cases of unilateral keratoconus may eventually become bilateral always exists (Holland *et al.*, 1997). Li *et al.* (2004) reported that approximately half of the clinically normal fellow eyes of unilateral keratoconics progressed to keratoconus within 16 years, most within the first 6 years. Therefore, it would be imprudent to perform a refractive surgical procedure on an apparently normal cornea once keratoconus has been diagnosed in the fellow eye.

The undeveloped forme fruste form of keratoconus (detailed later under Section **III Symptoms and Signs, Delayed Onset Keratoconus**) could also be mentioned here because the advent of videokeratoscopes has increased dramatically, the apparent incidence of the condition. This is a result of the instrument's greater ability to detect regional, inferior corneal steepening, a hallmark of *forme fruste* keratoconus.

6




8L10640-97

7

**KERATOCONUS  
CLEK DATA: CORNEA**

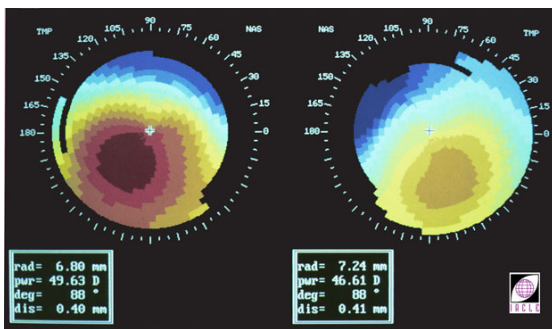
<i>Normals: 60 Eyes</i>	<i>Keratoconics: 690 Eyes</i>
• 44.37 D (SD 1.6 D)	• 48.02 D (SD 3.88 D)
• 0.50 D Cyl (SD 0.18 D)	• 2.46 D Cyl (SD 0.99 D)
• Axis 175°	• Axis 26°
• Corneal Tilt: 0.38° (SD 0.11)	• Corneal Tilt: 3.94° (SD 1.45)
• Base-Apex line: 56° - 236°	• Base-Apex line: 69° - 249°

97741-73.PPT **Raasch et al., 1998**



8L197741-73

8



8L1DCP 4 3 20

According to Rabinowitz (1995, 1998), a diagnosis of keratoconus can be made if the patient has keratometry readings greater than 47.20 D, inferior corneal steepening of more than 1.20 D greater than the superior cornea, and skewing of the radial axis of astigmatism by more than 21 degrees.

Maruyama *et al.* (2000) investigated whether certain keratoconus characteristics, e.g. cathepsin B & G,  $\alpha$ 1-protease inhibitors (reduced),  $\alpha$ 2-macroglobulin (reduced), and transcription factor Sp1, are also present in the conjunctiva of keratoconics. Their data suggests that keratoconus is a disease localized to the cornea and involves the epithelium and stroma (Maruyama *et al.*, 2001). Furthermore, using three-dimensional scanning electron microscopy, Sawaguchi *et al.* (1998) demonstrated alterations to Bowman's layer specific to keratoconus. However, Dogru *et al.* (2003) did show increased conjunctival squamous metaplasia in keratoconus. Maruyama *et al.* (2002) confirmed an inverse relationship between  $\alpha$ 1-protease inhibitor ( $\alpha$ 1-P1, gene is reduced in keratoconus probably by Sp1-mediated downregulation [Maruyama *et al.*, 2001]) and transcription factor Sp 1 (increased in keratoconus). Confounding their results was an interaction between the distal and proximal Sp 1 sites.

9

**KERATOCONUS**  
ABNORMALITIES IN THE CONJUNCTIVA TOO?  
*Maruyama et al., 2000*

**No!**  
Keratoconus seems to be a corneal disease

Abnormalities studied ( $\uparrow$  or  $\downarrow$  in keratoconus):

- Cathepsin B & G ( $\uparrow$ )
- $\alpha$ 1-protease inhibitors ( $\downarrow$ )
- $\alpha$ 2-macroglobulin ( $\downarrow$ )
- Transcription factor Sp1 ( $\uparrow$ )

97741-82S.PPT

8L197741-82

Wollensak and Buddecke (1990) reported that keratoconic corneas had increased ratios of dermatan sulphate to keratin sulphate proteoglycans, compared with normal corneas.

10

**KERATOCONUS**  
SOME OTHER CHARACTERISTICS  
*Cf. the normal eye, the keratoconic eye has:*

- $\downarrow$  corneal sensitivity
- $\downarrow$  BUTs
- $\uparrow$  sodium fluorescein staining
- $\uparrow$  Rose Bengal staining
- $\downarrow$  goblet cell density
- Conjunctival squamous metaplasia
- Disordered tear quality

Most aspects worsen with disease progression

Dogru et al., 2003

97741-93S.PPT

8L197741-93

Gondhowiardjo and van Haeringen (1993) and Gondhowiardjo *et al.* (1993) reported alterations to corneal aldehyde dehydrogenase in keratoconus, alterations that could be mimicked *in vitro* by reduced glutathione. Later, Pappa *et al.* (2003) confirmed the metabolic function of aldehyde dehydrogenase 3A1 (present only in the epithelium and stromal keratocytes according to the authors) as a corneal defense mechanism against oxidative damage caused by aldehydic products of lipid peroxidation.

Meek *et al.* (2005) reported that keratoconus involves a high degree of inter and probably intralaminar displacement and slippage of collagen fibrils.

11

**PREVALENCE**

Cyprus	1 : 3,000
UK	1 : 10,000
USA	1 : 13,000
Holland	1 : 40,000

97741-4S.PPT

8L197741-4

**Prevalence and Incidence of Keratoconus**

The prevalence of keratoconus is difficult to ascertain and there is significant variability in the data available. Figures as high as 600 per 100,000 (Ponzin, 2001) and as low as 3 per 100,000 have been presented (slide 11). This may be due, at least partially, to the use of differing diagnostic criteria in the studies presenting prevalence data. Further, keratoconus may be more common in some ethnic/racial groups, certain geographical regions, or within population pockets within regions, at least partly because of the probable genetic component(s) of the disease. This is especially relevant to studies of populations where marriage



12

### INCIDENCE

- About 1 in 2000 in general population
- More common in hot, dry climates
- Sexes affected equally
- Onset may be earlier in females
- More common in some racial and ethnic groups

97741-5B.PPT



8L197741-5

between blood relatives is permitted and/or common (see studies by Pearson *et al.*, 2000 and Georgiou *et al.*, 2004).

The incidence of keratoconus has been reported as 2 per 100,000 per year with a prevalence of 55 per 100,000 (after Kennedy *et al.*, 1986).

It is generally accepted that a higher incidence of keratoconus exists in countries that have hot, dry, and dusty, tropical and sub-tropical climates.

Compounding such factors are apparent differences between some racial and ethnic groups, e.g. Pearson *et al.* (2000) reported a 4X increase in the incidence of keratoconus in Asians compared with Caucasian patients and Georgiou *et al.* (2004) reported a 7.6X difference between Asian and Caucasian patients (the Asians in these studies were largely from the Indian continent, i.e. of Indian/Pakistani/Bangladeshi origin living in the UK). Furthermore, Asian keratoconics are generally younger at first presentation of the condition and require corneal grafting at an earlier age should their condition progress to that extent (Pearson *et al.*, 2000). The majority of Asian/Indian keratoconics demonstrate the severe stage of keratoconus (Pearson *et al.*, 2000; Saini *et al.*, 2004) by the second decade (Saini *et al.*, 2004).

Some claim that approximately equal numbers of males and females are diagnosed with keratoconus (see summary in Herverly and Lowther, 2005). However, some claim that males exhibit keratoconus more frequently (e.g. Kennedy *et al.*, 1986; CLEK Baseline Statistics, 1999; Lim and Vogt, 2002; Owens and Gamble, 2003) while others claim that females are more affected, although even in this aspect of the published data, considerable variation exists. Onset may be earlier in females than in males (Olivares Jimenez *et al.*, 1997) or earlier in males than females (Owens and Gamble, 2003). Kennedy *et al.* (1986) reported the condition peaked earlier in males while Al-Yousuf *et al.*, 2004 reported more males underwent PK in their retrospective study spanning 10 years.

According to Ruben and Khoo (1989) most cases of keratoconus present between the ages of 12 and 25 and the pubertal significance cannot be overlooked.

Over a 1-year period, more than 16% of patients attending a tertiary specialist contact lens clinic at a UK hospital had keratoconus. During the study, the mean age of the predominantly male patients was 34.9 years while the mean of their age at first referral to the centre was 28.6 years (Lim and Vogt, 2002).

13

**KERATOCONUS  
LIFE EXPECTANCY**

The life expectancy of keratoconics is not significantly different from that of the general population

Moodaley *et al.*, 1992



97741407S.PPT

8L197741-67

**Life Expectancy**

Partly because contact lens practitioners can often be heard asking the question “Where do older keratoconics disappear to?” it was assumed that a contributing factor may have been a shorter life expectancy. This has been shown to be untrue, i.e. the life expectancy of keratoconics is no different from that of the general population when all relevant factors are accounted for (Moodaley *et al.*, 1992).

Further, some keratoconics are lost to contact lens practitioner follow-up because they undergo PK and may seek alternative sources of after-care subsequently.

Conversely, some keratoconics go through life visually handicapped because they were not corrected with contact lenses or by surgery. Such cases can be corrected successfully even late in life.



## II Aetiology and Associated Conditions

14

### AETIOLOGY

- Not clearly established
- Collagen abnormality is implicated
- Familial tendency is slight
- Mode of hereditary transmission is unclear
- Environmental factors
  - atopy
  - eye rubbing ?

97741-6S.PPT



8L197741-6

15

### KERATOCONIC CORNEAS LABORATORY OBSERVATIONS

- Abnormal Epithelial Basement Membranes (EBMs) (Kenney *et al.*, 1996)
- Abnormal stromal components in areas of subepithelial fibrosis & stromal scars (Kenney *et al.*, 1996) (result of a repair [wound-healing] mechanism?)
- Abnormal ExtraCellular Matrices (ECMs)
  - may reflect ↑ protease activity locally (Kenney *et al.*, 1997)
- ↑ expression of IGF-1 & TGF-β2 (healing-related growth factors [→ remodelling & fibrosis]) (Kenney *et al.*, 2000)
- ↓ TIMP-1 mRNA (an inhibitor of matrix metalloproteinases) & ↑ cathepsin V mRNA (related to breaks in Bowman's layer?) (Kenney *et al.*, 2000)

97741-6S.S.PPT



8L197741-69

16

### KERATOCONIC CORNEAS LABORATORY OBSERVATIONS

- ↓ in the mRNA: GRP78(BIP), a protein involved in protein folding in the endoplasmic reticulum (Brown *et al.*, 1998)
- ↑ in the mRNA: CD45, a membrane-bound receptor with phosphotyrosine phosphatase activity (Brown *et al.*, 1997)
- ↑ cathepsins V/L2, -B, and -G (that can ↑ H<sub>2</sub>O<sub>2</sub> production that in turn can ↑ catalase, an antioxidant enzyme) (Kenney *et al.*, 2005)
- ↓ TIMP-1 (Kenney *et al.*, 2000, 2005)
  - the combination of ↑ cathepsin V/L2 & ↓ TIMP-1 may → matrix degradation
  - supports the hypothesis that oxidative stress & tissue degradation occur in the keratoconic cornea

8L1-16S.PPT



8L197741-70

17

### KERATOCONIC CORNEAS LABORATORY OBSERVATIONS

- ↑ mitochondrial DNA (mtDNA) damage (deletions & mutations)
  - ↑ oxidative stress & ↓ integrity of mtDNA may be interrelated & involved in the pathogenesis of keratoconus
  - ↓ mtDNA-to-nDNA ratio (Attilano *et al.*, 2005)
- ↑ levels of malondialdehyde (cytotoxic) & peroxynitrite (from superoxides & nitric oxide) – both damage DNA
- ↓ VEGF RNA but other corneal diseases also show this effect (Saghizadeh *et al.*, 2001)
- ↑ stromal keratocan (a mRNA that is one of three corneal keratan sulphate proteoglycans believed to be involved in the maintenance of the stromal matrix & corneal transparency
  - altered stromal fibrillogenesis → structural defects? (Wentz-Hunter *et al.*, 2001)
- ↑ mtDNA

97741-74S.PPT



8L197741-74

### Aetiology of Keratoconus

Although the aetiology of keratoconus is not fully understood, it is probably multifactorial or it represents the final common pathway for a variety of different pathological processes (Edwards *et al.*, 2001). While heredity is believed to be a factor (see below), associations with collagen abnormalities and other atopic diseases have been suggested as additional possible factors (see later). The evidence implicates an abnormality of stromal collagen tissue.

Most cases are apparently isolated and some authors refer to such cases as 'sporadic'.

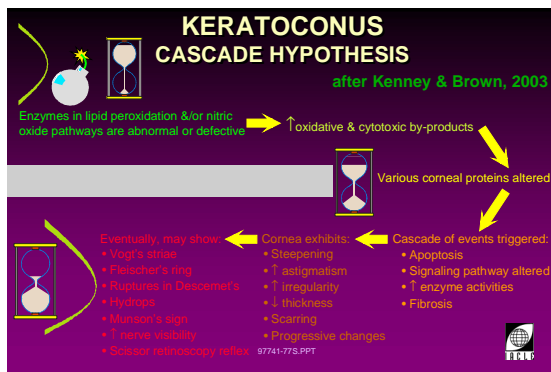
### Genetic

While intuitively genetics has a role, if not the central role, in the aetiology of keratoconus, not all data is supportive unequivocally, e.g. McMahon *et al.* (1997) (CLEK study) reported on two pairs of discordant (at least for keratoconus) monozygotic twins, i.e. only one of each pair exhibited keratoconus despite sharing the same DNA set. Current evidence suggests that different expressions of genes can lead to demonstrable differences that can increase as 'identical' twins age. The authors concluded that, because there was an absence of convincing evidence of keratoconus in other family members of both pairs, they could not rule out environmental factors in the aetiology of keratoconus in these cases. Parker *et al.* (1996) reported on an apparent case of discordant monozygotic twins (age: 28) but videokeratoscopy, and only videokeratoscopy, revealed that the non-keratoconic twin actually had inferior steepening that progressed over time.

Four cases of concordant keratoconus in monozygotic twins have also been reported (Hutchings *et al.*, 2005) which does suggest a genetic component in keratoconus. Kenney and Brown (2003) believe it is likely that keratoconus is a result of multiple gene defects and not just a single gene defect. This probably means that prevention will require multiple 'silver bullets' to be completely successful.

Genetically, keratoconus is usually described as an autosomal dominant condition with variable expressivity and/or incomplete penetrance (Bisceglia *et al.*, 2005), with only slight familial tendencies. Other modes of inheritance have been described including autosomal recessive (Wang *et al.*, 2000; Hutchings *et al.*, 2005) and rarely, X-linked (Hutchings *et al.*, 2005). The exact mode of hereditary transmission remains unknown. Around 6 – 10% (see earlier in this lecture) or up to 16% (Assiri *et al.*, 2005) of reported keratoconus cases have a positive family history or show evidence of familial transmission (see slides 22 to 24 for patient, mother, maternal uncle).

18



8L197741-77

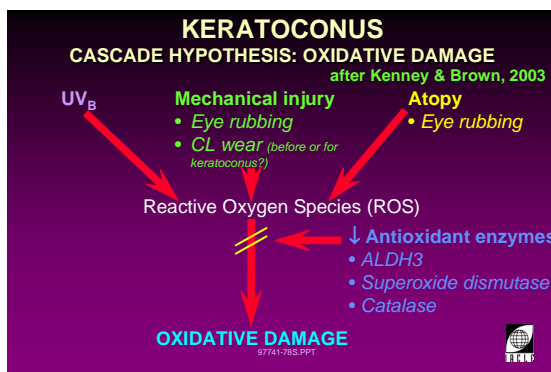
With respect to stromal thinning in keratoconus, Nguyen *et al.* (2004) identified genes that warranted further investigation. These include the genes for Tumor Necrosis Factor Alpha-Induced Protein 6 (TNFAIP6), and Insulin-like Growth Factor Binding Proteins 5 (IGFBP5) and 3 (IGFBP3).

Wang *et al.* (2000) concluded that the evidence suggests strongly that keratoconus is most likely to be due to a major gene defect.

**Scientific Observations and a Unifying Theory**

Some of the published findings and observations relating to keratoconus appear in slides 15 to 17. However, the underlying aetiology or aetiologies have yet to be determined.

19

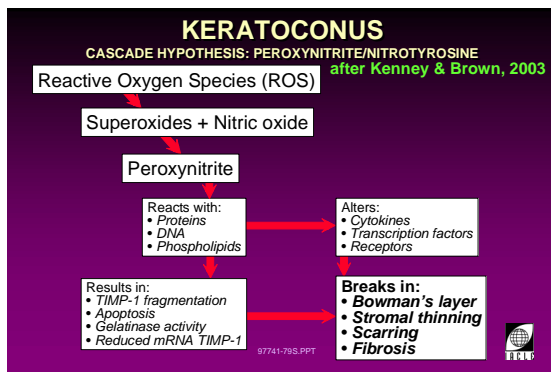


8L197741-78

At least one 'unifying' theory has been proposed (Kenney and Brown's Cascade Hypothesis, 2003, see slide 18). Their hypothesis seeks to explain the many reports published by various workers (including themselves) in the field (some of the details are presented in slides 19 to 21). The authors do not attempt to explain the initial cause(s) rather, they seek to explain the effects.

Collier (2001) reviewed briefly the issues of elevated proteinase levels in keratoconus, particularly the membrane-bound metalloproteinase MT-1-MMP (MMP-14). Research on the latter's significance continues.

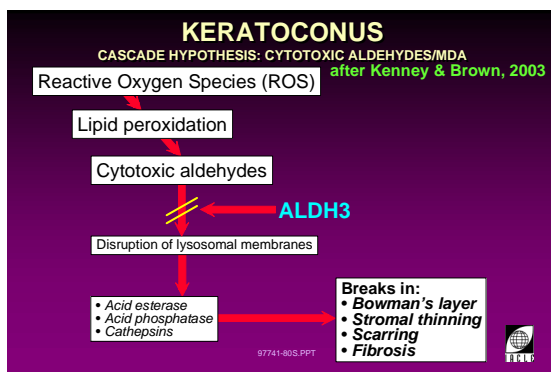
20



8L197741-79

Typically, keratoconus starts around puberty and progresses until the third or fourth decade of life after which it stabilizes (after Hutchings *et al.*, 2005). The disease progresses as a result of the combined effects of concurrent destructive and healing processes (Rabinowitz, 1998). Brookes *et al.* (2003) observed disruptions of Bowman's layer in keratoconic corneas at the anatomical point where the corneal nerves pass between the stroma and the epithelium. In the human cornea, the anterior keratocytes lie close to the corneal nerves. Brookes' team postulated that in keratoconus, these keratocytes express high levels of destructive enzymes. Gradually, deeper and deeper layers of the cornea are destroyed, and a scarred cone forms as this degradation overwhelms the concurrent corneal wound healing process.

21

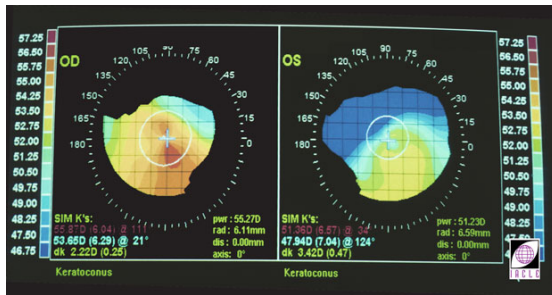


8L197741-80

More recently, the involvement of apoptosis (programmed cell death) in keratoconus, particularly keratocyte apoptosis, has been investigated and it is now believed to play a significant role (Kim *et al.*, 1999). The authors raised the possibility that the epithelial damage resulting from apoptosis may link the common risk factors of chronic eye rubbing, poorly-fitted contact lenses, and atopic eye disease.

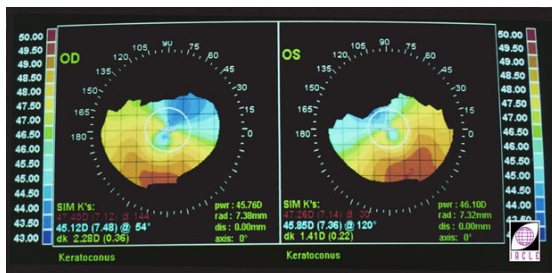
Smolek and Klyce (2000) postulated that keratoconus (at least in its mild to moderate forms) was a specialized form of corneal warpage rather than an ectasia.

22



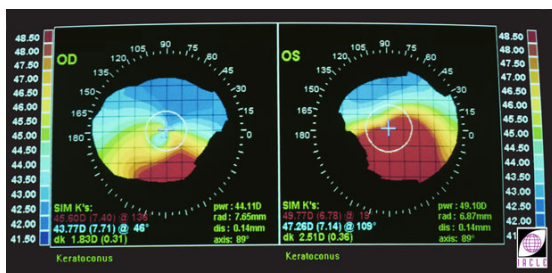
8L1DCP 4 5 1 (PATIENT: AT)

23



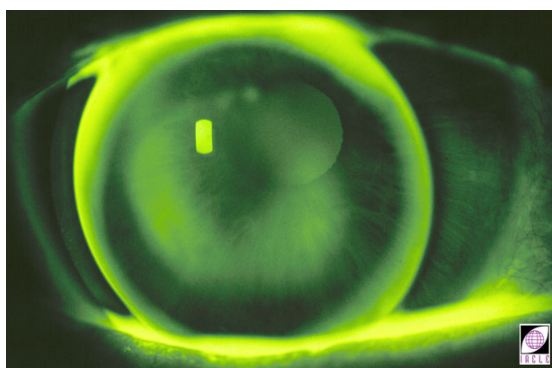
8L1DCP 4 5 2 (MOTHER OF PATIENT: AT)

24



8L1DCP 4 5 3 (UNCLE [MATERNAL] OF PATIENT: AT)

25



8L1DCP 4 6 4 (KC AFTER 15 YRS RGP LENS WEAR) (ROSE K)

### Associated Conditions, Especially Atopy

Keratoconus is often associated with atopic conditions (spring catarrh, sinusitis, hay-fever) (Khan *et al.*, 1988), ocular itch as well as vigorous eye rubbing. The latter may also play a part in the aetiology (Lindsay *et al.*, 2000; Bawazeer *et al.*, 2000; McMonnies and Boneham, 2003; Jafri *et al.*, 2004) and the progression of the condition especially if the condition is asymmetric (the most affected eye is almost invariably the most rubbed) (Maguluri *et al.*, 1999; Zadnik *et al.*, 2002; Jafri *et al.*, 2004). However, as atopic diseases are significantly less common in Asians than in Caucasian, Georgiou *et al.* (2004) postulated that the aetiology of keratoconus in each of these groups may be different.

### Contact Lens Wear

Periodically, the role of RGP lenses in the progression of the keratoconus and/or the state of the cornea is questioned. Szczotka *et al.* (1996) studied the influence of contact lens wear on corneal topography and concluded that the irregularity seen with RGP lenses was either due to the mechanical effect of the lenses themselves or simply that such lenses are necessary once the disease reaches a more advanced stage. The irregularity they observed may simply be a mirror of this fact. Using other criteria to assess the stage of keratoconus development reached, they concluded that the irregularity was due largely to the stage of the disease and not the contact lenses worn. Some believe that the progression of keratoconus only occurs in genetically predisposed individuals. Given the complexity and unpredictability of the condition generally, such a causal relationship is difficult to investigate, let alone prove or disprove. Slide 25 shows a patient that developed keratoconus (at the age of 30) some 15 years after commencing RGP lens wear.

Some relevant issues follow:

- Some rigid lens wearers were probably fitted well before videokeratoscopes became available widely. This raises the possibility that rigid lenses were fitted to undetected *forme fruste* cases of keratoconus. Later, frank keratoconus developed and the erroneous connection to lens wear was made.
- PMMA (poly[methyl methacrylate]) is capable of inducing corneal oedema and corneal warpage. However, these cases usually 'recover' on refitting with RGP lenses or cessation of lens wear. Those that fail to recover may belong in the *forme fruste* category.
- Early rigid lenses were capable of reshaping the cornea mechanically (as opposed to physiologically, see the previous point). These cases also 'recovered' on wear cessation or refitting with lenses offering better corneal physiology and/or having lower material rigidities.



**Deficiencies**

Thalasselis ( 2005) raised the possibility that magnesium deficiency may be a co-factor in keratoconus and suggested further investigation of this issue was warranted.

**Other**

Keratoconus was also reported to have followed a Vth nerve palsy in a 38 year old male (a previously unknown association) (Ruddle *et al.*, 2003).


Assiri *et al.* (2005) concluded that genetic and environmental factors, especially an average altitude greater than 3,000 metres, may play a role in the aetiology of the condition in Asir province of the kingdom of Saudi Arabia.

26

**ASSOCIATED CONDITIONS**

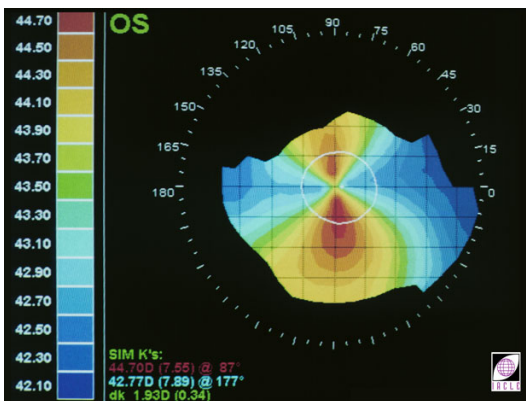
- Down's syndrome
- Connective tissue disorders
- Systemic atopic disorders
- Ocular disorders

974175.PPT



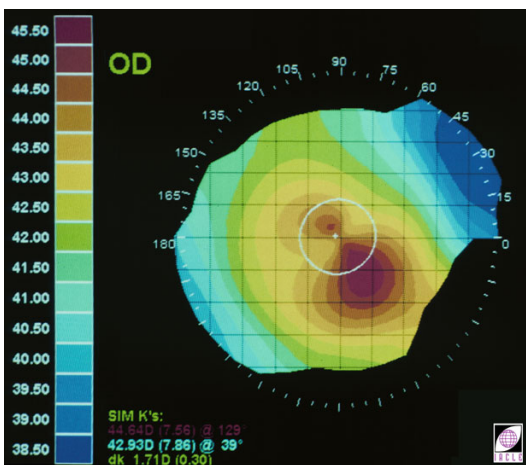
8L197741-7

27



8L1 DCP 4 39 13 (DOWN)

28



8L1DCP 8 7 14 (OSTEO IMPERFECT)

**Conditions Associated with Keratoconus**

One of the major (and most likely) aetiological factors in keratoconus seems to be genetic. The condition shows a familial inheritance (see earlier), and is associated with certain genetic disorders.

These include:

- Down Syndrome: the incidence of keratoconus within Down syndrome patients is reported to be as high as 15% (i.e. about 300 times more common than in the general population). Acute hydrops (accumulation of serous fluid in body tissues or cavities, e.g. corneal hydrops, gross central corneal oedema) is also more common in Down syndrome keratoconics (slide 27 shows the topography of a Down syndrome case – symmetrical bowtie, centred, see classification later).

A number of connective tissue disorders also have a strong association with keratoconus. Defective synthesis of connective tissue or a progressive weakening of connective tissue may be responsible. Conditions include:

- Ehlers-Danlos syndrome (abnormal cross-linking of collagen). Of all the connective tissue diseases, E-D syndrome has the most frequent association with keratoconus.

Other conditions associated with keratoconus include:

- Marfan's, Rieger's, and Crouzon's syndromes.
- Osteogenesis imperfecta (Bennett and Grohe, 1986) (slide 28).
- Pseudo-xanthoma elasticum and coeliac disease (Ruben and Khoo, 1989).
- Corneal Granular Dystrophy (Wollensak *et al.*, 2002).

Many systemic atopic disorders are also strongly linked with keratoconus. Characteristically, atopic patients have decreased secretory IgA responses, and increased IgE responses.

29



8L1DCP 8 5 4 (PMD)

Ocular abnormalities that occur more frequently in keratoconus include:

- Congenital cataract.
- Retinitis pigmentosa.
- Ectopia lentis.
- Pellucid marginal degeneration (PMD) (slides 29 and 30).

In a retrospective study by Sridhar *et al.* (2004), about 10% of eyes with PMD also had keratoconus.

It has been postulated that keratoconus and PMD represent different clinical manifestations of the same underlying corneal ectatic disorder. However, it is important to distinguish keratoconus from other ectatic disorders, such as PMD or Terrien's marginal degeneration because these conditions present differently and are, therefore, managed differently.


In Terrien's marginal degeneration, the corneal ectasia is limited to the peripheral cornea and may affect both the inferior and superior cornea. The area of thinning is vascularized and often has associated lipid deposits.

In PMD, typically, the corneal thinning is located in the periphery of the inferior cornea, with a narrow band (approximately 2 mm wide) of unaffected cornea adjacent to the limbus (see slide 29). The condition is usually bilateral, but may be asymmetric (Zadnik *et al.*, 2002). It causes large amounts of against-the-rule (ATR) astigmatism (Sridhar *et al.*, 2004) that often makes these patients difficult to fit successfully with contact lenses. Unfortunately, because of the peripheral corneal thinning, PMD cases are also not good candidates for PK.

LASER (Light Amplification by Stimulated Emission of Radiation) refractive surgery, especially LASIK, is also known to induce corneal ectasia in some susceptible individuals post-operatively.

For a much more comprehensive list of conditions associated with keratoconus see Table 1 of Rabinowitz (1998).

30



8L1DCP 8 5 3 (PMD SAME PATIENT AS ABOVE)

31

**ATOPY**

- Hypersensitivities associated with:
  - Vernal keratoconjunctivitis
  - Hay fever
  - Asthma
  - Eczema
  - Food allergies

97741-8S.PPT

8L197741-8

**Atopy**

Atopy refers to the hypersensitivity associated with such disorders as hay fever, asthma, eczema, and food allergies.

Many atopic conditions have a strong link with keratoconus.

One of the earliest presenting signs in a patient who may be keratoconic is the diagnosis of atopy around the age of puberty.

A number of studies have reported a strong relationship between keratoconus and atopy, e.g. Ruben and Khoo (1989), gave a figure of 40%. It is important for keratoconus suspects to be questioned carefully about any hypersensitivities that they may have. Bawazeer *et al.* (2000) suggested that the connection between keratoconus and atopy may be the eye rubbing induced.


32

**ATOPY**

Relationship to keratoconus:

Ridley, 1956	15% history
Rahi <i>et al</i> , 1977	32% history
Swann & Waldron, 1986	42% history
Ruben & Khoo, 1989	40% history

97741-9S.PPT



8L197741-9

As a result of associated atopy, many keratoconus patients are intolerant of contact lenses, and their motivation needs to be high if they are to be successful rigid lens wearers. Occasionally, a keratoconus patient may also have severe atopic eczema or vernal conjunctivitis and only be able to tolerate soft contact lenses (SCLs). In all but the early stages of keratoconus, the visual outcome with SCLs can only be a compromise, a compromise that may exceed their tolerance level once their keratoconus progresses.


Hand dominance can also be a determinant of both the eye most affected (often the side of the dominant hand) and the condition's severity (eye on the side of the dominant hand becomes keratoconic earlier, progresses faster, and exhibits the most severe signs) (after McMonnies and Boneham, 2003).

33

**TYPES OF KERATOCONUS**

- Early
- Advanced
  - Nipple
  - Oval
  - Globus

97741-10S.PPT



8L197741-10

**Classification of Keratoconus**

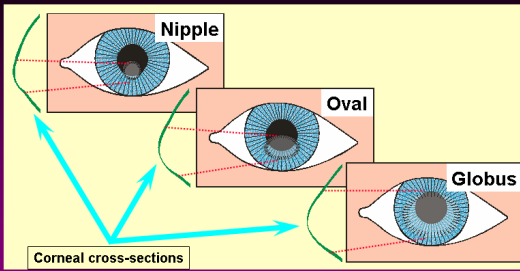
**By Type**

A simple classification of keratoconus divides the condition into early and advanced stages. Advanced keratoconus can be further classified by a description of the shape of the cornea (slides 33 and 34). The location can also be used as an additional descriptor, e.g. central (slides 37 and 38), or decentred inferiorly, temporally, etc.


Keratoconic patients generally exhibit the same cone type in each eye, although the severity is often dissimilar and the cones may present as mirror images of each other when assessed with a videokeratoscope (or other type of topographer) (slide 44).

34

**KERATOCONUS: TYPES**



8L1-34B.PPT



8L197741-87


Slide 34 presents diagrammatically the three main types of cones. These are:

- Nipple (paracentral steepening, relatively small diameter at the base).
- Oval (inferior steepening, larger base diameter).
- Globus (overall steepening, large base diameter).

35

**KERATOCONUS CLASSIFICATION BY CORNEAL CURVATURE**  
Booyesen, 2003

- Mild: <45 D
- Moderate: 45 – 52 D
- Advanced: 52 – 65 D
- Severe: > 62 D




8L197741-118

**By Corneal Curvature**  
See slide 35.

36

**KERATOCONUS CLASSIFICATION BY CORNEAL THICKNESS**  
Booyesen, 2003

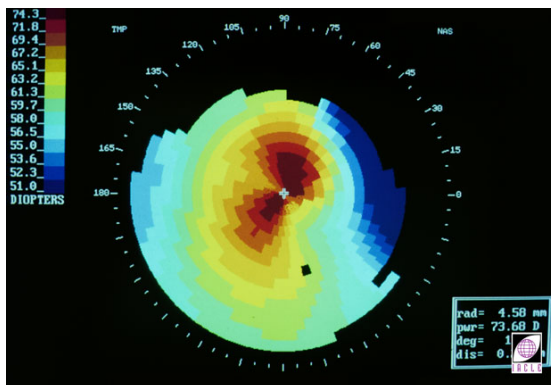
- Normal: 543  $\mu\text{m}$
- Early: 506  $\mu\text{m}$
- Moderate: 473  $\mu\text{m}$
- Advanced: 446  $\mu\text{m}$



8L197741-119

**By Corneal Thickness**  
See slide 36.

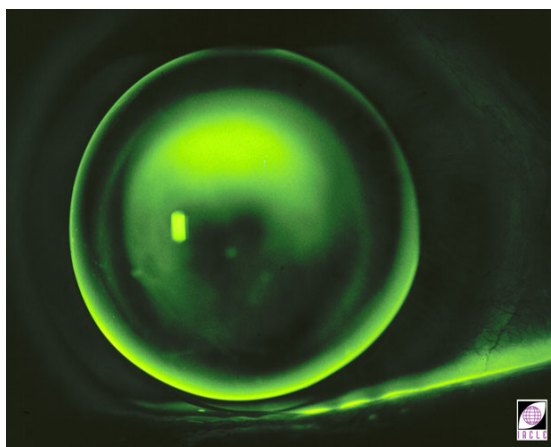
37



8L1DCP 4 3 8 CENTRAL

Slide 37 shows a central cone and slide 38 shows the same eye fitted with a Rose-K lens.

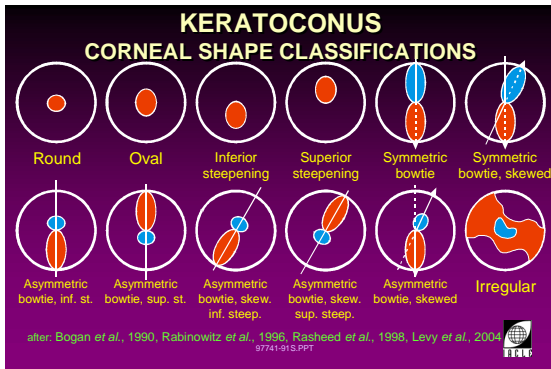
38



8L1DCP 4 3 9 (SAME PATIENT AS ABOVE) (ROSE K)

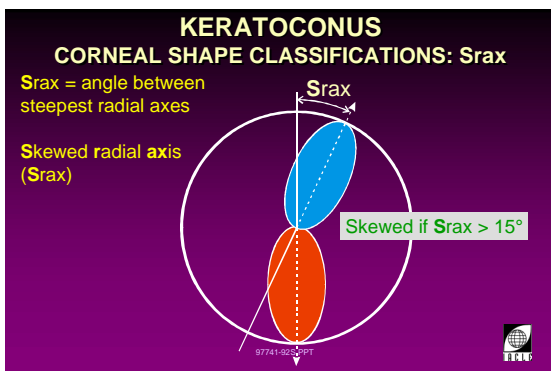


39



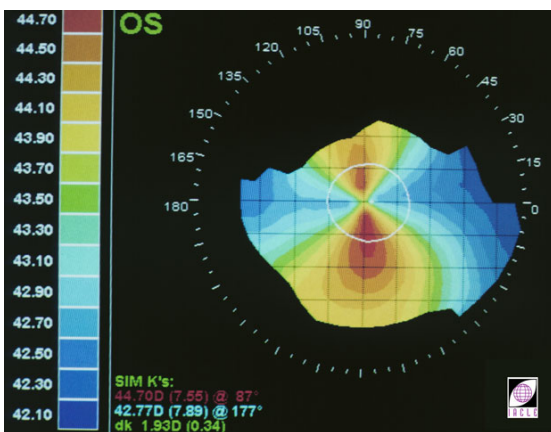
8L197741-91

40



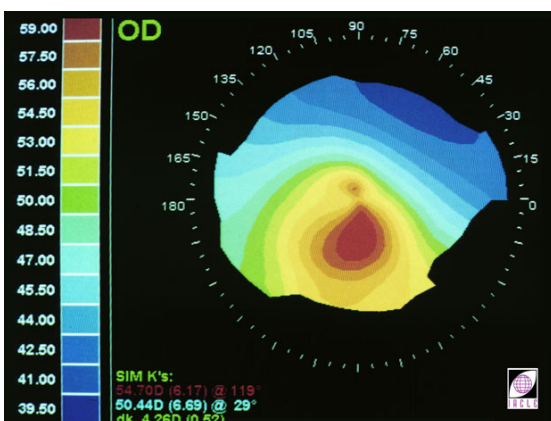
8L197741-92

41



8L1DCP 4 24 16 (SYMMETRIC BOWTIE)

42



8L1DCP 4 20 14 (ASYMMETRIC BOWTIE INFERIOR)

**By Topography**

A more comprehensive classification has been evolved by several authors (see slide 39). The starting point for such a system is partly based on a database of topographical maps of normal and abnormal human corneas (see McMahon *et al.*, 1991; Rabinowitz *et al.*, 1996).

The Srax skewed steep meridians concept is presented diagrammatically in slide 40 and topographically in slide 42.

Some of the topographies appearing diagrammatically in slide 39 are illustrated topographically in slides 41 to 43, 45, and 52.

Rasheed *et al.* (1998B) reported that even less experienced observers can get consistent results with such a classification system. What is unclear is how much the patterns, especially their elements of symmetry, if any, depend on the computational algorithms used in the particular instrument generating the topographical map.

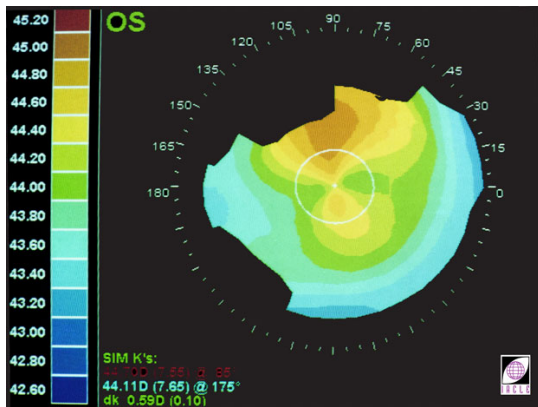
A system based on Zernike polynomials derived from videokeratography has also been proposed (Twa *et al.* visit: [http://dmrl.cse.ohio-state.edu/papers/Twa\\_1.pdf](http://dmrl.cse.ohio-state.edu/papers/Twa_1.pdf) and [http://www.siam.org/meetings/sdm03/proceedings/sdm03\\_01.pdf](http://www.siam.org/meetings/sdm03/proceedings/sdm03_01.pdf)).

While classification systems have utility, they cannot hope to cater for all situations, e.g. two cones within the one cornea (see slides 46 to 50). Exceptions must be expected because a hallmark of keratoconus is the large variation in its expression and its apparent non-conformity with any 'system' that would allow it to be dealt with in a routine manner (this may also explain at least partially, why there are few 'textbooks' on keratoconus, i.e. keratoconus is seldom a 'textbook' disease).

Saks (personal communication, 2005) has observed that many cases of keratoconus occur in extremes of somatype (body type). Larger, sagging, geographic cones are seen in endomorphs (people with a large, rounder, jowlish body shape), e.g. Pacific islanders/ Polynesians. Ectomorphs (leaner, smaller, shorter people), e.g. Indians/Pakistanis/Asians, tend to have steep, central, nipple-like cones.

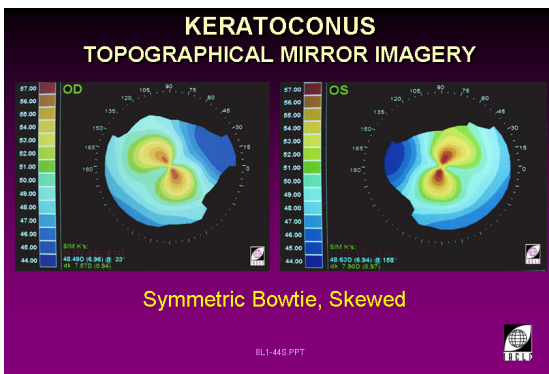


43



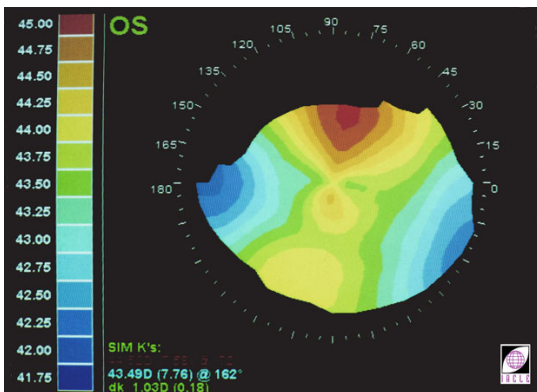
8L1DCP 4 20 22 (ASYMMETRIC BOWTIE SUPERIOR)

44



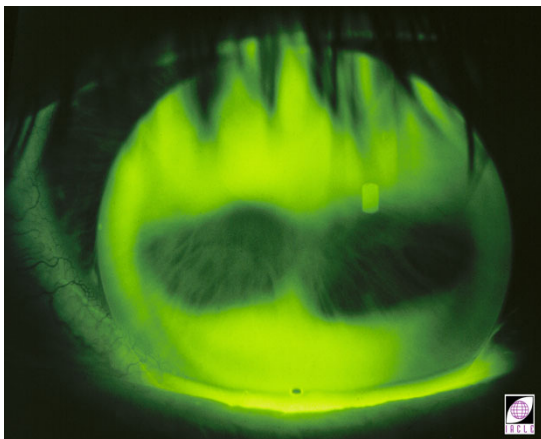
8L197741-114 (DCP 4 32 20 & 4 32 22)

45



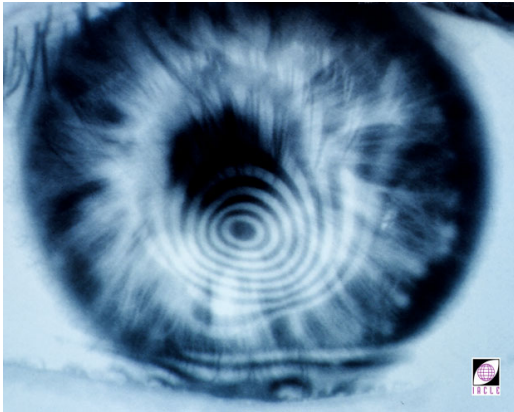
8L1DCP 4 20 5 (IRREGULAR)

46



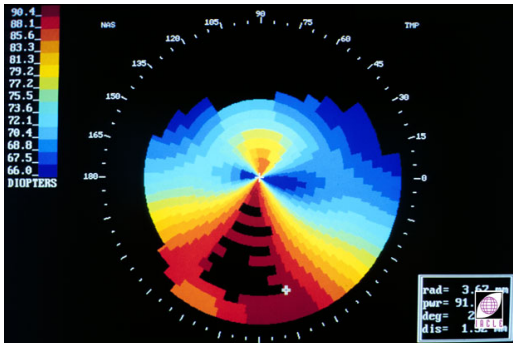
8L1DCP 4 1 19 (ROSE K LENS)

47



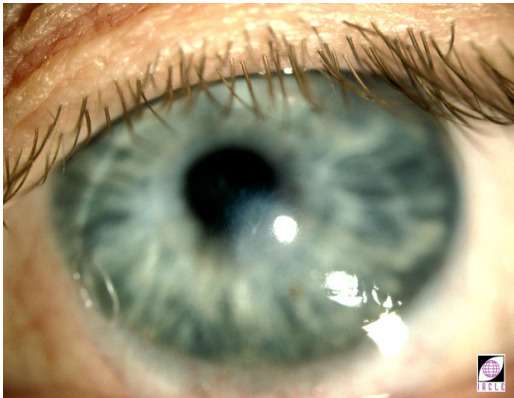8L1DCP 4 1 17 (SAME PATIENT AS SLIDE 46)

48




8L1DCP 4 1 18 NOTE ABSENT DATA IN PLOT (SAME PATIENT AS SLIDE 46)

49



8L1DCP 4 2 13 FRONTAL ELEVATION (SAME PATIENT AS SLIDE 46)

50




8L1DCP 4 1 13 SIDE ELEVATION (SAME PX AS SLIDE 46)

51

**EARLY KERATOCONUS**

- Mean K: < 50.00 D
- Small area of irregular astigmatism in the inferior paracentral cornea
- Best-corrected spectacle acuity may be reduced

97741-11.S.PPT



8L197741-11

### Early Keratoconus

In cases of early keratoconus, it is probable that no single sign allows a definitive diagnosis of the condition to be made. However, interestingly, the literature is leaning increasingly towards videokeratoscopy as a main diagnostic tool (e.g. Maguire and Bourne, 1989; Lee *et al.*, 1995; Parker *et al.*, 1996 [who stated that videokeratoscopy was the only way of detecting sub-clinical keratoconus]; Kenney and Brown, 2003; Hutchings *et al.*, 2005). Ultrasonic pachometry is not a reliable method of detecting keratoconus (Rabinowitz *et al.*, 1998).

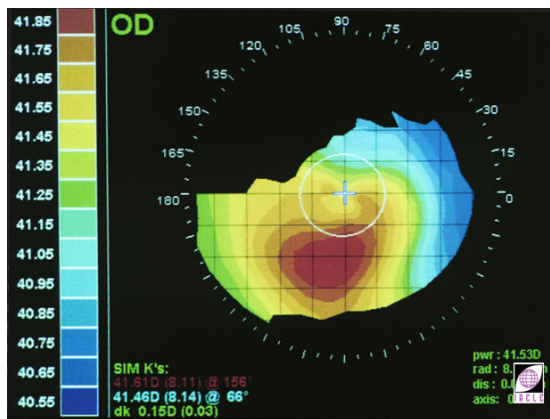
In the early stages of the disease, corneal curvature, as measured by keratometry, is less than 50.00 D. In some cases the curvatures can be flat or nearly normal but the tell-tale topography is still apparent (see slide 52).

A topographical mapping device such as a videokeratoscope may provide the earliest sign of the onset of keratoconus, commonly an inferior steepening of the cornea. Because computer-assisted corneal topography is not always available or performed routinely, diagnosis of keratoconus is often delayed until such time as spectacles (or conventional contact lenses) fail to provide adequate corrected vision. Subsequent investigations of why best corrected vision is reduced will often reveal keratoconus as a cause.

Videokeratoscopy has also been used to predict the progress of the disease using spherical equivalent as a manifest indicator of both progress and the increases in irregular astigmatism (Oshika *et al.*, 2002).

Using the thickness-determining function of the Orbscan™ topographer, Pflugfelder *et al.* (2002) were able to differentiate successfully between keratoconus-induced corneal thinning and contact lens-induced corneal thinning.

52



8L1DCP 8 7 8 (FLAT RADII)

53

**ADVANCED KERATOCONUS**

- Mean K: 50.00 to  $\geq$  60.00 D
  - keratometry often difficult & of questionable usefulness
  - videokeratoscopy more useful
- Nipple (paracentral steepening)
- Oval (inferior steepening)
- Globus (overall steepening)

97741-12.S.PPT



8L197741-12

### Advanced Keratoconus

In cases of advanced keratoconus, the cornea is steepened significantly and the keratometry values are frequently greater or much greater than 50.00 D.


Keratometry is often difficult to perform in such cases and is, therefore, of limited use. A topographical mapping device, especially a videokeratoscope, provides more useful information and can provide better guidance to trial lens selection and subsequently, lens fit.

54

**NIPPLE CONE**

- Small, paracentral cone
- Usually < 5 mm diameter (2 – 4 mm)
- Very steeply curved

97741-13S.PPT



8L197741-13

**Advanced Keratoconus: Nipple Cone**

Advanced cones can also be classified according to their shape.

A nipple cone has a short radius of curvature, is round, and has a small diameter. Nipple cones are often located centrally or just below the centre of the cornea, near the optical axis or decentred slightly infero-nasally. In the case of nipple cones, the superior cornea is often regular in shape and of approximately normal thickness.

55

**OVAL CONE**

- Displaced corneal apex
- Inferior temporal quadrant
- Cone diameter 5 – 6 mm
- More challenging to fit with CLs

97741-14S.PPT



8L197741-14

**Advanced Keratoconus: Oval Cone**

The oval or 'sagging' cone is larger than the nipple cone and is usually located just below the corneal centre and slightly temporally.


Such a cone shape is more likely to be associated with episodes of corneal hydrops (see later) and corneal scarring. Usually, oval cones are more difficult to fit with contact lenses.

56

**GLOBUS CONE**

- Largest area of thinning
- Involves up to 75% of the corneal area

97741-15S.PPT



8L197741-15

**Advanced Keratoconus: Globus Cone**

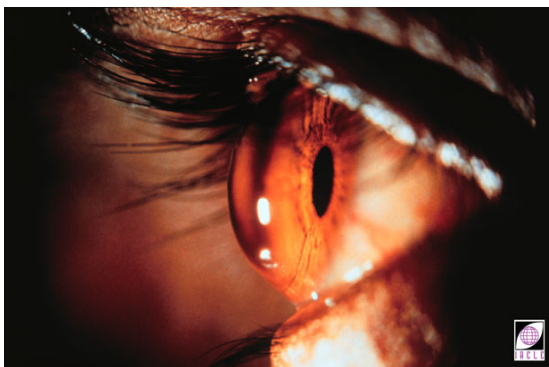
A globus cone is rare. It involves a large amount (up to 75%) of the corneal area (slide 57) and presents the practitioner with a very challenging and difficult contact lens fitting.

Cones may also be located superiorly (Gundel and Libassi, 2002).

It is sometimes necessary to fit a large, flat RGP lens to globus cones, to ensure adequate lid-lens interaction.

Globus cones should not be confused with keratoglobus, which is a non-inflammatory and non-progressive thinning of the cornea due to a systemic collagen abnormality.

57



8L11476-94

In keratoglobus, the generalized thinning of the cornea has the appearance of an enlarged cornea that protrudes and is surrounded by a misshapen sclera.

58

KERATOCONUS KRUMEICH <i>et al</i> CLASSIFICATION	
STAGE	CHARACTERISTICS
1	Eccentric corneal steepening Induced myopia and/or astigmatism < 5 D Corneal radii ≤ 48 D Vogt's striae, no scars
2	Induced myopia and/or astigmatism > 5 D < 8 D Corneal radii ≤ 53 D No central scars Corneal thickness ≥ 400 μm

8L197741-55

### Alternative Clinical Classification of Keratoconus

Krumeich *et al.* (1998) proposed a 4-stage clinical classification of keratoconus, based on astigmatism, corneal transparency, power and thickness (slides 58 and 59).

The first stage is characterized by eccentric corneal steepening and induced myopia/astigmatism of 5 D or less.

In the second stage, the myopia and astigmatism are more pronounced, corneal radii are steeper, and the cornea is thinner.

Stage three presents with myopia/astigmatism between 8 D and 10 D, steep corneal radii (more than 53 D), and a thinned cornea of 200 to 400 μm.

When the cornea steepens and thins even further and shows scarring, it is classified as Stage 4 keratoconus.

59

KERATOCONUS KRUMEICH <i>et al</i> CLASSIFICATION	
STAGE	CHARACTERISTICS
3	Induced myopia and/or astigmatism > 8 D < 10 D Corneal radii > 53 D No central scars Corneal thickness 200 to 400 μm
4	Refraction not measurable Corneal radii > 55 D Central scars, perforation Corneal thickness 200 μm

8L197741-56




### III Symptoms and Signs

60

**SYMPTOMS**

- Initially, asymptomatic
- Visual degradation reported at or after time of puberty
- Progresses slowly over 5 – 10 years

97741-16S.PPT



8L197741-16

#### Symptoms Associated with Keratoconus

Commonly, keratoconus is asymptomatic in the early stages of its development.

A slight degradation of vision, often initially in one eye only, possibly in the form of a ghost image located superiorly or 'double vision' in one eye (monocular diplopia), may be the first symptom reported.


The visual difficulties may be reported at or soon after the onset of puberty but their true significance may not be revealed until sometime later when conventional spectacles or contact lenses fail to provide 'normal' vision. The reduced vision is a result of irregular astigmatism (irregular cornea) that can also cause other visual disturbances, e.g. flare and photophobia. The latter are more likely to occur in the later stages of the disease.

61

**SYMPTOMS**

- Ghosting/monocular diplopia due to irregular astigmatism
  - commonly, first reported in one eye only
- Flare, especially at night
- Photophobia

97741-17S.PPT



8L197741-17

In most cases, the visual degradation progresses slowly over many years. This is due to the increasingly irregular corneal shape and/or corneal scarring. Attempts have been made to predict the vision quality in keratoconus using ray tracing and corneal topography data. Success was reported for mild to moderate degree keratoconus (Uçakhan, 2003).


Contrast sensitivity testing may show altered visual performance before any deterioration can be measured using Snellen acuity charts. This is usually because only high contrast charts are employed in routine contact lens practice. Low contrast acuity charts may be more useful in the early detection of compromised vision. However, since many other factors may also lower low contrast acuity, e.g. poor lens surface condition, care is required in interpreting the results. Increasingly, corneal topographers, e.g. videokeratoscopes, are becoming the early detection tool of choice. However, some caution is required because early keratoconus can be diagnosed falsely (pseudokeratoconus) with poor instrument alignment and/or poor fixation (even when  $<5^\circ$ ) (Hubbe and Foulks, 1994).

62

**ADOLESCENT ONSET FEATURES**

- Early to mid teens
- Usually bilateral with asymmetric presentation
- Progression over approximately 10 years
- May progress further in the 30s and 40s

97741-18S.PPT



8L197741-18

#### Adolescent Onset Keratoconus

Despite the frequent association with pubertal onset, the age of the onset of keratoconus and its rate of progression can vary greatly. In most cases, bilateral involvement can be observed but the rate of progression and, therefore, the presentation may be quite asymmetric between the eyes (Wilson *et al.*, 1991; Zadnik *et al.*, 2002). In some cases, as many as 16 years may pass before the second cornea is manifestly keratoconic. However, most will be apparent in under 6 years (Li *et al.*, 2004). In rare cases, the condition may be truly unilateral.

The common critical age range of onset is 12 to 25 (Ruben and Khoo, 1989).

63

### DELAYED ONSET FEATURES

- Late 20s and early 30s
- Not always bilateral
- May be minimally progressive

97741-19S.PPT



8L197741-19

### Delayed Onset Keratoconus

At least 5% of keratoconus presents, and/or is diagnosed, after 40 years of age (Ruben and Khoo, 1989).

Keratoconus that is first detected in the late 20s or even later in life is often slowly progressive. In many cases it apparently remains a unilateral condition.

However, a sub-clinical form of keratoconus can exist, that presents as corneal thinning and irregular astigmatism. Typically, the topographic map with videokeratoscopy shows the region of inferior corneal steepening but no other signs of keratoconus. This is called '*forme fruste*' keratoconus, and can usually be managed with a spectacle correction. [Note: *forme fruste*: Literally, 'worn-down form' - an incomplete, abortive, or unusual form of a syndrome or disease].

While studying family members of keratoconics, Levy *et al.* (2004) determined that many cases of *forme fruste* keratoconus remained undetected until a videokeratoscope was used to assess their corneas in detail. A significant number of asymmetric, bowtie patterns with skewed radial axes and inferior steepening (mainly) or asymmetric, bowtie patterns with skewed radial axes (Srax) and superior steepening patterns (less common) were found (see slide 39 for classifications).

Although most *forme fruste* cases remain unidentified, to a refractive surgeon they are potentially ticking time bombs. Should a case of *forme fruste* keratoconus pass unnoticed through the screening process for refractive surgery, the result can be unpredictable at best. Even when suspect cases are deleted from surgical lists, a potential post-surgical complication of (Laser Assisted *In situ* Keratomileusis (LASIK) is so-called iatrogenic keratoconus (Edwards *et al.*, 2001B) (see later).

Clinical experience suggests that many so-called unilateral keratoconics are really bilateral with a sub-clinical form of the condition in the other eye (see Phillips, 2003 for an apparent case of monocular keratoconus and a discussion of related issues).

Some late-onset cases may be the simple progression of the disease from the *forme fruste* stage to the manifest stage.

64

### KERATOCONUS CORNEAL CHANGES

- Central ectasia
  - thinning
- Hydrops
  - stromal oedema
  - splits/tears in the endothelium/Descemet's membrane

97741-21S.PPT



8L197741-21

### Corneal Changes in Keratoconus

Corneal ectasia is a direct result of the action of intraocular pressure (IOP) on a thinned, weakened cornea (slide 66).


The lamellae of the posterior (deeper) stroma are arranged regularly. However, the anterior bundles are much less regular and, unlike the deeper layers, they also pass between adjacent anterior layers resulting in an 'interweaving' of anterior lamellae. It is believed that this increases the tensile strength of the anterior cornea. As a result, it is postulated that the corneal form is more attributable to the properties of the anterior cornea and that early

65

**KERATOCONUS  
CORNEAL CHANGES**

- Endothelial cells may be elongated
  - long axis points towards the apex
- Corneal scarring
- Reduced keratocyte density seen in confocal microscopy

97741-20S.PPT



8L197741-20

corneal changes are more likely to occur in the posterior stroma (after Ruben and Khoo, 1989) (see also Module 1, Lecture 1.1, Section **I.A.5 Stroma**).

The peripheral cornea, being thicker normally (anatomically), as well as thicker relative to any 'thinning' of the central zone, is less affected in keratoconus and is usually the last corneal region to exhibit any change in 'form'.

Stromal thinning, breaks in Bowman's layer, scarring, and iron deposition in the basal layers of the corneal epithelium are classic features of keratoconus (slides 66 to 69).

One possible longer-term outcome of keratoconus is corneal hydrops that presents as significant central corneal oedema. Hydrops occurs due to tears or ruptures of Descemet's membrane and the posterior stroma, i.e. a loss of the barrier function of these layers. Most such cases resolve spontaneously when Descemet's membrane resurfaces (heals) over the split, i.e. the barrier function is restored.

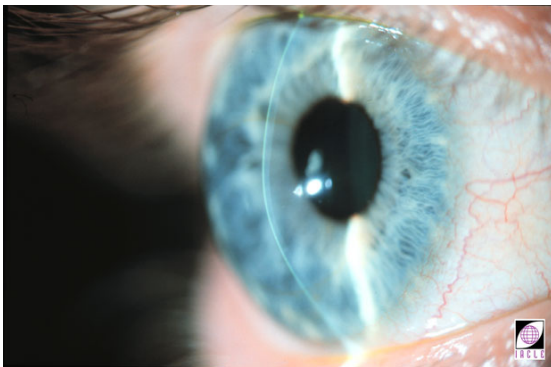Unfortunately, although the occurrence of hydrops is often an indication for a penetrating keratoplasty, such cases have a greater chance of graft rejection if one is performed. Worse, after an episode of hydrops has resolved (no keratoplasty performed), there is increased difficulty in re-establishing contact lens wear and only a minority are successful (Tuft *et al.*, 1994B).

The endothelium of the keratoconic cornea is usually normal, but abnormalities such as pleomorphism and cell elongation have been reported. Laing *et al.* (1979) observed that the long axes of the elongated endothelial cells seemed oriented towards the apex of the cone (slide 70).

Using a confocal microscope, Erie *et al.* (2002) reported reduced keratocyte density in contact lens-wearing keratoconus patients.

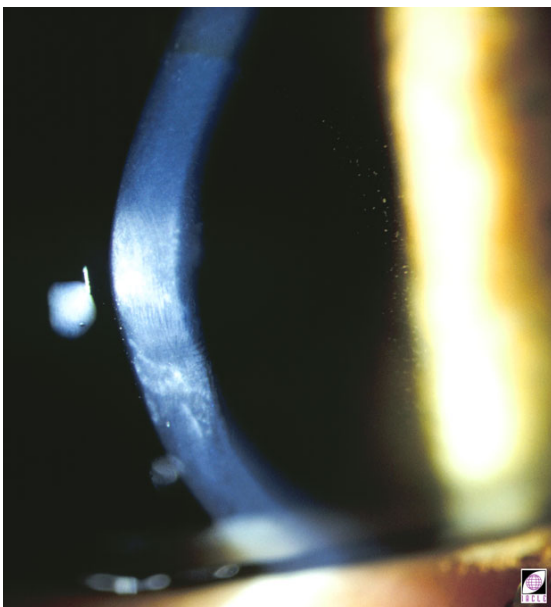
Many keratoconus patients eventually show corneal scarring, which may or may not be contact lens-induced. Lens-induced scars are usually in the anterior stroma, while scars located deeper in the stroma are probably due to the disease process itself (Leung, 1999).

66



8L11601-95 THINNING

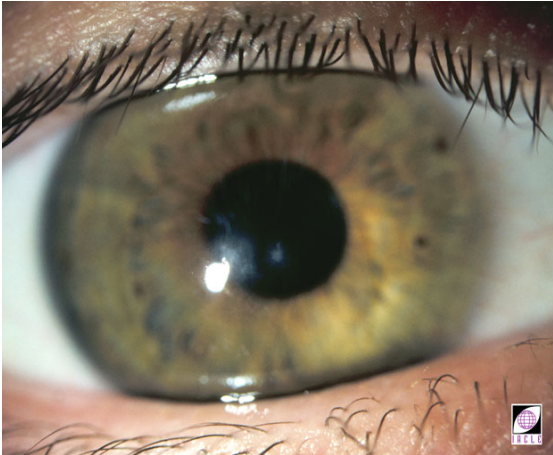
67



8L1DCP 4 38 5 (SCARRING & THINNING)

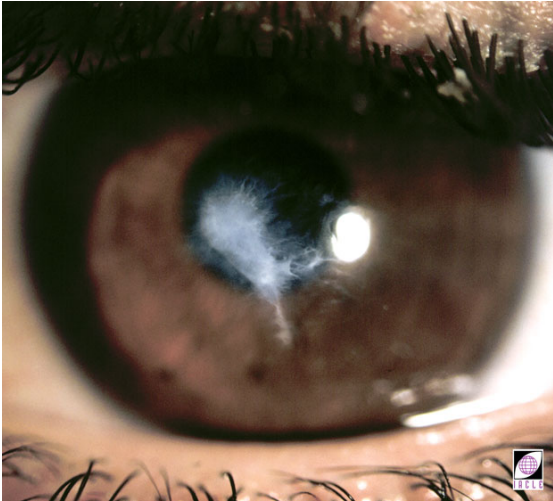

68




8L1DCP 4 38 4 (SCARRING)

69



8L1DCP 4 52 9 CENTRAL SCAR

70




8L1LEW34-80VERT ENDOTHELIAL CELL 'POINTING'

71

**INFLUENCES ON KERATOCONUS**

- Upper lid pressure
- Eye rubbing
- Collagen disorders
- Atopic condition
- Age of mother



8L197741-22

**Other Influences On Keratoconus**

Various external influences are implicated in the development of keratoconus, e.g. the pressure of the lids, especially the upper lids. Additional influences such as finger pressure applied to the lids during eye rubbing (finger and knuckle rubbing) seem to play a role in induced corneal changes (slide 72).

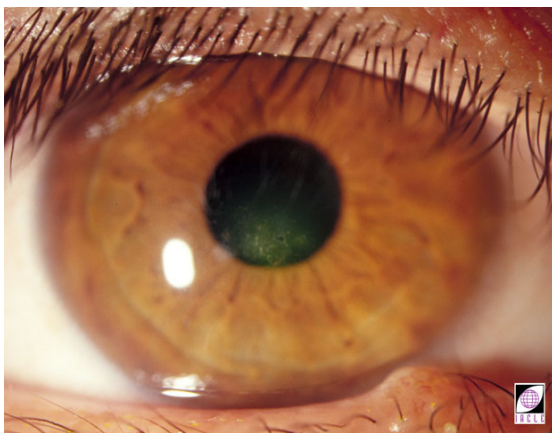
It is now accepted that keratoconus is a manifestation of an underlying collagen disorder. However, the quest for other manifestations of such a collagen disorder seldom reveals concomitant problems elsewhere in the body.

Possibly 40% of keratoconics show a weakness of the mitral heart valves, but within physiological limits of normal function.

A high proportion of keratoconics are atopic (Ruben and Khoo, 1989).

The age of the mother at the time of a keratoconic's birth is also believed, by some authors, to be an influential factor as keratoconus is more common in children born later in a mother's fertile years. However, in a large study (2,723 patients), Tuft *et al.* (1994) failed to find a significant association between these two factors.

72




8L1DCP 4 42 2 (RUBBING SCARS)

73

**EARLY SIGNS**

- Distorted retinoscopy reflex
- Irregular astigmatism
- Decreased unaided vision and visual acuity
- Marked changes in the refractive sphere, cylinder and axis
- Closely held reading material
- Narrowed palpebral aperture



8L197741-23

**Early Signs of Keratoconus**

To an examiner, two of the earliest signs of keratoconus are those of a distorted retinoscopic reflex described by some as a 'scissoring' motion (slide 75) or a 'zonal' reflex (Saks, 2005 personal communication), and a 'swimming' appearance of the posterior pole reflex during direct ophthalmoscopy. Irregular (or non-orthogonal) corneal astigmatism causes these effects as well as a reduction in habitual vision and possibly BCVA.

Over a short period of time, the refractive correction may change rapidly and substantially. The first refractive error change to occur is usually a change in the amount of cylinder and its axis. Reading material may be held at an abnormally close range due to irregular myopic astigmatism.

In some cases, the palpebral aperture may be smaller than average (stenopaeic slits?).

A number of signs may be present when performing keratometry on a keratoconic subject.


These include:

- Inability to obtain a sharp focus of the mires.
- Inclination or distortion of the mires.
- Inability to align the mires despite appropriate instrument rotation.
- Asymmetric steepening of mires inferiorly or centrally.

74

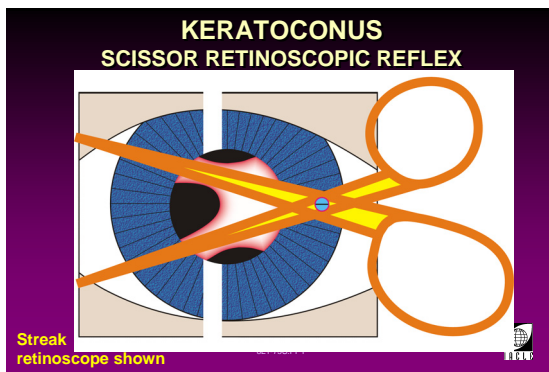
**EARLY SIGNS**

- Distorted keratometry mires
- Distorted photokeratometry rings
- Inferior steepening in videokeratometry maps
- Apical corneal thinning (stromal)
- Cone formation



8L197741-24

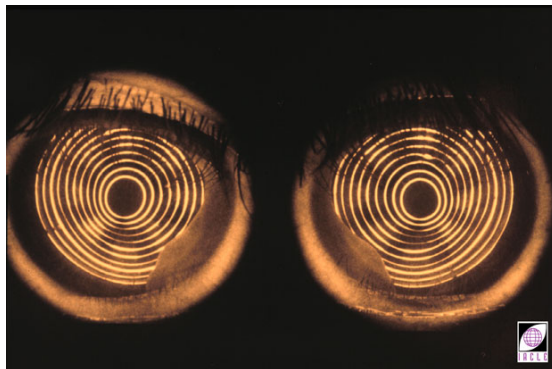
75



8L197741-89

A keratoscope (based on a Placido disk or a more sophisticated mire locus) or equivalent instrument can provide qualitative information about the corneal shape. In keratoconus, the image of the circles are, commonly, wide apart in the superior/nasal sector of the cornea, but tend to be closer together in the infero-temporal sector, i.e. the steepest region of the cornea (slide 76). Generally, keratoscopy/photokeratoscopy has given way to videokeratoscopy. While the latter has a higher initial cost, the immediate analysis capability, the low operating costs, and the ease of extensive data storage has seen photokeratoscopes fade from the clinical scene and a wave of computer-based devices take their place (see Module 9, Lecture 9.1, Section *III Keratoscopes*).

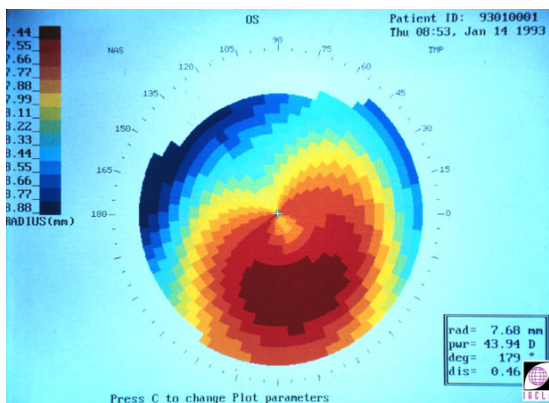
76



8L11021-93

Videokeratoscopy provides a comprehensive view of the complex curvature changes associated with the anterior corneal surface. The inferior steepening of the cornea can be easily appreciated by the use of false-colour data mapping, e.g. steeper zones may be displayed in red (slide 77). Modern software allows the operator to alter the range of colours over a range of corneal curvatures. In this way, finer or coarser gradations of colour, which is presented as a continuous variable, can be invoked to optimize the visualization of the corneal topographical data being displayed. Such instruments also provide a quantitative indication of just how asymmetric keratoconus can be at the time of diagnosis (Burns *et al.*, 2004).

77



8L10724-93

Videokeratoscopy is extremely valuable in the early detection of keratoconus (see Maeda *et al.*, 1994, 1995) as well as monitoring the progression of the disease. More recently (Smolek and Klyce, 1997; Agostina *et al.*, 2002; Carvalho, 2005), artificial neural networks have been proposed and trialed as a means of classifying videokeratoscopic data using Zernike coefficients as the primary input.

Apical thinning of the cornea may be seen using an optic section with the slit-lamp biomicroscope (slide 66) and the cone development may be observed with a direct ophthalmoscope.

Corneal thinning may also be confirmed by optical, ultrasonic, or videokeratoscopic pachometry.

Early detection of keratoconus has taken on greater importance since the resurgence of refractive surgery. Obviously, keratoconus contraindicates any optional surgical procedures on the cornea.

The value and applications of the early detection of keratoconus has been questioned by Zadnik (1997). She felt that raising the range of possible keratoconic visual and surgical outcomes may limit career choices unnecessarily, as well as cause unwelcome and/or premature concerns for visual wellbeing that may not be realized in practice.

Other methods have been researched, e.g. the Keratoconus Index (KI) that relates the ratio of peripheral and thinnest corneal thicknesses and a calculation based on an ultrabiomicroscopy examination (Avitabile *et al.*, 2004).




78

**LATER SIGNS**

- Advanced cone formation seen in profile
- Scarring in corneal epithelium or sub epithelium
- Munson's sign on lower lid
- Fleischer's iron ring
- Increased visibility of corneal nerve fibres

97741-25S.PPT



8L197741-25

**Later Signs in Keratoconus**

In moderate to advanced stages of the disease, slit-lamp examination of the cornea may reveal stromal thinning (centrally or paracentrally, usually inferiorly or infero-temporally) and corneal disorganization. Increased corneal curvature and irregularity can be revealed by images of topographer mires (slide 84 and the progressively smaller area appearing in topographical maps (slide 85) as the data exceeds an instrument's range or becomes too irregular to be useful mathematically.

79

**LATER SIGNS**

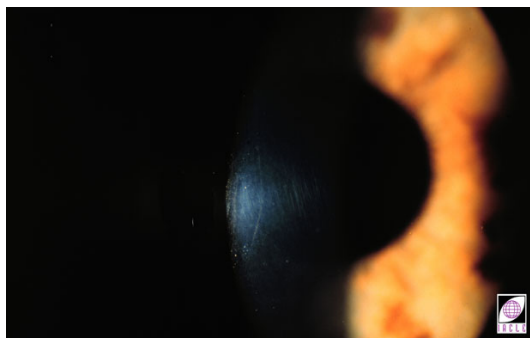
- Vogt's striae
- Apical scar formation
- Non uniform red reflex with ophthalmoscopy
- Rupture of Descemet's membrane (corneal hydrops)
- Reduced intra-ocular pressure

97741-26S.PPT



8L197741-26

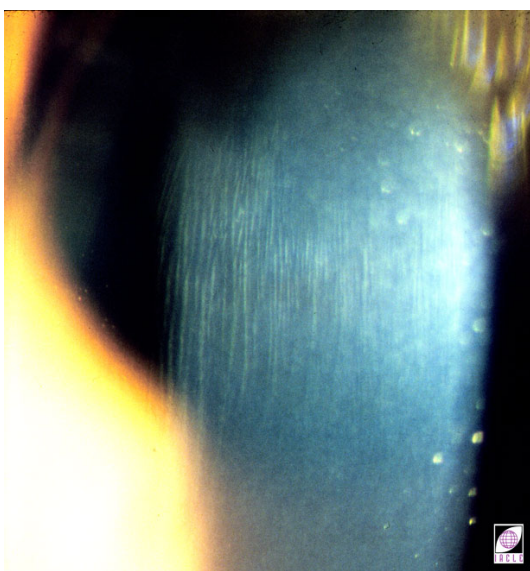
80



8L10190-98


Striae of Vogt are vertical (slides 80 and 81), horizontal (slide 82), starburst (slide 83), or oblique lines in the posterior stroma and Descemet's membrane within the region of the cone that are seen in about half of all keratoconus patients. They are due to disruption of the stromal lamellae that occur as a result of corneal ectasia. Pressure on the globe from a finger (applied via the lid) may reduce the visibility of the striae. Vogt's striae are visible folds in Descemet's membrane that run parallel to the steepest axis of the cone (Levit, 2001).

81



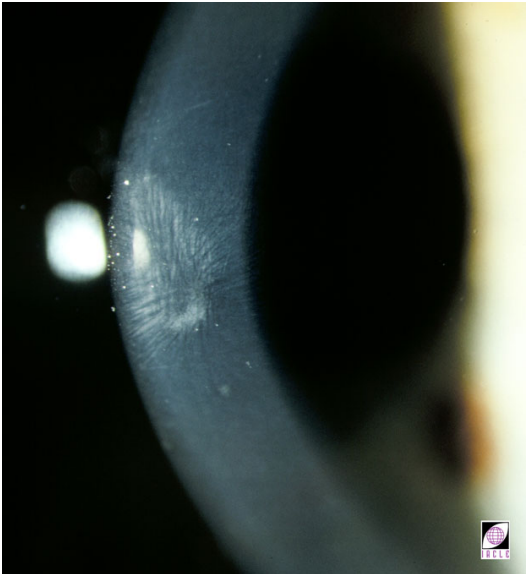
8L1LeW FrJ 1980

82



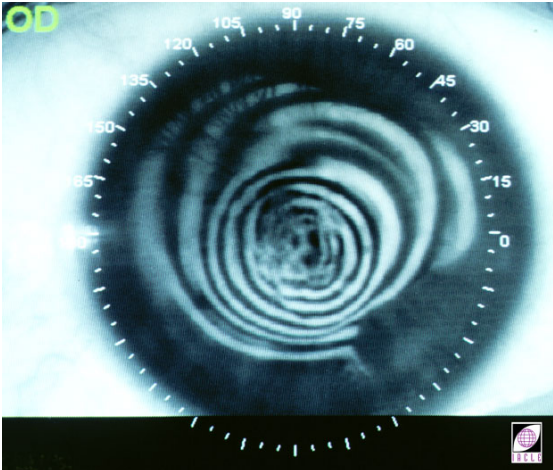
8L1DCP 4 28 14

83



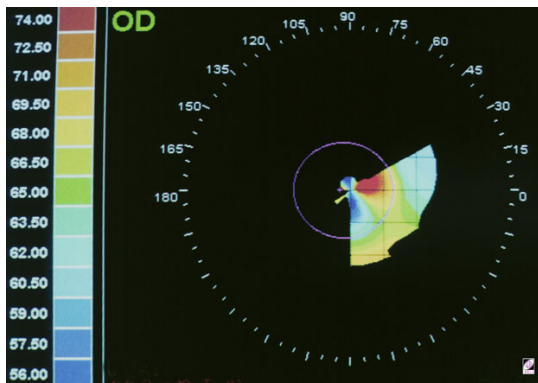
8L1DCP 4 16 3

84



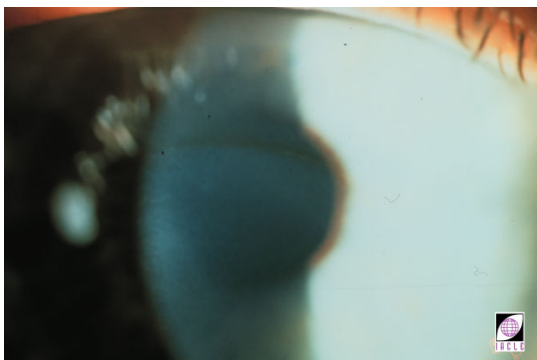
8L1DCP 4 29 13

85



8L1DCP 4 29 14 (SAME PATIENT AS ABOVE)

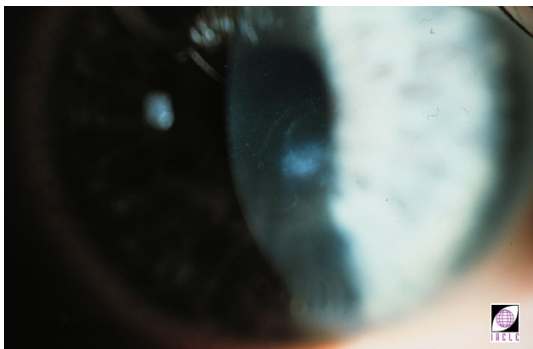
86



8L10064-97

A characteristic of keratoconus is the accumulation of an iron ring deposit that may surround the cone partially or completely. This is called Fleischer's ring (slide 86) and is best observed using cobalt blue illumination with the slit-lamp. This iron deposit may appear as a yellow or greenish ring and is believed to be caused by a disruption in, or a modification to, the normal process of epithelial cell sliding.

87

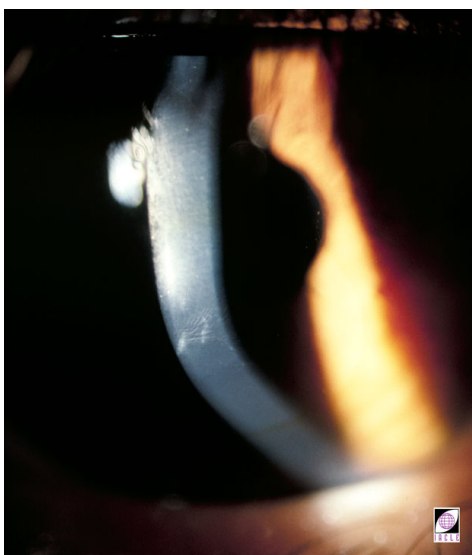


8L10316-98

A large variety of scars may be observed in keratoconic eyes. The development of a scar generally begins with a fine reticular pattern at the level of Bowman's layer. Denser and deeper scars occur as the condition progresses (slides 87 and 88).

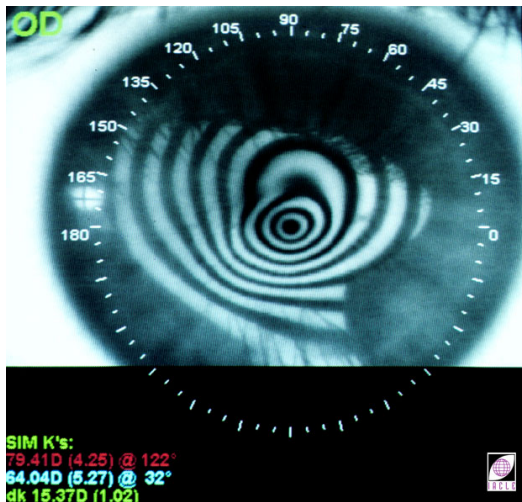
Corneal scarring in keratoconus can be exacerbated by contact lens wear, which is of course the main mode of management of the condition.

88



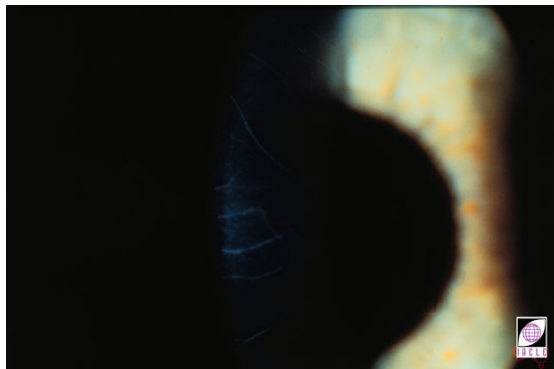
8L1DCP 4 28 11 (IRREGULARITY & SCARRING STARBURST)

89



8L1DCP 4 28 4 (SAME PATIENT AS ABOVE)

90



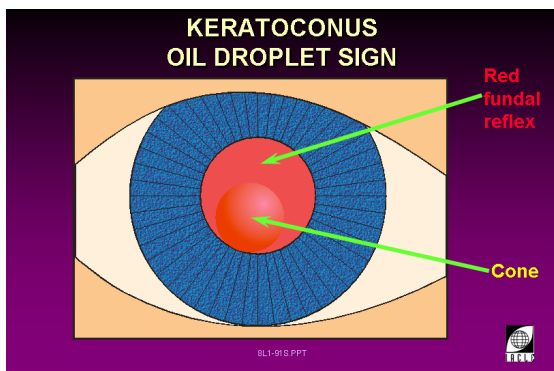
8L10915-93

The corneal nerve fibres in keratoconics are often more conspicuous when viewed with a slit-lamp (slide 90). The reason for this is not yet understood fully.

As the cone develops, the corneal profile becomes increasingly distorted and more prominent. This is best observed by instructing the patient to look down and noting the V-shaped conformation or bulge in the lower lid's profile produced by the ectatic cornea. This is referred to as Munson's sign.

In keratoconus, the red reflex seen with the ophthalmoscope has a non-uniform appearance and sometimes gives rise to a 'swimming' effect. This is due to the formation and progression of the cone that distorts the retro-illumination from the fundus. For a useful qualitative assessment of the shape, size, and location of the cone, use a +4 D lens in the Rekoss disc of a direct ophthalmoscope and observe the cornea retro-illuminated by the red fundal reflex (Sankaridurg, 2005 - personal communication). This is a variation of the so-called oil droplet sign (a.k.a. Charleux). It is the refractile result of an obvious and well-delineated cone, retro-illuminated by the red fundal reflex. This sign is best seen with a dilated pupil.

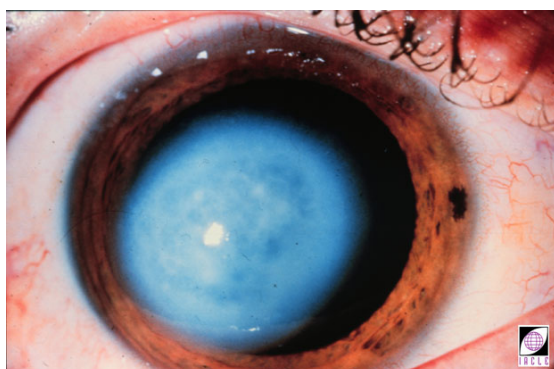
91



8L197741-120

The reduced corneal, and possibly scleral, rigidity (altered physical properties of the cornea) in keratoconus, especially advanced keratoconus, can lead to an apparent lowering of IOP (Burger *et al.*, 2003). However, the reliability of IOP findings is questionable and care should be taken when examining the eye, paying particular attention to other aspects of glaucoma screening, e.g. fundus appearance, optic disc, visual fields, and gonioscopy. The relationship between corneal physical properties and corneal thickness, and IOP (in all eyes, normal and keratoconic eyes) is the subject of ongoing research.

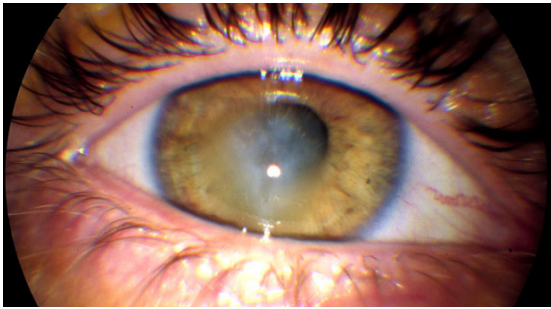
92



8L11008-93



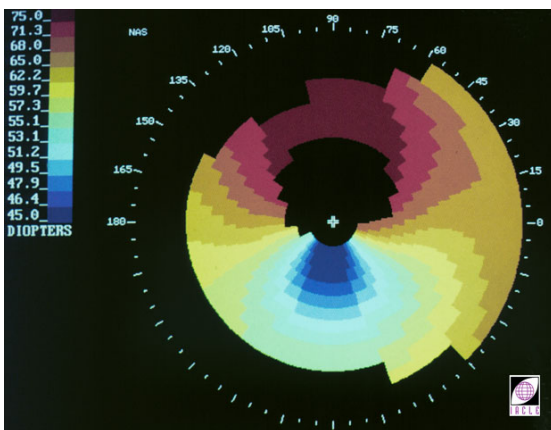
93



8L1AC-D DCP 4 3 5 (HYDROPS) ORIGINAL IMAGE SUPPLIED BY MR ANTHONY CHAPMAN-DAVIES, SYDNEY

In advanced keratoconus, breaks may form in Descemet's membrane, allowing stromal imbibition of aqueous humor causing severe corneal oedema. This is referred to as acute corneal hydrops (slide 92 to 94 – slide 93 courtesy of Mr Anthony Chapman-Davies, Sydney), and may be accompanied by pain, sudden vision loss, conjunctival injection, and diffuse stromal opacification. The pain and oedema may persist for a considerable period of time (3 to 4 months may be required to re-establish posterior corneal integrity/barrier function [Vyas, 2005]), gradually resolving with scarring.

94



8L1DCP 4 3 4 HYDROPS (TOPOGRAPHICAL) (SAME PATIENT AS ABOVE)

Rizzuti's sign is the nasal image of a (pen) torchlight shone from the temporal side, anterior to, but parallel with, the iris plane. The image is a result of refraction by the anterior eye, influenced particularly by corneal shape (slide 95). A similar process in the normal eye is believed to be a contributing factor in the so-called ocular ophthalmohelioses (Coroneo, 1993) of which pterygium is the best known and most common. In the normal eye, the nasal pattern of illumination is diffuse and even.

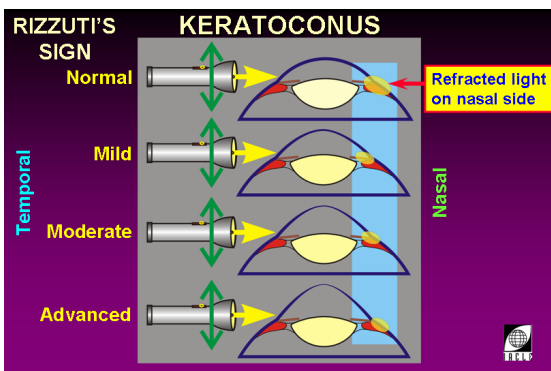
In keratoconus (and high myopic astigmatism that can give a false positive), the light rays are focused more sharply near the limbus. In mild cases, the light is focused inside the limbus, i.e. on the iris near the limbus.

In moderate to advanced cases, the light focuses outside the limbus, i.e. beyond the limbus to retro-illuminate the paralimbal sclera and conjunctiva.

In extreme cases or in keratoglobus, the cornea loses its conical shape and the light rays fail to converge to a sharp focus, again illuminating the corneo-limbal zone diffusely.

(Note: the literature contains most possible misspellings of the name *Rizzuti*. When searching for information on Rizzuti's sign, some of the alternatives [Ri, Ru, z, zz, t,tt, etc.] may be required).

95



8L197741-101

96


**KERATOCONUS**  
**IS IT KERATOCONUS?**

KISA%: Rabinowitz, 1995, Rabinowitz & Rasheed, 1999, Rabinowitz, 2003, Levy et al., 2004

- Corneal power (K) [ $>47.2$  D]
- Inferior-Superior dioptric asymmetry (I-S) [ $>1.2$  D]
- Astigmatism (Ast)
- Skewed Radial Axis (SRAX) [ $>21^\circ$ ]

• If KISA%  $> 60\%$ , case is a keratoconus suspect

97741-86S.PPT



8L197741-86

### Is It Keratoconus?

The effective diagnosis of keratoconus has always been, and remains, a challenge especially when other corneal conditions can meet the diagnostic criteria selected by a particular diagnostic schema, e.g. contact lens-induced warpage, corneal transplants (obvious in most cases), PMD, and refractive surgery (see Klyce *et al.*, 2000).

An early attempt at a single number descriptor is the Surface Asymmetry Index of Dingeldein *et al.* (1989). A more recent schema based on corneal topography is that of KISA% (see slide opposite) proposed by Rabinowitz, Rasheed, Levy and others. Wygledowska-Promienska and Zawajska (2000) reported favourably on their experiences with the KISA% system.

However, when applied in the broader context of a general cornea clinic, Klyce *et al.* (2000) urged caution in the use of KISA% because they found a high rate of false positives. This was attributed partially to the use of a population made up only of normal and keratoconics in the development of the system.

Regardless of whether early, *forme fruste*, or manifest keratoconus is being investigated, Saks (personal communication, 2005) suggested the following as aids to diagnosis:

- History of eye rubbing.
- History of allergy.
- Monocular diplopia.
- Ghosting of vision.
- A large 'collection' of spectacles.

He also suggested that during retinoscopy, the observation of what he termed a 'zonal' retinoscopic reflex (he avoids the use of the term scissor reflex as he does not regard it as typical of keratoconus although it does occur in keratoconus) is suggestive of keratoconus. Further, if a videokeratoscope is not available, the appearance of mire distortion or doubling through a one-position keratometer is also suggestive of keratoconus.

97

### CHARACTERISTICS OF KERATOCONICS

- Psychological profiles ?
  - creative
  - extrovert
  - intellectual
- Type A personality
- Mother's age

9741-27.S.PPT



8L197741-27

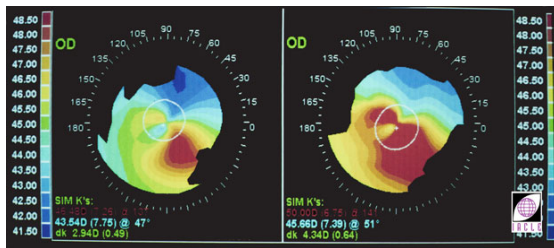
### Psychological and Sociological Factors in Keratoconus

Ophthalmic practitioners are frequently heard to observe that keratoconics are 'different' people, often of above-average intelligence. It is not uncommon to find them involved in the arts, other creative avenues, and jobs that tend to be more demanding intellectually.

It has been claimed that keratoconics are more sensitive to tactile stimuli, are more likely to feel depressed and anxious, and tend to become introspective about their 'condition' (Ruben and Khoo, 1989). The latter is not unreasonable given the difficulty of managing the condition, the daunting prospects of grafting, perhaps more than once in a lifetime, and the long-term uncertainty of the visual outcome, especially in the more progressive or more advanced cases.

**IV Contact Lens Fitting**

98



8L1DCP 4 4 13 (PROGRESSION: 1994 TO 1997)

**Contact Lens Fitting in Keratoconus**

As keratoconus progresses (slide 98), the magnitude and irregularity of corneal astigmatism increases. As a direct result, the quality of vision decreases. Generally, the contact lens correction of choice is RGP contact lenses, as they provide a regular refracting surface (albeit man-made) that neutralizes (almost, see Module 2, Lecture 2.3, slide 73) the irregular keratoconic corneal surface and provides an optimum visual correction. However, problems of physical fit resulting from the irregularity remain.

99

**CONTACT LENS FITTING**

- RGP CLs required by most keratoconics
- Corneal topography requires careful assessment
- Skilled fluorescein patterns interpretation is the cornerstone of successful fitting
- Lens modifications often required (in house?)

97741-28S.PPT

8L197741-28

Usually, conventional RGP designs work well in the early stages of keratoconus. Special multi-curve, specialized keratoconic fitting sets are required later when the cone becomes more clearly defined and the cornea more 'abnormal'.

To facilitate the fitting process, the practitioner needs to acquire as much information as possible, including quantitative data, about the topography of the corneas to be fitted. Generally, this involves measurements and observations made with a videokeratoscope, a keratometer, and the slit-lamp. It is useful to know the radius of curvature and approximate diameter of the cone in advance of any contact lens fitting. Topographical details about the cornea outside the region of the cone are also useful, especially if large diameter lenses are to be fitted.

100

**KERATOCONUS  
VARIABLES AFFECTING LENS COMFORT**

CLEK: Edrington et al., 2004

**Had a significant effect:**

- Minimal peripheral clearance → ↓ comfort

**Did not have a significant effect:**

- Disease severity (as measured by corneal steepness or BOZR that just clears apex)
- Apical fitting relationship (steep or flat)

97741-102S.PPT

8L197741-102

The key to fitting keratoconus successfully is the ability to interpret fluorescein patterns correctly and to choose appropriate alternative lens parameters based on interpretations of the pattern. Such decision making amounts to lens redesigning to optimize the lens-to-cornea fitting relationship. However, unintuitively, the central (at least) fitting relationship appears not to affect comfort (Edrington et al., 2004) (see slide 100).

Managing advanced cases of keratoconus can be both a most challenging and most rewarding experience.

101

**CONTACT LENS FITTING**

Other alternatives:

- Soft lenses
- Scleral lenses
- Hybrid designs

97741-29S.PPT

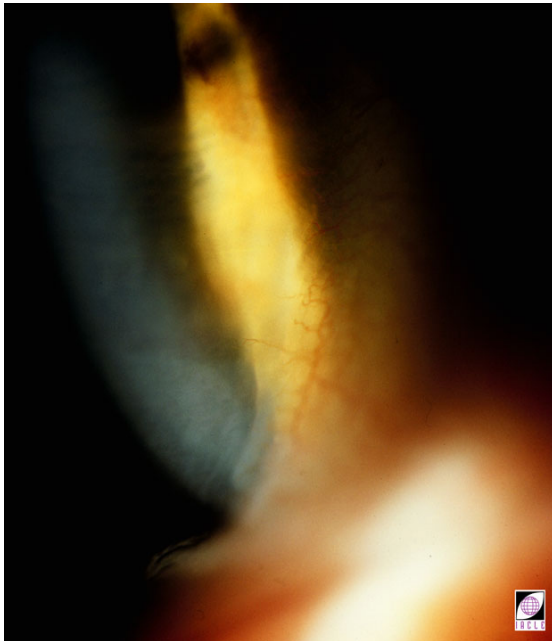
8L197741-29

**Fitting Keratoconus: Other Alternatives**

SCLs play a very limited role in the correction of keratoconus, as they usually do not provide keratoconics with adequate vision. In the early stages of the progression (or when RGP lenses cannot be tolerated due to an atopic condition), soft lenses may provide acceptable visual correction, especially if used in combination with an astigmatic spectacle over-correction. Furthermore, in the high Rx's often required, the low  $Dk/t$  of most SCLs can result in corneal neovascularization including deep stromal neovascularization (slide 102).

However, good clinical success with SCLs, especially toric SCLs, e.g. Soflens 66 Toric, has been reported (Saks, 2005 personal communication), especially in those cases that are

102



8L1DCP 4 15 21 (NEOVASC THICK SCL)

103

**KERATOCONUS  
CONTACT LENS OPTIONS**  
Lim & Vogt, 2002

n = 130

- CLs both eyes: 78.5%
- CLs one eye: 18.5%
- No CLs: 3%

Types of CLs

- PMMA: 2.7%
- RGPs: 96.1%
- SoftPerm™ (hybrid): 0.8%
- Scleral (haptic): 0.4%

9741-85S.PPT

8L197741-85

RGP lens-intolerant. Furthermore, the availability of higher cylinder powers (e.g. 2.75 D in Soflens 66) in stock, frequent replacement lenses has increased the number of cases that may be helped with some form of SCL. Provided they do not stress the corneas mechanically, siloxane hydrogel lenses, and more recently toric siloxane hydrogel lenses may also offer some assistance to rigid lens-intolerant keratoconics.

Ultimately, a balance must be struck between potential wearing time, vision quality, and comfort, a balance that probably rests more with the patient than the practitioner.

As corneal irregularity increases, RGP lenses are often required, eventually. In more advanced cases, lenses intended for post-corneal graft applications may offer some advantages, e.g. the earlier Swiss Falko asymmetric lathed lens or the more recent Bi-Sym™ asymmetrical lens (see later) that allows the superior and inferior radii of curvature to be stipulated independently. The blends required between the vertical zones are located in the lateral zones outside the central optic. A Quad-Sym™ lens also exists in which all four zones (two vertical, two horizontal) outside the optic can be ordered individually. This lens probably has few applications before grafting.

In cases where RGP lenses are unsatisfactory, a hybrid design such as the SoftPerm™ may be an acceptable alternative, albeit one offering low physiological performance. A hybrid lens has a rigid central portion with the optical neutralizing properties of a normal rigid lens and a soft peripheral skirt for improved wearer comfort. The major disadvantage of the SoftPerm™ lens is the low Dk material. This results in a lens with low oxygen transmissibility that can induce hypoxia, corneal neovascularization, and reduced endothelial cell density (Edmonds *et al.*, 2004). SoftPerm lenses have little application to the majority of keratoconics (Saks, 2005 personal communication).

Neovascularization is highly undesirable in keratoconus because the presence of active or potentially active blood vessels inside the normal perimeter of the limbal vasculature can be a significant factor in possible corneal graft rejection should a penetrating or lamellar keratoplasty be performed at a later date.

More recently (2005), a hybrid lens with greater physiological performance has been announced following its approval by the United States Food and Drug Administration (FDA). The SynergEyes™, a spherical hybrid lens from synergeyes, will be the initial product released ( $\pm 20$  D, up to 6 D of astigmatism) but it will be followed by the SynergEyes™ M lens for presbyopia sometime in 2006. While these lenses offer much 'on paper', their clinical effectiveness has yet to be tested outside the constraints of a formal clinical/trial.



Another 'unconventional' lens is the lathe-cut EpiCon LC lens, a large (13.5 mm total diameter) RGP lens specially designed for keratoconus. It is available from UltraVision Capricornia Australia ([www.ultravision.com.au](http://www.ultravision.com.au)).


In advanced keratoconus, the large diameter of the corneal ectasia can mean that a scleral lens may be the only option remaining before it becomes necessary to refer the patient for corneal surgery. If the apex of the cone is significantly decentred inferiorly, corneal lenses of any reasonable diameter may not provide an acceptable fit or good VA due to problems with limited optic zone diameters. Under these circumstances, scleral lenses may be an alternative. Furthermore, scleral lenses may be suitable for Down syndrome keratoconus cases. From a 1-year study of 130 keratoconics attending a tertiary contact lens referral centre at a UK hospital, Lim and Vogt (2002) derived the contact lens options data presented in slide 103.

104

**VIDEOKERATOSCOPY**

- Valuable for understanding corneal topography
- Provides central and peripheral information
- Useful for contact lens fitting

97741-305 PPT

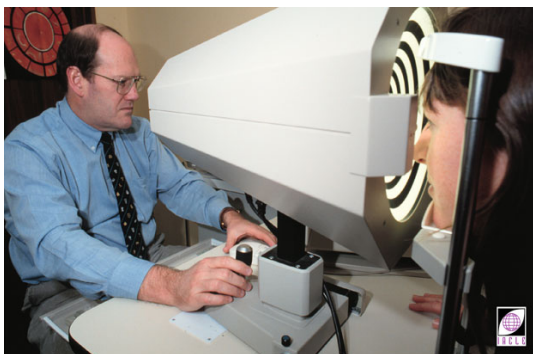

8L197741-30

**Videokeratotomy and Keratoconus**

Since computer-assisted videokeratoscopes are now more common in contact lens practices, the ability to detect keratoconus earlier and quantifiably has been enhanced significantly. Early sub-clinical forms of keratoconus may go undetected unless the topography of the cornea is evaluated carefully. As keratometry is limited to the central 3 mm of the cornea (approximately, the actual value depends on the corneal curvature), and because it assumes that the measured surface is spherocylindrical, it does not provide complete and accurate information on the topography of the keratoconic cornea. Furthermore, data from the CLEK study showed that the reproducibility of videokeratotomy data is lower in keratoconic eyes (McMahon *et al.*, 2005). It is reasonable to assume that keratometry suffers from the same difficulty and is potentially less accurate, especially as the irregularity increases with progression of the disease.

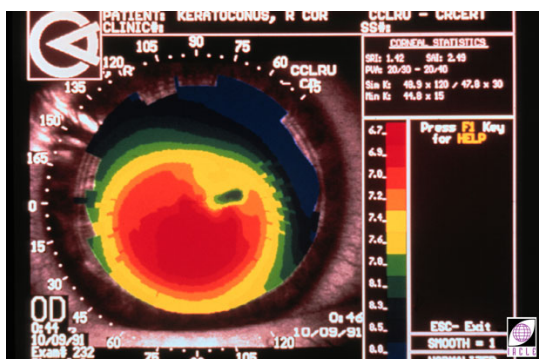
105



8L1548-99

Assessment of the corneal topography (slide 105) in keratoconus provides valuable information to the practitioner. It can help determine the location, curvature, and size of the cone, as well as the corneal eccentricity value (e.g. a highly prolate ellipse – see slide 106). The simulated keratometric values provided by these instruments can also be a useful guide in diagnostic lens selection.

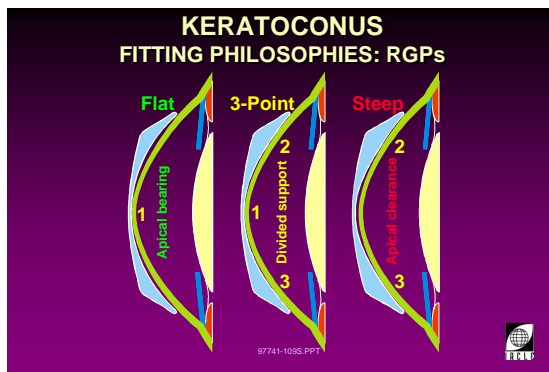
106



8L10961-95

In patients considering refractive surgery, the detection of sub-clinical keratoconus is extremely important, as *forme fruste* keratoconus is a contraindication for refractive surgery. Videokeratotomy is the only effective means of screening such unsuitable cases from patient lists (Nesburn *et al.*, 1995).

107



8L197741-109

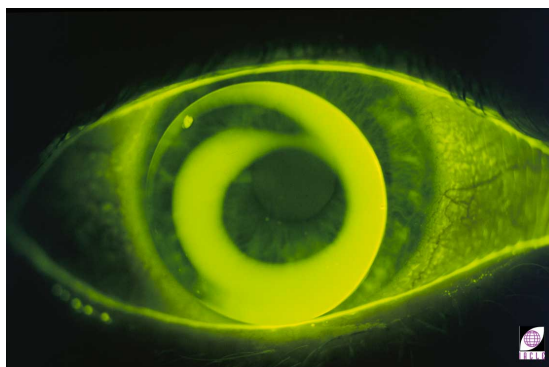
108

### APICAL BEARING

- Lens bears heavily on the corneal apex
- Provides good vision (regularized cornea?)
- May result in corneal insult and lens intolerance
- Likely to cause corneal scarring
  - no longer a favoured fitting method

8L197741-57

109



8L11685-95

110

### APICAL CLEARANCE

- Lens back surface vaults apex of cone
- Less risk of corneal scarring and corneal damage
- May cause variable vision due to uncorrected corneal astigmatism

8L197741-58

## Keratoconus: Fitting Philosophies

Three different general fitting philosophies (slide 107) for the keratoconic are in use:

- **Apical bearing:** the lens is fitted so that it bears heavily against the apex of the cone (slide 109). This fitting technique was widely used in earlier times when it was thought that a large flat rigid lens could reshape the cornea and halt the progression of keratoconus. Because this technique is more likely to cause corneal scarring, apical bearing has fallen from favour in recent years. Generally, it is not a prudent fitting philosophy and should be avoided.

Flat fitting RGP lenses, especially if the fit results in heavy bearing on the cornea, can also result in corneal abrasions, epithelial breakdown over the bearing area, and lens intolerance. If the situation is allowed to continue and the lens fit is poor, the risk of corneal scarring rises to unacceptable levels.

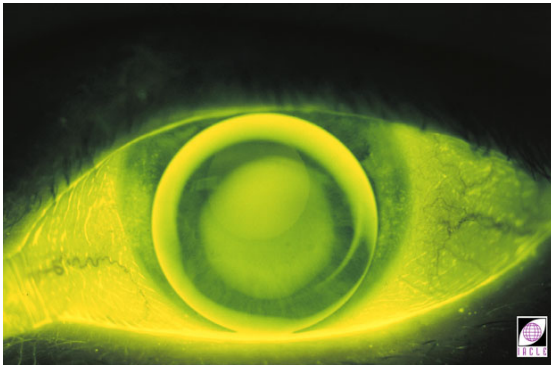
The apical bearing fitting technique often yields good vision, possibly due to corneal reshaping (regularizing) and/or masking of irregular astigmatism. With this fitting philosophy, a patient's vision may also remain relatively good for a period of time after lens removal. This is probably as a result of the corneal flattening (an ortho-K effect?).

- **Apical clearance:** the lens back surface vaults (clears) the cone apex (slide 111). Lens support or bearing is redirected to the paracentral cornea, away from the cone apex. The risk of scarring is reduced with this type of fitting, and it also contributes to minimal corneal oedema and reduced punctate staining. However, it may result in variable vision due to uncorrected corneal astigmatism.

Obviously, fitting a lens with apical clearance requires a relatively steep back optic zone radius (BOZR), which is also associated with a smaller back optic zone diameter (BOZD) and a smaller lens total diameter (TD). These small diameters could result in flare and/or monocular diplopia, especially at night when the pupil is larger. This is due largely to the fact that small lenses tend to centre on the cone itself. Because the cone is not usually on the visual axis, the entrance pupil of the eye is often covered partly by the edge/transition of the optic zone or even the lens edge itself. Poor vision is the inevitable result.

- In cases where this fitting philosophy is followed, the fluorescein pattern should be monitored carefully to ensure there is no lens-to-cornea adherence or peripheral 'seal-off' resulting in a stagnant post-lens tear film. The plus tear lens resulting from an apical clearance fit necessitates a more minus contact lens back vertex power (BVP; and greater junction thicknesses at the

111




8L1294-98

112

**THREE-POINT TOUCH**

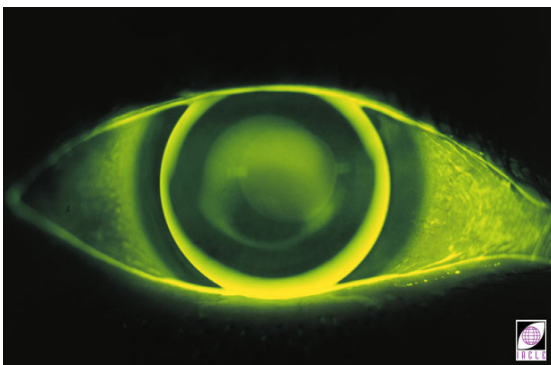
- Divided support
- Lens weight distributed over larger area
- Preferred lens fitting technique
- Stable vision and lens fitting

97741-59S.PPT



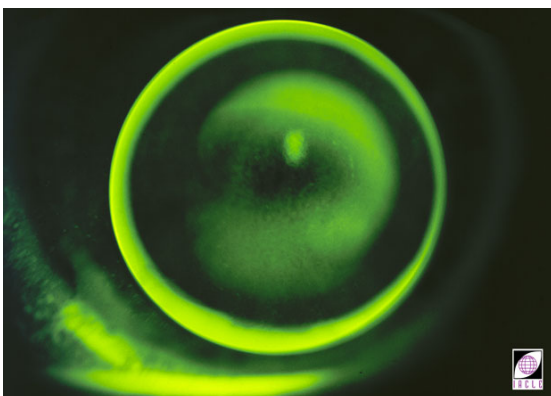
8L197741-59

113



8L11681-95

114



8L1DCP 4 33 14

edge of the optic zone). This can lead to increased lens discomfort.

- **Three-point touch:** the lens rests lightly against the cone apex and is also supported on the nasal and temporal corneal zones by the mid-periphery of the lens back surface (slides 113 and 114, with a Rose K lens shown in slide 115). It is a balance or compromise between apical bearing and apical touch. This fitting technique is also known as 'divided support', and the weight of the lens is distributed over as large an area of the cornea as possible. The apical contact area is usually about 2 to 3 mm, surrounded by an intermediate clearance zone, a mid-peripheral contact annulus, and conventional edge clearance at the lens periphery.

Three-point touch is the preferred lens fitting technique of many practitioners as it provides stable fitting and vision, with long-term comfort, and increased wearing time. It appears to give the best results in almost all degrees of keratoconus, from mild to the most advanced. As with pure apical bearing, there is the possibility of corneal scarring, so close ongoing monitoring of the patient is recommended.

The divided support fitting technique can also be modified to tend towards apical clearance, as long as there is no compromise in the visual acuity. In this way, the central touch would still be acceptable for some time as the condition progresses and the cone advances.

It has been pointed out (Saks, 2005 personal communication) that '3-point touch' is something of a misnomer in that what is really implied is more donut-like, i.e. a circular zone of central touch surrounded by an annulus of sodium fluorescein pooling which in turn is surrounded by a mid-peripheral annulus of touch (see slide 107, middle image and slide 111 [note: some decentration is apparent in this image so the pattern is not exactly as described above]), i.e. '2-zone' touch.

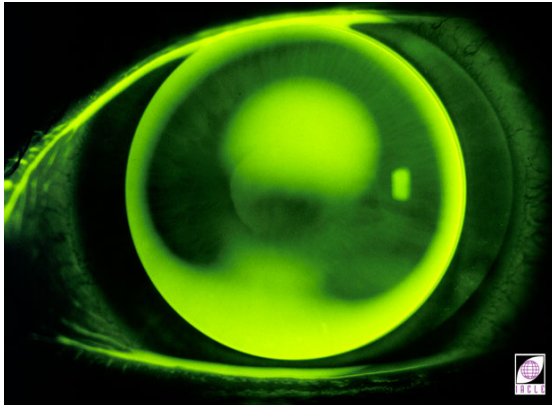
With nipple cones, a small apical clearance lens is usually suitable and easy to achieve.

In the case of sagging or oval cones, larger diameter rigid lenses may be required.

Apical clearance is much harder to achieve with oval cones, and the three-point touch (divided support) technique is more useful.



115




8L1DCP 4 22 18 (ROSE K)

116

**LENS FITTING OBJECTIVES**

- Provide best possible vision
- Minimize interference with corneal physiology
- Optimize lens comfort
- Relocate lens bearing area to the mid-peripheral cornea

97741-32S.PPT



8L197741-32

**Keratoconus: Fitting Objectives**

Although the keratoconic eye is generally more difficult to fit than a normal eye, the fitting objectives are essentially the same for both.

Excessive bearing should be prevented by optimal selection of the back surface shape (slide 118).


A key factor in any RGP lens fitting is the quality of movement. A keratoconic lens must demonstrate good movement with each blink to prevent the risk of lens adherence and/or 3 & 9 o'clock staining (slide 111) as well as to ensure adequate tear exchange under the lens.

117

**LENS FITTING OBJECTIVES**

- Gentle (benign) cone contact (BOZR)
- Minimize bubble formation (especially over pupil area) by matching BOZD to diameter of cone
- Optimize lens movement (TD)

97741-33S.PPT



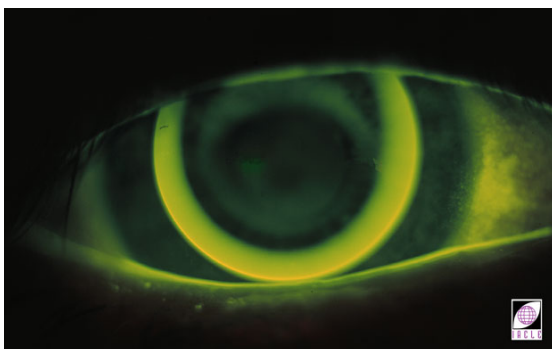
8L197741-33

The degree of edge lift achieved with an RGP lens on a keratoconic cornea is almost as important as determining the central curve. When the peripheral curves are too steep, lens movement is restricted and there is an inadequate tear reservoir. This may lead to lens adherence. Furthermore, a prime reason for RGP discomfort in keratoconus is a 'tight' fitting lens.

On the other hand, peripheral curves that are too flat may result in excessive edge lift, causing a foreign body sensation and lid irritation, excessive lens movement, and repeated lens dislodgement.

Lenses with toroidal peripheral curves are sometimes used in keratoconic eyes to enhance lens centration or to improve the lens fit when there is too much inferior edge clearance (stand-off). In some cases, lenses with a toric back surface and a toric periphery may be required. In more extreme cases, asymmetric lenses, e.g. Bi-Sym™ or Quad-Sym™ lenses, may be required.

118




8L10100-99

119

**FITTING CONSIDERATIONS**

- Cone position
- Cone size and shape
- Degree of myopia and corneal astigmatism
- Corneal radius (central and steepest)
- Corneal toricity
- Corneal eccentricity value

97741-34S.PPT




8L197741-34

120

**FITTING CONSIDERATIONS**

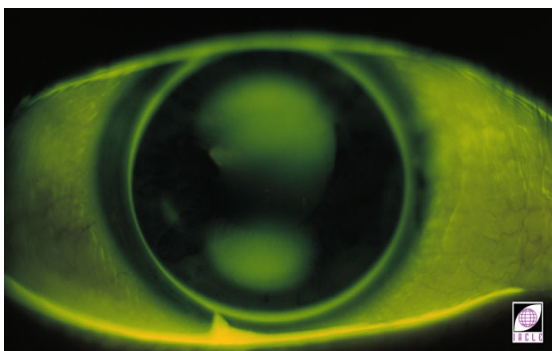
- Corneal topography
- Disease progression
  - degree
  - rate
- Visual acuity
- Contact lens tolerance

97741-35S.PPT



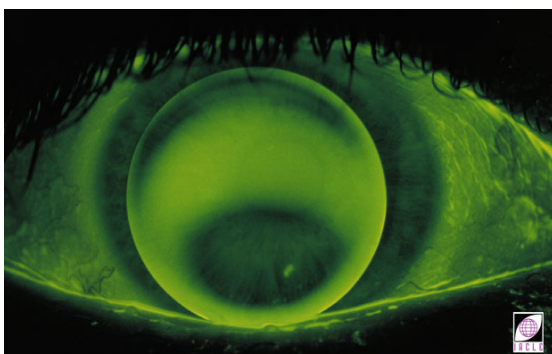
8L197741-35

121



8L1921-93

122



8L1171-95

### Keratoconus: Lens Fitting Considerations

A number of factors must be considered when attempting to fit a keratoconus patient with contact lenses.

The practitioner must assess the cornea with both a slit-lamp and a videokeratoscope to determine the location, size, and shape of the cone.

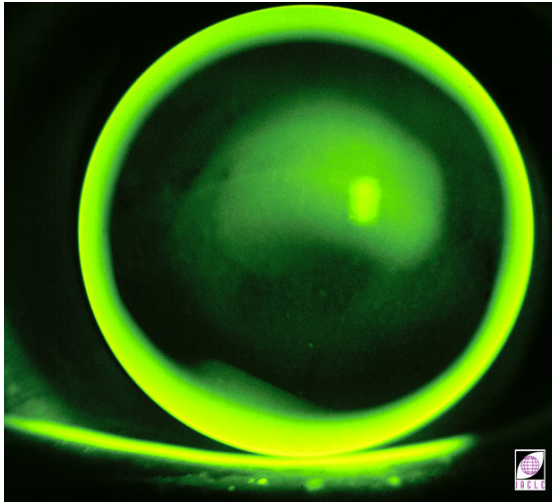
Advanced keratoconus is more challenging to fit with contact lenses and the practitioner must rely heavily on interpreting the lens fitting characteristics and fluorescein patterns if a successful outcome is to be achieved (slides 121 to 124).

Patient expectations regarding lens comfort and quality of vision must be realistic. An important part of the practitioner's patient management strategy is to keep the patient's expectations realistic. If the expectations are otherwise, the experiences of both patient and practitioner will be unduly stressful.

Mid-periphery too tight and low axial edge clearance (slide 121).

Too much touch over the cone. Aim for 2 to 3 mm of 'feather' touch. The picture also shows a large BOZD with excessive superior pooling. The BOZD should be reduced and the BOZR should be steepened (slide 122).

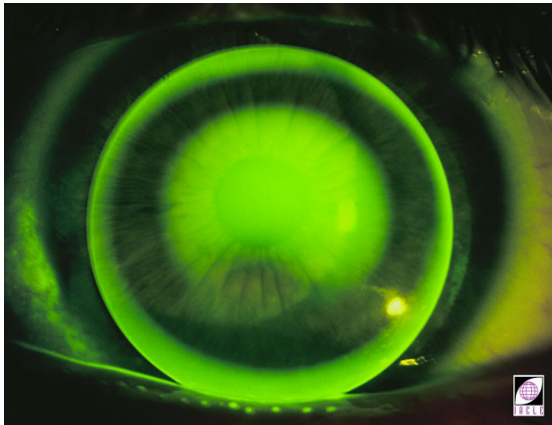
123



8L1DCP 4 47 10 ROSE K

Reduced cone apex bearing (slide 123).

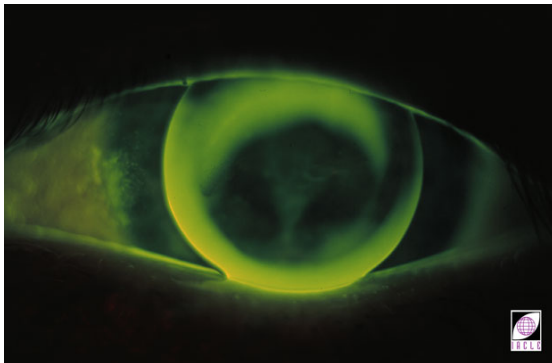
124



8L1DCP 4 40 24

A more eccentric cone with some cone apical bearing (slide 124). The post-lens tear film above the apex would probably benefit from some reduction in the depth of pooling but the location of the cone apex probably makes such a reduction difficult without the use of an asymmetric (inf.-sup.) lens, e.g. a Bi-Sym (see slide 137).


125



8L10101-98

Large area of central touch causing central scarring. Lower lens edge is sitting on the lower lid margin. Usually, such lid-lens interaction reduces comfort (slide 125).

126



8L1DCP 4 23 9

Excessive edge clearance (in this example at 5 o'clock) can lead to excessive tear pooling and bubble formation (slide 126).

127

### FITTING KERATOCONUS TRIAL LENSES

- Quality
- Quantity
- Range of BOZR, BOZDs, TDs, and BVPs
  - generally, as BOZR ↓, BVP ↑
- Range of designs & fitting philosophies

97741-36S.PPT

8L197741-36

128

### FITTING KERATOCONUS TRIAL LENSES

- Special keratoconus sets:
  - tricurve,
  - tetracurve, or...
  - aspheric
- Lenses to cover range from moderate to advanced cases
- Desirable to include more than one design

97741-37S.PPT

8L197741-37

129

### KERATOCONUS LENS DESIGNS: RGP's

*Woodward Tri-curve KC Trial Set*

(abbreviated set of parameters)

BOZR	BOZD	TD	BVP
5.50	5.50	8.00	-10.00
5.60	5.60	8.00	-10.00
5.70	5.70	8.80	-9.50
5.80	5.70	8.80	-9.00
5.90	5.80	8.80	-8.50
6.00	5.80	9.00	-8.00
6.10	5.90	9.00	-7.50
6.20	5.90	9.00	-7.00
6.30	6.00	9.00	-6.50
6.40	6.00	9.00	-6.00
6.50	6.00	9.00	-5.50
6.60	6.00	9.00	-5.00
6.70	6.00	9.00	-4.50
6.80	6.00	9.20	-4.00
6.90	6.00	9.20	-3.50
7.00	6.00	9.20	-3.00

**Woodward, 1989**

**Note as BOZR ↑:**

- BOZD ↑
- TD ↑
- BVP ↓

97741-104S.PPT

8L197741-104

130

### KERATOCONUS LENS DESIGNS: RGP's

*UltraVision CLPL Topflex KC Trial Set*

**Note as BOZR ↑:**

- Axial edge lift ↓

BOZR	TD Nipple	TD Oval	TD Globus	BVP
5.60	8.1	8.6	9.1	-10.00
5.70	8.1	8.6	9.1	-9.50
5.80	8.1	8.6	9.1	-9.00
5.90	8.1	8.6	9.1	-8.50
6.00	8.1	8.6	9.1	-8.00
6.10	8.1	8.6	9.1	-7.50
6.20	8.1	8.6	9.1	-7.00
6.30	8.1	8.6	9.1	-6.50
6.40	8.1	8.6	9.1	-6.00
6.50	8.1	8.6	9.1	-5.50
6.60	8.1	8.6	9.1	-5.00
6.70	8.1	8.6	9.1	-4.50

**Nipple Cone Set**  
BOZR: 5.60 to 6.70  
TD: 8.10  
BVP: -4.50 to -10.00

**Oval Cone Set**  
BOZR: 5.60 to 6.70  
TD: 8.60  
BVP: -4.50 to -10.00

**Globus Cone Set**  
BOZR: 5.60 to 6.70  
TD: 9.10  
BVP: -4.50 to -10.00

97741-105S.PPT

8L197741-105

### Keratoconus: Trial Lenses

A wide range of specialized trial lenses is required if keratoconus patients are to be fitted successfully. The trial sets must be designed specifically for keratoconic corneas and it is prudent to have a range of lenses that covers mild to advanced cases. An extensive trial lens set enables the practitioner to fit a lens that is close to the optimal design from their own trial set. Any design change that is required for the lens ordered should be minimal, thereby increasing the chance of success with the first fitting.

A recommended range of trial lenses to cater for all degrees of keratoconus is as follows:


- BOZR from 5.3-7.5 mm. If the practice specializes in keratoconus, thought needs to be given to having a wider range of parameters, e.g. BOZR to 4.9 mm or steeper.
- BOZD from 5.6 to 7.6 mm. It is widely believed that the BOZD must be made smaller as the BOZR steepens. However, in recent years corneal topography has suggested that more advanced cones are actually larger. Therefore larger BOZD may be more suitable in steeper, more advanced cases, to achieve three-point touch and to avoid bubble formation over the cone. Obviously, for a spherical BOZR, the theoretical limit for the BOZD is 2 X BOZR, i.e. a perfect hemisphere for the optic. In practice, this is neither practical nor desirable.
- BVP from -2.00 to -18.00D. The BVP must be higher as the BOZR steepens (see slides 129 to 136 for some examples of keratoconic trial sets).
- TD from 8.40 to 9.20 mm. The TD is dictated by a number of factors. Generally, a smaller TD is considered more effective as the degree of keratoconus increases.

131

**KERATOCONUS**  
**LENS DESIGNS: RGP's**  
*Nu Contacts (A.J Phillips) KC Trial Set*

**K2**  
Early to moderate keratoconus

BOZR	BPR1	BPR2	BPR3	TD	BVP
<b>BOZR: 6.80</b>	<b>1 mm</b>	<b>0.3 mm</b>	<b>0.2 mm</b>		
6.00	7.50	10.50	12.25	9.80	-5.00
6.10	7.60	10.50	12.25	9.80	-5.00
6.20	7.70	10.50	12.25	9.80	-5.00
6.30	7.80	10.50	12.25	9.80	-5.00
6.40	7.90	10.50	12.25	9.80	-5.00
6.50	8.00	10.50	12.25	9.80	-5.00
6.60	8.10	10.50	12.25	9.80	-5.00
6.80	8.20	10.50	12.25	9.80	-5.00
6.90	8.30	10.50	12.25	9.80	-5.00
7.00	8.40	10.50	12.25	9.80	-5.00
7.10	8.30	10.50	12.25	9.80	-5.00
7.20	8.40	10.50	12.25	9.80	-5.00
7.30	8.50	10.50	12.25	9.80	-5.00
7.40	8.60	10.50	12.25	9.80	-5.00

97741-108S.PPT 


8L197741-108

132

**KERATOCONUS**  
**LENS DESIGNS: RGP's**  
*Nu Contacts (A.J Phillips) KC Trial Set*

**K1**  
Advanced keratoconus

BOZR	BOZD	BPR1	BPR2	BPR3	TD	BVP
		<b>1 mm</b>	<b>0.3 mm</b>	<b>0.2 mm</b>		
5.00	6.00	7.20	10.50	12.25	9.00	-10.00
5.20	6.00	7.40	10.50	12.25	9.00	-10.00
5.40	6.00	7.60	10.50	12.25	9.00	-10.00
5.60	6.00	7.70	10.50	12.25	9.00	-10.00
5.80	6.00	7.80	10.50	12.25	9.00	-10.00
6.00	6.50	8.00	10.50	12.25	9.50	-10.00
6.20	6.50	8.20	10.50	12.25	9.50	-5.00
6.40	6.50	8.40	10.50	12.25	9.50	-5.00
6.50	6.50	8.50	10.50	12.25	9.50	-5.00
6.60	6.50	8.10	10.50	12.25	9.50	-5.00
6.70	6.50	8.20	10.50	12.25	9.50	-5.00
6.80	6.50	8.30	10.50	12.25	9.50	-5.00
6.90	6.50	8.40	10.50	12.25	9.50	-5.00
7.00	6.50	8.50	10.50	12.25	9.50	-5.00

97741-107S.PPT 


8L197741-107

133

**KERATOCONUS**  
**LENS DESIGNS: RGP's**  
*ACL KC Trial Set*

**3-Point touch**  
Small diameter

BOZR	BPR1	BPR2	BPR3	TD	BVP
<b>BOZR: 6.60</b>	<b>0.6 mm</b>	<b>0.4 mm</b>	<b>0.3 mm</b>		
5.20	6.50	8.50	12.00	8.00	-18.00
5.30	6.60	8.50	12.00	8.00	-16.50
5.40	6.70	8.50	12.00	8.00	-16.50
5.50	6.80	8.50	12.00	8.00	-16.50
5.60	6.90	8.50	12.00	8.00	-14.50
5.70	7.00	8.50	12.00	8.00	-14.50
5.80	7.10	8.50	12.00	8.00	-14.50
6.00	7.10	8.50	12.00	8.00	-13.00
6.10	7.00	8.50	12.00	8.00	-12.50
6.20	7.10	8.50	12.00	8.00	-12.00
6.30	7.20	8.50	12.00	8.00	-10.50
6.40	7.30	8.50	12.00	8.00	-9.50
6.50	7.40	8.50	12.00	8.00	-10.00
6.60	7.30	8.50	12.00	8.00	-9.50
6.70	7.40	8.50	12.00	8.00	-8.50
6.80	7.50	8.50	12.00	8.50	-6.50
6.90	7.60	8.50	12.00	8.50	-6.00
7.00	7.70	8.50	12.00	8.50	-5.50
7.10	7.60	8.50	12.00	8.50	-5.00
7.20	7.70	8.50	12.00	8.50	-4.50
7.30	7.80	8.50	12.00	8.50	-4.00

97741-110S.PPT 

8L197741-110

134


**KERATOCONUS**  
**LENS DESIGNS: RGP's**  
*Rose K KC Trial Set*

BOZR's available: 4.75 - 8

TDs available: 7.9 - 10.2

Edge Lift:  
Standard,  
Increased,  
Decreased

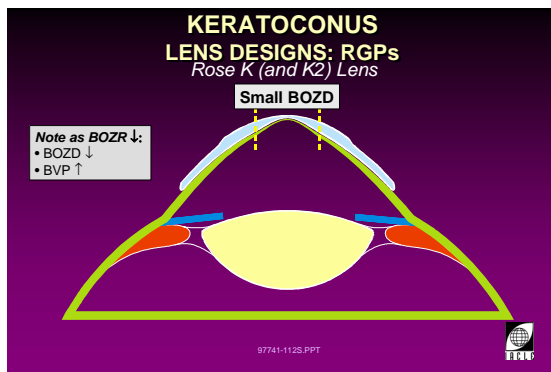
BOZR	BOZD	TD	BVP
5.10	4.00	8.70	-19.00
5.20	4.10	8.70	-19.00
5.30	4.20	8.70	-19.00
5.40	4.30	8.70	-19.00
5.50	4.40	8.70	-18.50
5.60	4.50	8.70	-18.00
5.70	4.60	8.70	-17.50
5.80	4.70	8.70	-16.50
5.90	4.80	8.70	-16.50
6.00	4.90	8.70	-14.50
6.10	5.00	8.70	-13.50
6.20	5.10	8.70	-12.50
6.30	5.20	8.70	-11.50
6.40	5.30	8.70	-10.50
6.50	5.40	8.70	-9.00
6.60	5.50	8.70	-8.00
6.70	5.60	8.70	-7.50
6.80	5.70	8.70	-6.50
6.90	5.80	8.70	-5.50
7.00	5.90	8.70	-4.00
7.10	6.00	8.70	-3.00
7.20	6.10	8.70	-3.00
7.30	6.20	8.70	-3.00
7.40	6.30	8.70	-2.00
7.50	6.40	8.70	-2.00
7.60	6.50	8.70	-2.00

97741-109S.PPT 

8L197741-106



135



8L197741-112

136

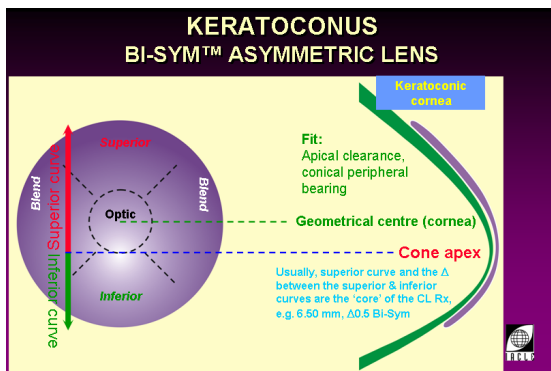
**KERATOCONUS**  
**LENS DESIGNS: RGP's**  
*CLEK KC Trial Set* from Edrington et al., 1998

BOZR 6.5mm	BOZR 7.0mm	BOZR 7.5mm	BOZR 8.0mm	BOZR
10.00	11.00	11.00	11.00	-10.00
10.25	11.00	11.00	11.00	-9.50
10.50	11.00	11.00	11.00	-9.00
10.75	11.00	11.00	11.00	-8.50
11.00	11.00	11.00	11.00	-8.00
11.25	11.00	11.00	11.00	-7.50
11.50	11.00	11.00	11.00	-7.00
11.75	11.00	11.00	11.00	-6.50
12.00	11.00	11.00	11.00	-6.00
12.25	11.00	11.00	11.00	-5.50
12.50	11.00	11.00	11.00	-5.00
12.75	11.00	11.00	11.00	-4.50
13.00	11.00	11.00	11.00	-4.00
13.25	11.00	11.00	11.00	-3.50
13.50	11.00	11.00	11.00	-3.00
13.75	11.00	11.00	11.00	-2.50
14.00	11.00	11.00	11.00	-2.00
14.25	11.00	11.00	11.00	-1.50
14.50	11.00	11.00	11.00	-1.00
14.75	11.00	11.00	11.00	-0.50
15.00	11.00	11.00	11.00	0.00

97741-113S.PPT

8L197741-113

137



8L197741-115

138

- TRIAL FITTING PRINCIPLES**
- Steeper lenses with advanced cone
  - Smaller TD in more advanced cases?
  - Select BOZR equivalent to mean central keratometry (or videokeratoscopy) value
  - Start with BOZR that produces apical clearance and flatten gradually, subsequently
  - Change the BOZR in 0.10 mm steps
- 97741-38S.PPT

8L197741-38

**Keratoconus: Trial Fitting Principles**

When fitting keratoconus, the ideal is to use a trial lens whose shape is close to that of the cone being fitted. For more advanced cones, the lenses must be steeper. Many practitioners also prefer to fit smaller lens diameters in the case of advanced cones but if the cone diameter is also larger (as well as more advanced) this may not be possible.

A suitable starting point is to choose a lens with a BOZR that approximates the midpoint of the apical keratometric or videokeratometric values, especially if larger TDs and BOZDs are being considered.


In cases where it is more desirable to fit a lens with a smaller TD and BOZD, it is appropriate to start with a BOZR 0.2 mm steeper than the mean keratometry (or videokeratoscopy) reading.

139

8L197741-39

**TRIAL FITTING PRINCIPLES**

- BOZD approximately equal to BOZR + 0.2 mm
- Small BOZD is preferred (6.0 – 7.0 mm)
- Lens TD 8.50 to 9.50 mm
- Trial fit to achieve acceptable central and peripheral lens-to-cornea relationship

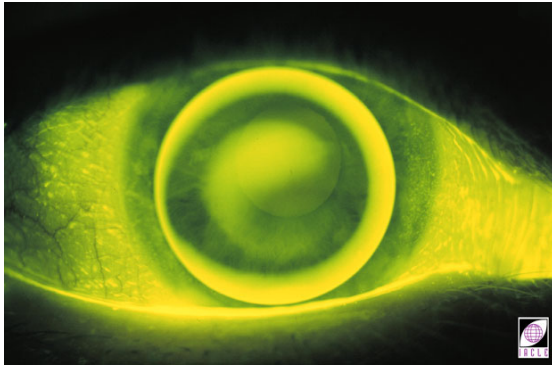
97741-39S.PPT 

The TD of the first trial lens should be kept small. A suitable starting point is 8.70 mm.

Ideally, the trial lens fluorescein pattern should demonstrate light apical touch with mid-peripheral bearing and adequate (0.5 to 0.7 mm) edge lift and clearance (slide 140).

Usually three to four back curves are necessary to accommodate adequately the rapid flattening of the cornea in the mid-periphery and periphery. To prevent seal-off and lens adherence, the outer peripheral curves of a keratoconus lens are often made flatter and wider than conventional designs. A minimum peripheral curve radius of 12 mm with a 0.4 mm width is not uncommon (Bennett and Hom, 2004). An alternative is to use an aspherical peripheral curve design (e.g. Schlanger *et al.*, 1998).

140



8L10291-98


The lens should move approximately 1 mm with each blink. Excessive lens movement may cause mechanical abrasion of the cornea and unnecessary discomfort.

The dioptric power of the contact lens to be ordered should be determined by over-refraction through a trial lens incorporating the final back surface design.

141

**FITTING PRINCIPLES  
PRACTICAL TIPS**

- Fluorescein pattern assessment is crucial
- Know the trial lens peripheral curves (design)
- Peripheral curves can be flattened, but not steepened, by in-house modification tools
- Do not raise patient's expectations too high regarding expected visual performance
- Maintain detailed fitting notes and diagrams, including photo documentation if possible

97741-40S.PPT 

8L197741-40

### Practical Tips for Fitting Keratoconics

Many of the practical fitting tips for a keratoconic patient (slides 141 and 142) are similar to those applied to routine RGP lens fitting.

A thorough understanding of the back surface shape of the trial lenses enables the practitioner to fine-tune the lens design for optimal fitting. A key factor is the assessment and interpretation of the fluorescein fitting pattern. Areas of excessive lens bearing may cause significant damage to a keratoconic cornea and generally should be avoided.

Modifications to the peripheral curve are often required. A toric peripheral curve design (slide 143) or even a bitoric lens (slide 144) can be considered if there is inconsistent axial edge clearance around the lens periphery.

However, toric back surface lens designs are rarely successful in keratoconus, as the astigmatism is irregular.


The BVP of the contact lens cannot be determined empirically and an over-refraction will always be required. If necessary, uncorrected cylinder power can be provided by over-spectacles.

Over the years, several special lens designs have been developed in an attempt to fit the keratoconic cornea successfully.

142

**FITTING PRINCIPLES  
PRACTICAL TIPS**

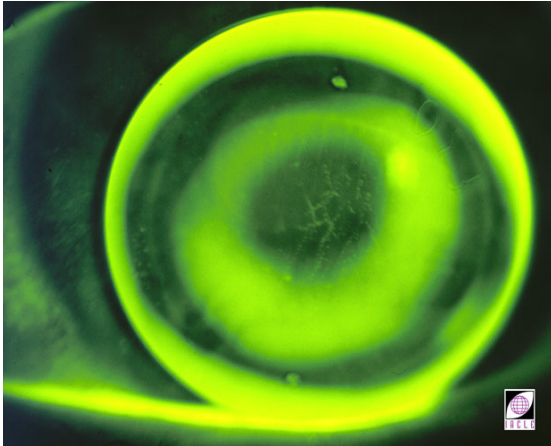
- Toric back surface lenses rarely work (non-orthogonal astigmatism)
- Consider toric peripheral curve design if axial edge clearance is inconsistent around lens edge
- Modification of peripheral curve is often required
- BVP not determinable empirically (use over-Rx on a trial lens)
- Correct any residual cylindrical Rx with over-spectacles
- Review patient regularly (e.g. 3-monthly in early stages of care)
- Look for 3 & 9 o'clock and central punctate staining
- Consider fenestrations for ↑ tear exchange

97741-41S.PPT 

8L197741-41

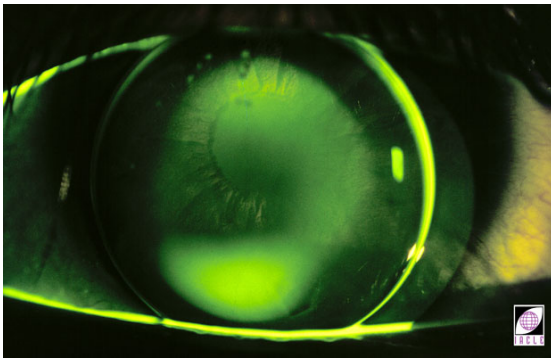


143



8L1DCP 4 34 9 (TORIC PERIPHERY)

144



8L1DCP 4 19 21 (BITORIC LENS)

The Rose K lens (see Caroline *et al.*, 1997), for example, has a smaller posterior optic zone and three peripheral lens clearances to help minimize superior corneal impingement. Betts *et al.* (2002) reported that although Rose K lenses provided equal VA compared to other specialty lenses, Rose K lenses were preferred by the wearers and had a higher successful fitting rate.

Other widely used special keratoconus lenses include the Soper Cone, Bi-Sym (intended originally as a post-graft lens design), McGuire, and CLEK designs.


Irrespective of contact lens type or fitting philosophy, regular keratoconus patient after-care is essential. At such visits, the corneal shape must be assessed and any changes monitored because they alter the lens-cornea relationship. It is recommended that patients should be evaluated at least every 6 months while the disease is progressing, and annually once the condition has stabilized.

145

**FITTING PRINCIPLES  
LENS MATERIAL**

- Need stable material
- High oxygen transmissibility
- Lenses should be checked for flexure and/or warpage at each after-care visit

97741-42S.PPT



8L197741-42

#### Keratoconus: Choice of Lens Material

Stability of the lens design is a key factor in successful keratoconus fitting. Ideally, the lens should show minimal flexure or warpage characteristics and maintain a stable shape in the longer term. This requires the use of stable lens materials.

Materials with high oxygen transmissibility ( $Dk/t$  of 60 to 100+) and known shape stability are the most suitable and should result in minimal compromise of corneal physiology.

To prevent flexure, the centre thickness of the lens could also be increased (with an attendant decrease in lens transmissibility).

Some authors have also suggested the incorporation of UV-blocking tints into lenses for keratoconus. This may be due at least partially to the Kenney and Brown (2003) Cascade Hypothesis that implicates  $UV_B$  in the aetiology of keratoconus (slide 19).

146

### FITTING KERATOCONUS OTHER OPTIONS

- Soft lenses (rarely used)
- Piggyback lens systems
- Hybrid (soft skirt, RGP centre)
- Scleral lenses (in advanced cases)

97741-43S.PPT



8L197741-43

### Keratoconus: Other Lens Fitting Options

For the majority of keratoconus patients, RGP lenses provide the best alternative for vision correction.

When centration and/or comfort with RGP lenses are problematic, piggyback lenses are an alternative. A siloxane hydrogel offers the most appropriate choice of carrier lens.

In some cases, alternative lenses or management options must be explored.

147

### FITTING KERATOCONUS SOFT LENSES

- Early in the progression only
- In cases of RGP intolerance
- Usually, cylindrical correction provided by over-spectacles

97741-44S.PPT



8L197741-44

### Soft Lenses for Keratoconus

In the very early stages of keratoconus a SCL may provide adequate visual correction.

A toric lens is usually required due to the degree of astigmatism associated with the condition.

In general, soft lenses have a limited role to play in fitting keratoconic patients and were used rarely (Cox, 1984). However, the advent of stock, siloxane hydrogel spherical lenses and toric hydrogel and siloxane hydrogel torics, e.g. Soflens 66 Toric, Advance Toric, etc. means that the view that SCLs generally have a small role to play in correcting keratoconus may need to be reviewed.

Special soft lens designs can be custom-made in conventional hydrogel materials in any power or curvature to fit eyes with keratoconus. These and siloxane hydrogel lenses may have a role when patients are unable to tolerate RGP lenses and complain of significant lens discomfort or lens intolerance.

148

### FITTING KERATOCONUS PIGGYBACK LENSES

- SCL acts as a carrier for the overlying RGP lens
- Used to improve comfort and minimize risk of epithelial abrasion by RGP lens
- Ultra-thin soft lens (usually disposable)

97741-45S.PPT



8L197741-45

### Piggyback Lens Fitting for Keratoconus

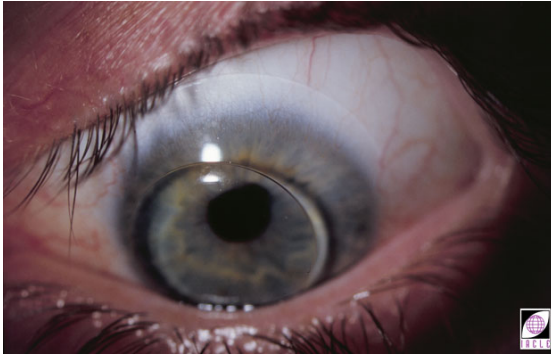The piggyback system consists of a SCL resting on the keratoconic eye and an RGP lens riding on top of the soft lens (slide 149). This combination may be useful in cases where an RGP lens causes discomfort or produces an abrasion, scarring, or an epithelial erosion.

This system is also employed when the level of tolerance of an RGP lens is poor, or when lens centration is a problem. The recommended SCL design is either an ultra-thin lens that drapes over the cone or a high plus power lens that provides more bulk (and greater rigidity) on which to fit the RGP lens.

The SCL is fitted first. Often, it is a disposable or frequent replacement lens. It is essential that the soft lens moves adequately.

Subsequently, keratometry is performed with the SCL *in situ* and a highly gas-permeable, thin rigid lens is fitted over the soft lens. The rigid lens should centre well, move independently of the soft lens, and cause minimal lid sensation. The fit of the rigid lens can be further evaluated with the aid of high molecular weight fluorescein (normal sodium

149



8L10079-01B

fluorescein will 'dye' the SCL).

Generally, unless a peroxide lens care system is used, both RGP and soft lens care systems are required to maintain piggyback lens systems, making it more complex and expensive for the patient. In addition, the RGP conditioning solution needs to be rinsed from the rigid lens, using a soft lens rinsing or multipurpose solution, prior to lens insertion. It can be seen that, i.e. in addition to the benefits bestowed on the patient by both lens types, the disadvantages of both lens types and their care systems are also present.

Alternatively, some practitioners have resorted to using a SCL multipurpose solution for both the RGP and soft lenses and report few difficulties. The practitioner must judge the safety of each approach on a case-by-case basis.

The main problems associated with piggyback fitting are the added expense and inconvenience of double lens systems, the need for extra lens care and maintenance, patient handling problems, and the reduced oxygen supply to the cornea through both lenses (centrally), and the SCL peripherally. Siloxane hydrogel lenses have overcome the overall oxygen problem and the final physiological situation now depends more on the characteristics of the RGP component of the piggyback system.


Soft lenses with a countersunk or recessed lens well on the front surface can also be ordered. The RGP lens locates in the depression for improved lens and vision stability, and wearer comfort. Unfortunately, there is a tendency for other entities to locate in the well also, e.g. tear debris and other lens contaminants. Under these circumstances, lens care assumes an even greater role.

150

**FITTING KERATOCONUS  
PIGGYBACK**

- More complicated care and maintenance
- Reduced oxygen transmissibility
- Silicone hydrogels offer advantages

97741-46S.PPT




8L197741-46

151

**FITTING KERATOCONUS  
SCLERAL LENSES**

- Often a last resort for advanced cases
- Ideal for intolerant rigid lens wearers regardless of the stage of the disease
- May delay or avoid need for surgery

97741-47S.PPT



8L197741-47

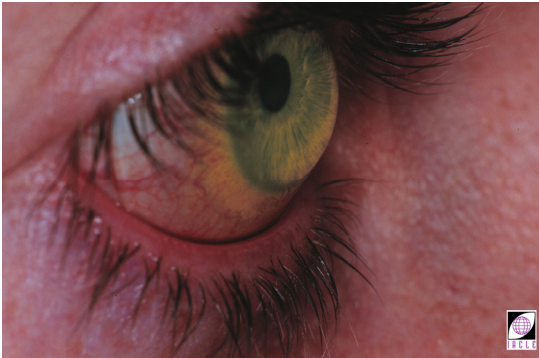
**Scleral Lens Fitting for Keratoconus**

In many cases of keratoconus, especially when the condition is advanced, scleral contact lenses are an ideal means of correction (slide 152). However, because relatively few practitioners have the skills or the materials necessary to fit these lenses, they tend to be under-utilized.

Scleral lenses are often considered as a last resort and are, therefore, more likely to be fitted to advanced cases of keratoconus only. Even in these cases, a comfortable correction can be achieved that often defers or even eliminates the need for surgery such as a PK.

Even though modern scleral lens manufacturing and fitting techniques (including preformed lenses) have simplified the process to some extent, these lenses are still complicated and relatively expensive to manufacture, and only a few laboratories worldwide offer the service.

152



An alternative is the large (13.5 mm TD) RGP EpiCon LC design (UltraVision Capricornia, Brisbane, Australia) that could be described as being a semi-scleral design since it exceeds the normal horizontal visible iris diameter (HVID).


8L12074-95

153

**FITTING KERATOCONUS**  
**HYBRID LENSES**

- Soft and rigid designs & properties combined into a true one-piece lens
- Suitable for early to moderate keratoconus
- Only limited parameters available
- Poor oxygen transmissibility (low Dk materials)

97741-48S PPT



8L197741-48

### Hybrid Lenses for Keratoconus

Hybrid lenses such as SoftPerm™ (based on the historical Saturn and Saturn II hybrid lenses) combine both soft and rigid designs and properties into a single, one-piece lens, i.e. the lens is not a result of bonding two disparate materials into a lens. In fact, the properties are the result of differing phases of the same lens material (DePaolis *et al.*, 1992). The aim of the hybrid lens is to provide the quality of vision achievable with a RGP lens while providing the comfort associated with SCL wear.

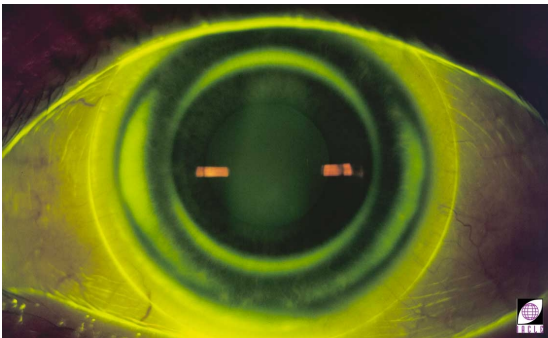
Lens fit is evaluated using high molecular weight fluorescein (slide 154).

Although theoretically a good concept, such a lens has limitations for keratoconus due to the narrow range of parameters made available. They also have low oxygen transmissibility and usually show limited movement. These factors can lead to corneal oedema, neovascularization, and endothelial cell loss (Edmonds *et al.*, 2004) with prolonged lens usage. Other disadvantages include handling difficulties, a tendency to tear or split acutely at the soft-rigid junction, and high replacement costs.

The new SynergEyes™ A high Dk hybrid lens (from synergeyes, announced 2005) promises to negate the oxygen transmissibility disadvantage of previous hybrid lenses.

When hybrid contact lenses are prescribed, close follow-up is needed to monitor for complications such as contact lens-induced papillary conjunctivitis (CLPC) and corneal neovascularization, as well as lens condition and integrity.

154



8L1022-94



## V Surgery for Keratoconus

155

### SURGERY FOR KERATOCONUS

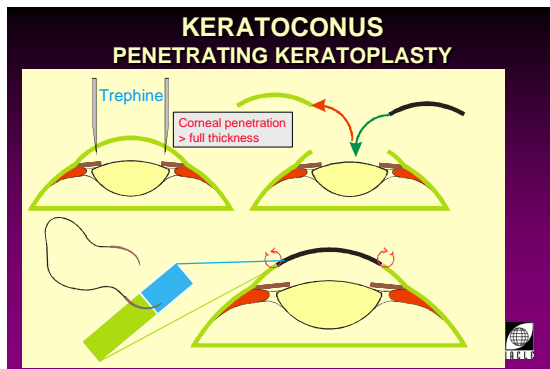
- 10 to 20% require surgery
- Dictated by tolerance of lens wear and acceptability of vision
- Excessive delay may compromise graft success
- Penetrating keratoplasty is most common

97741-49S.PPT



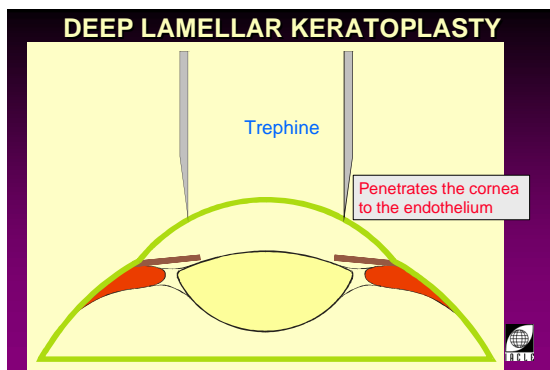
8L197741-49

156



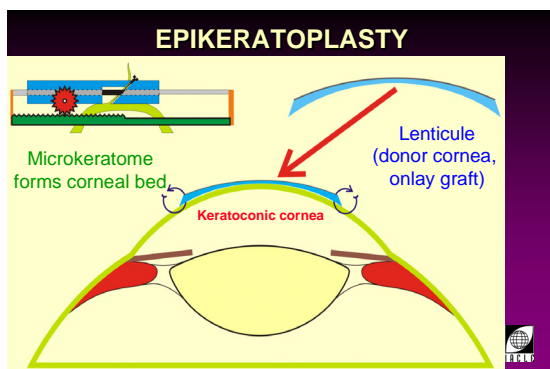
8L197741-94

157



8L197741-96

158



8L197741-98

### Surgery for Keratoconus

If the management of keratoconus with contact lenses is unsuccessful, usually due to unsatisfactory vision, corneal scarring, unstable contact lens fit or intolerable discomfort, surgery is usually the next option.

One estimate of the rate of surgical intervention is 10 to 20% usually within the first 10 years of 'onset' (Ruben and Khoo, 1989). Bennett and Hom (2004) estimate that about one in eight (12.5%) keratoconics require corneal transplantation.

PK (slide 156) has long been the most common surgical management of the condition, and provides good visual results in most cases (best corrected visual acuity [BCVA] of 6/12 or better). Traditionally, it has been regarded as the final solution to keratoconus once the contact lens options fail to either be tolerable or produce satisfactory vision (Olson *et al.*, 2000).

Deep lamellar keratoplasty (DLK) or partial transplant (slide 157) has proved to be a safe alternative to PK. Although it is technically more challenging for the surgeon, the risk of endothelial rejection can be avoided. DLK seems to have similar visual outcomes and complication rates as PK (Watson *et al.*, 2004). However, Funnell *et al.* (2005) reported that, while DLK produces less astigmatism and no risk of an endothelial graft rejection, there was a reduced likelihood of achieving 6/6 vision (best corrected).

Occasionally, intracorneal rings (see later), or even epikeratoplasty may be considered in the management of keratoconus. This is especially so if the patient is very young because penetrating keratoplasties have a finite life expectancy (about 20 years) before a repeat surgical procedure is required (Spitznas *et al.*, 2002).

Epikeratoplasty (slide 158) for keratoconus management has largely been replaced by penetrating (full thickness) keratoplasty as this achieves better visual results. However, in some cases, epikeratoplasty may still be the treatment of choice because it is non-invasive (or less invasive should a microkeratome be used to create a cornea bed onto which is sutured the 'onlay' of donor cornea tissue) and there is reduced risk of graft rejection. Further, in cases when it is not desirable to perform a PK, epikeratoplasty is the recommended alternative (Wagoner *et al.*, 2001). Despite achieving similar visual outcomes to PK, epikeratoplasty has a significantly longer healing period (12 vs. 3 months) and the degree of keratoconus that can be treated with epikeratoplasty remains undefined (Steinert and Wagoner, 1988). Further, Rodrigues *et al.* (1992) found evidence (altered stromal proteoglycans) of keratoconic pathological processes occurring within graft tissue post-surgically.



159

**KERATOCONUS  
REASONS FOR PENETRATING  
KERATOPLASTY**

	Dana <i>et al.</i> , 1992	Weed & McGhee, 1998	Lim & Vogt, 2002
↓ VA	43%	13.5%	8.5%
↓ Lens Tolerance	32%	67.5%	83%
↑ CL Displacement	13%	19%	8.5%

97741-84S.PPT

8L197741-84

Management of keratoconic refractive error with phakic intraocular lenses has also been reported (Sauder and Jonas, 2003).

Keratoconus is generally considered a contraindication for most forms of refractive surgery, especially LASIK.

Wollensak *et al.* (2003) describe the use of collagen cross-linking (see **VI Miscellaneous 'Treatments' for Keratoconus** next) to halt the progression of kerectasia, possibly reducing the need for PK.

Practitioners must manage their patient's concerns on an individual basis. The need for surgical intervention is usually dictated by the quality of the vision achieved with contact lenses. Progressive loss of tolerance to contact lens wear and/or decreasing VA are the prime concerns for the patient and the prime reasons for corneal surgery for keratoconus.

The reasons for PK from several sources are presented in slide 159.

160

- KERATOCONUS PROGRESSION  
PROGNOSTIC FACTORS**
- Factors associated with progression to PK:*
- Maximum & minimum K readings
  - Corneal cylinder > 1.9 mm  
(≈ 13.5 – 25 D depending on Ks)
  - Snellen acuity
  - Racial group
- Tuft *et al.*, 1994
- 97741-116S.PPT

8L197741-116

**Prognostic Factors for Keratoconus Progression**

161

- KERATOCONUS PROGRESSION  
PROGNOSTIC FACTORS**
- Factors associated with progression to PK:*
- Diagnosed at a younger age
  - Longer CL wearing history
  - Steeper Ks
  - Poorer corrected acuity
  - Manifest scars, Vogt's striae, and/or Fleischer's rings
- after Booyesen, 2003
- 97741-117S.PPT

8L197741-117

162

**PENETRATING KERATOPLASTY  
KERATOCONUS**

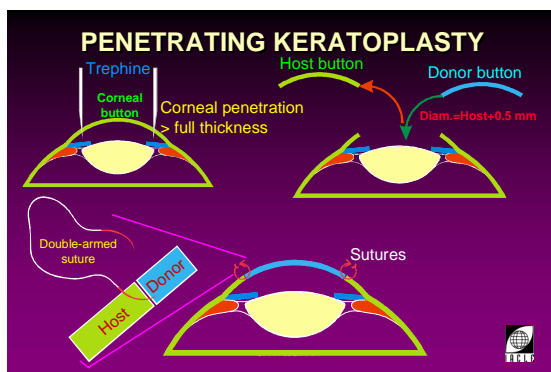
- Most common surgical technique
- Good graft survival
  - experienced surgeons
  - time of surgery
  - no concurrent inflammation
- Large grafts are problematic

97741-90S.PPT



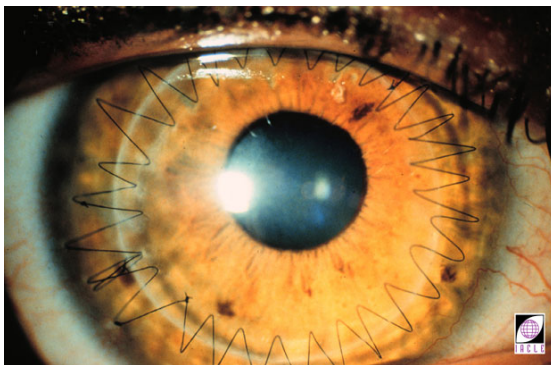
8L197741-50

163



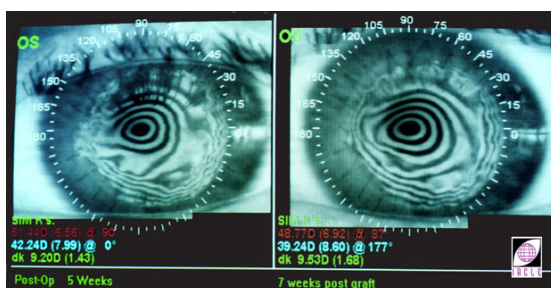
8L197741-95

164



8L10042-91

165



8L1DCP 4 11 14 (7 WEEKS POST-OP – NOTE SUTURES IN IMAGE)

### Penetrating Keratoplasty (PK)

PK is an alternative form of treatment in keratoconic eyes not correctable by more conservative and traditional methods, and can be very successful (Tay and Chan, 1997). It is the usual treatment method for keratoconics who fail with contact lenses, and/or those who develop apical scarring that precludes good vision with contact lenses. Sray *et al.* (2002) reported that the presence of scarring and high keratometric values at initial presentation might be indicative of the patient requiring a PK in the future.

A study done in the UK/Ireland reported that 19.9% of all grafts performed were for keratoconus while a similar earlier study in Australia showed the figure to be 31% (for other data see slides 3 and 4 early in this lecture).

The most common corneal transplantation (slide 163 to 166 – note that the sutures can be seen in slides 164 to 166) technique employed is allografting (or homografting) in which the central area of the keratoconic cornea is removed and a full-thickness button from a donor cornea is sutured in its place.

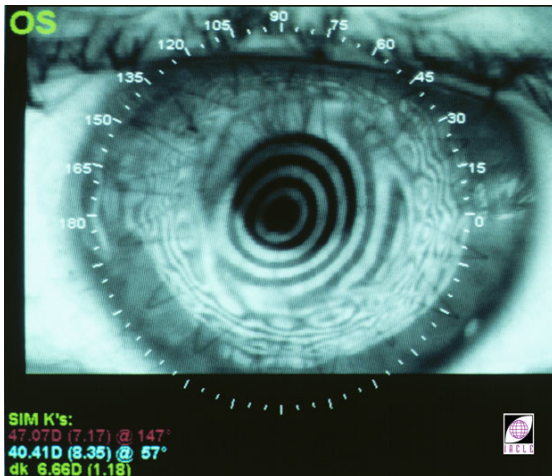Grafts for dystrophic conditions, particularly keratoconus, are seldom rejected, and have a very high graft survival rate (Lim *et al.*, 2000). Better results are produced by more experienced surgeons but for reasons of better management decisions rather than better surgical skills (Coster, 1997).

Lower graft survival rates were found in women who have had children, or been pregnant at some stage (Williams *et al.*, 1993). Corneas with deep stromal vascularization also have reduced graft survival rates (limbal vasculature closer to the 'foreign' donor material) (Thompson *et al.*, 2003). Further, a graft is less likely to be rejected if the recipient cornea has few inflammatory cells (Williams *et al.*, 1989). To this end, fine (often 10-0) non-reactive, monofilament nylon (polyacrylamide) sutures are combined with topical corticosteroids and any inflammation, infection, or ulceration must be treated promptly (Coster, 1997).

Large grafts are best avoided (Williams *et al.*, 1993, Vail *et al.*, 1993). This is significant, because to delay grafting unnecessarily may necessitate a graft larger than originally required (because of the mismatch between host and donor corneal thicknesses).

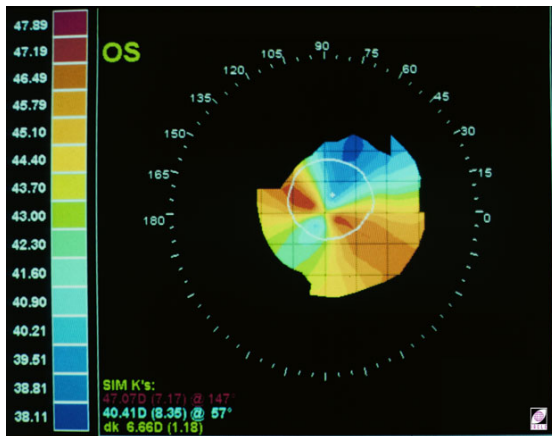
It is often thought that patients with unilateral disease are poor candidates for corneal transplantation, since it is unlikely that they would achieve better vision in the grafted eye than in the fellow eye. However, visual function and binocularity may improve in these cases, possibly depending on ocular dominance, even if patient satisfaction is not apparent immediately.

166



8L1DCP 4 C 3 2 (NOTE SUTURES IN IMAGE)

167



8L1DCP 4 C 3 3 (SAME PATIENT AS ABOVE) (NOTE SMALL AREA OF USEABLE DATA THAT APPEARS IN PLOT – INDUCED CORNEAL IRREGULARITY)

168

### PENETRATING KERATOPLASTY VISUAL OUTCOME

- Generally successful, high graft clarity
- 50% chance of needing contact lenses due to residual myopia and/or astigmatism
- VA improves in first 3 – 9 months
- Patient satisfaction generally high

97741-54S.PPT



8L197741-54

### Penetrating Keratoplasty: Visual Outcome

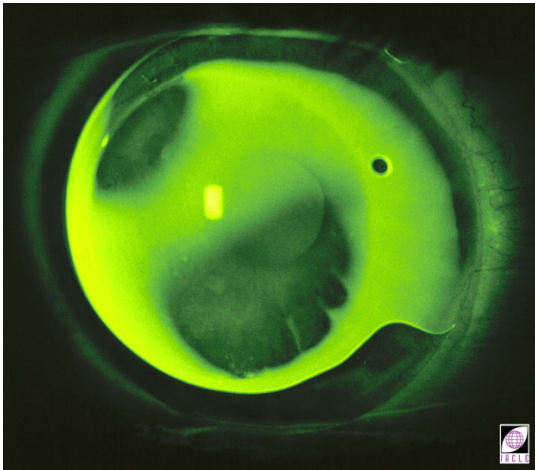
Generally, PK is considered to be a successful surgical procedure for keratoconic patients, and the graft clarity rate in these patients can be as high as 97% 4 years after the procedure (Brahma *et al*, 2000).

Despite the fact that many corneal grafts remain clear, the vision is often compromised by the degree of residual corneal astigmatism. In fact, following the procedure, about half of PK recipients need contact lenses to compensate for residual myopia and/or astigmatism.

VA usually improves significantly between 3 and 9 months following surgery, but further improvement after this time is unlikely.

The majority of patients require some form of optical correction for functional VA following PK (e.g. a special post-graft RGP, see slide 169). However, the level of patient satisfaction with their vision after PK is often very high. This may be due to the PK reducing corneal distortion and removing scarred tissue, both of which result in improved contrast sensitivity. Furthermore, any corneal astigmatism

169



8L1DCP 5 2 8 (GELFLEX [WA] POST GRAFT II RGP LENS IN QUANTUM II)

remaining after PK is usually regular.

Pre-operative contrast sensitivity in keratoconic patients is usually lower to much lower than normal. It often improves to normal or near normal levels soon after PK.

Patient satisfaction with PK is generally high. Dissatisfaction usually relates to graft failure and/or the need to wear contact lenses or some other forms of optical correction following the procedure. In some cases, the disappointment may be a direct result of a failure by the practitioner to control and lower post-surgical vision expectations to realistic levels.

170

### PENETRATING KERATOPLASTY COMPLICATIONS

- Relatively uncommon in compliant patients
- Graft rejection
- Corticosteroid complications
- Punctate keratitis
- Postoperative astigmatism
- Failure of the corneal endothelium
- Recurrence of keratoconus?

97741-61 S.PPT



8L197741-61

### Penetrating Keratoplasty: Complications

Although PK is a viable alternative in the management of keratoconus, and complications are rare in compliant patients, the procedure is not without risks. Keratoconic patients with Down syndrome are more likely to develop serious complications following PK due to reduced compliance, extensive eye rubbing, and even self-inflicted trauma.

Corneal transplants usually have about a 95% success rate, due largely to the avascular nature of the cornea. Allograft reactions (both epithelial and endothelial) occur in about a third of cases, and this is usually treated with topical corticosteroids. Steroid complications could result in glaucoma and cataract, complication that patients should be warned about. Other complications may also occur as a result of PK, e.g. stromal outgrowth or corneal ulceration causing scarring.

Punctate keratitis following PK occurs in about one fifth of cases and is believed to be a form of neurotrophic keratitis. If severe enough, it may lead to reduced VA.

Loose sutures or filaments following PK may cause discomfort and irritation, even if the vision is not affected.

Other possible complications following PK include post-operative astigmatism and a fixed, dilated pupil.

Visual rehabilitation following PK is often fairly slow and there may be a continued corneal endothelial cell loss.

Keratoconus may also recur in the graft eye many years later. Recurrent keratoconus following keratoplasty is rare and its aetiology remains uncertain. It can be managed in various ways, including spectacles, contact lenses, or a second PK in more advanced cases.

It has also been reported (Saks, 2005 personal communication) that significant increases in post-graft astigmatism can occur in the second and third decade post-graft.



171

### PENETRATING KERATOPLASTY REGRAFTING

- Outcomes are less successful
- Aligning host and donor tissue is difficult (disparate tissue thicknesses)

97741-63S.PPT



8L197714-53

### Penetrating Keratoplasty: Regrafting

Graft rejection rates in keratoconus patients are generally low (7.8 to 31%). Generally, regrafts are less successful. Regrafts account for 18% of all grafts undertaken (Vail, 1993) but data varies according to the source (see slides 3 and 4 to confirm that regrafts are among the leading reasons for grafting in general. Numerical data is available from the references cited in the slides).

Generally, grafts do not last indefinitely. Committing a keratoconic patient to surgery has lifetime consequences. However, ophthalmic surgeons have been heard to voice complaints about contact lens practitioners who have 'kept' keratoconics too long leading to thinner corneas and more difficult grafts subsequently. Difficulty arises from the discrepancy between the thicknesses of the donor and host tissue. Either the epithelia or endothelia can be located in apposition but not both. This increases the risk of an adverse outcome.

Some surgeons believe that corneal transplantation is a viable primary treatment option in keratoconus when best corrected spectacle VA is worse than 6/12 (Buzard and Fundingsland, 1997). However, PK is usually reserved for cases of contact lens intolerance with poor spectacle VA, or unacceptable VA even with otherwise successful contact lens wear.

Regrafting may be performed within the perimeter of the original graft or outside the original. The latter can be problematic because the graft is larger and is closer to the limbal vasculature. This proximity increases the risk of rejection.

172

### PENETRATING KERATOPLASTY CONTACT LENS FITTING: OPTIONS

- RGP lenses with spherical BOZR
- Piggyback lenses (RGP on a 'soft' lens)
- Scleral (haptic) lenses (performed or from an impression)
- Reverse-geometry lenses (originally for ortho-K)
- Soft lenses (usually toric)

97741-62S.PPT



8L197714-62

### Contact Lens Fitting following Penetrating Keratoplasty

The post-keratoplasty patient is often managed successfully with spectacles. However, contact lenses are sometimes needed to compensate for post-keratoplasty irregular (non-orthogonal) astigmatism and corneal distortion.

The initial fitting of contact lenses to corneal grafts should be done with great care and in consultation with the surgeon responsible. Contact lenses may promote graft rejection especially if they trigger an inflammatory episode.

RGP lenses are the first choice in most cases, as they provide better vision and offer good corneal physiology. In the case of larger grafts, small diameter lenses can be used to fit within the dimensions of the graft. When the graft diameter is small, a larger RGP lens with the BOZD extending across both the host and donor corneas might prove to be more suitable.

When a graft is 'proud' (i.e. protruding and steeper than the host cornea), there is a significant curvature change at the donor-host junction and contact lens fitting may be difficult.



An RGP lens with a spherical BOZR is usually the most successful. Occasionally, however, it may be necessary to fit toric back surface or bitoric RGP lenses, Bi-Sym or Quad-Sym (or other asymmetric lens), piggyback lenses, or scleral lenses to achieve sustained, acceptable vision.

When the graft zone is decentred relative to the visual axis, the patient may experience problems such as monocular diplopia and flare through their contact lenses, because RGP lenses tend to position themselves on the (decentred) graft zone. In these cases, it may be necessary to fit a piggyback lens system, design a lens with a decentred BOZD, or consider a special post-graft lens design that may or may not be symmetrical.

SCLs, including spherical or toric siloxane hydrogel lenses, are playing an increasingly important role in the correction of keratoconus. A potential difficulty is achieving satisfactory visual results when significant irregular astigmatism is manifest. A piggyback lens combination may be a compromise in such cases.

Scleral lenses may be very successful in a post-keratoplasty case, providing good centration and VA. They are now available in high Dk gas permeable materials.

In recent years, reverse geometry RGP lenses, as used in orthokeratology, have proved to be successful when used on grafted or refractive surgery-modified eyes.

173

**SURGERY FOR KERATOCONUS  
INTRACORNEAL RINGS**

- Alternative to PK if cornea is clear
- May delay or eliminate need for corneal graft
- Produces flattening of central cornea
- Long-term effects still uncertain

97741-60S.PPT



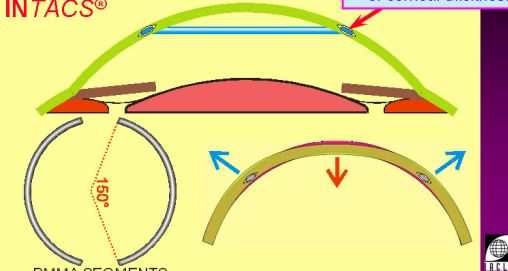
8L197741-60

174


**INTRASTROMAL CORNEAL RINGS**

INTACS®

Insertion channel @ 68% of corneal thickness



PMMA SEGMENTS



8L197741-90

**Intrastromal Corneal Rings**

Intrastromal corneal rings (slide 174) could be considered an alternative way of delaying or avoiding PK in keratoconics who have clear corneas but who are intolerant of contact lens wear. They may be a viable surgical means of reducing corneal steepening and corneal astigmatism in keratoconus. Generally, they provide acceptable acuity and may delay or eliminate the need for a corneal graft.

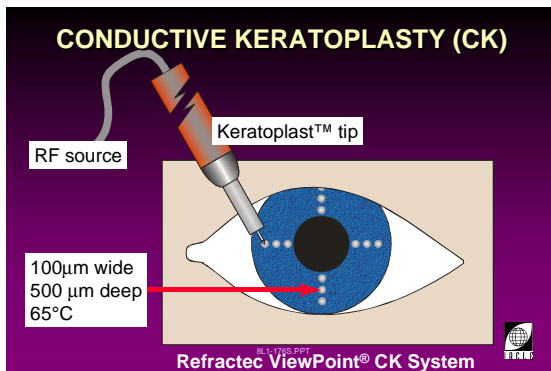
Corneal rings reduce myopia of keratoconus by flattening the central cornea (slide 174). As the cornea is thinner and less rigid in keratoconus, it can be flattened more easily.

This procedure has the added advantages of being reversible and preserving the central cornea (Kwitk and Severo, 2004). However, infectious keratitis following corneal ring implantation is a possible and potentially sight-threatening complication (Hofling-Lima *et al.*, 2004).

Colin *et al.* (2000) reported a mean keratometric reduction of 5 D with corneal rings in keratoconus. The procedure seems to be less effective in more advanced keratoconus, but may prove satisfactory in the early stages, provided the central cornea is transparent (Colin and Velou, 2002).

The long-term effects and predictability of intrastromal corneal ring implantation as a management option for keratoconus are still a concern and remain uncertain.

175

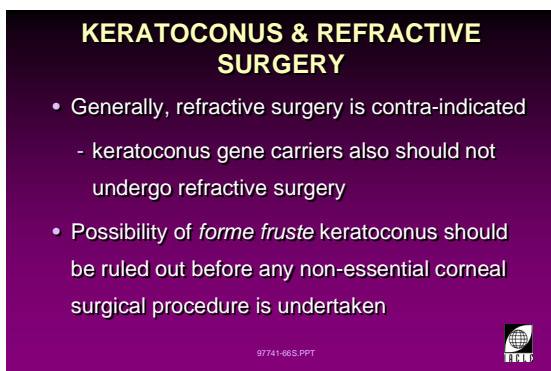


8L197741-99

### Conductive Keratoplasty (CK)

It has been suggested that CK can be used to reduce ectasia in corneas after a PK (Price, 2004). As yet, such a suggestion has not met with wide acceptance.

176



8L197714-66

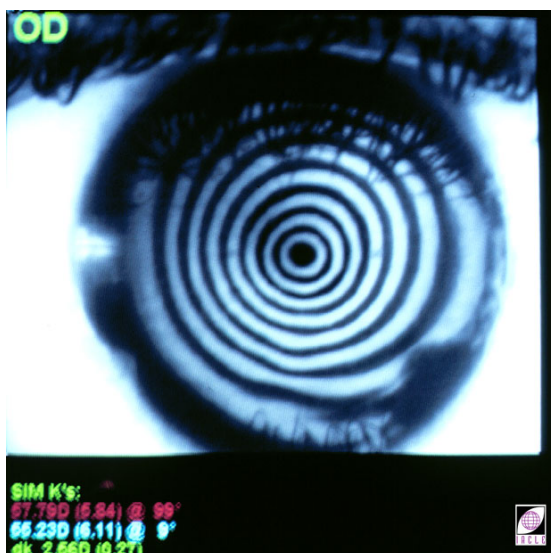
### Keratoconus and Refractive Surgery

There is general agreement that refractive surgery (e.g. LASIK, LASEK, Photo-Refractive Keratectomy [PRK], RK, etc.) is not an option for keratoconics. Perhaps of greater importance is ensuring that those carrying the mutated keratoconus gene do not become candidates for refractive surgery before the condition has manifested itself. Furthermore, a thorough investigation is warranted to prevent the possibility of an existing *forme fruste* case being subjected to corneal surgical procedures for non-essential reasons as the outcome may not be predictable.

Interestingly, Varssano *et al.* (2004) reported that more than half of the corneal topographies of refractive surgery candidates did not comply with the assumed 'normal' spherical or spherocylindrical patterns. This complicates the decision making in a refractive surgery suite and Varssano *et al.* raised the possibility that there may be a continuum between steep normal and early keratoconic patterns making the decision of a 'cut-off' point difficult but essential.

Keratoconus or a keratoconus-like ectasia can occur after LASIK that follows a flap made too thick, leaving the central cornea too thin (e.g. just anterior of the endothelium) (Chan *et al.*, 2005). Slide 177 shows a similar outcome in an unrelated case where the cornea was 'microkeratomed' too deeply.

177



8L1DCP 4 C 4 10 (POST-LASIK 'KERATOCONUS')

## VI Miscellaneous 'Treatments' for Keratoconus

178

### KERATOCONUS NON-SURGICAL, NON-CL 'TREATMENTS'

- Combined riboflavin(C3-R)/UV<sub>A</sub> treatment (human): induces collagen cross-linking in cornea → ↑ biomechanical rigidity (Wollensak *et al.*, 2003, Spoerl *et al.*, 2004, Boxer Wachler, 2005)
  - dose-dependent keratocyte damage has been reported – significance yet to be determined (Wollensak *et al.*, 2004)

97741-725.PPT



8L197714-72

### Non-Surgical and Non-Contact Lens 'Treatments' for Keratoconus

Treatments other than the more normal contact lenses and PK appear in the literature. Many are experimental and/or trialed on animals.

One of these approaches appears opposite.

More are likely in the future.

## VII Conclusions

179

### General Recommendations

#### **KERATOCONUS RECOMMENDATIONS FOR PATIENTS**

after Kenney & Brown, 2003

- Use UV protection in CLs & spectacles
- Use CLs fitted optimally
  - often difficult
  - minimize corneal 'trauma'
  - track significant fitting changes
- Minimize eye rubbing by:
  - making lenses as comfortable as possible
  - use of NSAIDs
  - use of allergy medications as needed



8L197741-81

 **References**

- Agostino P, et al. (2002). *Neural network-based system for early keratoconus detection from corneal topography*. J Biomed Informatics. 35(3): 151 – 159.
- Al-Yousuf N, et al. (2004). *Penetrating keratoplasty: indications over a 10 year period*. Br J Ophthalmol. 88: 998 – 1001.
- Assiri AA, et al. (2005). *Incidence and severity of keratoconus in Asir province, Saudi Arabia*. Br J Ophthalmol. 89: 1403 – 1406.
- Atilano SR, et al. (2005). *Accumulation of mitochondrial DNA damage in keratoconus corneas*. Invest Ophthalmol Vis Sci. 46(4): 1256 – 1263.
- Australian Corneal Graft Registry (1993). *Australian Corneal Graft Registry 1991 to 1992 Report*. Aust NZ J Ophthalmol. 21(2)(Suppl.): 15.
- Auffarth GU, Wang L, Völcker HE (2000). *Keratoconus evaluation using the Orbscan Topography System*. J Cataract Refract Surg. 26: 222 – 228.
- Avitabile T, et al. (2004). *Keratoconus staging: A computer-assisted ultrabiomicroscopic method compared with videokeratographic analysis*. Cornea. 23(7): 655 – 660.
- Bawazeer AM, et al. (2000). *Atopy and keratoconus: a multivariate analysis*. Br J Ophthalmol. 84: 834 – 836.
- Beardsley TL, Foulks GN (1982). *An association of keratoconus and mitral valve prolapse*. Ophthalmology. 89: 35 – 37.
- Bennett ES (1986). *Keratoconus*. In: Bennet ES, Grohe RM (Eds.): *Rigid Gas Permeable Contact Lenses*. Professional Press Books, New York.
- Bennett ES, Hom MM (2004). *Manual of Gas Permeable Contact Lenses*. 2<sup>nd</sup> ed. Elsevier Science (USA).
- Betts AM, et al. (2002). *Visual performance and comfort with the Rose K lens for keratoconus*. Optom Vis Sci. 79(8): 493 – 501.
- Bisceglia L, et al. (2005). *VSX1 mutational analysis in a series of Italian patients affected by keratoconus: Detection of a novel mutation*. Invest Ophthalmol Vis Sci. 46: 39 – 45.
- Bogan SJ, et al. (1990). *Classification of normal corneal topography based on computer-assisted videokeratography*. Arch Ophthalmol. 108: 945 – 949.
- Booyesen DJ (2003). *Keratoconus: A new look at an old disease*. Vision – Vol 11 (5). <http://www.edoc.co.za/modules.php?name=News&file=article&sid=163>.
- Boxer Wachler BS (2005). *Corneal collagen crosslinking with riboflavin. A new treatment to strengthen the cornea for keratoectasia and keratoconus*. Cataract Refract Surg Today. Jan.: 73 – 74.
- Brahma A, et al. (2000). *Visual function after penetrating keratoplasty for keratoconus: a prospective longitudinal evaluation*. Br J Ophthalmol. 84: 60 – 66.
- Brancati F, et al. (2004). *A locus for autosomal dominant keratoconus maps to human chromosome 3p14-q13*. J Med Genet. 41; 188 – 192.
- Brierly SC, et al. (2000). *Penetrating keratoplasty for keratoconus*. Cornea. 19: 329 – 332.
- Brookes NH, et al. (2003). *Involvement of corneal nerves in the progression of keratoconus*. Exp Eye Res. 77: 515 – 524.
- Brown DJ, et al. (1997). *Differential gene expression in keratoconus keratocytes*. Invest Ophthalmol Vis Sci. 38(4)(Suppl.): S960.
- Brown DJ, et al. (1998). *Gene expression in keratoconus corneas*. Invest Ophthalmol Vis Sci. 39(4)(Suppl.): S635.
- Burger DS (1993). *Contact lens alternatives for keratoconus: an overview*. CL Spectrum. March: 49 – 55.



- Burger D, et al. (2003). *Keratoconus: Diagnosis and management*. [www.kcenter.org/disease\\_info/Keratoconus.html](http://www.kcenter.org/disease_info/Keratoconus.html).
- Burns DM, et al. (2004). *Keratoconus: An analysis of corneal asymmetry*. *Br J Ophthalmol*. 88: 1252 – 1255.
- Buzard KA, Fundingsland BR (1997). *Corneal transplant for keratoconus: results in early and late disease*. *J Cataract Refract Surg*. 23: 398 – 406.
- Carney LG (1982). *Visual loss in keratoconus*. *Arch Ophthalmol*. 100: 1282 – 1285.
- Caroline P, et al. (1978). *Preliminary report on a new contact lens design for keratoconus*. *Contact Intraocular Lens Med J*. 4: 69 – 73.
- Caroline PJ, et al. (1997). *The latest design for keratoconus*. *CL Spectrum*. 12(8): 36 – 41.
- Carvalho LA (2005). *Preliminary results of neural networks and Zernike polynomials for classification of videokeratography maps*. *Optom Vis Sci*. 82(2): 151 – 158.
- Chan CCK, et al. (2005). *Woman presents with progressive kerectasia after LASIK*. *Oc Surg News*. 4/15/2005 (<http://www.osnsupersite.com/>).
- Chen W-L, et al. (2001). *Changing indications for penetrating keratoplasty in Taiwan from 1987 to 1999*. *Cornea* 20(2): 141 – 144.
- Chiplunkar S, et al. (1999). *Enhanced expression of a transmembrane phosphotyrosine phosphatase (LAR) in keratoconus cultures and corneas*. *Exp Eye Res*. 68(3): 283 – 293.
- Chung CW, et al. (2001). *Use of SoftPerm contact lenses when rigid gas permeable lenses fail*. *CLAO J*. 27: 202 – 208.
- CLEK Baseline Statistics (1999). *Presented in: Keratoconus survey – 1999*. Visit: <http://home.revealed.net/ddwyer/results.html>.
- Colin J, Velou S (2002). *Utilization of refractive surgery technology in keratoconus and corneal transplants*. *Curr Opinion in Ophthalmol*. 13(4): 230 – 234.
- Colin J, Velou S (2003). *Current surgical options for keratoconus*. *J Cataract Refract Surg*. 29:379 – 386.
- Colin J, et al. (2000). *Correcting keratoconus with intracorneal rings*. *J Cataract Refract Surg*. 26: 1117 – 1122.
- Collier SA (2001). *Is the corneal degradation in keratoconus caused by matrix-metalloproteinases?* *Clin Exp Ophthalmol*. 29(6): 339.
- Coroneo M (1993). *Pterygium as an early indicator of ultraviolet insolation: a hypothesis*. *Br J Ophthalmol*. 77: 734 – 739.
- Coster DJ (1997). *Evaluation of corneal transplantation*. *Br J Ophthalmol*. 81: 618 – 619.
- Cox SN (1984). *Management of keratoconus*. *J Brit Cont Lens Assoc*. 7: 86 – 92.
- Cursiefen C, et al. (1992). *Changing indications for penetrating keratoplasty: Histopathology of 1,250 corneal buttons*. *Cornea*. 17(5): 468 – 470.
- Dana MR, et al. (1992). *Contact lens failure in keratoconus management*. *Ophthalmology* 99: 1187 – 1192.
- Davis LJ (1997). *Keratoconus: current understanding of diagnosis and management*. *Clin Eye Vis Care*. 9: 13 – 22.
- DePaolis MD, et al. (1992). *Chapter 32: Hybrid Materials and Designs*. In: Bennett ES, Weissman BA (Eds.): *Clinical Contact Lens Practice (revised ed. – 1992)*. JB Lippincott Company, Philadelphia. 4.
- Dingeldein SA, et al. (1989). *Quantitative descriptors of corneal shape derived from computer-assisted analysis of photokeratographs*. *Refract Corneal Surg*. 5(6): 372 – 378.
- Dogru M, et al. (2003). *Tear function and ocular surface characteristics in keratoconus*. *Ophthalmology*. 110(6): 1110 – 1118.

- Edmonds CR, *et al.* (2004). *Corneal endothelial cell count in keratoconus patients after contact lens wear.* Eye Cont Lens. 30(1): 54 – 58.
- Edrington TB, *et al.* (1995). *Keratoconus.* Optom Clin. 4: 65 – 73.
- Edrington TB, *et al.* (1998). *Repeatability and agreement of two corneal-curvature assessments in keratoconus: Keratometry and the first definite apical clearance lens (FDACL).* Cornea. 17(3): 267 – 277.
- Edwards M, *et al.* (2001). *The genetics of keratoconus.* Clin Exp Ophthalmol. 29: 345 – 351.
- Edwards M, *et al.* (2001B). *Keratectasia (iatrogenic keratoconus) following laser refractive surgery.* CME J Ophthalmol. 5(3): 70 – 73.
- Erie JC, *et al.* (2002). *Keratocyte density in keratoconus. A confocal microscopy study.* Am J Ophthalmol. 124: 689 – 695.
- Funnell CL, *et al.* (2005). *Comparative cohort study of the outcomes of deep lamellar keratoplasty and penetrating keratoplasty for keratoconus.* Eye online publication. May 6:doi:10.1038/sj.eye.6701903.
- Galin MA, Berger R (1958). *Atopy and keratoconus.* Am J Ophthalmol. 45: 904 – 906.
- Georgiou T, *et al.* (2004). *Influence of ethnic origin on the incidence of keratoconus and associated atopic disease in Asians and white patients.* Eye. 18(4): 379 – 383.
- Gondhowiardjo TD, van Haeringen NJ (1993). *Corneal aldehyde dehydrogenase, glutathione reductase, and glutathione S-transferase in pathologic corneas.* Cornea. 12(4): 310 – 314.
- Gondhowiardjo TD, *et al.* (1993). *Analysis of corneal aldehyde dehydrogenase patterns in pathologic corneas.* Cornea. 12(2): 146 – 154.
- Gundel RE, Libassi DP (2002). *Keratoconus: Diagnosis and Management.* In: Scheid TR: *Clinical Manual of Specialized Contact Lens Prescribing.* Butterworth-Heinemann, New York.
- Heaven CJ (2000). *Keratoconus associated with chromosome 13 ring abnormality.* Br J Ophthalmol. 84: 1075.
- Héon E, *et al.* (2002). *VSX1: A gene for polymorphous dystrophy and keratoconus.* Human Molec Genetics. 11(9): 1029 – 1036.
- Heverly VL, Lowther G (2005). *Keratoconus: Epidemiology of keratoconus.* [http://www.opt.indiana.edu/lowther/html/keratoconus\\_epidemiology.htm](http://www.opt.indiana.edu/lowther/html/keratoconus_epidemiology.htm).
- Hofling-Lima AL, *et al.* (2004). *Corneal infections after implantation of intracorneal ring segments.* Cornea. 6: 547 – 549.
- Holland DR, *et al.* (1997). *Unilateral keratoconus. Incidence and quantitative topographic analysis.* Ophthalmology. 104: 409 – 1413.
- Hubbe RE, Foulks GN (1994). *The effect of poor fixation on computer-assisted topographic corneal analysis.* Ophthalmology. 101; 1745 – 1748.
- Hutchings H, *et al.* (2005). *Identification of a new locus for isolated familial keratoconus at 2p24.* J Med Genetics. 42: 88 – 94.
- Jafri B, *et al.* (2004). *Asymmetric keratoconus attributed to eye rubbing.* Cornea. 23(6): 539 – 540.
- Kalin NS, *et al.* (1996). *Automated topographic screening for keratoconus in refractive surgery candidates.* CLAO J. 22: 164 – 167.
- Karseras AG, Ruben M (1976). *Aetiology of keratoconus.* Br J Ophthalmol. 60: 522 – 525.
- Kennedy RH, *et al.* (1986). *A 48-year clinical and epidemiologic study of keratoconus.* Am J Ophthalmol. 101: 267 – 273.
- Kenney MC, Brown DJ (2003). *The cascade hypothesis of keratoconus.* Cont Lens & Ant Eye. 26: 139 – 146.
- Kenney MC, *et al.* (1996). *Extracellular matrix of human keratoconus corneas.* Invest Ophthalmol Vis Sci. 37(3)(Suppl.): S645.

- Kenney MC, *et al.* (1997). *Abnormalities of the extracellular matrix in keratoconus corneas.* *Cornea.* 16(3): 345 – 351.
- Kenney MC, *et al.* (2000). *Altered expression pattern of growth factors, proteinases and TIMPs in keratoconus corneas.* *Invest Ophthalmol Vis Sci.* 41(4)(Suppl.): S539.
- Kenney MC, *et al.* (2005). *Increased levels of catalase and cathepsin V/L2 but decreased TIMP-1 in keratoconus corneas: evidence that oxidative stress plays a role in this disorder.* *Invest Ophthalmol Vis Sci.* 46(3): 823 - 832.
- Khan MD, *et al.* (1988). *Incidence of keratoconus in spring catarrh.* *Br J Ophthalmol.* 72: 41 – 43.
- Kirkness CM, *et al.* (1990). *The success of penetrating keratoplasty for keratoconus.* *Eye.* 4: 673 – 688.
- Klyce SD, *et al.* (2000). *Keratoconus detection with the KISA% method – another view.* *J Cataract Refract Surg.* 26(4): 472 – 473.
- Korb DR, *et al.* (1982). *Apical changes and scarring in keratoconus as related to contact lens fitting techniques.* *J Am Optom Assoc.* 53: 199 – 205.
- Korb DR (1984). *Recent developments in fitting contact lenses for keratoconus.* *J Am Optom Assoc.* 55: 172 – 175.
- Krachmer JH, *et al.* (1984). *Keratoconus and related noninflammatory corneal thinning disorders.* *Surv Ophthalmol.* 28: 293 – 322.
- Krumeich JH, *et al.* (1998). *Live-epikeratophakia for keratoconus.* *J Cataract Refract Surg.* 24: 456 – 463.
- Kwitko S, Severo NS (2004). *Ferrara intracorneal ring segments for keratoconus.* *J Refract Surg.* 30: 812 – 820.
- Lafond G, *et al.* (2001). *Bilateral severe keratoconus after in situ keratomileusis in a patient with forme fruste keratoconus.* *J Cataract Refract Surg.* 27: 1115 – 1118.
- Laing RA, *et al.* (1979). *The human corneal endothelium in keratoconus: A specular microscopic study.* *Arch Ophthalmol.* 97:1867 –1869.
- Lass JH, *et al.* (1990). *Clinical management of keratoconus.* *Ophthalmology.* 97: 433 – 445.
- Lawless M, *et al.* (1989). *Keratoconus: diagnosis and management.* *Aust NZ J Ophthalmol.* 17: 33 – 60.
- Lee LR, *et al.* (1995). *Clinical detection of unilateral keratoconus.* *Aust NZ J Ophthalmol.* 23(2): 129 – 133.
- Leung KKY (1999). *RGP fitting philosophies for keratoconus.* *Clin Exp Optom.* 82: 230 – 235.
- Levit A (2001). *The use of contact lenses in advanced keratoconus.* *Optom Today.* June 15: 21 – 24.
- Levy D, *et al.* (2004). *Videokeratographic anomalies in familial keratoconus.* *Ophthalmology* 111(5): 867 – 874.
- Li X, *et al.* (2004). *Longitudinal study of the normal eyes in unilateral keratoconus patients.* *Ophthalmology.* 111(3): 440 – 446.
- Lim N, Vogt U (2002). *Characteristics and functional outcomes of 130 patients with keratoconus attending a specialist contact lens clinic.* *Eye.* 16(1): 54 - 59.
- Lim L, *et al.* (2000). *Penetrating keratoplasty for keratoconus: visual outcome and success.* *Ophthalmology.* 107: 1125 – 1131.
- Lindsay RG (1995). *Post-keratoplasty contact lens management.* *Clin Exp Optom.* 78: 223 – 226.
- Lindsay RG *et al.* (2000). *Keratoconus associated with continual eye rubbing.* *Cornea.* 19: 567 – 569.
- Liu E, Slomovic AR (1997). *Indications for penetrating keratoplasty in Canada, 1986 – 1995.* *Cornea.* 16(4): 414 – 419.
- Macasai MS, *et al.* (1990). *Development of keratoconus after contact lens wear: patient characteristics.* *Arch Ophthalmol.* 108: 534 – 538.

- Maeda N, *et al.* (1994). *Automated keratoconus screening with corneal topography analysis*. Invest Ophthalmol Vis Sci. 35: 2749 – 2757.
- Maeda N, *et al.* (1995). *Comparison of methods for detecting keratoconus using videokeratography*. Arch Ophthalmol. 113(7): 870 – 874.
- Maguen E, *et al.* (1991). *The use of Saturn II lenses in keratoconus*. CLAO J. 17: 41 – 43.
- Maguire LJ, Bourne WM (1989). *Corneal topography of early keratoconus*. Am J Ophthalmol. 108(2): 107 – 112.
- Maguluri S, *et al.* (1999). *Keratoconus in Tourette's Syndrome*. Invest Ophthalmol Vis Sci. 40(4)(Suppl.): S329.
- Malecaze F (2004). *Researchers narrow hunt for keratoconus gene*. Oc Surg News. Europe/Asia-Pacific Ed. June. <http://www.osnsupersite.com/view.asp?ID=8243>.
- Mamalis N, *et al.* (1992). *Changing trends in the indications for penetrating keratoplasty*. Arch Ophthalmol. 110: 1409 – 1414.
- Mandell RB (1988). Keratoconus. In: Contact Lens Practice. 4<sup>th</sup> ed. Charles C Thomas Publisher, Springfield.
- Mannis MJ, *et al.* (1987). *Personality traits in keratoconus*. Arch Ophthalmol. 105: 798 – 800.
- Mannis MJ, Zadnik K (1989). *Contact lens fitting in keratoconus*. CLAO J. 15: 282 – 289.
- Maruyama I, *et al.* (2000). *Normal expression levels of cathepsins, protease inhibitors, and Sp1 in conjunctival tissues from patients with keratoconus*. Curr Eye Res. 21(5): 886 – 890.
- Maruyama Y, *et al.* (2002). *Involvement of Sp1 elements in the promoter activity of genes affected in keratoconus*. Invest Ophthalmol Vis Sci. 42: 1980 – 1985.
- Maruyama I, *et al.* (2002). *Mapping of Sp1 regulation sites in the promoter of the human  $\alpha$  1-proteinase inhibitor gene*. J Cell Biol. 85(3): 482 - 489.
- McKusick VA, *et al.* (1986-2004). #148300 Keratoconus 1; KTCN1. <http://srs.sanger.ac.uk/srsbin/cgi-bin/wgetz?%5Bomim-ID:148300%5D+-e>.
- McMahon TT, *et al.* (1991). *The spectrum of topography found in keratoconus*. CLAO J. 17: 198 – 204.
- McMahon TT, *et al.* (1997). *Discordance for keratoconus in two pairs of monozygotic twins*. Invest Ophthalmol Vis Sci. 38(4)(Suppl.): S960.
- McMahon TT, *et al.* (2005). *Repeatability of corneal topography measurement in keratoconus with the TMS-1*. Optom Vis Sci. 82(5): 405 – 415.
- McMonnies C (2004). *Keratoconus fittings: Apical clearance or apical support?* Eye & CL. 30(3): 147 – 155.
- McMonnies CW, Boneham GC (2003). *Keratoconus, allergy, itch, eye rubbing and hand-dominance*. Clin Exp Optom. 86: 376 – 384.
- Meek KM, *et al.* (2005). *Changes in collagen orientation and distribution in keratoconus corneas*. Invest Ophthalmol Vis Sci. 46: 1948 – 1956.
- Merck (2005). Visit: <http://www.merck.com/mrkshared/mmanual/section8/chapter96/96l.jsp>.
- Moodaley LC, *et al.* (1992). *Life expectancy in keratoconus*. Br J Ophthalmol. 76: 590 – 591.
- Moodaley L, *et al.* (1994). *Excimer laser superficial keratectomy for proud nebulae in keratoconus*. Br J Ophthalmol. 78: 454 – 457.
- Nesburn AB, *et al.* (1995). *Keratoconus detected by videokeratography in candidates for photorefractive keratectomy*. J Refract Surg. 11(3): 194 – 201.
- Nguyen TH, *et al.* (2004). *Microarray analysis identified differentially expressed genes in keratocytes from keratoconus patients*. Curr Eye Res. 28(6): 373 – 379.

- Olivares Jimenez JL, *et al.* (1997). *Keratoconus: age of onset and natural history*. *Optom Vis Sci*. 74: 147 – 151.
- Olson RJ, *et al.* (2000). *Penetrating keratoplasty for keratoconus: A long-term review of results and complications*. *J Cataract Refract Surg*. 26: 987 – 991.
- Oshika T, *et al.* (2002). *Progression of keratoconus assessed by fourier analysis of videokeratography data*. *Ophthalmology*. 109(2): 339 – 342.
- Owens H, Watters GA (1995). *Keratoconus in monozygotic twins in New Zealand*. *Clin Exp Optom*. 78: 125 – 129.
- Owens H, Gamble G (2003). *A profile of keratoconus in New Zealand*. *Eye & CL*. 22(2): 122 – 125.
- Pappa A, *et al.* (2003). *Human aldehyde dehydrogenase 3A1 (ALDH(3A1): biochemical characterization and immunohistochemical localization in the cornea*. *Biochem J*. 376: 615 – 623.
- Parker J, *et al.* (1996). *Videokeratoscopy of keratoconus in monozygotic twins*. *J Refract Surg*. 12(1): 180 – 183.
- Pearson AR, *et al.* (2000). *Does ethnic origin influence the incidence or severity of keratoconus?* *Eye*. 14: 625 – 628.
- Pflugfelder SC, *et al.* (2002). *Corneal thickness indices discriminate between keratoconus and contact lens-induced corneal thinning*. *Ophthalmology*. 109(12): 2336 – 2341.
- Phillips AJ (2003). *Can true monocular keratoconus occur?* *Clin Exp Optom*. 86(6): 399 – 402.
- Ponzin D (2001). *Atopy and keratoconus: a multivariate analysis*. *BJO Online*  
<http://bjo.bmjournals.com/cgi/eletters/84/8/834>.
- Price FW (2004). *CK reduces ectasia in post-PKP keratoconus eyes*. *Ophthalmol. Review*, March 2004 Archives.
- Raasch TW, *et al.* (1998). *Fundamental component differences in topography between keratoconic and normal corneas*. *Invest Ophthalmol Vis Sci*. 39(4)(Suppl.): S635.
- Rabinowitz YS (1995). *Videokeratographic indices to aid in screening for keratoconus*. *J Refract Surg*. 11(5): 371 – 379.
- Rabinowitz YS (1998). *Keratoconus*. *Surv Ophthalmol*. 42: 297 – 319.
- Rabinowitz YS, McDonnell PJ (1989). *Computer-assisted corneal topography of keratoconus*. *Refract Corneal Surg*. 5: 400 – 408.
- Rabinowitz YS, Rasheed K (1999). *KISA% index: a quantitative videokeratography algorithm embodying minimal topographical criteria for diagnosing keratoconus*. *J Cataract Refract Surg*. 25(10): 1327 – 1335.
- Rabinowitz YS, *et al.* (1993). *Videokeratography of the fellow eye in unilateral keratoconus*. *Ophthalmology*. 100: 181 – 186.
- Rabinowitz YS, *et al.* (1996). *Videokeratography database of normal human corneas*. *Br J Ophthalmol*. 80: 610 – 616.
- Rabinowitz YS, *et al.* (1998). *Accuracy of ultrasonic pachymetry and videokeratography in detecting keratoconus*. *J Cataract Refract Surg*. 24(2): 196 – 201.
- Rabinowitz YS, *et al.* (1998B). *Interobserver and intraobserver reliability of a classification scheme for corneal topographic patterns*. *Br J Ophthalmol*. 82: 1401 – 1406.
- Rabinowitz YS, *et al.* (1999). *Keratoconus: Non parametric linkage analysis suggests a gene locus near the centromere of chromosome 21*. *Invest Ophthalmol Vis Sci*. 40(4): S564.
- Rabinowitz YS, *et al.* (2000). *Keratoconus: Further gene linkage studies on chromosome 21*. *Invest Ophthalmol Vis Sci*. 41(4): S539.
- Rahi A, *et al.* (1977). *Keratoconus and co-existing atopic disease*. *Br J Ophthalmol*. 61: 761 – 764.



- Reinke AR (1975). *Keratoconus: a review of research and current fitting techniques, Part 1*. Int Cont Lens Clin. 2: 66 – 80.
- Ridley H (1956). *Contact lenses in the treatment of keratoconus*. Br J Ophthalmol. 40: 295 – 304.
- Rizzuti AB (1970). *Diagnostic illumination test for keratoconus*. Am J Ophthalmol. 70(1): 141 - 143.
- Rodrigues M, et al. (1992). *Clinical and histopathological changes in the host cornea after epikeratoplasty for keratoconus*. Am J Ophthalmol. 114(2): 161 – 170.
- Rubin A, et al. (2004). *Intra-ocular diurnal variation of autorefracton in keratoconic and non-keratoconic eyes*. S Afr Optom. 63(4): 159 – 166.
- Ruddle JB, et al. (2003). *Clinical progression of keratoconus following a Vth nerve palsy*. Clin Exp Ophthalmol. 31: 363 – 364.
- Saghizadeh M, et al. (2001). *Altered expressions of growth factors and cytokines in keratoconus, bullous keratopathy and diabetic human corneas*. Exp Eye Res. 73(2): 179 – 189.
- Saini JS, et al. (2004). *Keratoconus in Asian eyes at a tertiary eye care facility*. Clin Exp Optom. 87(2): 97 – 101.
- Santo RM, et al. (1999). *Corneal topography in asymptomatic family members of a patient with pellucid marginal degeneration*. Am J Ophthalmol. 127: 205 – 207.
- Sauder G, Jonas JB (2003). *Treatment of keratoconus by toric foldable intraocular lenses*. Eur J Ophthalmol. 13: 577 – 579.
- Sawaguchi S, et al. (1998). *Three-dimensional scanning electron microscopic study of keratoconus corneas*. Arch Ophthalmol. 116(1): 62 – 68.
- Schlanger J, et al. (1998). *Evaluation of the “Infinity” contact lens design in the management of keratoconus*. Invest Ophthalmol Vis Sci. 39(4)(Suppl.): S635.
- Shovlin JP, et al. (1986). *Contact lens-induced corneal warpage syndrome vs keratoconus*. Cont Lens Forum. August: 32 – 36.
- Siganos CS, et al. (2003). *Management of keratoconus with Intacs*. Am J Ophthalmol. 135: 64 – 70.
- Smolek MK, Klyce SD (1997). *Current keratoconus detection methods compared with neural network approach*. Invest Ophthalmol Vis Sci. 38: 2290 – 2299.
- Smolek MK, Klyce SD (2000). *Is keratoconus a true ectasia? An evaluation of corneal surface area*. Arch Ophthalmol. 118: 1179 – 1186.
- Spitznas M, et al. (2002). *Long-term functional and topographic results seven years after epikeratophakia for keratoconus*. Graefes Arch Clin Exp Ophthalmol. 240(8): 639 – 643.
- Spoerl E, et al. (2004). *Thermomechanical behaviour of collagen-cross-linked porcine cornea*. Ophthalmologica. 218: 136 – 140.
- Sray WA, et al. (2002). *Factors associated with the need for penetrating keratoplasty in keratoconus*. Cornea. 21: 784 – 786.
- Sridhar MS, et al. (2004). *Pellucid marginal corneal degeneration*. Ophthalmology. 111: 1102 – 1107.
- Steinert RF, Wagoner MD (1988). *Long-term comparison of epikeratoplasty and penetrating keratoplasty for keratoconus*. Arch Ophthalmol. 106(4): 493 – 496.
- Swann PG, Waldron HE (1986). *Keratoconus: The clinical spectrum*. J Am Optom Assoc. 57: 204 – 209.
- Szczotka LB, et al. (1996). *Influence of contact lens wear on the corneal topography of keratoconus*. CLAO J. 22(4): 270 – 273.
- Tay KH, Chan WK (1997). *Penetrating keratoplasty for keratoconus*. Ann Acad Med Singapore. 26: 132 – 137.
- Thalasselis A, et al. (1988). *Keratoconus, magnesium deficiency, type A behaviour, and allergy*. Am J Optom Physiol Optics. 65: 499 – 505.

- Thalasselis A (2005). *the possible relationship between keratoconus and magnesium deficiency*. Ophthalmol Physiol Opt. 25(1): 7 – 12.
- Thalasselis A, Etchepareborda J (2002). *Recurrent keratoconus 40 years after keratoplasty*. Ophthalmol Physiol Opt. 22: 330 – 332.
- Thompson RW Jr, et al. (2003). *Long-term graft survival after penetrating keratoplasty*. Ophthalmology. 110: 1396 – 1402.
- Tuft SJ, et al. (1994). *Prognostic factors for the progression of keratoconus*. Ophthalmology. 101: 439 – 447.
- Tuft SJ, et al. (1994B). *Acute corneal hydrops in keratoconus*. Ophthalmology. 101: 1738 – 1744.
- Tynnismaa H, et al. (2002). *A locus for autosomal dominant keratoconus: Linkage to 16q22.3-q23.1 in Finnish families*. Invest Ophthalmol Vis Sci. 43: 3160 – 3164.
- Uçakhan ÖÖ (2003). *Predicting corneal visual acuity in keratoconus as determined by ray tracing*. Acta Ophthalmol Scan. 81(3): 264 – 270.
- Vail A, et al. (1993). *Corneal transplantation in the United Kingdom and Republic of Ireland*. Br J Ophthalmol. 77: 650 – 656.
- Varssano D, et al. (2004). *Topographic patterns in refractive surgery candidates*. Cornea. 23(6): 602 – 607.
- Vyas D (2005). *Keratoconus*. [www.ophthalmic.hyperguides.com/tutorials/refractive/keratoconus/tutorial.asp](http://www.ophthalmic.hyperguides.com/tutorials/refractive/keratoconus/tutorial.asp).
- Wagoner MD, et al. (2001). *Penetrating keratoplasty vs. epikeratoplasty for the surgical treatment of keratoconus*. J Refract Surg. 17: 138 – 146.
- Wang Y, et al. (2000). *Genetic epidemiological study of keratoconus: evidence for major gene determination*. Am J Med Genetics. 93(5): 403 – 409.
- Watson SL, et al. (2004). *Comparison of deep lamellar keratoplasty and penetrating keratoplasty in patients with keratoconus*. Ophthalmology. 111: 1676 – 1682.
- Weed K, McGhee CNJ (1998). *Referral patterns, treatment management and visual outcome in keratoconus*. Eye. 12: 663 – 668.
- Wentz-Hunter K, et al. (2001). *Keratocan expression is increased in the stroma of keratoconus corneas*. Molec Med. 7(7): 470 – 477.
- Williams KA, et al. (1989). *Leucocytes in the graft bed are associated with corneal graft failure: analysis by immunohistology and actuarial graft survival*. Ophthalmology. 96: 38 – 44.
- Williams KA, et al. (1993). *The Australian corneal graft registry, 1990 – 1992 report*. Aust NZ J Ophthalmol. 21 (suppl): 1 – 48.
- Wilson SE, et al. (1991). *Corneal topography of keratoconus*. Cornea. 10: 2 – 8.
- Wollensak J, Buddecke E (1990). *Biochemical studies of human corneal proteoglycans – a comparison of normal and keratoconic eyes*. Graefes Arch Clin Exp Ophthalmol. 228(6): 517 – 523.
- Wollensak G, et al. (2002). *Keratoconus associated with Corneal Granular Dystrophy in a patient of Italian origin*. Cornea. 21(1): 121 – 122.
- Wollensak G, et al. (2003). *Riboflavin/ultraviolet-A-induced collagen crosslinking for the treatment of keratoconus*. Am J Ophthalmol. 135(5): 620 – 627.
- Wollensak G, et al. (2004). *Keratocyte apoptosis after corneal collagen cross-linking using riboflavin/ultraviolet-A treatment*. Cornea. 23(1): 43 – 49.
- Woodward EG, Morris J (1990). *Joint hypermobility in keratoconus*. Ophthalmic Physiol Optics. 10: 360 – 363.
- Wyględowska-Promienska D, Zawojcka I (2000). *In Polish, translated as: Procedure for keratoconus detection according to Rabinowitz-Rasheed method – personal experience*. Klin Oczna. 102(4): 241 – 244.

Woodward EG (1989). *Chapter 21: Contact lenses in abnormal ocular conditions. Keratoconus* In: Phillips AJ, Stone J (Eds.). *Contact Lenses 3<sup>rd</sup> ed.* Butterworths, London. 755.

Woodward EG (1991). *The role of rigid contact lenses in the management of keratoconus.* J Brit Cont Lens Assoc. 14: 211 – 217.

Yeung K, *et al.* (1995). *Clinical experience with piggyback contact lens systems on keratoconic eyes.* J Am Optom Assoc. 16: 539 – 543.

Young S, *et al.* (1991). *The spectrum of topography found in keratoconus.* CLAO J. 17: 198 – 204.

Zadnik K, Mutti DO (1987). *Contact lens fitting relation and visual acuity in keratoconus.* Am J Optom Physiol Optics. 64: 698 – 702.

Zadnik K, *et al.* (2002). *Between-eye asymmetry in keratoconus.* Cornea. 21(7): 671 – 679.

# Practical 8.1

(2 Hours)

## Keratoconus Fitting

## Schedule of Practical Session

**Instructions.** Divide the students into small groups of four or five. Each group is to conduct the following steps on the keratoconus patient assigned to them. Findings are to be documented on the record form provided:

1. Perform accurate refraction (subjective and retinoscopy).
2. Perform keratometry and/or videokeratoscopy.
3. Examine the eye with the slit-lamp.
4. Choose the appropriate trial contact lens.
5. Assess the fluorescein fitting pattern.
6. Consider modification to lens curves.
7. Do over-refraction (Over-Rx).
8. Order lens(es).

A class discussion should follow.



**Practical Session**

**RECORD FORM**

Group No: \_\_\_\_\_

Date: \_\_\_\_\_

ASSESSMENT VARIABLES	RESULTS
Eye	<input type="checkbox"/> Right <input type="checkbox"/> Left
Keratometry Reading	_____ D _____ @ meridian _____ _____ D _____ @ meridian _____ On K radius _____ mm
HVID	_____ mm
Baseline Eye Check	<input type="checkbox"/> clear <input type="checkbox"/> slightly red <input type="checkbox"/> irritated <input type="checkbox"/> staining  Clearance by: _____ Supervisor
Trial Lens	Lens Design _____ BCOR _____ mm Lens material _____ Thickness _____ mm Lens diameter _____ mm
Insertion Time	_____
<b>Lens Evaluation</b>	
Evaluation Time	_____
Centration	horizontal (x) _____ mm vertical (y) _____ mm
Stability	<input type="checkbox"/> yes <input type="checkbox"/> no  If no, please explain _____ _____ _____
Movement with Blink	_____ mm
Movement Type	<input type="checkbox"/> smooth <input type="checkbox"/> jerky <input type="checkbox"/> apical rotation
Speed of Movement	<input type="checkbox"/> fast <input type="checkbox"/> average <input type="checkbox"/> slow
Central Fluorescein Pattern	<input type="checkbox"/> pooling <input type="checkbox"/> alignment <input type="checkbox"/> touch
Mid-peripheral Fluorescein Pattern	<input type="checkbox"/> pooling <input type="checkbox"/> alignment <input type="checkbox"/> touch



**Module 8: Special Contact Lens Fitting**

Edge Width Horizontal (right/left) Vertical (top/bottom)	_____ / _____ mm _____ / _____ mm
Edge Clearance	<input type="checkbox"/> low <input type="checkbox"/> average <input type="checkbox"/> high
Fit Classification	<input type="checkbox"/> flat <input type="checkbox"/> tight <input type="checkbox"/> optimal <input type="checkbox"/> accept <input type="checkbox"/> reject
If rejected, what can be improved?	
Patient Comfort Rating	0      1      2      3      4      5
<b>Notes:</b>	

# **Tutorial 8.1**

(1 Hour)

## **Keratoconus Fitting And Assessment**

## Video Case Analysis

Name: \_\_\_\_\_

Date: \_\_\_\_\_

**Instruction.** A video program showing 5 cases of contact lens fits in keratoconus will be presented. Fitting assessment for each case is to be recorded in the table below.

### Case 1

ASSESSMENT VARIABLES	RESULTS
<b>Lens Evaluation</b>	
Evaluation Time	_____
Centration	horizontal (x) _____ mm vertical (y) _____ mm
Stability	<input type="checkbox"/> yes <input type="checkbox"/> no If no, please explain _____ _____ _____
Movement with Blink	_____ mm
Movement Type	<input type="checkbox"/> smooth <input type="checkbox"/> jerky <input type="checkbox"/> apical rotation
Speed of Movement	<input type="checkbox"/> fast <input type="checkbox"/> average <input type="checkbox"/> slow
Central Fluorescein Pattern	<input type="checkbox"/> pooling <input type="checkbox"/> alignment <input type="checkbox"/> touch
Mid-peripheral Fluorescein Pattern	<input type="checkbox"/> pooling <input type="checkbox"/> alignment <input type="checkbox"/> touch
Edge Width	
Horizontal (right/left)	_____ / _____ mm
Vertical (top/bottom)	_____ / _____ mm
Edge Clearance	<input type="checkbox"/> low <input type="checkbox"/> average <input type="checkbox"/> high
Fit Classification	<input type="checkbox"/> flat <input type="checkbox"/> tight <input type="checkbox"/> optimal <input type="checkbox"/> accept <input type="checkbox"/> reject
If rejected, what can be improved?	
Patient Comfort Rating	0    1    2    3    4    5

Case 2

ASSESSMENT VARIABLES	RESULTS
<b>Lens Evaluation</b>	
Evaluation Time	_____
Centration	horizontal (x) _____ mm vertical (y) _____ mm
Stability	<input type="checkbox"/> yes <input type="checkbox"/> no If no, please explain _____ _____ _____
Movement with Blink	_____ mm
Movement Type	<input type="checkbox"/> smooth <input type="checkbox"/> jerky <input type="checkbox"/> apical rotation
Speed of Movement	<input type="checkbox"/> fast <input type="checkbox"/> average <input type="checkbox"/> slow
Central Fluorescein Pattern	<input type="checkbox"/> pooling <input type="checkbox"/> alignment <input type="checkbox"/> touch
Mid-peripheral Fluorescein Pattern	<input type="checkbox"/> pooling <input type="checkbox"/> alignment <input type="checkbox"/> touch
Edge Width	Horizontal (right/left) _____ / _____ mm Vertical (top/bottom) _____ / _____ mm
Edge Clearance	<input type="checkbox"/> low <input type="checkbox"/> average <input type="checkbox"/> high
Fit Classification	<input type="checkbox"/> flat <input type="checkbox"/> tight <input type="checkbox"/> optimal <input type="checkbox"/> accept <input type="checkbox"/> reject
If rejected, what can be improved?	
Patient Comfort Rating	0      1      2      3      4      5



Case 3

ASSESSMENT VARIABLES	RESULTS
<b>Lens Evaluation</b>	
Evaluation Time	_____
Centration	horizontal (x) _____ mm vertical (y) _____ mm
Stability	<input type="checkbox"/> yes <input type="checkbox"/> no If no, please explain _____ _____ _____
Movement with Blink	_____ mm
Movement Type	<input type="checkbox"/> smooth <input type="checkbox"/> jerky <input type="checkbox"/> apical rotation
Speed of Movement	<input type="checkbox"/> fast <input type="checkbox"/> average <input type="checkbox"/> slow
Central Fluorescein Pattern	<input type="checkbox"/> pooling <input type="checkbox"/> alignment <input type="checkbox"/> touch
Mid-peripheral Fluorescein Pattern	<input type="checkbox"/> pooling <input type="checkbox"/> alignment <input type="checkbox"/> touch
Edge Width	Horizontal (right/left) _____ / _____ mm Vertical (top/bottom) _____ / _____ mm
Edge Clearance	<input type="checkbox"/> low <input type="checkbox"/> average <input type="checkbox"/> high
Fit Classification	<input type="checkbox"/> flat <input type="checkbox"/> tight <input type="checkbox"/> optimal <input type="checkbox"/> accept <input type="checkbox"/> reject
If rejected, what can be improved?	
Patient Comfort Rating	0    1    2    3    4    5

Case 4

ASSESSMENT VARIABLES	RESULTS
<b>Lens Evaluation</b>	
Evaluation Time	_____
Centration	horizontal (x) _____ mm vertical (y) _____ mm
Stability	<input type="checkbox"/> yes <input type="checkbox"/> no If no, please explain _____ _____ _____
Movement with Blink	_____ mm
Movement Type	<input type="checkbox"/> smooth <input type="checkbox"/> jerky <input type="checkbox"/> apical rotation
Speed of Movement	<input type="checkbox"/> fast <input type="checkbox"/> average <input type="checkbox"/> slow
Central Fluorescein Pattern	<input type="checkbox"/> pooling <input type="checkbox"/> alignment <input type="checkbox"/> touch
Mid-peripheral Fluorescein Pattern	<input type="checkbox"/> pooling <input type="checkbox"/> alignment <input type="checkbox"/> touch
Edge Width	Horizontal (right/left) _____ / _____ mm Vertical (top/bottom) _____ / _____ mm
Edge Clearance	<input type="checkbox"/> low <input type="checkbox"/> average <input type="checkbox"/> high
Fit Classification	<input type="checkbox"/> flat <input type="checkbox"/> tight <input type="checkbox"/> optimal <input type="checkbox"/> accept <input type="checkbox"/> reject
If rejected, what can be improved?	
Patient Comfort Rating	0    1    2    3    4    5

Case 5

ASSESSMENT VARIABLES	RESULTS
<b>Lens Evaluation</b>	
Evaluation Time	_____
Centration	horizontal (x) _____ mm vertical (y) _____ mm
Stability	<input type="checkbox"/> yes <input type="checkbox"/> no If no, please explain _____ _____ _____
Movement with Blink	_____ mm
Movement Type	<input type="checkbox"/> smooth <input type="checkbox"/> jerky <input type="checkbox"/> apical rotation
Speed of Movement	<input type="checkbox"/> fast <input type="checkbox"/> average <input type="checkbox"/> slow
Central Fluorescein Pattern	<input type="checkbox"/> pooling <input type="checkbox"/> alignment <input type="checkbox"/> touch
Mid-peripheral Fluorescein Pattern	<input type="checkbox"/> pooling <input type="checkbox"/> alignment <input type="checkbox"/> touch
Edge Width	
Horizontal (right/left)	_____ / _____ mm
Vertical (top/bottom)	_____ / _____ mm
Edge Clearance	<input type="checkbox"/> low <input type="checkbox"/> average <input type="checkbox"/> high
Fit Classification	<input type="checkbox"/> flat <input type="checkbox"/> tight <input type="checkbox"/> optimal <input type="checkbox"/> accept <input type="checkbox"/> reject
If rejected, what can be improved?	
Patient Comfort Rating	0    1    2    3    4    5
<b>Notes:</b>	

# Unit 8.2

(2 Hours)

## Lecture 8.2: Presbyopia and Contact Lenses

## Course Overview

### Lecture 8.2: Presbyopia and Contact Lenses

- I Overview of the potential presbyopia market
- II Types of contact lens correction available/possible
- III Special considerations when fitting contact lenses to presbyopes
- IV Advantages/disadvantages/success rates of various approaches
- V Types of contact lenses and contact lens designs
- VI Patient factors and expectations

# Lecture 8.2

(2 Hours)

## Presbyopia and Contact Lenses



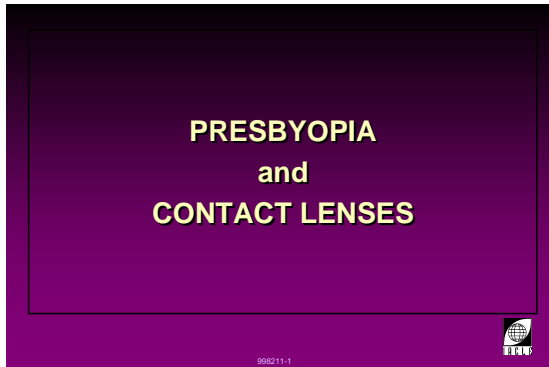


## Table of Contents

<b>I</b>	<b>Introduction .....</b>	<b>85</b>
<b>II</b>	<b>Monovision Lens Fitting .....</b>	<b>95</b>
<b>III</b>	<b>Concentric Lenses for Presbyopia .....</b>	<b>107</b>
	III.A Aspheric Simultaneous Vision Bifocals .....	114
	III.B Diffractive Bifocals .....	119
<b>IV</b>	<b>Asymmetrical Lenses for Presbyopia.....</b>	<b>129</b>
<b>V</b>	<b>Fitting Tips and Summary .....</b>	<b>139</b>

## I Introduction

1



8L2998211-1

### Correcting Presbyopia with Contact Lenses

In 1989, Ghormley declared that the greatest untapped source of future growth in the contact lens field was the fitting of the presbyopic patient. Since that was written, the presbyopic options available to fit presbyopes have improved significantly and the potential market has grown further (slide 2), so the assertion is probably even more relevant now than when penned. Further, United Nations (UN) data suggests that for the century from 1950 to 2050, life expectancy worldwide is projected to increase from 44 to 77 years.

Further, satisfied presbyopes are a significant source of referrals because of their own satisfaction and/or because of positive comments about the change (from spectacles to contact lenses when the patient is new to contact lenses) noticed by family and friends. The changes may not just be the absence of spectacles and can include:

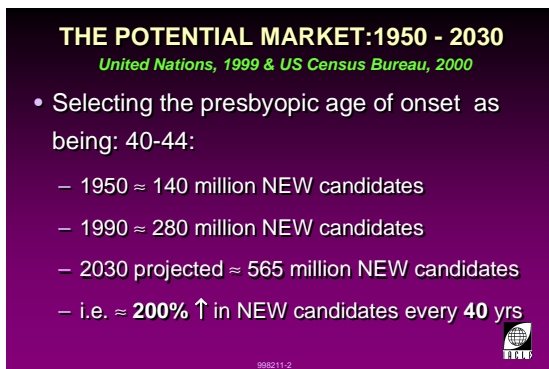
- The absence of bifocal spectacles and their 'tell-tale' near segments makes determination of the wearer's age-group less certain.
- Improved posture. No head tilt to position spectacle near segments advantageously.
- Elimination of spectacle pressure points (bearing areas) from nose pads/bridges and temples (sides).
- Some patients may exude greater confidence.

Feinbloom is credited with patenting the first bifocal contact lens in 1938 (Meyler and Veys, 1999).

Correcting presbyopia with contact lenses can be both rewarding and challenging. While somewhat dependent on the lens type chosen and patient-related factors, the degree of difficulty encountered when correcting presbyopia with contact lenses can sometimes approach that of other, technically more demanding, tasks such as astigmatism and keratoconus. However, the correction of the latter is somewhat more objective, e.g. fluorescein fitting pattern, lens centration, lens design, corneal topography, etc. whereas the correction of presbyopia is more about selecting a lens type/correction mode that will provide acceptable vision at both distance and near, albeit often being something of a compromise at one distance at least.

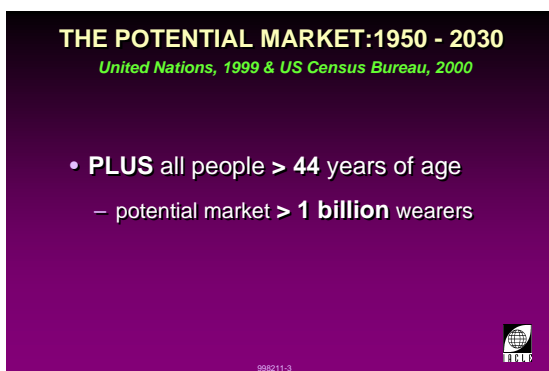
The nature and significance of presbyopia itself may need to be explained clearly to the patient before proceeding to detail their correction options (i.e. contact lenses and spectacles) along with the advantages and disadvantages of each. Once contact lenses are chosen, the contact lens-relevant aspects of presbyopia need to be presented. Other discussion topics should include contact lenses generally, patient and practitioner responsibilities, and the role of the practitioner and their practice.

2



8L2998211-184

3



8L2998211-197

The common belief that a near vision correction (of any type) makes the eyes 'weaker' may also need to be addressed but only on an as-needed basis.


The evolution of materials, lens designs, and replacement programs has increased the potential number of patients who can be fitted successfully, regardless of whether contact lenses are required full-time, part-time, or just for social occasions.

4

**PRESBYOPIC CORRECTION:  
CONTACT LENS OPTIONS**

- Combination of CLs (D) and spectacles (N)
- Monovision
  - one eye for D
  - one eye for N, but which one?
- Bifocals:
  - simultaneous vision
  - alternating vision (translating lens)
- Modified monovision
  - combination of single vision & bifocal CLs
- RGP, soft, or siloxane hydrogel materials

998211-2



8L2998211-2

**Presbyopia Correction: Contact Lens Options**

Currently, many contact lens correction options are available to the presbyope. Often it is difficult to determine in advance, which one will provide the most effective vision correction.

In the simplest scenario, the early presbyope who is already a contact lens wearer continues to use their contact lenses for distance vision and acquires a pair of reading spectacles for near, an approach that has been shown to cause the least visual confusion at near (Sidock *et al.*, 2000). However, for most contact lens wearers, the prospect of wearing spectacles, or spectacles and contact lenses, is an unattractive option, usually for the same reasons they chose contact lenses in the first place, e.g. a dislike of spectacles or a simple preference for contact lenses.

Monovision provides the simplest method of correcting both distance and near vision with contact lenses. A distance contact lens is fitted to one eye and a near contact lens is fitted to the other.

A more complex monovision approach uses a bifocal lens in one eye and a single vision contact lens in the other, i.e. so-called modified monovision. Usually, the single vision lens is used to correct the patient's vision for their most critical viewing distance, i.e. distance or near.

The alternative is to use bifocals in both eyes. Bifocal contact lenses can be of either a simultaneous vision design (rigid or soft) or an alternating (translating) design (usually a rigid lens).

Although the design of most of these lenses has evolved over time, not all provide the level of vision correction required or desired by every patient.

Practitioners now have a wide range of presbyopic lens designs available for trial fitting in both hydrogel and RGP materials. Eventually, siloxane hydrogel materials will also be available in bifocal contact lenses (obviously, single-vision siloxane hydrogels can be used now for simple monovision).

While a practitioner should be familiar with all presbyopic options, a balance needs to be struck between stocking all designs available (trying to maximize the chances of success), and stocking just those designs that have proved to be successful in the practitioner's hands (the practicalities of limited time and storage space, and relatively low wearer numbers).

To some extent, the availability of disposable single vision and bifocal trial lenses has simplified the fitting process, reduced the financial risk to both parties, and lowered the barriers to prospective wearers trying the presbyopic contact lens options.

5

**PRESBYOPIA FITTING: STRATEGIES**

- Disposable lenses are ideal
- Extended trial
  - more realistic, better feedback
- Use trial lens close to power required
- Follow manufacturer's fitting suggestions
  - for first lenses
  - subsequently, modify as necessary
- Use tinted lenses to assist handling
  - uncorrected advanced presbyopes work by sight (albeit very blurred) and feel?



8L2998211-84

**Fitting the Presbyope: Strategies**

The development of disposable hydrogel contact lenses has significantly increased the opportunities for practitioners to fit presbyopic patients. An extensive inventory of trial lenses enables the practitioner to select a lens that approximates the power required and, following an extended trial wearing period, they are better equipped to finalize all lens parameters, the suitability of the design, etc.

Initially, manufacturer's fitting recommendations should be followed. After a suitable trial period (the manufacturer's literature often includes suggestions), the visual performance at distance, intermediate, and near should be reconciled with the needs of the patient.

6

**PRESBYOPIC CL CORRECTION: CONSIDERATIONS**

after Ghormley, 1989

- |                             |                                |
|-----------------------------|--------------------------------|
| • Visual requirements       | • Status of tears/tear film    |
| • Occupational environment  | • Lid tensions/positions       |
| • Binocularity & stereopsis | • Sensitivity of cornea & lids |
| • Near add(s) required      | • Contact lens materials       |
| • Motivation                | • Availability of tints        |
| • Medication(s)             | • Costs involved               |



8L2998211-107

**Presbyopic Contact Lens Correction: Considerations**

When examining a prospective presbyopic contact lens wearer, many aspects of their case warrant consideration. Some of the more important issues are detailed in the slide opposite (after Ghormley, 1989B).

7

**EARLY PRESBYOPIA**

- Accommodation and convergence
  - CLs different from spectacles
    - ↑ demands on myopes in CLs
    - ↓ demands on hyperopes in CLs
    - especially for high Rx's
- Beware early presbyopia in myopes
  - may be able to avoid problems with hyperopes (push for maximum + power)



8L2998211-12


**Considerations in Early Presbyopia**

The accommodation and convergence demands on the early presbyope warrant consideration. It is possible that under some viewing circumstances the patient's binocular vision may be under stress. Typically, this applies to myopes who have an advantage with spectacles in the form of reduced accommodative and convergence demands at near (see Module 2, Lecture 2.3, Section **IV Accommodation with Contact Lenses** and Section **V Convergence with Contact Lenses**).

8

**PRESBYOPIA:  
CONTACT LENS-ONLY OPTIONS**

- Monovision
- Modified Monovision
- Simultaneous-Vision Bifocals
- Alternating-Vision Bifocals
- Diffractive Bifocals




8L2998211-185

9

**PRESBYOPIC CL CORRECTION:  
GENERAL APPROACHES**

- **Simultaneous vision** (rotationally symmetric):
  - designs
    - concentric 'segments'
    - back or front surface
  - aspheric
    - progressive optics (PALs)
    - diffractive (currently, hydrogel only)
  - **all** are independent of lens rotation




8L2998211-34

10

**PRESBYOPIC CL CORRECTION:  
GENERAL APPROACHES**

- **Alternating vision** (asymmetric)
  - one-piece contact lens, or...
  - fused (or embedded) segment



8L2998211-198

### Presbyopic Contact Lens Correction: General Approaches

Each of the presbyopic contact lens types available has its advantages and disadvantages. Any one of these or a combination of them can influence patient success rates.

However, almost all contact lenses for presbyopia exact some compromise on visual performance and care must be taken when considering patients with demanding visual needs or visually demanding environments (Edwards, 1999). Compromises can include the following:

- Reduced stereo-acuity.
- Loss of monocular or binocular contrast sensitivity.
- Reduced or fluctuating vision.
- Image jump.
- Changes in binocular balance (e.g. phorias, etc.).

The goals when fitting these lenses are:

- Minimize any problems induced.
- Seek compromises that are acceptable to the patient within the context of their normal visual environment and visual needs.
- Colour the patient's expectations by imparting 'knowledge' to them.

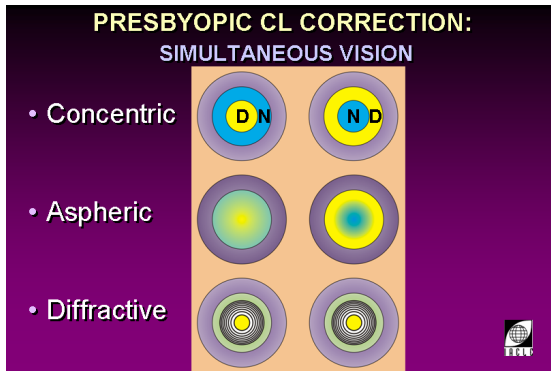
Usually, an unwillingness to compromise is a contraindication to the fitting of contact lenses for presbyopia. At the very least, an unwillingness to compromise is indicative of a potentially difficult and circuitous path to lens wear success.

Slides 5 and 6 present the general approaches to correcting the presbyope with contact lenses, using (theoretically) either soft or rigid materials. However, some of these approaches are not possible in all material types, e.g. diffractive lenses are only available in a conventional hydrogel material and few, if any, translating SCLs are still available. This reduced availability is often indicative of marketing factors, lens wear success rates, or a combination of these factors.

Obviously, monovision, i.e. a system requiring just two single-vision contact lenses, is always possible using any available single-vision contact lenses, including torics.

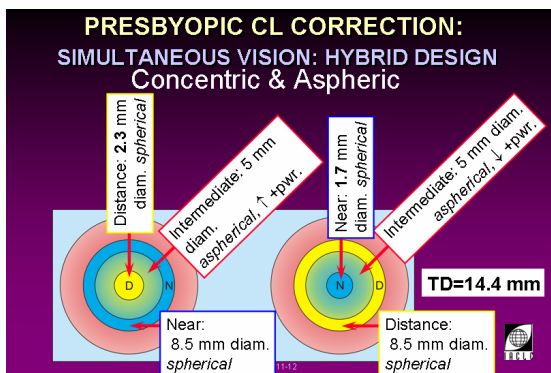
Each approach is detailed in the sections that follow.

11



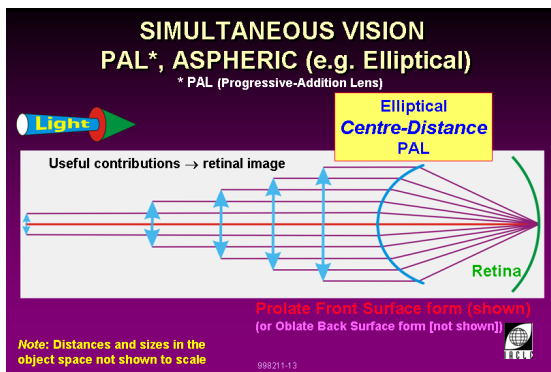
8L2998211-186

12



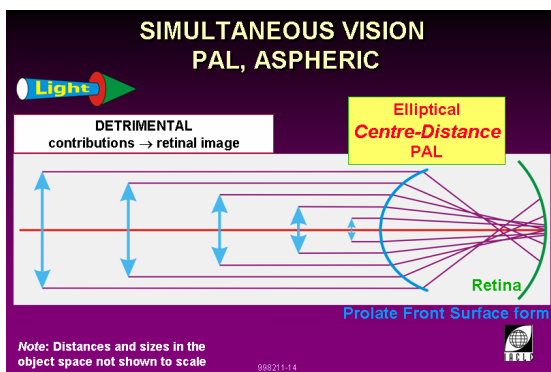
8L2998211-187

13



8L2998211-114

14



8L2998211-190

**Presbyopic Contact Lens Correction: Simultaneous Vision**

Simultaneous vision refers to the fact that the light entering *each* eye has emanated from distant *and* near objects and, importantly, all distances in between (slide 13). Although monovision is regarded as a form of simultaneous vision, the light entering each eye does not emanate from all distances and, therefore, does not meet the definition presented above. Rather, in monovision, the integration of visual information occurs at the level of the occipital cortex rather than the retina, as occurs in 'true' simultaneous vision.

When observing a distant object with a simultaneous vision lens, a retinal image is formed of the distant object by the lens' distance zone over which is superimposed a blurred retinal image of near objects formed by the lens' near zone. At near, this situation is reversed.

The lenses used for simultaneous vision are symmetrical about the geometric centre of the lens regardless of whether they are spherical, aspherical, or diffractive (see Section **III.B Diffractive Bifocals**) (slide 11). Attempts to improve the performance of simultaneous vision bifocals include hybrid designs that have optical zones of varying diameters and shape factors (i.e. spherical or aspherical) as well as a combination of centre-distance and centre-near lenses, e.g. CooperVision's Balanced Progressive™ Technology available in Proclear® Multifocal or Frequency® 55 Multifocal (slide 12).

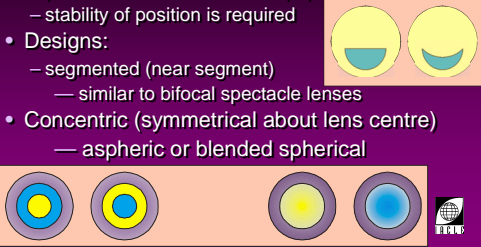
The main disadvantage of simultaneous vision lens designs is the reduced vision quality experienced by many wearers. This reduction is due to the effects of the superimposed, out-of-focus images originating from *all* other distances imaged by all optical zones of the lens being incident on the retina simultaneously (see slide 14 for a simplified treatment).



15

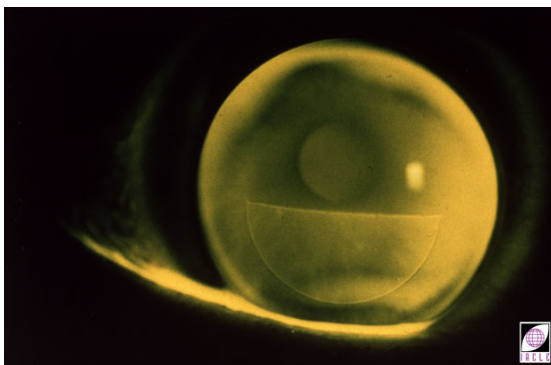
**PRESBYOPIC LENS CORRECTION:  
ALTERNATING VISION**

- Lens moves (translates) on the eye
  - positions D or N zones over pupil
  - stability of position is required
- Designs:
  - segmented (near segment)
    - similar to bifocal spectacle lenses
- Concentric (symmetrical about lens centre)
  - aspheric or blended spherical



8L2998211-188

16



8L20445-92

**Presbyopic Contact Lens Correction:  
Alternating Vision**

Alternating vision lenses are intended to provide either distance or near vision (i.e. alternate between the distances) by changing the positions of the contact lenses on the eyes, i.e. the lenses are said to ‘translate’ as the wearer’s direction of gaze is changed from straight ahead (for distance, see slide 12) to down for near.


With translating designs, excessive or insufficient lens movement can result in disturbed vision, e.g. when inadequate translation results in some of each lens zone occupying the pupil area.

The lenses must remain oriented correctly on the eye at all times. Usually, this is achieved by the use of prism ballasting or a truncation.

17

**BIFOCAL FITTING:  
POSITIVE FACTORS**

- Strong motivation
- Occupation that is less demanding visually, e.g. gardener/landscaper
  - moderate visual demands
  - some compromise acceptable
- Concern about appearance
- Being female
- Previous/current CL success
  - low myope
  - early presbyope
- Realistic expectations/part-time wear



8L2998211-5

**Bifocal Fitting: Positive Factors**

Arguably, the most important pre-requisite for the successful fitting of a presbyope is high motivation to wear contact lenses as their correction mode of choice. This is dependent largely on the practitioner providing a balanced view of all the options for the visual correction of presbyopia including contact lenses.

Often early presbyopes, even existing single vision contact lens wearers, are unaware that presbyopic contact lens options are readily available. Further, du Toit *et al.* (2000B) reported that, in addition to previous contact lens wear, being a low myope, an early presbyope, or female were positive factors for preferring bifocal contact lenses.

Because of the likelihood of some degradation of vision resulting from the use of bifocal contact lenses at distance and/or near, the prospective patient should be well informed before commencing lens wear so that they have realistic expectations about the likely visual outcome(s). Some key relevant factors are summarized in slide 17.

18

**BIFOCAL FITTING:  
NEGATIVE FACTORS**

- Emmetropia, hyperopia, higher myopia
  - may not tolerate distance blur
- Critical visual demands
  - gaze-dependent vision
  - visually-demanding occupations
- History of bifocal adaptation problems
- Poorly lit environments, esp. at near
- Significant amount of night driving



8L2998211-6

**Bifocal Fitting: Negative Factors**

Many factors must be considered carefully when selecting potential contact lens wearers from the numerous presbyopes seen in practice. Although many monovision wearers prefer bifocal contact lenses (du Toit *et al.*, 2000) some have difficulty making the transition from single vision lenses to bifocal contact lenses. To be successful, the practitioner may need to trial several of the bifocal lens designs available if optimum vision is to be achieved. Lack of practitioner enthusiasm may also reduce the chances of wearer success.

It is crucial to establish the patient's expectations clearly, early in the fitting process as the practitioner may need to moderate any demands/expectations that cannot be met by current bifocal lens designs.

As pupil size plays such an important role in likely success, it is important for the wearer to understand that variations in pupil size due to changes in light levels can influence their visual satisfaction. Such information should be included in any basic patient information supplied before fitting.

19

**BIFOCAL FITTING:  
NEGATIVE FACTORS ....contd.**

- Unrealistic expectations
  - vision
- Unenthusiastic practitioner
- Contra-indications to lens wear (general)
  - dry eye
  - some medications



8L2998211-70

20

**PRESBYOPIC CL CORRECTION  
DESIRABLE FACTORS**

- Well motivated
- Mature and responsible
- An appreciation of other benefits
  - useful for sport
  - improved cosmesis
  - convenient
- Availability of bifocal designs that offer good VA and binocularity



8L2998211-10

**Presbyopic Contact Lens Fitting: Desirable Factors**

Some patient characteristics (see slide 20) increase the chance of a successful presbyopic contact lens fitting. Additionally, those patients who are well motivated and are currently, or were previously, successful contact lens wearers are more likely to achieve a satisfactory outcome.

Patient characteristics such as an average or slightly smaller than average pupil size (anatomical: 3.5 mm, appearance [entrance pupil]:  $\approx$  4 mm [see Module 2, Lecture 2.3, Section *XI Fields of View*]) may increase the chances of success.

Dryness and discomfort were not found to be factors in wearer preferences for spectacles, monovision, or bifocal contact lenses by du Toit *et al.* (2000B).

21

**PRESBYOPIC CL CORRECTION  
DESIRABLE FACTORS**

- Lower sensitivity:
  - to reduced contrast
  - to ghosting
  - to reduced near vision in low light
- CL tolerant
- $\leq$  average pupil size (4 mm apparent)
- Dependence on a correction for near



8L2998211-9

22

**PRESBYOPIC CL CORRECTION  
UNDESIRABLE FACTORS**

- Lid tonus
  - flaccid lids a problem for translating bifocals
- Head position & very large pupil size
  - dependent on lens design
- Poor dexterity (handling difficulties)
- Inappropriate attitude:
  - no effort required
  - just a routine matter
  - no visual compromises involved
  - as simple as previous SV lenses



8L2998211-7

23

**PRESBYOPIC CL CORRECTION  
DISADVANTAGES**

- More chair time
- Lower success rate (cf. SV lenses)
  - improving with newer designs
- Greater expenses
  - for wearer (more expensive than SV)
  - for practice (trial lenses, less so with disposables)
- Dual corrections/images (i.e. D & N)
  - visual compromise often required
  - intermediate may be impossible



8L2998211-71

24

**PRESBYOPIC CL CORRECTION  
DISADVANTAGES**

- Vision often < with spectacles
- Complex designs mean more factors to consider
- Occupational considerations
  - is image suppression acceptable?
  - driving, especially at night?



8L2998211-8

25

**PRESBYOPIC CL CORRECTION  
DISADVANTAGES: GENERAL CL ISSUES**

- Adequacy of tear quality and quantity
- Medications
  - is dry eye a possibility?
- Trial lens sets (more parameters)
  - expense, storage, inventory control



8L2998211-72

**Presbyopic Contact Lens Fitting: Undesirable Factors**

Some patient variables and some lens design limitations can influence adversely the outcome of using bifocal contact lenses. Most lens designs have features that may be better suited to certain patients and it is not possible usually for one design to suit all candidates optimally. Therefore, it is important for the practitioner to have access to a range of trial lenses to gain experience and expertise with a variety of types if a successful combination of lens design and wearer characteristics is to be found.

Over time, the practitioner will develop a preference for designs with the widest application or higher success rates but these 'choices' will not guarantee success in all situations.

The practitioner should evaluate carefully each candidate and caution should be exercised in cases of:

- Pre-existing binocular vision difficulties.
- Amblyopia (say deeper than 6/12).
- Reduced distance acuity at or near the motor vehicle drivers licence standard applicable locally (usually about 6/12 in at least one eye).
- High demand for precise vision (this includes contact lens practitioners for whom monovision is unsuitable when using a slit-lamp or for performing other, detailed binocular tasks. Watchmakers and jewellers may be suitable monovision candidates provided they are not habitual users of a stereo microscope).

Despite the limitations, it is important for the practitioner to be proactive in recommending contact lenses to presbyopes, e.g. an unsuccessful bifocal fitting can still lead to other contact lens fitting opportunities with the patient and/or their family and friends, provided the issues are dealt with professionally and the patient is kept informed at all times.

26

### PRESBYOPIC CONTACT LENSES VISION CONSIDERATIONS

- Good distance vision required?
  - driving, flying, crane operator
- Good near vision
  - editor, desk job, precision work
- Good intermediate vision
  - word processing, musician (esp. keyboard instruments)



8L2998211-90

### Bifocal Contact Lenses: Vision Considerations

A careful analysis of the patient's visual needs is required before selecting the most suitable contact lens option(s). Considerations that play a role in selecting the best lens option include:

- Light levels at work and home.
- The individual's need for depth perception.
- Relative importance of distance *versus* intermediate *versus* near vision demands.

Usually, the visual requirements dictate the most appropriate type of presbyopic contact lens correction. Time spent determining the wearer's exact visual requirements before lens finalization is likely to save both parties time and effort.

Other considerations include:

- Time spent working with a computer or similar display device (i.e. working at an intermediate distance for considerable periods of time).
- Work done at arm's length (intermediate distance).
- Frequency of changes from near to far viewing distances (more relevant to translating designs than simultaneous vision lenses or monovision).

After testing three bifocal designs, Martin and Roorda (2003) concluded that vision with bifocal contact lenses, complicated by the aberrations of the eye, is not always bifocal. They found that a patient's ocular aberrations can be used to predict the vision quality with a bifocal contact lens. However, unless or until ocular aberration assessment becomes routine, the usefulness of this finding beyond a research environment is questionable.

27

### PRESBYOPIC CONTACT LENSES VISION CONSIDERATIONS

- Primary need
  - distance, intermediate, or near, ?
- Functioning environment
  - direction of gaze, duration of fixation
- Secondary need
  - social, part-time, other occupations
- Supplementary spectacles
  - will CLs + supplementary spectacles meet all the wearer's visual needs?



8L2998211-91

28

### RGP BIFOCALS ADVANTAGES

- Ideal for:
  - existing PMMA/RGP wearers
  - SCL wearers experiencing difficulties, e.g.:
    - vascularization
    - chronic oedema/corneal exhaustion
    - unsuccessful with presbyopic options
- Correct corneal astigmatism
- Potentially, deliver excellent vision



8L2998211-76

### RGP Bifocals: Advantages

In general, RGP bifocal lenses have a number of advantages over hydrogel lenses. Currently, a major advantage is the higher oxygen transmissibility achievable with modern RGP materials. However, the oxygen transmissibility advantage of RGP lenses will be addressed once bifocal siloxane hydrogel lenses become available (of course monovision with single-vision siloxane hydrogel spherical lenses is already possible).

Current SCL presbyopic options are all simultaneous vision designs. Should these prove to be unsuccessful, a RGP translating or simultaneous vision lens (in that order) is always a possibility.

Theoretically, successful, adapted RGP wearers should make an easy transition to bifocal contact lenses, as the wearer only has to adapt to the bifocal aspects of their new lenses. In the case of long-term PMMA lens wearers, it is probable that they should be refitted with suitable distance RGP lenses (see Module 7, Lecture 7.3, Section **IV.B Corneal Warpage: Management** and Lecture 8.5: **Refitting PMMA Lens Wearers**) before being


refitted with bifocal contact lenses. This enables the corneal shapes and refractive states to stabilize which may save time and effort over the course of the 'treatment'.

29

**SCL BIFOCALS  
ADVANTAGES**

- Ideal for:
  - existing, successful SCL wearers
    - comfort, adaptation, knowledge
  - RGP wearers experiencing difficulties
    - chronic 3 & 9 o'clock staining
    - discomfort
    - decentration
    - residual astigmatic errors

998211-77



8L2998211-77

**SCL Bifocals: Advantages**

Conventional hydrogel contact lenses are often the first choice for the presbyope. This is especially true when the early presbyope is already a successful SCL wearer.

Previous RGP lens wearers who experienced problems such as 3 & 9 o'clock staining that resulted in lens wear discontinuation are probably also better suited to hydrogel bifocals.



## II Monovision Lens Fitting

30

### MONOVISION

- Monocular *add* for near vision
  - one eye biased to *distance* vision
  - one eye biased to *near* vision
- Used since the 1920s
- Similar principle to a monacle
- Minimal prismatic and magnification effects
  - this is not so with spectacle monovision



8L2998211-13

31

### MONOVISION

- Ethical and legal aspects
  - runs counter to all eyecare philosophies
    - education pushes maximum binocularity
  - a deliberate visual compromise
    - what is the wearer's occupation?
  - raises professional liability/negligence issues
  - are auxiliary visual aids required?
  - adequate education and cautioning required



8L2998211-14

32

### MONOVISION CONTACT LENSES

- RGP, SCL, Siloxane hydrogels
- Spherical, Aspheric, Toric
- Clear, Tinted (opaque tints less suitable?)
- Disposed of:
  - daily
  - weekly
  - monthly
  - quarterly (too infrequent?)
  - annually (too infrequent?)



8L2998211-201

### Introduction to Monovision

Monovision is a popular, simple, and relatively successful technique. Success figures from the literature include:

- 67 to 88% [Molinari, 1988, Ghormley, 1989, Collins *et al.*, 1994, du Toit *et al.*, 1998].
- Average 73% [Jain *et al.*, 1996]) for correcting the presbyope under most visual circumstances.

While traditionally thought of as being better suited to the early presbyope (see Stein, 1990), studies (e.g. du Toit *et al.*, 1998) and reviews (e.g. Run Johannsdottir and Stelmach, 2001) suggest that the add (i.e. the anisometropia induced) is not a significant determinant of wearer success at least for 'adds' up to 2.50 D. However, Schor *et al.* (1987) did find that so-called interocular blur (see below) was less stable when higher adds were worn.

Monovision's success seems to be related to the wearer's ability to select, smoothly and transparently, the best quality monocular image available under a wide variety of circumstances and viewing distances (after Run Johannsdottir and Stelmach, 2001).

However, strong ocular dominance and visual tasks that require a smooth shift of gaze from object to object are factors that reduce success rates. The ability to select the 'better' image may actually be the ability to suppress the blur of the alternative image, i.e. a measure of interocular blur suppression, a sensory inhibitory process (see Schor *et al.*, 1987).

Patients with alternating ocular dominance, i.e. they exhibit different ocular dominances at distance and near (often due to anisometropia) are, potentially, suitable candidates for monovision (after Edwards, 1999).

Interocular blur suppression is subject to large individual variations (Collins and Goode, 1994). However, the ability to suppress also depends on the visual stimuli involved, e.g. the blur from out-of-focus, small, bright stimuli against a dark background (i.e. high contrast) was found to be difficult to ignore even by successful monovision wearers, even though the latter were better at such suppression (Schor *et al.*, 1987). This difficulty is reported frequently by monovision patients when driving. However, Wood *et al.* (1998) showed that in daylight hours, adapted wearers showed no adverse effects on driving performance when using a monovision correction (cf. their normal habitual distance correction).


For the practitioner, a major attraction of monovision is the simplicity that results from the use of single vision lenses. For the wearer, the use of 'ordinary' lenses at 'normal' costs is sometimes seen as a bonus.



33

**MONOVISION  
CRITICISMS**

- Contrary to all education and training
- Conceptually, 'one-eyed'
- Suppression is induced intentionally
- Contrast sensitivity is ↓
- Stereopsis is ↓
- Vision quality is ↓
- Can → disorientation and imbalance
- No adaptations occurs



8L2998211-199

34

**MONOVISION  
DIFFICULTIES**

- Presence of strong ocular dominance
- Tasks requiring smooth gaze shift
- Blurred, small, bright stimuli against dark background difficult to ignore
- Night driving (daylight driving is OK)
- Intermediate vision reduced if add > 2 D
- Pupil size is a factor (larger is worse)



8L2998211-200

Monovision lenses can be soft, RGP, or siloxane hydrogels that are spherical, aspherical, or toric, clear or tinted. Such lenses can be disposed of daily, weekly/two-weekly, monthly, or less often depending on the marketing applied to the particular lenses used and/or the local regulatory authority's approved indications. It is probable that because of their 'mechanical' pupil, especially if a dot-matrix iris is employed (density of dots decreases progressively to zero towards the centre to 'form' the pupil), opaque tinted lenses (see Lecture 8.8: **Tinted Contact Lenses**) are unsuitable for monovision but their use should not be ruled out absolutely.

Monovision has been criticized on a number of grounds which include the following:

- It is contrary to the training of all the professions involved with the prescribing and supplying of contact lenses. That training emphasizes the philosophy of optimizing rather than compromising all aspects of binocular vision.
- Conceptually, some prospective wearers have objections to being 'one eyed'.
- Central suppression is induced monocularly, deliberately.
- Contrast sensitivity is altered adversely.
- Stereopsis is reduced (Ghormley, 1989; du Toit *et al.*, 1998).
- Vision quality can be compromised. Is the wearer a driver of motor vehicles, a forklift operator, an operator of large cranes, an air traffic controller, etc.?
- Uncommonly, can cause disorientation and imbalance.
- Adaptation to monovision does not occur. The ability to suppress blur does not 'improve' over time (Schor *et al.*, 1989), and stereoacuity remained unchanged after 2 weeks of monovision wear (du Toit *et al.*, 1998).

Erickson (1988) studied the issue of intermediate vision with monovision and concluded that with adds up to 2 D, little compromise was likely in any gaze position. With adds greater than 2 D, some intermediate zone blur can be expected.

In view of these concerns, it is important for the practitioner to 'educate' the prospective monovision wearer about the modality. In this way, the wearer can make an informed decision about pursuing the matter further. This may mean that the prospective wearer does not progress to a trial fitting or a trial fitting does not result in lenses being ordered.

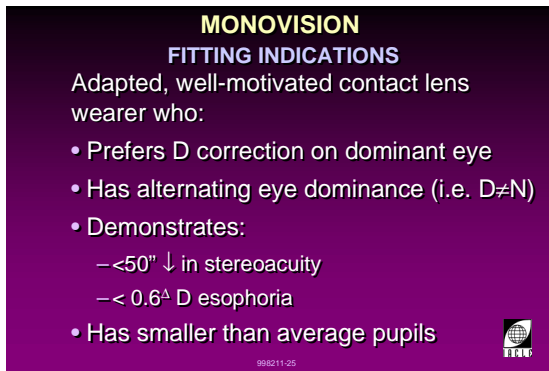
Despite the high success rates claimed for monovision, in a soft lens cross-over study by Josephson and Caffery (1987), 80% of the participants preferred bifocal correction to the monovision alternative. Du Toit *et al.* (2000) reported that, after a 12 months cross-over study of

contact lens monovision and bifocals, 30% preferred bifocal contact lenses, 42% contact lenses monovision, and 28% spectacles. They also reported that generally, bifocal contact lenses were preferred by previous contact lens wearers, females, low myopes, and early presbyopes. Conversely, contact lens monovision was preferred by hyperopes, higher myopes, and the more advanced presbyopes. After a 6 month study of successful monovision wearers, Situ *et al.* (2003) reported that 68% preferred bifocal contact lenses while only 25% preferred monovision.

Pupil size was shown to be a factor in monovision acceptance by Schor *et al.* (1987). This is probably because smaller pupils facilitate the binocular suppression process by reducing the differential blur of the two ocular images. As interocular suppression is more effective with smaller amounts of anisometropic blur, smaller pupils increase the chances of monovision success.

For a comprehensive review of monovision, see Josephson *et al.* (1990).

35



**MONOVISION**  
**FITTING INDICATIONS**

Adapted, well-motivated contact lens wearer who:

- Prefers D correction on dominant eye
- Has alternating eye dominance (i.e.  $D \neq N$ )
- Demonstrates:
  - $< 50''$  ↓ in stereoacuity
  - $< 0.6^{\Delta}$  D esophoria
- Has smaller than average pupils

8L2998211-25

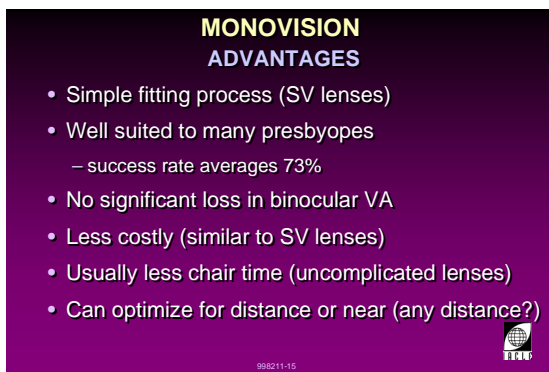
**Monovision: Fitting Indications**

Some indications for wearers suited to monovision appear in the slide opposite. However, should the patient's main visual tasks need good binocularity, it is probable that monovision is not the most suitable form of correction.

Existing contact lens wearers make ideal candidates for monovision as the add power can be incorporated simply into their current contact lens prescription in one eye.

Du Toit *et al.* (1998) found that personality and the difference between binocular and monovision stereopsis were the only two significant factors predicting monovision success. They found that the worse the stereoacuity, the lower the chances of monovision success. Wearers who were conscientious, persevering, determined and driven to do their best, moralistic, cooperative, realistic, hopeful, and dominated by a sense of duty, were significantly more likely to succeed with monovision.

36



**MONOVISION**  
**ADVANTAGES**

- Simple fitting process (SV lenses)
- Well suited to many presbyopes
  - success rate averages 73%
- No significant loss in binocular VA
- Less costly (similar to SV lenses)
- Usually less chair time (uncomplicated lenses)
- Can optimize for distance or near (any distance?)

8L2998211-15

**Monovision: Advantages**


The major advantage of true monovision is the simplicity of fitting a single vision lens to each eye. In cases where the patient is emmetropic or a relatively low myope, it may be possible to fit a lens on one eye only. However, in some situations, having a non-lens-wearing eye to compare the comfort of the lens-wearing eye with can be a disadvantage.

Current (successful) contact lens wearers are obvious candidates for monovision fitting (and for bifocal contact lenses as well). Generally, they are highly motivated to continue with contact lens wear, having made the decision already that contact lenses are their correction form of choice.

37

**MONOVISION  
ADVANTAGES**

- It works in most cases
- Fitting is simple
- Usually, quick to accept or reject
  - if negative initially – failure likely
  - if positive initially – not a reliable indicator
- Ideal for social/occasional users
- Often, fewer trial lenses are required (cf. trial bifocal CLs)

998211-21 

8L2998211-21

A number of studies have shown that the success rate with monovision is higher than that achieved with many bifocal contact lenses. Although successful when fitting the early presbyope, advanced presbyopes (e.g. adds 2.00 D) may not fare as well (Schor *et al.*, 1987; Erickson, 1988; du Toit *et al.*, 2000).

Situ *et al.* (2000) studied bifocal and monovision contact lenses and found:

- no significant differences between modalities except for:
  - near vision in poor lighting in which monovision was rated as being better;
  - depth perception in which bifocal contact lenses were rated as better;
  - intermediate vision was better with bifocal contact lenses;
  - distance stereopsis (@ 3 m) was better in bifocal contact lenses.
- binocular high and low contrast VA was rated higher at both distance and near with monovision contact lenses.


Du Toit *et al.* (1998) found that an initial negative response to monovision was indicative of likely failure whereas an initial positive response was not a reliable indicator of likely success.

Fonn *et al.* (2000) found that, on average, 2 lenses per eye were required to achieve an optimum monovision contact lens fit while 3.1 lenses per eye were required for bifocal contact lens optimization.

38

**MONOVISION  
DISADVANTAGES**

- Practitioner & patient attitudes
- Decreased stereo acuity
  - reduced binocular summation
- Decreased contrast sensitivity
  - however, other presbyopic CL options may also have this problem
- Loss of clear *intermediate* vision with higher adds
  - correct for intermediate rather than near?

998211-16 

8L2998211-16

**Monovision: Disadvantages**

The monovision technique relies on an innate ability of the wearer to suppress visual information that is either not beneficial or confounds the preferred visual input. This can result in some disruption to their binocular status. Such an effect may become apparent when testing the stereoacuity and contrast sensitivity functions at near and/or distance. The results will be lower than when wearing spectacles.

While monovision is generally well-tolerated by most presbyopes, the compromises inherent in monovision may not be as well-tolerated as the disparity between the two retinal images increases, i.e. as the add increases in magnitude and the 'imbalance' between the eyes increases.

Wearers should be counselled that, if spectacle wear is to be avoided, and monovision rather than bifocal contact lenses are chosen, the 'cost' is the compromises that have to be made. Before commencing monovision lens wear, the likely adverse effects, especially driving in less than ideal light circumstances, should be presented clearly, and informed wearer consent obtained.

In some cases, or under some circumstances, over-spectacles can be used to improve vision at either distance or near, especially if light levels are

39

### MONOVISION DISADVANTAGES

- Speed of visual tasks may be reduced
- Unsuitable for amblyopic patients
- Unsuitable for use with some existing binocular vision anomalies
- Night vision/night driving problems
- Long-term use may induce a sustained change in refractive error



8L2998211-73

40

### MONOVISION DISADVANTAGES

- Need to consider supplementary spectacles or contact lenses for:
  - enhanced DV
  - enhanced NV
  - prolonged use at some other distance



8L2998211-88

41

### MONOVISION DISADVANTAGES

- Infrequently, the following have been reported:
  - hazy vision
  - occasional loss of balance
  - dizziness
  - loss of stereopsis



8L299821-191

42

### MONOVISION CONTRA-INDICATIONS

- Binocular vision problems, amblyopia, SNV
- Personalities that:
  - disregard rules
  - give up easily
  - are unreliable
  - are self-pitying
  - are dependent
  - exhibit fickle behaviour
- Visual task requirements
  - fine detail
  - good stereopsis
- Low lighting conditions
- Strong sighting preference



8L2998211-20

low. Alternatively, if long-distance and/or night driving is contemplated, a second distance contact lens could be provided so that the near lens can be replaced by a distance lens in the interests of vision quality and binocularity.

Concern has been raised about the possible effects the induced anisometropia of monovision may have on refractive error in the long term. After just 6 months, Situ *et al.* (2002) found no significant changes. To investigate the possible effects of prolonged (>12 months) monovision contact lens wear on the eyes' refractive status, Wick and Westin (1999) studied 62 monovision wearers and compared them with two closely matched control groups, one of which was composed of contact lens wearers while the other group was spectacle wearers. Anisometropia was more likely to develop in the monovision group, apparently as a result of the anisometropia induced by monovision, and changes of 0.50 D (max. 1.25 D) were recorded in 29% of the monovision wearers. McGill and Erickson (1991) reported a tendency for unsuccessful monovision wearers to exhibit esophoria at distance when so corrected.

The suitability or otherwise of monovision to a particular stage of presbyopia has drawn conflicting reports. Du Toit *et al.* (1998) found that wearers with higher Rx's and higher adds were more successful in monovision than other presbyopes possibly because of their greater dependence on both D and N Rx's. However, Schor *et al.* (1987) and Heath *et al.* (1988) reported that lower reading adds were advantageous because of better preservation of binocular summation, better stereopsis, and more stable suppression.

#### Monovision: Contraindications

Monovision compromises binocular vision to some extent. Each prospective monovision candidate should be assessed with a view to determining if any contraindications are apparent. Those with a very high visual demand or those with an existing binocular vision problem are unlikely to be suited to monovision.

Strong and obvious ocular dominance (Benjamin and Borish, 1998), and significantly unequal BCVA, also affect likely success rates adversely. A patient requiring good intermediate vision requires a lower add (providing distance and intermediate vision at the expense of true near vision) or an alternative modality, i.e. a presbyopic correction other than monovision.

43


**MONOVISION  
DOMINANT EYE**

- Usually, dominant eye corrected for Distance

*Types of dominance*

- **Sighting dominance**
- **Ocular dominance**
  - least plus acceptance (viewing binocularly)
  - more definite endpoint to subjective refraction
  - last to break in near point of convergence (NPC) assessments

998211-22




8L2998211-22

44

**MONOVISION  
DOMINANT EYE** .....continued

- **Sensory dominance**, e.g. Ogle *et al.*'s fixation disparity-based test, +2 D test, monocular blur suppression
- **Functional dominance**, changes according to test or test distance
- Eye with **best corrected acuity**
- **Occupational issues**, e.g. driving & vehicle mirror locations (RH drive or LH drive?)

998211-23



8L2998211-23

### Monovision: The Dominant Eye

Although there is no agreement on which distance the dominant eye should be corrected for, there is a common thread in the literature of the dominant eye being corrected for distance (see review by Jain *et al.*, 1996; Garland, 1987; Ghormley, 1989; Erickson and Schor, 1990; Hansen, 1999B) at least as a starting point. Other views exist and some are unrelated to ocular dominance. These include:

- Use the dominant eye at the most important or relevant distance.
- Correct the eye nearest to a car's rear-view mirror (depends on which side of the road cars drive on).
- Correct the least myopic eye for distance.

In the majority of cases, the distance vision lens is prescribed for the 'dominant' eye because the crucial tasks of sighting, localization and navigation are largely distance ones (after Benjamin and Borish, 1998). Jain *et al.*'s 1996 review supported correcting the dominant eye for distance as having the highest success rate in monovision.

However, in cases of anisometropia, consideration should be given to selecting the near eye with a view to achieving something of a balance in Rx between the eyes rather than automatically selecting the non-dominant eye for near. For example: if the distance Rx is: +1.00 DSph & +3.00 DSph, ADD 2.00 D, the monovision Rx choices are: +1.00 & +5.00, or +3.00 & +3.00. The latter is more likely to be successful than the former because of the large imbalance that results, i.e. +4.00 (Ghormley, 1989).

Before fitting monovision contact lenses, it is useful to determine which eye is dominant functionally. Unfortunately, there are several forms of ocular dominance and while ocular dominance and handedness are often on the same side of the body, true crossed dominance exists (Rabbetts, 1998).

To complicate matters further, anisometropes or unilateral ametropes may have different functional eye dominances at distance (less myopic or emmetropic) and near (more myopic, or myopic) (Rabbetts, 1998). However, a recent study (Cheng *et al.*, 2004) found the opposite result at least in significant anisometropic myopia ( $\Delta > 1.75D$ ), i.e. the dominant eye was the *more* myopic.

Some tests of ocular dominance are presented here. It is important to confirm the result using more than one 'test'. Many tests fail to eliminate the issue of handedness from their outcomes. Some tests include:

- Sighting tests (Dolman Card [hole-in-the-hand], double-handed pointing [two-index finger shooting, manoptoscope).

**Dolman Card:** The patient is asked to hold the special sighting card with *both* hands. The card



has a small hole in the centre. They are requested to keep both eyes open and sight a nominated letter on a Snellen chart through the central hole. By covering one of the patient's eyes, the practitioner can determine which eye was used for sighting the letter. This eye is considered the dominant eye. A variation of this theme is observing which eye is used to operate a camera/video camera (or a focimeter/lensometer) assuming they are monocular devices.

**Double-handed pointing:** The patient is instructed to clasp their hands together (a crude attempt to eliminate handedness as a factor in the test's outcome) while holding their forefingers together as a single pointing device. From a short distance away, the practitioner, with one eye closed, asks them to point at his open eye. Usually, the patient's dominant eye will be aligned with their pointing fingers and the practitioner's open eye.

**Manoptoscope (a.k.a. Parson's Cone):** Essentially, this is a truncated pyramid. The wider end is held over the eyes as if using a pair of binoculars and a nominated distant object is viewed through the narrow end. As fixation by both eyes is impossible (viewing aperture is too small), the subject is forced to re-align the device so that their dominant eye takes up fixation of the nominated target.

Regardless of the pointing test used, the test should be repeated once or twice to confirm that the initial result was not simply a case of the 'device's' original position being close to that required for the non-dominant eye to fixate the nominated target.

- **Plus to blur:** This test is performed with both eyes open while viewing a distance letter chart. Plus power is added monocularly until the onset of blur is reported. The plus power is noted. Usually, the eye that accepts the most plus before blurring is detected as the non-dominant eye. This eye is probably better suited to near vision as it will be subjected to the greatest over-plusing under general viewing conditions.
- **Fixation loss at the Near Point of Convergence (NPC):** If a simple 'pencil to nose' or similarly crude NPC determination is done, it is usually the non-dominant eye that breaks fixation first, once the NPC is exceeded. Because the break may be bilateral and the speed of eye movement rapid, it can be difficult to determine which eye gave up fixating first. Repetition of the test may be required.
- **Other tests:** Ogle *et al.* (1967, cited in Rabbetts, 1998) designed an ocular dominance test based on fixation disparity that eliminated the handedness factor. It is not in common use. It has been observed that when light levels change from low to very high suddenly, e.g.



stepping from a dark room into bright sunlight, it is usually the dominant eye that closes leaving the non-dominant eye responsible for vision (the greater 'asset' being protected?).


Clinical experience may also show that, at least at distance, the dominant eye may have a more definite subjective refraction end point, i.e. a more concise, decisive, more rapid, or more confident decision that the Rx determined is the optimum for the eye under test. Unfortunately, pathology affecting the tear film, cornea, and/or crystalline lens may negate this generalization.

- **+2.00 D test:** The best binocular Rx is placed in a trial frame (not a refractor head) and the subject directed to view a distance chart through it. A +2.00 D trial lens (or flipper) is placed alternately in front of each eye. The patient is asked to indicate when the chart is 'clearest' subjectively. The eye 'uncovered' (no +2.00 D lens) when the subject indicates clearest is assumed to be the dominant eye for monovision purposes. The result may be the opposite of that from other tests of ocular dominance (this test after Maldonado-Codina *et al.*, 1997).
- **Monocular blur suppression test** (see Fisher, 1997): The relative disruption to spectacle acuity produced by a 0.50 D or 1.00 D lens (plus at distance, minus at near) is assessed and the result used when doubt existed about which eye was dominant or which eye suppressed more effectively.

45

**FITTING THE DISTANCE EYE GUIDELINES**

- Identify 'dominant' eye
- Rx for maximum distance vision
  - correct astigmatism  $\geq 0.75$  D
- Use disposables lenses
  - they allow a low-cost trial
- Reverse the roles of each eye if necessary
- Discontinue if acceptance is still poor



8L2998211-18

### Monovision: Fitting the Distance Eye

Usually, the dominant eye is fitted with the distance vision lens. However, for occupational reasons, this is reversed if the patient's visual needs suggest that greater visual demands are made at near.

If a correction for astigmatism is also needed to maximize the VA at both distance and near, this should be incorporated into the final prescription. Uncorrected astigmatism can also result in asthenopic symptoms and reduced lens tolerance, thereby reducing the chances of success.

An extended trial with diagnostic lenses is advisable to determine the likely level of patient acceptance and adaptation (usually, little or no adaptation required according to most studies). If the initial monovision trial produces an ambiguous result, it is often worthwhile changing the near vision correction over to the dominant eye, i.e. reversing the roles of each eye, to ascertain whether any improvement is possible.

If the wearer shows a definite intolerance to monovision, an alternative form of presbyopic contact lens correction should be trialled, as the chance of adaptation to monovision is minimal.

Problems that the wearer may experience include:


- Poor vision.
- Ghosting.
- Poor spatial localization and disorientation.
- Nausea.
- Poor suppression of the out-of-focus image.

Sanchez (1988) advocated fitting the right eye for near, especially in those countries that have left-hand drive cars. Sanchez also advised against night driving with monovision contact lenses.

46

**FITTING THE NEAR EYE GUIDELINES**

- Least plus that provides clear N
- Maximize range of clear vision
  - new presbyopes may have difficulty suppressing if power difference between eyes is small
  - old presbyopes may have difficulty if add is too high

988211-19 

8L2998211-19

**Monovision: Fitting the Near Eye**

Generally, it is advisable to fit the near vision eye with the lowest amount of plus power that provides acceptable near vision and an adequate range of clear vision. In some cases, an astigmatic correction may be required for optimum near vision. Toric lens re-orientation at near may need to be compensated for in some wearers.

Signs that indicate a greater chance of success with monovision include:

- Binocular VA with contact lenses equal (or nearly equal) to the best spectacle acuity.
- Reduction in stereopsis (stereoacuity) of less than 80 to 100" of arc (see McGill and Erickson, 1988, Table 5).
- No significant difficulty experienced with the reduced contrast sensitivity of monovision (loss is evident with higher spatial frequencies [ $>4$  cycles/degree] but not with low spatial frequencies [0.5 to 4 cycles/degree], see Collins *et al.*, 1989; Run Johannsdottir and Stelwach, 2001).


Wood *et al.* (1998) concluded that monovision did not affect daytime driving performance adversely for adapted wearers. Collins *et al.* (1994) also found that with monovision, overall night driving satisfaction was 'diminished substantially'.

For some wearers, it may be better to reduce the add power in the 'near' eye and supply the patient with over-spectacles for those occasions that optimum distance vision is required. Alternatively, in circumstances such as night driving and when long periods of critical near work are undertaken, it may be more appropriate to supply a third contact lens to optimize the VA at the required distance.

47

**FITTING NEAR EYE GUIDELINES**

- Occasionally, over-spectacles or a third CL may be required for recurring demanding tasks at:
  - near (only distance Rx requires alteration)
  - intermediate (both Rx's require alteration)
  - distance (only near Rx requires alteration)
- Discontinue if intolerance is demonstrated


988211-74 

8L2998211-74

48

**MONOVISION  
OCCUPATIONAL NEEDS**

- Child carer: few detailed tasks (bifocal CLs?)
- Accountant: mainly near (desk-based)
  - reading lens on dominant eye
- Word processor: mainly near with lateral gaze
  - reading lens on eye nearest the 'copy'
- Motor mechanic: near & intermediate
  - less than ideal environment for CLs?
- Jeweller: mainly near visual task
  - experienced suppressor (jewellers' eyepiece)
- Graphic artist or precision engineer (too demanding?)
- Are there any safety issues?



8L2998211-24


**Monovision: Occupational Needs**

When deliberating on the utility of monovision contact lenses, an evaluation of the occupational and other needs of the potential wearer is required. This is more important in monovision than other forms of presbyopic correction because the type of work performed by the wearer often dictates the choice of lens powers (and possibly the types of lenses) to be prescribed.

49

**MONOVISION  
FITTING PROCEDURE**

- Unadapted CL wearers
  - consider fitting a pair of D lenses first
- After adaptation period, try monovision
- Adapted CL wearers
  - near lens for non-dominant eye with lowest acceptable plus addition
  - trial this combination
  - assess after 2 - 10 days



8L2998211-26

**Monovision Fitting Procedure**

Experienced contact lens wearers usually find the change to monovision uncomplicated. However, their experience does not negate other factors, e.g. personality, that may have adverse effects on their chances of success with monovision.

Initially, neophytes can be fitted with a pair of distance vision lenses until they are adapted to, and better understand what is involved in contact lens wear. Once proficiency has been demonstrated, they can be transferred to a monovision lens wear trial.

50

**MONOVISION  
ADVICE**

- Prescribe a handling tint
- Discuss care and maintenance systems
  - with experienced wearer, reinforce/correct
  - with neophyte wearer, get it right from the start



8L2998211-27

**Advice for Monovision Wearers**

Although adaptation to monovision is usually rapid for most wearers, realistic advice can facilitate adaptation. In some cases, the rate of adaptation may be slow and sensations of dizziness have been reported.

To enable new wearers to adapt quickly, offer advice on the usage and pitfalls of their correction, e.g. suggest that the near lens be inserted first as this offers them the best vision for inserting their distance lens. Logically, the near lens should be removed last.


Use lenses with handling tints to maximize the chance of the presbyope seeing the lens against light backgrounds, e.g. lens case, bench top, sink, or the palm of their hand.

51

**MONOVISION  
ADVICE**

- Insert N lens first, remove N lens last
- Adaptation
  - usually rapid but can take 'days to weeks'
  - although unlikely, blur and dizziness possible
- When driving at night haloes & glare may affect:
  - depth perception
  - distance estimation
  - reaction times, and...

**Confusion is possible**



8L2998211-28

High-risk tasks such as driving at night should be undertaken with caution by the newly-fitted monovision wearer.

*Clinico-legal aspects*

A summary of the clinico-legal aspects of monovision was presented by Harris and Classé (1988) and of presbyopic contact lenses in general by Harris (1990). Their recommendations and warnings are summarized in the slide 52.

52

**MONOVISION**  
**CLINICO-LEGAL ASPECTS**


Mono vision patients should be: after Harris and Classé

- Selected carefully
- Fitted properly
- Informed adequately of the risks of reduced visual acuity and stereopsis

Negligence in the prescribing, fitting, or after-care of these patients can create liability for the contact lens practitioner

The principle of informed consent is applicable

98211-192




8L2998211-192

53

**WHY BOTHER WITH BIFOCALS ?**

- 25-30% of patients are intolerant of monovision
- Some bifocals give better low-contrast VA and stereopsis
- Better for those with binocular vision problems
- Better in amblyopia or strong ocular dominance
- 'High tech' solution
  - practice building
  - may help to retain patients

98211-32



8L2998211-32

### Need for Bifocal Contact Lenses

As the world's population ages, the need for further developments in presbyopic contact lenses, especially bifocal contact lenses, has been recognized. While many advances have been made, and success rates continue to rise, routine fitting and wearing success is still not assured.

Although it is successful in a high percentage of those who proceed to wearing contact lenses, monovision is not the ideal way to correct presbyopia because stereopsis is reduced in the majority of wearers. Bifocal contact lenses are more suitable for those who have strong ocular dominance or are unable to adapt to monovision.


A specialist contact lens practice must encompass the provision of bifocals if their service is to be regarded as being comprehensive. Generally, bifocal lens fitting differentiates a specialist contact lens practice from an ordinary practice. This specialized and comprehensive approach to contact lenses promotes patient loyalty and increases the likelihood of referrals from the existing patient base.

54

**ENHANCED MONOVISION**

- SV distance lens in dominant eye
- Bifocal N lens in non-dominant eye
  - consider over correcting N Rx
- Depending on tasks:
  - reduce D Rx and correct N fully
  - reduce N Rx and correct D fully

98211-29



8L2998211-29

### Fitting Enhanced/Modified Monovision

Should the performance of monovision prove to be inadequate, a number of options to modify the traditional monovision fitting technique can be considered. These include 'enhanced monovision' and 'modified monovision'. While the terminology varies according to the user or the origin, the meanings used here are:

- 'Enhanced monovision' refers to a single vision lens in one eye (usually the dominant eye) and a bifocal lens in the other, usually biased towards near vision. This is probably more suitable for the presbyopic low ametropes because the dominant eye has unimpaired distance vision and reduced visual conflict with the non-dominant eye (after Edwards, 1999).
- 'Modified monovision' refers to a bifocal contact lens in each eye with one lens tailored to provide 'better' distance vision (usually the dominant eye) and the other lens providing 'better' near vision. This method is intended to provide the benefits of bifocals combined with some benefits of monovision.

55

### ENHANCED MONOVISION

- Often useful for high adds
- Incorporate one bifocal lens into a monovision system
  - to enhance N
    - use centre-near (C-N) bifocal in dominant eye
    - full N Rx (SV) in non-dominant eye
  - to enhance D
    - use centre-distance (C-D) bifocal in non-dominant eye
    - D Rx (SV) in dominant eye



8L2998211-31

Regardless of whether enhanced or modified monovision is used, in the interests of good distance vision, the dominant eye wears a distance vision-biased lens while the non-dominant eye wears a near-biased bifocal lens. Should occupational reasons dictate that the best vision be provided at near, the reverse of the previous statement applies.

When bifocal lenses are used in both eyes, the wearer obtains some of the benefits of bifocal lenses along with some of the added visual advantages of monovision. However, the disadvantages of both modalities are also still present and applicable.

With back surface aspheric (PAL) simultaneous-vision lenses, as the near addition increases, modified monovision may become necessary because of the limited range of reading additions that can be fabricated in such designs, i.e. the Rx may have to be intermediate and near, rather than distance and near, because of the practical limitations in the add power that can be supplied.

As with most types of presbyopic correction, the practitioner must determine the respective merits of each type of bifocal lens at distance and near before prescribing enhanced or modified monovision.

56

### MODIFIED MONOVISION

- Applicable to advanced presbyopia or those with special visual needs
- D-biased bifocal CL fitted to the dominant eye
- N-biased bifocal CL fitted to the non-dominant eye
- Depending on tasks:
  - reduce D Rx and correct full N
  - reduce N Rx and correct full D (e.g. driver)



8L2998211-109

As with most types of presbyopic correction, the practitioner must determine the respective merits of each type of bifocal lens at distance and near before prescribing enhanced or modified monovision.

57

### MODIFIED MONOVISION

- Use C-D bifocal on dominant eye
  - fit C-N bifocal on non-dominant eye
- For advanced presbyopes ( $\geq +2.00$  Add)
  - fit dominant eye for D with annular (or progressive-addition) bifocal SCL in other eye
  - like many presbyopic options,  $\downarrow$  VA can be a problem
  - reading glasses over SCLs may be preferred



8L2998211-30



### III Concentric Lenses for Presbyopia

58

#### SIMULTANEOUS VISION 'BIFOCALS' (BIFOCALS, MULTIFOCALS, & PALs)

- Bifocals: D and N images formed on retina simultaneously (along with blurred images from all other distances)
- Multifocals & PALs: D, N, & Intermediate images formed on retina simultaneously (along with blurred images from all other distances)
  - clarity varies according to working distance



8L2998211-85

59

#### SIMULTANEOUS VISION 'BIFOCALS' (BIFOCALS, MULTIFOCALS, & PALs)

- Two definite foci (bifocals)
- Multiple (multifocals) or Continuously variable foci (PALs)
- Power changes across surface
  - discrete steps (bifocal, multifocal)
    - blended transitions?
  - smoothly (PAL)
  - optically, similar to spherical aberration
    - image quality decreased accordingly
    - ↑ depth of focus → ↑ depth of field



8L2998211-110

#### Concentric Bifocal, Multifocal, and Progressive Addition Contact Lenses Providing Simultaneous Vision

Simultaneous vision bifocals (as well as multifocals and Progressive Addition Lenses [PALs]) are contact lenses in which light from both far, near, and all intermediate distances enter the eye simultaneously. The retinal images formed represent the whole range of objects and working distances present in the field of view (see slides 9 and 10 of this lecture). Visually, discrimination of the main object of regard becomes a cortical function. Its focused image must be 'isolated' from all the other, out-of-focus images present. This can only occur in a centre(s) further up the visual pathway than the retinas. For a detailed discussion on the perception and physiological optics of 'simultaneous vision' see Benjamin (1993).

Stein (1990) believes that prospective patients whose ametropia is greater than their reading add make poorer bifocal candidates, i.e. a +2.00 D hyperope with a +1.50 D add is less well suited to bifocals than a +1.00 D hyperope with a +2.00 D add (only hyperopic examples were presented and myopia was not mentioned specifically – no reason was presented but it is probably related to the magnitude of the add rather than the sign of the ametropia).

60

#### SIMULTANEOUS VISION BIFOCALS ADVANTAGES

- Available in RGP and SCL designs
- D & N corrections present within pupil simultaneously
- With larger pupils, better than alternating designs
- Not gaze dependent *but* light dependant
- Positive spherical aberration a benefit?
- More comfortable than segmented designs
  - equal to single vision lenses
- Easier to fit



8L2998211-35

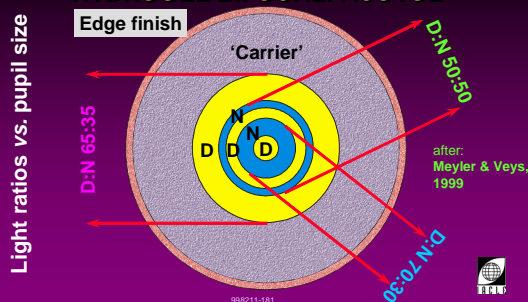
#### Advantages of Simultaneous Vision Bifocals

The major advantage of simultaneous vision lens designs is that no special lens orientation or movement characteristic is required for them to function as intended. As long as the lens covers the pupil, there is the potential for a good visual result. By using alternate concentric zones for D and N (e.g. the Acuvue® hydrogel bifocal, a C-D design with three D and two N zones), pupil dependency is reduced (referred to as 'pupil-intelligent' by the maker) (see slide 56).

A combination of good lens centration without excessive lens movement provides the optimum fitting characteristics for a successful visual outcome. To some extent, the needs for a good visual outcome (little or no lens movement) are the opposite to those for a good physiological outcome (adequate tear exchange, and metabolic by-product and sloughed-cell removal, requiring blink-induced lens movement).

61

#### CONCENTRIC SIMULTANEOUS VISION HYDROGEL BIFOCAL: ACUVUE



8L2998211-181



62

**SIMULTANEOUS VISION BIFOCALS  
DISADVANTAGES**

- Some ↓ VA
- Some ↓ contrast
  - especially in low luminance
- Pupil size dependent
- Adaptation/acceptance problems
  - VA?
  - ↓ contrast
  - haloes/ghosting
- Accurate over-refraction is difficult
  - pupil zone has multiple Rx's effective



8L2998211-81

**Disadvantages of Simultaneous Vision Bifocals**

The main disadvantages of simultaneous vision contact lenses include:

- Decreased contrast due to multiple images of varying focus quality formed on the retina simultaneously.
- With most designs, changes in pupil size due to varying lighting and viewing conditions and distances have an impact on the effectiveness of the correction.
  - small pupils 'convert' most simultaneous vision lenses to single vision lenses (only the centre zone fills the eye's reduced entrance pupil). Diffractive lenses (see later) and lenses that have alternating D and N zones (see slide 56) have a lesser problem but are not exempt from the effects of small pupils.
- Retinal image brightness is reduced (see Benjamin, 1993, 1994).

Harris *et al.* (1991) studied 40 hydrogel concentric, simultaneous vision bifocal wearers and failed to identify risk factors for the discontinuations that were due mainly to blurred vision.

63

**SIMULTANEOUS VISION BIFOCALS  
CONCENTRIC**

- Centre near (C-N) or centre distance (C-D)
- Zone location
  - front or back surface
- Any material (except siloxane hydrogels currently)
- Any zone size (within reason)



8L2998211-36

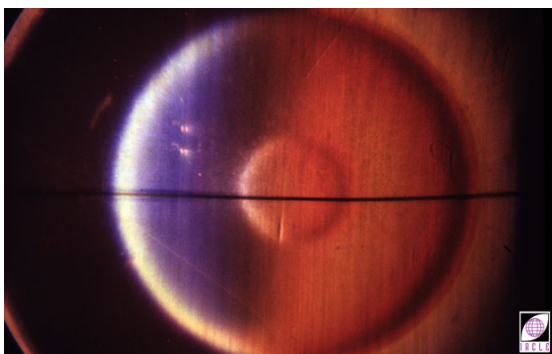
**Bi-Concentric Simultaneous Vision Bifocals**

These lenses are of solid (i.e. one-piece) construction and incorporate either a back or front-surface 'near' segment. In most cases, the segment is on the front surface as this provides a more predictable fitting (lens-cornea relationship) and increased comfort.

The lens' central zone may be intended for either distance (Centre Distance [C-D]) or near (Centre Near [C-N]) use (slide 59). The surrounding 'carrier' portion of the lens provides the near or distance power respectively.

Such lenses are produced in either soft or RGP form and in a wide range of designs.

64



8L20830-91

65

### CENTRE-NEAR CONCENTRIC FITTING PROCEDURE

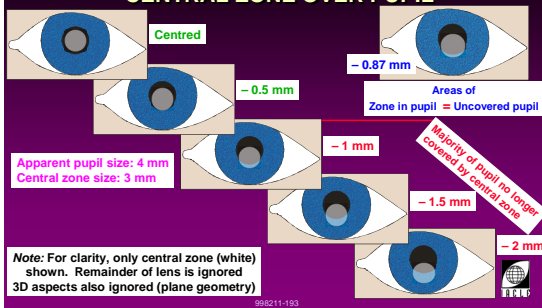
- Centred fit
  - fit to minimize lens movement
- Adequate/reduced movement
  - zone always within pupil area
- Zone diameter covering 50% of pupil area
  - as starting point
  - verify habitual ambient lighting
- If difficulties arise, try modified monovision



8L2998211-37

66

### SIMULTANEOUS VISION BIFOCALS CENTRAL ZONE OVER PUPIL



8L2998211-193

67

### SIMULTANEOUS VISION C-N DESIGNS

- Generally good NV
  - low illumination favours distance vision
  - high illumination favours near vision



8L2998211-38

68

### SIMULTANEOUS VISION BIFOCALS C-N ISSUES

- Most C-N bifocals have small OZDs (<3 mm)
- Pupil size is important
  - light-level dependent
  - small pupils decrease distance vision quality or render the lens near-only
- Pupil coverage is important
  - lens centration and minimal lens movement are important
- If similar lenses OU are inadequate, consider different OZDs or a mix of lens designs



8L2998211-203

### Fitting Centre-Near (C-N) Concentric Designs

Successful fitting of simultaneous vision concentric bifocal designs relies on good lens centration combined with a minimum amount of blink-induced lens movement. The acceptability of the latter needs to be assessed clinically.

Most C-N lenses have central zone diameters of less than 3 mm. For an apparent pupil of 4 mm and a lens optic zone of 3 mm (flat-plane projection used and the transition from the lens central zone to the adjacent zone is assumed to be infinitely narrow), decentrations greater than 0.87 mm leave less than half the pupil covered by the lens' central zone (slide 61). Assuming a C-N lens, near vision can be expected to be reduced by such a lens excursion. A zone diameter of 2.5 mm within a 4 mm pupil is always dominated by the surrounding zone because the central zone area is less than 50% of the pupil zone even when the lens is centred. Reduced VA can be expected regardless of the lens decentration (unless the zone is out of the pupil zone completely).

As the central zone of the lens is dedicated to near vision, the surrounding lens area provides the distance correction. It is possible to vary the diameter of the near zone to optimize the quality of vision at both distances. However, as the size of the pupil varies with the level of ambient light, the visual performance at either distance or near can be compromised.

This has been confirmed by Jones and Lowther (1989), who found that larger (3 to 3.5 mm diameter) C-N zones improved near vision at the expense of distance vision and *vice versa*. Somewhat surprisingly, they found little correlation between zone size and pupil size with respect to VA.

If a range of near zone sizes is available, it is possible to fit a lens to the non-dominant eye with a larger near diameter, thereby providing better near vision.

If a C-N concentric design fitted bilaterally proves to be ineffective or sub-optimal, the practitioner can adopt a modified monovision approach and fit the dominant eye with a lens design that provides better distance vision. Subsequently, the near zone diameter of the C-N lens on the non-dominant eye can be optimized to provide the best possible near vision.

Pupil size is an important variable in the determination of the quality of vision achieved with simultaneous vision lenses. A qualitative estimate of the lens' functional 'segment' size relative to the pupil diameter can be obtained by using an ophthalmoscope focused on the plane of the pupil at a working distance of about 50 cm. This provides an estimation of how much of the pupil is being covered by the 'segment'.

When assessing the performance of the contact lens segment size (which may or may not be customizable), it is important to simulate the lighting level of the patient's normal working environment. This is often difficult to do. Usually, the best option is to assess the performance of the lens after a period of trial wear in the intended environment.

It is unwise to use a refractor head (phoropter) when determining distance and near visual acuities because the pupil diameter can increase as a result of a significant reduction in the ambient light level reaching the eye due to obstruction of light by the instrument.

Patients prescribed concentric (simultaneous) vision lenses should be advised that their vision might vary with the ambient light level. In bright light, a C-N wearer may experience a reduction in distance vision quality (little of the distance zone within the reduced entrance pupil) while their near vision may be impaired by low light levels (distance and near zones within the enlarged entrance pupil).

Concentric bifocal lens wearers may also complain of the presence of 'double' images in their field of vision.


One of the better known hydrogel C-N bifocals is the Alges (now Simuvue) Bifocal.

69

**CENTRE DISTANCE  
ALTERNATING CONCENTRIC  
FITTING PROCEDURE**

- Centred fit
- Modified monovision approach
  - dominant eye segment 0.5mm > pupil diameter
  - non-dominant eye 0.5mm < pupil diameter
  - some translation on downward gaze required
- If difficulties arise, revert to monovision

998211-39



8L2998211-39

**Fitting Centre-Distance Concentric Designs**

Although C-D concentric designs, like C-N concentric designs, rely on optimal lens centration in primary gaze, they also perform better at near if the lens translates on the eye as the wearer looks down to read (Edwards, 1999).

Because SCLs move minimally, inadequate SCL translation leaves the distance Rx dominating the pupil zone and near vision may not reach satisfactory levels. Typically, a larger distance zone is prescribed for the dominant eye.


A *multi-zone* concentric design reduces the dependence on pupil size somewhat, especially in relation to differing lighting conditions.

70

**SIMULTANEOUS VISION  
C-D DESIGNS**

- Generally poor NV
  - low illumination favours near vision
  - high illumination favours distance vision
  - some translation (minimal with SCLs) during inferior gaze will benefit near vision

998211-40



8L2998211-40


Generally, multi-zone C-D designs alternate distance and near powered zones where the spacing of the zones is based on the variation of pupil zone in different lighting conditions.

Theoretically, the lens design favours distance vision in extremely high (mostly the C-D zone) and low (several zones within the entrance pupil) lighting conditions while providing an almost equal division of light between distance and near under conditions of average ambient illumination, e.g. the Acuvue Bifocal (see slide 61).

71

**USING A C-N WITH A C-D  
SIMULTANEOUS VISION BIFOCAL**

- Centre Distance (C-D) in dominant eye
- Centre Near (C-N) in non-dominant eye
- Can mix spherical and aspheric designs, and vary zone diameters, to optimize
- Can reverse if dominant task is at near or preferred by wearer
- Endeavours to capitalize on the advantages of:
  - lens type (RGP, hydrogel)
  - lens design (C-D, C-N, zone diameters, asphericity)



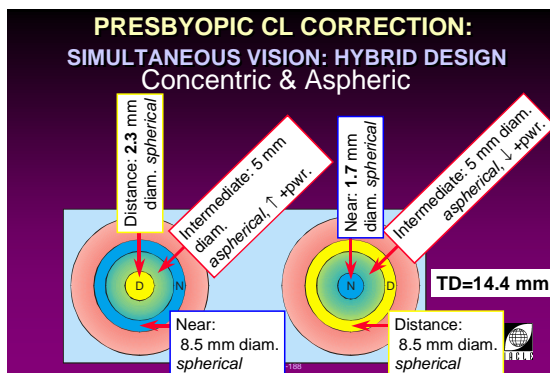
8L2998211-178

**Fitting a Centre-Distance and a Centre-Near**

A viable alternative is to use a combination of C-N and C-D lenses (e.g. UltraVue system, LifeStyle MV2 [see Hansen, 1999B]). In this way, each lens type can be employed for its particular advantages.

Further refinement may also be possible by varying the surface designs (aspheric *versus* spherical) and zone diameters (e.g. Balanced Progressive™ from CooperVision, slide 66). Usually, the dominant eye wears the C-D lens but this too can be changed according to individual circumstances or personal preferences.

72




8L2998211-187

73

**RIGID CONCENTRIC BIFOCALS**

- *Simultaneous* or *alternating* vision principle
- Simultaneous principle is method of choice
  - easier to fit
  - more easily modified (new lens may be required)
  - visual compromises likely



8L2998211-41

**RGP Concentric Bifocals**


Theoretically, concentric RGP bifocal contact lenses could be employed as either simultaneous vision or alternating vision lenses. However, the latter is more difficult if a back surface concentric design is used. The reasons for this include:

- The need for a larger central distance zone increases the chance of bubble formation (increased sagittal height of the local post-lens tear film).
- Fitting difficulties or alterations to corneal shape may occur (atypical back surface shape).

74

**RGP CONCENTRIC BIFOCALS**

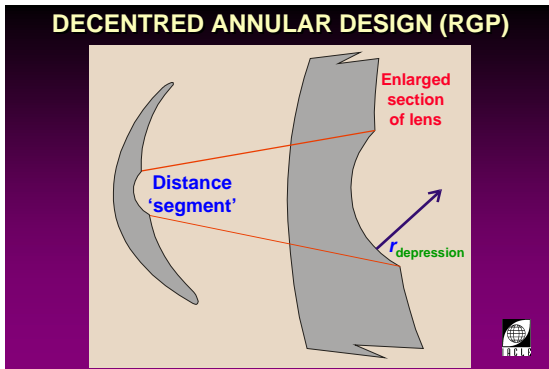
- Centre distance power zone, annular add
  - back surface concentric bifocal (De Carle)
  - front surface concentric
- Reverse Centrad Bifocal
  - centre near add, annular distance Rx
  - fused from plastics of two different refractive indices (e.g. RGP & PMMA)
  - one piece (RGP)



8L2998211-42

The decentred (rotationally asymmetric) de Carle bifocal (slide 69) is an annular design in which two power zones are created within the posterior optical zone using two different curvatures. The distance zone curvature is made steeper than the near zone. Although this makes a more positive tear lens locally, the contact lens itself is more negative over the same area because the refractive index of the lens material is significantly greater than that of the tears. The net effect of the lens-tear lens combination in this region is an increase in overall minus power. By a judicious choice of zone curvature, a full distance correction is available within this zone.

75



8L2998211-111

The centre distance zone is made small enough for the pupil zone to be covered by it only partially, allowing a portion of the near zone (the lens periphery) to remain within the pupillary area at all times. The average distance segment diameter is 4.0 mm (Hansen, 1996).

De Carle-type decentred annular lenses are relatively thin and usually require no more than 1.5<sup>Δ</sup> base-down prism to orient correctly. Lens diameter (TD) is determined by the palpebral aperture size (PAS). Typically, a truncation of 0.3 mm on a 9.4 mm diameter lens (horizontal: 9.4 mm, vertical: 9.1 mm) provides adequate resistance to lens rotation. An optical zone diameter of 8.0 mm is recommended. The *distance* optical zone is represented within this optical zone.

76

**DECENTRED ANNULAR DESIGN (RGP)**

Light → Distance 'add' = -1.50 D (for example)

Material = tisilfocon A,  $n = 1.44$

$F = \frac{n' - n}{r}$

$-1.50 = \frac{1.336 - 1.44}{r_{depression}}$

$r_{depression} = +6.93 \text{ mm}$

$n_{lens} = 1.44$     $n_{tears} = 1.336$

8L2998211-112

For such a design to work satisfactorily, a sufficient area of the near zone must fall within the entrance pupil when reading. This may require a degree of lens translation.

*How practical is this lens design?*

This lens type is not common, especially in modern RGP materials for reasons that will become obvious. Calculating the Distance Zone (the back-surface 'depression') radius for a material with a refractive index of 1.44 (e.g. tisilfocon A):

$$F_{add} = \frac{n' - n}{r}$$

$$-1.50 = \frac{1.336 - 1.44}{r}$$

$$r_{depression} = \frac{0.104}{-1.50}$$

$$r_{depression} = 6.93 \text{ mm}$$

However, if a material with a lower  $n$  is chosen, e.g. hexafocon A,  $n = 1.415$

$$r_{depression} = 5.27 \text{ mm}$$

The latter represents a relatively steep back surface curve and a greater post-lens tear film thickness. If the distance 'add' needs to be higher (greater reading add present over the rest of the optical zone) this curvature will be even steeper. Bubbling in and/or corneal curvature changes from the depression may result, especially if a relatively large zone diameter (>4 mm) is required (a greater sagittal height results).

77

**DECENTRED ANNULAR DESIGN (RGP)**

Light → What if the lens material has a low  $n$ , e.g. hexafocon A,  $n = 1.415$ ?

Distance 'add' = -1.50 D

$-1.50 = \frac{1.336 - 1.415}{r_{depression}}$

$r_{depression} = +5.27 \text{ mm}$

$n_{lens} = 1.415$     $n_{tears} = 1.336$

8L2998211-113



78

### RGP CONCENTRIC BIFOCALS FITTING

- Simultaneous vision
  - fit to minimize lens movement
  - good centration needed
- Central distance power zone is made smaller than entrance pupil in normal illumination
  - approximately 3.0 mm



8L2998211-43

79

### RGP CONCENTRIC DESIGNS FITTING

- Alternating vision
  - better with a front surface design
  - lower lid properties are important
    - moves lens ↑ when looking ↓ for near
  - careful selection of zone diameters
  - works best with small pupils



8L2998211-92

### Fitting RGP Concentric Bifocals

When using simultaneous vision RGP concentric bifocal lenses, it is important that they centre well and exhibit a minimum amount of movement with each blink. Ideally, the lens should rest just above the corneal centre. Such characteristics can be achieved by fitting the lens:

- Larger than usual.
- With a slightly steeper BOZR.
- Slightly thinner.

The diameter of the central distance zone is dependent primarily on the pupil diameter. On average, the central zone is 3.0 mm in diameter. However, the selection of central zone diameter should be based on the pupil diameter in reduced illumination. This is often larger than 3.0 mm.

Steps need to be taken to ensure that the lenses are comfortable.

Back surface concentric RGP bifocals are an uncommon clinical option. This is due at least in part to the finding that alternating vision, RGP, concentric, bifocal lenses generally work better with a front surface design. In this design, the lens must move up when the direction of gaze moves down from the primary (distance) gaze position to view near objects.

80

### RGP CONCENTRIC BIFOCALS FITTING

- Advantages
  - easy to fit
  - good physiology under lens (high  $Dk/t$ )
- Disadvantages
  - ghost images possible (especially at night)
  - pupil size dependent
  - some discomfort (typical of an RGP lens)



8L2998211-44

### Advantages and Disadvantages of RGP Concentric Bifocals

The primary advantages of concentric RGP bifocal lenses are their ease of fit and the high level of oxygen transmissibility that is available with all modern RGP materials.

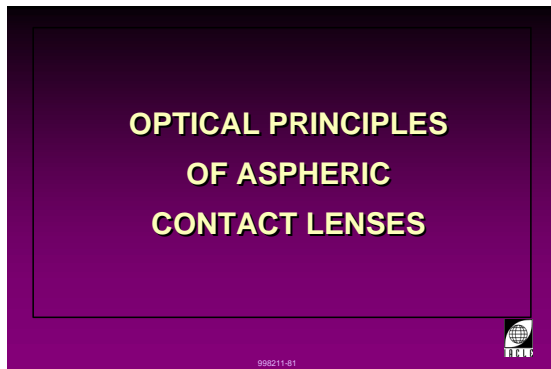
Visual problems can be experienced with concentric bifocal contact lenses if the eye's entrance pupil size exceeds the lens' central optic zone diameter, as is likely in low light levels. The problem may be described as the presence of ghost images around objects.

Initial discomfort typically associated with RGP lenses is also a disadvantage of these bifocal lenses.



III.A Aspheric Simultaneous Vision Bifocals

81



8L2998211-47

**Principles of Aspheric Simultaneous Vision Bifocals**

These lenses make use of either a front or back surface aspheric design. The type of aspheric surface is determined by the degree of departure from a spherical curve. This is referred to as the surface's eccentricity value ( $e$ ) (see slide 76). The  $e$  value is related to the shape factor ( $p$ ) value by the following equation:

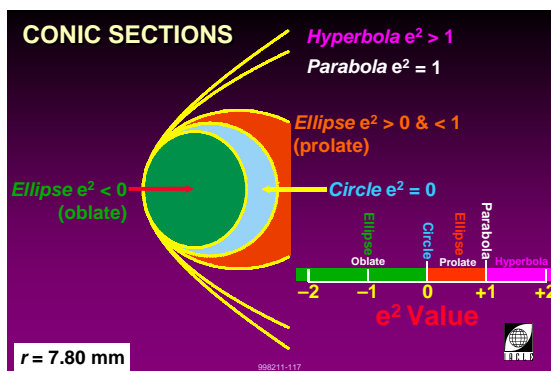
$$p = 1 - e^2$$

(See Lindsay *et al.*, 1998 for further details of conic sections). To avoid 'difficulties', e.g. square roots of negative numbers, it is sometimes more convenient to deal with  $e^2$  as is done in the following.

- $e^2 < 0$  [i.e. a negative value] is an ellipse (oblate presentation) ( $p > 1$ ).
- $e^2 = 0$  is a circle ( $p = 1$ ).
- $e^2 > 0$  &  $< 1$  is an ellipse (prolate presentation) ( $p > 0$  &  $< 1$ ).
- $e^2 = 1$  is a parabola ( $p = 0$ ).
- $e^2 > 1$  is a hyperbola ( $p = < 0$ , i.e. negative).

Although these lenses are not a true bifocal design (more PAL-like in reality), they provide an increased depth of focus at the retina and hence an increased depth of field that increases the near range for the wearer. Such lenses also increase the size of the circle of least confusion at or near the retina that can affect VA adversely if the addition is much greater than about +1.00 D.

82



8L2998211-117

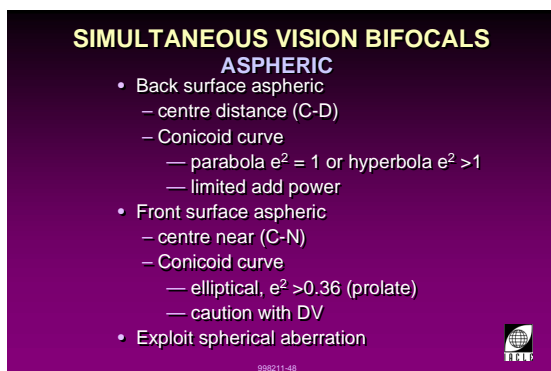
Low-add power lenses are often successful because they do not induce marked secondary or ghost images to disturb vision. They also offer an option for a modified monovision fitting approach.

A posterior aspheric surface that is progressively flatter toward the periphery produces a PAL lens with distance power in the centre (C-D) progressing to the reading portion away from the centre. The outer portion of the optical zone has the maximum reading addition.

Conversely, an anterior aspheric surface produces a PAL lens with near power in the centre (C-N). This lens design is the most common in SCLs. It is difficult to execute in RGP materials because of a reliance on lathing to fabricate lenses.

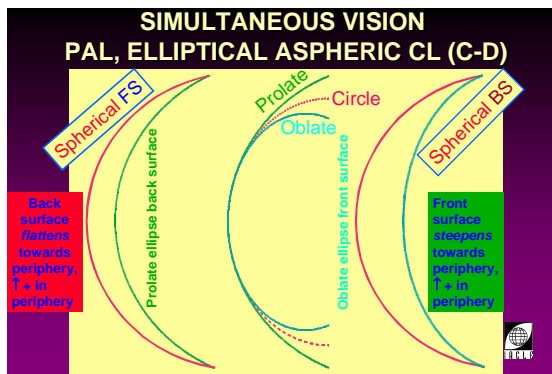
Front surface aspheric, C-N bifocals are the most common (in soft materials). The rate of power change away from the centre of the lens depends on the reading addition and the pupil size, the latter being affected by fixation distance, light levels, etc. Back surface bifocals typically offer limited reading adds and are, therefore, better suited to the early presbyope (up to about 1.50 D). Attempts to alter the asphericity to achieve higher adds can cause a reduction in distance acuity. However, multiple aspherics can achieve higher adds without a deleterious effect on distance vision (Edwards, 1999).

83



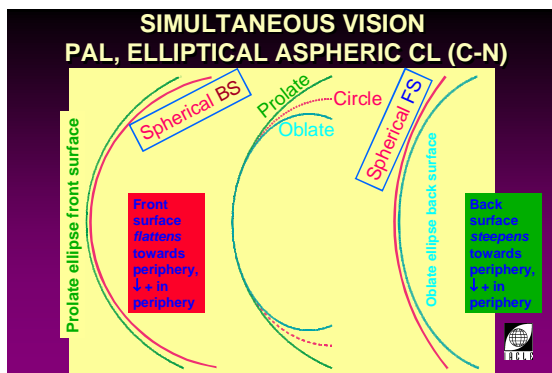
8L2998211-48

84



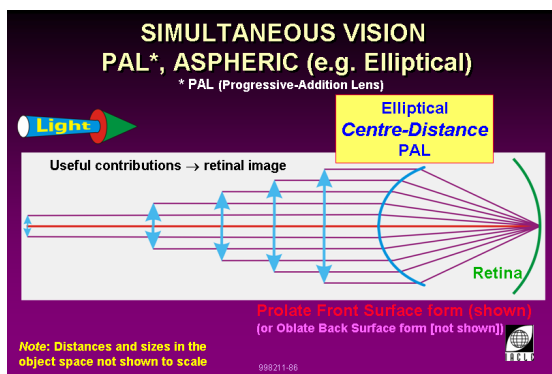
8L2998211-115

85



8L2998211-118

86



8L2998211-114

87

**SIMULTANEOUS VISION BIFOCALS ASPHERIC**

- Exploit aberrations
  - use spherical aberration to produce 'add'
  - generally one surface is spherical
  - less effective in high adds? (difficult to configure for high adds)
  - centration important
  - most designs ignore corneal topography and lens BVP
  - other aberrations may be increased, e.g. peripheral astigmatism

8L2998211-46

Lens developments have shown that increased eccentricities can lead to significant increases in peripheral astigmatism. More sophisticated (often more complex) curvatures are required to overcome such disadvantages.

As with all presbyopic contact lens options, trial lenses should be used to evaluate the fitting of the aspheric lens. This also enables the practitioner to determine the quality of vision that is likely to be achieved at both distance and near.


When labelling C-N, aspheric, PAL SCLs, data can be presented in two ways:

- The add power can be added to the distance Rx, therefore, only a single power appears on the vial label.
- The lens can be labelled with the distance power and the add power is either:
  - assumed (usually about +1.50 D);
  - labelled as either *high* or *low*;
  - given as profile A or B.

88

**RIGID ASPHERIC BIFOCALS DESIGN**

- Back surface aspherics
  - prolate ellipse usually centre-distance (C-D) [see slide 84]
- Front surface aspherics
  - oblate ellipse if centre-distance (C-D) [slide 84]
  - too difficult to make, therefore usually centre-near (C-N) [slide 85]




8L2998211-45

89

**RIGID ASPHERIC BIFOCALS DESIGN**

- Quasi aspherics, i.e. not a single curve design
  - spherical apical zone + aspheric periphery
- $e^2$  values used from 0.5 to 2.2
- Larger the  $e^2$  value, the greater the peripheral flattening and the greater the add power
  - usually, maximum is +1.50 D add




8L2998211-75

90

**RGP ASPHERIC BIFOCALS MODIFYING LENS FITTING**

- Need to fit *steep* to obtain required asphericity peripherally
- On an identical eye for an add of +1.75D
  - spherical fit of  
7.75 (p=1.0) 9.60/-4.25
  - becomes  
7.35 (p = 0.1) 9.60/-6.60




8L2998211-51

91

**RGP ASPHERIC BIFOCALS FITTING**

- Need to take account of:
  - corneal topography
  - Rx
  - add
  - power of tear 'lens'
  - lens/tear/corneal aberrations



8L2998211-49

**Aspheric RGP Bifocal Contact Lenses**

An RGP lens with a back surface that is aspheric (e.g. a prolate ellipse) produces a PAL lens with the distance correction in the centre progressing peripherally to a near vision zone. The most peripheral part of the optical area has the greatest reading addition.

In RGP lenses, any significant departure from the normal geometry of the back surface to accommodate optical requirements, e.g. increasing the asphericity, will have an impact on the fitting characteristics. These lenses are generally fitted significantly steeper than the cornea to produce the graduated intermediate and near vision zones.

The higher the eccentricity, the greater is the power variation (from centre to periphery) and, therefore, the greater is the available reading 'add' (slides 78 and 79).

**Fitting Rigid Aspheric Bifocals**

Lenses with back surface aspheres of high eccentricity result in significant peripheral flattening necessitating steeper than central corneal fitting to achieve good centration and movement.

Usually, an aspheric back surface requires an apical clearance fit steeper than would be acceptable normally. This is necessary to prevent the periphery of the lens standing off the cornea excessively, a fitting philosophy that can result in discomfort and unstable centration and movement.

Because the back surface flattens rapidly from the lens apex, a small zone of central clearance appears in the fluorescein pattern.

92

### RGP ASPHERIC BIFOCALS FITTING

- Fit steeper than flattest K by 1.5 to 3.5 D
  - to get peripheral 'add'
- Must use diagnostic lenses
- Over-refract
- Fluorescein pattern
  - central pooling
  - intermediate bearing
  - peripheral clearance (must not be excessive)



8L2998211-50

If an aspheric front surface RGP bifocal lenses is available, the back surface conforms to normal geometry. Consequently, no compromises in the fitting characteristics of the lens are required.

To ensure stable quality vision for distance and near, a well-centred lens that is not excessively mobile is usually required. The lens should move sufficiently on downgaze to allow the lens to locate at least some of its near power zone over the pupil. An exception may be lenses that are designed to decentre upwards under the top lid to facilitate an effective reading addition.

In some back surface aspheric RGP designs, the rapid rate of peripheral flattening may require the lens to be fitted significantly steeper than the central cornea for the reading add to be effective and an acceptable peripheral fit to be realized.

For distance vision not to be compromised by the peripheral add power in aspheric RGP designs, lens decentration, especially inferiorly, should not exceed 1 mm. In some cases, some superior decentration may be acceptable.

93

### RGP ASPHERIC BIFOCALS FITTING

- Good centration is essential
- Decentration causes:
  - fluctuating vision at distance
  - possibly discomfort from:
    - excessive edge clearance
    - excessive movement
- Minimum acceptable movement is desired



8L2998211-106

94

### RGP ASPHERIC BIFOCAL FITTING PROBLEMS

- Inferior decentration
  - steeper BOZR to increase tear volume
  - flatter BOZR to increase lid attachment
  - larger diameter
  - minus carrier for plus and low minus powers



8L2998211-97

### Fitting Problems with Aspheric RGP Bifocals

Any decentration of an aspheric bifocal lens is likely to result in poor vision. Steps must be taken to optimize the quality of centration when a lens is riding either excessively low or high on the cornea.

Excessive movement is likely to cause irritation and variable vision.

In C-D, back surface aspheres, as the add power increases (by increasing the back surface eccentricity, i.e. increasing the flattening rate), the BOZD in effect decreases. Thus, when switching to an increased add power, the BOZR must be steepened (shortened) to compensate for this effect if the same fitting relationship is to be maintained. Further, suitable compensation must also be made to the front surface curvature if the distance Rx is to be correct.

95

### RGP ASPHERIC BIFOCAL FITTING PROBLEMS

- Superior decentration (excessive)
  - steeper BOZR
  - add prism ballast
  - thin edge design
    - lenticulating high minus lenses
    - anterior bevel




8L2998211-98

96

**RIGID ASPHERIC BIFOCALS ADVANTAGES**

- Easy to fit
- Good vision at all distances
- Corrects corneal astigmatism



8L2998211-52


**Advantages of Rigid Aspheric Bifocals**

Multiple aspheric curves with differing eccentricities can be used to enhance the reading addition without reducing distance acuity. This cannot be achieved with SCLs.

97

**RIGID ASPHERIC BIFOCALS DISADVANTAGES**

- Corneal molding
  - spectacle blur
- Oedema with low Dk/t lenses
- High adds impossible
  - to increase the add somewhat in C-D, back-surface aspheres, the front surface can also be made aspheric to gain +0.50 to +0.75 D more
- Dependent on pupil size



8L2998211-53

**Disadvantages of Rigid Aspheric Bifocals**

Excessive decentration may result in:

- lens adherence;
- poor vision;
- changes in corneal topography.

Excessive lens decentration compromises vision as the power of the lens over the pupil is inappropriate for distance vision.


When a patient wearing a C-D aspheric RGP lens has a small pupil diameter, it is likely to limit the effectiveness of the peripheral reading addition. As a result, the distance vision is likely to be good or better while the near vision is compromised.

Conversely, with a C-N design, a small pupil restricts vision to the near correcting central region of the lens, thereby enhancing near vision at the expense of good distance vision.

98

**ASPHERIC SOFT LENS FITTING**

- To ascertain effectiveness, trial lens must have BVP close to final Rx
- Decide on DV/NV requirement
  - Good distance vision
    - C-D both eyes
  - Good near vision
    - C-N both eyes
  - Compromise
    - modified monovision



8L2998211-54

**Fitting Soft Aspheric Bifocals**

As with any presbyopic correction (spectacle or contact lens), it is important for the practitioner to evaluate the vision needs of the patient carefully before fitting aspheric soft bifocal contact lenses. The practitioner has the option of fitting C-N or C-D lenses bilaterally, or using a combination of these, i.e. modified monovision.

Back surface aspheric soft lenses are best suited to early to moderate presbyopes as they offer only limited reading adds.

Should a SCL aspheric fit result in significant irregular lens deformation, unexpected power changes across the lens may not occur. Such an outcome may be the result of a poor lens to cornea fitting relationship. Where appropriate or possible, a different lens BOZR should be trialled.


Good lens centration and minimal movement are vital to the success of aspheric lenses for the presbyope. Excessive post-blink movement usually results in variable/fluctuating vision.



99

**ASPHERIC SOFT LENS FITTING**

- Centration vital (for all simultaneous vision lenses)
- Good fit vital
  - aspheric properties change with poor fit
- Allow adaptation / settling



8L2998211-55


Since lenses generally have pre-determined zones of distance and near power, i.e. few options exist, the size of the wearer's pupil will be critical to the success of most lenses. Large pupils result in reduced vision because multiple Rx's are within the pupil zone all the time.

In C-D designs, the smaller the pupil the better will be the distance acuity but the poorer will be the near vision. With large pupils, more light enters the pupil through the lens periphery (near correction) and near VA is likely to be improved at the expense of distance vision. In C-N aspheric design bifocals, the reverse is likely to be true.

100

**ASPHERIC SOFT LENS FITTING**

- No account of individual aberrations
- Check refractive end point
- Use binocular viewing conditions
- No evidence that it is more successful than monovision



8L2998211-56

As with most simultaneous vision lens designs, the effect of the reading addition is pupil-size dependent. If the pupil size changes, so too does the relative balance of distance and near corrections. Therefore, a lens that works well in the consulting room may not be as effective in other environments in which lighting levels differs significantly.

**III.B Diffractive Bifocals**

101

**DIFFRACTIVE BIFOCAL DESIGN**



8L2998211-60

**Diffractive Bifocal Design**

This section assumes a basic knowledge of diffraction based on Huygen's Principle (wave theory of light) and the concepts of secondary wavelets and the wave-fronts these form (see Longhurst, 1973; Klein and Furtak, 1986; Meyer-Arendt, 1995).

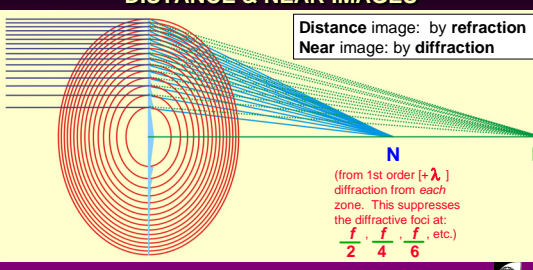
A diffractive bifocal (sometimes called a holographic bifocal, see Loshin, 1989) is a simultaneous vision (slides 102, 103) contact lens consisting of several zones of progressively increasing size arranged concentrically. Each diameter is  $\sqrt{N}$  times the central zone's diameter but the zone widths get progressively smaller – N is the zone number. All of the len's diffractive ('optic') zone is used to form both distance and near images making the design largely independent of pupil (entrance pupil) size (after Cohen and Cohen, 1989).

The design can trace its origins to Fresnel zone plates (slide 111). However, instead of dealing with half wavelength differences, whole wavelength differences are involved (slide 107) so that constructive interference can occur at the near focus formed by first (1st) order diffraction (slides 108 and 110). Conceptually, whole wavelength differences can be considered to be the result of the amalgamation of two adjacent Fresnel half-plate zones (the traditional optical presentation of zone plates) into a single, full-wavelength zone. Each


102

**DIFFRACTIVE BIFOCAL DISTANCE & NEAR IMAGES**

Distance image: by refraction  
Near image: by diffraction




ASMMETRICAL PHASE ZONE PLATE



8L2998211-168

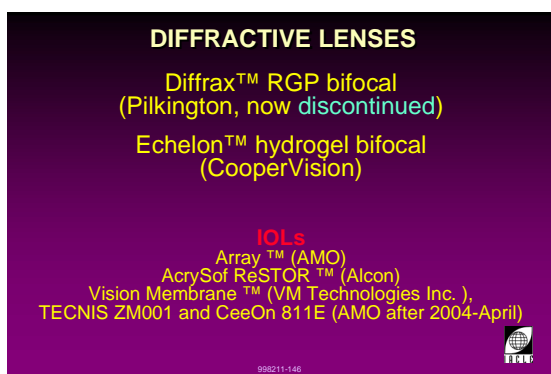


103



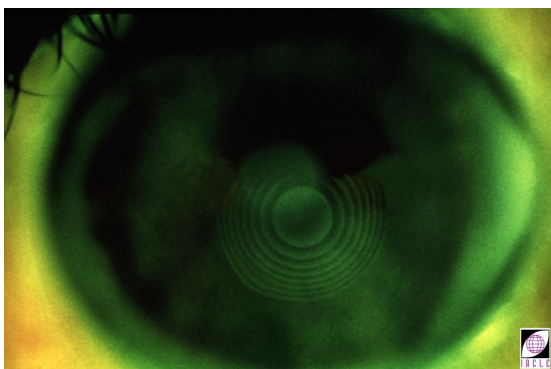
8L2998211-153

104




8L2998211-146

105



8L20897-94

106



8L20831-91

subsequent zone is one whole wavelength further removed from the 'focus' (slide 110) (see Appendix to Atchison *et al.*, 1992).

As blocking-off alternate zone (slide 111 shows the possible ways of doing this) is very light inefficient, the alternative, (slides 111 to 115) patented by Freeman (but based on the 1923 phase zone plate of Wood [Charman, 1986]) produces a phase shift equal to one wavelength across each zone\*, is much more light efficient, albeit with a loss of about 20% of incident light (Loshin, 1989).

\*[Inner, thicker edge gives zeroth (0th) order diffraction while the thinner, outer edge gives 1st order diffraction [slides 113 and 114] to produce the near focus, the phases of the rays traversing the zone between these extremes tend to reinforce [adjacent to the edges] or interfere destructively (near the centre of the zone)]. This means that each zone encompasses both even (inner ray) and odd (outer ray) orders of light. The term asymmetric is used to describe this lack of symmetry across *each* zone and the fact that each zone 'width' decreases the further the zones are located from the centre.

The distance Rx is formed largely by refraction (0th order diffraction, slides 118 and 124) while the near focus is formed by a modified asymmetrical zone phase plate (slides 112 to 114, 123 to 124), *each* zone of which contributes to the near image and varies from its inner neighbour by having its optical path length one wavelength [ $\lambda$ ] longer. In this way, the 1st order diffracted light at the point P remains in-phase and contributes to the brightness of the near image by constructive interference (see slides 108, 110, and 112) to form a near focus. If the rays were to arrive out of phase (slide 109), the image would not be as bright as the distance image (formed by refraction) because of destructive interference at point P.

Both rigid and soft versions have appeared in the past but only the soft version is still available (the OSI Echelon™).

Although the first diffractive bifocal contact lens patent was granted to Freeman in 1984 (Charman, 1986), the most relevant (full-zone, asymmetric phase control, diffractive back surface) patent was not granted until 1986 (Freeman and Stone, 1987). The resulting lens was the Pilkington Diffrax™ RGP bifocal (now discontinued, it was made in silafocon A, a relatively low Dk siloxane acrylate material) that incorporated a holographic phase plate 5 mm in diameter on its central back surface.


This lens was not distributed widely, was difficult and expensive to manufacture (great precision was required), and was withdrawn after failing to reach commercial viability (after Walker and Hough, 1999).

The soft diffractive bifocal, based originally on the patents of Cohen (1993) (see slide 129), was developed by Allergan Hydron. However, because of optical and legal difficulties (see Hemenger and

107

### DIFFRACTION IN A CL CONTEXT WAVELENGTH DIFFERENCES

- When detailing *diffraction*, optics textbooks usually discuss phase differences of half a wavelength (i.e.  $\frac{\lambda}{2}$ )
  - $\therefore$  1<sup>st</sup> order diffraction involves  $+\frac{\lambda}{2}$
  - 2<sup>nd</sup> order involves  $+\lambda$ , 3<sup>rd</sup> order:  $+\frac{3\lambda}{2}$ , etc.
- In the context of *diffraction* here (CLs), whole wavelengths are used, i.e.  $\lambda$ 
  - $\therefore$  1<sup>st</sup> order diffraction involves  $+\lambda$
  - 2<sup>nd</sup> order involves  $+2\lambda$ , 3<sup>rd</sup>  $+3\lambda$ , etc.



98211-107

8L2998211-169

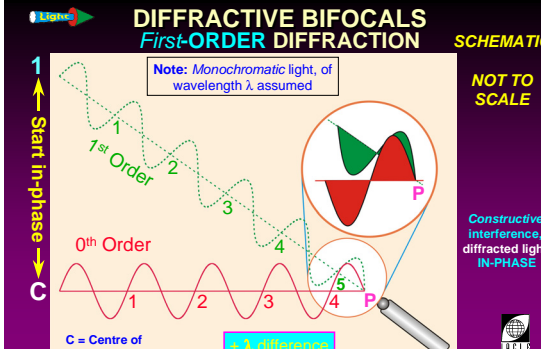
108

### DIFFRACTIVE BIFOCALS First-ORDER DIFFRACTION

SCHEMATIC

NOT TO SCALE

Note: Monochromatic light, of wavelength  $\lambda$  assumed



C = Centre of diffractive lens

$\frac{\lambda}{2}$  difference

Constructive interference: diffracted light IN-PHASE

IACLE

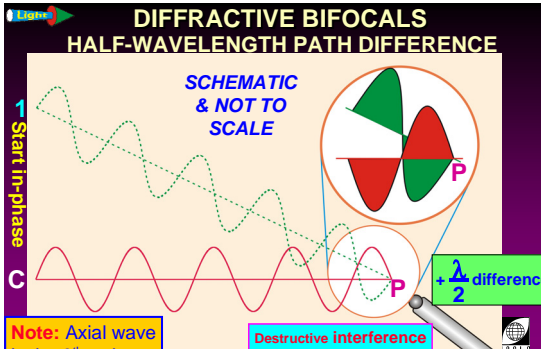
8L2998211-155

109

### DIFFRACTIVE BIFOCALS HALF-WAVELENGTH PATH DIFFERENCE

SCHEMATIC & NOT TO SCALE

Note: Axial wave is the 0<sup>th</sup> order



Destructive interference OUT-of-PHASE

$\frac{\lambda}{2}$  difference

IACLE

8L2998211-171

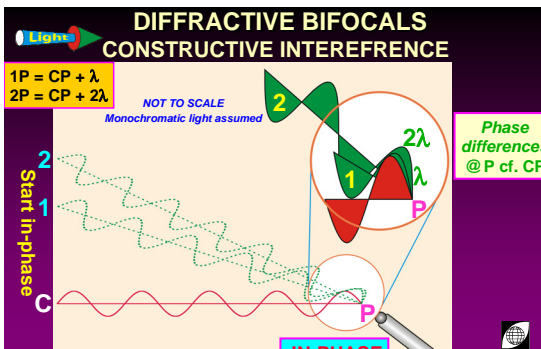
110

### DIFFRACTIVE BIFOCALS CONSTRUCTIVE INTERFERENCE

1P = CP +  $\lambda$   
2P = CP +  $2\lambda$

NOT TO SCALE  
Monochromatic light assumed

Phase differences @ P cf. CP



IN-PHASE

IACLE

8L2998211-182

Tomlinson, 1990) the product that reached the market (Echelon™, slide 105 *in vivo*, slide 106 *in vitro*) is very similar optically to the Freeman-developed Diffrax™ product.

Diffractive lenses can be produced by cast-molding with the concentric diffractive zones on the back surface (Cohen, 1984) and there are few reasons why the same process cannot be applied to RGP lenses as well. Freeman mentions electro-formed molds and single-point diamond turning as possible manufacturing methods for diffractive RGPs (Freeman and Stone, 1987).

An interferometric study by Woods (1995) showed some differences in the profile of the zone surfaces on rigid and soft diffractive bifocal contact lenses. RGP zones showed a constant curvature across their surfaces (i.e. between the transition steps at the edges of each zone) while the soft lens zones exhibited some variation of curvature across each zone. The ideal shape is parabolic (Emerton *et al.*, 1987 cited in Woods, 1995).

Although a full presentation of the relevant optics is not possible here (it would occupy too much space) a summary is included.

In a diffractive bifocal, a Fresnel zone plate creates a distance and near image by diffraction (slide 102), splitting the light equally between the two images but with some overall losses. The brightnesses calculated for the distance and near images are equal at 40.5% (Loshin, 1989, see slide 127 after Saunders, 1990; Hemenger and Tomlinson, 1990). The depth of the zone steps (called *echelettes*), typically only a few microns (all slides appearing here exaggerate the step size greatly), determines the light intensity at the two focal points, while changing the zone separation (zone width) alters the add power (slides 117 and 118 to 122).

In the soft form, only 7 to 9 (cf. slides 119 and 121) concentric, inclined facets (asymmetric phase plate *echelettes*) are molded into the back surface of the contact lens over a 4.5 mm 'optic' zone (Brenner, 1994) (slide 106 is a Contact Lens Optical Quality Analyser [CLOQA, a Foucault knife-edge tester] image of an Echelon bifocal).

Since the elements of the diffraction grating are small, the balance between distance and near is maintained over a wide range of pupil sizes. Pupil dependency only really occurs with truly miotic pupils or when entrance pupil diameters are greater than 5 mm 'optic' zone (after Edwards, 1999).

A claimed advantage of diffractive bifocals is that they do not divide the lens into two small, discrete zones as happens with conventional (refractive) concentric designs. Consequently, the image formed at the retina (slide 103) consists of focused images and blur circles [from objects out of focus] formed by the whole of the lens' optical zone, i.e. diffractive bifocals superimpose high-resolution focused images (slide 103 and 128) on dim and diffuse blur circles from out-of-focus objects.

111

**DIFFRACTIVE BIFOCAL DERIVATION**

Zone diameters are related by  $\sqrt{N}$ , i.e.  $D_{Zone N} = \sqrt{N} \times D_{Zone 1}$

**Fresnel Zone Plate**  
Flat  
Opaque alternate zones  
Complementary pair shown

Light inefficient

**Echelon Zone Plate**  
Alternate zones have altered thickness & profiles to control the light's phase

Light efficient

998211-158

8L2998211-158

112

**ECHOLON ZONE PLATE ASYMMETRICAL PHASE ZONE PLATE**

after: Freeman and Stone, 1987

$\lambda$  difference across each zone

Constructive interference @ near focus

998211-159

8L2998211-159

113

**ECHOLON ZONE PLATE DERIVATION OF THE ASYMMETRICAL PHASE PLATE**

Range of path length differences across each zone

Optical Path Length:  $AB = A'B' + \lambda$

Wood (1923) zone plate,  $\lambda$  difference across zone  
Symmetrical zone plate

998211-135

8L2998211-135

114

**ECHOLON ZONE PLATE ASYMMETRICAL PHASE ZONE PLATE**

after: Freeman and Stone, 1987

By design, the optical path length difference experienced by the extreme rays passing through each echelette is made to  $= \lambda$ . This compensates optically for the longer physical path the ray AB has to travel cf. A'B', i.e. the optical path length  $AB = [A'B' + \lambda]$ . Therefore, B and B' are in phase

Thickness & curvature exaggerated

Enlarged section

Note: Think of the echelon as an infinite series of parallel-sided optical retarders rather than as a prism

998211-136

8L2998211-136

However, the latter do act to reduce overall contrast sensitivity. The shallower depth-of-focus delivered by a diffractive bifocal (slide 128) helps reduce the retinal image confusion of simultaneous vision.

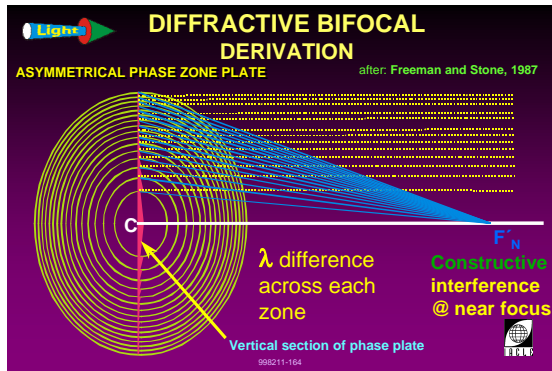
Over the years, the fact that the diffractive contact lenses available were not 'pure' applications of diffractive theory, i.e. they incorporate both refractive and diffractive components, led many to question whether they were in fact diffractive lenses at all or rather variations of a Fresnel lens (slide 111). The principal differences are:

- The number of zones [few in diffractive lenses].
- Step size [a few microns in the case of diffractive zones *versus* anything up to thousands of wavelengths in the case of Fresnel lenses, e.g. the Echelon steps are about 3  $\mu\text{m}$  (Atchison *et al.*, 1992)].
- Fresnel lenses do not attempt to control the phase of image-forming light rays whereas diffractive lenses are largely dependent on control of the phases of image-forming light rays.
- Diffractive optics results in chromatic aberration that is the opposite of refractive optics (slide 126). Diffractive optics bring longer wavelengths to a focus closer to the lens whereas a refractive lens focuses longer wavelengths further from the lens.

To examine the doubts surrounding these so-called diffractive contact lenses, Atchison *et al.* (1992) studied the optical properties of the Echelon lens and Atchison and Thibos (1993) studied the Diffrax lens and found that both lenses had the properties expected of diffractive lenses. They paid particular attention to the issues of 'reverse' chromatic aberration and measurable *versus* predicted lens powers.

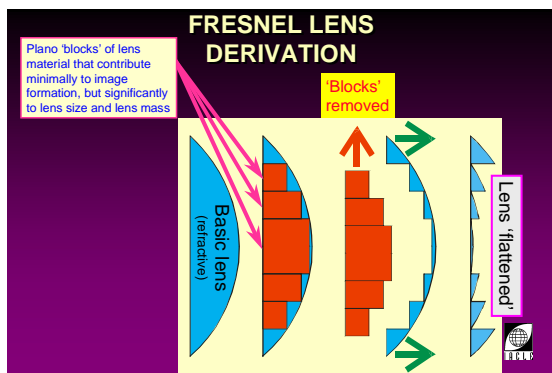
Although diffraction as an imaging-forming method appears to have fallen from favour in contact lens circles, the technique is used in several intraocular lenses available currently (see slide 104). Furthermore, there is the possibility that such lenses may be making a bid for success again as trials of various experimental refractive/diffractive (0th and 1st order?) bifocal contact lenses have been reported, e.g. Soni *et al.*, 2003.

115



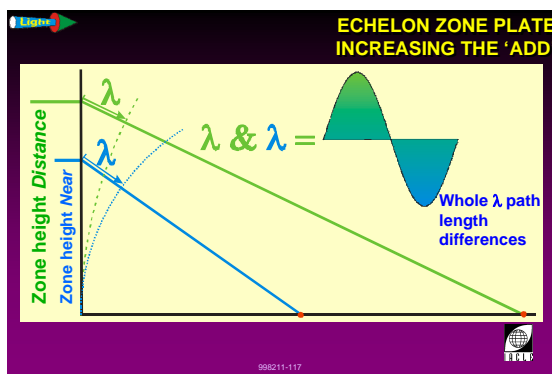
8L2998211-164

116



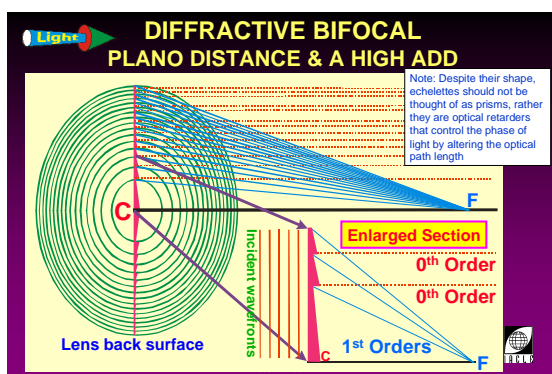
8L2998211-143

117



8L2998211-154

118



8L2998211-160



119

**ECHOLON ZONE PLATE**  
**INCREASING THE 'ADD'**  
 after: Freeman and Stone, 1987

Light →

'Optic' zone diameter (Note # of zones)

Once the diameters are decreased more rings (of progressively decreasing widths) are required to fill the 'optic' zone fully.

$f_{Zone} \propto r_{Zone}^2$

$f_{Zone} \approx \frac{r_{Zone}^2}{\#_{Zone} \times \lambda}$

$f_{Small\ diameter}$   
 $f_{Medium\ diameter}$   
 $f_{Large\ diameter}$

Note: Changing  $\lambda$  induces longitudinal chromatic aberration

8L2998211-140

120

**DIFFRAX™ LENS**  
**ZONES versus ADD POWER**  
 Bennett et al., 1990

ADD	# of Zones
• +1.00	• 6
• +1.50	• 8
• +2.00	• 11
• +2.50	• 14
• +3.00	• 17

8L2998211-172

121

**DIFFRACTIVE CONTACT LENSES**  
**ADDs (RGP LENSES)**  
 after: Freeman and Stone, 1987

5 mm

LOW MEDIUM HIGH

Optical zones only shown

8L2998211-149

122

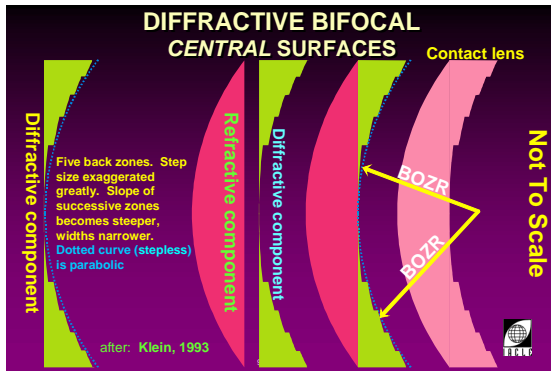
**DIFFRACTIVE CONTACT LENSES**  
**DIFFERENCES: HIGH & LOW ADDs**

Low High Low High

Enlarged central sections

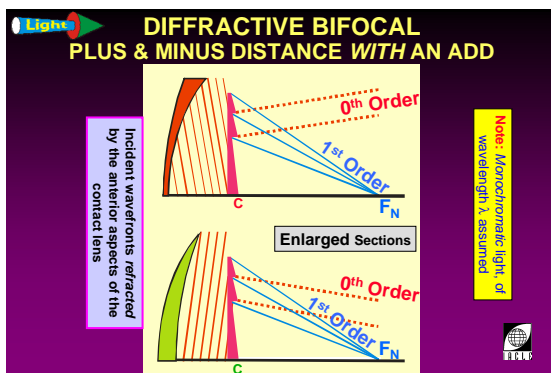
8L2998211-151

123



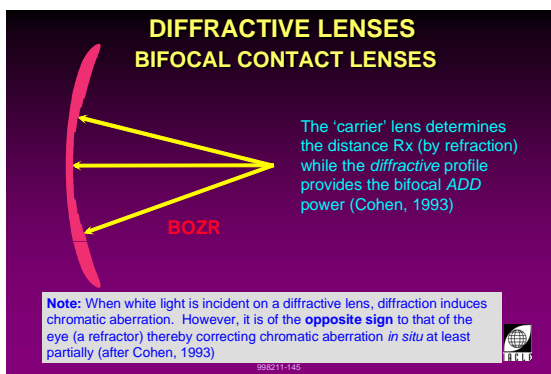
8L2998211-167

124



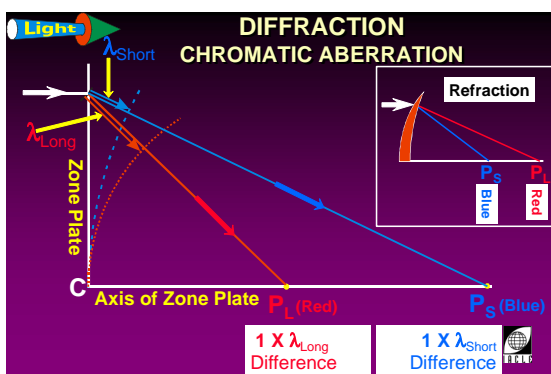
8L2998211-161

125



8L2998211-145

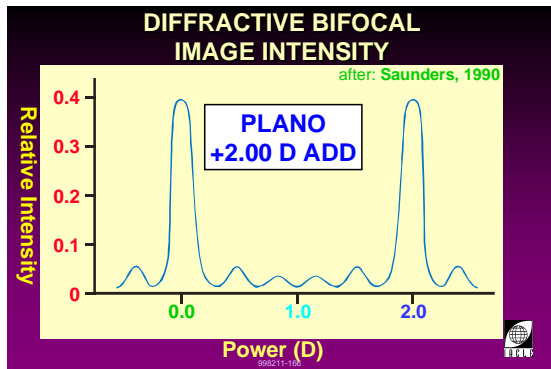
126



8L2998211-165

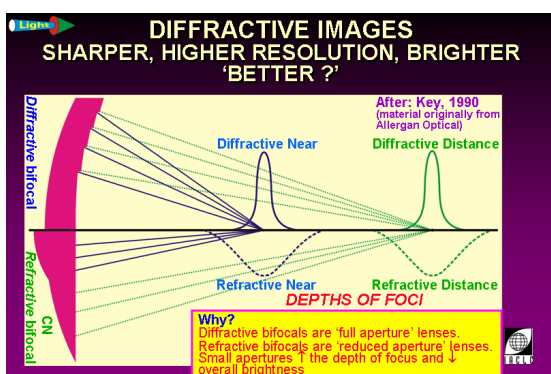


127



8L2998211-166

128



8L2998211-170

129

**DIFFRACTIVE CONTACT LENSES**  
**DIFFERENCES: Freeman vs. Cohen Patents**

- Freeman:
  - distance Rx by refraction (0<sup>th</sup> order) within all zones, near by diffraction (1<sup>st</sup> order) from all zones
  - more numerous zones
- Cohen:
  - alternating diffractive zones of D & N Rxs
  - fewer zones
- Although differences exist in the patents, the actual lenses produced (DiffraX [Freeman], Echelon [Cohen]) were similar optically (Hemenger & Tomlinson, 1990)

8L2998211-150

130

**DIFFRACTIVE LENSES ADVANTAGES**

- Usually, good acuity
- Simultaneous vision
- Easy to fit
- Pupil size has little effect on performance
  - approximately equal image brightness @ D & N
- Often, likely success determinable at fitting
- Usually performs well in moderate presbyopia
- Offers higher resolution and sharper images

8L2998211-147

**Advantages of Diffractive Bifocal Design**

One of the main theoretical advantages of a diffractive lens design is that good optical quality is achievable regardless of the pupil size. Conventional concentric bifocal designs encompass two lens powers within the pupil and, as the size of the pupil changes, the relative contribution of each component to the final retinal image varies. With a diffractive lens, all of the 'optical' zone directs light to its two focal points largely independent of pupil size.

Diffractive lenses are more suited to patients with moderate adds, small to medium pupil sizes, and a good tolerance of reduced contrast.

These lenses have a wide range of add powers and, as the optic zone size is fixed, they are relatively easy to fit. Furthermore, the likely visual outcome can be ascertained quickly.

131

### DIFFRACTIVE CONTACT LENSES DISADVANTAGES

- Reduced image contrast
- Simultaneous vision
- Poor VA in low illumination
  - 20% light loss (more light required?)
  - night driving more difficult
- Chromatic aberration
- Few parameters (& few manufacturers)
  - not available in toric form



8L2998211-59

### Disadvantages of Diffractive Bifocal Design

Vision can suffer from the problems of the distance and near images being superimposed, causing a reduction in image contrast, especially at near (Stone, 1988). Note that simultaneous vision appears in both the Advantages and Disadvantages presented here because of this. Sometimes, the size of the diffractive zone is too small for a particular wearer.

In diffractive lenses, the incident light is split between the distance and near images. Forty percent of the light goes to each of the distance and near images, and 20% is lost to higher order diffractive images, scatter, reflection, absorption, etc.

It is important for the diffractive zone to centre over the pupil. This can be ascertained easily with a slit-lamp using either white light or a cobalt blue light in combination with high molecular weight fluorescein.

Some degree of flare in low levels of illumination may also be reported. The reduction in image contrast (see Philips, 1988 for a comparison of the Modulation Transfer Functions of single vision and Diffrax lenses) is compounded by any uncorrected astigmatism. Patients with 0.75 D of cylinder or greater are not likely to be successful with a diffractive lens.

If some of the contact lens area outside the diffractive zone is within the wearer's entrance pupil, it is unlikely that the vision will be acceptable, especially at near.

It is important to realize that:

- Most wearers will not adapt to ghost images.
- Visual performance will not improve with further wear.

Generally, staining levels with the Diffrax RGP bifocal lenses were not significantly different from similar single vision lenses although some staining, as distinct from abrasions, was reported centrally (Walker and Churms, 1987). Freeman (in Freeman and Stone, 1987) pointed out that the echelette 'steps' were usually well below conventional lens manufacturing tolerances and frequently of a lower profile than many scratches on lens surfaces.

A 3-D effect (false stereopsis) was reported with the Diffrax lens when it was available (Rakow, 2001) as were occasional colour fringes around objects (Stone, 1988).

Lenses were also difficult to verify *in vitro* because of chromatic aberration, the existence of only an 'effective' BOZR (see slides 123 and 125), and the fact that the lenses only 'functioned' correctly optically (Stone, 1988) when in contact with a normal post-lens tear film, i.e. *in vivo*. The add power was probably best ascertained by counting the number of zones on the lens (see slide 120).

132

### DIFFRACTIVE LENSES DISADVANTAGES

- A false 3-D effect was reported by some wearers
- Some glare & ghosting (especially @ near)
  - ↓ contrast sensitivity
- Adaptation may take time (weeks, months)
- Difficult to make (great precision required)
- Made in low Dk materials only
- Must centre well
- Relatively small 'optic' zone size (5 mm)
- RGP version required steeper-than-K fitting
  - in some cases, Ks were altered by the lenses
  - sometimes lenses were difficult to remove



8L2998211-148

Usually, the trial fitting visual result with diffractive lenses is indicative of the likely long-term results. Diffractive lenses should not be dispensed if the wearer is unenthusiastic about their vision experienced during the trial phase.


Although intuition may suggest that the steps on the back surface of a lens may be a source of lens deposits, Ghormley (1990) reported that the hydrogel Echelon bifocal product was no more deposit prone than other lenses of similar age and that, generally, the echelette areas were less prone to deposition.

## IV Asymmetrical Lenses for Presbyopia

133

ASYMMETRICAL CL DESIGNS

- Segment incorporates the N Rx
- 'Carrier' portion has the D Rx
- Lens moves (translates) on the eye so that vision **alternates** between D & N predictably
- Fused and one-piece (solid) designs exist
- Rigid and soft (latter is uncommon)



8L2998211-61

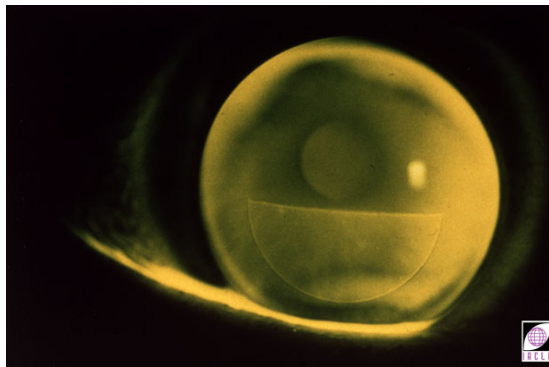
### Asymmetrical Bifocal Designs

These are bifocal RGP or soft lenses that incorporate a reading or near segment located eccentrically.

Such designs only function correctly if the lenses translate (move) on the cornea in such a way that the wearer views distance or near through the appropriate segment at the appropriate time.

To be effective, the contact lens must move upwards on the cornea when the eye looks down to view near objects or to read. Excessive or unstable lens movement with each blink, large pupils, or a near zone located too high can result in the near segment of the lens covering part of the pupil when distant objects are being viewed.

134




8L20445-92

### RGP Translation


As the design is rotationally asymmetric (slide 134), the lens must remain correctly oriented at all times to allow the appropriate transition from distance to near and *vice versa*, provided the appropriate translation occurs. Prism ballast of about 1.5 prism dioptres with or without an inferior truncation is used to achieve and maintain the correct lens orientation *in situ*.

135


BIFOCAL SEGMENT SHAPES



Two-Piece (Fused, Embedded, Implanted)



One-Piece (Solid)



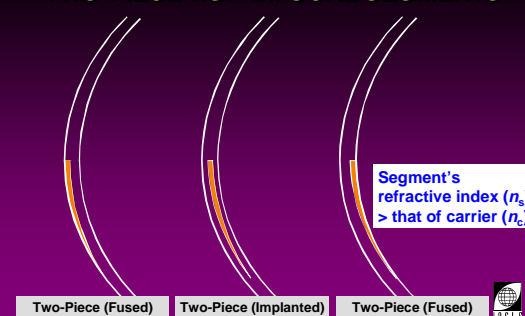
L2998211-179

Possible segment shapes are presented in slide 135, possible segment locations in slide 136, and desired segment positioning appear in slides 139 and 140. Although a common back surface curvature location allows the production of semi-finished lens blanks, a back location also means steeper 'depressions' (to overcome the increased minus power contributed by the segment-tear lens interface compared with the carrier-tear interface), and a 'depression' that is unique to each combination of add power and BOZR. This increases inventory sizes considerably.

Embedded (implanted or encapsulated) segment lenses with flat-top segments are designed to limit image jump, e.g. the FluoroPerm® ST (Edwards, 1999), and allow rational inventory sizes since the add does not vary with either the BOZR or the FOZR. However, minimum lens thickness is limited by the need to leave the segment surrounded by carrier material.

136

TWO-PIECE RGP BIFOCAL SEGMENTS




Segment's refractive index ( $n_s$ ) > that of carrier ( $n_c$ )

Two-Piece (Fused)  
(Common front curve)

Two-Piece (Implanted)  
(Embedded)

Two-Piece (Fused)  
(Common back curve)

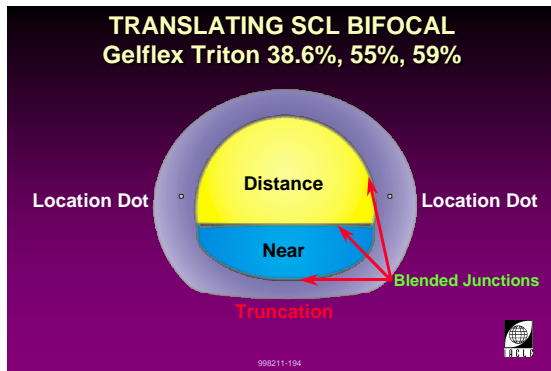


8L2998211-183

It is important that a trial lens set be used to determine the optimum design for alternating vision bifocal RGP lenses. Important parameters for the practitioner to consider when fitting these lenses include:

- Power of the near addition.
- Size and shape of the near segment.
- Height of the segment above the lower edge of the lens.
- Amount of prism ballast.

137



8L2998211-194

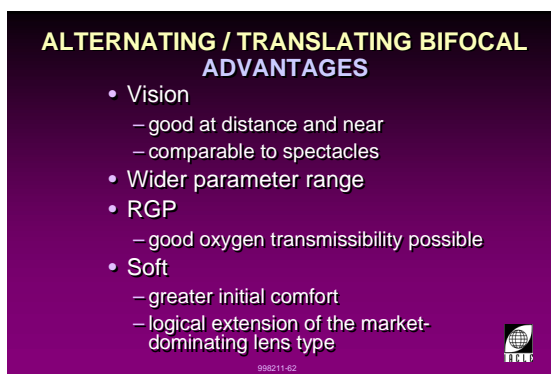
- Thickness of the lower lens edge.
- TD in the vertical meridian.
- Stability of the lens fit.

**SCL Translation**

Although several attempts at a translating soft bifocal or PAL have been made, none has achieved widespread acceptance to date. The most recent addition to this category is the Triton Bifocal (slide 131) from Gelflex Laboratories, Australia.

It is assumed that a mass market awaits a successful translating soft bifocal lens and the size of the potential market is expanding as the large so-called baby boomer generation is now spread across early to advanced presbyopia. Further, in most parts of the world, life expectancies are increasing.

138



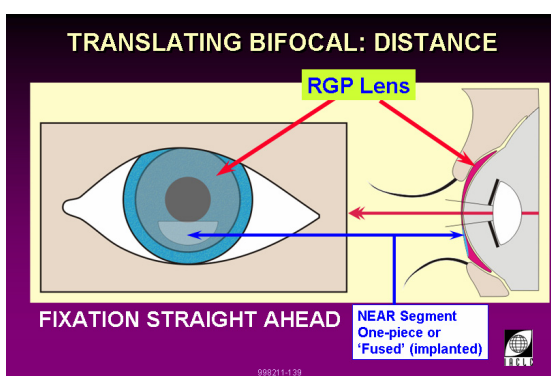
8L2998211-62

**Advantages of Alternating/Translating Bifocal Designs**

These lenses are suited to the following patients:

- Those requiring higher add powers.
- Those who require good stereopsis at both distance and near.
- Those whose tolerance of blur is poor.
- Simultaneous vision lens failures that remain highly motivated.

139



8L2998211-173

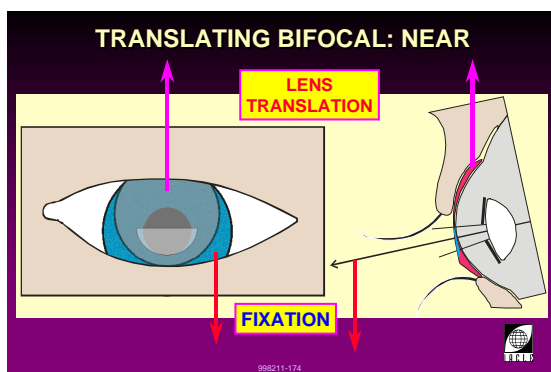
**RGP Lenses**

A primary advantage of the alternating vision RGP bifocal designs is the quality of vision that can be achieved at both distance and near when the correct zone of the lens is in front of the pupil (slides 134, 139, 140).

Usually, the lenses are custom-made and provide the practitioner with a wide variety of options for both front and back surfaces.

The high oxygen transmissibility of RGP lenses offers the wearer improved physiological performance when compared with conventional hydrogel bifocal contact lenses.

140



8L2998211-174

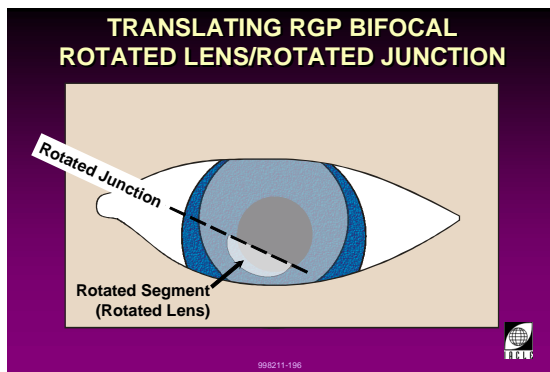
**Soft Lenses**

To date the greatest barrier to soft translating bifocal success has been a failure to achieve adequate translation, adequate comfort, or both. To achieve adequate translation, significant steps, ledges, or thickness differentials are required, often in combination with a thinned superior lens zone (to reduce lens rigidity locally so that the lens can flex as it rises). Unfortunately, many of these features also reduce lens comfort for some wearers.

These factors can also lead to problems of orientation, whereby the lens no longer has a horizontal division (transition zone) between distance and near (slide 141). Instead, they have a



141



8L2998211-196

tilted division that may affect vision quality adversely.

However, there is little doubt about the desirability of having a routinely successful, comfortable, translating, soft bifocal (or PAL) that provides good vision at least at distance and near, if not at all distances.

142

**ALTERNATING / TRANSLATING BIFOCAL DISADVANTAGES**

- Lens must translate without significant rotation
- Translation must be sufficient to relocate near zone over all or most of the pupil
- Image jump in non-monocentric lenses
- Translation and re-centration (recovery) must be rapid
- Non-ideal translation may ↓ VA (D &/or N)
- Head position/attitude/movement may need alteration or limitation
- Comfort (RGP, usual initial comfort; SCL, truncation)
- Cost, often > custom lenses

8L2998211-63

### Disadvantages of Alternating/Translating Bifocal Designs: RGP Lenses

There are a number of potential limitations in both design and fitting of alternating RGP bifocal lenses. The shape and size of the near segment and the ability of the lens to translate properly on the cornea are among the key factors to be considered.

If the segment is too small or the lens moves laterally or obliquely, the resulting vision is compromised. Further, if the optical centres of the near and distance zones are separated by a significant distance, a 'jump' in vision (i.e. the 'image jump' that can also occur with some spectacle bifocals) is created as the wearer's visual axis passes from one zone to the other.

Any increase in near segment size results in greater overall lens thickness. Increased thickness can cause discomfort and, because of the added lid/lens interaction and greater lens mass, increase the likelihood of excessive inferior decentration. This decentration can compromise lens translation that is the core issue for translating bifocal success.

Fitting these lenses requires significantly greater practitioner skill than single vision lens fitting. The novice fitter would be well advised to work closely with the lens manufacturer and follow their fitting recommendations closely during the learning phase.

143

**TRANSLATING BIFOCALS REQUIREMENTS**

- Inferior centration on downgaze
  - taut lower lid
  - relatively high, lower lid margin position
- Correct orientation
- Rapid post-blink recovery (RGPs only)
- Acceptable anterior eye fitting relationship
- Translation from D to N on down-gaze
- Pupil coverage in either lens position

8L2998211-89

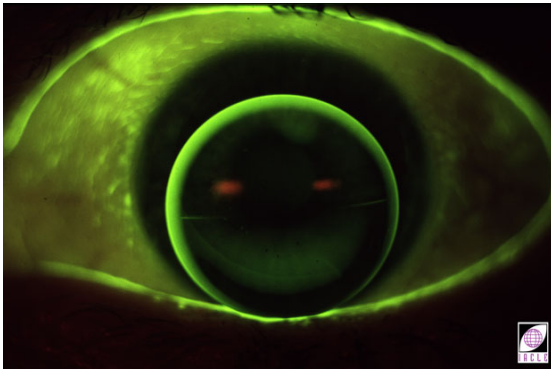
### Alternating/Translating Bifocals: Requirements

Lens translation occurs as a result of the following factors:

- Ease with which the lens moves over the superior cornea and/or limbus. Usually, this means the lenses must be fitted slightly looser than single vision lenses.
- Elastic force of the lower lid against the lower prism ballasted portion (with or without truncation) of the lens.
- The resistance to lens movement includes:
  - the shear forces generated between the lens and cornea (much greater in SCLs). This force is related inversely to the thickness of the tear film ( $1/[t]^2$ );



144



8L21074-93

- the physical properties of the tears themselves, e.g. their viscosity;
- the elastic properties of the lens, especially if a SCL..

While the first two factors are relatively constant for an individual, the tear film thickness may be greater at the time of trial fitting (profuse tearing?). Consequently, the amount of translation observed during the trial fitting period may be different to that observed after lens adaptation.

145

**SELECTING BIFOCAL TYPE  
LID POSITION**

<b>Upper High</b>	<b>Upper Low</b>
Translating	Simultaneous
<b>Upper Low</b>	<b>Lower Low</b>
Translating	Simultaneous
Simultaneous	

998211-102

8L2998211-102

**Contraindications of Alternating/Translating Bifocal Designs**

Certain patient characteristics reduce the chances of success with bifocal contact lenses, especially translating bifocals, e.g. lid position (see slide 145).

If the pupil size is greater than about 5 mm, the wearer may experience some flare due to unintended simultaneous vision through both the distance and near zones.

The wearer's lower lid must be able to hold the lens stationary while the eye moves downwards. An important consideration is the position of the lower lid margin. It should be level with the lower edge of the visible iris. If it is any *lower* than this, the lens may move downwards too far, i.e. beyond the limbus at 6 o'clock, before finally resting against the lid, and will, consequently, not translate up far enough relative to the pupil to provide good near vision.

If the lower lid is significantly *above* the inferior limbus, then there is usually insufficient vertical space for adequate translation. A smaller diameter lens can be tried as well as an increased truncation (to reduce the vertical lens TD and increase the lid/lens interaction).

A high riding lens or one where the upper lid has a significant influence on lens position will result in the reading segment locating over the pupil during distance vision, causing significant visual disturbance (an RGP example of this is shown in slide 142). Lenses should be designed with limited optic zone sizes and a tapered upper edge to minimize this problem by limiting any tendency towards a 'lid attachment' fitting. A larger diameter lens or one with greater prism may improve the fitting.

A simultaneous vision lens design or monovision is a better option if the main zone of near vision for the wearer is in the primary gaze direction.

146

**ALTERNATING / TRANSLATING BIFOCAL  
CONTRAINDICATIONS**

- Large pupil size
- Lower lid below the limbus
- Lower lid too far above the limbus
- Loose lids (reduced lid tonus)
- Poor blinker

998211-64

8L2998211-64

147

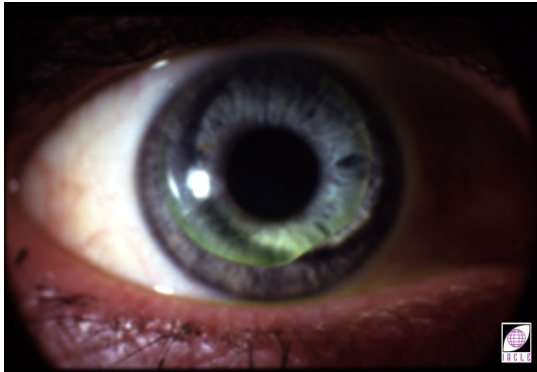
**ALTERNATING / TRANSLATING BIFOCAL  
CONTRAINDICATIONS**

- High-riding lenses
- Ptosis
- Near-vision tasks at eye level (primary gaze)
- Intolerant of RGP lenses
- Poor motivation
- Low add needed
  - try monovision RGPs

998211-94

8L2998211-94

148



8L2TSBFIT

149

### ALTERNATING/TRANSLATING BIFOCAL SEGMENT

- Considerations
  - fused or one-piece (solid)
  - material refractive index ( $n$ )
  - size (horizontal & vertical diameters)
  - shape (flat-top, D-seg, crescentic, etc.)
  - image jump
  - impact on overall lens thickness
  - 'height' from lens edge

990211-93

8L2998211-93

### Segment Considerations for Alternating/Translating Bifocal Designs

To ensure that there is a reading segment of sufficient size within the contact lens' optic zone for adequate near vision, the front optic zone diameter (FOZD) should not be ordered too small.

In RGP lenses incorporating a fused segment, the segment must be made of a higher refractive index material to provide the add power. Usually, this also means the segment material has a lower Dk, cf. the main lens (i.e. the 'carrier'). Slide 136 shows the possible segment locations in relation to the lens surfaces.

The lens front surface remains continuous, either because the segment is surrounded by the 'carrier' lens material (embedded) or because the segment's front surface is finished at the same time as the lens front surface (similar to fused glass bifocal spectacle lenses). There is minimal image jump and lens blanks are supplied semi-finished to laboratories to allow custom lenses to be made.

With embedded segments, local lens thickness cannot be less than the segment thickness. If it is, the carrier-segment interface will be non-existent and an incorrect near BVP will result.

Fused segments can give rise to reflections from the segment top. This problem can be minimized by placing the segment top at or slightly below the lower pupil margin as determined in 'normal' illumination. In some cases, the segment needs to be positioned below the pupil border by 0.4 to 0.7 mm to prevent light reflections from the segment line interfering with the quality of normal distance vision.

Observing the segment position with a slit-lamp can sometimes be misleading due to the pupil miosis that results from the instrument's bright illumination system. Instead, the normal position can be assessed using a simple magnifier (or a direct ophthalmoscope used from the side, focused on the iris, and not turned on) while being careful not to obstruct the normal room light entering the eye.

In some one-piece RGP bifocal lenses, the use of prism to create both the segment and orientate the lens can give rise to potential problems with image


jump as the eye passes vertically over the segment top. This will be most noticeable with higher minus distance powers and may create an unacceptable disturbance of vision.

Certain lens designs offer minimal or 'no-jump' optics. These are usually monocentric lens designs, i.e. the optical centres of both the distance and near zones coincide (e.g. Tangent Streak™ [Kirman and Kirman, 1988] and the X-Cel Solution™ bifocals, both one-piece designs). A straight-top segment bifocal results (this is similar to a so-called Executive™ spectacle bifocal lens). If the segment is positioned too high, the wearer may complain of flare in dim light.

150

**ALTERNATING VISION RGP BIFOCAL FITTING**

- Fit 'on flattest K' to 'slightly flatter than K' (<0.50D)
  - align closely
- Large BOZD
- Select TD carefully
  - controls segment position
- Too steep
  - lens may swing nasally and not translate
- Too flat
  - lens may swing temporally and decentre



8L2998211-67

**Fitting Alternating Vision RGP Bifocal Lenses**


A bifocal trial lens fitting will enable the practitioner to determine the optimum lens and segment design for each patient. When fitting RGP lenses, topical corneal anaesthesia can minimize the effects of excess tearing on the lens fitting assessment.

To obtain adequate centration and the desired lens position on the cornea, an appropriate combination of BOZR, back surface design, and TD must be selected. Lenses that are even slightly too steep or too flat can cause problems with poor translation and/or decentration.

151

**ALTERNATING VISION RGP BIFOCALS FITTING**

- Considerations
  - vertical lens diameter
    - small enough to enable lens translation?
  - BOZR
    - centration
    - movement
    - segment rotation
  - BVP
    - use a trial lens BVP close to ocular refraction



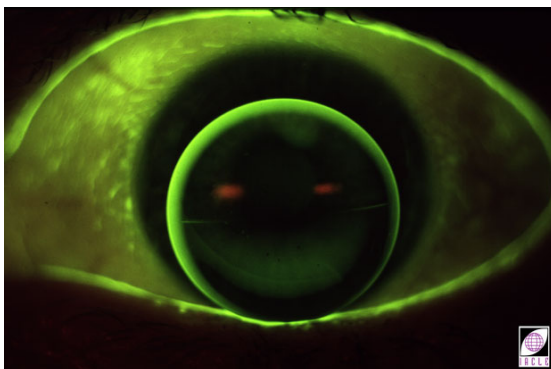
8L2998211-104

The segment line must be positioned at the appropriate height relative to the visual axis (slides 133 and 138). On average, this is achieved when the top of the segment is near the inferior pupil border. For some combinations of lens design and wearer's ocular anatomy, the segment can be fitted slightly higher or lower than the pupil border.

Selection of the optimum lens design must result in adequate lens translation on downgaze to enable the segment to cover as much of the pupil as possible at near.

The effects of segment height and lens TD need to be considered separately, e.g. a small, low-riding lens can give a similar effect to that of a low segment position. Conversely, a large, high-riding lens can mimic a high segment position. However, before segment height is altered (slide 152), the lens fitting should be optimized.

152



8L21074-93

The optimum lower lid arrangement is a firm lid that is at a tangent to and at or slightly above the limbus at 6 o'clock (from the Tangent Streak Fitting Tips sheet).

Some designs include a truncation routinely, e.g. the Tangent Streak (TD – 2 mm = vertical diameter) while others do not unless requested, e.g. X-Cell Solution.

Movement of some translating RGP bifocal lenses can cause some visual compromise due to the optical effects of the segment junction. Where appropriate, the wearer should be counselled about this prior to fitting and the concept of sensory/visual adaptation explained.

153

**ALTERNATING VISION RGP BIFOCAL FITTING**

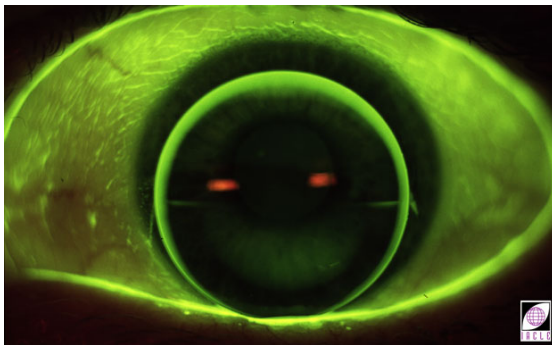
- Segment line near inferior pupil border
  - exact location depends on lens type
  - follow recommended fitting
  - precise measurements required
  - measure relative to visual axis
- Need minimum of 2 mm translation
- Small pupils are best for avoiding flare



8L2998211-68

Although, intuitively, translating RGP bifocal lenses may suit successful rigid lens wearers, the ‘new’ presbyopic experience including the effects of lens translation, may work against their acceptance.

154



8L208391

155

**ACHIEVING ROTATIONAL STABILITY PRISM**

- Prism ballast or periballast (induces thickness differences on the lens)
- Lid pressure interacting with thickness differentials
  - secondarily, increased weight inferiorly
- Inferior slab-off prism, superior slab-off prism, or both
- ↑ prism needed as ADD ↑
- ↓ prism with high + Rx's
- ↑ prism with high – Rx's



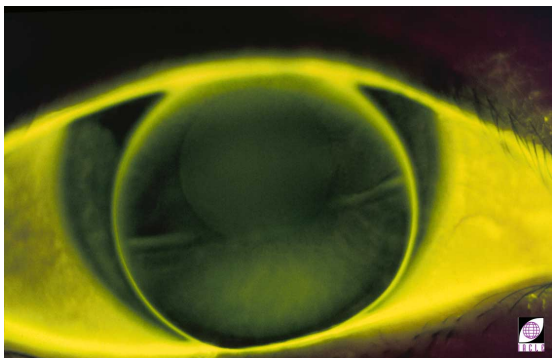
8L2998211-65

**Achieving Rotational Stability**

The thickness of an RGP bifocal is greater than that of an equivalent single vision design. Generally, because of greater lid-lens interaction and greater lens mass, such lenses tend to sit lower on the cornea. The fitting relationship may need to be altered to compensate for this tendency. This compensation should be made before any other steps are taken to achieve rotational stability.

Consistent misorientation is not necessarily a major concern, especially if it is nasal in direction, since the effect is often offset by the convergence of the eyes for near vision tasks (slide 156).

156



8L1443-91

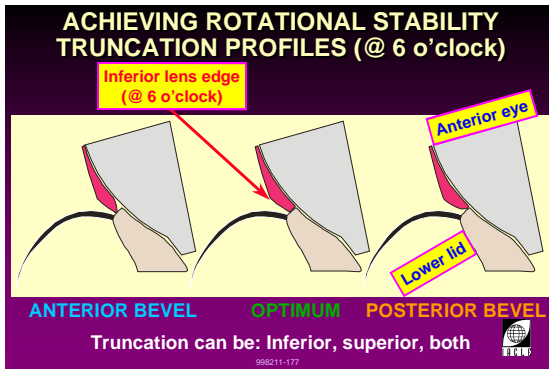
To reduce the tendency of the lids to rotate the lens during a blink, prism ballasting is used. In general, a smaller amount of prism is required for moderate to high plus D Rx's and, conversely, a greater amount of prism is required for minus Rx's (slide 149). In most cases, the amount of prism does not need to exceed 1.5 prism dioptres.

The increased inferior lens edge thickness also plays a role in preventing the lens from sliding down behind the lower lid margin on downgaze. Ideally, the lower edge of the lens rests on the lid margin. This is necessary to ensure that the near vision segment of the lens is positioned in front of the pupil for near vision, i.e. the lens is pushed up on the cornea on down-gaze.

Because it does not always eliminate a lens' tendency to rotate, the inclusion of prism ballast in RGP bifocals can be augmented by the



157

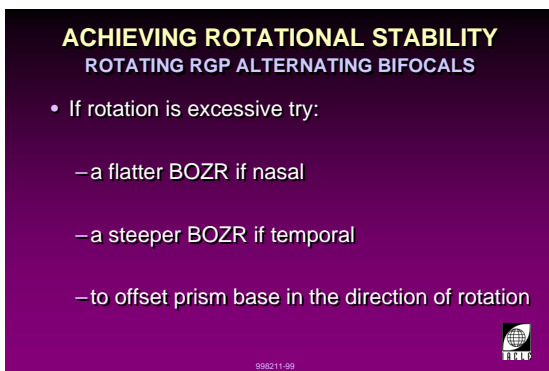


8L2998211-177

incorporation of a truncation inferiorly. One advantage of truncation is that it increases the area of the lens edge that engages the lower lid on downgaze. However, it is probable that the edge thickness and edge shape are of greater significance to both rotation and comfort. It is important for the truncation to be flat, as any anterior or posterior bevel will reduce the lid-lens interaction (slide 157).

The truncation can be either straight or a customized shape, e.g. slightly curved, to match the shape of the lower lid. Although uncommon, it is possible to produce a lens with both inferior and superior truncations.

158

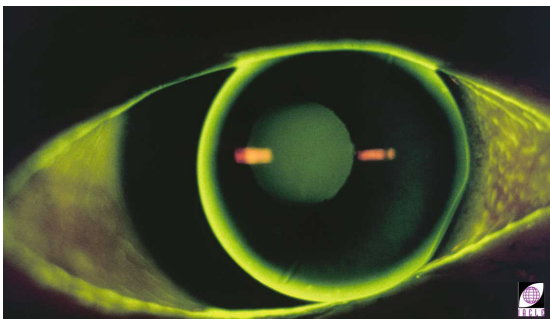


8L2982211-99

Unfortunately, the incorporation or modification of a truncation on a lens can have a negative effect on lens rotation by altering the ballasting effect of the prism already included. Increasing the truncation in a plus power lens increases its existing prism effect. Conversely, increasing the truncation in a minus lens decreases any prism ballasting effect.

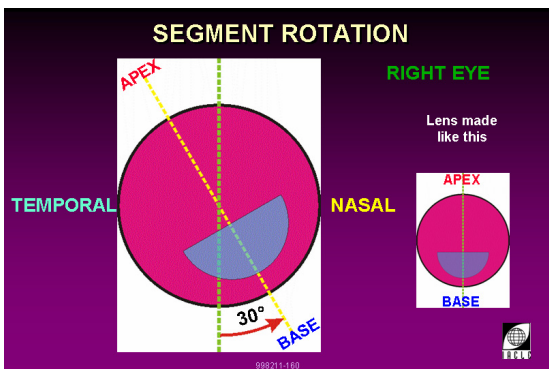
If significant segment rotation exists (e.g. slide 159) in the absence of other fitting problems, the segment can be offset relative to the prism base-apex meridian to account for the habitual orientation (slides 160, 161). In the diagrammatic example shown, the lens rotates anticlockwise 30°. To compensate for this rotation, a lens is ordered with the prism base adjusted by 30° in the same direction as the rotation. The base-apex meridian is now at 120°. Provided the lens rotates by the same amount as compensated for, and has stable fitting characteristics, the segment should exhibit no rotation, i.e. the junction should be horizontal.

159



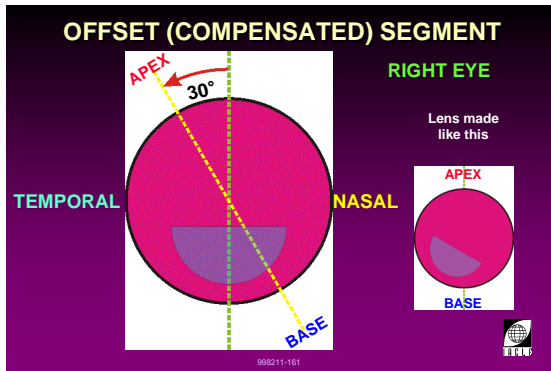
8L21011-91

160



8L2998211-175

161



8L2998211-176

162

**ALTERNATING VISION RGP BIFOCAL SEGMENT HEIGHT**

- Too high
  - ↑ inferior truncation (to lower lens)
  - flatten BOZR (lens may sit lower)
  - ↓ total diameter (to lower lens)
  - ↓ BOZD (lens may sit lower)
  - thin upper edge (less lid attachment)
  - truncate superiorly to ↓ influence of upper lid
  - ↑ prism (↑ thickness differentials, ↑ lens weight inferiorly)
  - ↓ seg height

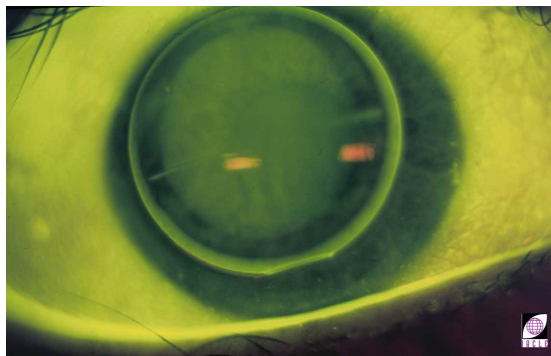
8L2998211-100

**Adjusting Segment Height Position**

It is important that the position of an RGP bifocal segment be evaluated carefully. The availability of a large trial lens set permits the practitioner to fit a range of lenses to determine the most appropriate segment height and position relative to the pupil.

Several options are available to the practitioner to improve the position of the segment height in cases where it is riding too high (slide 157) or too low.

163



8L23115-93

164

**ALTERNATING VISION RGP BIFOCAL SEGMENT HEIGHT**

- Too low
  - ↓ decrease truncation or no truncation
  - steepen BOZR
  - ↑ total diameter
  - ↑ BOZD
  - ↑ prism if lens slips beneath lower lid margin
  - new segment height (higher)

8L2998211-101



165

**PUPIL SIZE AND LENS SELECTION**

- Small pupil
  - simultaneous vision bifocal
- Large pupil
  - problematic for many bifocal designs
  - choose translating lenses initially



998211-105

8L2998211-105

**Pupil Size and Lens Selection**

Pupil size is an important factor in the successful fitting of RGP bifocal lenses. It is useful to measure the size of the pupil in both normal room illumination and dim (mesopic and scotopic) conditions.

When the pupil size is smaller than average, a simultaneous vision bifocal design will probably be more suitable.

Very small pupils may be unsuited to aspheric (PAL) lenses with large optic zones (say greater than 3.5 mm) as the pupil is unable to dilate sufficiently for the paracentral near vision zone to be in the pupil zone. The wearer may experience blur at both distance and intermediate distances.

Generally, large pupils are problematic for all bifocal lenses but the first choice should be to try a translating design.

## V Fitting Tips and Summary

166

### PRESBYOPIA FITTING STRATEGY CLINICAL TIPS

- If changing distance Rx
  - ensure subjective & objective VA improves significantly
  - ensure near VA is maintained or improved
- If changing near Rx
  - ensure VA improves significantly
  - ensure distance VA is maintained or improved



8L2998211-79

167

### PRESBYOPIA FITTING STRATEGY CLINICAL TIPS

- Use a range of lens types
- Do not use a refractor head (phoropter)
  - changes pupil size by shielding the eye
- Use trial lenses, flippers, twirls, etc.



8L2998211-80

168

### PRESBYOPIA FITTING STRATEGY CLINICAL TIPS

- Assess binocular vision
  - same, better, worse than with spectacles?
- Follow fitting recommendations
- Use anaesthetic for RGP trial fitting
  - decreases reflex tearing
- Extended trial wear period



8L2998211-95

169

### PRESBYOPIA FITTING STRATEGY

- Low to moderate adds (+1.50 or less)
  - monovision
  - aspheric simultaneous vision design
- Moderate to high adds (+1.75 or more)
  - concentric simultaneous vision design
  - diffractive simultaneous vision design (soft)
  - alternating (translating) RGP design



8L2998211-69

### Clinical Tips for Fitting the Presbyope

Some useful tips for fitting a presbyope with contact lenses include the following:

- Ensure the patient's expectations are realistic before embarking on a trial fitting.
- Make minimal adjustments to establish optimal balance between distance and near. Ensure that an improvement at one distance is not offset by a significant reduction in the other.
- Reassess both objective and subjective distance vision and near vision with each adjustment in lens power.
- Allow the patient to adapt (longer for RGP lenses) before assessing the visual performance.
- Where the size of the pupil is critical to vision, do not use a refractor head (phoropter) as the shading effect of the instrument can dilate the pupils artificially.
- Use full-aperture flippers or twirls (these are two pairs of equally powered lenses but of opposite signs, mounted on a common handle, e.g. a pair of +0.25 D and –0.25 D spherical lenses) to assess the over-refraction.
- Binocular over-refraction is preferable to a monocular assessment.

### Summary of Fitting Strategies for the Presbyope

Generally, fitting presbyopes with contact lenses offers the practitioner a significant opportunity to expand their practice's patient base. Given that the average age of the population in most countries is increasing, the opportunity to fit presbyopes will arise more frequently.

Although presbyopic contact lenses are still not regarded as routine clinical entities by many practitioners, their designs have evolved, and continue to evolve, to such an extent that many presbyopes can now be satisfied with one or two of the wide variety of either soft and RGP lenses now available.

170

### PRESBYOPIA FITTING STRATEGY

- Careful patient screening
  - successful single vision lens wearers
    - try bifocal lenses first
    - use monovision as second option
    - D CLs and spectacles for N, or intermediate & N, as last resort (if combination acceptable to patient)
  - poor suppression or spatial localization
    - successful monovision wear likely to be problematic



998211-11

8L2998211-11

Often, achieving success with bifocal contact lenses is associated with a high degree of practitioner enthusiasm for this modality. Enthusiasm and a good working knowledge of the wide range of lens types available are important ingredients in creating and maintaining a presbyopic contact lens practice.

Other important aspects of successful presbyopic contact lens fitting are careful patient selection and management of the patient's expectations (i.e. keeping them realistic). These considerations enable the most suitable lens to be selected on a case-by-case basis so that the benefits of contact lens wear can be combined with acceptable standards of visual performance at the distances required.

171

### CL FOR PRESBYOPIA SUMMARY

- CL fitting for presbyopia is:
  - both satisfying & challenging
  - profitable, with huge market potential
- Bifocal success rates improving progressively
  - monovision will always be the same



998211-78

8L2998211-78

The advent of disposable bifocal contact lenses has enabled the practitioner to offer short-term fitting trials to many patients, usually at no cost to the practice.

172

### CL FOR PRESBYOPIA SUMMARY

- Success depends on:
  - understanding patients' needs
  - using a wide range of fitting options/trial sets
  - listening to patient feedback
  - practitioner enthusiasm
- Charge appropriate fitting fees (time = \$)



998211-96

8L2998211-96


**References**

- Atchison DA, Thibos LN (1993). *Diffraction properties of the Diffrax bifocal contact lens*. *Ophthalmol Physiol Opt.* 13: 186 – 188.
- Atchison DA, *et al.* (1992). *Chromatic aberration and optical power of a diffractive bifocal contact lens*. *Optom Vis Sci.* 69(10): 797 - 804.
- Back A, *et al.* (1989). *Correction of presbyopia with contact lenses: Comparative success rates with three systems*. *Optom Vis Sci.* 66(8): 518 – 525.
- Back A, *et al.* (1992). *Comparative visual performance of three contact lens corrections*. *Optom Vis Sci.* 69: 474 – 480.
- Back A, (1991). *Presbyopes and contact lenses: Is there hope?* *Optician.* 202 (5038): 16 – 19.
- Benjamin WJ (1993). *Simultaneous vision contact lenses: Why the dirty window argument doesn't wash*. *Int Cont Lens Clin.* 20(Nov/Dec): 239 – 241.
- Benjamin WJ (1994). *Back-surface hydrogel bifocals: Part 1. featuring the Echelon diffractive bifocal*. *Int Cont Lens Clin.* 21(Jul/Aug): 151 – 153.
- Benjamin WJ, Borish IM (1994). *Presbyopia and the influence of aging on prescription of contact lenses*. In: Ruben M, Guillon M (Eds.), *Contact Lens Practice*. Chapman & Hall, London. 763 - 828.
- Benjamin WJ, Borish IM (1998). *Chapter 26: Presbyopic Correction with Contact Lenses*. In: Benjamin WJ (Ed.), *Borish's Clinical Refraction*. WB Saunders Company, Philadelphia.
- Bennett ES, Henry VA (Eds.) (1994). *Clinical Manual of Contact Lenses*. Chapter 14. JB Lippincott Co.
- Bennett ES, *et al.* (1990). *The Diffrax bifocal contact lens*. *CL Forum.* 15(3): 31 – 35.
- Borish IM, Perrigin D (1987). *Relative movement of lower lid and line of sight from distant to near fixation*. *Am J Optom Physiol Opt.* 64(12): 881 – 887.
- Borish IM (1988). *Pupil dependency of bifocal contact lenses*. *Am J Optom Physiol Opt.* 65: 417 - 423.
- Brenner MB (1994). *An objective and subjective comparative analysis of diffractive and front surface aspheric contact lens designs used to correct presbyopia*. *CLAO J.* 20(1): 19 – 22.
- Charman WN (1986). *Diffractive bifocal contact lenses*. *Contax.* (May): 11 – 17.
- Cheng C-Y, *et al.* (2004). *Association of ocular dominance and anisometropic myopia*. *Invest Ophthalmol Vis Sci.* 45: 2856 – 2860.
- Cohen AL (1984). *An improved bifocal lens design*. *CL Forum.* 9: 21 – 33.
- Cohen AL (1993). *Diffractive bifocal lens design*. *Optom Vis Sci.* 70(6): 461 – 468.
- Cohen AL, Cohen HR (1989). *Bifocal optics: Diffractive bifocal designs vs. simultaneous vision*. *CL Spectrum.* 4(3): 49 – 51.
- Collins MJ, Goode A (1994). *Interocular blur suppression and monovision*. *Acta Ophthalmol.* 72: 376 – 380.
- Collins M, *et al.* (1989). *Contrast sensitivity with contact lens corrections for presbyopia*. *Ophthalmol Physiol Opt.* 9:133 – 138.
- Collins M, *et al.* (1994). *Monovision: the patient's perspective*. *Clin Exp Optom.* 77: 69 - 75.
- De Carle J (1989). *Transactions BCLA Conference, Birmingham. A refractive multizone bifocal*. *J BCLA.* 12(5): 66 – 70.
- du Toit R, *et al.* (2000). *Results of a one year clinical trial comparing monovision and bifocal contact lenses*. *Optom Vis Sci.* 77(12S) (Suppl.): 18.
- du Toit R, *et al.* (2000B). *Factors that discriminate between monovision and bifocal contact lens preference*. *Optom Vis Sci.* 77(12S) (Suppl.): 160.
- Edwards K (1999). *Contact lens problem-solving: bifocal contact lenses*. *Optician.* 218 (5721): 26 - 32.

- Edwards K (2000). *Progressive power contact lens problem solving*. Optician. 219 (5749): 16 - 20.
- Erikson P (1988). *Potential range of clear vision in monovision*. J Am Optom Assoc. 59(3): 203 - 205.
- Erickson P, McGill E (1992). *Role of visual acuity, stereoacuity, and ocular dominance in monovision patient success*. Optom Vis Sci. 69(10): 761 – 764.
- Erickson P, Schor C (1990). *Visual function with presbyopic contact lens correction*. Optom Vis Sci. 67(1): 22 – 28.
- Fincham WHA, Freeman MH (1974). *Optics 8<sup>th</sup> ed*. Butterworths, London. 319 – 357.
- Fisher K (1997). *Presbyopic visual performance with modified monovision using multifocal soft contact lenses*. Int Cont Lens Clin. 24(May/June): 91 – 99.
- Fonn D, et al. (2000). *Determination of lens prescription for monovision and Acuvue bifocal contact lenses*. Optom Vis Sci. 77(12s) (Suppl.): 160.
- Freeman MH, Stone J (1987). Transactions BCLA Conference, 1987. *A new diffractive bifocal contact lens*. J BCLA. 11(5): 15 – 22.
- Garland MA (1987). *Monovision and related techniques in the management of presbyopia*. CLAO J. 13(3): 179 – 181.
- Ghormley NR (1989). *Contact lenses & presbyopia Part I*. Int Cont Lens Clin. 16(4): 102 – 103.
- Ghormley NR (1989B). *Contact lenses & presbyopia Part II*. Int Cont Lens Clin. 16(5): 133 – 135.
- Ghormley NR (1990). *The echelon bifocal – Will lens deposits decrease visual performance?*. Int Cont Lens Clin. 17(3): 118 – 120.
- Hansen DW (1996). *Problem solving for RGP alternating multifocal lenses*. Optom Today. Feb 12: 36 – 38.
- Hansen DW (1999). *Advanced multifocal fitting and management*. CL Spectrum. 8: 25 – 33.
- Hansen DW (1999B). *selecting the preferred presbyopic contact lens option*. CL Spectrum. 8(11): 13.
- Harris MG, Classé JG (1988). *Clinicolegal considerations of monovision*. J Am Optom Assoc. 59(6): 491 – 495.
- Harris MG (1990). *Informed consent for presbyopic contact lens patients*. J Am Optom Assoc. 61(9): 717 – 723.
- Harris M, et al. (1991). *Patient response to concentric bifocal contact lenses*. J Am Optom Assoc. 62(5): 389 - 393.
- Harris MG, et al. (1992). *Vision and task performance with monovision and bifocal contact lenses*. Optom Vis Sci. 69(8): 609 - 614.
- Hemenger RP, Tomlinson A (1990). *Diffractive bifocals: Confusion of design*. CL Forum. 15(3): 27 – 30.
- Jain S, et al. (1996). *Success of monovision in presbyopes: review of the literature and potential applications to refractive surgery*. Surv Ophthalmol. 40: 491 - 499.
- Jenkins FA, White HE (1981). *Fundamentals of Optics 4th ed*. McGraw-Hill, Auckland. 383 – 386.
- Jones B, Lowther GE (1989). *The effect of near zone size of a hydrogel contact lens bifocal on visual acuity*. Int Cont Lens Clin. 16(3): 87 – 93.
- Josephson JE, Caffrey BE (1987). *Monovision vs. aspheric bifocal contact lenses: a crossover study*. J Am Optom Assoc. 58: 652 - 654.
- Josephson JE, et al. (1990). *Monovision*. J Am Optom Assoc. 61(11): 820 – 826.
- Key JE (1990). *Hydron Echelon diffractive soft bifocal for presbyopia*. Contactologia. 12E: 89 – 92.
- Key J, et al. (1996). *Prospective clinical evaluation of Sunsoft multifocal contact lens*. CLAO J. 22: 179 - 184.
- Kirman ST, Kirman GS (1988). *The Tangent Streak bifocal contact lens*. CL Forum. 13(6): 38 – 40.

- Klein SA (1993). *Understanding the diffractive bifocal contact lens*. *Optom Vis Sci*. 70(6): 439 – 460.
- Klein MV, Furtak TE (1986). *Optics* 2nd ed. John Wiley & Sons, New York. 34, 435.
- Koetting R, Castellano CF (1984). *Successful fitting of the monovision patient*. *Contacto*. 28: 24 - 26.
- Longhurst RS (1973). *Geometrical and Physical Optics*. 3rd ed. Longman, London. 3, 276 - 280
- Loshin DS (1989). *The helegraphic/diffractive bifocal contact lens*. *Int Cont Lens Clin*. 16(3): 77 – 86.
- Maldonado-Codina C, et al. (1997). *Monovision revisited*. *Optician*. 214(5608): 23 – 28.
- Martin JA, Roorda A (2003). *Predicting and assessing visual performance with multizone bifocal contact lenses*. *Optom Vis Sci*. 80(12): 812 – 819.
- McGill E, Erickson P (1988). *Stereopsis in presbyopes wearing monovision and simultaneous vision bifocal contact lenses*. *Am J Optom Physiol Opt*. 65(8): 619 – 626.
- McGill E, Erickson P (1991). *Sighting dominance and monovision distance binocular fusional ranges*. *J Am Optom Assoc*. 62(10): 738 – 742.
- Meyer-Arendt JR (1995). *Introduction to Classical and Modern OPTICS* 4th ed. Prentice Hall, Englewood Cliffs. 232 – 250.
- Meyler J, Veys J (1999). *A new "pupil-intelligent" lens for presbyopic correction*. *Optician*. 217(5687): 18 - 23.
- Michaud L, et al. (1995). *New perspectives in monovision: a study comparing aspheric with disposable lenses*. *Int Cont Lens Clin*. 22: 203 - 208.
- Molinari JF (1988). *Transactions BCLA International Conference, 1988. A clinical comparison of subjective effectiveness of monovision, aperture-dependent and independent bifocal hydrogel lens fittings*. *J BCLA*. 11(5): 58 – 59.
- Morgan P, Efron N (2000). *Trends in UK contact lens prescribing 2000*. *Optician*. 219(5749): 22 - 23.
- Myler J, Veys J (1999). *A new 'pupil-intelligent' design for presbyopic correction*. *Optician*. 217(5687): 18 – 23.
- Phillips AJ (1988). *Transactions BCLA International Conference, 1988. Diffrax – A diffractive bifocal RGP lens – Clinical trial results & advice to practitioners*. *J BCLA*. 11(5): 89 – 94.
- Plakitsi A, Charman WN (1995). *Comparison of the depths of focus with the naked eye with three types of presbyopic contact lens correction*. *J Brit Cont Lens Assoc*. 18: 119 - 125.
- Rabbetts RB (1998). *Bennett & Rabbetts' Clinical Visual Optics*. Butterworth Heinemann, Oxford. 180.
- Rakow PL (2001). *The road to presbyopic contact lens success*. *Eyewitness*. 4th Quarter: 1 – 5.
- Run Johannsdottir K, Stelmach LB (2001). *Monovision: a review of the scientific literature*. *Optom Vis Sci*. 78(9): 646 – 651.
- Ruston DM, Meyler J (1995). *How to fit alternating vision RGP bifocals. Part 2: The Fluoroperm ST bifocal*. *Optometry Today*. Nov 23rd: 27 - 31.
- Sanchez FJ (1988). *Monovision: Which eye for near?* *CL Forum*. 13(6): 57.
- Saunders B (1990). *A soft diffractive bifocal contact lens*. *Optician*. 200 (Sept 7): 15 – 18.
- Schor C, et al. (1987). *Ocular dominance and the interocular suppression of blur in monovision*. *Am J Optom*. 64(10): 723 - 730.
- Schor C, et al. (1989). *Effects of interocular blur suppression ability on monovision task performance*. *J Am Optom Assoc*. 60(3): 188 - 192.
- Sidock NC, et al. (2000). *A comparison of reading performance: Bifocal and multifocal soft CLs versus a combination of soft CLs with reading glasses*. *Optom Vis Sci*. 77(12S) (Suppl.): 162.
- Situ P, et al. (2000). *Visual function assessment and subjective vision ratings of bifocals and monovision contact lens wearers*. *Optom Vis Sci*. 77(12s) (Suppl.): 161.



- Situ P, *et al.* (2002). *Refractive error in presbyopes after 6 months of monovision contact lens wear.* Invest Ophthalmol Vis Sci. 43(E-Abstract): 3107.
- Situ P, *et al.* (2003). *Successful monovision contact lens wearers refitted with bifocal contact lenses.* Eye & Cont Lens. 29(3): 181 – 184.
- Soni PS, *et al.* (2003). *Is binocular contrast sensitivity at distance compromised with multifocal soft contact lenses used to correct presbyopia?* Optom Vis Sci. 80(7): 505 – 514.
- Stein H (1990). *The management of presbyopia with contact lenses: A review.* CLAO J. 16(1): 33 – 38.
- Stone J (1988). *Experience with the Diffrax lens.* Optician. 195 (Mar 4): 21 – 36.
- Walker P, Churms P (1997). *The Diffrax bifocal contact lens.* Optician. 194 (Oct 2): 21 – 24.
- Walker D, Hough T (1999). *RGP multifocals: Delivering credible product is the challenge to industry.* Global Contact. 23: 10 – 14.
- Wood JM, *et al.* (1998). *The effect of monovision contact lens wear on driving performance.* Clin Exp Optom. 81(3): 100 – 103.
- Woods C, *et al.* (1999). *Clinical performance of an innovative back surface multifocal contact lens in correcting presbyopia.* CLAO J. 25: 176 - 181.
- Woods RL (1995). *Interferometric assessment of the surface profile of diffractive bifocal contact lenses.* URL: <http://www.eri.harvard.edu/faculty/peli/lab/woods/publications/VSIA95a.pdf>
- Young G, *et al.* (1990). *Simultaneous vision bifocal contact lenses: a comparative assessment of the in vitro optical performance.* Optom Vis Sci. 67(5): 339 - 345.

# Unit 8.3

(2 Hours)

## Unit 8.3: Children and Contact Lenses

## **Course Overview**

### **Lecture 8.3: Children and Contact Lenses**

- I Choice of Correction Based on Prescription, Age, and Other Factors**
- II Advantages and Disadvantages of Various Lenses and Their Success Rates**
- III Lens Types**
- IV Special Considerations: Counselling, Collaboration, and Parental Roles**

# Lecture 8.3

(2 Hours)

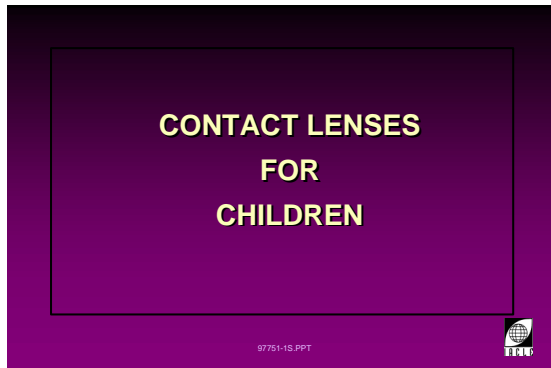## Children and Contact Lenses

## Table of Contents

<b>I</b>	<b>Paediatric Patients</b> .....	<b>149</b>
<b>II</b>	<b>Paediatric Contact Lens Fitting</b> .....	<b>152</b>
	II.A General Considerations .....	152
	II.B Indications for Use.....	155
<b>III</b>	<b>Paediatric Contact Lenses</b> .....	<b>162</b>
<b>IV</b>	<b>Pre-Fitting Evaluation</b> .....	<b>168</b>
<b>V</b>	<b>Lens Application and Removal</b> .....	<b>171</b>
<b>VI</b>	<b>Follow-Up, After-Care, and Management</b> .....	<b>173</b>

## I Paediatric Patients

1



8L397751-1

### Contact Lenses for Children

Contact lenses have an important role to play in the visual correction of children and infants. They can permit more normal development of VA, and motor and perceptual skills compared with spectacles, especially in cases of high refractive errors. Contact lenses offer a 15% wider field of view compared to spectacle lenses.

In many cases, contact lenses are preferred over spectacles due to the difficulty of keeping spectacles on a child's face. Many infants or children, as well as some parents, also react negatively to spectacles. In these cases, contact lenses may be very useful and a contact lens trial may help in the appreciation of vision (Gasson and Morris, 2003).

Problems associated with spectacles for the young include:

- Absence of a prominent nose bridge.
- Spectacles are easily removed, bent, scratched and broken.
- Potential for retinal image size disparity.
- Alterations/distortions in the peripheral field of view.

Children also tend to grow out of their spectacle frames quite quickly, and may be better suited to a disposable or frequent replacement type of contact lens.

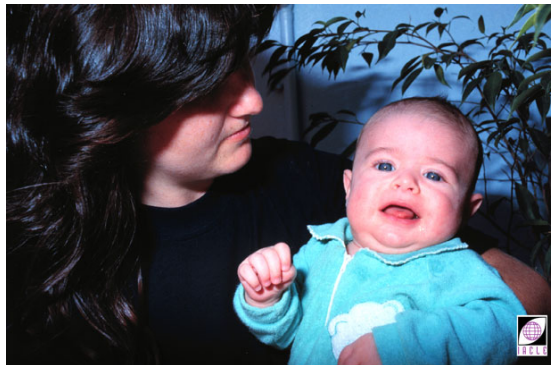Fitting contact lenses to the very young is a challenge for the contact lens practitioner and usually requires considerable effort on the part of all parties involved. A strong relationship must be developed between the practitioner and the parents/guardians of the child. The practitioner needs to be empathetic and understand that parents are naturally concerned about their children's eye health and development.

Parents should always be well informed of the purpose and benefits of the contact lens correction, as well as the potential complications and difficulties that may arise. They need to know what to expect, and should be told well in advance that the initial learning period is often frustrating and can be very stressful for the whole family.

As soon as practicable, the child should also be made to understand that contact lenses are beneficial and that they are not a punishment.

Most commonly, young children needing contact lenses are seen in a hospital eye department. Older children are more likely to be managed within a general practice environment. In either situation, families need to know that they have access to the practitioner's support should questions or problems arise.

2



8L31842-91

3



8L31834-91




4

**REFRACTIVE COMPONENTS THAT CHANGE WITH AGE**

- Axial length
- Corneal curvature
- Corneal diameter
- Refractive power

97751-2S.PPT



8L397751-2

**Refractive Components with Age**

The length of the infant eyeball is approximately 17 mm, as opposed to 24 mm in the adult.

Corneal diameter at birth is 10.0 mm and by the age of 1 year it has reached almost adult size, around 11.6 mm.

At birth, the corneal radius is approximately 7.0 mm, which gradually flattens to an adult average of 7.86 mm by the age of 10 years.


The normal neonate has a refractive error that is moderately hyperopic with a slight astigmatic component. Retinoscopy is a very useful method of assessing refractive error objectively, while also providing information regarding the clarity of the eyes' optical media.

5

**REFRACTIVE COMPONENTS**  
BALDWIN, 1990

COMPONENT	AGE (YEARS)			
	BIRTH	1	3	5
Axial Length (mm)	17.20	19.00	21.40	22.00
Corneal Power (D)	50.00	45.00	44.00	43.50
Refractive Power (D)	+2.20	+1.50	+1.30	+1.20

97751-40S.PPT



8L397751-40

When fitting contact lenses to a paediatric patient it is important to consider the change in corneal shape and refractive error that occurs over the first few years of life. The lens TD, BVP, and radius of curvature ( $r_0$ ) must be altered to maintain an optimum lens-to-cornea fitting relationship.

In many cases of fitting very young infants, the contact lens BVP is determined by the child's near point needs. As they grow and develop, the lens prescription can be altered to favour distance vision.


Because the child's visual system is changing constantly, it is essential to do regular follow-up examinations and contact lens modifications when necessary.

6

**ACUITY TESTING TECHNIQUES**

- Target detection
  - beads and balls
- Preferential looking
- Optokinetic response
- Visual evoked potential
- Geometric symbols
- Letter charts

97751-42S.PPT



8L397751-42

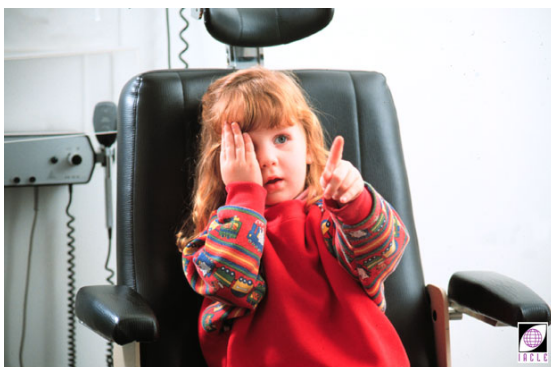**Visual Acuity Assessment in the Young**

From birth to about 5 years of age the VA of a child undergoes significant changes. Visual development in an infant is also accompanied by developments in their motor and cognitive abilities.

These factors, as well as the communication difficulty between adult practitioners and young patients, can make it difficult to obtain a true understanding of the level of visual performance in the very young (Suttle, 2001).

Various tests and techniques are available for paediatric visual assessment. Estimates of visual function may depend on the technique used for measurement.

7



8L30428-98

Detection acuity is the ability to discriminate a single element, such as a bead or a grain of rice on the examiner's hand.

The preferential looking technique can be used from birth as a form of acuity assessment. A card is presented to the infant where one half consists of a black and white grating pattern, while the other half is uniformly grey. The infant is expected to look towards the pattern if it can be discriminated. This ability to discriminate between elements is called resolution acuity.

Pattern movement, such as a spinning drum covered with a vertical grating pattern, elicits the

involuntary optokinetic response or optokinetic nystagmus. If this response is very weak or absent, it may indicate poor visual function. It is possible to estimate the VA by measuring the width of the grating pattern lines, as well as noting the furthest distance at which the optokinetic response is induced.

A visual evoked potential is an electrophysiological measure of cortical function. It is evoked by a visual stimulus that provides insight into the function of the entire retino-striate visual pathway. Electrodes placed at strategic points on the scalp overlying the occipital cortex may detect the electrical activity that is created in response to visual stimuli.

The ability to recognize and correctly identify complex shapes such as letters or pictures is known as recognition acuity. VA charts suitable for the assessment of young children include:

- Tumbling E.
- Allen picture cards.
- HOTV letter charts.
- Faye symbols chart.
- Lea symbols chart, which contains apple, circle, house and square symbols.

(From the Vision in Preschoolers Study Group, 2004).

Snellen letter charts can normally be used in children 5 years or older. The choice of which VA test is the most appropriate to use is generally dictated by age (Fern, 1986) as well as the child's cognitive level. It is advisable to choose a test at the most advanced level that a child is capable of understanding.

## II Paediatric Contact Lens Fitting


### II.A General Considerations

8

**PAEDIATRIC CL FITTING**

- Significant clinical challenges
- Long-term involvement by the practitioner
- Very rewarding results

97751-12S.PPT



8L397751-12

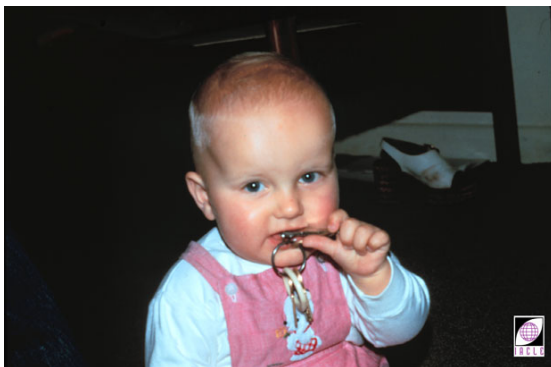#### Paediatric Contact Lens Fitting

Fitting contact lenses to paediatric patients is usually very time consuming and may be costly in some cases. However, the rewards are often significant for both the patient and the practitioner.

Many different professionals are often involved in the care of a child who requires contact lens fitting. The contact lens practitioner must work within such a team to ensure the best outcome for the child.

A key factor in successful paediatric contact lens fitting is the level of motivation of the child as well as the parents.

9



8L30334-93

Practitioners who wish to do a lot of contact lens fitting for children, are advised to create a child-friendly environment in their practice, or at least in certain areas. This may even include a play area to make children feel more at ease when visiting the practice.

Child-friendly and informed practice staff, who are aware of the opportunities to fit children with contact lenses, can also be very beneficial to growing this aspect of a contact lens practice.

10

**PAEDIATRIC CL FITTING COLLABORATION**

Collaboration between:

- Contact lens practitioner
- Paediatrician
- Optometrist/ophthalmologist
- Community nurse
- Educational officers
- Family members

97751-13S.PPT



8L397751-13

#### Management Considerations

Fitting contact lenses to the paediatric patient provides many challenges for the practitioner. Anatomical features play a major role in the fitting of contact lenses in these cases.


The relatively small palpebral aperture and the tight lids of the infant can make it difficult to insert contact lenses. This is exacerbated by crying and the accompanying tight lid closure. Manually trying to force the lids open may cause lid eversion, especially if the child has loose eyelids.

11

**PAEDIATRIC FITTING CONSIDERATIONS**

- Small palpebral aperture size (PAS)
- Strong orbicularis oculi muscle tone
- Reduced blink frequency
- Tear volume
- Changing corneal shape and refractive error

97751-46S.PPT



8L397751-46

12

### PAEDIATRIC MANAGEMENT CONSIDERATIONS

- Development of tear reflex
- Steep anterior corneal curvature
- Changing corneal shape and refractive error
- Pupil size and shape

97751-38S.PPT



8L397751-39

To increase the chance of successfully applying the lenses, parents can do the following:

- Wait until the child is asleep.
- Avoid inserting lenses if the child is crying.

13

### PAEDIATRIC MANAGEMENT CONSIDERATIONS

- Has the eye healed following surgery?
- Is an adult able to assist?
  - compliance
- Is their environment suited to good lens care
  - hygiene
  - availability of solutions, etc

97751-66S.PPT



8L397751-66

14

### PAEDIATRIC FITTING ADVANTAGES

- Wider field-of-view than spectacles
- More normal visual development
- Children are more tolerant of contact lenses than adults

97751-15S.PPT



8L397751-15

### Advantages of Paediatric Contact Lens Fitting

One of the major advantages of fitting a paediatric patient with contact lenses is their 15% greater field-of-view compared to spectacles.

Generally, contact lenses permit more normal visual development than spectacles, especially in cases where the refractive error is significant.

Paediatric patients tend to be more tolerant of contact lenses than adults. This is particularly true in cases of RGP lens fitting.

Compared with adults, infants tend to have a higher aqueous component of the tear film. The wetness of the infant's eye can be beneficial when fitting contact lenses.

15

### PAEDIATRIC FITTING DISADVANTAGES

- Risk of corneal infection
- Difficulty in lens handling
- Expense involved

97751-50S.PPT



8L397751-50

### Disadvantages of Paediatric Contact Lens Fitting

It is also important to consider the potential disadvantages of fitting contact lenses to the paediatric patient. These include:

- Potential for corneal abrasion and infection.
- Difficulty with lens handling.
- Psychological and social impact on the child and their parents.
- Possible high costs involved in frequent lens changes and ongoing eye care.

16

### POTENTIAL PROBLEMS

- Counselling of parents
- Communication with practitioner
  - lens tolerance
  - problems
- Levels of motivation
- Contraindications due to systemic or ocular conditions



8L397751-16

### Potential Problems in Paediatric Contact Lens Fitting

Importantly, the practitioner must minimize the risk of problems occurring during contact lens wear.

A key to this is the inclusion of the child's parents in the whole process. They must be familiar with the likely outcome of the fitting and, more importantly, the potential for adverse reactions to the lenses.

Family members must be capable of handling the contact lenses *in vitro* as well as their insertion and removal.

17

### LENS SELECTION CRITERIA

- Need a stable fitting
  - centration
  - movement
- Adequate BOZD
- Ease of replacement



8L397751-17

### Lens Selection Criteria

In cases of paediatric contact lens fitting where it is not possible to obtain feedback regarding the performance quality, the practitioner must ensure that the key fitting characteristics of lens centration and movement are optimized.

Ideally, the final choice of lens should take into account the ease with which a replacement lens or lenses can be obtained.

18

### FITTING LENSES UNDER ANAESTHESIA ADVANTAGES

- Permits accurate measurement of the eye
- Ease of lens insertion
- Static fitting characteristics can be assessed
- Other tests where necessary



8L397751-30

### Fitting Lenses Under Anaesthesia

Assessment of the eye when the child is under anaesthesia can provide more reliable measurements of corneal shape and refractive error and assists in determining the optimal contact lens prescription. Lens insertion is achieved with ease, as is the assessment of the static fluorescein pattern of an RGP lens fitting.

Fitting assessment under anaesthesia does not permit the practitioner to observe the dynamic characteristics of the lens, as the child remains unblinking. The assessment of this important component of the fitting must wait until the child is awake.

19

### FITTING LENSES UNDER ANAESTHESIA DISADVANTAGES

- Risk involved in anaesthetizing child
- Expense
- Ocular characteristic may change under anaesthesia
- Dynamic fitting characteristics cannot be evaluated
- Fitting may be different when the child is awake



8L397751-31

While the child is under anaesthesia it is possible to obtain detailed diagrams of any abnormality and to photograph the eyes before and after the fitting of contact lenses. Where necessary, special testing such as visual evoked responses and electroretinograms can also be performed at this time.

20

### LENS ASSESSMENT TECHNIQUES

- Clinical judgement of the practitioner
- Basic assessment is often required due to non-compliance of the child
- Retinoscopy is very important when determining BVP



8L397751-32

### Lens Assessment Techniques

When fitting contact lenses to a young child the practitioner needs to be creative if assessments of the lenses on-eye are to be accurate. In many cases the child will not cooperate fully with the practitioner, or may even perceive the practitioner as a threat and behave accordingly.

It may not be possible to use the slit-lamp to assess the lens fitting so other instrumentation must be employed. This can include:

- Pen torch.
- Ophthalmoscope.
- Burton lamp or other simple magnifying system.
- Retinoscope.

The retinoscope is one of the most important instruments to use when evaluating the contact lens on a young child. Not only can it be used to judge lens fitting but it can also be used to assess the refractive correction.

## II.B Indications for Use

21

### INDICATIONS FOR USE

- Refractive errors
  - aphakia, myopia, hyperopia, astigmatism, anisometropia
- Binocular vision anomalies
  - accommodative esotropia



8L397751-18

### Indications for Use

Many ocular conditions that affect young children can be managed successfully using contact lenses. Contact lenses are considered superior to spectacles in many cases involving young children.

Spectacles often provide inadequate visual correction and may be unsightly, especially in cases of high refractive error.

A well-fitting contact lens remains relatively centred on the cornea and follows eye movements closely. Contact lenses, therefore, give rise to fewer distortions and prismatic effects than do spectacle lenses, especially in the case of large refractive errors.

Contact lens fitting for young children generally falls into three categories:

- Refractive.
- Therapeutic (e.g. in albinism, slide 42).
- Cosmetic.

As is the case with adults, contact lenses are usually also a more convenient option for children who participate in sports.

22

### INDICATIONS FOR USE

- Therapeutic
  - patching for amblyopia, bandage, photophobia, nystagmus, albinism
- Cosmetic
  - scarred cornea, aniridia
- When spectacles are inappropriate/disliked
  - craniofacial abnormalities



8L397751-19




23

**HIGH REFRACTIVE ERROR**

- Aphakia
- High myopia/hyperopia
- Unilateral ametropia
- Anisometropia
- Strabismus with high refractive error
- Corneal irregularity due to trauma

97751-20S.PPT



8L397751-20

**High Refractive Error**

Correction of high refractive error is the principal reason for fitting a young child with contact lenses. The main cause of high refractive error is aphakia, which may be congenital or traumatic, unilateral or bilateral.

Other refractive conditions include:

- High myopia.
- Unilateral ametropia.
- High hypermetropia.
- Strabismus with a high refractive error.
- Anisometropia.
- Corneal irregularity as a result of trauma.

24



8L3730-91

Low to moderate myopia in the young need not always be corrected immediately. Vision usually develops normally without any correction due to the clarity of vision at near points. As the child develops, the use of contact lenses may be beneficial, especially when spectacles are not accepted.

Contact lenses are an excellent option for correcting high myopia in children, allowing an increased field of view and in refractive cases, a more normal image size than spectacles.

In the past, it has been suggested that rigid contact lenses may retard the progression of childhood myopia, but this has not yet been proved conclusively.

Moderate to high hyperopic refractive errors should be corrected as early as possible. Contact lenses are often more readily accepted in hyperopes due to the reduced accommodative demand compared with spectacles.

Contact lenses also reduce the convergence demands in hyperopic patients, making them the correction of choice for hyperopes with associated accommodative esotropia.

Patients with anisometropia may benefit significantly from a combination of part-time occlusion and contact lens wear, to prevent or treat amblyopia. Special tinted or high plus powered SCLs can be used as an alternative method of occlusion therapy. Any kind of occlusion therapy should always be closely monitored to avoid amblyopia in the occluded eye.

In cases of unilateral ametropia, contact lens correction usually provides better stereopsis than spectacles.


The practitioner may face certain difficulties when fitting contact lenses to a child with high refractive error. Where a contact lens of high minus power is needed (e.g. -8.00 D or more), the lens may ride high due to the upper lid grasping the thicker lens edge, i.e. lid attachment. In such cases, a larger lens diameter may be required to ensure adequate pupil coverage.

25

**HIGH REFRACTIVE ERROR**

- Cycloplegic examination
- What is the progression rate?
- Can myopia progression be slowed?

97751-67S.PPT



8L397751-67

In high plus lenses, where the centre of the lens is noticeably thicker than the edges, a lenticular lens design may be required. These designs incorporate a minus carrier portion peripherally to ensure adequate lens centration, thereby avoiding a low-riding lens.


Where possible, patients or their parents should possess a spare pair of contact lenses in case of lens breakage or loss. In the interests of continuous visual stimulation, a pair of spectacles should also be prescribed and available as a back-up during periods when contact lenses cannot be worn.

26

**ASTIGMATISM**

- Not corrected when <1 year old
- Prescribe if >1.25 D when child is >1 year
- Prescribe if VA is below normal for age

97751-21.S.PPT



8L397751-21

**Astigmatism**

The practitioner must consider the degree of astigmatism present in a child's refractive error prior to fitting contact lenses. Unless the astigmatism is high, it is generally not corrected with astigmatic contact lenses in the first year.

However, when the level of VA is below the expected age norm, the practitioner should correct fully any astigmatic component of the refractive error to minimize the risk of meridional amblyopia.

A spherical rigid contact lens may correct some or all of a child's astigmatism when it is principally corneal in origin.

27



8L31843-91


In all cases of refractive error correction the child must be examined regularly to monitor any change in the prescription.

28

**PAEDIATRIC APHAKIA**

- Congenital cataract incidence about 1:10,000
- Time of onset of cataract
- Unilateral or bilateral

97751-22.S.PPT



8L397751-22

**Paediatric Aphakia**

Congenital cataract (slide 30) is a common cause of preventable blindness in children and one of the leading causes of form deprivation amblyopia.

Cataract formation in infants may be due to a wide range of causes including:

- Trauma.
- Systemic disease.
- Maternal illness such as rubella (German measles).
- Exposure to drugs.
- Exposure to radiation.
- Genetic (autosomal dominant).
- Down syndrome.


For optimum VA to develop, the removal of congenital cataracts should occur before the age of 3 months, followed by immediate and 'permanent' optical correction of the resulting aphakia.

29

**PAEDIATRIC APHAKIA**

- Congenital
- Traumatic
- Surgical

97751-23S.PPT



8L397751-23

Treatment of later onset cataract is not as urgent, as the visual system has already had time to develop.

Infants with bilateral congenital cataracts or vitreous anomalies should have surgery as soon as possible to prevent the onset of amblyopia.

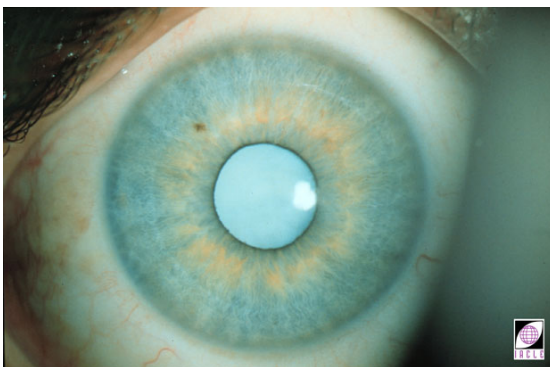
To avoid multiple surgeries in the growing eye, intraocular lenses are not usually fitted in infants or very young children following cataract extraction.

Obviously, contact lenses are the preferred method of correction in cases of unilateral aphakia. Even in bilateral aphakes, contact lenses are preferred to spectacles, as they compensate for the refractive error effectively, without the image magnification, field reduction, bad cosmesis, weight and thickness associated with aphakic spectacles.

Contact lenses can be fitted almost immediately following cataract removal, provided there is no significant ocular inflammation.

Practitioners who are interested in fitting aphakic infants with contact lenses should maintain a comprehensive trial fitting set.

30



8L32161-95


31

**PAEDIATRIC APHAKIA**

Physiological considerations:

- Reduced corneal sensitivity
- Reduced epithelial metabolic activity

97751-68S.PPT



8L397751-68


32

**SURGICAL APHAKIA**

Factors to consider:

- Size and density of the cataract
- Obstruction of the visual axis
- Unilateral or bilateral

97751-24S.PPT



8L397751-24

**Surgical Aphakia**

The following factors are considered when deciding on the need for surgery:

- Size and density of the cataract.
- Obstruction of the visual axis.
- Unilateral or bilateral.

The prognosis for developing good VA is poor, unless dense cataracts are removed before the child is 6 months old.

The type of surgery performed on an infant with cataract generally determines the amount of recovery time needed prior to contact lens fitting. Regardless, the consulting surgeon should be involved in any decision to proceed with contact lenses. Physiological considerations are the same as those for paediatric aphakia (slide 31).


33

**SURGICAL APHAKIA**

When to fit lenses:

- ICCE/ECCE 5 weeks
- Pars plana lensectomy 3 weeks
- Phacoemulsification 3 weeks

97751-70S.PPT



8L397751-70

In general, the more invasive the surgical procedure, the longer the time needed for recovery.

Surgery should preferably be done with minimal tissue manipulation to minimize post-operative corneal oedema, providing a relatively quiet eye for contact lens fitting.


Following cataract extraction, a soft high water content SCL is sometimes fitted while the child is still under general anaesthesia. This achieves immediate correction of the aphakia, and has the additional advantage of not having to subject the child to a further anaesthetic or restraint for contact lens fitting.

34

**CLs FOR PAEDIATRIC APHAKIA**

- Good optical correction
- Significantly reduced distortion and aniseikonia
- Less image magnification
- Promotes binocular development
- Easy to change as required
- Better tolerated than spectacles
- Only choice for unilateral cases

97751-25S.PPT



8L397751-25

**Contact Lens Advantages in Paediatric Aphakia**

Not only do contact lenses provide a more normal visual environment for the aphake, they also overcome the mechanical difficulties of wearing spectacles.

In cases of unilateral aphakia, contact lens fitting is the only option as a high-powered spectacle lens in front of one eye will not be tolerated.

It is always recommended that the infant have a back-up pair of spectacles for use in the event they are unable to wear their contact lenses.


35

**PAEDIATRIC APHAKIA**

Contact lens choices:

- Silicone elastomer
- Rigid gas-permeable
- Hydrogel

97751-26S.PPT



8L397751-26

**Contact Lenses for Paediatric Aphakia**

A range of lenses can be considered for the aphakic child. In most cases it is best to fit the infant or very young child with hydrogel or silicone elastomer contact lenses first. At a later stage the advantages of RGP lenses should be considered.

Ideally, contact lenses should be fitted as early as possible to correct aphakia. It is easier to get a very young child to adapt to lens wear and to keep the child in lenses as they grow older than it is to commence lens wear in an older child.


Until the age of 3, silicone lenses are usually the preferred choice for aphakic kids. From then on, the choice of lens wear modality and material is largely determined by the severity of lens deposits (de Brabander *et al*, 2002).

36

**PAEDIATRIC APHAKIA  
SUGGESTED SOFT LENS PARAMETERS**

Age (months)	BOZR (mm)	BVP (D)
0 – 6	7.5	+29.00
7 – 17	7.7/7.9	+26.00
18 – 28	7.9	+23.00
29 – 34	7.9/8.1	+18.00

97751-45S.PPT



8L397751-45

**Range of Contact Lens Parameters for Paediatric Aphakia**

Selection of the initial contact lens in cases of paediatric aphakia is based on age. This provides the practitioner with a useful starting point from which the final lens can be determined based on clinical assessment.

The suggested contact lens power (slide 36) is for distance vision. An increase of +1.00 to +3.00 D can be incorporated based on the practitioner's desire to establish a near vision environment for the child.




37

**PAEDIATRIC APHAKIA CONTACT LENS POWER**

- Overcorrect the BVP
  - for optimum near VA
- Retinoscopy

97751-27S.PPT




8L397751-27

38

**PAEDIATRIC APHAKIA GUIDELINES FOR LENS POWER**

AGE:	SUITABLE BVP:
6 weeks	+34.00 D
6 months	+28.00 D
12 months	+24.00 D

97751-51S.PPT




8L397751-51

39

**TRIAL FITTING SET**

BOZR (mm)	TD (mm)				
	12.00	12.50	13.00	13.50	14.00
7.00	+34.00 +30.00	+32.00 +28.00	+30.00		
7.20	+32.00	+30.00 +26.00	+28.00 +24.00	+22.00	
7.40		+28.00	+26.00 +22.00	+24.00 +20.00	+22.00
7.60			+24.00	+22.00	+18.00
7.80				+20.00	+16.00

SPEEDWELL, 1990 97751-41S.PPT



8L397751-41

**Determining the Contact Lens Power**

The optimum contact lens prescription is determined by retinoscopy. As there is no accommodative mechanism in aphakes, there is no requirement for a cycloplegic assessment.

Care must be taken to keep the trial lenses close to the eye of the infant to minimize the risk of prescribing an incorrect contact lens BVP due the high prescription involved. Compensation must be made for the vertex distance. For example, a trial lens of +19.00 D held at a vertex distance of 10 mm is equivalent to an on-eye contact lens power of +23.50 D.

Typically the contact lens BVP for an aphakic infant corrected for distance vision is between +20.00 D and +35.00 D, depending on the age of the child. An infant's visual world is at near and, therefore, to provide optimum focus the contact lens should be over-corrected by +2.00 D to +3.00 D.

The lens power is changed to a distance prescription by the time the child goes to school. Bifocal spectacles are prescribed for reading, which may also incorporate any astigmatic correction that improves the visual performance.

As a general guideline, especially when retinoscopy is difficult, a BVP of:

- +34.00 D is suitable for a 6 week old infant.
- +28.00 D for a 6 month old baby.
- +24.00 D at 1 year old.


Unilateral aphakes require contact lens correction as well as extensive patching of the good eye in cases of suspected amblyopia. Without treatment by patching, the aphakic eye will remain densely amblyopic.

40

**PAEDIATRIC AMBLYOPIA**

- Opaque tint (black occlusive)
- Monocular occlusion of the better eye
- Tolerated better than patching
- Better cosmetic effect
- Optical defocus with high plus power

97751-28S.PPT



8L397751-28

**Paediatric Amblyopia**

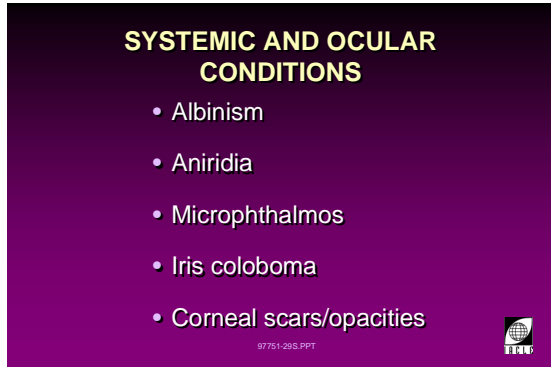
When traditional patching treatment is difficult to maintain, this can often be effectively done with contact lenses. In such cases, opaque black tinted contact lenses, opaque pupil lenses, or lenses that are significantly over-plussed may be used in the 'good' eye.

This form of patching is not successful in all cases, as the child may learn to move the lens off the cornea to the upper fornix or rub it from the eye.

The quality of tinting must be considered as in some cases a light black tint may permit a standard of acuity in the good eye that is better than in the densely amblyopic eye.

Amblyopia treatment requires the early institution of a patching regimen. In general a hydrogel occlusive lens achieves faster adaptation than an RGP lens, allowing the practitioner to commence treatment immediately.

41



**SYSTEMIC AND OCULAR CONDITIONS**

- Albinism
- Aniridia
- Microphthalmos
- Iris coloboma
- Corneal scars/opacities

97751-29S.PPT

8L397751-29

**Therapeutic and Prosthetic Lenses**

Conditions requiring cosmetic lenses are similar in both adults and children. Contact lenses can be used in the management and cosmetic improvement of a wide range of conditions, such as aniridia, microphthalmos, albinism, corneal scars, and iris coloboma.

Albinism (slide 42) is associated with photophobia, nystagmus, as well as high ametropia and astigmatism. Tinted soft or rigid contact lenses may be helpful, especially by reducing light transmission through the unpigmented iris, even though they often do not significantly improve the VA compared with spectacles.

Cases of iris coloboma and aniridia require opaque iris tinted lenses, even if there is no improvement in vision.

A microphthalmic eye may be improved cosmetically by fitting a scleral lens. A high plus soft lens with a standard cosmetic tint may also provide a satisfactory result with microphthalmos.

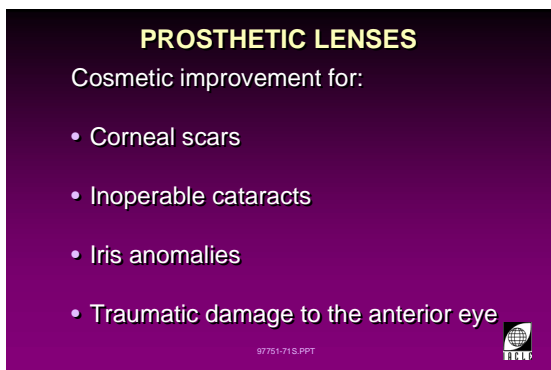
Bandage contact lenses can be used to reduce ocular discomfort caused by corneal lacerations. These lenses may also be beneficial in several rare paediatric corneal dystrophies.

42



8L3190-91

43



**PROSTHETIC LENSES**

Cosmetic improvement for:

- Corneal scars
- Inoperable cataracts
- Iris anomalies
- Traumatic damage to the anterior eye

97751-71S.PPT

8L397751-71



### III Paediatric Contact Lenses

44

#### LENS SELECTION

- Silicone elastomer
- Hydrogel
- Siloxane hydrogel
- Rigid gas permeable
- Hybrid
- Scleral



8L397751-55

45

#### LENS SELECTION CRITERIA

- Ability to provide visual correction
- Ease of fitting and handling
- Cost
- Comfort
- Deposit resistance



8L397751-43

46

#### LENS SELECTION CRITERIA

- Oxygen transmission
- Ease of lens replacement (and manufacture)
- May need to consider certain conditions, e.g.
  - keratoconus requires RGPs
  - albino eyes require darker therapeutic tints
  - aniridia may need an artificial pupil
- Required wearing schedule



8L397751-48

47

#### SILICONE ELASTOMER LENS ADVANTAGES

- Excellent physiological performance
- Good durability and handling
- Corneal adherence problems



8L397751-6

#### Paediatric Contact Lenses

Contact lenses provide some significant advantages over spectacles when fitting the paediatric patient.

These include:

- Better cosmetic effect.
- Better field-of-view.
- Minimized magnification in high plus powers.
- More likely to remain in place.

A wide range of contact lenses is available for fitting the paediatric patient.

Selection of the most appropriate lens is dictated by many factors, including:

- Nature of the ocular problem.
- Refractive error.
- Oxygen transmission.
- Required wearing schedule (part-time or full-time, daily wear [DW] or extended wear [EW]).
- Cost.
- Ease of handling and manufacture.
- Deposit resistance.

#### Silicone Elastomer Lenses

Silicone elastomer lenses have an important, though somewhat limited, role to play in paediatric fitting. A major advantage over most other lenses is the very high oxygen transmissibility of the material. As such they are ideal for high refractive errors such as in cases of aphakia.

Other advantages of silicone elastomer lenses include:

- They are very durable and can withstand most handling and cleaning procedures.
- Easier to handle compared with hydrogel lenses.
- Easier to insert, especially in cases of small palpebral apertures.

48

### SILICONE ELASTOMER LENS DISADVANTAGES

- Expensive
- Limited parameters
- Short life span
  - deposit build-up (lipids)
  - alcohol-based cleaner/good wetting agent for storage
  - poor wettability



8L397751-57

- The child cannot easily rub the lenses out of the eye.
- Less likely to be lost.
- No dehydration of the material occurs during wear.

Although silicone elastomer lenses have very high oxygen transmissibility, their usefulness has been limited by their tendency to become heavily deposited and also to adhere to the cornea during wear.

Other disadvantages of silicone elastomer lenses include:

- Very few manufacturers are producing such lenses, so they are not readily available.
- They are more expensive than hydrogel or RGP lenses. They also need to be replaced fairly regularly due to eye growth, refractive changes, and their short lifespan.
- Limited parameters are available to the practitioner for fitting the paediatric patient.
- The lenses must be replaced on a regular basis due to the build-up of deposits and the reduction in lens wettability.
- Lens removal may be difficult due to the great capillary attraction between the eye and the silicone rubber, which may also lead to red eye problems in some cases.

49

### SILICONE ELASTOMER LENSES

- Lens total diameter 11.5 or 12.0 mm
- BOZR from 7.30 mm
- Stock designs only

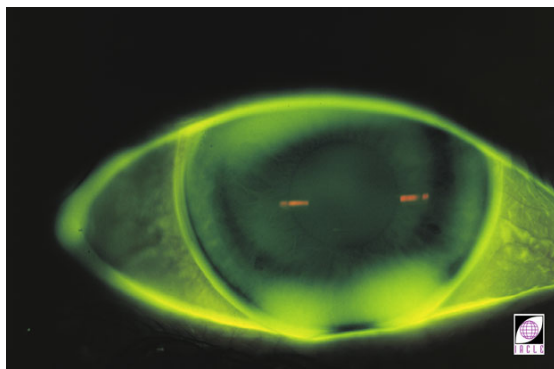


8L397751-58

The initial trial lens is usually about 0.40 mm to 0.60 mm flatter than the average corneal radius (K readings). Although somewhat dependent on age, should keratometry readings not be available, 0.5 mm can be added to the HVID to select the initial lens. Silicone rubber lenses that are too tight may be extremely difficult to remove.

Fitting assessment of these lenses is best achieved using sodium fluorescein and a cobalt blue light source (slide 50). Immediately after lens insertion, the fluorescein pattern should show minimal apical clearance and some degree of peripheral clearance. The fitting should be checked 10 and 60 minutes later to observe any changes in the fitting pattern.

50



8L30612-93

A key to successful fitting is the maintenance of lens movement. Movement of around 0.5 mm after a blink is optimal. The practitioner must always check the fitting to determine if there is any indication that the lenses are binding to the cornea.

Over-refraction using retinoscopy and loose trial lenses should establish the optimum contact lens BVP for distance vision. The practitioner may then elect to increase the BVP by +2.00 D to +3.00 D to ensure optimal near vision. This additional correction to optimise near vision could also be incorporated into bifocal spectacles.

Aphakic children should be supplied with either contact lenses or spectacles that contain a UV filter. This is important because removal of the crystalline lens, which plays a role in ultraviolet absorption, leads to an increase in UV radiation incident on the retina.

51

### SILICONE ELASTOMER LENSES FITTING ASSESSMENT

- Movement characteristic is important
- Check with fluorescein
- Edge fluting
- Longer trial fitting required
- Retinoscopy to evaluate BVP




8L397751-7

52

**HYDROGEL LENSES**

- Most commonly used
  - initial comfort
  - ease of fitting
- Stock *versus* custom designs
- Fewer deposit-related problems with HWC materials
- Physiological concerns



8L397751-59

**Hydrogel Lenses**

Hydrogel materials are most commonly used for paediatric contact lens fitting. They usually work well, especially in patients who are not tolerant of the initial discomfort experienced when trying rigid lenses.


There are a number of potential difficulties associated with the manufacture of hydrogel lenses for children, including:

- Variable hydration of the material.
- Lack of precision in measuring the lens parameters.
- Need for thick, small lens designs.

53

**HYDROGEL LENSES DESIGN FEATURES**

- Lens Total Diameter 12.5 or 13.0 mm
- Large BOZD
- BOZR range 7.0 to 8.0 mm
- HWC for rigidity
- Tint and UV blocker if available
- Custom and stock designs



8L397751-60

High water content lenses are used in many cases to ensure adequate oxygen transmissibility. However even the best high water content materials are unable to provide an oxygen supply to the cornea that satisfies the criteria for safe EW.


Hydrogel materials that incorporate an ultraviolet blocker are advantageous, especially in cases of aphakic correction due to the loss of the ultraviolet filter protection provided by the crystalline lens.

Selection of the optimum contact lens parameters should be dictated by the physical fitting characteristics of the lens. There are no set guidelines for choosing the lens parameters.

54

**HYDROGEL LENSES FITTING ASSESSMENT**

- Quality of centration and movement
- Slightly tight fitting is preferred
- Evaluate retinoscopic reflex



8L397751-8


A key determinant of a successful fitting is the quality of lens centration. In cases where a very highly powered small diameter lens is required, the centration must be optimized to ensure that the optical zone of the lens is over the pupil.

Daily disposable lenses, which eliminate the need for lens cleaning and disinfection, are a good choice for older children and teenagers (Walline *et al.*, 2004). Not only is this a more convenient option that also improves compliance, but at the same time it also forces children to learn to how to insert and remove their contact lenses.

55

**SILOXANE HYDROGELS**

- Ability to provide high oxygen transmission
  - much greater than hydrogels
- Ease of handling
- Ease of lens replacement
  - compared with silicone elastomer
- Parameter range is increasing
- Good extended wear capability



8L397751-78

**Siloxane Hydrogel Lenses**

The development of siloxane hydrogel contact lens materials has increased significantly the fitting options available for paediatric cases.

A major advantage of these lenses is the high oxygen transmissibility that makes them suitable for EW. They are also a good option to consider for DW.


For aphakic cases in particular, it is hoped that these materials will become available in high powers and smaller diameters, and that they will eventually supersede the silicone elastomer lenses.

56

**RGP LENSES**

- Physiological advantages
- Handle well
- Ease of care and maintenance
- Custom fitting difficulties
- Risk of mislocation and dislodgement

97751-61S.PPT




8L397751-61

57

**RGP LENSES  
DESIGN FEATURES**

- Lens Total Diameter 8.0 to 10.5 mm
- Large BOZD
- BOZR equal to flattest corneal curvature
- Reasonable centre and edge thickness for durability
- Tint and UV blocker if available

97751-62S.PPT




8L397751-62

58

**RGP LENSES  
FITTING ASSESSMENT**

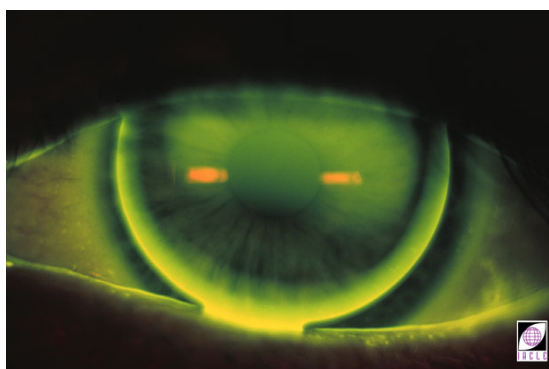
- Lens needs to be stable
- Evaluate with fluorescein

97751-68S.PPT



8L397751-9

59



8L31150-99

### Rigid Gas Permeable (RGP) Lenses

The development of highly oxygen permeable RGP materials has made these lenses a safe and effective mode of correction for young children. They provide a much better physiological environment for the cornea than conventional hydrogel lenses, as well as reduced bacterial and protein adherence. Highly oxygen transmissible RGP materials are probably the best option for children when EW is required.

Furthermore, rigid lenses can be manufactured in a wide range of parameters and powers. RGP lenses are also easier to handle than soft lenses, as they do not fold up or invert.

Generally, rigid lenses provide better VA than hydrogels, and they are also capable of compensating for irregular corneal astigmatism. They can be custom fitted using traditional techniques utilizing fluorescein and cobalt blue light from a Burton lamp or slit-lamp biomicroscope (slides 59, 60).

For these reasons, RGPs are often the first choice when fitting contact lenses to the young.

The main difficulty for an infant wearing RGP lenses is the common sensation of a trapped foreign body that causes discomfort or pain. The infant is unable to describe or understand the nature of the irritation.

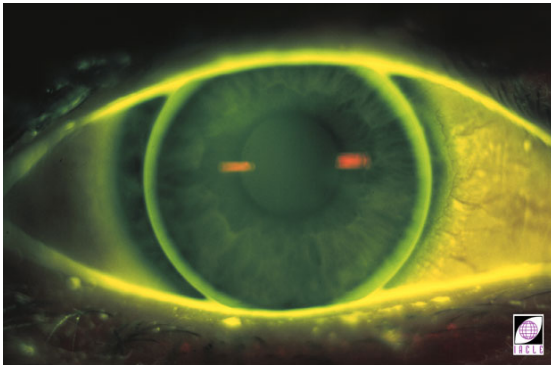
Rigid lenses are also more likely to be dislodged or ejected from the eye (slide 59 shows a RGP lens engaging the lower lid margin, a risk factor for lens ejection or dislodgement). Corneal insults from eye rubbing are also a potential problem with rigid lenses.

RGP lens design is dictated by many factors. The most important of these include:

- Age of the child.
- BVP required.
- Corneal shape.

Whatever the design chosen, the practitioner must assess carefully the on-eye fitting characteristics after a suitable period of lens settling.

60




8L31762-93

61

**HYBRID LENSES  
INDICATIONS**

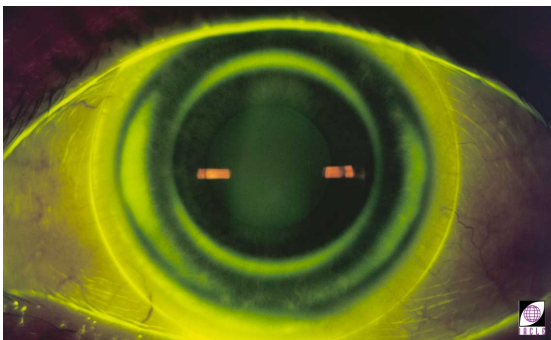
- Astigmatism, irregular corneas and keratoconus
- Intolerance of RGPs
- High ametropias

97751-10S.PPT



8L397751-10

62




8L1022-94

63

**HYBRID LENSES  
FITTING**

- Minimum of 0.25 mm movement
- Absence of limbal impingement
- Patient comfort

97751-11S.PPT



8L397751-11

### Hybrid Lenses

The SoftPerm<sup>®</sup> lens is currently the only commercially available hybrid contact lens design. It incorporates the features of both hydrogel and RGP lenses (slide 62) and has been used with success in some paediatric fitting. It is available in powers ranging from +6.00 D to -13.00 D.

The major disadvantages of this lens are:

- It has a tendency to adhere to the eye, and can be difficult to remove.
- It may tear in the transition zone between the soft skirt and RGP centre.
- Low oxygen transmissibility leading to complications such as oedema and neovascularization.
- The need to use high molecular weight fluorescein to observe the fitting pattern.

Another entrant into this category of lens has been described recently (2005) but few details of the product (SynergEyes) have been released. The lens has a high Dk rigid centre with a hydrophilic, non-ionic soft skirt. It has been FDA approved to treat ametropia from -20.00 D to +20.00 D with up to 6.00 D of astigmatism. The manufacturer claims its technology makes the interface between the soft and rigid portions of the lens durable and comfortable.



64

**SCLERAL LENSES**

- Small percentage of paediatric patients
- More difficult to insert and remove
- Discomfort
- Minimal lens loss or accidental removal

97751-65S.PPT



8L397751-65

**Scleral Lenses**

Scleral lenses are rarely used for paediatric cases but can be utilized successfully by a motivated practitioner.

The fact that these lenses can be manufactured from highly oxygen permeable materials makes them a good choice for the paediatric patient. There is very little likelihood of lens loss or accidental displacement compared with hydrogel or RGP lenses.

The lens shape and power can be modified as the child's eye develops and changes topography.

The technique for lens insertion and removal are slightly more involved and challenging than for hydrogels or RGP lenses. When fitting scleral lenses, the child's parents must be adequately trained to care for, maintain, and insert and remove the lenses.



## IV Pre-Fitting Evaluation

65

### OCULAR MEASUREMENTS

Need to know:

- Refractive error
- Corneal curvature
- Corneal diameter

97751-3S.PPT



8L397751-3

### Pre-Fitting Evaluation

A full ocular examination is required when fitting contact lenses to children. However, it is usually more difficult to obtain accurate information about the ocular characteristics of a child than it is for an adult.

Practitioners must use all the techniques available to them to ascertain the ocular requirements and dimensions prior to contact lens fitting.

Some children may be very apprehensive and need a lot of reassurance (as do their parents in many cases).

66

### REFRACTIVE ASSESSMENT OBJECTIVE TECHNIQUES

- Detection, resolution, recognition
- Retinoscopy
  - static
  - dynamic
- Cycloplegic
- Auto-refraction
- Photo-refraction

97751-52S.PPT



8L397751-52

### Refractive Assessment

Refractive error assessment of most infants and young children is made by retinoscopy, utilizing both static and dynamic techniques. It is advisable to assess the child in a number of different ways, using various techniques to obtain the most accurate refractive error information.

A cycloplegic examination is often performed to ensure that the accommodative mechanism does not produce a false result.

In older children, the use of standard subjective refraction examination techniques may be applicable. The decision to use any specific technique must be made by the practitioner on a case-by-case basis.

67

### REFRACTIVE ASSESSMENT SUBJECTIVE TECHNIQUES

- Full subjective refraction based on:
  - level of comprehension
  - age
  - interaction

97751-4S.PPT



8L397751-4

68

### MEASURING CORNEAL CURVATURE

- Keratometry
- Videokeratometry
- Keratometry
- Based on child's age
- Trial and error lens fitting

97751-53S.PPT



8L397751-53

### Measuring Corneal Curvature

Hand-held keratometers simplify the assessment of corneal shape in young children and should be used wherever possible. A conventional keratometer can be used with the child lying down on their side, and then simply interchanging the measurements in the vertical and horizontal meridians.

Knowledge of the corneal radius is important when fitting rigid lenses. For hydrogel lens fitting, however, assessment of the lens fitting characteristics are perhaps more important than knowing the precise corneal shape.

It is usually neither possible nor easy to obtain accurate keratometry measurements in children. In non-traumatized corneas it is possible to use age norms for corneal curvature as a starting point for lens fitting.

The central corneal curvature of infants is usually steep:

- 47.00 D (7.18 mm) to 50.00 D (6.75 mm) in the first 1 to 2 months.
- By 3 to 4 years of age, the cornea flattens to between 43.00 D (7.85 mm) and 44.00 D (7.67 mm), except in cases of retinopathy of prematurity, where the value remains steep.

69

### MEASURING CORNEAL DIAMETER

- Hand-held rule
- Based on the horizontal visible iris diameter (HVID)
- Trial and error lens fitting

97751-54S.PPT



8L397751-54

### Measuring Corneal Diameter

In most cases, it is possible to obtain an accurate assessment of the corneal diameter by measuring the HVID with a hand-held rule or similar device.

The average corneal diameter at birth is about 9.8 mm. Corneal diameter increases rapidly in the first year of life, then slows over the next few years, until reaching an adult diameter of about 12 mm by 3 to 4 years of age.

SCLs are usually made about 2 to 2.5 mm larger than the HVID. If it is not possible to obtain such a measurement, the first trial lens fitted to the eye can act as a guide to obtain subsequently the optimum lens diameter.

Sometimes, it is necessary to fit lenses of smaller or larger diameter to achieve adequate lens centration, depending on factors such as lid tonus, scleral and peripheral corneal topography.

70

### OTHER TESTS

- Ocular motility
- Fixation stability
- Assessment of visual potential

97751-55.PPT



8L397751-5

### Other Ocular Tests

A full evaluation of the child's ocular status is required before contact lens fitting. Numerous tests can be employed to determine the level of binocular vision, range of eye movements (slides 71 and 72), and potential level of visual outcome with contact lenses.

The cover-uncover test should be normal, and the corneal light reflex should be investigated to confirm normal ocular alignment.

Several computer aided programs and software are available today for the evaluation and treatment of binocular vision function, and children generally seem to enjoy these.

Evaluation of stereopsis may also be a useful indicator of binocular function.

71



8L3326-93

72



8L3325-93

## V Lens Application and Removal

73

### LENS APPLICATION TECHNIQUES

- Appropriate child restraint
- Pacification of the child
- Sedation, anaesthesia may be required
- Lens assessment for foreign matter
- Creating lid gap
- Apply lens under the top lid
- Teaching child/parents



8L397751-33

### Lens Application Techniques

Application and removal of a contact lens in very young paediatric patients can be difficult for both the practitioner and parents. Deep-set eyes are the most difficult to deal with for both lens insertion and removal.

Ideally, the child should be as calm as possible prior to lens application or removal. This can be promoted with the use of a pacifier or bottle.

Some children are also scared of the doctor's white coat, so in some cases it might be useful to remove the coat to put the child more at ease.

It is vital that the parents are involved fully at every stage of the contact lens fitting procedure.

It might be useful getting the parents to hold the child's hands and shoulders down, while the practitioner holds the baby's head and inserts the lens.

In the case of infants or very young children, it is sometimes necessary for one or two people to hold the child's arms and shoulders down, while another person pulls the lids apart and inserts the lens. It is therefore a good idea to involve both parents where possible.

The child can also be wrapped in a towel or blanket to restrain him/her, in which case only one person is needed to insert the contact lens.

Following the insertion of an RGP lens, it is recommended that the patient's eyelids be not released immediately. This is to demonstrate to them that the lens does not scratch or damage the eye and that any initial discomfort is due to the lids interacting with the lens edges. They may need to be reassured that they will get used to the feeling (adaptation).

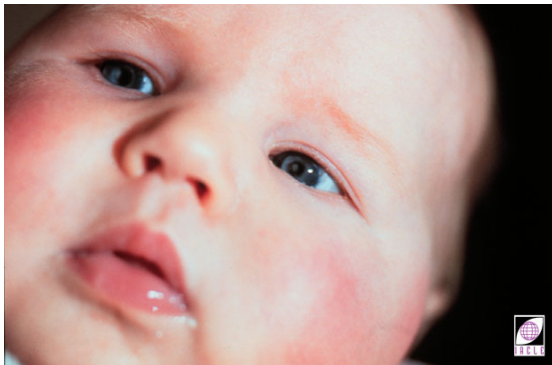Parents must learn the technique of applying and removing the lenses (slide 75), especially if children are not old enough to do this by themselves. The initial learning process is often stressful and frustrating for both the child and the parents, but most families eventually learn to cope well. It could be said they have little choice in the matter if vision correction is essential.

The practitioner should take every opportunity to teach the parents alternative methods of handling the child's contact lenses. This makes them feel much more confident of being able to cope with any difficulty that may arise.

Following their instruction session, parents should be supervised during the initial contact lens insertion. They should be encouraged to seek help should problems arise when they get home.

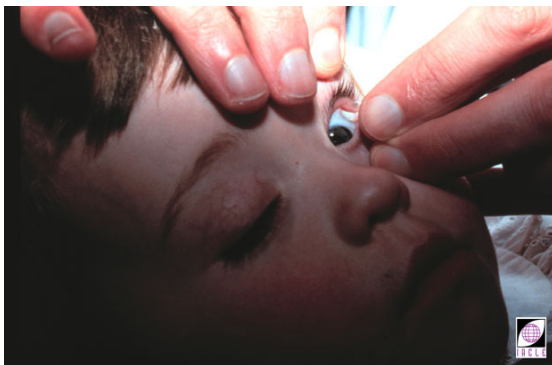Older children can be taught to handle and care for their own lenses, with appropriate guidance from their contact lens practitioner and their parents.

74



8L30587-94

75



8L30638-94

76

### LENS REMOVAL TECHNIQUES

- Teaching child/parents
- Breaking the 'suction'
  - using the lid margins
  - slide and pinch
- If unsuccessful, wait then try again

97751725.PPT



8L397751-72

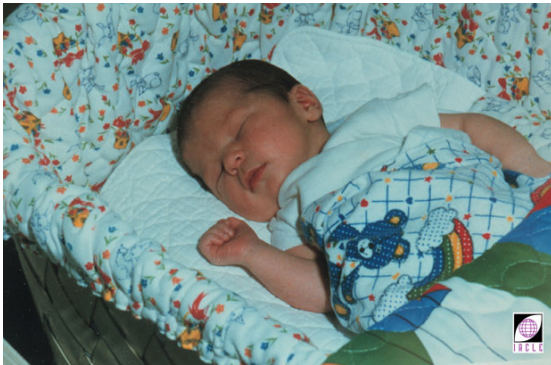### Lens Removal Techniques

Lens removal is usually a much simpler procedure than insertion. Manipulating the child's eyelids to break the 'suction' (overcoming the negative pressure generated under a lens during its removal) and then lifting the lens out with the aid of the lids is usually all that is required to remove RGP lenses.

With SCLs, a slight squeeze between the thumb and forefinger is usually all that is required for removal.

Regardless of lens type, as the child gets older and more comfortable with lens insertion and removal, they can be handed the responsibility for doing most routine procedures themselves.

77



8L31098-91

In some cases, a modified technique is needed based on the degree of cooperation of the child. For example, a hydrogel lens may need to be removed in a manner similar to that of an RGP lens due to the limited interpalpebral space available.

Silicone elastomer lenses can be difficult to remove due to their tendency to become tighter fitting or to adhere to the cornea. In these cases, the 'suction' must be broken before attempting to remove the lens. This can be achieved by pressing a lid margin against the lens edge to lift the lens slightly off the eye and to allow air to fill the space underneath the lens.

If the child becomes uncooperative when lenses are either being applied or removed it is best to let the child calm down before trying again.

In infants younger than 6 months of age, parents often find it easier to insert and remove contact lenses when the child is asleep (slide 77).

Written instructions must be supplied to the parents to assist them with lens application and removal.

Many children are able to remove and sometimes even insert their contact lenses at the age of 5 or 6 years. They should be encouraged to learn these techniques as soon as possible.



## VI Follow-Up, After-Care, and Management

78

### LENS CARE PROCEDURES

- Same as for adults
- Education of child and guardian(s)
- Degree of involvement in the child
- Increasing the level of responsibility of the child
- Err towards frequent replacement of solutions

97751-34S.PPT



8L397751-34

### Lens Care Procedures

The care regimen must be suited to the type of lens worn by the child. For most wearers there is no difference in the type of solutions used by children and adults.

The parents must be educated fully regarding the need for lens care, including the frequent replacement of lenses, solutions, and lens cases.

It is also important for them to understand the need to minimize the risk of lens-related complications such as microbial infection and papillary conjunctivitis, as these can affect or even prevent future contact lens wear.

As the child develops they can take greater responsibility for all aspects of lens care and maintenance.

79

### LENS WEARING SCHEDULE

- Daily wear (DW)
- Flexible wear (FW)
- Extended wear (EW)
- Continuous wear (CW)

97751-73S.PPT



8L397751-73

### Lens-Wearing Schedule

Selection of the lens-wearing schedule for a child must be done on a case-by-case basis.

The practitioner needs to decide whether DW, occasional overnight wear flexible wear, EW or continuous wear would be the best option.

Many factors need to be considered when making this decision and these include:

- Lens type prescribed for the child's condition.
- Ability to insert and remove lens.
- Level of assistance from parents/guardian.
- Importance of the need for full-time wear.
- Oxygen transmissibility of the lens.

The initial lens adaptation schedule with RGP lenses is usually slower than that for SCLs. Therefore, rigid lenses are worn initially for 3 to 4 hours on the first day, and wear is increased by 1 to 2 hours each day thereafter until all-day wear is achieved.

EW of highly oxygen permeable lenses is an excellent choice for the very young, as it eliminates the need for daily lens insertion and removal, regular handling of the lenses, and lens care procedures.

However EW also carries a significantly greater risk of complications, and the child should therefore be monitored carefully, especially for asymptomatic changes such as neovascularization.

Another disadvantage of an EW schedule is that the patient does not become as proficient in handling their lenses.

It is advisable to have a spare set of lenses available in case of lens loss or breakage, especially in young infants with high refractive errors.

80

### EXTENDED WEAR RISK vs RESULTS

- Ease of management if no complications occur
- Long-term asymptomatic changes
- Acute adverse complications
- Lens handling skills are not optimized
- Selected cases for short-term use

97751-35S.PPT



8L397751-35



81

**FOLLOW-UP SCHEDULE**

- Frequent visits required
- Numerous factors dictate schedule
  - age
  - reason for fitting
  - competency of child/parent



97751-36S.PPT

8L397751-36

**Follow-Up Schedule**

Frequent follow-up is needed in all cases of paediatric contact lens fitting. This is especially so in cases of infants who are unable to communicate the nature of any ocular and/or lens discomfort to their parents or practitioner.

The contact lens practitioner must be confident that the child's parents are committed fully to the role they must play in ensuring a successful outcome.

The parents must be instructed to bring the child in for examination whenever there is unusual ocular redness and/or discharge.

82

**AFTER-CARE**

- Lens performance:
  - optical
  - physical
  - physiological
  - lens tolerance
  - loss rate



97751-74S.PPT

8L397751-74

**After-Care**

Contact lens fitting is not complete until subsequent examinations confirm a satisfactory lens fit with minimal or no physiological disturbances to the eye.

The first after-care appointment is usually scheduled for a week after the initial contact lens dispensing.

The level of tolerance of the contact lenses is an important component of the after-care evaluation. Where possible, both the child and the parents should be questioned regarding the level of comfort experienced with the lenses.

Practitioner evaluation of the physical lens fitting characteristics and any adverse effects on ocular physiology is mandatory at every opportunity. The practitioner must not rely on patient and/or parent testimony alone.

The practitioner should never forget to evaluate the child's eyes for conditions other than contact lens performance. Such conditions may include:

- Integrity of sutures.
- IOP.
- Retinal health.

During after-care visits, it is also important to review the patient's progress, lens condition, and the lens handling techniques employed, even if the parents are doing the insertion and removal.

If everything is going well, the second after-care visit is usually scheduled 2 weeks later.

Follow-up appointments every 6 months after that are usually recommended.

83

**AFTER-CARE**

- Frequent evaluation is required
- Refractive alteration
- Topographical changes
- Lens refitting
- Psychological effect of lens fitting on the child
- Non-lens related issues



97751-75S.PPT

8L397751-75

84

### CL COMPLICATIONS

- Similar to adult
- Not self-reporting
- Mechanical
- Hypoxia

97751-76S.PPT



8L397751-76

### Complications and their Management

Complications are just as likely to occur among children wearing contact lenses as they do in the adult population.

The very young child cannot report the onset of an ocular or lens problem. The parents must be vigilant and should always be looking for signs of problems. These may include:

- Redness.
- Discharge.
- Dull lens surface indicating the presence of deposits.
- Increased eye rubbing.
- Increased crying.

The major complications that the practitioner must look out for include:

- Infection of the cornea and/or conjunctiva.
- Photophobia.
- CLPC.
- Vascularization of the cornea.

Many children experience photophobia with contact lens wear, especially in the initial stages. Once other causes have been excluded, it is usually sufficient to reassure the parents that this is not uncommon.

85

### PARENTAL INSTRUCTION

- Crucial component of successful paediatric lens wear
- Total involvement needed at all stages
- Knowledge of lenses and lens care

97751-37S.PPT



8L397751-37

### Parental Instruction

Total involvement of parents in the contact lens-wearing experience of their child is vital to maximize the chance of success.

The practitioner must recognize the role that parents have to play and needs to provide as much instruction to them as they would receive if they were being fitted with contact lenses themselves.

If the parents have no prior experience with contact lens wear they should be taught how to handle, insert, and remove lenses from their own eyes before learning the skills involved in assisting their child with their contact lenses. The parents must be competent and confident to be able to deal with emergency situations as they arise during lens wear.

Instruction of parents should include the following:

- Normal lens performance characteristics.
- Signs of adverse reactions.
- Appropriate emergency responses.
- Proper use of solutions.
- Lens handling.
- Likely loss or damage to lenses resulting in higher costs.

86

### PARENTAL INPUT

Parental assessment of:

- Lens performance
- Child's response to lens wear
- Complications

97751-38S.PPT



8L397751-38

### Parental Input

Prescribing contact lenses for children necessitates good cooperation between the child, the parents, and the practitioner.

In many cases the child wearing contact lenses is unable to provide feedback to the practitioner regarding the level of success experienced with their lenses. It is, therefore, vital that the child's parents or guardian are actively involved in monitoring contact lens performance and observing the child's eyes for signs of complications.

Contact lens wear will not always be possible or successful for some children. Further, in some cases an infant may start out successfully but as they grow they may start to rebel against the use of lenses. The practitioner must decide for each case whether transferring the child to spectacles is a better option.

Successful contact lens wear can improve both the vision and the quality of life of the paediatric patient. This can be very rewarding for the child, the parents, and the contact lens practitioner.

87

### PAEDIATRIC CONTACT LENSES

- Always consider individual case – contact lenses vs spectacles
- Successful contact lens wear can improve vision and quality of life for the child
- Rewarding for the child, parents, and contact lens practitioner

97751-48S.PPT



8L397751-49



## References

- Aasuri MK, Venkata N, Preetam P, Rao NT (1999). *Management of pediatric aphakia with silsoft contact lenses*. CLAO J. 25: 209 – 212.
- Amos CF, Lambert SR, Ward MA (1992). *Rigid gas permeable contact lens correction of aphakia following congenital cataract removal during infancy*. J Pediatr Ophthalmol Strab. 29: 243 – 245.
- Atkinson J, Braddick OJ, Durden K, et al. (1984). *Screening for refractive errors in 6-9 month old infants by photorefractometry*. Br J Ophthalmol. 68: 105 – 112.
- Baldwin WR (1990). *Refractive status of infants and children*. In: Principles and Practice of Paediatric Optometry. JP Lippincott, Philadelphia.
- Burger D (2004). *Contact lenses and little ones: Practical applications*. 11<sup>th</sup> International Contact Lens Congress, Cypress Lakes, Australia, 14 –19 March 2004.
- Catania LJ, Fingeret M, Beatty RL, White KG (1979). *Primary eye care of the pediatric patient*. J Am Optom Assoc. 50: 1201 – 1206.
- Chia A, Johnson K, Martin F (2002). *Use of contact lenses to correct aphakia in children*. Clin Exp Ophthalmol. 30: 252 – 255.
- Cutler SI, Nelson LB, Calhoun JH (1985). *Extended wear contact lenses in pediatric aphakia*. J Pediatr Ophthalmol Strab. 22: 86 – 91.
- De Brabander J (2002). *A practical approach to and long-term results of fitting silicone contact lenses in aphakic children after congenital cataract*. CLAO J. 28: 31 – 35.
- De Brabander J, Kok J, Nuijts R, Wenniger-Prick L (2002). *A Practical Approach to and Long-Term Results of Fitting Silicone Contact Lenses in Aphakic Children after Congenital Cataract*. CLAO J. 28: 31 – 35.
- Ehrlich MI, Reinecke RD, Simons K (1983). *Preschool vision screening for amblyopia and strabismus: Programs, methods, guidelines*. Surv Ophthalmol. 28: 145 – 163.
- Ezekiel D (1995). *A gas-permeable paediatric aphakic scleral contact lens*. Optician. 35 (5): 25 – 27.
- Fern KD, Manny RE (1986). *Visual acuity of the preschool child: A review*. Am J Optom Physiol Opt. 63: 319 – 345.
- Gasson A, Morris J (2003). *Contact Lenses and Children*. In: The Contact Lens Manual. Butterworth-Heinemann, Oxford.
- Holmström G, Speedwell L, Taylor D (1990). *Contact lenses – still the only solution for infant aphakia*. Eur J Implant Ref Surg. 2: 265 – 267.
- Joslin CE, McMahon T, Kaufman L (2002). *The effectiveness of occluder contact lenses in improving occlusion compliance in patients that have failed traditional occlusion therapy*. Optom Vis Sci. 79: 376 – 380.
- Joubert L (2003). *Contact lens wear and children*. Eyesite Magazine, Nov 2003, 58 – 59.
- Joubert L (2004). *Setting up a practice geared towards paediatric vision*. Eyesite Magazine, April 2004, 22 – 23.
- Katz J, Schein OD, Levy B, Cruisculo T, Saw SM, Rajan U, Chan TK, Yew Khoo C, Chew SJ (2003). *A randomized trial of rigid gas permeable contact lenses to reduce progression of children's myopia*. Am J Ophthalmol. 136: 82 – 90.
- Ma JJ, Morad Y, Mau E, Brent HP, Barclay R, Levin AV (2003). *Contact lenses for the treatment of pediatric cataracts*. Ophthalmology. 110: 299 – 305.
- McDonald MA (1986). *Assessment of visual acuity in toddlers*. Surv Ophthalmol. 31: 189 – 210.
- Moore BD (1985). *The fitting of contact lenses in aphakic infants*. J Am Optom Assoc. 56: 180 – 183.
- Moore BD (1996). *Managing young children in contact lenses*. CL Spectrum. May: 34 – 38.
- Morris J (1979). *Contact lenses in infancy and childhood*. Contact Lens J. 8: 15 – 18.

Morris JA, Taylor D (1994). *Contact lenses for children*. In: Ruben M and Guillon M (Eds). *Contact Lens Practice*. Chapman & Hall, London.

Ozbek Z, Durak I, Berk TA (2002). *Contact lenses in the correction of childhood aphakia*. *CLAO J.* 28: 28 – 30.

Perrigin J, Perrigin D, Quintero S, Grosvenor T (1990). *Silicone-acrylate contact lenses for myopia control: 3-year results*. *Optom Vis Sci.* 67: 764 – 769.

Rhodes LJ, Hittner HM (1987). *Challenges of pediatric contact lens fitting*. *CL Spectrum.* Oct: 25 – 29.

Shaughnessy MP, Ellis FJ, Jeffery AR, Szczotka L (2001). *Rigid gas-permeable contact lenses are a safe and effective mode of treating refractive abnormalities in the pediatric population*. *CLAO J.* 27: 195 – 201.

Speedwell L (1997). *Contact lens fitting in infants and pre-school children*. In: Phillips AJ, Speedwell L (Eds). *Contact Lenses*. Butterworth-Heinemann, Oxford.

Suttle CM (2001). *Visual acuity assessment in infants and young children*. *Clin Exp Optom.* 84: 337 – 345.

Vision in Preschoolers Study Group (2004). *Preschool visual acuity screening with HOTV and Lea symbols: Testability and between-test agreement*. *Optom Vis Sci.* 81: 678 – 683.

Walline JJ, Long S, Zadnik K (2004). *Daily disposable contact lens wear in myopic children*. *Optom Vis Sci.* 81: 255 – 259.

Zikoski E (1993). *Methods of correction for pediatric aphakia*. *CL Spectrum.* June: 51 – 57.

## Unit 8.4

(4 Hours)

**Lecture 8.4:** Aphakia and Contact Lenses

**Practical 8.4:** Aphakic Contact Lens Fitting and Assessment



## Course Overview

### Lecture 8.4: Aphakia and Contact Lenses

- I The Aphakic Patient
- II Pre- and Post-operative Considerations in Aphakia
- III Contact Lens Correction of Aphakia
- IV After-Care and Patient Management

### Practical 8.4: Aphakic Contact Lens Fitting and Assessment

- Lens Types
- Instrumentation
- Procedures



# Lecture 8.4

(2 Hours)

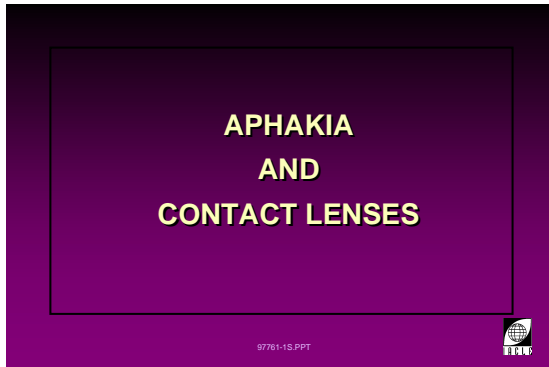
## Aphakia and Contact Lenses

## Table of Contents

<b>I</b>	<b>The Aphakic Patient .....</b>	<b>183</b>
<b>II</b>	<b>Pre- and Post-operative Considerations .....</b>	<b>187</b>
<b>III</b>	<b>Contact Lens Correction of Aphakia.....</b>	<b>190</b>
III.A	Contact Lens Fitting Options and Considerations .....	190
III.A.1	RGP Lens Designs .....	193
III.A.2	Hydrogel Lens Designs.....	200
III.A.3	Siloxane Elastomer Lenses .....	201
III.A.4	Scleral Lenses .....	202
<b>IV</b>	<b>After-Care and Patient Management .....</b>	<b>203</b>

## I The Aphakic Patient

1



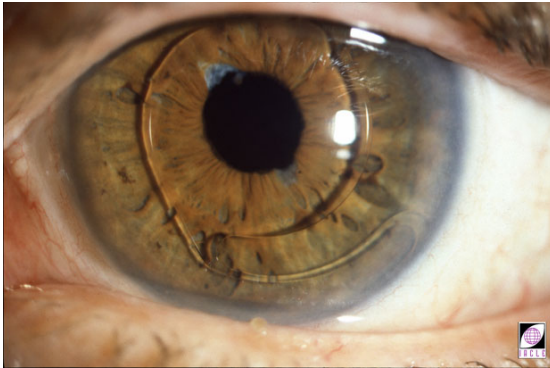
8L497761-1

### The Aphakic Eye and Contact Lens Fitting

The rapid developments in Intraocular Lens (IOL) implantation have resulted in the procedure becoming the preferred treatment for cataract. However, the rise of IOL usage has meant an attendant reduction in the number of aphakic contact lenses fitted post-operatively.

On balance, this is probably beneficial to all concerned. To the patients the benefits are physiological, optical, visual, and probably psychological. To the contact lens practitioner the use of thick, high-plus contact lenses with poor physiological performance was difficult, the complications predictable, and the additional monitoring they required, a relatively unproductive use of chair time.

2



8L40654-98

In cases where IOL implantation is impossible, e.g. congenital cataract cases, the aphakic patient requires either contact lenses or spectacles. Due to the significant optical side effects/disadvantages and the poor cosmesis of high plus-powered spectacles, the use of contact lenses is generally the preferred option, albeit second choice after IOL implantation.

Furthermore, aphakes who were fitted with contact lenses before the era of successful IOLs may also seek contact lens care and/or lens replacements from contact lens practitioners.

Regardless of the reasons for their use, this lecture details contact lenses for aphakes.

#### Note:

The replacement of the crystalline lens with an IOL creates the condition of pseudophakia (slide 2) and renders the patient pseudophakic. Slide 2 shows the less common anterior chamber type of IOL *in situ*. The haptics of the lens (the locating arms) are clearly visible, as is the optic.

However, the appearance of an eye with the more common posterior chamber IOL *in situ* is little different from that of a normal phakic or uncorrected aphakic eye because the obvious features (the optic and haptics) are hidden behind the iris. It is only the observation of clinical features such as iris tremulous, iris trauma, non-circular and/or eccentric pupil, etc. that the actual situation can be deciphered. In some cases, even the patient cannot provide reliable information on the status of their crystalline lenses and/or their substitution by IOLs.

3

**APHAKIA**


The absence of the normal crystalline lens due to:

- Surgery
- Trauma
- A congenital abnormality

Mislocation of the normal crystalline lens due to:

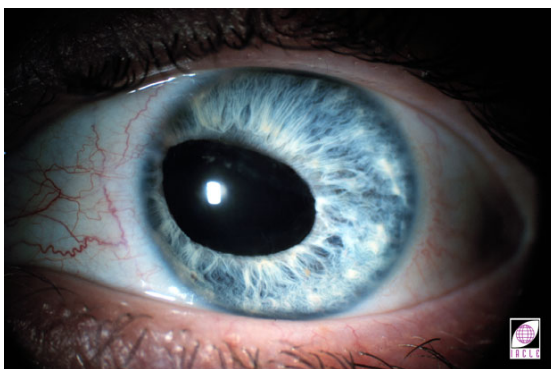
- A congenital abnormality
- Trauma
- Defect of the zonules

97761-2S.PPT



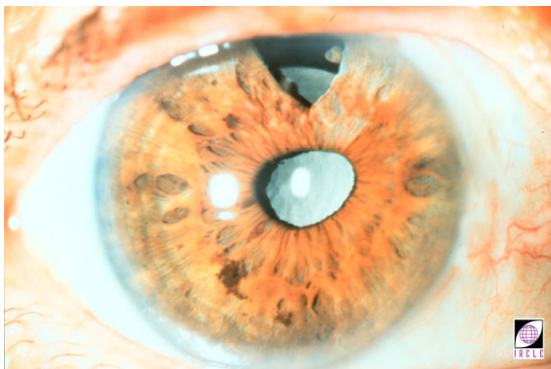
8L497761-2

4



8L40596-94

5



8L40747-95

### Definition and Classification of Aphakia

Aphakia is defined as the absence of the crystalline lens from the pupillary area (slide 3). Events leading to the loss of the crystalline lens may be traumatic or, less dramatically, diseases like diabetes or simply advancing age.

Traumatic causes include:

- Blunt force injuries rupturing the lens capsule.
- Blunt force injuries tearing the suspensory zonules and resulting in lens mislocation/subluxation.
- Penetrating injuries rupturing the capsule.
- Chemical exposure, especially to strong alkalis with or without physical access to the anterior chamber, i.e. by direct access through an opened anterior chamber (traumatic) or by diffusion along a concentration gradient from the anterior external eye to the posterior chamber. Unlike acidic chemical entities that tend to be self-limiting, an alkali keeps diffusing and constitutes a much more serious threat to the future well-being of the eye and vision sequelae.

Slide 4 shows a distorted pupil and dislocation (subluxation) of the crystalline lens secondary to trauma. Eventually, the crystalline lens was removed, creating aphakia surgically.

Other causes of cataract that may lead to surgical intervention include:

- Diabetes
- Congenital cataract in infancy.
- Radiation exposure leading to cataract at any age.
- Most commonly, so-called senile cataracts of advanced age.
- Idiopathic.


Slide 5 is an example of a congenital cataract (the Peripheral Iridectomy was performed for the management of the associated secondary glaucoma).

6

**APHAKIA**

- Patient age – the older vs. younger eye
  - metabolic rate of the cornea
  - ↓ tear production → dry eye
  - ↓ corneal sensitivity
  - ↓ lid tonus, Δ positions, ptosis?, ectropion?
- Any age:
  - loss of crystalline lens' 'filtering' role in blocking transmission of UV to the retina

97761-3S.PPT



8L497761-3

### Considerations for the Aphakic Patient

Because cataracts can result in aphakia at any age (see previously), a wide range of factors warrant consideration when dealing with an aphakic patient.

Since most aphakes are elderly, some of the physical and physiological differences between older and younger eyes are a consideration. These may include:

- Lower basal metabolic rate of the cornea.
- Decreased tear production and the potential for an associated dry eye.
- Reduced corneal sensitivity depending on the age and the type of surgery performed.

- Changes in corneal astigmatism.
- Change in upper lid tonus and position (and the possibility of ptosis developing).

Regardless of age, aphakia creates a significant decrease in the eye's ability to block transmission of UV radiation to the retina, i.e. the 'filtering' role, formerly played by the crystalline lens.

While more important in cases of paediatric aphakes (congenital cataract) in which visual development is incomplete, when doubt of the actual Rx exists, it is prudent to err on the side of excessive plus BVP so that some point within optical infinity is conjugate with the retina.

Under-correction results in no point in the visual space being imaged sharply on the retina and complaints of poor vision will ensue.

7

### PROBLEMS WITH SPECTACLES

- Magnification
- Aberrations
- Prismatic effect
  - image jump
- Visual field & field of fixation anomalies
- Anisometropia/aniseikonia
  - surgically induced anisocoria

97761-4S.PPT



8L497761-4

8

### PROBLEMS WITH SPECTACLES

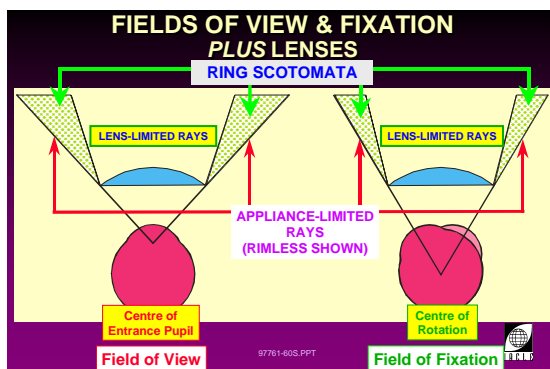
- Fusion/diplopia (from aniseikonia)
  - stereopsis
- Distortion
  - spatial localization
- Cosmesis
- Weight

97761-5S.PPT



8L497761-5

9



97761-60S.PPT



8L497761-60

### Problems with Aphakic Spectacles

Often, aphakia is unilateral and the problems of the differences between the two eyes in image size, magnification, and prism, disallow spectacles as a reasonable, functional or cosmetic option. In unilateral aphakia, in which an IOL is not an option for whatever reason, a contact lens is the remaining option of choice.

Management of aphakia with contact lenses helps to alleviate the problems associated with aphakic spectacles. These include:

- Large amounts of spectacle magnification (20 to 35%).
- An increase in peripheral aberrations with spectacle lenses (e.g. the pincushion effect in which the magnification increases from lens centre to lens edge).
- Prismatic effects (e.g. the jack-in-the-box effect in which objects jump into the field of view due to a large amount of *Base In* prism).
- A restriction of visual fields by some 30% due to the optical effects of the lens combined with the physical limitations of the appliance (spectacles) causing a ring scotoma (slide 9) (see Module 2, Lecture 2.3, Section **XI Fields of View**). Slide 9 shows a rimless (zero frame thickness) scenario. The scotoma due to a thick spectacle frame would be larger than that depicted.
- Anisometropia usually induces an attendant aniseikonia (a difference in image sizes between the two eyes). In monocular aphakia, the aniseikonia produced can be very significant. The resulting problems with binocular fusion usually result in diplopia.

During convergence, the increased amount of *Base Out* prism the eyes experience can cause a problem with aging patients who are already convergent insufficient.



Aphakic spectacle lenses, although usually aspheric in shape, still exhibit/induce peripheral distortions.

Other factors limiting the acceptability of aphakic spectacle wear include:

- The cosmesis of high plus spectacle lenses.
- The associated weight on the bridge of the nose (even in lightweight, high index materials);
- The need for regular adjustment.

## II Pre- and Post-Operative Considerations

10

### PRE-OPERATIVE CONSIDERATIONS

- Visual assessment
- Corneal/conjunctival topography
  - pre-existing astigmatism?
- Ocular health
- Refractive error
- Mental state & motivation
  - general competency



8L497761-7

11

### PRE-OPERATIVE CONSIDERATIONS

- Patient education
  - surgical options
  - need for visual correction @ D & N
  - IOLs vs. CLs vs. spectacles
- Contact lens options
  - visual needs
  - dexterity
  - DW, EW, CW



8L497761-6

### Pre-Operative Considerations

Pre-operatively, the following factors need to be assessed when trying to predict the likely surgical outcome:

- Visual assessment, expected VA (dependent on macular integrity).
- Corneal and conjunctival topography (is there any pre-existing corneal astigmatism?).
- General ocular health.
- Original refractive error.

Preparation for surgical management of the cataract patient involves education and information on the following:

- The range of vision correction modalities available post-surgically.
- Why corrections for both distance and near are necessary after surgery.
- Why contact lenses are superior to spectacles in providing for their visual needs but both options are secondary to IOL implantation.
- The need for reasonable manual dexterity and how it may affect their ability to insert and remove their own contact lenses.

12

### POST-OPERATIVE CONSIDERATIONS

- Prognosis for contact lens success?
- How soon after surgery should lenses be fitted?
- Corneal topography
- Refractive error
- General ocular health
- Rate of wound healing
- Patient motivation



8L497761-8

### Post-Operative Considerations

Many factors affect the prognosis for successful contact lens wear. Factors include previously successful contact lens wear and currently successful contact lens wear.

The post-surgical delay in fitting contact lenses depends on the surgical outcome and the time course of the individual's healing process. The topography of the anterior eye can be altered by the general surgical technique used, the size and number of incisions made during surgery, the surgeon's skill, etc. The absence of the crystalline lens results in a considerable refractive error change of some +12 to +14 D. Ocular health and wound-healing rates need to be monitored after surgery.

After removal of the crystalline lens, it may be difficult to achieve a precise end-point for a subjective refraction and disagreements between subjective and objective results may be exaggerated. These may be due to changes in pupil size and position, movement of the vitreous body and anomalies of any lens capsule remaining.


After removal of a long-standing cataract, it is important to ascertain if any strabismus is present post-surgically. Fitting a contact lens as soon as possible after surgery may be warranted in such cases.

13

**EFFECTS OF SURGERY  
OPTICAL**

- Induced corneal astigmatism
- Total loss of any remaining accommodation
- Irregular pupil shape
  - size
  - position
  - induced anisocoria

97761-9S.PPT



8L497761-9

**Effects of Surgery on Optical Performance**

Optical effects of the surgery include a high plus prescription and a complete loss of any remaining accommodation. Possible effects include an increase in ATR astigmatism and a pupil that may have become eccentric, and/or distorted and elongated (e.g. slide 15). Pupil anomalies may be due to iris trauma or iris nerve damage at the time of surgery. Generally, modern, minimal intervention surgical techniques result in almost universal success rates with minimal adverse effects.


Removal of the yellow light-absorbing crystalline lens causes an increase in photophobia and a decrease in UV absorption. To minimize the effect of UV light on the retina, spectacles and contact lenses should incorporate a UV filter.

14

**EFFECTS OF SURGERY  
OTHER**

- Photophobia
  - sudden ↑ in light transmission
- ↓ UV absorption (↑ actinic light exposure)
- Vitreous changes
- Capsular opacities
- Visual field changes

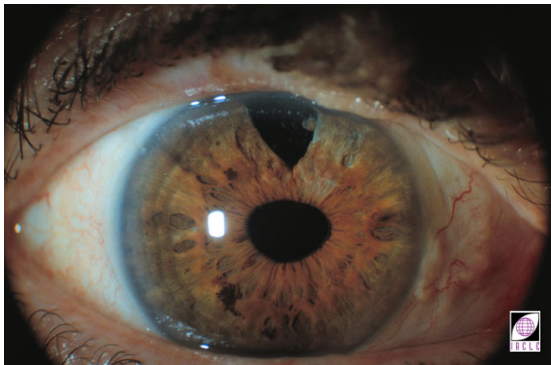97761-57S.PPT



8L497761-57

The vitreous body and posterior lens capsule may be disturbed or, if the lens capsule is excised entirely, the vitreous body may prolapse into the anterior chamber (especially if older surgical techniques are used). Any remaining lens capsule can develop opacities that may require treatment subsequently. Subsequent treatment may be as simple as a LASER treatment of any opacity through the anterior eye or as involved as surgical entry into the anterior chamber.

15



8L42923-93

Having the post-operative high plus refractive correction in the spectacle plane causes a constriction in the visual field (slide 9).


Additionally, the ring scotomata that result from high plus spectacle lenses (and their frames) causes objects in the patient's mid-peripheral object field to jump in and out of view with head movements (sometimes referred to as the 'jack-in-the-box' phenomenon).

16

**EFFECTS OF SURGERY  
PHYSIOLOGICAL**

- ↓ epithelial oxygen uptake
- ↓ corneal sensitivity
- ↓ endothelial cell density
- ↑ oxygen levels at the endothelium
- ↓ corneal oedema response to lenses

97761-10S.PPT



8L49795-10

**Effects of Surgery on Physiology**

The physiological effects of surgery on the aphakic eye are many. They include:

- Reduced epithelial O<sub>2</sub> uptake and consumption due to the denervation of the cornea affecting epithelial metabolic activity significantly.
- Decreased corneal sensitivity due to the incision required for IOL placement.
- Reduced endothelial cell density (more in the superior quadrant, due to the surgical incision). Modern techniques make this less of a problem.
- Higher O<sub>2</sub> levels at the endothelium due to the absence of the crystalline lens.

17

### EFFECTS OF SURGERY PHYSIOLOGICAL

- ↓ tear production, possibly → dry eye
- Corneal/conjunctival staining
- ↑ UV radiation levels
- ↑ risk of retinal changes

9781-11S.PPT



8L497761-11

- Lower corneal oedema response to contact lens wear. The process appears to be a combination of factors:
  - increased oxygen availability due to the absence of the crystalline lens;
  - corneal denervation that results in decreased epithelial metabolic activity (function);
  - increased endothelial permeability (cell damage and loss);
  - an increase in lactic acid efflux (i.e. decreased lactic acid accumulation).

The physiological effects include:

- A decrease in tear production possibly resulting in a dry eye.
- Increased corneal and conjunctival staining.
- Increased UV radiation levels.
- The risk of retinal changes such as cystoid macular edema and retinal detachment.

18

### EFFECTS OF SURGERY POSSIBLE PHYSICAL OUTCOMES

- Thinner epithelium
  - ↑ astigmatism
  - Against-the-Rule astigmatism
- Other considerations:
- ↓ upper lid tonus
    - ↓ palpebral aperture size (PAS)
    - partial ptosis?

9781-12S.PPT



8L497761-12

### Physical Effects of Surgery and Other Considerations

The resulting physical effects of the surgery can include:

- Thinner epithelium due to the altered metabolism.
- Increased astigmatism with a tendency toward ATR astigmatism.

Other considerations include:

- The elderly patient may have reduced upper lid tonus. This can result in:
  - a smaller PAS due to the loss of tonicity of the lid muscles;
  - a partial ptosis.

19

### POST-SURGICAL COMPLICATIONS

- Retinal detachment
- Cystoid macular oedema
- Iritis
- Glaucoma
- Corneal oedema
- Vitreous anomalies

9781-13S.PPT



8L497761-13

### Post-Surgical Complications

Pathological conditions that can occur as a result of cataract surgery include:

- Retinal detachment (especially high myopes).
- Cystoid macular oedema.
- Iritis.
- Secondary glaucoma (requiring concurrent Peripheral Iridectomy management).
- Corneal oedema (immediate response in the majority of cataract extractions) manifested as striae and folds.
- Vitreous anomalies, as described previously.

### III Contact Lens Correction of Aphakia


#### III.A Contact Lens Fitting Options and Considerations

20

**CORRECTION OF APHAKIA**

- Intra-ocular lenses (IOLs)
- Contact lenses
- Spectacles

97761-14S.PPT



8L497761-14

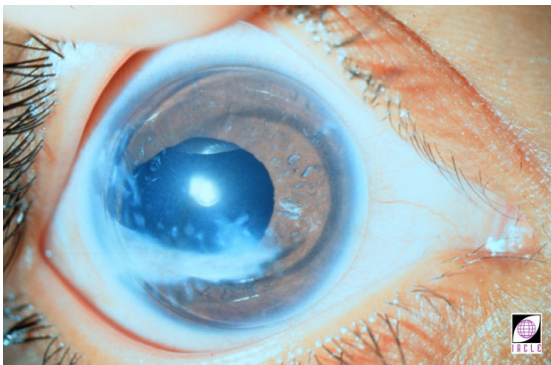
#### Correction of Aphakia

Options for the correction of aphakia include:

- Implantation of IOLs.
- Contact lenses.
- Spectacles.

Slide 21 shows a large diameter RGP contact lens being used to correct the irregular corneal surface resulting from a traumatic incident that also necessitated crystalline lens removal.

21



8L42146-95

22

**CONTACT LENSES**

Required when:

- Unsuitable for IOLs
- Failed IOL recipient

97761-15S.PPT



8L497761-15

#### Contact Lens Options for Aphakia

Contact lenses are the treatment of choice for all patients who are unsuitable for IOL implants or who have experienced a failed IOL implant.

Lens designs that can be fitted to correct the aphakic patient include:


- Hydrogel lenses (cases with low astigmatism or failed RGP lens wearers).
- RGP lenses (cases with higher corneal astigmatism and/or corneal distortion).
- Silicone elastomer (cases with low astigmatism, paediatric aphakic patients).
- Scleral lenses (significant corneal distortion).
- Tinted lenses (to attenuate bright light and offer some UV protection).
- DW or EW contact lenses based on manual dexterity. EW is best suited to those patients who demonstrate poor lens handling.

23

**CONTACT LENS OPTIONS**

- Hydrogel (SCL)
- Rigid gas permeable (RGP)
- Siloxane elastomer
- Scleral (haptic)
- Tinted
- DW, EW, or CW

97761-16S.PPT



8L497761-16

24

### CONTACT LENS CONSIDERATIONS OCULAR FACTORS

- High +Rx
- Astigmatism?
- Pupil sizes, shapes, position?
- Lid positions and tonus?
- Dry eye?
- Blink quality?
- Need for supplementary spectacles?
  - intermediate and/or near
  - astigmatism



8L497761-17

### Contact Lens Considerations: Ocular Factors

Ocular factors to be considered in prescribing contact lenses include:

- High plus power.
- ATR astigmatism or irregular astigmatism.
- Pupil size, shape, and position.
- Lid position and tonus.
- Presence of dry eye or marginal dry eye.
- Blink quality.
- Need for supplementary spectacles (e.g. to correct any residual astigmatism and/or a near prescription).

25

### CONTACT LENS CONSIDERATIONS OCULAR FACTORS

- Patient's age
  - geriatric
  - paediatric
- Type and extent of surgery
  - dictates delay before fitting



8L497761-53

A patient's age is another consideration, i.e. are they a geriatric patient, a paediatric patient, or from an intermediate age group? From the patient's age, an estimate can be made of how many years of contact lens wear awaits the individual. In all cases, consideration must be given to the level of assistance, if any, required by the patient and whether or not such assistance is available from family and/or friends.

Differences include tonus of lids, corneal size and shape, quality of the tear film, palpebral fissure sizes, blink reflex, presence of degenerative conditions, manual dexterity, and the presence of systemic illnesses such as diabetes or arthritis.

26

### CONTACT LENS CONSIDERATIONS VISUAL PROBLEMS

- Variable refraction and vision
- High +Rx lenses more likely to decenter
- Need for over-spectacles
  - reading and intermediate vision Rx
  - any residual Rx, i.e. for astigmatism
- Binocular vision, anisometropia/aniseikonia



8L497761-18

### Contact Lens Considerations: Visual Problems

Visual correction too early in the recovery cycle may demonstrate variability in refractive status and vision. Frequent changes in refraction can be frustrating for the patient so they must be forewarned of the possibilities well in advance of any such changes. The practitioner should avoid getting caught in a cycle of frequent contact lens Rx changes. Waiting until the refractive error has stabilized somewhat is therefore desirable.

Further, the high plus power of the contact lens may induce visual compromise due to dynamic lens decentration (blink-induced). Over-spectacles are needed to provide the reading power and to correct any residual error, especially astigmatism.

The binocular status may need reassessment should any induced anisometropia (for the monocular aphake) lead to aniseikonia. If such aniseikonia exists, designing contact lens power and spectacle over-correction to provide a (Galilean) telescope effect may be required. This approach has its own set of problems, e.g. field of view, distortion, chromatic aberration, spatial localization, and mobility while wearing the combination.

If indecision arises over exactly what Rx is required, the practitioner should err towards over-correction (more plus power but not by more than say +0.50 D) rather than under-correction (Lindsay, 2004 personal communication). Although true generally, this is especially important in congenital aphakes as it ensures that there is some distance within optical




infinity that is imaged clearly on their retinas. Additionally, in the case of RGP lenses, it is relatively easy to 'remove' small amounts of plus power (i.e. flatten the FOZR slightly) from a lens, whereas adding plus power (steepening the FOZR) to a contact lens is more difficult and prone to producing a poorer optical outcome (manual lens modifications are not as regular optically).

27

**CONTACT LENS CONSIDERATIONS  
PHYSIOLOGICAL**

- Type and extent of surgery
- Wound healing
- Oxygen transmissibility required
- Appearance of the palpebral conjunctiva

97761-19S.PPT



8L497761-19

**Contact Lens Considerations: Physiological**

In selecting the appropriate lens type, the type of surgery (Intra or Extra Capsular Cataract Extraction, phacoemulsification, etc.), the oxygen transmissibility required, and the appearance of the palpebral conjunctiva need to be considered.


Some of the corneal nerves are severed during cataract extraction resulting in some reduction of corneal sensitivity. Regardless of the type of lens selected, the patient must be aware that they may not feel the presence of a foreign body under the lens, thereby increasing the risk of corneal abrasion and infection.

28

**CONTACT LENS CONSIDERATIONS  
PATIENT FACTORS**

- Dexterity
  - lens handling difficulties
  - assistance needed?
- Compliance problems
- General assistance needed?
- Need for sunglasses
- Ocular medications
- Systemic conditions
  - arthritis
  - diabetes

97761-20S.PPT



8L497761-20

**Contact Lens Considerations: Patient Factors**

In selecting the appropriate lens type, the following patient factors warrant consideration:


- Dexterity to enable lens insertion and removal.
- Lens handling difficulties due to arthritis, etc.
- Compliance issues.
- Level of assistance needed to manage lens handling, care and maintenance, etc.
- Need for sunglasses due to photophobia.
- Ocular medications.
- Systemic conditions such as arthritis (leading to a dry eye) or diabetes (leading to a reduced facility for epithelial repair, and refractive changes).

29

**FITTING THE APHAKE  
KEY FACTORS**

- Patient counselling in advance of surgery
- Adequate trial lenses to hand
- Ability to solve all problems encountered
- Extensive routine after-care & follow-up
- Generally, greater needs than routine cases

97761-21S.PPT



8L497761-21

**Key Factors in Fitting the Aphake**

Key factors in fitting the aphakic patient successfully include:

- Patient counselling prior to surgery regarding options and contact lens fitting procedures.
- Having appropriate trial lenses to more easily predict the final parameters required.
- Ability to handle unique problems that may be encountered by the patient and practitioner.
- Follow-up and after-care visits to assess lens performance and eye health extensively.

30

**PRE-FITTING PROCEDURES**

- Post-surgical evaluation of ocular health
- Accurate spectacle refraction (stable?)
- Determine best corrected VA
- Corneal topography assessment (stable?)
- Determine pupil size, shape, and position
- Examination of the eyelids
  - tonus
  - resting position
  - closure completeness



8L497761-22

**Pre-Fitting Procedures**

The pre-fitting information that should be acquired includes:

- An assessment of ocular health after surgery.
- The ability to obtain an accurate and repeatable spectacle refraction.
- The BCVA to enable comparison with the contact lens VA.
- An assessment of corneal topography to locate any corneal distortion or irregular astigmatism induced by the surgery.
- A determination of pupil size, shape, and position to enable correct selection of lens optic zone and/or TDs.
- An assessment of the eyelid tonus and a measurement of the PAS.

**III.A.1 RGP Lens Designs**

31

**RGP LENSES  
ADVANTAGES**

- Often correction is more complete
- Fewer eye complications
- Easier lens care
- Customized designs possible
- Curves & BVP can be modified



8L497761-23

**RGP Lens Advantages**

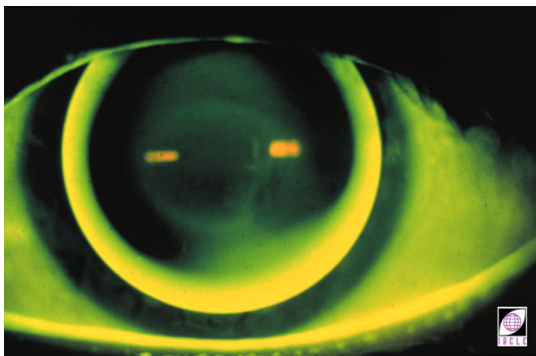
Fitting RGP lenses has many advantages as either spherical or toric designs can be used to provide optimum vision correction. Furthermore, the ocular complications related to RGP lenses fitted appropriately are fewer than with hydrogel lenses and RGP lenses are easier to care for and manage. Custom designs are available in virtually all lens parameters.

Other advantages of RGP lenses over SCLs include:

- Durability and strength.
- Tear exchange and debris removal.
- High oxygen transmissibility.
- Lower risks of inflammation and infection.
- Small modifications to lens curves and BVP can be made using normal rigid lens modification tools and techniques.

Slide 32 is an example of a well-fitted RGP lens on an aphakic eye with minimal ATR astigmatism. The lens centres well with minimal apical clearance.

32



8L42000-99

33

**RGP TRIAL FITTING**

Essential to determine:

- Back and front surface designs
- BVPs required at D & N
- How to correct for near
- Binocular status with contact lenses



8L497761-25

**RGP Lens Trial Fitting**

When determining the final lens design, the following must be considered:


- The designs of the back and front surfaces.
- The BVP required at:
  - distance
  - near.
- How to correct for near (over-spectacles, PAL or bifocal contact lenses).
- The binocular status with the contact lenses on.

34

**RGP TRIAL FITTING  
IMPORTANT REQUIREMENTS**

- Adequate movement
- Acceptable centration
- Appropriate fluorescein fitting pattern

97761-26S.PPT

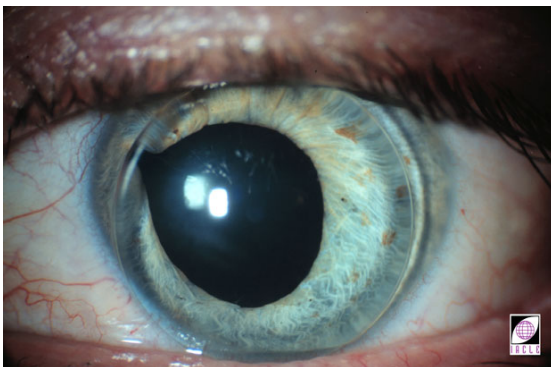


8L497761-26

**RGP Lens Trial Fitting: Requirements**

The final lens design must have adequate movement on a blink, acceptable centration over the pupil, and an appropriate fluorescein fitting pattern.

35



8L40607-97


Slide 35 is an example of an RGP lens that is sitting slightly inferiorly on the cornea. This decentration along with the irregular pupil may cause some visual disturbance.

36

**RGP LENS DESIGN**

- High plus power trial sets are essential
- Lenticular and single-cut designs
- Spherical and aspheric designs
- Diameter from 9.0 - 10.5 mm
- Peripheral lens design usually standard

97761-27S.PPT



8L497761-27

**RGP Lens Designs**

To predict the correct RGP lens design accurately, a high plus trial lens set is required. Most high plus designs are lenticulated rather than single-cut to promote a lens that positions more centrally than inferiorly and to reduce the centre thickness of the lens (and increased Dk/t). Spherical, toric or aspheric back surface designs may be used.

The total lens diameter (TD), may range from 9.0 to 10.5 mm but the larger diameter (9.6 to 10.5 mm) lenses are more commonly used. The peripheral lens design should be standard to provide an Axial Edge Clearance from 90 to 120 µm.


37

**RGP LENS DESIGN**

Potential fitting problems

- Excessive decentration
- Flare and diplopia
- Poor adaptation

97761-28S.PPT



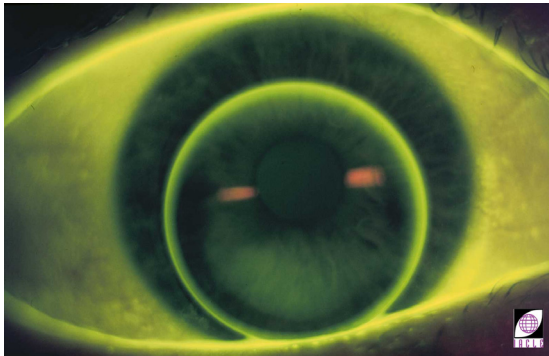
8L497761-28

Potential fitting problems include:

- Excessive decentration.
- Flare.
- Diplopia due to a small TD, small BOZDs, and excessively thick lenses.

These problems may lead to poor initial lens adaptation.

38



8L41733-93

Slide 38 demonstrates a small, thick, high plus lens that has decentered inferiorly. Such a fitting is likely to cause irritation and poor adaptation due to an abnormal blink pattern.


39

**LENTICULAR RGP LENS DESIGN**

Lenticular design for:

- Reduced centre thickness
- Higher riding position
- Centration of optical zone
- Posterior placement of centre of gravity

97761-29S.PPT



8L497761-29

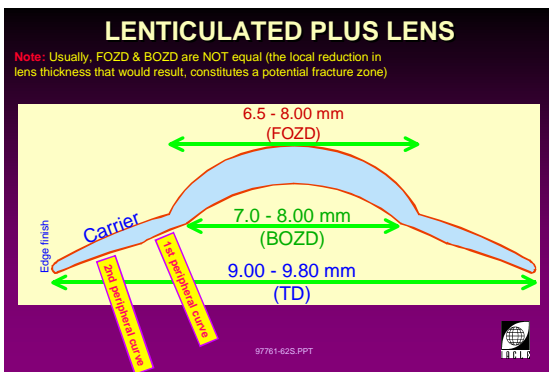
**Lenticular RGP Lens Design**

Front surface lenticular designs with minus carriers are usually fitted to:

- Reduce the centre thickness.
- Increase the peripheral thickness to encourage lid interaction and cause a higher riding position so that the BOZD will be better centred over the pupil.

This thinner design with a minus carrier and a larger diameter are all factors that will place the plus lens centre of gravity more posteriorly and prevent the lens 'dropping' to the inferior lid margin.

40



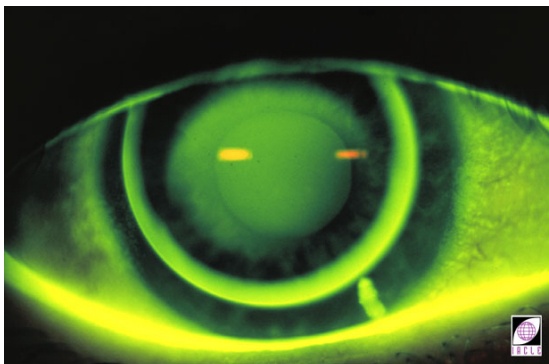
8L497761-62

Slide 40 is a profile of a lenticulated high plus tricurve lens. Note that the FOZD and BOZD rarely correspond in size. The front is usually slightly larger than the back to avoid a thin point of weakness (a neck) in the lens profile.

Slide 41 is an example of an aphakic lens with a minus carrier that is being held up by the lid to a slightly superior but still acceptable position. In theory, the flatter the minus carrier radius, the higher riding the lens will position. There is slightly excessive but acceptable apical clearance shown by this fit.

Lenticular lens designs have proved successful for flatter corneas, ATR astigmatism, larger PASs, and looser lids. They also promote better centration of RGP lenses due to the thinner design.

41




8L4109-99

42

**LENTICULAR RGP LENS DESIGN**

Lenticular design used for:

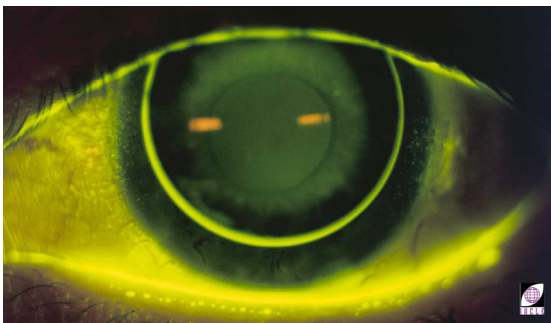
- Flatter corneas
- ATR astigmatism
- Large PASs
- Loose lids



97761-305.PPT

8L497761-30

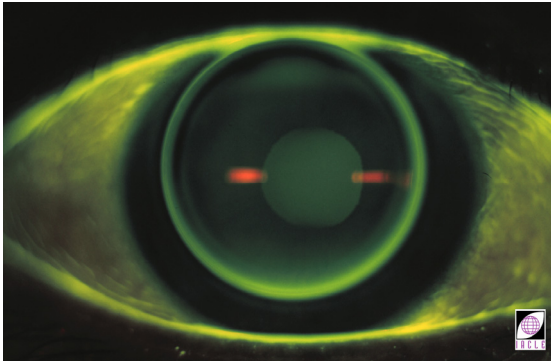
43



8L40243-94

Slides 43 and 44 compare the fitting of a larger TD, larger BOZD, and slightly steeper fitting lens with good lid interaction, to a smaller TD, smaller BOZD that results in a looser fit and greater decentration that may also be less stable and tend to drop after a blink.

44




8L40102-99

45

**LENTICULAR DESIGN FITTING PHILOSOPHY**

- Choose a BOZR that gives slight apical pooling (i.e. steeper than K)
- Use a lenticulated front surface
- Stability and centration are essential
- Lens must move adequately
- Good tear exchange must be demonstrated



97761-315.PPT

8L497761-31

**Lenticular RGP Design: Fitting Philosophy**

The most common RGP fitting philosophy is to fit a lens with a lenticulated front surface and a BOZR that has slight apical clearance (showing as apical pooling) to ensure stability and lens centration. The lens should move adequately (1 to 1.5 mm) and achieve good tear exchange with each blink.




46

**LENTICULAR DESIGN  
TOTAL DIAMETER**

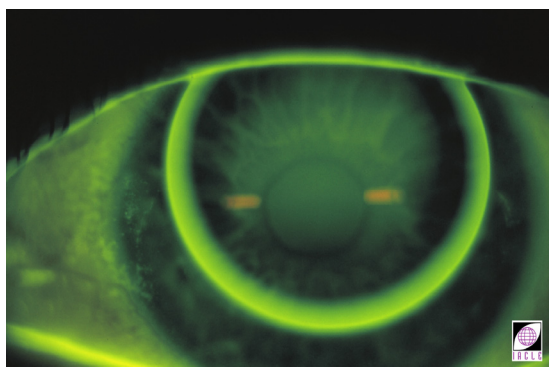
- TD range: 9.0 - 10.5 mm
- TD > FOZD by 1.5 - 2.0 mm
- Larger TDs can ↑ comfort
- TD can influence 3 and 9 o'clock staining

97781-32S.PPT



8L497761-32

47



8L400104-99

**Lenticular RGP Design: Total Diameter**

Total lens diameters (TDs) used a range from 9.0 to 10.5 mm. The lens should be larger than the FOZD by 1.5 to 2.0 mm to give a sufficiently large minus carrier.

Larger lenses may increase comfort and reduce the incidence or severity of 3 & 9 o'clock staining by causing minimal peripheral desiccation due partly to a complete and continuous blink action.

Slide 47 shows a lens with a fluorescein pattern and position that are acceptable but causing some 3 & 9 staining that can result in discomfort.


A lens with a larger TD and BOZD, and a compensating increase in BOZR (flatter), should result in an equivalent fluorescein pattern but be more comfortable and fit more centrally. Such a fit has less potential to cause peripheral corneal desiccation staining.

48

**LENTICULAR DESIGN  
OPTIC ZONE DIAMETERS**

- Dependent on pupil size and shape
- OZD range: 7.6 - 8.0 mm
- FOZD ≠ BOZD
- ↑ FOZD → ↑ lens thickness  
- similarly, ↓ FOZD → ↓ lens thickness

97781-33S.PPT



8L497761-33

**Lenticular RGP Design: Optical Zone Diameter**

The FOZD can be chosen on the basis of the pupil size and shape to ensure adequate coverage by both the FOZD and BOZD, even with a dilated pupil (range of OZDs: 7.6 to 8.0 mm).


It is prudent not to match the FOZDs and BOZDs. To reduce the centre thickness of a high plus lens, a smaller FOZD can be ordered.

49

**LENTICULAR DESIGN  
POSTERIOR PERIPHERAL CURVE DESIGN**

- Align with the mid-periphery for stability
- Optimize edge width and clearance
- Consider toric peripheral curves when appropriate

97781-34S.PPT



8L497761-34

**Lenticular RGP Design: Posterior Peripheral Curve Design**

The mid-periphery back surface curves should align with, or be very close to aligning with, the cornea to help stabilize the lens on the eye.

The peripheral curvatures and widths should be chosen to give the optimum edge width (0.5 mm) and clearance (90 to 120 μm).

The peripheral curves can be made toric when significant peripheral corneal astigmatism (toricity) is present. This should help stabilize the lens fit and aid lens centration.




50

**LENTICULAR DESIGN**  
**ANTERIOR PERIPHERAL CURVE DESIGN**

- Anterior curve dictates lenticular design
- If too flat may:
  - ↑ carrier thickness
  - this excessive thickness may → discomfort

97761-35S.PPT



8L497761-35

**Lenticular RGP Design: Anterior Peripheral Curve Design**

The lenticular carrier radius is dependent on the FOZD. If it is too flat, the lens periphery may be too thick and cause discomfort when the upper eyelid interacts with the lens.


51

**RGP LENS DESIGN**

Single-cut design for:

- Steeper corneas
  - especially if spherical, or...
  - only some WTR corneal astigmatism
- Narrow PASs (most common reason)

97761-36S.PPT



8L497761-36

**RGP Single-Cut Design**

The term 'single-cut' refers to a lens that has a single radius of curvature on its front surface. This contrasts with a lenticular cut, described previously, in which multiple radii are used to form a lenticulated front optical surface with a peripheral 'carrier' zone that can influence the interaction between lid and lens.

Although uncommon, single-cut lens designs may be used when:


- the cornea is steeper;
- little or no with-the-rule (WTR) corneal astigmatism is present;
- a narrow PAS calls for a smaller overall lens diameter (this is the most common reason).

52

**SINGLE-CUT DESIGN**  
**TOTAL DIAMETER**

- Range from 7.5 - 8.5 mm
- ↑ TD → ↑ lens thickness
  - similarly, ↓ TD → ↓ lens thickness

97761-38S.PPT



8L497761-38

**RGP Single-Cut Design: Total Diameter**

To keep the centre thickness of a single-cut lens to a minimum, a small TD must be chosen. Usually, TDs range from 7.5 to 8.5 mm.

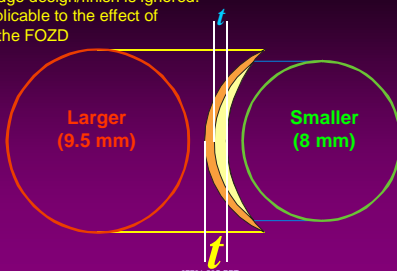
Slide 53 demonstrates how the centre thickness increases with a larger TD single-cut lens of equal power. Such increases in centre thickness add significantly to lens mass and bulk, push the lens' centre of gravity forward, and increase lens interaction with the eyelid during blinking.

All of these factors contribute to the lens dropping and centring low on the cornea. Consequences include compromised tear exchange, encouragement of peripheral corneal desiccation and decentration of the optics downward relative to the pupil.


53

**SINGLE-CUT PLUS LENS DESIGN**  
**EFFECT OF TD ON LENS THICKNESS**

**Note:** Edge design/finish is ignored.  
Also applicable to the effect of varying the FOZD



97761-61S.PPT



8L497761-61

54

### SINGLE-CUT DESIGN BACK OPTIC ZONE DIAMETER

- Based on pupil size
- ↑ BOZD → tighter lens fit

97761-39S.PPT



8L497761-39

### RGP Single-Cut Design: Back Optic Zone Diameter

To ensure sufficient pupil coverage, the BOZD should be based on pupil size in the dark. However, a larger BOZD can result in a tighter fitting relationship due to an increase in the lens surface sagitta. This increase may need to be compensated for by increasing the BOZR if excessive central clearance occurs.

55

### SINGLE-CUT DESIGN POSTERIOR PERIPHERAL CURVE DESIGN

- Bicurve in most cases
- Tricurve if TD >8.5 mm
- Edge thickness must be considered
- Need to ensure adequate tear exchange

97761-40S.PPT



8L497761-40

### RGP Single-Cut Design: Posterior Peripheral Curve Design

Normally, single-cut lenses are of a bicurve design due to their small TDs (and therefore small BOZDs). A tricurve design may be utilized if the lens TD is larger (>8.5 mm). For a high plus, single-cut lens, peripheral curve radii that are too flat tend to result in an edge that is too thin. Adequate tear exchange must be ensured and steps taken to prevent the peripheral curve being too 'tight' (too closely aligned with the cornea at or near the lens edge, i.e. the lens edge clearance is too little).

56

### RGP MATERIALS CONSIDERATIONS

- Siloxane acrylates
- Fluoro-siloxane acrylates
- High Dk
- Good durability
  - low breakage rate
- UV blocking

97761-54S.PPT



8L497761-54

### Aphakic RGP Lenses: Material Considerations

While both siloxane acrylate and fluoro-siloxane-acrylate materials can be used for these lens designs, generally, the latter class offers the greater oxygen performance. Because of the increased lens thickness (high plus), the permeability of the material chosen should be among the highest possible while demonstrating good durability to avoid a high breakage rate. An ability to block UV light is also an essential consideration in choosing the best lens material to use for an aphake.

57

### RGP LENSES EXTENDED WEAR ADVANTAGES

- Higher oxygen transmission
  - corneal physiology better maintained
- Debris removal on awakening
- Spherical lenses correct 90% of corneal astigmatism
  - physical limits to this exist
- Fewer complications than hydrogels
- Easy care and maintenance
- Strength and durability

97761-41S.PPT



8L497761-41

### RGP Extended Wear Lenses: Advantages

RGP EW lenses can be considered for the aphakic patient. Their advantages include:

- Higher O<sub>2</sub> transmission than SCLs. Siloxane hydrogels are not yet available in aphakic Rx and hydrogel lenses for aphakic EW are not available (Dk/t too low).
- Debris moves readily from beneath an RGP lens after a few blinks upon awakening.
- Greater rates of tear exchange.
- A spherical lens corrects 90% of corneal astigmatism. However, there are physical limits to the amount of corneal astigmatism that can be fitted with a spherical lens.

The literature reports fewer complications with RGP EW than with hydrogel EW (see Module 7, Lectures 7.2 and 7.3). RGP lenses are easier to care for and

maintain and, since the materials are stronger and more durable, they need less frequent replacement. However, it is likely that lens condition rather than lens breakage is likely to be the limiting factor of lens life.


### III.A.2 Hydrogel Lens Designs

58

**HYDROGEL LENSES  
ADVANTAGES**

- Offer good initial comfort
- Less prone to displacement
- Offer good centration
- Stable positioning of the optics over the eye during blinks and eye excursions
- Stabilize promptly after insertion

97761-42S.PPT



8L497761-42

#### Advantages of Hydrogel Lenses


For some patients, hydrogel lenses may be preferred. Hydrogel lenses offer the advantages shown in the slide opposite.

59

**HYDROGEL LENSES  
DISADVANTAGES**

- Poorer oxygen transmission
- Symptoms of dryness may be induced
  - may aggravate existing dry eye problems
- Greater care and maintenance needs
- Higher overall costs
- Limited parameters available
- Handling can be more difficult
- May discolour with topical medications
- Uptake of preservatives

97761-43S.PPT



8L497761-43

#### Disadvantages of Hydrogel Lenses

The disadvantages of hydrogel lenses include:

- Poorer oxygen transmission (especially with higher plus power Rx's).
- A tendency to dehydrate on the eye. This can lead to or aggravate dry-eye symptoms.
- More care and maintenance required.
- Can be more costly due to custom design considerations.
- Relatively limited lens parameters are available.
- Lens handling can be difficult.
- Lenses can discolour when topical medications are applied while lenses are worn, e.g. glaucoma medications.
- Preservatives are absorbed more easily (e.g. from lens care products and re-wetting drops).
- Lens power or curves cannot be modified once original manufacturing process is completed.

60

**HYDROGEL LENSES**

- Low water content, or...
- High water content
- Which lens design?
- What fitting philosophy?

97761-44S.PPT



8L497761-44

#### Hydrogel Lens Types

Hydrogel lens types include:

- Low water content materials.
- High water content materials.
- Lenticulated front surface designs.
  - with small FOZDs;
  - with larger FOZDs.

#### Fitting Philosophies

Conflicting fitting philosophies exist:

- Use low H<sub>2</sub>O lenses to:
  - minimize dehydration;
  - minimize lens deposits;
  - maximize durability;
  - broaden lens care options.
- Use high H<sub>2</sub>O lenses to:
  - maximize oxygen transmissibility to minimize the risk of complications associated with lens wear.

61

### HYDROGEL LENSES FITTING PHILOSOPHY

- Regular hydrogel lens fitting philosophies apply
- Lens material
  - high vs. low water content lens
  - larger TDs used
- Lens design
  - spherical design
  - aspheric design
- Longer settling time required



8L497761-45

### Fitting Philosophy for Hydrogel Lenses

The basic hydrogel fitting philosophies and goals employed with normal hydrogel lenses are applicable to aphakic hydrogel lenses.

Moderate to high water content lenses, while perhaps being less durable than low water hydrogels, provide the advantage of increased oxygen availability to the cornea, especially during overnight EW.

Usually larger diameter lenses are employed to enhance lens centration. Out of necessity, these lenses are lenticulated to minimize the centre thickness and overall lens bulk and mass.

The lenses may have spherical or aspheric back surfaces. Aspheric front surface designs may enhance optical quality by decreasing spherical aberration in high plus lenses, much as they do for high plus spectacle lenses.

Due to the greater volume of water in such lenses and how far away from the lens surface some of the water is located, a longer settling (equilibration) time may be needed before a valid assessment of the fit can be made.

62

### EXTENDED WEAR ISSUES FITTING PHILOSOPHY

- Patient selection is important
- Patient management is more difficult
- Costs are usually higher
- Wearing schedule needs monitoring
- Replacements needed more frequently
- Greater potential for infection



8L497761-46

### Extended Wear Issues

EW of lenses may be an option for the pediatric or geriatric aphake if there are problems with lens handling, and insertion and removal.

It may be difficult to manage these patients due to the increased frequency of visits needed. Costs are higher since these lenses are not generally a disposable or frequent replacement type of lens. The wearing schedule must be monitored closely to ensure that after no more than 6 consecutive nights of lens wear there is at least 1 night of no-lens wear during which the lenses are cleaned and disinfected thoroughly.

Frequent lens replacement may be indicated should lens deposits become a problem.

Finally, there may be an increased incidence of ocular infection in these patients due to their reduced corneal sensitivity, a faculty that otherwise would alert them to a complication earlier.

## III.A.3 Siloxane Elastomer Lenses

63

### SILOXANE ELASTOMER LENSES

- ↑ POSITIVES
- Good physiology
- NEGATIVES
- ↓
- Deposit problems
  - Lens adherence is common
  - Coating integrity & durability
  - High cost



8L497761-47

### Siloxane Elastomer Lenses

Siloxane elastomer lenses are particularly suited to the pediatric aphakic patient due to their high  $O_2$  permeability ( $Dk > 100$ ) and relatively small TD (11.5 mm). Due to their high oxygen transmissibility, there is usually a good physiological response from the eye, but there are problems with protein deposits and lens adherence to the cornea.

Siloxane elastomer lenses are surface coated to provide a hydrophilic surface for good on-eye wettability. Scratches and other damage to the coating are a relatively frequent occurrence that can lead to significant and irreversible losses of lens wettability, affecting wearing comfort and vision.

Lens replacement every 3 to 6 months may be necessary. To avoid lens adherence, the lens should be fitted relatively flat, possibly to the extent of exhibiting a fluted edge. This fluting can cause discomfort. Further, these lenses are expensive and only limited BVPs and BOZR are available. Finished lenses cannot be modified should changes be required.


**III.A.4 Scleral Lenses**

64

**SCLERAL LENSES FOR APHAKES CONSIDERATIONS**

- Ease of handling compared with RGP and SCLs
- SCL spoilage and deposition
- Irregular corneal astigmatism

97761-48S.PPT



8L497761-48

**Scleral Lenses for Aphakes**

Scleral (haptic) lenses are included here as an option for aphakia as they may occasionally be appropriate. However, scleral lenses are not a first choice for correcting the aphakic and are rarely fitted, usually because of the expertise required in fitting, and the costs involved.

Scleral lenses may be considered for aphakic patients for the following reasons:


- They may be easier to handle since they are larger compared with corneal contact lenses.
- SCLs may deposit (especially with jelly bumps) and need more frequent replacement.
- Irregular corneal astigmatism may be better managed with a scleral lens.

65

**SCLERAL LENS FITTING**

- Same fitting considerations as for other conditions
- Usually, post-fitting modifications are necessary
- Corneal astigmatism induced by surgery can complicate achieving a 'perfect fit'

97761-49S.PPT



8L497761-49

Refer to Module 9, Lecture 9.4 for a detailed account of lens selection, design parameters, and fitting.

If the aphake is elderly, contact lens fitting success rates may be increased by adding scleral lenses to your contact lens-fitting armamentarium. Despite most cases requiring post-fitting modification(s), especially if significant corneal or irregular astigmatism need correcting, scleral lenses offer one of the few solutions to such difficulties.

Slide 66 is an example of a scleral aphakic lens positioned on the wearer's fingertips in preparation for filling with normal saline solution and, subsequently, lens insertion.

66



8L42063-95



## IV After-Care and Patient Management

67

### SPECIFIC AFTER-CARE CONSIDERATIONS

- Convenience of patient and family member(s)
- Reminder and follow-up calls
- Use of larger text fonts in handouts to aphakic and low-vision patients
- Simplify instructions
- Re-education may be required (repeat if necessary)
- Collaboration with their medical/ophthalmological practitioner may be required
- UV protection

97761-50S.PPT



8L497761-50

### Specific Considerations for After-Care of the Aphake

After-care visits must be made at the convenience of both the patient and the family member involved in their contact lens care. Frequent reminder and follow up calls may be necessary initially. If the geriatric aphake's vision is compromised post-surgically, then larger fonts for written handouts may be needed.

Keep the verbal instructions simple and re-educate and repeat at every visit. Collaborate with the medical practitioner, informing him when you have fitted your patient and the results of the fitting. Keep in mind the need to prescribe UV protection if the contact lens does not provide for it.

68

### PATIENT EDUCATION

- Lens handling problems
- Application and insertion techniques
- Lens cleaning procedures
- Wearing schedule
- Abnormal signs and symptoms
- Compliance
- Follow-up care/after-care visits

97761-51S.PPT



8L497761-51

### Patient Education

Initially, the novice wearer may have lens-handling problems that require the teaching of a range of insertion and removal techniques. Lens cleaning procedures, wearing schedules, abnormal signs and symptoms, compliance issues, and after-care schedules should be discussed verbally and supplied in writing.

69

### RGP LENSES COMMON COMPLICATIONS

- Corneal staining
  - 3 & 9 o'clock staining
- Deposits/coatings
  - lens adherence
- Edge chips and lens fractures
- Decentration
- Displacement on to the conjunctiva
- Lens loss from the eye

97761-58S.PPT



8L497761-58

### Lens-Related Complications

The same lens-related complications experienced with RGP, SCL and siloxane elastomer, and scleral lenses fitted under other, more normal clinical circumstances, can be expected with aphakic lenses.

#### With RGPs:

- Corneal staining.
  - 3 & 9 o'clock staining.
- Deposits/coatings.
- Lens adherence.
- Edge chips and lens breakage.
- Mislocation on the eye, relocation on to the conjunctiva, lens loss from the eye.

#### With SCLs:

Complications related to hypoxia may be exacerbated by the increased lens centre thickness of high plus lenses. However, the aphakic eye may be less sensitive and responsive to hypoxia due to the absence of the crystalline lens.

70

### HYDROGEL LENSES COMMON COMPLICATIONS

- Hypoxia
- Deposits
- Dehydration
- Inflammation
- Infections in EW

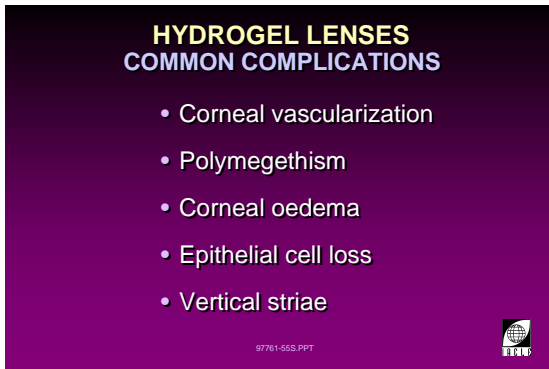
97761-52S.PPT



8L497761-52




71



**HYDROGEL LENSES  
COMMON COMPLICATIONS**

- Corneal vascularization
- Polymegethism
- Corneal oedema
- Epithelial cell loss
- Vertical striae

97761-555.PPT



8L497761-55

The specific hypoxia-related complications to be mindful of during after-care evaluations include:

- Corneal oedema:
  - increased corneal thickness (pachometry);
  - corneal hazing;
  - vertical striae.
- Corneal vascularization.
- Epithelial/endothelial cell loss.
- Endothelial polymegethism.

**With Siloxane Elastomers:**

- Deposits/coatings.
- Lens adherence.
- Fragility/durability of lens coating
  - decrease in/loss of wettability.

**Overall Ocular Health:**

It is important that the general state of the aphake's ocular health be monitored at all times. At a minimum these checks should include:

- A detailed ocular fundus examination.
- Measurement of the IOP.
- Lens capsule (if present) transparency.

## References

- Amos CF *et al.* (1992). *Rigid gas permeable contact lens correction of aphakia following congenital cataract removal during infancy.* J Pediatr Ophthalmol Strab. 29: 243 – 245.
- Andrew NC, *et al.* (1989). *The bandage lens in bullous keratopathy.* Ophthalmol Physiol Opt. 9: 66 – 68.
- Baldone JA (1979). *Soft lens design in aphakia.* Ophthalmology 86: 403 – 408.
- Benjamin WJ, Simons MH (1984). *Extended wear of rigid contact lenses in aphakia: a preliminary report.* Int Cont Lens Clin. 11: 44 – 54.
- Blok MD *et al.* (1990). *Use of the Megasoft Bandage Lens for treatment of complications after trabeculectomy.* Am J Ophthalmol. 110: 264 – 268.
- Boyd HH (1979). *Hard contact lens corrections in aphakia.* Ophthalmology. 86: 399 – 402.
- Carpel EF, Parker P (1985). *Extended wear aphakic contact lens fitting in high-risk patients.* CLAO J. 11: 231 – 233.
- Carlson KH *et al.* (1990). *Effect of silicone elastomer contact lens wear on endothelial cell morphology in aphakic eyes.* Cornea 9: 45 – 47.
- Cavanagh HD (1984). *Extended-wear contact lenses in aphakia: physiology, lens design, fitting, and results.* Trans New Orleans Acad Ophthalmol. 32: 13 – 23.
- Cutler SI *et al.* (1985). *Extended wear contact lenses in pediatric aphakia.* J Pediatr Ophthalmol Strabismus. 22: 86 – 91.
- Ezekiel D (1991). *Gas-permeable scleral lenses.* CL Spectrum. 6(7): 19 - 24.
- Ezekiel D (1995). *A gas-permeable paediatric aphakic scleral contact lens.* Optician 210(35): 25 – 27.
- Farkas P, Kassalow TW (1971). *Binocular considerations for the monocular aphake.* J Am Optom Assoc. 42: 562 – 566.
- Farkas P *et al.* (1983). *Management and fitting the aphakic with contact lenses.* J Am Optom Assoc. 54: 215 – 222.
- Graham CM, *et al.* (1988). *Prospects for contact lens wear in aphakia.* Eye 2 ( Pt 1): 48 - 55.
- Guillon M, Warland J (1980). *Aniseikonia and binocular function in unilateral aphakes wearing contact lenses.* J Brit Cont Lens Assoc. 3: 36 – 38.
- Holden BA *et al.* (1980). *Corneal swelling responses of the aphakic eye.* Invest Ophthalmol Vis Sci. 19: 1394.
- Holden BA *et al.* (1982). *Effects of cataract surgery on corneal function.* Invest Ophthalmol Vis Sci. 22: 343 – 350.
- Holmström G *et al.* (1990). *Contact lenses – still the only solution for infant aphakia.* Eur J Implant Ref Surg. 2: 265 – 267.
- Koetting RA (1977). *Tips for teaching aphakics.* CL Forum. 2: 53 – 59.
- Korb DR *et al.* (1980). *Physiological response of the cornea to hydrogel lenses before and after cataract extraction.* J Am Optom Assoc. 51: 267 – 270.
- Lightman JM, Marshall D (1996). *Clinical evaluation of back optic radius and power determination by age in pediatric aphakia due to congenital cataract fitted with a silicone elastomer contact lens.* Optom Vis Sci. 73: 22.
- Moore BD (1985). *The fitting of contact lenses in aphakic infants.* J Am Optom Assoc. 56: 180 – 183.
- Nelson LB *et al.* (1985). *Silsoft extended wear contact lenses in pediatric aphakia.* Ophthalmology. 92: 1529 – 1531.
- Polse KA (1969). *Contact lens fitting in aphakia.* Am J Optom Arch Am Acad Optom. 46: 213 – 219.
- Polse KA *et al.* (1982). *Predicting corneal edema accompanying aphakic extended wear.* Invest Ophthalmol Vis Sci. 22(3) (Suppl.): 19.
- Sabiston DW (1984). *The use of extended wear contact lenses in aphakia.* Aust J Ophthalmol. 12: 331 – 334.
- Weissman BA (1983). *Fitting aphakic children with contact lenses.* J Am Optom Assoc. 54: 235 – 237.
- Zikoski E (1993). *Methods of correction for pediatric aphakia.* CL Spectrum. 8(6): 51 – 57.



# **Practical 8.4**

(2 Hours)

## **Aphakic Contact Lens Fitting and Assessment**

## Practical Session

### Requirements:

**Lenses:** Hydrogel lenses in aphakic BVPs  
RGP high plus lenses (lenticulated, single-cut)  
Siloxane elastomer lenses in aphakic BVPs

**Equipment:** 7X or 10X Loupe, Centre Thickness Gauge, Focimeter (Vertometer, Lensometer), Slit-Lamp, Keratometer, Refractor Head (Phoropter).

### Part 1

#### Lens Verification

1. Measure and compare the **centre thicknesses** ( $t_c$ ) of the rigid contact lenses supplied.
2. Measure and compare the **FVP** (Front Vertex Power) and **BVP** (Back Vertex Power) of all the RGP and hydrogel lenses supplied.
3. Measure and compare **TD** (Total [overall] Diameter), **FOZD** (Front Optic Zone Diameter), and **BOZD** (Back Optic Zone Diameter) of the RGP and hydrogel lenses supplied.
4. Observe the **periphery** of lenses supplied: Compare lenticulated with single-cut designs.

### Part 2

#### Lens Fitting

1. Select one eye of your partner.
2. Determine corneal topography and ascertain the spectacle refraction and resulting VA.
3. Assess eyelid position and lid tonus, Palpebral Aperture Size (PAS), Horizontal Visible Iris Diameter (HVID), and pupil size.
4. Select lens diameter (TD).
5. Select BOZR.
6. Predict the BOZD, FOZD, and BVP that would be suitable.
7. Select an appropriate trial lens.
8. Insert the lens and allow it to settle.
9. Assess lens fitting: note size, position, movement, lag, and fluorescein pattern (if appropriate).
10. Measure Front Surface K (FSK) (if appropriate), over Rx, best vision sphere over-Rx, over-Rx vertex distance, and the resulting visual acuities.
11. Compare your results with those you calculated from their spectacle Rx/over-Rx, etc.
12. Fill out an order for a suitable lens.

# Unit 8.5

(1 Hour)

## Lecture 8.5: Refitting PMMA Lens Wearers



## **Course Overview**

### **Lecture 8.5: Refitting PMMA Lens Wearers**

- I      Background and Rationale**
- II     Refitting Considerations and Criteria**
- III    Refitting Techniques and After-Care**

# Lecture 8.5

(1 Hour)

## Refitting PMMA Lens Wearers

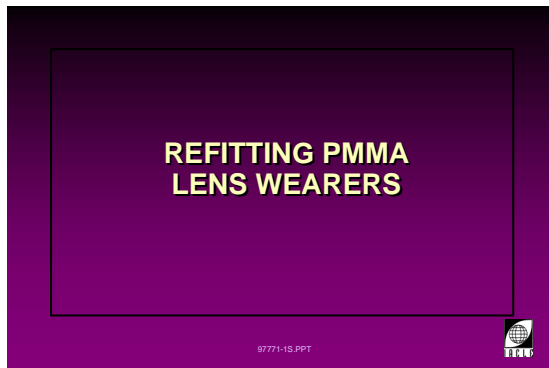


## Table of Contents

<b>I</b>	<b>Refitting PMMA Lens Wearers: Background and Rationale .....</b>	<b>213</b>
<b>II</b>	<b>Refitting Considerations and Criteria.....</b>	<b>217</b>
<b>III</b>	<b>Refitting Techniques and After-Care .....</b>	<b>222</b>

## I Refitting PMMA Lens Wearers: Background and Rationale

1



8L597771-1

### Introduction to Refitting PMMA Lens Wearers

One of the most difficult tasks for a contact lens practitioner is the refitting of veteran PMMA contact lens wearers.

Despite RGP lenses having been available for more than two decades, there are still some 'happy' PMMA wearers among the general population. Fortunately, their numbers are dwindling but not necessarily for the right reasons, e.g. discontinuation of contact lens wear rather than conversion to superior products.

While the wearers may be 'happy' there is compelling evidence that the cornea has every reason to be quite 'unhappy' with its continued burden in the form of PMMA lens wear.

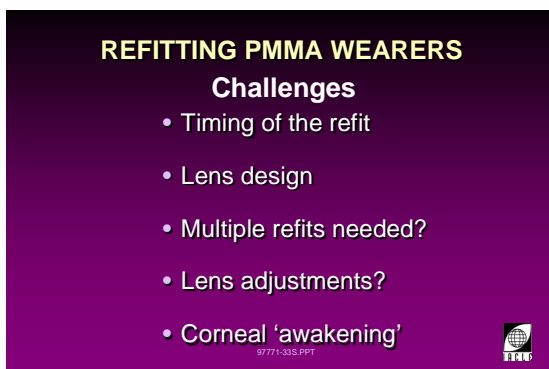
One of the more obvious signs of alteration to the anterior eye by long-term PMMA lens wear is endothelial polymegethism. To date, the significance of polymegethism has not been determined with certainty.

Other common clinical signs of corneal oedema include the epithelial presentations of Central Corneal Clouding and oedematous corneal formations. The so-called Corneal Exhaustion Syndrome is another documented condition (Sweeney, 1992) that presented itself during the PMMA 'era'.

The challenges for the contact lens practitioner include:

- How long, if at all, should the PMMA lenses be left out before refitting with RGP lenses?
- What BOZR, TD, and other design features should be used for the initial RGP lenses?
- The possible need for several RGP lenses before any refitting is considered 'successful' or complete.
- How often are such lens parameter changes likely to be required?
- How to deal with the return of corneal sensitivity.
  - the corneal sensitivity of the PMMA-wearing cornea is reduced significantly by the hypoxic conditions under such lenses. As a result, the cornea is almost anaesthetized.

2



8L597771-33

3



**REASONS FOR REFITTING**

- Visual
- Physical
- Physiological

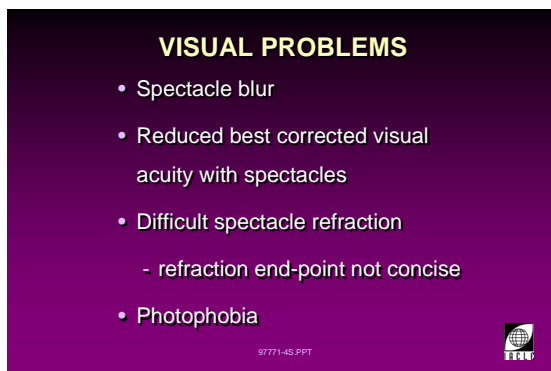
9771-3S.PPT

8L597771-3

**Reasons for Refitting**

- Visual: prolonged significant spectacle blur
  - the spectacle blur refraction is the Rx measured immediately after contact lens removal (Brungardt and Potter (1971)).
- Physical: corneal distortion and/or warpage.
- Physiological:
  - overwear causing corneal oedema;
  - lens intolerance;
  - other corneal decompensation;
  - chronic corneal oedema (can be asymptomatic).

4



**VISUAL PROBLEMS**

- Spectacle blur
- Reduced best corrected visual acuity with spectacles
- Difficult spectacle refraction
  - refraction end-point not concise
- Photophobia

9771-4S.PPT

8L597771-4

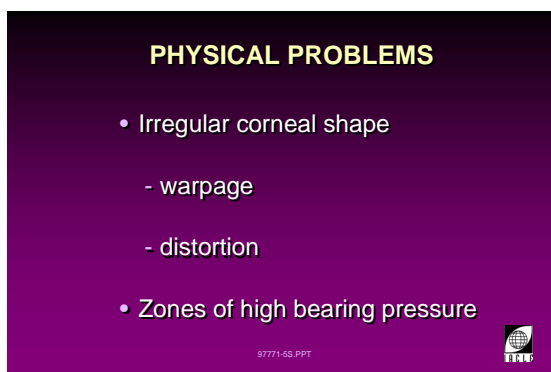
**Visual Problems with PMMA Lens Wear**

Efron *et al.* (1988) showed that the amount of ametropia influenced the total contact lens-wearing time per week. Higher ametropes wore their lenses more, suggesting a greater 'dependence'. It is probable that rigid lens wearers exhibited similar characteristics.

Optical issues to consider include:

- Spectacle blur – amount and duration following removal of the contact lenses.
- Refraction changes are not just the result of corneal curvature changes (Neill, 1962).
- Corneal curvature changes overnight are usually a flattening (approx. 0.75 D) when PMMA contact lenses are removed after sleep (Rengstorff, 1979).
- Light sensitivity can be a result of light scatter secondary to corneal oedema.

5



**PHYSICAL PROBLEMS**

- Irregular corneal shape
  - warpage
  - distortion
- Zones of high bearing pressure

9771-5S.PPT

8L597771-5

**Physical Problems Associated with PMMA Lens Wear**

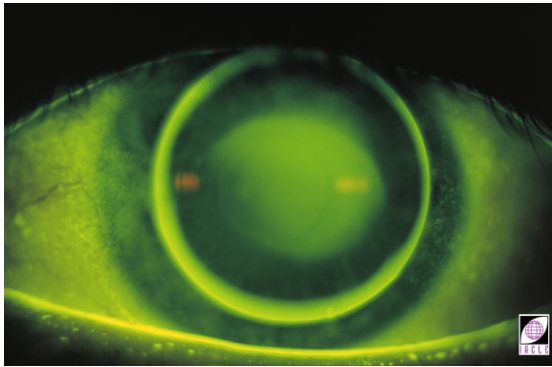
Astigmatism resulting from meridional differences in corneal curvature can vary considerably and can appear as irregular astigmatism.

It cannot be assumed that a steep fitting lens will result in a reduced corneal radius of curvature (steepening). In a study of 40 eyes with steep fitting PMMA lenses (slide 6) worn for periods up to 6 years, 24 corneas steepened, 12 flattened and 4 remained unaltered (Hill and Rengstorff, 1974).

Alignment and flat fitting lenses are more likely to cause corneal flattening. In some cases of superior lens decentration and/or lid attachment fitting, the cornea may mimic the shape of keratoconus where the superior cornea flattens and the inferior steepens (slide 7).

Upon ceasing lens wear, it takes up to 30 days for corneal changes to revert to baseline values according to Farkas (1976) and about 50 or more days according to Rengstorff (1969) and Williams (1988).

6

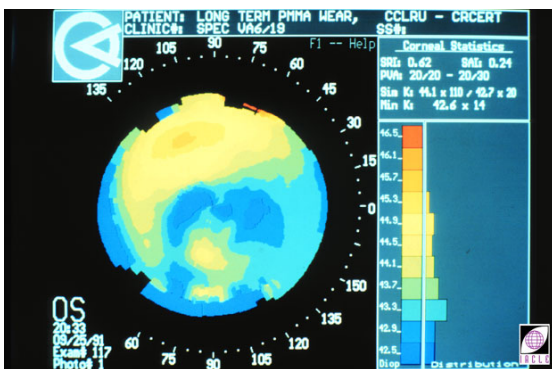


8L50166-00

Calossi *et al.* (1994) reported a case of the same PMMA lenses being worn for 30 years. They noted the presence of irregular astigmatism and loss of radial symmetry. Somewhat surprisingly, the cornea was restored to 'normal' condition following cessation of lens wear after just 12 weeks.

Huff (1992) suggested the possibility that corneal warpage and other corneal changes induced by PMMA wear (and significant hypoxia in general) may be due to an impaired corneal stromal matrix which may include loss of GAGs (glycosaminoglycans) from the stromal ground substance. Such losses may be localized or more general.

7



8L51414-91

8

**PHYSIOLOGICAL PROBLEMS**

- Epithelial staining/abrasion/erosion
- Endothelial polymegethism/pleomorphism
- Stromal oedema
- Haloes around lights
- Decreased wearing time
  - corneal exhaustion syndrome (CES)
- Reduced corneal sensitivity
- Vascularization

8L597771-6

**Physiological Problems Associated with PMMA Lens Wear**

A substantial number of physiological problems can be associated with PMMA lens wear. The majority of these are due to the corneal hypoxia resulting from the use of very low oxygen transmissibility lenses. Practically, the oxygen supply to the cornea during PMMA lens wear is achieved by tear exchange alone.

McMahon *et al.* (1996) showed that, compared to an age-matched population, long-term PMMA wearers showed significantly greater polymegethism (slide 9), lower endothelial cell density, and attendant greater average cell size.

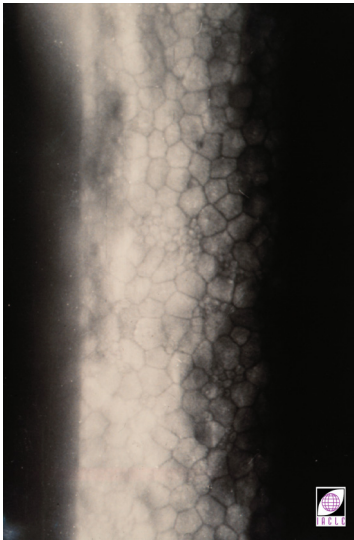
On average, the corneal thickness recovery rate following induced hypoxia was the same for both groups. However, a sub-group of the PMMA wearers studied showed a substantially reduced recovery rate that was strongly correlated with the number of years of wear and altered endothelial cell morphology.

Interestingly, the findings of Schoessler and Woloschak (1981) and Schoessler (1987) agreed with the polymegethism findings of McMahon *et al.* (1996) but showed no cell density changes.

Corneal oedema can be significant and may alter the refractive status and visual capacity of the eye.

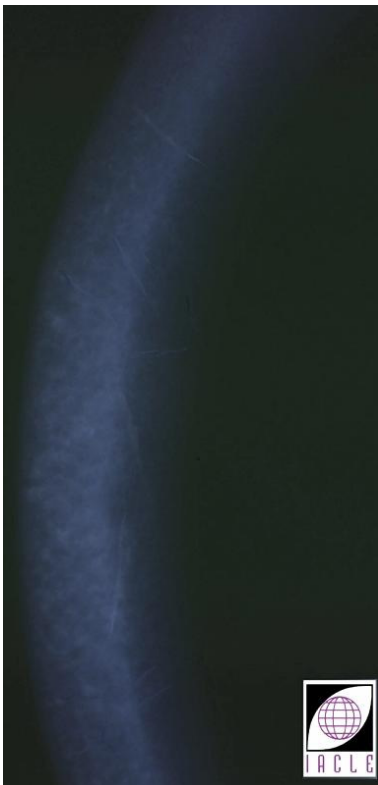


9



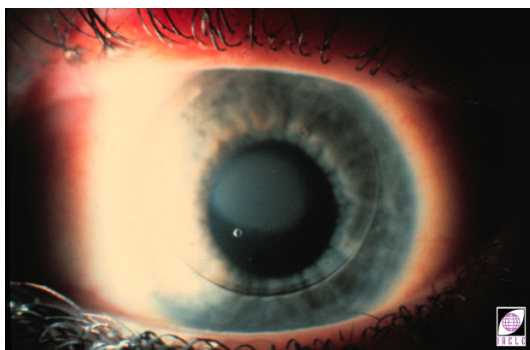8L51664-91

10



8L52015A-95

11



8L50629-91

Generally, oedema takes the form of one of the following:

- An oedematous corneal formation that has a sub-epithelial arborized or dendritic pattern (slide 10).
- Central Corneal Clouding that appears as a circumscribed (round) greyish haze when viewed against the black pupil (slide 11).

Chronic corneal oedema is endemic even in successful, asymptomatic PMMA lens wearers even when no clinical signs of hypoxia are evident. Snyder and Gordon (1985) evaluated a group of such patients and found a dramatic decrease in corneal thickness, a slight flattening of corneal curvature, and no significant refractive changes in cases of immediate refitting of PMMA wearers with low Dk RGP lenses.

The PMMA-wearing cornea had significantly reduced corneal sensitivity due largely to hypoxic conditions under such lenses.

## II Refitting Considerations and Criteria

12

### REFITTING PMMA WEARERS

- Reasons for refitting
- Patient assessment
- Problems
- Procedures

9771-25.PPT



8L597771-2

### Considerations When Refitting PMMA Lens Wearers

The landmark Fort Dix Report (Rengstorff, 1965) confirmed that PMMA contact lenses had pronounced effects on corneal curvature, e.g. distortion or warpage, that prudent contact lens practitioners could not ignore.

Refitting PMMA lens wearers with an alternative contact lens can take many months before a satisfactory outcome is achieved. The practitioner must consider a number of factors before, during, and after any refitting with RGP lenses.

Corneal warpage usually resolves over time if the eye is refitted with RGP lenses or if contact lens wear ceases altogether. However, achieving corneal curvature stabilization can be difficult in some cases (Bennett and Gilbreath, 1983) and any irregular component may be slow to resolve or may be permanent (Levenson and Berry, 1983).

Further, the refitted patient may experience discomfort with their new RGP lenses. This may be due in part to the return of much or all of the cornea's sensitivity. Deposits on the front surface of the lens or a decrease in lens wettability may further exacerbate the increased lens awareness that accompanies this return of corneal sensitivity (Andrasko, 1986).

Reliable, long-term and detailed historical patient information is usually not available, especially data relating to original lens parameters and corneal topography (or even just simple K readings). Refitting requires a great deal of 'guesstimation' (a combination of guesswork, estimation, anticipation, and clinical experience) as well as a good measure of trial and error (and a generous dose of patience).

The patient's working and general environments and other conditions in which the new lenses are to be used should be ascertained. Are the conditions suited to the use of soft lenses and were they a factor in selecting hard lenses in the first place?

Where possible, the wearer should be refitted with RGP lenses that *duplicate* the original PMMA lens design/parameters. Unfortunately, most frequently, this crucial information is not available or ascertainable, though some information can be obtained by measuring the current lenses. If stability of fit cannot be achieved in a reasonable time, soft lenses may need to be considered (Baldwin, 1987).

13

### REFITTING PMMA WEARERS

- Success can take time (several months?)
- Achieving a stable corneal shape can be difficult
  - some irregularity may be permanent
- Wearer may experience discomfort in new lenses (improved corneal sensitivity)
- Detailed historic data often unavailable
  - intuition often required as a substitute
- Where available, duplicate PMMA lens parameters

9771-25.PPT




8L597771-42

14

**REFITTING PROBLEMS**

- Hypoxia-tolerant, hypoaesthetic corneas
- Post-contact lens wear spectacle blur
- Corneal thickness/swelling/oedema
- Corneal curvature/refractive changes



8L97771-34

**Refitting Problems – Learned Before the RGP Lens Era**


Patients who were able to wear PMMA lenses successfully were, by nature of this ability, a selected population of individuals with ‘hypoxia-tolerant’ corneas. These PMMA patients of the past would typically report that they were experiencing no problems with lens wear. However, eye examinations often revealed corneal oedema and corneal distortion.

The absence of complaints may have been due to corneal hypoaesthesia. Also of assistance was the lens’ ability to mask any underlying corneal curvature changes, thereby providing a good level of vision.

15

**REFITTING PROBLEMS**

- Corneal distortion
- Fluctuating corneal shape
- Fluctuating refractive error
  - induced astigmatism
  - risk of permanency
- Reduced/variable visual acuity



8L97771-8

The following are some of the clinical findings that have been reported to be related to PMMA lens wear:

**Post-Contact Lens Wear Spectacle Blur**

- Brungardt and Potter (1971) showed that the spectacle blur refraction was essentially the same as the pre-contact lens spectacle Rx, i.e. within  $\pm 0.37$  D of the original for 76.3% of a large patient group of myopes (n=89). The contact lens Rx was also found to be similar, i.e. the spectacle Rx corrected for vertex distance.

**Corneal Thickness**

- Those wearers who exhibited oedema during lens wear also showed fluctuations in corneal thickness (hydration) after discontinuation of lens wear (Polse, 1972). Between 15 to 19 days were required for the effect to stabilize and the greatest changes were recorded on or about the third day (Polse, 1972).

**Corneal Curvature Changes/Refractive Changes**

- Change in corneal shape is a function of the number of years of lens wear (Rengstorff, 1969). Rengstorff (1973) showed that over a 1 to 6 year period, the fitting of PMMA lenses was characterized by a requirement to steepen the BOZR progressively. The original lens design had no bearing on the outcome, although the effect was more pronounced in the longer-term wearers.
- WTR toricity (horizontal flattening) increased after lens wear ceased (commonly about 3 D but up to 6 D has been reported). If lens wear is to be discontinued altogether, Rengstorff (1977) suggested that it is better to reduce wearing time gradually than to suddenly cease wear.
- According to Williams (1988), the greatest changes in corneal shape occurred in the first few days after discontinuation of lens wear and the refractive changes were induced largely by changes in corneal curvature. A less predictable outcome with regard to corneal shape and spectacle refraction was reported by Bennett

and Gilbreath (1983). Rengstorff also found that refractive changes were related to, but not identical to, corneal curvature changes (Rengstorff 1978). In this same work, Rengstorff also found that changes of corneal curvature of up to 1 D that varied in a circadian pattern were common in PMMA wearers (Rengstorff 1978). The changes ranged from 0.50 D to 1.5 D in curvature, and from 0.50 D to 3 D in refractive error.

#### Corneal Distortion

- Rengstorff (1965) found significant corneal distortion in 30% of long-term PMMA wearers.
- The possibility of permanent corneal distortion and resulting refractive error exists.

16

#### APPROACHES TO PMMA REFITTING

- 'Cold Turkey'
- Gradual ↓ in wearing time
- Refit immediately

9771-355.PPT



8L97771-35

#### Approaches to PMMA Refitting:

##### Before the RGP Lens Era

Early in the PMMA era and before RGP lenses, any corneal distortion and/or astigmatism caused by a tight fitting lens in long-term lens wearers was treated by changing the design of the PMMA lenses, e.g. reducing the TD and BOZD and also flattening the peripheral curves (Rengstorff, 1979). No alternative materials existed at the time so the avenues available to a practitioner were quite limited.

##### Approaches include:

- The 'cold turkey' approach, in which lens wear was discontinued suddenly, and the wearer went for many days or weeks without contact lenses, was not recommended because of associated corneal deformation and poor VA during the 'treatment' period.
- An alternative approach was to reduce wearing time gradually and then refit (Rengstorff 1975, Arner 1977). Arner (1977) advocated the use of a decrease in lens-wearing hours each day over several weeks to 'de-adapt', as he called it. He found that this minimized corneal deformation and acuity loss.

##### PMMA Refitting Today:

- The most popular approach today, and probably the most considerate from a patient perspective, is to simply refit the patient without delay. Lens fit is assessed under normal wearing circumstances and not after the original lenses had been off the eye for hours or days, i.e. the cornea is fitted promptly after PMMA lens removal using the corneal topography as it is found.


17

**CRITERIA FOR REFITTING**

97771-36S.PPT

**Reasons for refitting ALL PMMA wearers:**

- Presence of chronic corneal oedema
- Potential for corneal warpage/distortion
- Corneal hypoaesthesia is an unsuitable criterion for making refitting decisions
  - the lack of symptoms is ominous




8L97771-36

18

**CRITERIA FOR REFITTING**

Polse, 1974

- Decreased BCVA
- Prolonged spectacle blur
- Central corneal clouding (CCC)
- Coalescent corneal staining




8L97771-26

19

**CRITERIA FOR REFITTING**

Bennett, 1986

- Prolonged spectacle blur (>30 min)
- > Grade 1 CCC
- Coalescent central or peripheral corneal punctate staining
- Distorted keratometer mires
- $\Delta Ks \geq 0.75 D$
- Best spectacle Rx  $\rightarrow$  6/7.5 or worse VA
- Vascularization >1 mm into cornea
- Gradual  $\downarrow$  in wearing time




8L97771-38

20

**CRITERIA FOR REFITTING**

Sweeney, 1992

- Lens discomfort
- Reduced lens tolerance
- Blurred or fluctuating vision
- Excessive oedema response to:
  - hydrogel lenses
  - low Dk RGP lenses
- Significant endothelial changes:
  - polymegethism
  - bumpiness/distortion



8L597771-27

**When to Refit PMMA Lens Wearers**

A patient who is still wearing PMMA lenses (typically an older patient) will often report that they are experiencing no problems with lens wear. They may present for a routine eye examination or to obtain new spectacles. An eye examination may reveal no significant corneal oedema or distortion.

Most long-term wearers have no subjective symptoms and, therefore, offer a particular problem to practitioners because they do not believe that they need to be refitted. Consequently, symptomatology is a poor barometer to gauge proper contact lens fitting and freedom from adverse effects in the well-adapted PMMA contact lens wearer (Rengstorff, 1975).

However, in these cases the philosophy of 'no symptoms, no treatment' or 'if it isn't broken, don't fix it' should not apply (Polse, 1974). It is now well-accepted that *all* PMMA wearers should be refitted with lenses that offer much better physiological circumstances to the cornea, especially with regard to oxygen transmissibility. Snyder and Gordon (1985) evaluated such asymptomatic patients and found significant evidence of chronic corneal oedema, based upon pachymetry measures.

Polse (1974) proposed the following criteria for when to refit PMMA wearers:

- Spectacle blur  $\geq 6/9$  for greater than 45 minutes.
- Irregular corneal curvature.
- Persistent oedema or oedematous corneal lines (black lines, striae).
- Change in corneal curvature  $\geq 1 D$ .
- Persistent corneal staining.
- Wearer discomfort.

The detailed refitting criteria given by Bennett (1986) are presented in slide 19 while the criteria for refitting PMMA and low Dk hydrogel wearers proposed by Sweeney (1992) appear in slide 20.


21

**REFITTING  
LENS CHOICE**

- RGP
- Hydrogel
- Silicone hydrogel
- Hybrid
- Scleral (pre-formed?)

- uncommon

97771-32S.PPT



8L597771-32

**What to Refit: RGP or Soft**

Options for refitting the PMMA patient include an RGP, hydrogel, siloxane hydrogel, or perhaps a hybrid lens. A scleral lens, especially a preformed lens, is also a possibility, albeit a less common one.

Refitting with an RGP lens is by far the most common solution to solving the problems induced by PMMA lenses. Minor complaints of the increased need for cleaning, mild irritation due to the near-normal corneal sensitivity, and lens flexibility (handling difficulties and/or perceptions of reduced durability) far outweighed the physiological advantages imparted by the use of RGP materials.

The superiority of even low Dk RGP lenses compared to PMMA was shown early in the history of RGP lenses (Mandell 1977; Sarver *et al.*, 1977; Pearlstone, 1978 cited in Blake and Pearlstone, 1979; Hodd 1979; Goldberg 1979; Sarver *et al.* 1979; Finnemore and Korb, 1980).

Some even promoted the superiority of low Dk soft lenses (Fatt and St Helen, 1971; Hill and Augsburg, 1971; Polse 1974; Farkas 1976).

Once high Dk (100) RGP lenses became readily available, Holden (1989) suggested large RGP lenses be used for refitting.

Henry *et al.* (1991) advocated that all PMMA wearers should be refitted with RGP or if necessary, SCLs. In contrast with Holden (1989) (the high Dk approach), they suggested immediate refitting with a low to moderate oxygen permeable (Dk) lens material to reduce the potential for corneal warpage due to the sudden increase in oxygen availability.

They also believed that less 'exotic' materials (higher Dk at that time) were more stable dimensionally (Ghormley, 1987). It is probable that more modern materials can be just as stable, despite their higher Dk (Cornish, 1991). If a satisfactory and stable result is not achieved in a reasonable time, soft lenses are recommended (Baldwin, 1987).



### III Refitting Techniques and After-Care

22

**WHEN TO REFIT?**

- Immediately, or...
  
- After discontinuing lens wear

97771-12S.PPT



8L597771-12

#### PMMA Refitting Techniques in the RGP Era

The immediate refitting of PMMA wearers with RGP lenses has been advocated by several authors (Bennett, 1983; Redman, 1983; Snyder and Gordon, 1985; Hom, 1986; Williams, 1988; Morris and Wilson, 1992).

To maximize the chances of refitting a PMMA lens wearer successfully, the practitioner should try to establish the current and former eye and lens details. Such information provides a baseline from which the practitioner can monitor the progress of any new lenses.

Where possible, the refitting should be with an RGP lens as close as possible in design to the original PMMA lenses (provided the fit was satisfactory) (Snyder and Gordon, 1985; Redman, 1983). Rehabilitation is usually complete within the first 4 weeks of wear in the new lenses.

In duplicating the PMMA parameters, Snyder and Gordon (1985) found only a slight flattening of corneal curvature and no significant refractive changes when refitting successful PMMA wearers immediately. The patients in their study had no PMMA-related corneal distortion before the refitting.


When pre-existing PMMA lens-related corneal irregularity exists, the immediate refitting approach has been shown not to resolve the distortion completely (Novo *et al.*, 1995).

23

**REFITTING CONSIDERATIONS**

- If discontinuing, for how long?
- Rx
- Lens design
- Material
  - wettability
  - oxygen permeability
  - rigidity

97771-7S.PPT



8L97771-7

In contrast with duplication of previous parameters, an alternate method is to trial fit the patient with RGP diagnostic lenses based on the refractive and keratometric data obtained immediately following the removal of the PMMA lenses. This system works best if there is no indication of any corneal warpage.


Morris and Wilson (1992) suggested fitting RGP lenses which were flatter (0.05 mm) than the original PMMA, had larger BOZDs (0.5 mm), had larger TDs (0.2 mm), and had a BVP that was generally more minus than the PMMA originals. Holden (1989) suggested large high Dk (100) RGP lenses fitted with central alignment and a slightly flat periphery. The new lenses should be fitted immediately and the cornea should not be permitted to alter its shape by being left lens-free for any significant period of time. Comfort that was superior to that with PMMA lenses was claimed for this fitting method.

24

**PRELIMINARY REFITTING TECHNIQUE**

- Assessment of current PMMA lens fitting
- Determine spherocylindrical over-Rx
- Measure current spectacle Rx
- Determine spherocylindrical refractive error

97771-11S.PPT




8L597771-11

25

**PRELIMINARY REFITTING TECHNIQUE**

- Measure corneal curvature
- Verify current PMMA lens parameters
- Slit-lamp evaluation
- Compare:
  - current cornea with previous appearances (records, photos, recollections [reliable?])
  - current and previous contact lens parameters

97771-30S.PPT



8L59771-30

26

### REFITTING TECHNIQUE CHOOSING A LENS

- Oxygen requirements
- Wettability
- Deposit resistance

97771-15S.PPT



8L597771-15

27

### REFITTING TECHNIQUE CHOOSING A LENS

- Preferably, use *original* PMMA lens parameters (data available?), or...
- Use current PMMA lens design as a guide
- Otherwise, fit cornea *as it is* after PMMA lens
- Use RGP trial lens fitting set
- Consider lens centre thickness
  - make thicker if lens flexure excessive

97771-14S.PPT



8L97771-14

28

### REFITTING TECHNIQUE ORDERING A LENS

- Over minus the BVP?
  - clinical judgment required
- Material Dk
  - is a stepped change in  $Dk/t$  needed?
  - medium or high Dk?

97771-16S.PPT



8L97771-16

29

### PATIENT EDUCATION

Changes to:

- Wearing schedule
- Care and maintenance regimens
- Lens handling
  - risk of scratching
  - risk of breakage
  - proper storage
- Lens tinting
- Lens insertion and removal

97771-17S.PPT



8L597771-17

### Choosing the New Lens Material and Design

It is important to consider the potential difference in lens wettability and deposit formation when converting a patient from PMMA to an RGP lens material.

The effects of the lower rigidity of RGP lenses compared with PMMA should be factored into the design of the new lenses. Selection of a flatter BOZR, larger TD, steeper peripheral curve to give a reduced edge clearance, and an increased centre thickness compared to the PMMA lens design can optimize the RGP performance (Bennett, 1985).

An increased centre thickness of the initial (at least) pair of RGP lenses also improves lens durability and handling. For wearers accustomed to rigid and 'unbreakable' PMMA lenses, the benefits of a thicker lens ease the refitted wearer into the extra care required for their new lenses.

Since PMMA lenses delivered oxygen to the cornea only via tear exchange (the so-called 'tear pump'), the lenses were usually fitted with smaller TDs. The increased oxygen availability through the RGP lenses allows larger diameter lenses to be fitted. The larger lens size offers better potential pupil coverage and perhaps greater lens-wearing comfort because of reduced lens-lid interaction.

### Patient Education Issues

Inherent differences between PMMA and RGP lens materials means that re-education of the PMMA lens wearer is vitally important to their long-term success in RGP lenses. It is imprudent to assume that these wearers are able to care for their lenses properly.

Tips that the practitioner can offer the patient include:


- RGP lenses are 'softer' and can scratch more easily.
- Lens cleaning is important and should be done immediately after lens removal.

30

**PATIENT EDUCATION**

- Modify patient expectations
- Patient needs to understand the need for change
  - pictures and diagrams
  - videos
- Frequent after-care required
  - lens performance
  - ocular response
  - subjective response


97771-28S.PPT



8L597771-28

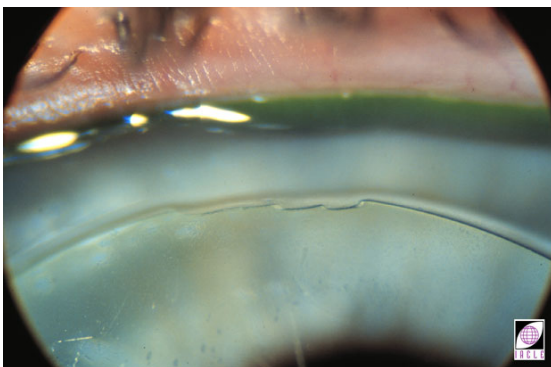
- Lens cleaning should be done in the palm of the hand and not between the fingers (the latter tends to 'flatten' the lenses).
- RGP lenses are more fragile and can chip (slides 31, 32), crack or warp.
- Lens care products formulated specifically for RGP materials are available and are the only ones that should be used.

31



8L51787-93

32



8L50053-94

33

**AFTER-CARE**

- Schedule of visits to be followed
- Early days/weeks are critical
- Attendance is essential
- 'Returning' corneal sensation is a key issue to be dealt with

97771-18S.PPT



8L597771-18

**After-Care Issues**

Scheduled after-care visits for refitted patients should occur more frequently than would be the case for new RGP lens patients. This is especially true for the first few days. Patients should be seen early in the new lens-wearing cycle:

- Between the first and third day after the new lenses are dispensed.
- At 1 and 4 weeks after that first after-care visit would be prudent. This schedule ensures that any fitting problems such as lens adherence (slides 36 and 37) can be detected and resolved (if possible).

The rate of after-care visits should then be tailored to the individual's circumstances. More visits should be requested if changes or complications are


34

**AFTER-CARE**

Changes from baseline values need assessment:

- Lens fitting
- Over-Rx
- Comfort
- Spectacle refraction
- Corneal topography
- Corneal appearance

9771-19S.PPT



8L597771-19

35

**AFTER-CARE**

Advising patient on:

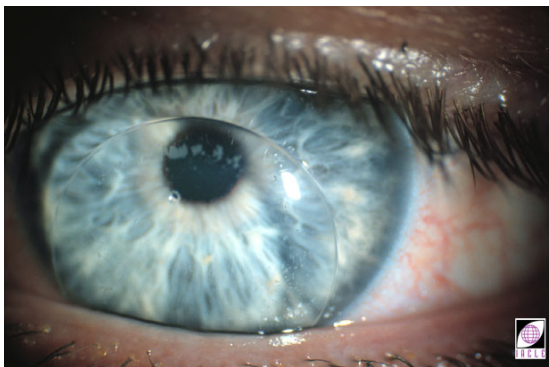- Changes observed
- Risk of lens adherence
- Lens awareness
- Foreign body sensations

9771-20S.PPT



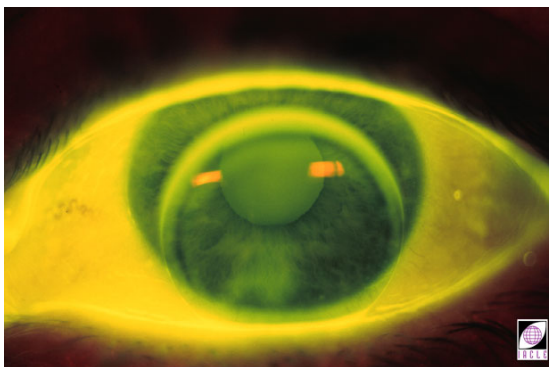
8L597771-20

36



8L50080-97

37



8L50199-91

experienced, while a less rigorous schedule should apply to apparently uncomplicated cases. Visits at the 12 week and 12 month points should also be scheduled to evaluate the effectiveness and completeness of corneal rehabilitation, and corneal stability.

The patient should be advised to:

- not leave their lenses out for extended periods without seeking professional advice first;
- adopt the attitude 'if in doubt, take them out' (and contact their practitioner).

After the first 4 to 6 weeks of RGP lens wear, the post-contact lens wear spectacle refraction should yield a consistent result, with the Rx having stabilized. Similarly, the VA associated with the spectacle refraction should improve somewhat compared to the level found with the immediate post-PMMA lens wear spectacle refraction. Consequently, the opportunity to determine a stable spectacle refraction should present after approximately 6 weeks of new RGP lens wear.

38

**AFTER-CARE  
PRESCRIBING SPECTACLES AFTER  
REFITTING**

- Delay for 4-6 weeks after commencement of successful RGP lens wear
- Advise patients of the potential (probable?) need to make changes in Rx and/or lens parameters over time

97771-37S.PPT



8L597771-37

39

**DEALING WITH PROBLEMS**

- Adjusting the BVP
  - modify existing lens, or...
  - reorder

97771-21S.PPT



8L597771-21

**Dealing with Refitting Problems**

Corneal changes can occur at an unanticipated rate and extent, with stabilization of the cornea extending over many months in some cases. Because of this, the contact lens design and prescription may need to be altered, and the post-contact lens wear spectacle prescription may need to be modified.

The patient should be made aware of these probabilities before any rehabilitation and/or remediation is undertaken. To raise these issues at some later time threatens the credibility of the practitioner, and tests the patience of the lens wearer.

40

**DEALING WITH PROBLEMS  
LENSES**

- Design improvements
- Deposits
- Poor wetting
- Damage
- Refitting with a SCL

97771-22S.PPT



8L597771-22

Small alterations in BVP can be made to RGP lenses either by a laboratory or in the practice using standard lens modification equipment. Further, small alterations can be made to the peripheral curves (flattening), and the edge profile can be altered slightly. Changes to the BOZR or lens design, significant BVP alterations, and TD increases all require a new lens.

41

**DEALING WITH PROBLEMS  
OCULAR HEALTH**

- Dryness/soreness/redness
- Palpebral conjunctival changes
- Lid margin changes

97771-23S.PPT



8L597771-23

**Ocular Health after Refitting**

Patients should be advised that their eyes may become more aware of the RGP lenses over the first few weeks and months of wear and that this is a good, albeit somewhat unwelcome, sign. This phenomenon is primarily due to the recovery of corneal sensitivity reduced previously by the poor physiological circumstances under PMMA lenses.

Any alteration in lens wettability and/or deposit formation on the RGP lenses may also pre-dispose the wearer to superior palpebral conjunctival changes, e.g. papillary conjunctivitis.



42

### REFITTING PMMA LENS WEARERS SUMMARY

- Refit immediately with an RGP lens:
  - consider using medium to high Dk materials initially
- Design, re-educate, then dispense
- Copy PMMA lens design, or...
- Refit larger, flatter, in a similar design
  - assess using a trial lens



8L597771-39

### Refitting PMMA Wearers: Summary and Conclusions

- Refit immediately with an RGP lens.
  - use medium to high Dk materials.
- Design, Re-educate, and then Dispense.
- Either copy the current lens design and parameters, or...
- Refit larger, flatter, and of similar design based on a trial lens fitting assessment.
- Warn of the likely need to change the lenses several times.
- Explain the reasons for delaying the determination of the spectacle Rx by at least 4 to 6 weeks of successful RGP lens wear.

Provide After-Care:

- On the first day to ascertain the acceptability of the new lenses.
- Within the first few days of new lens wear to monitor progress.
- At the 1 week stage.
- A 4 weeks to confirm the rate of change has slowed considerably.
- At the 12 week stage to confirm rehabilitation is well advanced or complete.
- At the 12 month stage to confirm ongoing stability.

43

### REFITTING PMMA LENS WEARERS SUMMARY

- BEFORE dispensing new lenses, warn of the probable need to alter them subsequently,
- Explain the need to delay finalizing the spectacle Rx until after some 4-6 weeks of successful contact lens wear



8L597771-40

44

### REFITTING PMMA LENS WEARERS SUMMARY

#### Schedule after-care visits:

- On the first day
- Within the first few days (say day 1-3)
- At 1 week
- At 1 month
- At 3 months
- At 12 months



8L597771-41

In most cases, if a professional, ethical and scientific approach to the long-term PMMA wearer is taken, and the steps required are explained to the patient *before* any treatment or rehabilitation is started, few problems should be encountered. However, it is uncommon for such courses of treatment to be entirely uneventful.

An understanding of the effects of PMMA lens wear on the cornea (see Module 7, Lecture 7.3: **RGP Contact Lens Complications and Their Management**) and RGP lens fitting experience should be all that is required for the successful refitting of long-term PMMA wearers.



 **References**

- Ames KS, Erickson P (1987). *Optimizing aspheric and spheric rigid lens performance*. CLAO J. 13(3): 165 - 170.
- Andrasko GJ (1986). *Should the 'asymptomatic' PMMA wearer be refitted?* CL Spectrum 1(12): 56 - 58.
- Arner RS (1977). *Corneal de-adaptation - the case against abrupt cessation of contact lens wear*. J Am Optom Assoc. 48(3): 339 - 394.
- Baldwin JS (1987). *The great dilemma: Refitting previous wearers*. CL Forum 12(3): 61 - 69.
- Bennett ES (1983). *Immediate refitting with gas permeable lenses*. J Am Optom Assoc. 54(3): 239 - 242.
- Bennett ES (1985). *Silicone acrylate lens design*. Int Cont Lens Clin. 12(1): 45 - 53.
- Bennett ES (1986). Chapter 15: *Treatment options for PMMA-induced Problems*. In: Bennett ES, Grohe RM (Eds.), *Rigid Gas-Permeable Contact Lenses*. Professional Press Books, New York.
- Bennett ES, Gilbreath MK (1983). *Handling PMMA-induced corneal distortion: A case study*. Optom Monthly. Oct: 529 - 533.
- Bennett ES, Tomlinson A (1983). *A comparison of two techniques of refitting long-term polymethyl methacrylate contact lens wearers*. Am J Optom Arch Am Acad Optom. 60(2): 139 - 145.
- Blake RF, Pearlstone AD (1979). *Clinical experience and fitting characteristics of gas-permeable lenses*. Int Cont Lens Clin. 6(5): 246 - 249.
- Brungardt TF, Potter CE (1971). *Spectacle blur refraction of long time contact lens wearers*. Am J Optom Arch Am Acad Optom. 48(5): 418 - 425.
- Burnett Hodd NF (1979). *The permeable hard option*. Optician. 178 (Sept.7): 17 - 19.
- Calossi A, et al. (1994). *Same PMMA contact lenses worn for over 30 years: A case report*. Int Cont Lens Clin. 21(5): 196 - 198.
- Cornish R, et al. (1991). *Relationship between material Dk, flexibility and correction of astigmatism*. Optom Vis Sci. 68(12S) (Suppl.): 145.
- Douthwaite WA, Atkinson HL (1985). *The effect of hard (PMMA) contact lens wear on the corneal curvature and sensitivity*. J Brit Cont Lens Assoc. 8(1): 21 - 25.
- Douthwaite WA, Connelly AT (1986). *The effect of hard and gas permeable contact lenses on refractive error, corneal curvature, thickness and sensitivity*. J Brit Cont Lens Assoc. 9(1): 14 - 20.
- Efron N, et al. (1988). *Wearing patterns with HEMA contact lenses*. Int Cont Lens Clin. 15(11): 344 - 350.
- Farkas P (1976). *Refitting the firm lens patient with soft lenses*. CL Forum. 1(7): 19 - 21.
- Fatt I (1992). *Fenestrated contact lenses...once again*. Optician. 204 (Sept.4): 27 - 29.
- Fatt I, St. Helen (1971). *Oxygen tension under an oxygen permeable contact lens*. Am J Optom Arch Am Acad Optom. 48(7): 545 - 555.
- Finnimore VM, Exford Korb J (1980). *Corneal oedema with polymethylmethacrylate versus gas-permeable rigid polymer contact lenses of identical design*. J Am Optom Assoc. 51(3): 271 - 274.
- Ghormley NR (1987). *Rigid EW lenses: Complications*. Int Cont Lens Clin. 14(6): 219.
- Goldberg JB (1979). *Gas-permeable contact lenses - How good are they?* Int Cont Lens Clin. 6(4): 281 - 287.
- Harknett AL (1984). *An investigation into the aftercare history of PMMA hard lens wearers fitted in 1965*. J Brit Cont Lens Assoc. 7(3): 111 - 120.
- Harris MG, et al. (1975). *The effect of fenestrated contact lenses on central corneal clouding*. Int Cont Lens Clin. 4(2): 35 - 38.

- Harris MG, *et al.* (1977). *The effect of peripherally fenestrated contact lenses on corneal oedema*. Am J Optom Physiol Opt. 54(1): 27 - 30.
- Henry VA, *et al.* (1991). *How to refit contact lens patients*. CL Forum. 16(2)(suppl.): 19 - 26.
- Hill JF, Rengstorff RH (1974). *Relationship between steeply fitted contact lens base curve and corneal curvature changes*. Am J Optom Physiol Opt. 51(5): 340 - 342.
- Hill RM, Augsburger A (1971). *Oxygen tensions at the epithelial surface with a contact lens in situ*. Am J Optom Arch Am Acad Optom. 48(5): 416 - 418.
- Hind HW, Szekely IJ (1959). *Wetting and hydration of contact lenses*. Contacto. 3(3): 65 - 68.
- Holden BA (1989). *Suffocating the cornea with PMMA*. CL Spectrum. 4(5): 69 - 70.
- Hom MM (1986). *Thoughts on contact lens refractive changes*. CL Forum. 11(11): 16 - 20.
- Huff J (1992). Chapter 5: *Corneal Stroma*. In: Bennett ES, Weissman BA (Eds.) (1992), *Clinical Contact Lens Practice*. JB Lippincott Company, Philadelphia.
- Koetting RA. *et al.* (1986). *PMMA lenses worn for twenty years*. J Am Optom Assoc. 57(6): 459 - 461.
- Levenson DS (1983). *Changes in corneal curvature with long-term PMMA contact lens wear*. CLAO J. 9(2): 121 - 125.
- Levenson DS, Berry CV (1983). *Findings on follow-up of corneal warpage patients*. CLAO J. 9(2): 126 - 129.
- Mandell RB (1977). *Oxygen permeability of hard contact lenses*. CL Forum. 2(9): 35 - 43.
- Mc Mahon TT, *et al.* (1996). *Recovery from induced corneal oedema and endothelial morphology after long-term PMMA contact lens wear*. Optom Vis Sci. 73(3): 184 - 188.
- Morris JA, Wilson C (1992). *Refitting of long-term PMMA lens wearers with hard gas permeable materials: Plus and minus points*. J Brit Cont Lens Assoc. 15(2): 85 - 88.
- Neill JC (1962). *Contact Lenses and Myopia*. In: *Transactions of the International Ophthalmic Optical Congress 1961*. Published for: The British Optical Association by Crosby Lockwood & Son Ltd., London.
- Novo AG, *et al.* (1995). *Corneal topographic changes after refitting polymethylmethacrylate contact lens wearers into rigid gas permeable materials*. CLAO J. 21(1): 47 - 51.
- Polse KA (1972). *Changes in corneal hydration after discontinuing contact lens wear*. Am J Optom Arch Am Acad Optom. 49(6): 511 - 516.
- Polse KA (1974). *Refitting of the problem patient*. Int Cont Lens Clin. 1(2): 72 - 82.
- Redman J (1983). *The PMMA to hard gas permeable adjustment*. CL Forum. 8(12): 45 - 53.
- Rengstorff RH (1965). *The Fort Dix report: Longitudinal study of the effects of contact lenses*. Am J Optom Arch Am Acad Optom. 42(3): 153 - 163.
- Rengstorff RH (1969). *Variations in corneal curvature measurement: An after-effect observed with habitual wearers of contact lenses*. Am J Optom Arch Am Acad Optom. 46(1): 45 - 51.
- Rengstorff RH (1971). *Corneal curvature: patterns of change after wearing contact lenses*. J Am Optom Assoc. 42(3): 264.
- Rengstorff RH (1973). *The relationship between contact lens base curve and corneal curvature*. J Am Optom Assoc. 44(3): 291 - 293.
- Rengstorff RH (1975). *Prevention and treatment of corneal damage after wearing contact lenses*. J Am Optom Assoc. 46(3): 277 - 278.
- Rengstorff RH (1977). *Astigmatism after contact lens wear*. Am J Optom Physiol Opt. 54(11): 787 - 791.
- Rengstorff RH (1978). *Circadian rhythm: corneal curvature and refractive changes after wearing contact lenses*. J Am Optom Assoc. 49(4): 443 - 444.
- Rengstorff RH (1979). *Changes in corneal curvature associated with contact lens wear*. J Am Optom Assoc. 50(3): 375 - 377.

Rengstorff RH (1979). *Refitting long-term wearers of hard contact lenses*. Review of Optom. 116(4): 75 - 76.

Rengstorff RH (1985). *Corneal refraction: Relative effects of each corneal component*. J Am Optom Assoc. 56(3): 218 - 219.

Sarver MD, *et al.* (1977). *Patient responses to gas-permeable hard (Polycon®) contact lenses*. Am J Optom Physiol Opt. 54(4): 195 - 200.

Sarver MD, *et al.* (1979). *Corneal oedema with several hard corneal contact lenses*. Am J Optom Physiol Opt. 56(4): 231 - 235.

Schoessler JP (1987). *The corneal endothelium following 20 years of PMMA contact lens wear*. CLAO J. 13(3): 157 - 160.

Schoessler JP, Woloschak MJ (1981). *Corneal endothelium in veteran PMMA contact lens wearers*. Int Cont Lens Clin. 8(6): 19 - 25.

Snyder AC, Gordon A (1985). *Refitting long-term asymptomatic PMMA lens wearers into gas permeable lenses*. J Am Optom Assoc. 56(3): 192 - 196.

Sweeney DF (1992). *Corneal exhaustion syndrome with long-term wear of contact lenses*. Optom Vis Sci. 69(8): 601 - 608.

Williams LJ (1988). *The effects of contact lenses on the cornea with special reference to corneal shape and the endothelium*. A paper presented at the 30th Anniversary Conference of the New Zealand Contact Lens Society, Wellington, New Zealand.

# Unit 8.6

(2 Hours)

## **Lecture 8.6:** Refractive Surgery and Contact Lenses

## Course Overview

### Lecture 8.6: Refractive Surgery and Contact Lenses

- I Description of Surgical Procedures (e.g. Radial Keratotomy (RK), Astigmatic Keratotomy (AK), Penetrating Keratoplasty (PK), Conductive Keratoplasty (CK), Excimer LASER-based procedures, i.e. PRK, LASIK, LASEK (Epi-LASIK), etc.)
- II Post-operative Corneal Changes
- III Fitting Methods and Contact Lens Options After Surgery
- IV Problems Associated with Contact Lens Wear

# Lecture 8.6

(2 Hours)

## Refractive Surgery and Contact Lenses



## Table of Contents

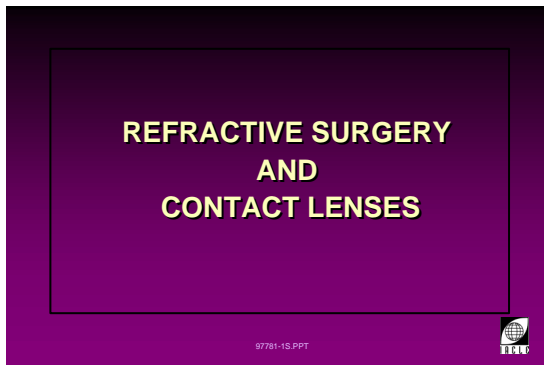
<b>I</b>	<b>Introduction to Refractive Surgery</b> .....	<b>235</b>
<b>II</b>	<b>Penetrating Keratoplasty (PK)</b> .....	<b>239</b>
<b>III</b>	<b>Radial Keratotomy (RK)</b> .....	<b>248</b>
	III.A Astigmatic Keratotomy (AK).....	254
<b>IV</b>	<b>Keratomileusis (KM)</b> .....	<b>256</b>
<b>V</b>	<b>Automated Lamellar Keratoplasty (ALK)</b> .....	<b>258</b>
<b>VI</b>	<b>Photo-Therapeutic Keratectomy (PTK)</b> .....	<b>260</b>
<b>VII</b>	<b>Photo-Refractive Keratectomy (PRK)</b> .....	<b>265</b>
<b>VIII</b>	<b>LASER-ASsisted <i>In Situ</i> Keratomileusis (LASIK)</b> .....	<b>269</b>
<b>IX</b>	<b>LASER-ASsisted Epithelial Keratectomy (LASEK)</b> .....	<b>276</b>
<b>X</b>	<b>Thermal Keratoplasties (TKs)</b> .....	<b>277</b>
	X.A Thermal Keratoplasty (TK) .....	277
	X.B Photo-Thermal Keratoplasty.....	277
	X.C Conductive Keratoplasty (CK) .....	278
<b>XI</b>	<b>Intrastromal Corneal Rings (ICR)</b> .....	<b>280</b>
<b>XII</b>	<b>Clear Lens Extraction (CLE)</b> .....	<b>283</b>
<b>XIII</b>	<b>Intraocular Lenses (IOLs)</b> .....	<b>284</b>
	XIII.A Anterior Chamber IOLs .....	284
	XIII.B Posterior Chamber IOLs.....	285
	XIII.C Aphakic, Posterior Chamber IOLs.....	286
	XIII.D Aphakic, Accommodating IOLs .....	288
<b>XIV</b>	<b>Post-Refractive Surgery Contact Lens Fitting</b> .....	<b>290</b>
<b>XV</b>	<b>Contact Lens Fitting Following PK</b> .....	<b>294</b>
<b>XVI</b>	<b>Contact Lens Fitting Following RK</b> .....	<b>303</b>
<b>XVII</b>	<b>Contact Lens Fitting Following PRK and LASIK</b> .....	<b>309</b>

This lecture is enhanced significantly by the inclusion of images supplied generously by Mr David Pye, UNSW, Sydney (identified by the addition of *DCP* to the slide ID) and Dr Prashant Garg, L V Prasad Eye Institute (LVPEI), Hyderabad (identified by the addition of *LVPEI* to the slide ID).

As well as supplying images, Dr Garg also suggested numerous improvements after a detailed review of an earlier draft of this lecture.

## I Introduction to Refractive Surgery

1



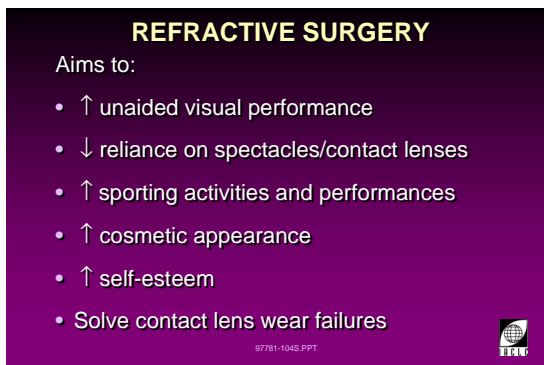8L697781-1

### Refractive Surgery: Introduction

Refractive surgery may be defined as the correction or reduction of any refractive error, including presbyopia, by surgical or surgically-assisted means. Using a success-based definition, refractive surgery has been a phenomenon of the last 30 years. As an ophthalmological pursuit, it has existed for more than a century.

Today, refractive surgery is a highly competitive, commercialized 'business'. Frequently, it is a viable competitor to the more traditional forms of vision correction (i.e. spectacles and contact lenses) as well as the less traditional ones (e.g. orthokeratology, see Lecture 8.9 of this Module).

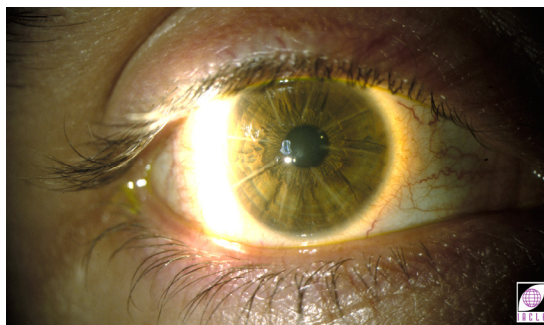
2



8L697781-104

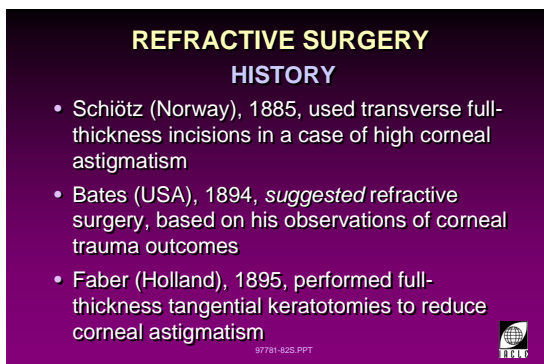
There are many reasons why a patient might consider refractive surgery as an option for their vision correction. It is important that extensive information regarding the pros and cons of refractive surgery be provided professionally. Only in this way can a potential candidate for refractive surgery make informed decisions in their pursuit of suitable vision correction. The contact lens practitioner should not allow his or her personal biases to cloud the issues raised by a prospective refractive surgery patient. Further, it would also be unwise to overstate or understate the responses given to a patient's questions. Equally, it would be imprudent to omit a discussion of the potential adverse outcomes of refractive surgery.

3



8L62667-93

4



8L697781-82

### History of Refractive Surgery


It is probable that the Norwegian ophthalmologist Schiötz (of tonometer fame) was the first to attempt a surgical alteration of refractive error in 1885 when he reduced a case of post-cataract surgically-induced astigmatism of 19.50 to 7.00 D using a 3.5 mm penetrating incision, at the limbus, in the steep meridian ([www.emedicine.com](http://www.emedicine.com), 2004). Later, Faber of the Netherlands (1895) and Lucciola of Italy (1896) also reported surgical astigmatic keratotomies. Lucciola's surgery was noteworthy because he was the first to use non-perforating incisions as part of his technique.

5

**REFRACTIVE SURGERY HISTORY**

- Lucciola (Italy), 1896, operated on 10 cases of corneal astigmatism using *non-perforating* corneal incisions
- Lans (Holland), 1896/97, doctoral thesis on treating corneal astigmatism with '*non-perforating*' incisions

97781-110S.PPT



8L697781-110

Somewhat prophetically, one of the earliest published works on refractive surgery was written by the New York ophthalmologist William H Bates in 1894. Bates went on to become much more famous (infamous?) as the author of the book titled 'Better Eyesight Without Glasses' using techniques unrelated to either surgery or conventional ophthalmic theory or practice.


Bates (1894) suggested the following as a method of correcting corneal astigmatism: "incisions of the cornea are made at right angles to the most convex meridian. The amount of correction can be regulated by the number, depth, shape, and location of the incisions" (essentially, a crude form of Astigmatic Keratotomy [AK]).

6

**REFRACTIVE SURGERY HISTORY**

- Sato (Japan) 1930s/40s, used radial incisions in the endothelium and epithelium
- Fyodorov (Russia), 1970s, used epithelial incisions for radial keratotomy
- Bores and Gould (USA), 1970s, introduced RK to North America

97781-111S.PPT



8L697781-111

The first systematic study of refractive surgery was undertaken in a doctoral thesis by the Dutch medical practitioner Leendert Jan Lans in 1896 (Waring, 1987).

Refractive surgery languished until relatively recently except for the work of Sato (Japan) in the late 1930s, Sato *et al.* (Japan) in the 1950s, and Barraquer (Colombia) in the early 60s. Reintroduction of RK by Fyodorov in the former USSR during the early 1970s prompted a resurgence of interest in refractive surgery. Interestingly, it could be argued that Fyodorov's methods were a variation of Lans' original 1897 work.

Since the 1970s, there has been a virtual explosion of research in the field of refractive surgery followed by a proliferation of surgical techniques and equipment, especially the introduction of the Excimer LASER, culminating in:

- PRK.
- More recently, LASER-ASsisted *In situ* Keratomileusis (LASIK).
- LASER-ASsisted Epithelial Keratectomy (LASEK).
- LASER Thermal Keratoplasty (LTK, FDA approved 2000).
- CK (a non-LASER technique, FDA-approved [2002, Feb.] for hyperopia).

Where possible in this lecture, the history of each technique is presented along with the technique's details.

Heavy, direct-to-consumers, promotion has been a distinguishing characteristic of modern refractive surgery. Necessitated largely by competitive market forces, this promotional marketing approach has arguably, led to the premature 'release' of many of the techniques.

Until the advent of refractive surgery as a 'consumer product', it was unusual to hear an ophthalmologist extolling their own virtues and the merit of their surgical suite in radio and television advertisements.

7

### REFRACTIVE SURGERY

- Clear Lens Extraction (CLE, a.k.a. Clear Lens Replacement [CLR], a variation of Fukala's operation)
- Limbal Relaxing Incisions (LRIs)
- Astigmatic Keratometry (AK)
- Penetrating Keratoplasty (PK)
- IntraOcular Lenses (IOLs)
- Keratophakia and Epikeratophakia (Epikeratoplasty)

97781-7S.PPT



8L697781-158

### Refractive Surgery Techniques: An Overview

It is virtually impossible to provide a complete list of all the techniques, variations of techniques and acronyms used in this discipline. Only the main techniques and/or key developmental techniques will be covered in this lecture.

More techniques and their variants are evolving frequently.

Initial surgical techniques made little or no attempt to address the more complex problems posed by hyperopes and astigmats. More recently, these problems, as well as those presented by presbyopia, have become the subjects of evolving research into techniques, tools, and outcomes.

8

### REFRACTIVE SURGERY

- Keratomileusis
- Radial Keratotomy (RK)
- Automated Lamellar Keratoplasty (ALK)
- PhotoTherapeutic Keratectomy (PTK, a.k.a. LASER Thermal Keratoplasty [LTK])
- Photo-Refractive Keratectomy (PRK)
- Photo-Astigmatic Refractive Keratectomy (PARK)
- IntraStromal Corneal Ring (ICR) (*inTacs*<sup>®</sup>)

97781-8S.PPT



8L697781-157

9

### REFRACTIVE SURGERY

- LASer-assisted *in situ* Keratomileusis (LASIK)
- LASER-Assisted *in situ* Epithelial Keratomileusis (LASEK, a.k.a. Epithelial LASIK)
- Intraocular or Implantable Contact Lenses (ICLs)
- Conductive Keratoplasty (CK)
- IntraLASIK (a.k.a. IntraLase)
- Custom LASIK (wavefront aberration correction)

97781-9S.PPT



8L697781-156

10

### REFRACTIVE SURGERY PRE-OPERATIVE EVALUATION

- General considerations include:
  - age
  - stability of the refractive error
  - previous contact lens wear
  - motivation

97781-138S.PPT



8L697781-138

### Refractive Surgery: Considerations

In an ideal situation, any refractive surgical procedure should have a high degree of predictability. However, taking spectacle or contact lens Rx's as an example, it is clear that being able to predict the Rx effected accurately is not all that is required to achieving a totally satisfied 'customer'.

Generally, the various techniques of refractive surgery take into account a range of variables in an endeavour to predict the outcome and satisfy all other needs arising.

Many variables play a role in the refractive outcome and some are dependent on the procedure employed by, and the skill of, the surgeon.

11

**REFRACTIVE SURGERY  
PRE-OPERATIVE EVALUATION**

- Exclusion criteria to consider:
  - existing corneal pathology
  - thin cornea
  - reduced best-corrected visual acuity in one eye
  - progressive myopia
  - systemic disease with a collagen abnormality
  - abnormal corneal topography



8L697781-139

Examples of the variables include:

- Refractive error (type and magnitude).
- Patient age.
- Gender.
- Corneal thickness and hydration.
- Ambient humidity during surgery.
- Ocular surface characteristics.

While some variables can be controlled, others by their very nature or because of technological limitations, are uncontrollable. In most cases, there is limited consensus on how to predict accurately the refractive outcome. It is necessary for the refractive surgeons to have individual nomograms to achieve the highest predictability. Such nomograms may include factors that account for their own techniques.

The risks and benefits of any refractive surgery procedure must be discussed in detail by the surgeon with a prospective candidate. The pre-operative procedures should include:

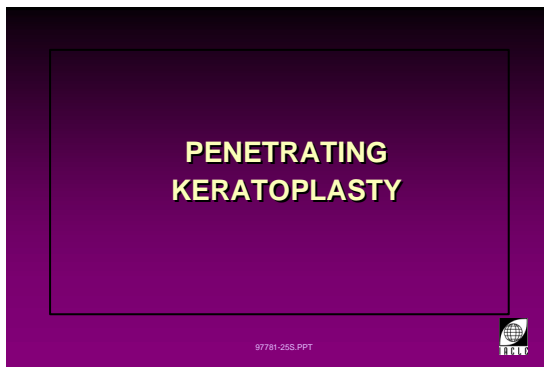
- Manifest and cycloplegic refraction.
- Ocular dominance testing.
- Distance and near unaided vision and VA following refraction.
- Corneal thickness measurement.
- An assessment of corneal topography.
- Overall assessment of the general fitness and suitability of the anterior eye for surgical intervention.

With the wider availability of wave-front aberration measuring technology, means are now available to customize LASER refractive surgery to the individual. It is claimed by Halladay (see Donald, 2005) that a combination of both corneal topography data and wave-front analysis can optimize (customize) LASER ablations that will improve the patient's visual outcome.



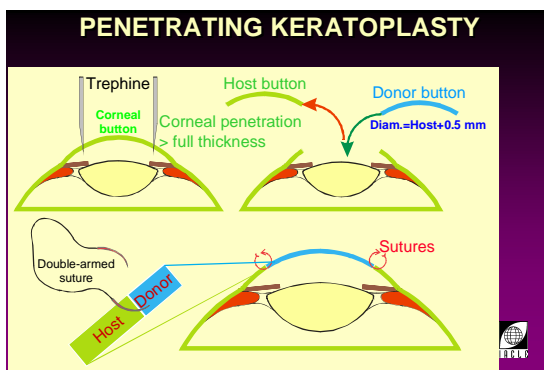
## II Penetrating Keratoplasty (PK)

12



8L697781-25

13



8L697781-168

14

**PK: HISTORY**

- Reisinger (1824) - suggested PK & 'keratoplasty'
- Zirm (1906) - 1<sup>st</sup> successful human PK
- Filatov (1931-1933) - concept of eye banking
- Castroviejo (1930-1950) & Vannas – micro-surgical tools
- Late 1950s – small, fine needles for suturing
- Troutman (mid-1950s) – surgical microscope & keratometer
- Maumenee (1960) – recognizes graft rejection
- Khodadoust – researches graft rejection
- Maurice (1968) – specular microscope
- McCarey & Kaufman (1974) – MK storage media

97781-160S.PPT

8L697781-160

15

**PENETRATING KERATOPLASTY (PK)**

- Abnormal cornea replaced by healthy donor tissue
- Full-thickness graft
- Reasons for grafting
  - optical
  - structural
  - therapeutic
  - cosmetic

97781-26S.PPT

8L697781-26

### Penetrating Keratoplasty (PK, sometimes PKP)

PK is the surgical removal of the full thickness central cornea and its replacement with a human donor corneal graft (slides 13, 16 and 19). It is the most common and the most successful organ transplant technique worldwide. PK is not undertaken on a healthy cornea with normal topography, as is often the case with other refractive surgical procedures. It is included in this section as it can be utilized to significantly improve the refractive capability of the eye. It is probably the only alternative in cases of advanced keratoconus that have proved ultimately to be unsuitable for any type of contact lens including sclerals.

Human PK, and the term 'keratoplasty', were first suggested by Reisinger in 1824 but it was not until 1906 that Zirm (Austria) performed the first successful PK in a human. The related concept of eye banking was fostered by Filatov (Russia, 1875 to 1956) circa 1931 to 1933. The availability of antibiotics in the 1940s and the introduction of steroids aided the rapid evolution of corneal surgery generally and PK in particular. The final surgical step was taken with the improved suturing techniques made possible by the arrival of small fine needles in the late 1950s. The issue of graft rejection was recognized by Maumenee (1960) and researched subsequently by Khodadoust. Microsurgical tools were created by Castroviejo and Vannas among others while Troutman designed special operating microscopes and keratometers as well as various surgical techniques and procedures (mid-1950s). Maurice developed the specular microscope (circa 1968) for use on banked eyes and to view the endothelium post-surgically. Preservation of donor corneal tissue owes much to McCarey and Kaufman (MK medium, circa 1974) (this section largely after: [www.thehighlights.com/Merchant2/merchant.mvc?Screen=CTGY&Store\\_Code=H&Category\\_Code=20-Jan-04](http://www.thehighlights.com/Merchant2/merchant.mvc?Screen=CTGY&Store_Code=H&Category_Code=20-Jan-04), and [www.dog.org/2000/e-abstract\\_2000/620.html](http://www.dog.org/2000/e-abstract_2000/620.html)).

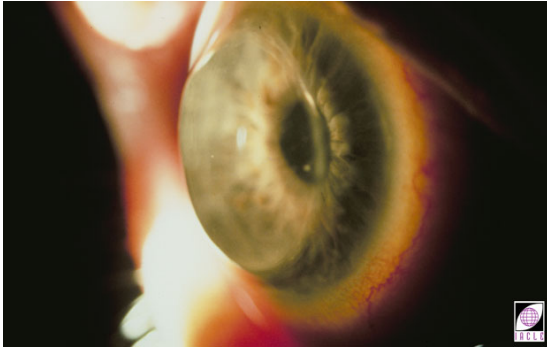
Many different ocular problems may require a PK to restore visual performance or to improve the cosmetic appearance of a badly scarred cornea.

While used for non-keratoconus cases earlier, the use of PK for keratoconus as a mainstream surgical solution for vision improvement probably dates from the early 1950s (see Kennedy *et al*, 1986).

Although VP Filatov is considered the 'father of eye banking' (publications in 1935 and 1937 based on work from 1931 onwards), it is unclear as to how successful his banking proposals were, beyond his own institution. The first US eye bank was set up in New York City in 1959. Eye banks are now relatively common in all parts of the world and have made it possible for grafts and transplants to become routine features of ophthalmological practice.



16



8L61747-97


17

**INDICATION FOR PK**

Most common:

- Keratoconus
- Bullous keratopathy
- Corneal scars and opacities
- Corneal dystrophies

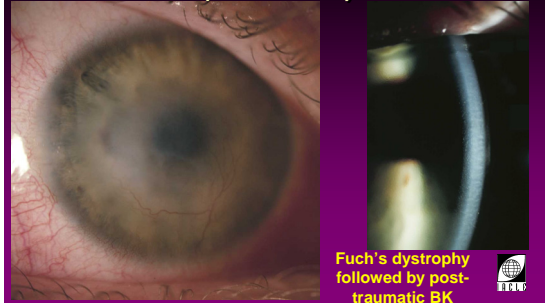
97781-27S.PPT




8L697781-27

18

**BULLOUS KERATOPATHY (BK)  
(Patient: GM)**



Fuch's dystrophy followed by post-traumatic BK



8L697781-232 DCP

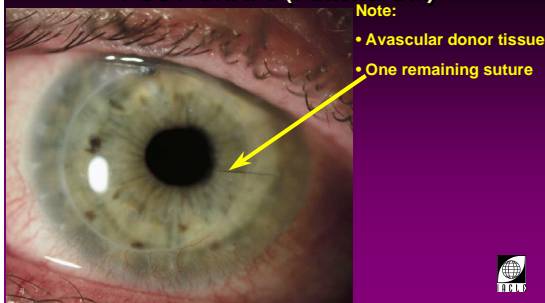

Slide 18 shows a case of Bullous Keratopathy (BK) that developed after trauma to an eye that already had Fuch's dystrophy.

19

**BULLOUS KERATOPATHY (BK)  
POST-GRAFT (Patient: GM)**

Note:

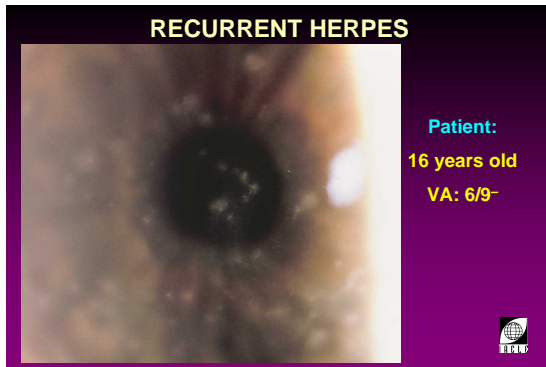
- Avascular donor tissue
- One remaining suture

8L697781-233 DCP

Slide 19 shows the same patient after a PK. It is noteworthy that the donor tissue has remained avascular whereas the host tissue was/is quite vascularized. The reason for the one suture remaining is unknown.

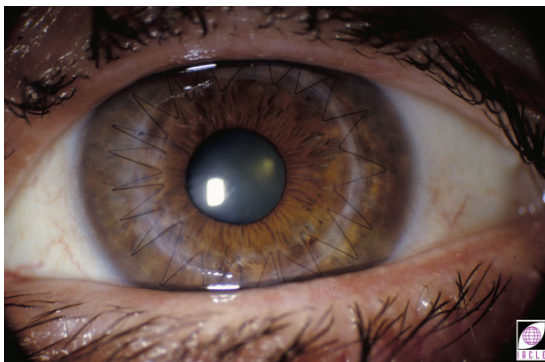
20



8L697781-231 DCP

Slide 20 shows the corneal appearance of a young male who suffered from recurrent herpes (probably herpes simplex). Ultimately, he may be a candidate for a PK should all else fail and his vision be impaired sufficiently, especially if the central cornea is affected.

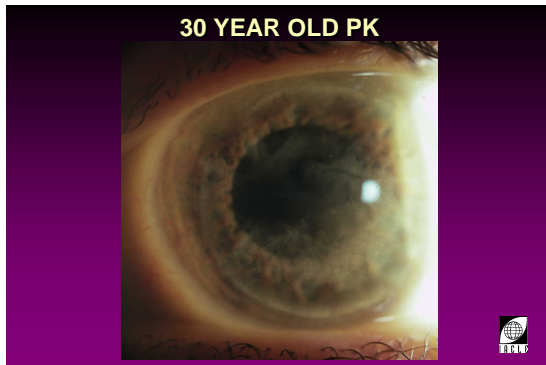
21



8L60676-98

Slide 21 shows a 'quiet' eye some time after surgery but before suture removal. In this case, there is also evidence of early crystalline lens changes.

22

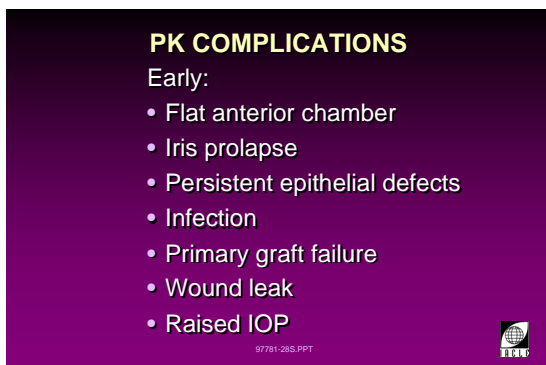

8L697781-225 DCP

The literature on the life expectancy of a PK is unclear. Commonly, failure rates after a certain period of time is given, e.g. the graft failure rate at 15 years after keratoplasty was 28% and was lowest for corneas transplanted for keratoconus. Furthermore, data at 15 years showed that increased donor age increases the risk of graft failure overall (data from Patel *et al.*, 2004).

Some expect the graft to last the rest of the recipient's life but this probably depends largely on the recipient's age at the time of grafting. Slide 22 is an image of a graft that was performed some 30 years beforehand (for recurrent herpes). From its appearance, it is probable that it will require replacement before the recipient's life is over.

23

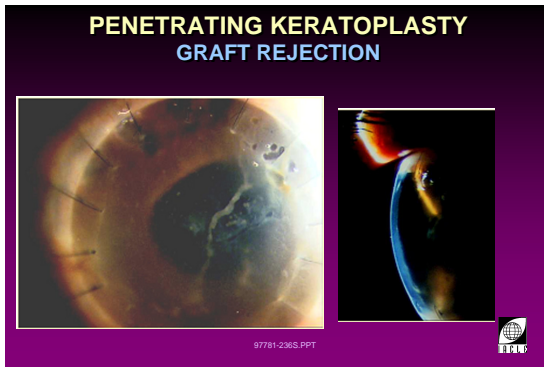


8L697781-28

### Complications with Penetrating Keratoplasty

While the technique is generally 'successful' surgically, a significant number of complications can occur both in the early and late post-operative period. Therefore it is necessary to maintain a frequent after-care schedule to detect these problems. Two most frequent and important complications associated with PK are astigmatism and graft rejection (slide 24). Therefore, it is necessary to maintain a frequent after-care schedule to detect subtle problems such as the onset of vascularization of the corneal graft (slide 25).

24

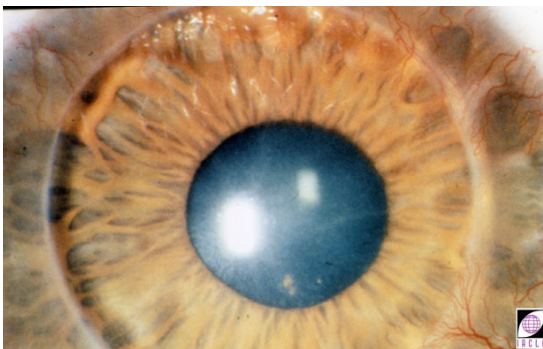


8L697781-236 LVPEI

Both regular and irregular astigmatism of significant degree can be associated with PK surgery (slide 26). Often, especially in keratoconus, the sutures help maintain the regularity of the cornea post-surgically. However, upon their removal, significant corneal astigmatism may develop. This can cause significant visual disability.

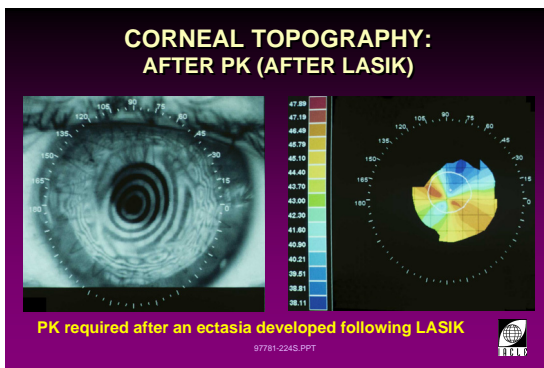
Recently, Javadi *et al.* (2005) studied factors that affected the outcome of PK in keratoconus. They found that neither severity of the disorder, nor trephination and suturing techniques affected the final visual outcome. They did suggest that smaller myopic shifts resulted from graft-recipient disparities of 0.25 mm rather than the more common 0.5 mm (donor tissue larger in diameter).

25



8L6240-97

26



8L697781-224 DCP

27

- PK COMPLICATIONS**
- Late:
- Astigmatism
  - Glaucoma
  - Recurrence of corneal problem
  - Graft failure
  - Rejection
  - Graft infiltrates


8L697781-29

28

**PK GRAFT REJECTION**

- Most likely with post-inflammatory disease PK
- Less common in dystrophic cases
- Risk is greater in the first year
- Inflammatory episode often precedes rejection
- Associated with glaucoma

97781-31S.PPT



8L697781-31

**Graft Rejection Following Penetrating Keratoplasty**

Eye-care practitioners should be aware of the signs and symptoms of corneal graft rejection. A graft is most at risk in the first year after surgery with rejection less frequently observed thereafter.

Early treatment of graft rejection is vital and the use of corticosteroids is often required to preserve the health of the graft tissue. The majority of grafts can be saved by such treatment. However the risk of failure increases significantly the longer remedial treatment is delayed.

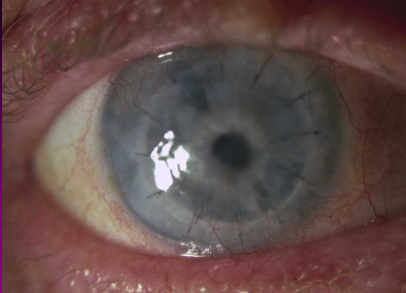
Initial warning signs of a graft rejection episode include:

- Ocular inflammation.
- Reduced vision (note clarity of pupil through the graft in slide 29).


Following the commencement of treatment with steroids, the practitioner must monitor the level of IOP carefully.

29

**FAILED SECOND GRAFT**



97781-227 DCP




8L697781-227 DCP

30

**PENETRATING KERATOPLASTY ASSESSMENT**

- History of the corneal transplant
- Time since surgery
- Age of the patient
- Refractive error and best VA
- Corneal topography measurement
  - keratometry
  - photokeratoscopy
  - videokeratoscopy

97781-32S.PPT



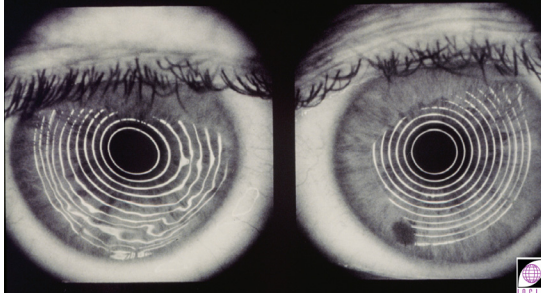
8L697917-32

**Assessment of the Post-Penetrating Keratoplasty Eye**


Following corneal transplantation, the donor tissue is usually quite oedematous and the practitioner may observe striae and folds within. The return to a 'normal' corneal appearance may take some days or weeks. After this period, the graft should be assessed to determine its state of health and to examine factors such as visual performance and corneal topography (slide 31).

A major factor in a successful graft (slide 33) is the health and function of the endothelium. The condition of the endothelium should be checked regularly by the practitioner and must be assessed prior to any contact lens fitting.

31



97781-91S.PPT



8L6791-91

Endothelial cell density is typically much reduced following a PK. Typically, the donor endothelium has a cell density approximately one-third to one-half that of the normal cornea. The change in the endothelium may cause problems during contact lens wear if a lens with low oxygen transmissibility ( $Dk/t$ ) produces corneal oedema.


Corneal sensitivity is reduced significantly following PK (severed nerve fibres). This is an important consideration if contact lenses are fitted on a corneal graft as the patient will experience little or no sensation to indicate anything untoward happening in or to the cornea.



32

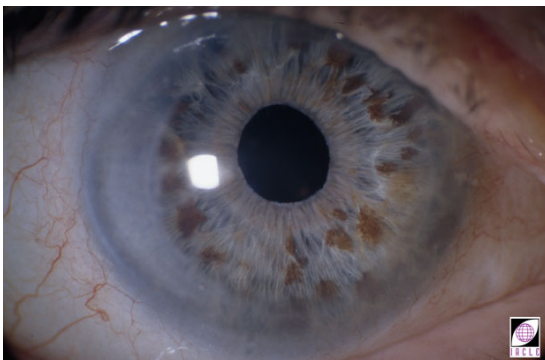
**PENETRATING KERATOPLASTY  
ASSESSMENT**

- Biomicroscopy
  - general corneal health
  - wound healing
  - appearance of sutures
  - endothelial cell layer
  - vascularization
  - anterior chamber inflammation
  - IOP



8L697781-33

33




8L60635-98

34

**CORNEAL TOPOGRAPHY  
ASTIGMATISM**

- Typically, moderate to high
- May be regular or irregular



8L697781-35

**Astigmatism Following Penetrating Keratoplasty**

Despite attention to surgical factors such as trephination of the recipient bed and donor button, graft-host size disparity, wound alignment, and suture placement and tension (slide 36), a significant amount of corneal astigmatism (slides 37 and 38) may be present following a PK.


The astigmatism can be regular or irregular in nature. The irregular astigmatism may be due to:

- host-graft interface wound healing;
- suture tension around the graft;
- scarring.

35

**CORNEAL TOPOGRAPHY  
CAUSES OF ASTIGMATISM**

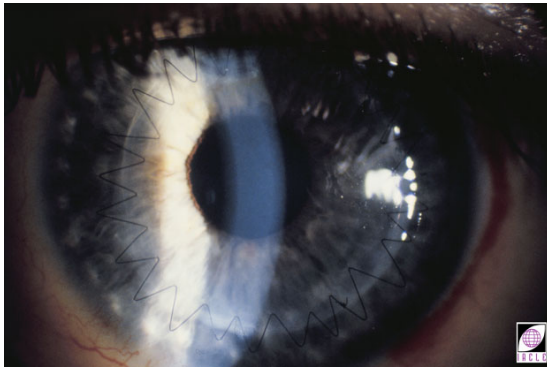- Incorrect placement of cardinal sutures
- Non-radial sutures
- Unequal suture tension(s)
- Pre-existing astigmatism in host or donor cornea
- Scar tissue in host cornea



8L697781-36

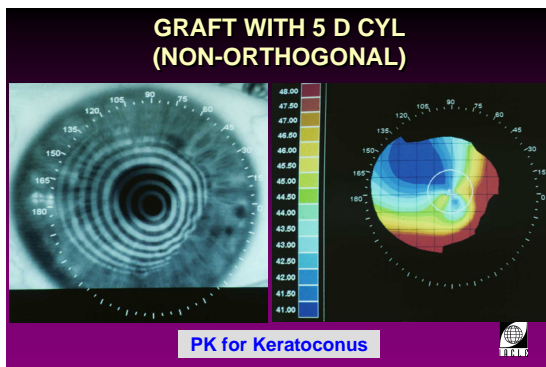
Residual refractive error following PK means that a significant number of patients will require contact lens fitting to achieve their optimum visual performance. Due to the significant astigmatism and irregular corneal shape, the use of RGP lenses is generally the preferred option.

36



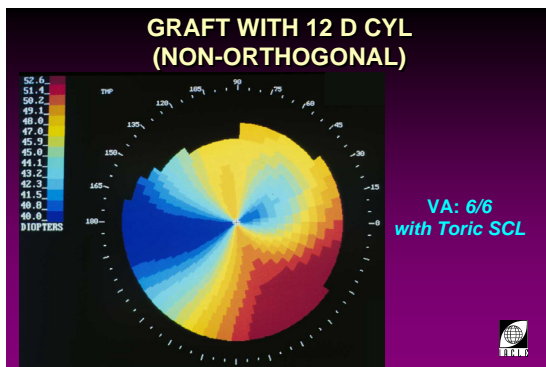
8L60643-97

37



8L697781-230 DCP

38




8L697781-229 DCP

39

**CORNEAL TOPOGRAPHY  
GRAFT APPEARANCE**

- Normal aspheric
- Nipple-like
- Flat centre with steep periphery
- Proud
- Tilted
- Eccentric

97781-34S.PPT



8L697781-34

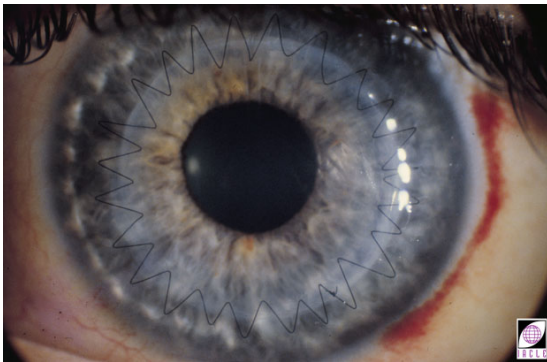
**Penetrating Keratoplasty Graft: Appearance**

Typically, corneal topography after PK is irregular. Factors that have an effect on corneal topography can include:

- Differences in curvatures between host and graft.
- Differences in thicknesses at the tissue interface between host and graft.
- Surgeon's operative technique and skill.
- Suture technique (slide 40) and uniformity of tension around the whole of the graft's circumference.
- Excessively large graft, especially if it is a subsequent graft following an earlier failure.
- Unpredictable healing response.



40



8L60529.7


A number of different graft topographies may be encountered following PK. The graft features have an impact on any subsequent contact lens fitting.

41

**CORNEAL TOPOGRAPHY  
REDUCING ASTIGMATISM**

- Relaxing corneal incisions
- Arcuate keratotomy
- Trapezoidal keratotomy
- Compression sutures
- Wedge resection

97781-37S.PPT



8L697781-37

**Reducing Astigmatism Following Penetrating Keratoplasty**

Correction of the post-PK patient exhibiting reduced vision due to high astigmatic refractive error (slide 42) can be attempted using one or more of a number of surgical techniques. The main limitation of these methods is their lack of predictability. Some techniques such as trapezoidal keratotomy have been all but abandoned in favour of the alternatives.

In most cases, the best method of correcting any astigmatism is with RGP contact lenses.

42

**GRAFT WITH 20 D CYL**



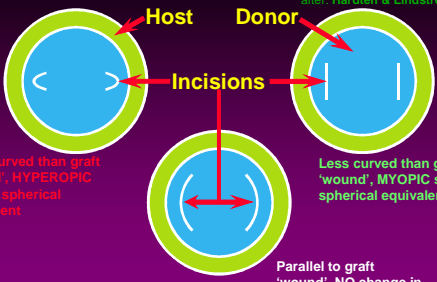
Subsequently, cyl reduced to about 0.50 D by relaxing incisions  
→ Photopic VA: 6/6



8L697781-228 DCP

43

**PK: POST-GRAFT INCISIONS**  
alter: Hardten & Lindstrom, 1997




More curved than graft 'wound', HYPEROPIC shift in spherical equivalent

Less curved than graft 'wound', MYOPIC shift in spherical equivalent

Parallel to graft 'wound', NO change in spherical equivalent

97781-159S.PPT



8L697781-159

**Other Post-PK Refractive Error Corrections**

PK can result in unpredictable spherical errors as well. This can result in gross anisometropia.

If a residual refractive error exists after a PK case has 'settled', consideration must be given to what secondary procedure may improve or correct vision to an acceptable level.

Should a spherical alteration be required, relaxing incisions may be an option (slide 43).

Other possibilities include:

- AK and RK.
- Wedge resection (for astigmatism > 10 D).
- PRK.
- LASIK.

(This section after Hardten and Lindstrom, 1997).

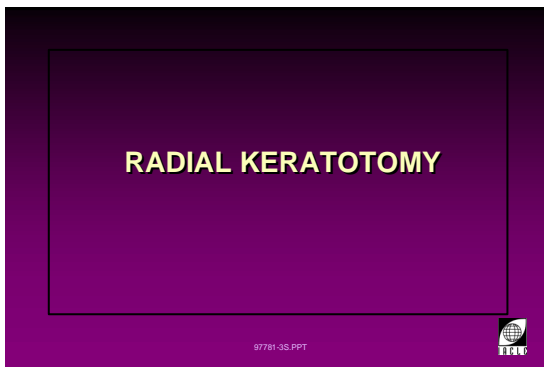
Many patients with residual refractive error can be corrected with contact lenses. These should be the correction of choice before considering surgical options, unless contraindications exist.

Surgery may also be associated with potentially serious complications including:

- Corneal perforation.
- Abscess formation.
- Graft rejection.

### III Radial Keratotomy

44



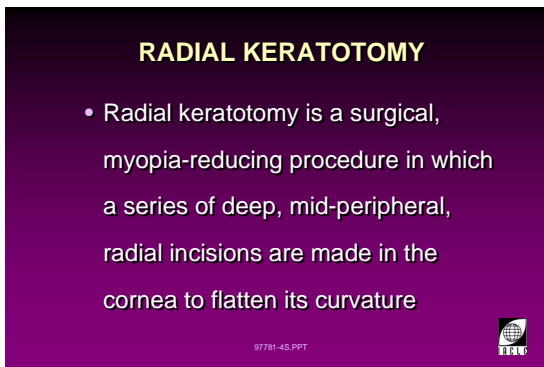
8L697781-3

#### Radial Keratotomy (RK): Overview and History

Refractive surgery involving corneal incisions has been reported for more than a century (slide 46). Papers by Schiötz (1885), Faber (1895), and Lans (1898) reported alterations to astigmatism following corneal incisions (Hardten and Lindstrom, 1997). Not all the incisions used were radial as was Lans' original technique (Allard, 1991).

Lans conducted studies that demonstrated that anterior surface corneal incisions resulted in corneal flattening within the meridian of the tangential incisions. He also demonstrated that deeper and longer incisions are associated with greater flattening and that there was steepening in the meridian 90 degrees away from the tangential incision (Assil, 1994).

45

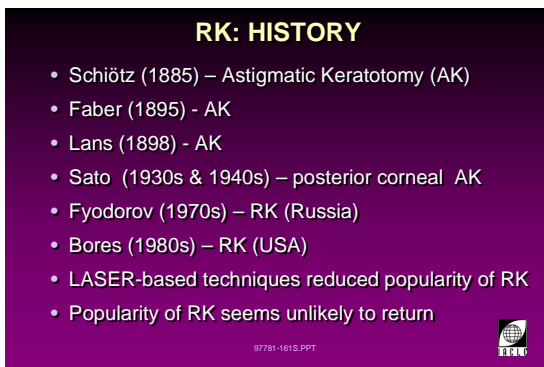

8L697781-4

In the 1930s and 1940s, Sato (Japan) used a posterior corneal technique of RK. The damage to the endothelium resulted in corneal decompensation in many patients who went on to develop frank BK (many required PK subsequently). Further development of RK techniques was limited to the anterior corneal surface.

RK was 'reintroduced' by Fyodorov and Durnev of Russia in the 1970s. It was introduced into the US by Bores in the 1980s (first performed in 1978 [Board of Directors, ISRK, 1988]) but by the early 1990s RK had started to decline because of the rising popularity of LASER-based techniques.

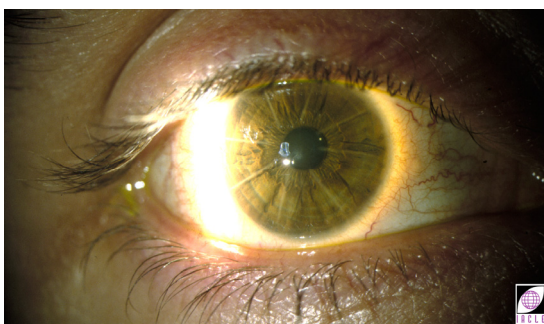
46



8L697781-161

Despite the competition from other procedures, e.g. PRK initially, and ultimately LASIK, and the relatively negative reviews it receives, RK remains in use in many parts of the world, even in the USA. This is probably because of its low equipment cost combined with procedural simplicity. It remains a refractive surgery option for the treatment of low myopia. Interestingly, it was never especially popular in the UK, with practitioners or patients (McGhee *et al.* (1997).

47



8L62667-93

#### Mechanisms

A cut in the cornea (slide 47) relaxes the tissue in the direction at right angles to the incision. If the incision is placed in a *radial* direction, its action is transmitted 360 degrees around the circumference of the cornea. Furthermore, increases in curvature of the mid-peripheral and peripheral cornea result in central flattening. The effect of the incision is proportional to the length and depth of the cut.


*Transverse* incisions act directly on the meridian crossing the central cornea, thus relaxing that meridian (see AK next).

48

**RADIAL KERATOTOMY**  
**PATIENT SELECTION**

- Low myopia <4.00 D
- Stable refractive error
- No corneal or other external eye disease(s)
- Realistic patient expectations

97781-55.PPT



8L697781-5

**Patient Selection for Radial Keratotomy**


To maximize the surgical outcome and predictability of RK, it is necessary for the refractive surgeon to follow a standardized protocol for patient selection and the surgical technique(s) used. It has been suggested that a knowledge of the physical properties of the patient's cornea would improve the predictability of the outcome of refractive surgery, including that of RK. Unfortunately, no clinical technique for assessing relevant factors is yet available.

49

**RK SURGICAL TECHNIQUE**

- Visual axis and optical zone positions are ascertained and marked
- Corneal thickness is measured
- Radial incisions:
  - 4-8
  - to 90% of corneal thickness
  - from just outside optical zone to peripheral cornea
- Infection control
- Manage post-operative pain

97781-65.PPT



8L697781-6

**Surgical Technique for Radial Keratotomy**

Equally-spaced radial incisions (slide 50) are made deeply (90 to 95% but not full thickness, slide 51) into the cornea. The reduced tension in the cornea results in flattening of the central portion of the cornea (slide 52), thereby decreasing the degree of myopia.

Radial incisions alone do not reduce astigmatism and they should not produce unwanted astigmatism if they are made symmetrically on the cornea.

Tangential or arcuate incisions are used to reduce astigmatism. The tangential incisions not only flatten the axis of surgery but also steepen the cornea in the perpendicular meridian.

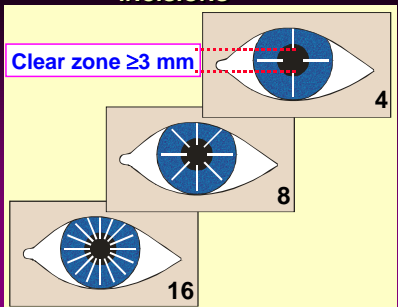
The recommended number of incisions has decreased considerably over the years. In the early phase of RK, it was common to see between 16 and 32 incisions. Modern techniques involve the use of only four (most commonly) to eight equally separated incisions of shorter length.

Should more than four incisions be used or needed, the surgeon is confronted by a situation involving the 'law of diminishing returns', i.e. each additional incision is less effective than the previous one. Consequently, it is now uncommon to see cases in which a large number of incisions have been made.


50

**RADIAL KERATOTOMY INCISIONS**

Clear zone  $\geq 3$  mm



4  
8  
16

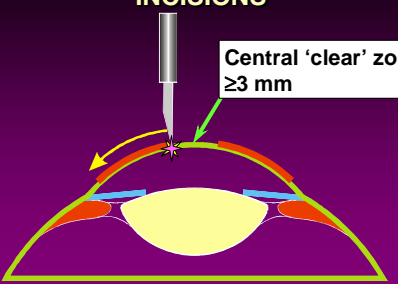


8L697781-169


51

**RADIAL KERATOTOMY INCISIONS**

Central 'clear' zone  $\geq 3$  mm

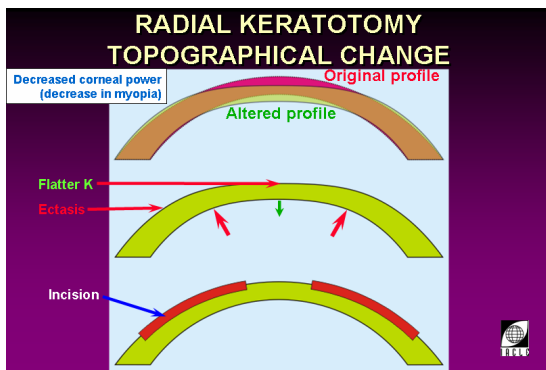


97781-170S.PPT



8L697781-170

52



8L697781-171

53

### RADIAL KERATOTOMY

- Factors determining success
  - diameter of central 'clear' zone
  - patient's age
  - depth of incisions



8L697781-7

### Factors for Success in Radial Keratotomy

The effectiveness and regularity of RK appears to be highly surgeon-dependent but can also be influenced by the patient's age, the incision depth, and the reproducibility of incision depth.

In the interests of good vision, a central, clear, optical zone of 3.5 to 4.0 mm is generally preferred. However, zone diameters exceeding 4.25 mm are sometimes associated with greater variability in the refractive outcome. Therefore, a balance between predictability of outcome and scars in the pericentral zone that may affect vision adversely when the pupil is relatively large needs to be struck.

If a small optic zone diameter is maintained, a greater number of incisions can be made if a higher refractive change is desired.

Fewer radial incisions are recommended in the presence of significant astigmatism. In such cases, six or even four incisions, and a small optic zone are preferred to the alternative of eight incisions with a larger clear zone. The latter may require the placement of arcuate or tangential incisions to correct astigmatism (see AK next).

In an attempt to improve RK, Lindstrom and Casebeer developed alternative RK procedures, e.g. Lindstrom's mini-RK and Casebeer's limbal-sparing RK. Optical zones of 3 to 5.5 mm are used and the incisions only extend out to a diameter of about 7 mm (Lindstrom) or 8 mm (Casebeer). This results in shorter incisions and the limbus and its vasculature are avoided. Both techniques use an ultra-thin diamond blade for finer incisions and approximately normal globe burst strength is claimed. The latter means the eye is at no greater risk of rupture than a normal eye. The smaller incisions tend to limit the amount of myopia correctable by the procedure (probably  $\leq -6$  D).

The mini-RK procedure employs either four or eight deep (95 to 98% depth) incisions and good stability is claimed out to 3 years.

Although still in use, RK and mini-RK procedures are now less common because of the wider availability of more predictable LASER-based procedures.




54

**RK SURGICAL TECHNIQUE**  
**COMPLICATIONS: INTRAOPERATIVE**

- Corneal perforation
  - macro or micro
- Incision extended across the optic zone or onto limbus
- Intersecting incisions
- Poor position of the optical zone

97781-145S.PPT



8L697781-145

**Complications Associated with Radial Keratotomy**

Complications associated with RK range from minor to severe.

Perforation of the globe during the RK procedure (not a rare occurrence) results in aqueous leakage and reduced IOP. The softening of the globe results in insufficient diamond knife penetration on subsequent incisions resulting in an unpredictable refractive outcome. Theoretically, such an event also offers a portal of entry to opportunistic microorganisms and a course of prophylactic antibiotics would normally be instigated.


A common side effect of RK is stellate iron lines. These are iron deposits in the epithelium and are similar to those that appear in keratoconus, Salzmann's Nodular Dystrophy, some corneal scars, keratoplasty, filtering blebs, and so-called Hudson-Stähli lines that appear in otherwise apparently normal corneas (Whaton, 1989).

55

**RADIAL KERATOTOMY**  
**COMPLICATIONS: POSTOPERATIVE**

- Infection
- Epithelial in-growth
- Recurrent corneal erosions
- Corneal oedema
- Globe rupture
- Stellate iron lines (epithelial Fe deposits)

97781-146S.PPT




8L697781-146

56

**OPTICAL PROBLEMS AFTER RK**

- Over-correction
- Under-correction
- Increase in astigmatism
- Loss of best-corrected visual acuity
- Diurnal fluctuations in vision
- Myopic or hyperopic shift
- Decreased contrast sensitivity
- Reduced tolerance of glare

97781-8S.PPT



8L697781-8

**Optical Problems Associated with Radial Keratotomy**

In patients with 1 D or more of astigmatism, the steep meridian should not receive a radial incision so that it is available for simultaneous or subsequent AK if required.

Progressive hyperopia after RK is often associated with the following factors:

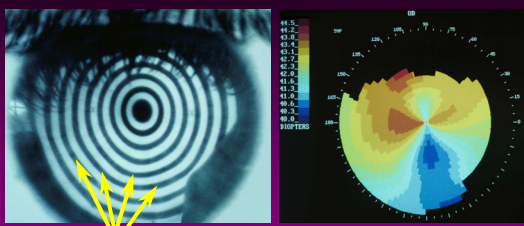
- Radial incisions that extend to the limbus.
- Multiple enhancement procedures.
- Undetected latent hyperopia.
- Peripheral re-deepening procedures.
- Post-operative ocular massage.

A significant problem following RK is the diurnal fluctuation in vision that is experienced by a number of patients. The fluctuation may traverse as many as five lines on a Snellen letter chart.

Another issue is surgically-induced corneal astigmatism (slide 57). One way of reducing this problem is to make transverse relaxing incisions in the cornea (slide 58).


57

**CORNEAL TOPOGRAPHY**  
**AFTER RK**



**Incisions**

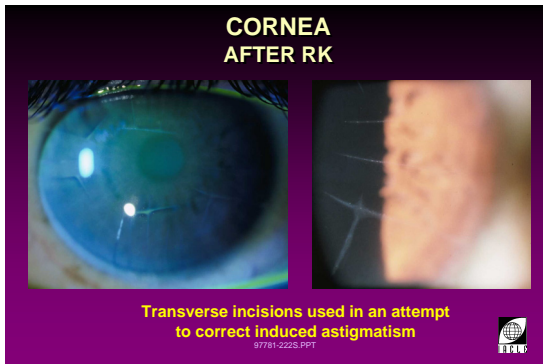
97781-221S.PPT



8L697781-221 DCP

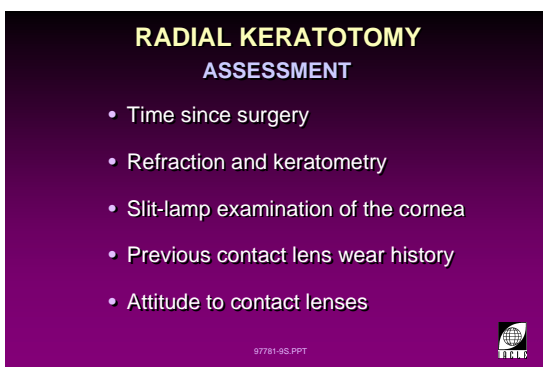


58



8L697781-222 DCP

59



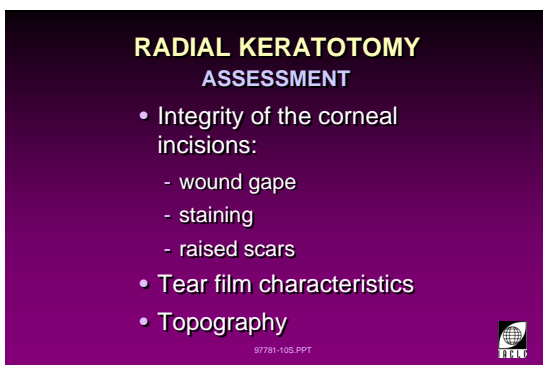
8L697781-9

### Ocular Assessment Following Radial Keratotomy

Contact lenses should only be fitted after the cornea has recovered from any surgically-induced oedema or inflammation. The practitioner should examine the eye to rule out the presence of:

- Excessive limbal redness.
- Vascularization.
- Severe corneal or conjunctival staining.
- Corneal oedema.
- Anterior chamber flare and/or cells.
- Reduced corneal sensitivity.

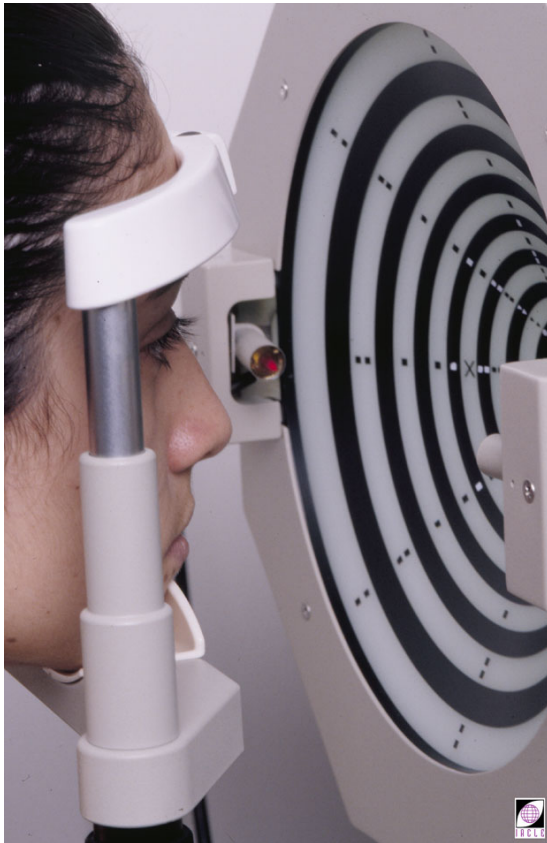
60



8L697781-10

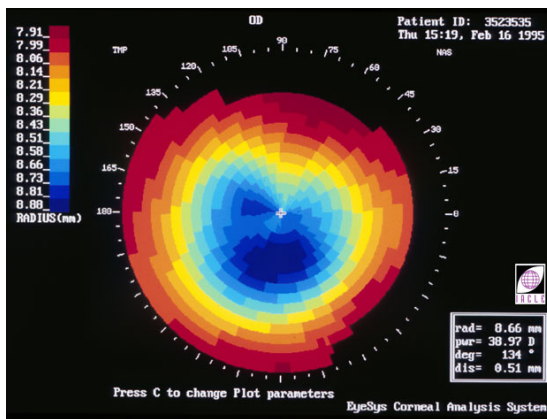
A key factor in post-RK contact lens fitting is the topography of the cornea. Mapping the cornea using a videokeratoscope is essential to a contact lens practitioner determination of the optimum lens design (slides 61, 62, and 63).

61



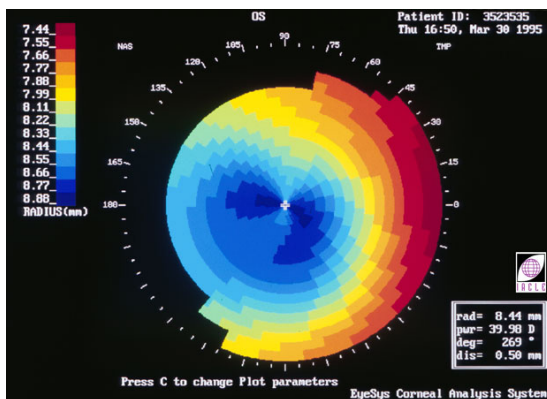
8L6TOPOG

62



8L62058-95

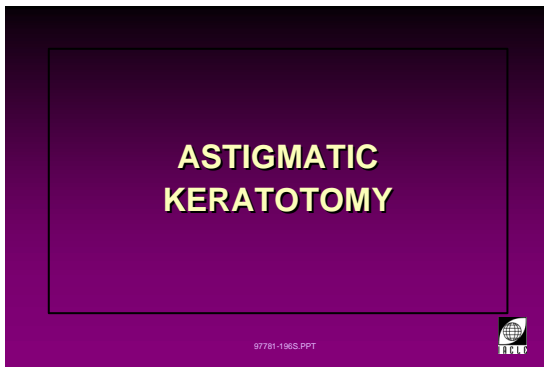
63



8L62057-95

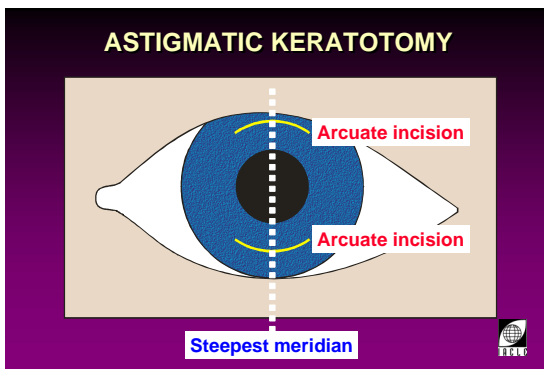
III.A Astigmatic Keratotomy (AK)

64



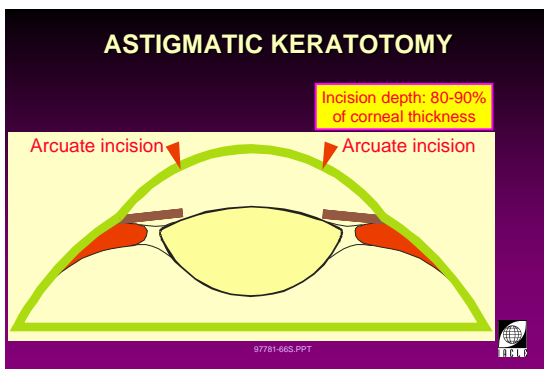
8L697781-196

65



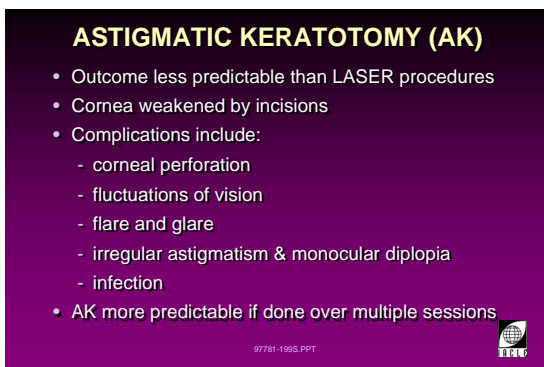
8L697781-197

66



8L697781-198

67



8L697781-199

**Astigmatic Keratotomy (AK)**

AK is a variation of RK in that it too uses relaxing corneal incisions made with either a diamond knife or a single-use disposable blade. However, instead of radial incisions, arcuate, transverse incisions are used (slides 65 and 66) that penetrate to a depth of about 80% of the corneal thickness. The incisions are located peripherally.

AK can be used in conjunction with RK, PRK, and LASIK either as part of the same surgical procedure or as an adjunct procedure (enhancement) subsequently.

Generally, it is an outpatient procedure lasting only a few minutes. The eye is immobilized during the procedure by a ring holder.

As its name suggests, AK targets astigmatism specifically (1 to 5 D) and is used to reduce corneal astigmatism. Often elimination is not possible using AK alone. Consequently, AK may be used to reduce astigmatism significantly and some 3 months later, LASIK can be used to eliminate the residual astigmatism.

The incisions are placed in the steepest corneal meridians and are intended to 'flatten' these areas thereby reducing the curvature differences and the astigmatism these differences cause.

**Astigmatic Keratotomy: Outcome and Complications**

Generally, the outcomes of both RK and AK are less predictable than LASER-based procedures (e.g. PRK and LASIK) but in the hands of a skilled and experienced surgeon, they may approach the latter.

Like RK, the weakened cornea increases the risk of globe rupture following trauma, especially direct trauma, e.g. a direct blow to the eye or the explosive impact of a motor vehicle air bag deploying.

Fluctuations of vision that are either transient or permanent are possible as are haloes, flare, starburst patterns, or veiling glare around lights. Fluctuations may be due to changing corneal curvature, heartbeat, variable pupil size, diurnal variations in IOP, physical exertion, etc. Fluctuations are more likely immediately after surgery and vision may take several weeks to stabilize.

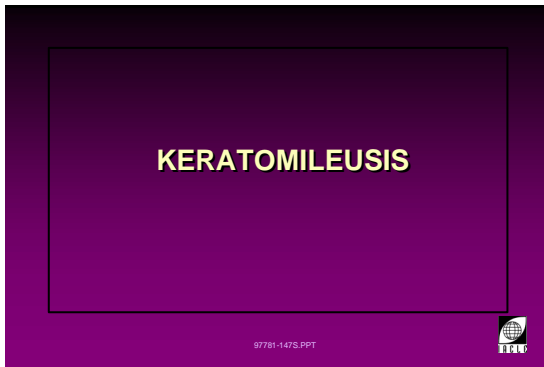Uncommon complications include:

- Accidental perforation of the cornea.
- Irregular or asymmetric incisions resulting in irregular astigmatism.
- Monocular diplopia.
- Infection.
- Photophobia (usually only post-operatively).
- Elevated IOP.
- Cataract and loss of vision.

Although uncommon, these complications can have serious consequences. Performing AK over more than one session (fewer incisions, larger optical zone, less aggressive treatment) reduces the risk of complications.

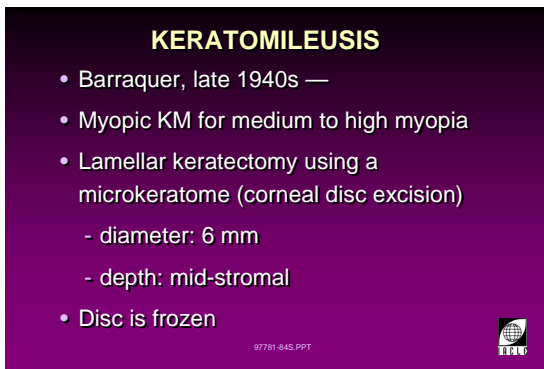
## IV Keratomileusis (KM)

68



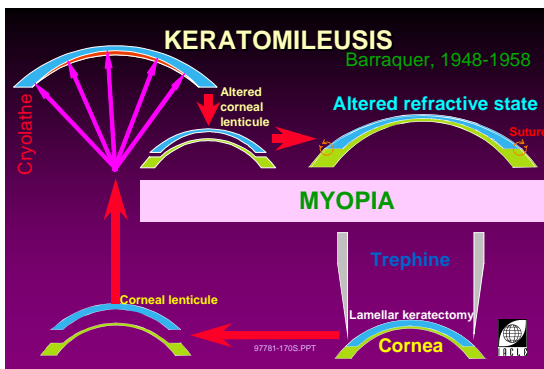
8L697781-147

69



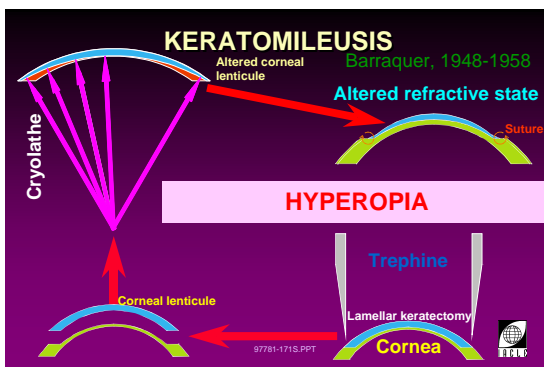
8L697781-84

70



8L697781-172

71



8L697781-173

### Keratomileusis (KM)

The term KM is derived from the Greek words *keras* (hornlike – cornea) and *smileusis* (carving).

From the late 1940s, Barraquer developed the technique of myopic KM in which a cryolathe is used to reshape a corneal disc (not full thickness) removed from the patient's cornea and frozen carefully (slide 70).

In his early technique, the corneal disc was about 300  $\mu\text{m}$  in thickness and 6 to 7 mm in diameter. It was attached to a contact lens lathe and then frozen. The stromal side was lathed to thin the centre of the disc, thus creating a concave lens. A change in the refractive power of the cornea was effected when the corneal disc was replaced.

As a refractive surgical technique to reduce myopia (–6 to –15 D [Thompson *et al.*, 1993]), KM offers moderate predictability. However, the complexity of the Barraquer procedure, difficulty in mastering the technique, and the frequent irregular astigmatism that results, limit its use.

The technique of KM, as described by Barraquer, progressed with the development of more sophisticated instrumentation. Improved microkeratomes and the introduction of the excimer LASER enabled refractive surgeons to refine the technique of stromal lamellar reshaping.

Another technique described as KM *in situ* involves cutting a single lamellar disc of tissue as a cap or a hinged flap, and a second disc as a lamellar section of the bed to thin out the central cornea. The first disc is then replaced and draped into the resected bed, altering the anterior curvature of the cornea and, as a direct result, the refractive error.

One of the difficulties of early KM was obtaining a high quality corneal section. The need for a precise microkeratome that produced accurate and consistent lamellar cuts was recognized early in the technique's evolution (see ALK below).


KM for hyperopes also proved much more difficult and the outcomes were generally less successful (slide 71) (Barraquer, 1996).

72

**KERATOMILEUSIS**

- Disc is lathed to shape in a cryolathe
  - change in refractive power
- Lathed disc is then reinserted into cornea
- Disc sutured in place
- Eye patched until epithelium healed

97781-85S.PPT




8L697781-85

73

**KERATOMILEUSIS**

- Capable of large refractive error corrections
- Extraocular procedure
  - fewer associated complications (?)
- Some irregular astigmatism for 'several months'
- RGPs can be used to refine vision
- Accuracy difficult to achieve
- Procedure is difficult to master

97781-86S.PPT




8L697781-86

74

**KERATOMILEUSIS  
COMPLICATIONS**

- Difficult to master
- Complexity of cryolathing
- Irregular cut by keratome
  - affects visual result
- Epithelial in-growth

97781-143S.PPT

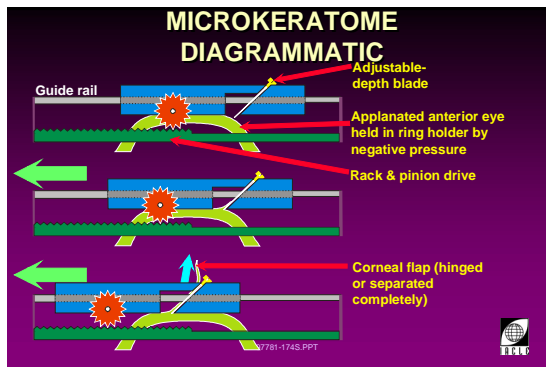


8L697781-143



## V Automated Lamellar Keratoplasty (ALK)

75



8L697781-174

76

**AUTOMATED LAMELLAR KERATOPLASTY (ALK)**

- For hyperopia
  - weakens the cornea by deep lamellar resectioning
    - microkeratome
    - 60 to 70% depth
  - an ectasia results under the flap
  - central cornea steepens effecting a hyperopic shift
    - amount depends on the diameter of the keratectomy

8L697781-101

77

**AUTOMATED LAMELLAR KERATOPLASTY (ALK)**

- The hyperopic analogue of myopic keratomileusis (MKM)
- No sutures are employed
- Refraction stabilized within a month
- Longer term stability is unknown

8L697781-102

78

**AUTOMATED LAMELLAR KERATOPLASTY (ALK)**

- For myopia
  - microkeratome makes a cut about 160 µm deep
  - diameter is about 7.5 to 8.0 mm
  - adjustable suction ring is then reset to resect a smaller diameter of stromal tissue
    - depth dictates degree of correction
  - flap is then replaced and positioned

8L697781-144

### Automated Lamellar Keratoplasty (ALK)

Advances in the technique of KM occurred in 1987 when Dr LA Ruiz developed a new and improved microkeratome (Barraquer, 1996). His device used gears engaging a toothed rack (like a rack or cog railway) (slide 75) to advance the cutting blade. The eye was held by an adjustable-height, suction-ring eye holder. The motorized advancement of this microkeratome permitted a constant velocity traversal that resulted in the resection of an even-thickness, corneal lamellar disc and a smoother corneal stromal bed. This development made lamellar corneal surgery more precise than the original KM technique of Barraquer.

Automated lamellar surgery is extraocular and, therefore, cannot give rise to the complications that are sometimes associated with intraocular surgery.

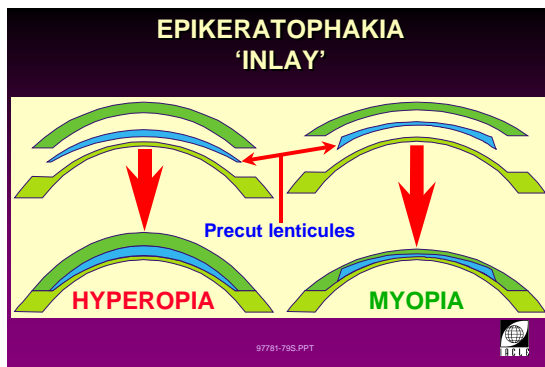
The technique is dependent critically upon correct use of the microkeratome. Careful attention to its operation is crucial. Appropriate placement of the suction ring, consistent suction holding throughout the procedure, and smooth movement of the microkeratome across/through the cornea, are all essential elements of adequate lamellar resections. Interruptions to the movement or suction holding during the resection can result in irregularities and may necessitate aborting the procedure.

Post-operative visual complications after lamellar surgery are similar to those associated with other refractive surgery procedures and include:

- Glare.
- Halos.
- Decreased contrast sensitivity.

The techniques of KM and ALK were the forerunners of techniques that led to the development of LASIK, i.e. Laser-ASSisted *In situ* Keratomileusis.

79




8L697781-175

80

**EPIKERATOPHAKIA**

- Freeze or non-freeze methods used
- Myopia and hyperopia
- Least invasive and most reversible
- Requires donor corneal tissue
- Prelathed lenticule sutured on top of cornea
- Delayed visual recovery common
- Stability and predictability less than desired

97781-90S.PPT



8L697781-90

### Epikeratophakia

The first lamellar refractive technique described by Barraquer was keratophakia. This procedure involved changing the anterior surface of the cornea by placing an insert of corneal tissue (own or donor material) or synthetic material (a corneal inlay) between layers of cornea (slide 79).

In the first keratophakia technique, the microkeratome was used to remove a layer of corneal tissue, and then a pre-cut lenticule, calculated to correct hyperopia, was inserted and covered by the first layer.

When using a synthetic implant, the biocompatibility and physical properties of the material are critical to a successful outcome. High permeability is important with any synthetic implant to allow sufficient corneal nutrition to the adjacent tissue.

Epikeratophakia was introduced by Kaufman in 1979 for the treatment of aphakia. In 1982, Werblin and Klyce used the technique for myopia. The early technique employed freezing and lathing of donor tissue to a pre-calculated power, freeze-drying of this lenticule, and its storage under vacuum. Corrections of up to  $-40$  D of myopia can be achieved using this technique (this section from Thompson *et al.*, 1993).

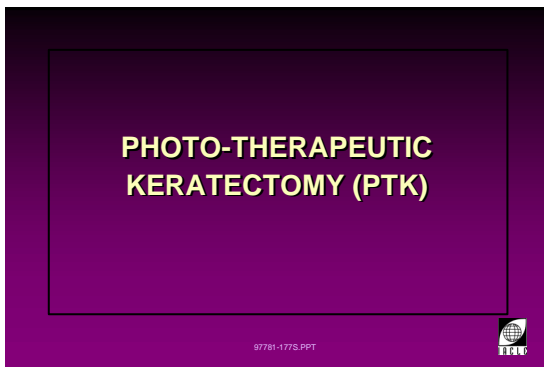The technique of epikeratophakia has lost favour among refractive surgeons. A haze often develops and it is often difficult to achieve a satisfactory level of VA.

Significant irregular astigmatism may also be present.

Recently, Watson and colleagues (in Wakhine, 2004) reported that DLK (procedure that removes a button of nearly full-thickness stroma and the attached epithelium) was an effective alternative to PK in keratoconus. DLK gave similar visual results to PK, was more complicated and demanding to perform, but resulted in fewer cases of rejection and failure because the host's endothelium and Descemet's membrane remained intact. Donor tissue was used to 'replace' the host's keratoconic button.

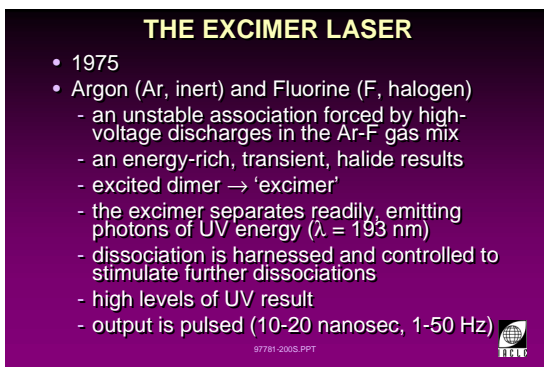
## VI Photo-Therapeutic Keratectomy (PTK)

81



8L697781-177

82



8L697781-200

### Photo-Therapeutic Keratectomy (PTK)

Before LASERs were applied to human eyes for refractive purposes, LASERs were used for therapeutic purposes (in 1986 [Seiler, 1993]) on human corneas (L'Esperance, 1993). Eventually, this use became part of the research and development process that led to LASER refractive surgery.

Therapeutic tasks undertaken included:

- The removal of corneal scars.
- The removal and/or reduction of islands of degeneration, opacities, nodules, etc. in various corneal dystrophies, e.g. the granular dystrophies, Salzmann's degeneration.
- Smoothing corneal surface irregularities due to trauma, pathology, pterygium surgery, etc.

In these cases, smoother, clearer corneas resulted in improved vision.

Excimer LASERs did not exist until 1975 and the early prototypes demonstrated an inherent ability to produce 'enormous' amounts of energy (L'Esperance, 1993). In an excimer LASER, molecules of argon (an inert gas) and fluorine (a halogen gas) are forced into an unstable association under the influence of an 'external' energy source (usually high-voltage discharges in the gas). Electrons are knocked from the argon molecules that then combine electrostatically with negative (electron-rich) fluorine molecules, producing argon fluoride. The resulting energy-rich (excited), diatomic, gaseous but transient halide is termed an 'excited dimer' from which the contraction 'excimer' is derived.

Strictly, dimer should be reserved for a molecule made of two identical atoms rather than a combination of two different atoms (for which the term *exciplex* is applicable). For reasons of simplicity and sound (and marketing?), the term *dimer* has been adopted in this context even though it is not correct technically (L'Esperance, 1993).

Because the excited molecules are unstable they seek a lower energy state (or their ground-state [original, pre-excitement level]), the dimer readily separates into its component gases with the release of photons of UV energy whose wavelength is characteristically (for the Ar-F 'dimer') 193 nm, i.e.  $\lambda=193$  nm. The 'dimer's' lifetime may be as brief as billionths of a second (Gower, 1987).

By design, photons from dissociating dimers are harnessed in a controlled manner to stimulate further dissociations within the gas, i.e. stimulated emission, resulting in relatively high output levels of UV light energy.

By controlling and repeating the excitation and dissociation cycle, excimer LASERs can produce an output of very short pulses (10 to 20 nanoseconds each) that are repeated (1 to 50 pulses per second).

Comparative studies showed that excimer LASERs delivered the optimum combination of power and tissue absorption with minimal collateral damage. The absorption of this coherent UV energy by macromolecules destabilizes/breaks their valency bonds which results in tissue destruction. Carbon-carbon and peptide bonds (in the stroma) can be disrupted readily by excimer wavelengths. The absorbing tissue vapourizes as a 'plume' with very little damage being sustained by the surrounding (deeper) tissue. The 'plume' of ablated tissue is removed from the eye's immediate environment by an integrated air extraction system.

83

**PTK: APPLICATIONS**

- Removal of superficial and sub-epithelial corneal scars
- Removal and/or reduction of islands of degeneration/dystrophies, opacities, etc.
- Smoothing corneal surface irregularities due to trauma, pathology, etc.
- Recurrent corneal erosions



8L697781-178

**Photo-Therapeutic Keratectomy: Patient Selection**

Patient Selection (some after Stark *et al.*, 1993).

The following are indications for PTK treatment:

- Opacities in the anterior one-third of the cornea (<160  $\mu\text{m}$  in depth), e.g. superficial opacities of Reis-Buckler's dystrophy, early granular and lattice stromal dystrophies, herpetic keratitis, and nodule and band dystrophies. Post-PTK corneal thickness must be expected to be >250  $\mu\text{m}$ .
- Patients with corneal surface irregularities that prevent good, functional vision with either spectacles or contact lenses.
- Anterior corneal dystrophies.
- Recurrent corneal erosions that are refractory to conservative treatment with patching, cycloplegia, topical antibiotics, and lubricants.
- Recurrent corneal erosions refractory to mechanical surgical treatment such as corneal micropuncture and/or epithelial curettage.
- Retreatment after primary PTK treatment that resulted in macroerosions complicating recurrent corneal erosion syndrome that had failed conservative management with ocular lubricants (see Maini and Loughnan, 2002).
- BK. PTK using a deeper ablation and adjunctive therapeutic contact lens was described as an easy to perform and effective treatment with less recurrence rate for patients with BK and poor visual potential (see Lin *et al.*, 2001).
- No age restrictions apply but younger patients are preferred because they are more willing to try a contact lens option should hyperopia result post-operatively.

Contraindications (some after Stark *et al.*, 1993):

- Blepharitis.
- Dry eye.
- Lagophthalmos.
- Any active inflammation.
- Thin cornea.
- Systemic immunosuppression.
- Patients unwilling to consider contact lenses post-operatively should be discouraged from undergoing PTK.

84

**PTK: CONTRAINDICATIONS**

- Blepharitis
- Dry eye
- Lagophthalmos
- Active inflammation
- Thin cornea
- Those unwilling to wear CLs postoperatively
- Systemic immunosuppression




8L697781-201

85

**PTK: PROCEDURE  
PREOPERATIVE**

- External & Slit-Lamp examination
- Dilated fundus examination
- Evaluation of VA:
  - with & without Rx
  - with pinhole
  - with RGP lenses
- Pneumotonometry
- Keratometry
- Ultrasonic pachometry
- Corneal thickness at scar locations

97781-202S.PPT




8L697781-202

86

**PTK: PROCEDURE  
PREOPERATIVE**

- Oral analgesic & a sedative
- Topical anaesthetic
- Lid speculum applied
- Patient instructed to fixate target
- Epithelium removed
  - mechanically (if cornea not smooth)
  - using the excimer LASER (if cornea smooth)
- Treatment zone must remain debris and cellular remnant-free

97781-203S.PPT




8L697781-203

87

**PTK: PROCEDURE**

- Surface roughness is 'filled' with viscous liquid, e.g. methyl cellulose, artificial tears
  - 'islands' protrude from surface and absorb more energy
  - a smoother surface results
- Ablation zones up to 6 mm used
- Eye is moved circularly during procedure and a 2 mm beam is used at the treatment zone edge to reduce refractive effects
- Antibiotics, steroids/NSAIDs, and a cycloplegic are used after surgery
- Eye is pressure patched

97781-205S.PPT



8L697781-205

**Photo-Therapeutic Keratectomy: Procedure**

A pre-operative examination should include (after Stark *et al.*, 1993):

- External eye examination.
- Slit-lamp examination.
- Dilated fundus examination.
- VA evaluation with and without Rx, with pinhole, with RGP lenses.
- Corneal thickness at location of corneal scars.
- Where possible the following are also included:
  - pneumotonometry;
  - keratometry;
  - ultrasonic pachometry;
  - videokeratoscopy.

After administering an oral analgesic and a sedative, a topical anaesthetic is instilled. A lid speculum is then applied and the patient asked to fixate the blinking light in the instrument (may vary with device).

The epithelium is removed either mechanically, e.g. the large irregularities of Salzmann nodules {Steinert, 1993} or using the LASER. The choice of method is based on the smoothness of the cornea, e.g. if smooth, the LASER method is used.

The treatment zone surface must be kept free of all debris and cellular remnants. Generally, methylcellulose and/or artificial tears (generally of relatively high viscosity [Steinert, 1993]) are applied to 'fill' the microscopic corneal surface roughness that results from the LASER ablation. These promote a regular surface for treatment by making protrusions stand proud of the corneal surface thereby increasing their exposure to the LASER's ablating energy.

Earlier work using a 6 mm ablation zone and a 0.5 mm 'blend' to the corneal periphery resulted in significant hyperopia. As a result, surgeons have dispensed with the blend and move the patient's eye around circularly (using the fixation target) during the procedure. They treat the edge of the ablation zone with a 2 mm diameter beam to decrease the likelihood of inducing an unwanted hyperopic shift.

Antibiotics, steroids, and a cycloplegic are applied post-surgically and the eye is pressure-patched. Analgesics may be used as required.

Once the eye patch is removed, visual comfort may be improved by the use of sunglasses.

Some ablation-resistant scars have been reported (see McDonnell *et al.*, 1992) and this may be the hyaline material in granular dystrophy (Steinert, 1993).



88

**PTK: POSTOPERATIVE CARE**

- Some discomfort and/or pain for the first 2 to 3 days may require treatment
- Eye examined at two-day intervals until cornea re-epithelializes (usually <1 week)
- Then after-care at:
  - 1 and 3 months
  - subsequently, at 6, 9, 12, 18, and 24 months
- Hypertonic saline ointment may be prescribed for use before sleep



8L697781-206

**Photo-Therapeutic Keratectomy: Post-Operative Care**

Some discomfort and/or pain may be experienced for 2 to 3 days. These symptoms may require treatment.

Patients are examined at 2-day intervals post-surgically until re-epithelialization occurs. Subsequently, they are examined at 1 month and 3 months after surgery. Additional after-care is also delivered at 6, 9, 12, 18 and 24 months.

At each after-care session from the 1-month visit onwards, the assessments made pre-operatively (see above) are repeated.

Hypertonic saline ointment for use before sleep may be prescribed.

89

**PTK: PROCEDURE POSTOPERATIVE (1 MONTH ONWARDS)**

- External & Slit-Lamp examination
- Dilated fundus examination
- Evaluation of VA:
  - with & without Rx
  - with pinhole
  - with RGP lenses (if used)
- Pneumotonometry
- Keratometry
- Ultrasonic pachometry



8L697781-204

90

**PTK: COMPLICATIONS**

- Persistent corneal defects or recurrence
- Corneal infection (ulceration possible)
- Recurrent corneal erosions (postsurgical)
- ↓ corneal 'clarity'
  - subepithelial haze
  - sub-ablation zone scar
- Epithelial hyperplasia
- Adjacent tissue damage
- Induced refractive error
  - hyperopia
  - astigmatism or irregular astigmatism
- Delayed healing



8L697781-207

**Photo-Therapeutic Keratectomy: Complications**

Potential complications include:

- Recurrent erosions (when not the reason for PTK initially).
- Infectious corneal ulceration.
- Persistent epithelial defects.
- Reduced corneal 'clarity' (increased corneal haze or translucency?).
- Some adjacent tissue damage as a result of using an excimer LASER.
- Epithelial hyperplasia.
- Induction of refractive error, especially hyperopia and/or refractive error that does not correct well with sphero-cylindrical lenses leaving reduced vision.
- Irregular astigmatism.
- Reformation of the epithelial basement membrane (basal lamina) adhesion structures may be delayed. Adhesion complexes include hemidesmosomes, the lamina densa and the lamina lucida of the basement membrane, anchoring fibrils, laminin, fibronectin, and type IV and VII collagen. Numerous hemidesmosomes, a major constituent of the adhesion complex, are scattered on the basal side of the epithelial cells. Fine fibrils radiate from the hemidesmosomes into the basement membrane to join them together.

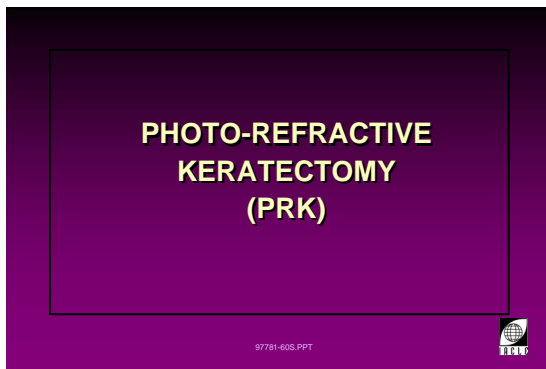


- Keratocytes may be activated and abnormal type III collagen deposition has been reported. These can contribute to a sub-epithelial haze and a mild scarring observable beneath the ablated area.
- Night glare (possibly caused by the issues detailed in the previous point).
- Corneal perforation.
- Some dystrophic conditions may recur.

Re-epithelialization usually takes less than 1 week although some cases take up to 3 or 4 weeks to complete the process.

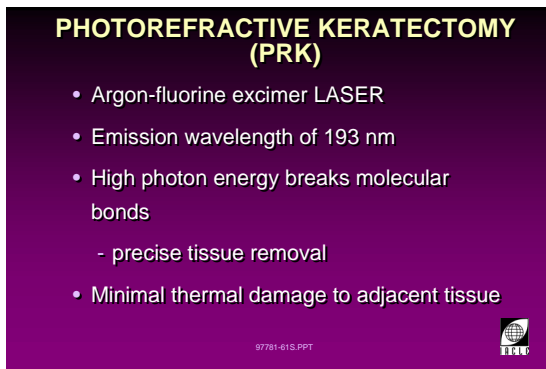
## VII Photo-Refractive Keratectomy (PRK)

91



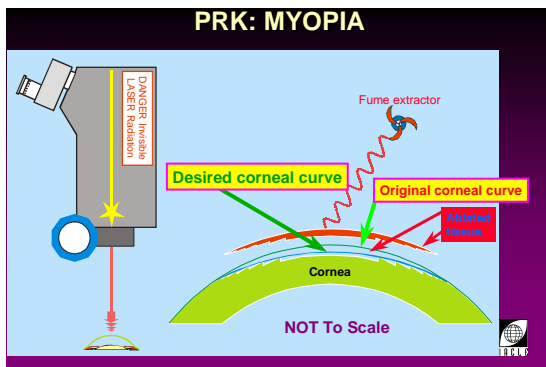
8L697781-60

92



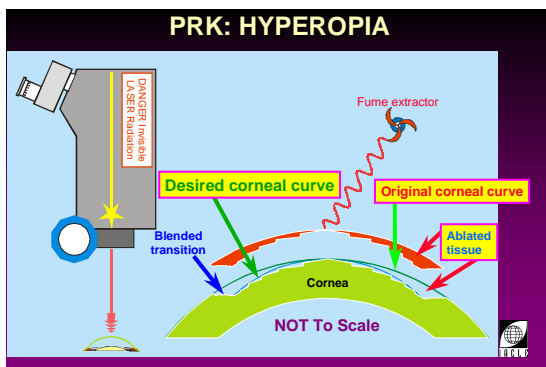
8L697781-61

93



8L697781-182

94



8L697781-183

### Photo-Refractive Keratectomy (PRK)

UV light is strongly absorbed by most biomaterials including the human cornea and, by altering the power and duration of the output pulses of UV-emitting LASERs, corneal tissue can be removed very precisely.

Once reasonable safety, reproducibility, and reliability had been demonstrated on animal eyes, the use of LASERs on human eyes for the purposes of effecting a refractive error correction was inevitable. PRK is that use and the first human application was described by Trokel *et al.* in 1983.

Since then, a significant number of improvements in the delivery of LASER energy to the eye have resulted in a viable technique for altering the anterior corneal contour and, thus, the ocular refractive error.

The first step in the refractive surgical technique of PRK is the removal of the corneal epithelium under topical anaesthesia, usually by the use of a blunt spatula. Should this prove difficult, a sharp instrument may be required (Thompson *et al.*, 1993). This is followed by an excimer LASER (see under PTK in the previous section of this lecture) ablation through Bowman's layer and deeper into the anterior stroma (slides 93 and 94). Therefore, PRK destroys Bowman's layer within the treatment zone.


The major disadvantage of the excimer LASER for refractive surgery is the expense involved in purchasing, maintaining, and calibrating the device. For these reasons, solid-state LASERs have been investigated and/or are under development and these are expected to reduce the costs of operating a LASER refractive surgery suite.

All LASER-based surgical devices require an integral fume-extraction system if uncontrolled and random attenuation of the incident LASER light by drifting translucent 'fumes' (sublimated corneal tissue) is to be avoided. A lack of extraction leads to unpredictable surgical outcomes and reduced precision.

95

**BROAD-BEAM EXCIMER LASER  
ADVANTAGES**

- Higher energy level
- Fast ablation speed
- Accurate ablations
- Easily calibrated



8L1697781-126

**Photo-Refractive Keratectomy: Broad-Beam Excimer LASER Technology**

Broad-beam LASERs have a limited maximum ablation diameter and have a greater tendency to produce an uneven refractive power across the ablation zone. This is referred to as the formation of 'central islands' that are sometimes observed on corneal topographical maps.


Early versions of broad-beam LASERs produced relatively small ablation diameters approximately 4.5 mm in diameter. Later versions produced larger optic zone sizes of up to 6.5 mm diameter.

Other concepts trialled include the erodable mask, a plastic disc made of polymeric material having identical absorption and ablation rates as the human cornea. By setting the size (diameter) and thickness profile of the mask, and using broad-beam LASER light, the profile of the corneal ablation can be controlled to create the desired corneal profile. The mask is 'sacrificed' in much the same way as the corneal tissue to be ablated is, at a matching rate.

96

**BROAD-BEAM EXCIMER LASER  
DISADVANTAGES**

- Ridges (steps) in the ablation zone
- Risk of tissue hyperplasia
- Limited treatment range




8L697781-127

97

**SCANNING EXCIMER LASER  
ADVANTAGES**

- Smooth ablation zone
- Accurate ablations
- Computer programmable
- Capable of custom ablations
  - topographical model
  - wavefront model
  - irregular corneas
  - reduced aberrations



8L697781-128

**Photo-Refractive Keratectomy: Scanning Excimer Laser Technology**


Scanning-beam and flying spot LASER technologies significantly reduce the amount of energy applied to the cornea. The LASER is applied to the cornea in the form of a small spot rather than a broad beam.

It is possible to use two spot sizes that may be interchanged by the LASER's control system. A larger diameter beam (2 mm) may be used for most of the treatment and then a smaller diameter beam (1 mm) is utilized to refine and smooth the corneal surface. This combines the benefits of fast treatment and optimal corneal smoothness.

98

**SCANNING EXCIMER LASER  
DISADVANTAGES**

- Slow ablation speed
  - tissue hydration control required
- Difficult to calibrate
- Risk of computer error
- Durability



8L697781-129

The slower ablation speed and possibility of corneal tissue dehydration is a potential disadvantage of the small-beam scanning excimer LASERs. Corneal dehydration during the ablation may result in poor and unpredictable control of the refractive correction.

99

**PRK: PATIENT SELECTION**

- Rx within the range of the procedure/equipment
- Rx stable for at least the last 12 months
- No:
  - irregular astigmatism
  - blepharitis or other external eye disease
  - uncontrolled connective tissue disorder
  - autoimmune disease
  - keratoconus/corneal thinning
  - oedema
- At least 18 years old
- Have realistic expectations of the outcome
- At least 3 months since any previous PRK
- CL wearers, discontinue until Rx & corneal topography stable (visits at least 1 week apart)

from: Am Acad of Ophthalmol., 2002



8L697781-208

**Patient Selection**

Because of extensive advertising, media interest, and word-of-mouth referrals, there is a large element of self-selection in PRK. It is largely up to the surgical suite/team to filter out those who are unsuitable for PRK, especially those with unsuitable corneas, e.g. the thin, the irregular, or those harbouring a *forme fruste* form of keratoconus.

100

**PHOTOREFRACTIVE KERATECTOMY  
WOUND HEALING**

- Deposition of new material
  - glycosaminoglycans
  - mucopolysaccharides
  - disorganized collagen
- Epithelial hyperplasia
- Anterior stromal scarring/haze

97781-62S.PPT



8L697781-62

**Photo-Refractive Keratectomy: Corneal Wound Healing**

Following debridement of the epithelium, Bowman's layer is removed completely in the zone of ablation. Complete epithelial regrowth occurs over a 3-day period after PRK, during which the patient usually experiences considerable ocular pain. Pain management strategies are required in all cases of PRK.

A stromal reticular scar develops in the zone of ablation in most PRK patients. The density of scarring peaks over the 1 to 3 month post-operative period and then gradually diminishes. The unpredictable nature of the wound healing response affects both the stability and predictability of the outcome of the PRK procedure.

Prophylactic antibiotics are prescribed after the procedure. Steroids may be used to hasten the recovery but they do not reduce the degree of residual scarring in the stroma.

101

**PHOTOREFRACTIVE KERATECTOMY  
VISUAL PROGNOSIS**

- Initial overcorrection of myopia
- Regression to a stable endpoint
- Some loss of BCVA in 10-15% of cases
- Continued regression in some cases
  - re-operate ('enhancement')?
  - contact lens correction?

97781-63S.PPT



8L697781-63

**Photo-Refractive Keratectomy: Vision Outcome**

Results of a large prospective study of PRK by McGhee (Craig, 2001) concluded that the procedure was very successful up to -5.00 DS with 72% of cases achieving at least 6/6 unaided. The predictability of the correction decreased as the level of myopia increased. Between 3 and 4% of eyes lost two lines of BCVA because of severe haze formation following the PRK procedure.


Further improvements in the visual outcome can be expected as the hardware and software improve, and the discipline's collective knowledge expands.

102

**PRK COMPLICATIONS**

- Persistent epithelial defect
- Dry eye
- Topographical changes
  - central islands
- Decentred ablation zone
- Over or under correction
- Rapid regression

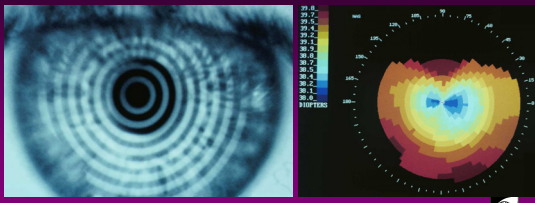
97781-137S.PPT




8L697781-137

103

**CORNEAL TOPOGRAPHY AFTER PRK**



97781-220S.PPT




8L697781-220 DCP

104

**PRK COMPLICATIONS**

- Persistent stromal scarring
  - early or late onset
- Optical degradation
  - loss of BCVA
  - haloes, contrast sensitivity
- Decreased corneal sensitivity
- Risk of infection
- Steroid complications

97781-142S.PPT



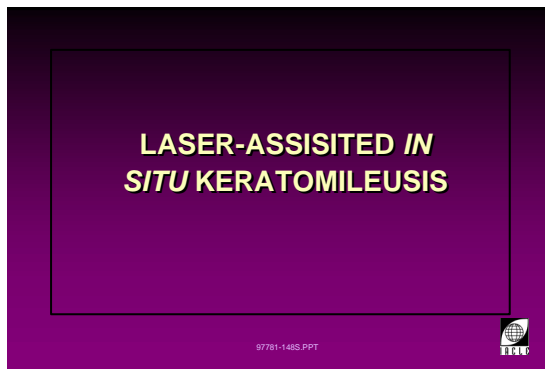8L697781-142

**Complications Following Photo-Refractive Keratectomy**

- Persistent epithelial defects are rare. Those that do occur may be associated with previous corneal trauma. Treatment generally involves the use of a soft bandage contact lens, topical lubricants, and prophylactic antibiotics
- Dry eye sensations are common following PRK. Frequent use of an artificial tear supplement is required.
- Abnormal corneal topography (slide 103)
  - central corneal islands occur in many cases.
- Ablation decentration is due to misalignment of the LASER beam. Residual refractive error and irregular astigmatism may require contact lens correction.
- Persistent stromal scarring is more common with higher refractive errors and may result in a reduction in the BCVA. Larger and smoother ablation zones of later generation excimer LASERs reduce the degree of scarring.

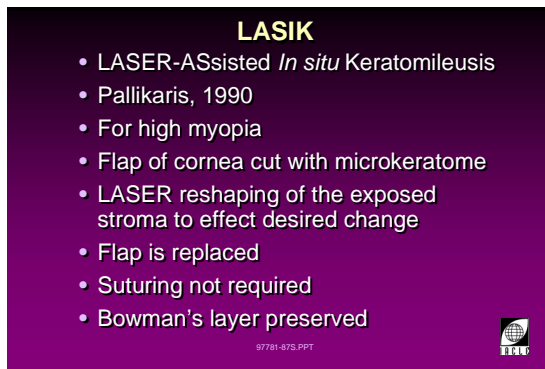
## VIII LASER-ASSISTED *In Situ* Keratomileusis (LASIK)

105



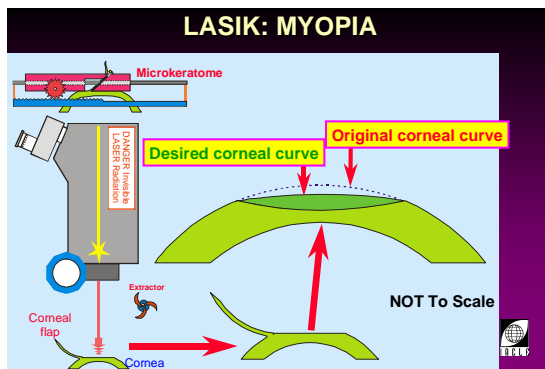
8L697781-148

106



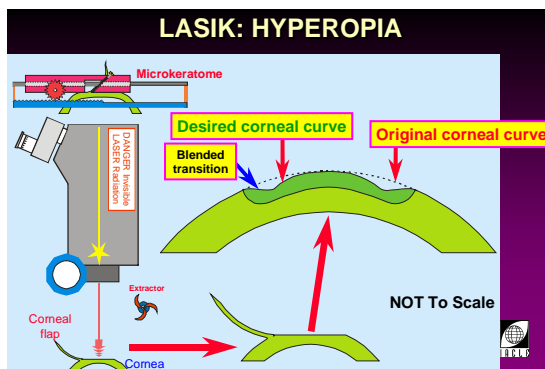
8L697781-87

107



8L697781-184

108



8L697781-185

### Laser-ASSISTED *In Situ* Keratomileusis (LASIK)

Pallikaris *et al.* (1990) provided the first extensive histopathological description of the technique called LASIK. In 1995, the FDA approved the use of the excimer LASER for myopia treatment using LASIK.

The technique involves first placing a suction ring around the limbus, centred over the pupil. The IOP is then raised to around 80 mmHg using this ring. A corneal flap with either a nasal or superior hinge is produced by a microkeratome and the exposed stromal bed is ablated with an excimer LASER to achieve the desired refractive change.

The plate used on the microkeratome determines the corneal flap thickness. Normally it is within the range of 140-160  $\mu\text{m}$ . After the flap is retracted and with the patient viewing a fixation target coaxial with the LASER beam, the exposed stroma is ablated to a pre-programmed depth and diameter. After the ablation is complete, the flap is returned to its original position and left to settle in position without the need for sutures (slides 107 and 108).

The depth of the stromal ablation determines the degree of refractive error correction. A minimum of 250  $\mu\text{m}$  of stromal bed should remain following the ablation. For any given correction, decreasing the ablation zone size will decrease the required ablation depth (analogous to contact lens diameter and sagittal depth). However, a significant risk of post-operative glare is associated with small ablation zone diameters.

For a safe thickness of 250  $\mu\text{m}$  of cornea to remain after ablation, the magnitude of any possible visual correction is often dictated by the thickness of the patient's cornea pre-operatively.

The essential advantage of the LASIK technique is that it maintains the integrity of the anterior corneal layers, i.e. the epithelium, basal lamina, and Bowman's layer. Unlike PRK, the procedure stimulates the development of relatively little new collagen material with epithelial hyperplasia occurring only at the flap margins.



109

**LASIK**

- Flap about 0.15 mm thick formed
- Heals better and faster than alternative procedures
- Sub-epithelial nerve plexus regenerates
- Relatively stable

97781-89S.PPT



8L697781-89

110

**LASIK TREATMENT RANGE**

- Sphere: – 12.00 to + 6.00D
- Myopic astigmatism: – 5.00D
- Hyperopic astigmatism: + 5.00D

97781-133S.PPT



8L697781-133

111

**LASIK**

- Evolved to cater for low myopia as well
- Relatively predictable
- Some regression occurs
- Subepithelial haze at 1-2 months
- Perforation is possible with some microkeratomes

97781-88S.PPT




8L697781-88

112

**LASIK: PATIENT SELECTION**  
after: Am. Acad. of Ophthalmol., 2002

- Rx within the range of the procedure/equipment
- Rx stable for at least the last 12 months
- At least 18 years old
- Normal ocular health
- Pupil size <6 mm (in normal light)
- Have realistic expectations of the outcome
- CL wearers, discontinue until Rx & corneal topography stable (visits at least 1 week apart)

97781-209S.PPT



8L697781-209

**Patient Selection**

Suitable and unsuitable LASIK patients are detailed in the slides opposite. It is noteworthy that the list of contraindications is substantial and can now be expected to grow more slowly as the technique matures. Additions are likely to be less common conditions that experience shows can lead to problems.

113

**LASIK: CONTRAINDICATIONS**

- Keratoconus/corneal thinning
- Corneal oedema
- Corneal dystrophies
- Irregular astigmatism
- Blepharitis or other external eye disease
  - esp. iritis and scleritis
- Uncontrolled connective tissue disorders
  - rheumatoid arthritis
- Autoimmune diseases
  - lupus
- Implanted pacemaker
- Diabetes
- Pregnant or breast feeding



8L697781-211

114

**LASIK: CONTRAINDICATIONS**

- History of herpes affecting the eyes
- Eyelash or eyelid anomalies
- Previous eye trauma or inflammation
- Cataract
- Glaucoma
- Large pupil size
- CL-induced corneal warpage or CL exhaustion syndrome
- Users of :
  - Accutane (for acne)
  - Cordarone (for cardiac arrhythmia)
  - Imitrex (for migraine)



8L697781-210

115

**LASIK  
ADVANTAGES**

- High level of comfort
- Immediate visual results
- Reduced patient visits
- Epithelium and Bowman's layer remain intact
- Minimal stromal haze
- Lower rate of regression
- Retreatment is safe and effective



8L697781-134

**LASIK Advantages**

The major advantage of LASIK is the faster rate of healing following surgery and improved reliability over other refractive surgery techniques. Fast healing is also associated with rapid visual recovery.

Compared with PRK, in which Bowman's layer is destroyed, LASIK preserves tissue. This factor reduces the likelihood of epithelial defects and thus minimizes the risk of corneal infection.

On comparing the level of corneal scarring associated with PRK and LASIK, the latter has a substantially reduced amount and the need for steroid therapy is also reduced.

The extreme pain associated with PRK is also absent in the LASIK procedure and this factor makes the technique more appealing to many potential refractive surgery candidates.

116

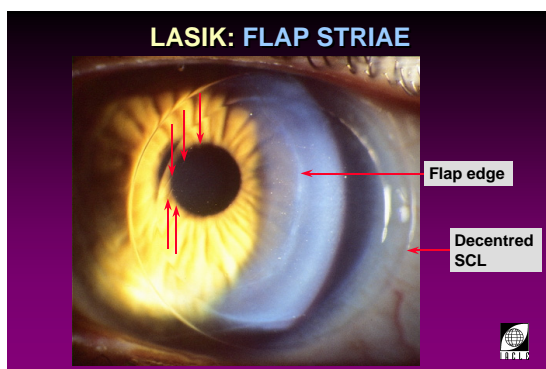
**LASIK COMPLICATIONS**

- Poor microkeratome cut
  - surgeon's (in)experience
  - loss of suction
  - too deep → perforation
- Flap complication
  - no hinge formed (detached flap)
  - too thin
  - too thick
  - wrinkling



8L697781-131

117



8L697781-241 FROM THE LATE R SALAZAR

118

**LASIK COMPLICATIONS**

- Epithelial in-growth
- Deposits in the flap
- Decentred ablation → monocular diplopia
- Photophobia
- Glare, haloes
- Dry eye
- Subconjunctival haemorrhages
- Ptosis
- Equipment problems during surgery



8L697781-140

119

**LASIK COMPLICATIONS**

- Refractive problems
  - over or under correction
  - induced irregular astigmatism
  - decentred ablation
  - regression
- Corneal ectasia
  - insufficient stromal bed thickness
- Corneal inflammation / infection
- Flap striae
- Diffuse lamellar keratitis



8L697781-132

### LASIK Complications

Problems associated with LASIK may be due to:

- Surgeon inexperience.
- Variable wound healing response.
- New LASER technology and algorithms.

The majority of complications associated with LASIK occur during the procedure. Microkeratome-related complications resulting in flap irregularities include:

- Incomplete flap creation.
- Flap striae (slide 117).
- Free cap formation (failure to halt the microkeratome's travel while a hinge still existed).
- Button-hole flap in which the flap is doughnut-shaped with a central portion still attached to the cornea.
- Decentred or irregular flap thickness.

Obtaining an optimal flap is crucial for the success of a LASIK procedure. It is, therefore, vital that the microkeratome is maintained in optimum condition. The keratome should be assembled carefully and a new blade used for each refractive surgery case.

Insufficiently high IOP causes many problems associated with the microkeratome function. Poor coupling of the suction ring to the globe is a common cause of inadequate IOP and may be due to:

- Sudden patient movement or severe blepharospasm.
- Conjunctival chemosis.
- Small corneal diameter.
- Deep-set eyes.

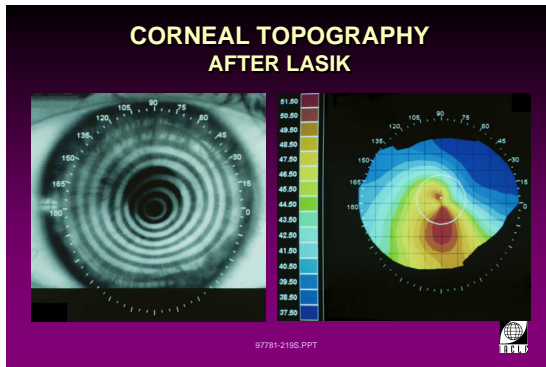
An important factor during LASIK is the maintenance of a dry stromal bed. The accumulation of fluid will affect the excimer LASER performance (e.g. tissue absorption may vary). Further, it is important that the surgical duration be as short as possible to prevent any significant change in corneal hydration that would otherwise affect the degree of refractive change or predictability thereof.

A small percentage of patients undergoing LASIK will experience a reduction in their BCVA (slides 120 and 121). Other visual problems include:

- reduction in night vision.
- ghost images.
- haloes.

A generally accepted view is that a corneal thickness of 250 µm must remain undisturbed beneath the flap and zone of ablation to minimize the risk of a corneal ectasia.

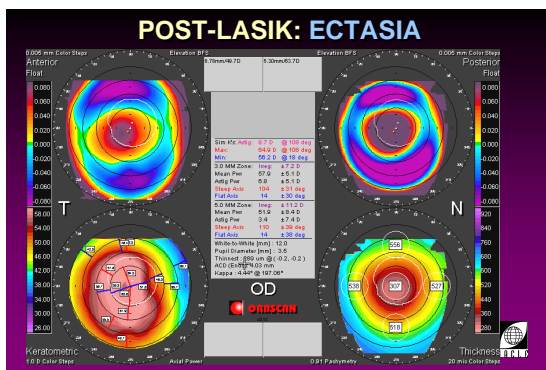
120



8L697781-219 DCP

Ocular dryness is common after LASIK and can occur in cases where there was no previous dry eye problem reported. A likely cause of post-LASIK dry eye is the severing by the microkeratome of sensory nerve fibres serving the lacrimation system. Regeneration of these fibres can take many months during which time the eye may experience a sensation of dryness necessitating some form of dry eye treatment.

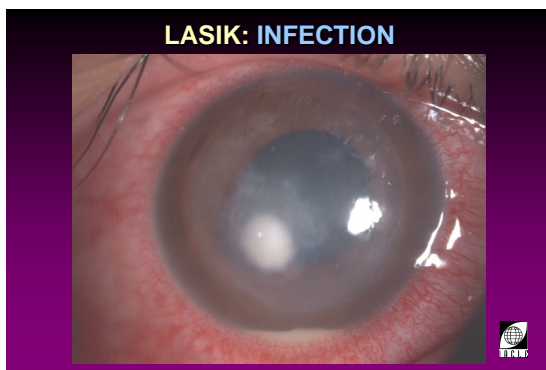121



8L697781-238 LVPEI

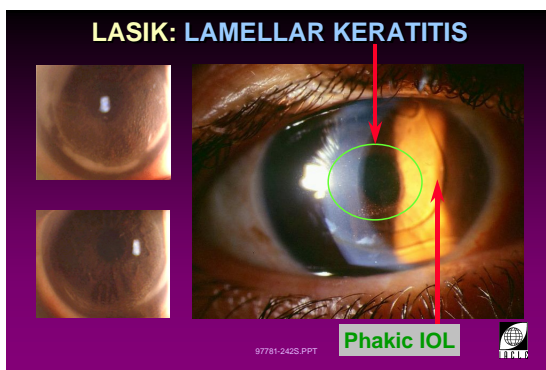
Corneal inflammation or infection (slide 122) is a potential complication following LASIK.

122



8L697781-237 LVPEI

123



8L697781-242 L IMAGES LVPEI, R THE LATE R SALAZAR, VENEZUELA

A diffuse, non-infective lamellar keratitis (also known as the 'Sands of the Sahara') (slide 123, a spherical, myopic, phakic IOL was used to correct the myopia, LASIK was used to correct the residual astigmatism) may occur as a reaction to debris from the surgical procedure. It occurs at the level of the flap interface, i.e. intracorneal, and results in reduced vision requiring the use of intensive topical steroids.

Probably the most common adverse outcome is eye irritation.

Recently, Sekundo *et al.* (2005) reported that a majority of LASIK patients reported no benefit from using bandage contact lenses after their surgery.

124

### LASIK RETREATMENT

- Stable Rx for at least three months
- Regular, smooth corneal topography
- Adequate corneal thickness
- Flap lift
  - recutting is not usually required
- Standard post-op medication
- Regression can occur



97781-135S.PPT

8L697781-135

### LASIK Retreatment

With LASIK, it is possible to re-operate sometime later simply by dissecting and lifting the flap and performing a second ablation. This is euphemistically referred to as an 'enhancement' by many exponents of LASIK.

Care must be taken with any LASER retreatment procedure to ensure that sufficient thickness of the stromal bed remains. Insufficient stromal bed thickness may result in corneal ectasia and reduced and/or irregular vision.

125

### CUSTOMIZED LASIK

- Wave-front guided technique
  - correct higher order aberrations
    - spherical, coma
  - optimize optic zone size
  - maintain natural asphericity of the cornea
    - prolate ellipse
  - aim is to generate a smooth wave-front, free of aberrations



97781-153S.PPT

8L697781-153

### Wave-Front Guided Customized LASIK

The human eye is subject to aberrations that limit ultimate visual resolution. The theoretical limit to visual resolution is the spatial distribution of photoreceptors on the retina. When the pupil diameter is less than 2 mm, resolution is entirely a function of diffraction. At larger pupil sizes, aberrations such as spherical aberration and coma become significant in limiting VA.

Wave-front technology is used to assess the degree of ocular aberrations present and their likely effect on reducing visual quality.

126

### CUSTOMIZED LASIK

- Integrated system combining a corneal topographer, aberrometer, and scanning LASER
- Corrects aberrations of the eye to improve:
  - Snellen acuity
  - contrast sensitivity
  - night vision



97781-152S.PPT

8L697781-152

In theory, controlling or neutralizing aberrations during refractive surgery will give better quality vision. Customizing the refractive surgery treatment based on measurements of the existing ocular aberrations can result in a more favourable corneal shape for aberration control thereby improving vision. The long-term stability of the eye's aberrations with or without surgical intervention remains unclear.

The ideal system is one that integrates the use of measurement of corneal topography and ocular aberrations with a custom-scanning LASER ablation. Customized wave-front guided treatment is only possible with small spot scanning LASER technology.

127

### CUSTOMIZED LASIK REQUIREMENTS

- Eye-tracking device
- Small spot scanning LASER
- Two LASER spot sizes
  - 1 and 2 mm
  - combines fast treatment time and optimal corneal surface shape
- Even distribution of LASER energy across the spot diameter



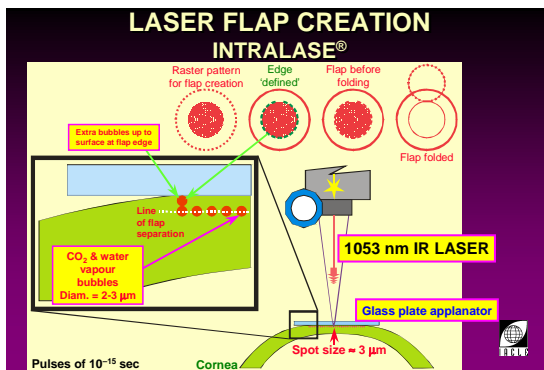
97781-154S.PPT

8L697781-154

It is likely that wave-front guided treatments would need to be applied in real-time or using PRK rather than LASIK because of the aberrations that a LASIK procedure causes. The latter is probably the result of severing the stroma's collagen fibrils when cutting the flap with the microkeratome. The structural integrity of the cornea is altered adversely by such action.



128



8L697781-212

### LASER Flap Creation (INTRALASE®)

The INTRALASE® device is an infrared femtosecond (energy burst of  $10^{-15}$  second duration) LASER used to produce more controlled LASIK flaps, i.e. a non-contact replacement for the microkeratome blade.

The brief infrared light ( $\lambda=1053$  nm) pulses separate tissue by photodisruption, a process in which the focused LASER pulses (spot size= $3 \mu\text{m}$ ) 'divide' material at the molecular level with little or no heating or other effects on the surrounding tissue (slide 128).

The eye is held by a negative-pressure ring (low-pressure 'suction' ring) and LASER energy is delivered through a precision glass plate used to applanate the cornea. The standard deviation of flap thickness is  $12 \mu\text{m}$  (Daya, 2005).

The steps include:

- The flap is created from inside the cornea.
- The LASER is focused to a point *within* the stroma (similar to optical sectioning with a confocal microscope, see Module 9, Lecture 9.1: Section **VIII Confocal Microscopes**). Each pulse of energy creates small ( $2$  to  $3 \mu\text{m}$ ) cavitation bubbles of carbon dioxide and water vapour. These divide the tissue at the desired level. Under computer control, the beam is played over the dimensions of the prospective flap in a linear raster pattern.
- Numerous (thousands) of these bubbles are positioned precisely to define the flap's dimensions as well as the location of the hinge.
- Finally, to complete the flap, bubbles are created around/along the edge of the flap up to the corneal surface.
- The procedure takes approximately 45 seconds in total.
- The flap is then lifted and a conventional LASIK procedure ensues.

Few epithelial defects are reported (Daya, 2005).

For further details, visit

<http://www.intralase.com/patient/laserflap/index.html>.

The instrument can also be used for intracorneal rings (e.g. **intacs**®) and lamellar keratoplasties.



## IX LASER-ASSISTED EPITHELIAL KERATECTOMY (LASEK)

129

### LASER-ASSISTED EPITHELIAL KERATECTOMY (LASEK)

- Modified version of PRK
- Epithelial flap is lifted following softening with alcohol
- LASER ablation is performed as in PRK
- Epithelial flap is replaced
- Results in:
  - less pain
  - quicker visual recovery

87781-1555.PPT



8L697781-155

130

### EPI-LASIK

- Disposable, oscillating, PMMA block (unsharpened edge) used to separate a hinged sheet of epithelium from Bowman's layer
  - separation occurs below the basement membrane but above Bowman's layer
- No alcohol is used
- Maintains:
  - integrity of the epithelium
  - structural integrity of the stroma
- Subsequently, procedure is the same as LASIK
- Reduced haze, striae, and subepithelial debris are reported

87781-2145.PPT



8L697781-214

### Laser-ASSISTED EPITHELIAL KERATECTOMY (LASEK) and Epi-LASIK

LASEK (a.k.a. ASLA [Advanced Surface LASER Ablation]) is a modified version of PRK and involves the preservation of the epithelium by lifting it as an intact flap following the use of 18 to 20% alcohol for less than 25 to 30 seconds to soften the tissue. The epithelial flap is rolled back and the LASER ablation performed. After photo-ablation through Bowman's layer, a procedure similar to PRK, the epithelial flap is replaced. In essence, this is a form of epithelial keratectomy.

However, epithelial flaps separated after alcohol 'softening' exhibit altered basal epithelial cells, enlargement of the intercellular spaces, and extensive discontinuities of the basement membrane. Separation occurs between the basement membrane's lamina lucida and the lamina densa (Guttman, 2004).

A hydrogel contact lens can be used as a bandage for up to 4 days to assist corneal healing and to decrease the level of ocular discomfort/pain the patient experiences.

LASEK is claimed to minimize comfort, hasten visual recovery, and reduce the incidence of corneal haze.

After-care of LASEK is largely the same as for LASIK. However, some LASEK patients may experience a delay in achieving good vision and photophobia may also be reported. A sub-epithelial haze can persist for several months but is not usually permanent.

### Epi-LASIK

A variation of this technique known as Epi-LASIK was developed by Pallikaris (Greece) and employs an unsharpened plastic edge (a disposable PMMA block) that oscillates at high speed as it sweeps across the cornea (the Centurion SES EpiEdge epikeratome) to separate a hinged sheet of epithelium from Bowman's layer, i.e. a flap of epithelium is involved rather than the more usual LASIK flap that includes some of the anterior stroma. The separation occurs beneath the basement membrane but above Bowman's layer and epithelial integrity is usually maintained, as is the structural integrity of the stroma (Guttman, 2004). No alcohol is used in Epi-LASIK.

The epikeratome is claimed to produce a precise, reproducible delamination of the epithelium, more precise than current microkeratomes it replaces.

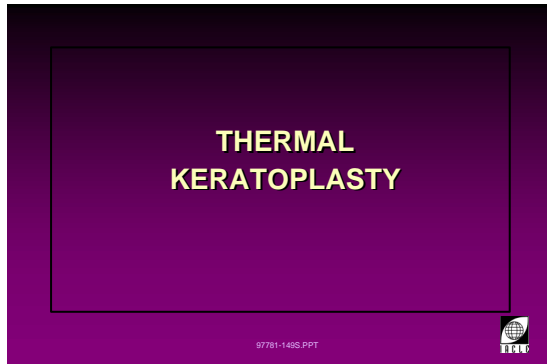
Epi-LASIK is claimed to be suitable for some refractive surgery candidates deemed unsuitable previously because of the thinness of their corneas.

The risk of haze, striae and sub-epithelial debris is reportedly minimal.

## X Thermal Keratoplasties (TKs)

### X.A Thermal Keratoplasty (TK)

131



8L697781-149

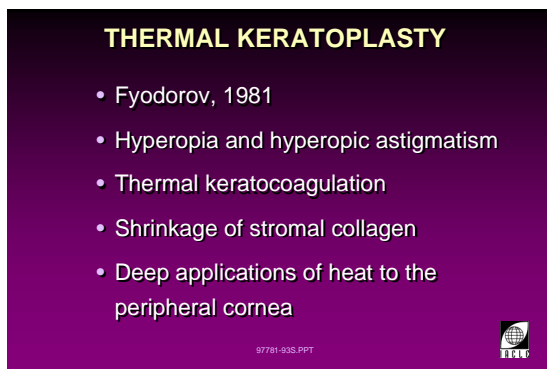
#### Thermal Keratoplasty (TK)

With the intention of inducing corneal curvature changes, several attempts have been made to shrink corneal collagen by the application of heat. One such technique devised by Fyodorov of Russia is radial TK. Lack of predictability and a high incidence of regression have accompanied this technique.

In radial TK, a wire probe that penetrates to about 90% of the corneal thickness and produces a temperature of about 600°C is used as a local heat source. Although this localized heat dissipates rapidly, the central region of the coagulation zone is subject to temperatures that cause a relaxation effect and, possibly, tissue necrosis adjacent to the probe. These effects can limit the amount of collagen shrinkage occurring in the outer region of the coagulation zone, thereby limiting the effectiveness of radial TK.

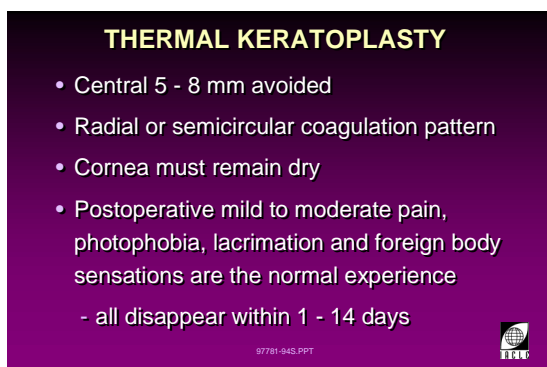
Regression of the refractive effect following the procedure is unpredictable and is a major limitation of the technique.

132



8L697781-93

133



8L697781-94

### X.B Photo-Thermal Keratoplasty

#### Photo-Thermal Keratoplasty

An alternative method of collagen shrinkage involves the use of either a holmium: YAG LASER or an excimer LASER. Like the UV excimer LASER, the infrared radiation from the solid-state, YAG LASER is capable of heating and thus shrinking corneal collagen. The pulse-length is about 200 µsec and the emitted wavelength is 2100 nm (UV excimer LASERS have a wavelength is 193 nm).

The penetration depth (about 400 µm) is comparable to the corneal thickness, which maximizes consistently deep coagulation effects.

134

**PHOTO-THERMAL KERATOPLASTY**

- P-TK is similar to TK but the technique of heating is different
- LASER beam is 210 nm IR
  - Holmium
- 8 - spot annular pattern of localized heating
- 8 - spot pattern repeated to form a radial pattern on cornea



8L697781-91

Long-term refractive change is achieved and the results remain stable if at least 80% of the corneal thickness is treated.

If applied in a circular pattern, the LASER treatment can correct hyperopia. If placed in the appropriate axis of astigmatism, it can steepen the flatter meridian of the astigmatism.

The coagulations are performed in a ring with a diameter between 6.5 mm and 9.0 mm. Less than 2 seconds of exposure is required to treat each spot. Once the procedure is completed, tissue debris is rinsed away using a sterile saline irrigation solution. Post-operative pain is managed with appropriate medication and prophylactic antibiotics are applied.

Advantages of this techniques include:

- It is minimally invasive.
- Visual axis is left untouched.
- No removal of corneal tissue.
- Treatment is rapid.
- Retreatment ('enhancement') is possible.

Regression can occur following PTK and is more noticeable in younger patients. Over-heating the stromal collagen may induce relaxation of the fibrils and result in a subsequent regression of the initial refractive effect. Generally, the regression is less than that associated with PRK or LASIK.

Other complications may include:

- Folds developing in Descemet's membrane.
- Superficial vascularization near the coagulation spot if it is too peripheral.
- Haloes if the treatment zone is too close to the visual axis.
- Plaque-like appearance at the site of the coagulation.

135

**PHOTO-THERMAL KERATOPLASTY**

- 8 - 32 spots used
- 0.15 - 0.6 mm spot size
- 3 mm clear 'optic' zone
- Up to 6D of hyperopia correction is possible



8L697781-92

**X.C Conductive Keratoplasty (CK)**

136

**CONDUCTIVE KERATOPLASTY**

- Utilizes corneal conductive properties
- Induces permanent collagen shrinkage
  - column of denatured stroma
- Hyperopia
- Astigmatism
- Quick procedure
- Some regression is likely

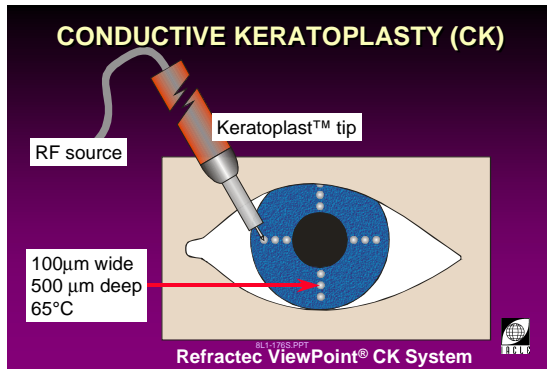


8L697781-136

**Conductive Keratoplasty (CK)**

One of the latest methods for the treatment of hyperopia is conductive or radio-frequency keratoplasty (Refractec Inc.). In essence, this technique (FDA approved Feb., 2004) is a variation on TK. In this procedure, heat is applied at discrete points on the cornea using a radio-frequency-heated fine probe whose pattern is similar to that of RK (slide 137). The heat is employed to alter stromal collagen in a way that leads to shrinkage post-operatively. Currently, the technique is marketed for the 'temporary improvement to near vision' (presbyopia) or 'spherical hyperopia between +0.75 D and +3.00 D or presbyopic patients who would benefit from a spherical treatment of between 1.00 D and 2.25 D to achieve a myopic endpoint of between -1.00 D and -2.00 D in their non-dominant eye to temporarily improve near vision'. (Note: this is not suggesting that myopia *per se* is an indication for the use of CK). Some regression is expected, hence

137



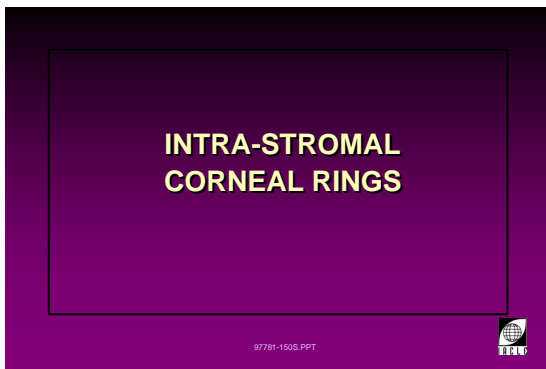
8L697781-187

the use of 'improvement' in the indications for the procedure.

A potential advantage of this technique is that it causes less damage to the cornea than TK or PTK, albeit with shorter-term expectations.

## XI Intrastromal Corneal Rings (ICR)

138



8L697781-150

### Intrastromal Corneal Rings: Introduction

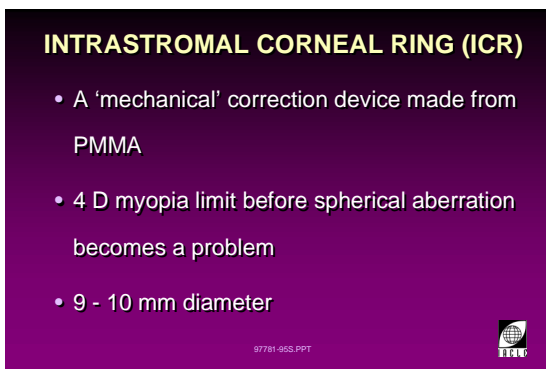
Barraquer (1949) was the first to discuss the possibility of using synthetic intracorneal implants for the correction of refractive error.

A more promising variant approved currently by the FDA for myopes between  $-1.00$  D and  $-3.00$  D with no more than  $1.00$  D of astigmatism, is the Intrastromal Corneal Ring Segment or **intacs**<sup>®</sup> device (by Addition Technology Inc., previously by KeraVision Inc) (slide 141). FDA approval has also been received for the use of **intacs**<sup>®</sup> devices in keratoconus (July, 2004).

Another intrastromal device is the Ferrara Ring implant for treatment of keratoconus. To cater for the level of correction required, five thicknesses of ring are available (Cimberle, 2005).

Sighted human eyes were first implanted with the rigid PMMA intrastromal corneal rings in 1991.

139



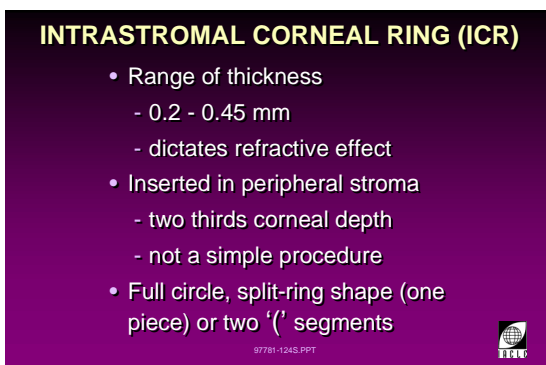8L697781-95

### Intrastromal Corneal Rings: What Are They and How Are They Used?

The degree of refractive error correction is determined by the thickness of the **intacs**<sup>®</sup> inserts. The rings are available in five sizes: 0.25, 0.275, 0.30, 0.325, and 0.35 mm. The thicker the **intacs**<sup>®</sup> inserts are, the greater the correction achievable.

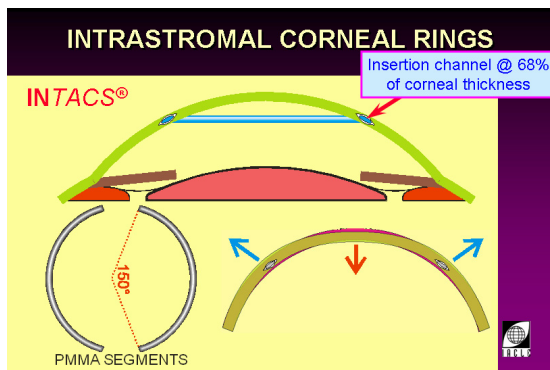
The two arcs of PMMA each subtend  $150^\circ$  (see slide 141).

140



8L697781-124

141



8L697781-179

### Intrastromal Corneal Rings: Mechanism of Correction

The lamellar structure of the corneal stroma allows for dissection of an intrastromal annular channel and implantation of the full ring or ring segments. The device flattens the central cornea by displacing (expanding) the mid-peripheral corneal collagen around the ring, thus shortening the central arc length and reducing the corneal sag height. Increasing the thickness of the ring results in a greater flattening effect and, therefore, a greater refractive correction (for myopes).

Inherent in their original mode of action is the ability to flatten the cornea rendering them only suitable for myopia. To be effective in hyperopia, the rings or segments will need to constrict the corneal 'skirt' uniformly to effect a steepening of the central cornea.

Hyperopic applications are currently in early clinical trials in Europe, as are trials to address astigmatism. An astigmatic correction will probably require either rings/segments whose thickness varies circumferentially in an appropriate way, a non-circular insertion channel and rings/segments of uniform thickness, or a combination of both approaches. Astigmatism greater than 1.00 D is being targeted. For current information visit: [www.getintacs.com/us/physicians/addtopractice.htm](http://www.getintacs.com/us/physicians/addtopractice.htm).

142

**INTRASTROMAL CORNEAL RINGS**  
**intacs® INDICATIONS**

- Reduction or elimination of mild myopia (−1.00 to −3.00 dioptres spherical equivalent at the spectacle plane)
- 21 years of age or older
- Documented stability of refraction ( $\Delta \leq 0.50$  D over the previous 12 months)
- Astigmatism of  $\leq 1.00$  D

97781-215S.PPT

8L697781-215

### Intrastromal Corneal Rings: Indications and Limitations

intacs® inserts are approved for patients who have -1.00 D to -3.00 D of myopic error with 1.00 D or less of astigmatism (current manufacturer's data suggests -1.00 D to -3.00 D spherical equivalent at the spectacle plane).

The patient should:

- be 21 years of age or older.
- have documented stability of refraction as demonstrated by a change of less than or equal to 0.50 D for at least 12 months prior to the pre-operative examination.
- have an astigmatic component of 1.00 D or less.

One limiting factor is the shape taken up by the cornea after insertion of intrastromal rings. Above about 4 D of change, the vision quality is decreased by the aberrations of the sub-optimal topography of the altered anterior cornea. The limited range of ring thicknesses available reflects this limitation.

143

**INTRASTROMAL CORNEAL RINGS**  
**intacs® CONTRAINDICATIONS**

- Patients with collagen, vascular, autoimmune, or immunodeficiency disease
- Pregnancy or breastfeeding
- Keratoconus
- Recurrent corneal erosions
- Corneal dystrophy
- Users of:
  - isotretinoin (Accutane)
  - amiodarone (Cordarone)
  - sumatriptan (Imitrex)

97781-213S.PPT

8L697781-213



144

**INTRASTROMAL CORNEAL RING**

- Does not disturb the central optical zone surgically
- Maintains corneal asphericity
- Can be removed (not easily)
- Does not correct astigmatism
- Minor complications



8L697781-130

**Intrastromal Corneal Rings: Advantages**

Some advantages of this general technique include:

- Preservation of the central cornea and elimination of the adverse effects of post-surgical corneal haze and surface irregularities.
- It is largely independent of the corneal wound healing response as it does not require incisions into the corneal tissue (other than one small entry point at the 12 o'clock position), or the removal or supply of corneal tissue to achieve a change in refraction.
- It maintains the cornea's prolate ellipsoidal shape thereby minimizing spherical aberration.
- Minimal loss of contrast sensitivity or induction of glare or haloes.
- The polymeric, biocompatible material (PMMA) can be removed if necessary and/or replaced with a different thickness implant should a different refractive target be desired.

The implantation technique was made simpler by the development of two arcuate segments instead of a complete 360° device. An advantage of this design was that the ring segments could be positioned away from the point of corneal incision (a non-gaping wound?) thus minimizing the risk of incision-related complications.

Further improvements are now feasible with the advent of the INTRALASE® device that makes no-touch channel creation possible.

145

**INTRASTROMAL CORNEAL RING**

- Peripheral corneal haze possible, usually resolves
- Lamellar channel deposits common
- Deep stromal vascularization common
- Corneal pannus also common



8L697781-96

**Intrastromal Corneal Rings: Complications**

Slit-lamp observations following intrastromal ring implantation include:

- Haze along or near the insertion channel.
- Deposits on the lamellae in the channel.
- Development of corneal iron lines.

Complications observed include:

- Stromal defects in the region of the incision.
- Delayed healing of the incision.
- Minor vascularization near the incision site.
- Induced astigmatism.
- Transient reduction in corneal sensitivity.

## XII Clear Lens Extraction (CLE)

146

### CLEAR LENS EXTRACTION

- Crystalline lens is removed to reduce high degrees of refractive error
  - with or without implantation of an IOL
- Creates a near problem in young patients
  - multifocal implants
- Uncommon
- Risk of retinal detachment

97781-985.PPT



8L697781-98

### Clear Lens Extraction

As early as 1857, clear crystalline lens extraction was proposed as a means of improving unaided vision in highly myopic eyes. The removal of a clear lens in a young patient is a means of correcting high myopia without the need, in some cases, of an IOL was originated by Fukala (Vincenz Fukala, Austrian ophthalmologist, 1847–1911 – Fukala's operation).

Correction of hyperopia following a clear lens extraction requires the implantation of an IOL (see next). Either way, the procedure results in a complete loss of accommodation and an increased risk of complications associated with cataract surgery such as retinal detachment.

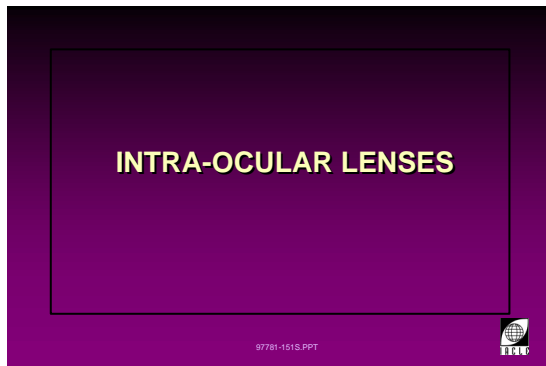
Combined procedures are also possible where residual refractive error following clear lens extraction can be corrected with, for example, LASIK.

When correcting hyperopia by clear lens extraction and IOL implantation, a very high plus-powered IOL is required. In some extreme cases, the power required may be beyond the range of powers manufactured or stocked and rather than order a custom lens, two stock IOLs may be placed in tandem (piggyback) in the vacated lens capsule to provide the power required. Difficulties can arise where the IOLs touch each other and debris can accumulate between them. Further, the optical calculations for two thick lenses 'in the bag' (lens capsule) are not straightforward.

## XIII Intraocular Lenses (IOLs)

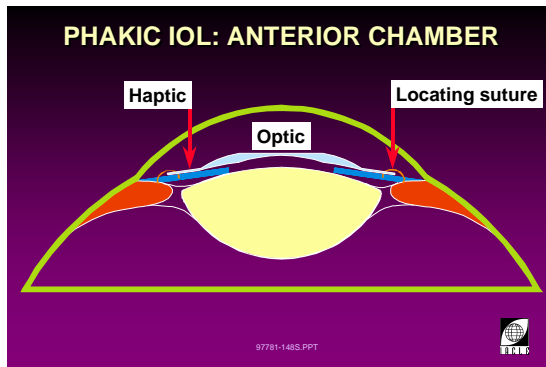
### XIII.A Anterior Chamber IOLs

147



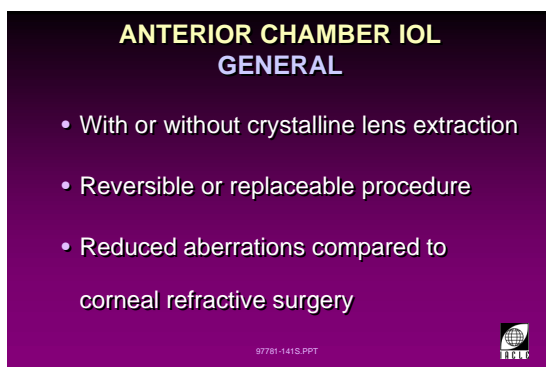
8L697781-151

148



8L697781-180

149



8L697781-141

#### Phakic IOLs: Anterior Chamber

Not long after the invention of the IOL (by Sir Harold Ridley of the UK who implanted the first lens in 1950 (see Spalton, 1999) for the correction of aphakia, ophthalmologists began inserting concave lenses in anterior chambers to correct myopia in phakic patients (Strampelli, 1953).

The modern AC IOL is produced with thin and flexible haptics (the locating fingers that hold the IOL in the eye and maintain the IOL's optics on the visual axis) and smooth surfaces, and is much more successful than the early designs although little difference conceptually. Two types of anterior chamber lenses are available, iris-supported or iris fixated (e.g. the Verisyse lens, slide 148) and angle-supported IOLs. The other type of phakic IOL is located in the posterior chamber (e.g. the Implantable Contact Lens [ICL]) just behind the iris and it is detailed in the next section.

Phakic IOL procedures are sometimes referred to as Refractive Lens Exchanges.

#### Advantages of Phakic IOLs Over-Refractive Surgery

- Cornea remains substantially unaltered and its topography remains largely the same.
- Crystalline lens remains unaltered (e.g. no secondary cataract, no other capsule anomalies, fewer IOL location and retention problems).
- Reversible, i.e. IOL can be removed and/or replaced.
- Vision quality can be superior because of the optical degrees of freedom possible with IOLs.
- A wider variety and range of spherical refractive errors (+5 D to -10 D) can be corrected along with significant manifest astigmatism.
- Small incision procedures mean less pain/discomfort, little eye disturbance, and a prompt return to 'normal' vision.
- May be suited to those rejected for LASER refractive surgery for whatever reason (e.g. error too high, cornea too thin or too irregular, corneal disease or dystrophy, chronic dry eye).
- Predictability of refractive error correction is high.
- No regression of error correction.
- Outpatient procedure taking 20 to 30 minutes.
- **Contraindications**
- Large pupils (>7 mm). Large pupils reduce the security of lens retention.
- Shallow anterior chamber depths (<3.2 mm). Phakic IOLs must clear the crystalline lens posteriorly and the corneal endothelium

anteriorly. Touch of any description is unacceptable and has serious ramifications for tissue integrity. Many high aphakes cannot be implanted because, either they have a shallow anterior chamber, or the IOL required is too thick centrally, or both factors apply.

- Older patients with no significant accommodation remaining but early signs of cataractous lens changes are probably better served by aphakic IOL implantation.

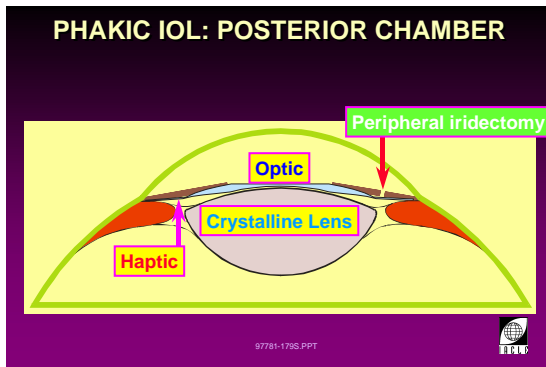
**Complications**

Implanting an anterior chamber IOL has the potential to change the structure of the anterior chamber angle and to damage the corneal endothelial cell layer. Complications associated with this technique include:

- Progressive endothelial cell loss.
- Low-grade anterior chamber flare and low-grade anterior uveitis have been associated with iris-fixed IOLs.
- Oval pupil.
- Ocular infection.
- Localized areas of capsular opacification due to contact between IOL and lens capsule have been reported.
- Elevated IOP.

**XIII.B Posterior Chamber IOLs**

150



8L697781-181

**Phakic IOLs: Posterior Chamber**

A recent addition to the extensive list of refractive surgery techniques is an implantation procedure in which a correcting lens is inserted immediately anterior to, but not in contact with, the normal crystalline lens. As it is fitted behind the iris, it is considered a posterior chamber lens (slide 150).

Developments in the field of cataract surgery such as more accurate calculation of the required power of the IOL, smaller (very small) incision size, and the advent of foldable lenses have made it possible to use IOLs for refractive correction and not just the preferred solution to cataract removal (see below). The main difference between phakic and aphakic procedures is the need for extra care of the crystalline lens and its fragile anterior capsule.


An optimal lens for posterior chamber implantation should have the following characteristics:

- Biocompatibility with the eye.
- High refractive index.
- Thin profile.
- Optimal size and shape.
- Designed to:
  - vault the crystalline lens.
  - permit circulation of the aqueous humor.

151

**PHAKIC IOLs**

- A posterior chamber IOL fitted in front of the crystalline lens to correct ametropia
- Astigmatic correction possible
- Plus and minus powers available
- Probably better suited to higher errors
- Sometimes referred to as the implantable contact lens (ICL)




8L697781-99

152

**PHAKIC IOLs**

- 3 - 15 D hyperopia correctable, optic diameter 4 - 5 mm
- 8 - 18 D of myopia correctable, optic diameter 4.5 to 4.8mm
- Suitable ages: 20 years or older

97781-100S.PPT



8L697781-100

- prevent rubbing on the iris surface or lens capsule.

An example is the Staar Surgical posterior chamber lens made of a porcine collagen-HEMA copolymer (collagen content is low) also described as an implantable contact lens. A folded (rolled-up) lens is inserted through a small, clear corneal incision and allowed to unfold in the anterior chamber prior to placement in front of the crystalline lens. Two optic zone diameters (4.8 and 5.8 mm) are available and the choice is made depending on the power required. A wide range of powers in minus and plus is available.

**Advantages**

Advantages of using a posterior chamber IOL include:

- Central cornea is undisturbed.
- Corneal aspheric shape is maintained.
- Natural crystalline lens is left in place and functional thus preserving any remaining accommodation.
- Predictability of refractive error correction is high.
- Astigmatic correction is possible.
- Reversible procedure.
- No regression of refractive error correction.

**Complications**

Potential complications of posterior chamber IOL implantation include:


- Cataract formation.
- Pigment dispersion.
- Pupil block if an iridectomy is not performed when it should have been.
- Glaucoma.
- Poor centration of the lens.

153

**PHAKIC IOLs**

- Injectable through small corneal incision (lens unfolds *in situ*)
  - similar to cataract surgery
- Need adequate anterior chamber depth and pupil size

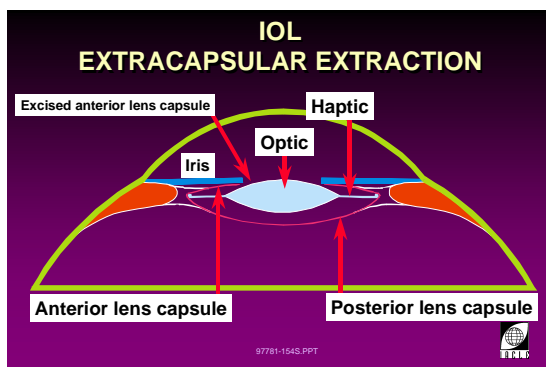
97781-125S.PPT



8L697781-125

**XIII.C Aphakic, Posterior Chamber IOLs**

154



8L697781-186

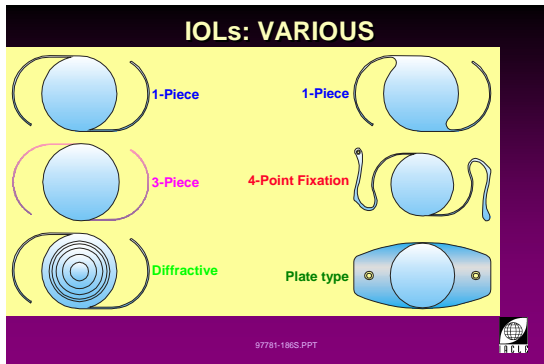
**ExtraCapsular Cataract Extraction (ECCE)**

This procedure is included here largely for completeness. Most commonly, aphakia is normally the surgical solution to the development of clinically significant cataract. Rarely is aphakia the result of a Clear Lens Extraction (see Section *XII Clear Lens Extraction*).

Logically, the accuracy of IOL power calculations are critical to the refractive success (see: [www.opthalmologytimes.com/opthalmologytimes/article/articleDetail.jsp?id=76779](http://www.opthalmologytimes.com/opthalmologytimes/article/articleDetail.jsp?id=76779)).

Generally, the preferred surgical option for dealing with cataract is an extracapsular extraction (lens capsule remains) rather than an intracapsular extraction (lens and its capsule removed completely). It allows IOL implantation (i.e. a posterior chamber IOL) and has a lower incidence of

155



8L697781-189

post-operative complications such as retinal detachment and cystoid macular oedema/degeneration. If necessary, an anterior chamber lens can be implanted.

The main complication of ECCE is the development of posterior capsule opacities (PCOs) and the decreased vision that results. Recently, hydrodissection (cleaving the lens cortex with a pressured, injected fluid – the fluid passes between the capsule and the lens cortex) combined with rotation of the cataractous lens within the capsule to confirm completeness of separation of the lens from the capsule have been shown to reduce the potential for PCOs. This is because the number of residual cells, particularly equatorial lens epithelial cells, is reduced by the technique (Vasavada *et al.*, 2005).

Fortunately, most PCO-caused vision problems can be resolved using a slit-lamp-mounted LASER (photo disruption of the opacity) and further entry into the anterior chamber is not required.

For descriptions of Large-Incision ECCE, IntraCapsular Cataract Extractions (ICCEs), and phacoemulsification see Kanski, 1999.

Various IOLs are presented in slide 155, not all are necessarily posterior chamber devices.

The complication rate is higher in intracapsular extractions, a reason for its decline in popularity. Complications include:

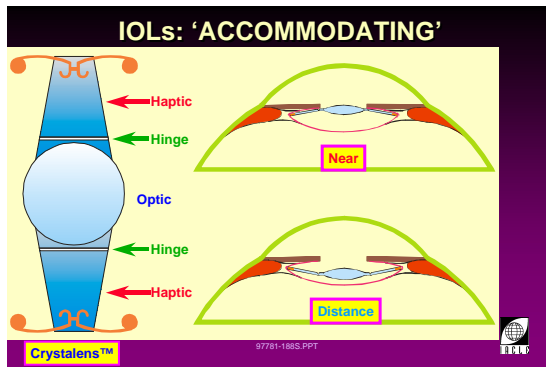
- Rupture of capsule during procedure.
- Vitreous loss.
- Retinal detachment.
- Cystoid macula oedema.
- Blood loss from incision or iris.
- Expulsive haemorrhage (an unusual complication, usually encountered in patients with glaucoma, hypertension, or diabetes, etc., or combinations of such conditions).

The advent of wave-front aberration determination has led to a newer generation of IOLs whose surfaces, particularly the anterior surface, have shapes designed to compensate for the negative spherical aberration of the cornea. These compensations are claimed to increase the overall functional vision (Lindstrom, 2005). If customized, in-house IOL production became a reality, there is every reason to believe that individually customized IOLs would become a routine possibility. These lenses would maximize the visual potential of each patient.



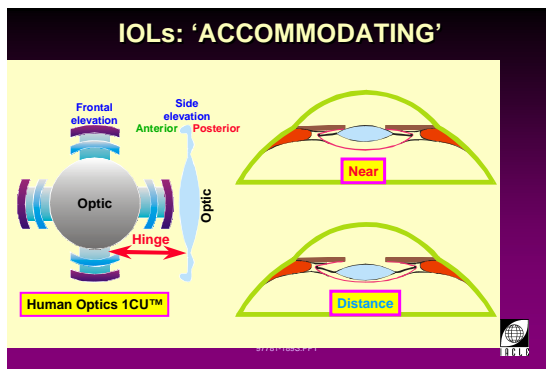
XIII.D Aphakic, Accommodating IOLs

156



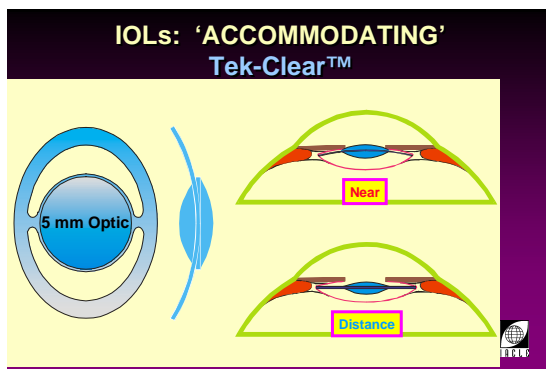
8L697781-190

157



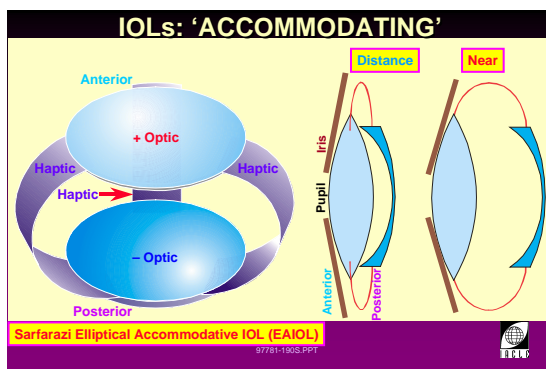
8L697781-191

158



8L697781-235

159



8L697781-193

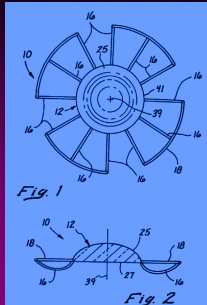
**Aphakic, Accommodating IOLs**

Regardless of the patient's age, whatever their amplitude of accommodation was before cataract surgery/clear lens extraction, it is absolutely zero after surgery. This has resulted in much research aimed at 'restoring accommodation'. The solutions to a lack of accommodation (not all of which are available or have even been used in human trials as yet) include:

- Bifocal and PALs.
  - all are simultaneous vision designs (no translation is possible).
- Relatively simple and subtle hinged IOLs, e.g. the Crystalens, the 1CU, or Tek-Clear devices that are 'in the bag' designs that move forward when the ciliary muscle contracts (slides 156, 157, 158).
- Complex dual element designs, e.g. the Hara dual-lens design, VisioGen's Synchrony one-piece dual optic lens (improved recently, visit: [www.osnsupersite.com/default.asp?ID=11315](http://www.osnsupersite.com/default.asp?ID=11315)), and the Sarfarazi EAIOL (slide 159). While these are conceptually similar designs, they differ in detail, e.g. the Synchrony is a one-piece design. While all dual-element designs rely on ciliary muscle-mediated changes in element separation to provide their 'accommodation', the lens system as a whole also probably moves during accommodation because significant backward movement is prevented by the vitreous gel body. This means that regardless of relative movements within the IOL, a forward movement of the lens system will be the ultimate result.
- Varifocal, e.g. the Lang patent (slide 160). A deformable variation of the hinged designs in which the position and the curvature of the lens changes during 'accommodation'. This design is not yet available.
- Extremely complex, e.g. the Skottun patent (slide 161). This is a compound lens design containing sliding mechanical components. No lenses of this type have been implanted in humans yet.
- Diffractive bifocal lenses, e.g. the AMO Array, Alcon's AcrySof ReSTOR, CeeOn 811E (now from AMO following their acquisition of Pfizer's surgical ophthalmological business), CIBA Vision's Vivarte phakic lens, IOLTech's MF4, TECNIS' ZM001, and Vision Membrane Technologies' VISION MEMBRANE (a combination refractive and diffractive device).

160


**IOLs: 'ACCOMMODATING' (Complex)**



**Lang (2001)**

- US Pat 6,231,603
- deforming IOL
- power change from deforming (altering) convexity

97781-195S.PPT

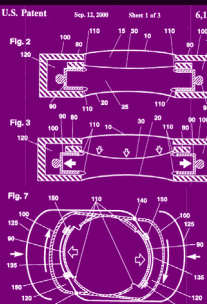


8L697781-195

Controversy surrounds the amplitude of accommodation these lenses can provide. Evidence suggests that the single lens, hinged designs can only deliver about 1 D per mm of lens movement. This means that the effect provided is limited to less than 2 D, with 1 D being a more likely outcome. Dual-element lenses offer greater amplitudes at about 1.5 to 4 D (Ho, 2004).

161


**IOLs: 'ACCOMMODATING' (Complex)**



**Skottun (1999)**

- US Patent
- encapsulated, accommodating IOL
- levering haptic
- compound lens
- compound refractive indices
- extremely complex

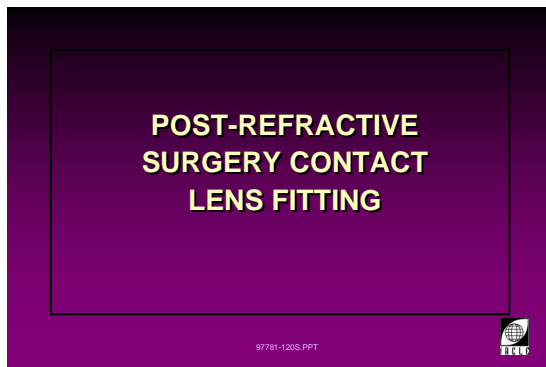97781-194S.PPT



8L697781-194

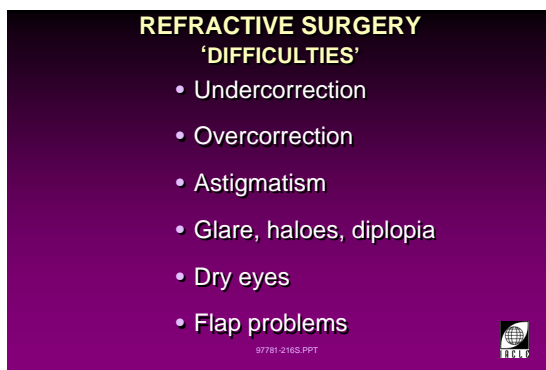
## XIV Post-Refractive Surgery Contact Lens Fitting

162



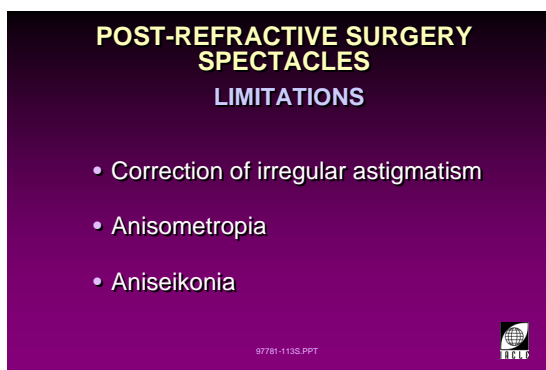
8L697781-120

163



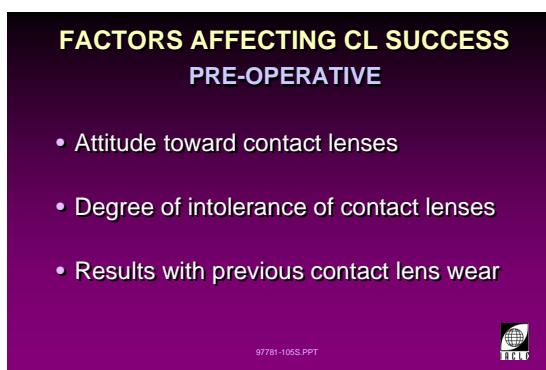
8L697781-216

164



8L698771-113

165



8L698771-105

### Post-Refractive Surgery Contact Lens Fitting

Contact lens fitting for post-refractive surgery patients is likely to become more common as the number of people undergoing surgical procedures to correct ametropia increases. Further, the development of new refractive surgery techniques could also result in some unexpected/unpredictable visual outcomes for which contact lenses may be the only satisfactory form of correction.

In many cases of high refractive error, modern techniques of refractive surgery are incapable of correcting the ametropia fully. However, post-surgical regression of the manifest refractive error can occur and contact lenses may be required to obtain optimum vision.

Fitting post-surgical patients with contact lenses can present a unique challenge because, in many techniques, the corneal integrity is breached and the cornea's topography is significantly different from normal.

Some of the difficulties that may arise as a result of refractive surgery include:

- **Under-corrections.** This results from too little tissue being removed from your eye and is more common in myopes. An enhancement may be required at some later stage.
- **Over-corrections.** It is also possible that the laser will remove too much tissue from your eye. Over-corrections may be more difficult to fix than under-corrections.
- **Astigmatism.** Astigmatism can be caused by uneven or irregular tissue removal. This can occur if the patient's eye moves excessively during surgery. Additional surgery may be required.
- **Glare, haloes, and double vision (diplopia).** These may make vision at night more difficult, especially where bright lights abound. In some cases, these symptoms may respond to cortisone eyedrops. Sometimes further surgery may be required.

- **Dry eyes.** Eyes may feel dry for up to the first 6 months after surgery. More severe cases may require punctal plugs.

- **Flap problems.** LASIK flaps are subject to infection, tearing and swelling. Flaps removed during PRK may regenerate abnormally.


Although spectacles are a viable alternative form of vision correction in some cases, limitations apply to this form of correction (slide 164).

Some factors that can affect the outcome of fitting contact lenses appear in slides 165 and 166.

166

**FACTORS AFFECTING CL SUCCESS  
POST-OPERATIVE**

- Amount of regression
- Lack of previous contact lens experience
- Change of contact lens modality
- Unilateral correction
- Onset of presbyopia
- Financial burden (additional expenses)
- Ptosis


9781-106S.PPT 

8L698771-106

167

**POST-REFRACTIVE SURGERY  
CONTACT LENS FITTING  
CONSIDERATIONS**

- Corneal wound healing
- Reduced corneal sensitivity
- Maintaining corneal health
- Oxygen supply to the cornea
- Need to satisfy basic fitting principles

9781-107S.PPT 

8L698771-107

### Considerations Prior to Contact Lens Fitting


Wherever possible, supply of oxygen to the post-refractive surgery cornea should be maximized by using contact lenses with high oxygen transmissibility. In most cases, conventional hydrogel lenses are not recommended due to their lower oxygen transmissibility compared with RGP or siloxane hydrogel lenses.

In many cases of post-refractive surgery contact lens use, it is difficult to achieve an optimum fitting due to the irregular nature of the altered cornea. Despite this, it is necessary in all cases to obtain the best possible fitting that meets the basic requirements for a soft or rigid lens fitting.

168

**POST-REFRACTIVE SURGERY  
CONTACT LENS FITTING  
SCL CONSIDERATIONS**

- Oxygen supply to the cornea
- Astigmatic correction
  - regular
  - irregular


9781-108S.PPT 

8L698771-108

169

**POST-REFRACTIVE SURGERY  
CONTACT LENS FITTING  
RGP CONSIDERATIONS**

- Central corneal shape
- Lens centration problems
- Lens back surface shape
  - spherical
  - aspheric
  - reverse geometry


9781-109S.PPT 

8L698771-109

170

**POST-REFRACTIVE SURGERY CONTACT LENS FITTING INDICATIONS**

- Residual refractive error
- Irregular astigmatism
- Anisometropia
- Night vision problems
- Therapeutic needs
  - bandage



8L698771-112

171

**LENS SELECTION**

- Rigid gas permeable
- Hydrogel
- Siloxane hydrogel
- Hybrid
- Scleral




8L697781-12

172

**POST-REFRACTIVE SURGERY SUGGESTED CONTACT LENS TYPES**

- RGPs (high Dk/t) when: *after Bufidis et al., 2005*
  - patient wore RGPs previously
  - postsurgical scarring present
  - corneal irregularities present
  - post-LASIK corneal ectasia
- SCLs in cases of:
  - postoperative myopia
  - postoperative regular astigmatism
- Scleral lenses (gas permeable) in cases of:
  - irregular corneas
  - sensitive corneas




8L697781-234

173

**FITTING PROBLEMS**

- Patient dissatisfaction
- Abnormal corneal topography
- Previous contact lens failure
- Instability of vision
- Reduced vision



8L697781-11

**Indications for Contact Lens Fitting**

In some post-refractive surgery cases, a contact lens fitting is required. Spectacles are generally unsatisfactory due to the significant optical problems, e.g. induced corneal irregularity or corneal astigmatism (slide 174), which can be associated with sub-optimal refractive surgery.

RGP lenses generally provide a better visual outcome than do SCLs, often because they provide a relatively inflexible, regular, artificial corneal front surface. RGP lens advantages include:

- Correction of irregular astigmatism and other optical problems (see Lecture 2.3 in Module 2 for the optics of such corrections).
- Vaulting of the central, flattened zone.
- More stable VA and improved visual function.

Typical vision problems associated with unsuccessful refractive surgery include:

- Blur.
- Multiple images.
- Glare.
- Haloes and ghost images.
- Haze.
- Reduced night vision.

Difficulty with vision at night can be a significant problem post-surgically. Night vision difficulties can have several causes including:

- Irregular astigmatism.
- Non-uniform corneal refractive indices.
- Decentration of the optical (ablation) zone.
- Pupil and optical zone size mismatch.
- Optical aberrations such as spherical aberration and coma.

Suggested lens types according to Bufidis *et al.* (2005) appear as slide 172.

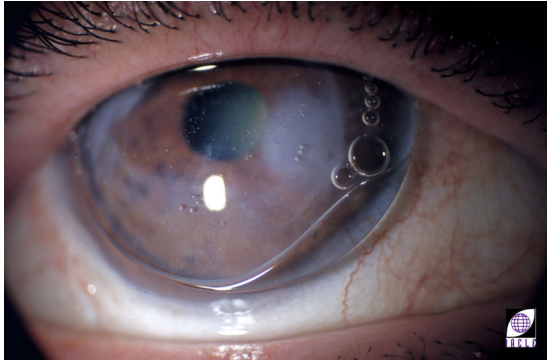
**Potential Contact Lens-Fitting Problems Following Refractive Surgery**

Although abnormal corneal topography is the major reason for fitting contact lenses following refractive surgery failure, the unusual corneal shape is also the main difficulty met when striving for a successful fitting (slide 174).

The types of topographical abnormalities that may present after refractive surgery include:

- Eccentric ablation creating a significant change in refractive power across the cornea located over the pupil.
- Central or paracentral islands.
- Inferior steepening.
- Irregular topography if the microkeratome causes a full-flap dislocation.

174

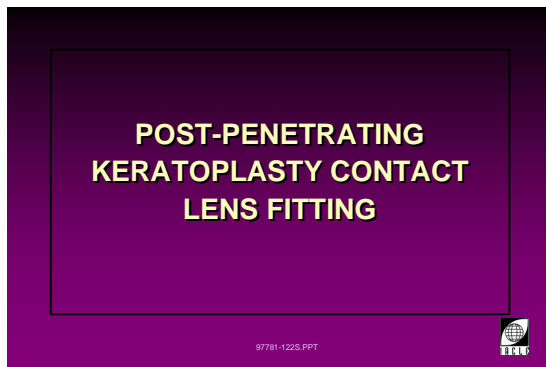

8L600IC



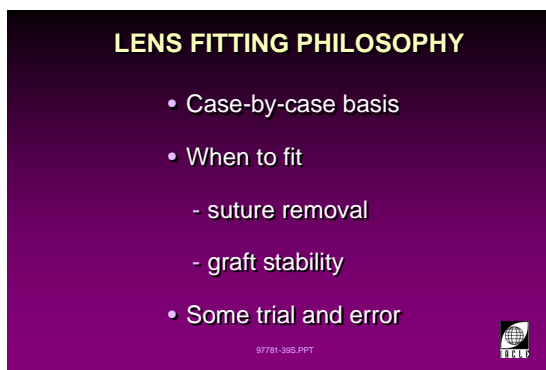
## XV Contact Lens Fitting Following Penetrating Keratoplasty

175



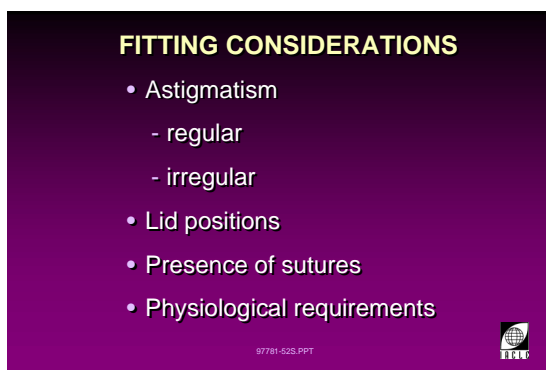
8L697781-122

176



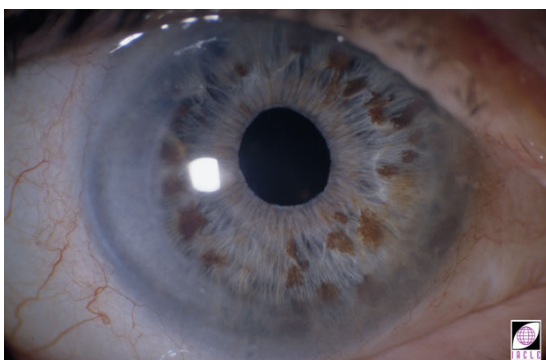8L697781-39

177



8L697781-52

178



8L60635-98

### Contact Lens Fitting Following Penetrating Keratoplasty

Indications for contact lens fitting after PK include:

- Anisometropia. Anisometropia is more likely to be induced when only one eye has been operated on and a similar refractive error or ocular condition remains in the unoperated eye.
- Regular and irregular astigmatism. Both types of astigmatism can result from pre-existing astigmatism of either type, or simply as a result of non-uniform or randomly uneven suture tensions around the full circle of the PK.

### Considerations for Contact Lenses After Penetrating Keratoplasty

Ideally, the likely need for contact lens fitting following PK should be discussed in some detail with the patient before they undergo the procedure. They also need to be made aware that it will take some time for the graft to settle and that changes to the contact lens fitting may be required during this settling period.

Any previous contact lens experience should be taken into account, especially if it was only marginally successful or was unsuccessful. The psychology of the patient is a key factor in lens fitting. A positive patient attitude is important if lens-wearing success is to be achieved.

Careful evaluation of the host and donor cornea must be made prior to any contact lens fitting. It is particularly important to note the presence of any blood vessels near the graft interface, the apparent health of the endothelium, and the type of graft (e.g. slide 178).

Contact lens fitting should be undertaken in consultation with the graft surgeon. It is important that the lenses are fitted after sufficient time is allowed for the eye to heal and for the graft to settle.

The graft sutures must be 'buried' in the cornea and any cut ends should not protrude in such a manner that they can abrade other parts of the anterior eye. A fluorescein examination should reveal no staining and good apposition of the graft and donor tissue.

*Contact lens fitting is generally contraindicated while the sutures are still in place.* If it is necessary to fit a lens before suture removal and after consulting with the attending surgeon, the contact lens practitioner must ensure that the eye is not inflamed and the graft is clear. Furthermore, such cases must be followed-up frequently to confirm the graft's ongoing satisfactory condition.

As corneal sensitivity may be reduced after surgery, prospective wearers should be advised to be especially vigilant about the physical circumstances of their eyes. They must be instructed to take special care not to touch them unnecessarily, nor to let foreign bodies touch or enter them while the feedback mechanism that normally protects them is

either depressed or absent. Care should also be taken to minimize the risk of epithelial breakdown that may occur if lenses are fitted before the cornea has had sufficient time to heal. Fitting too soon after surgery may contribute to graft rejection or other serious consequences. In most cases, the fitting of contact lenses can only be attempted some months after the eye surgery.

Commonly, an RGP contact lens is the lens of choice, especially if low to moderate corneal astigmatism is present. RGP lenses provide a smooth anterior refracting surface, albeit an artificial one, that provides a high level of VA in many cases.

179

### LENS FITTING OPTIONS

- Soft: spherical or toric
  - hydrogel
  - siloxane hydrogel
- RGP: spherical, aspherical, toric
- RGP: reverse geometry
- Hybrid lens
- Piggy-back
- Scleral

97781-38S.PPT



8L697781-38

### Contact Lens Selection for Penetrating Keratoplasty

A wide range of contact lens options should be considered when fitting a corneal graft. The most commonly used lenses are highly oxygen permeable RGPs. A number of key factors must be considered when choosing the lens most likely to provide the best combination of good vision and the maintenance of a healthy graft. These include:

- Supply the maximum amounts of oxygen possible to the cornea to minimize the risk of graft vascularization.
- Minimization or avoidance (not always possible) of heavy bearing on the graft-host interface.

A contact lens practitioner with specialist knowledge is best suited to fitting a post-graft eye. A key factor in such fittings is the availability of a wide range of trial RGP lenses in various designs.

To maintain the health of the graft, it is recommended that the contact lenses be used only on a DW basis. EW brings with it a heightened risk of complications as the cornea is already under greater stress following PK.

180

### LENS SELECTION

- Rigid gas permeable lenses are the modality of choice following penetrating keratoplasty
  - maximum correction of cylinder

97781-40S.PPT



8L697781-40

181

### RGP LENSES FOR PK

Optimizes:

- Oxygen supply
- Correction of astigmatism
- Level of visual acuity

97781-41S.PPT




8L697781-41

182

**RGP ADVANTAGES**

- Correction of irregular astigmatism
- Provide high oxygen transmissibility
- Custom designs available

97781-46S.PPT




8L697781-46

183

**PK LENS FITTING**

- Normal topography
  - traditional RGP lens designs
  - adequate static and dynamic fitting characteristics

97781-42S.PPT



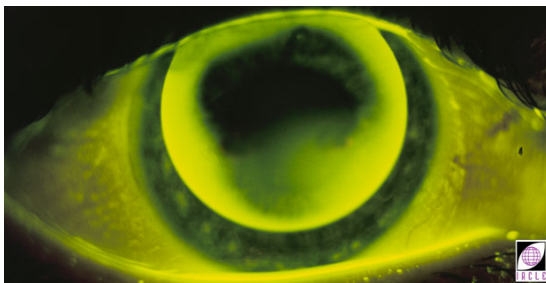
8L697781-42

**Contact Lens Selection for Normal Graft Topography**

A relatively normal corneal topography following PK is rare. In cases where the donor and host corneal tissue are well-aligned and topographical mapping indicates that regular astigmatism is present, the practitioner can consider the use of traditional RGP lens designs.

The success of such fittings is judged using standard assessment techniques utilizing both white light and fluorescein (slide 184 shows a degree of topographical abnormality).

184




8L60393-94

185

**PK LENS FITTING**

- Flat central topography
  - central vaulting
  - large diameter required (TD: 9.5 - 12.0 mm)
  - peripheral design must be optimized
  - fenestration if needed
  - reverse geometry designs

97781-43S.PPT



8L697781-43

**Contact Lens Selection for Flat Graft Topography**

A flat or sunken graft usually results from the graft and recipient bed being of the same size. An RGP lens will vault the area of the graft and may result in bubble formation if excessive pooling is present (the critical pool depth necessary for bubble formation remains unknown but estimates of between 75 and 250 µm have been given by various practitioners when the question was posed. The situation is probably more complicated than a simplistic 'depth' approach however). In such circumstances, a fenestration may be required to allow trapped air to escape from the post-lens tear film.

The lens bearing pressure on the peripheral cornea is a key factor in achieving a successful fit. Ideally, there should be adequate bearing along the horizontal corneal meridian to provide lens stability.


A reverse geometry RGP lens design should be considered when a traditional lens proves to be unsatisfactory.

186

**PK LENS FITTING**

- Proud graft
  - large lens diameter (TD)
    - 10.0 – 12.0 mm
  - large BOZD to clear the junction
    - typically 8.5 – 9.0mm

97781-44S.PPT



8L697781-44

### Contact Lens Selection for Proud Graft Topography

A difficult graft to fit with a contact lens is one that stands slightly proud of the host cornea. A proud graft is more likely following a PK for keratoconus. In such cases, the thickness of the host cornea at the margin of the trephination is less than the donor button from a normal cornea.

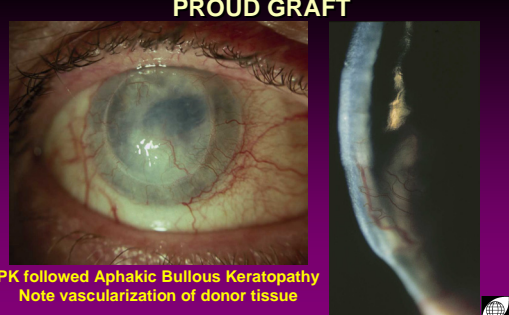
The raised step at the host-graft interface (slide 187) often causes an RGP lens of moderate TD to slide off the graft when displaced by the lid during a blink (slide 188). When this happens, a large diameter lens is usually required.

Large RGP lenses can cause some problems including:

- Handling difficulties.
- Lack of lens movement.
- Bubbles near the graft junction (excessive pooling under the lens in this region).


187

**PROUD GRAFT**



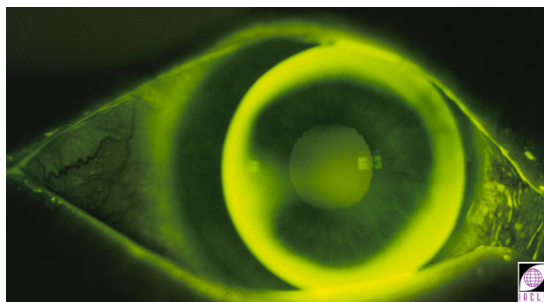
**PK followed Aphakic Bullous Keratopathy**  
Note vascularization of donor tissue

97781-226S.PPT



8L697781-226 DCP

188




8L61686-95

189

**PK LENS FITTING**

- Plateau-type graft
  - standard RGP design gives excessive edge lift
  - consider reverse geometry

97781-116S.PPT



8L697781-116

### Contact Lens Selection for Plateau Graft Topography


In many cases of RGP lens fitting after PK, the practitioner should consider the use of a reverse geometry (orthokeratology) design. This is particularly true for a plateau type graft where a spherical lens design would result in significant apical clearance and excessive edge clearance from the peripheral cornea.

190

**PK LENS FITTING**

- Tilted graft
  - difficult to fit with an RGP lens
  - high-riding fit may be successful
  - lens decentration is likely
  - consider custom soft lens (sphere/toric)

97781-45S.PPT



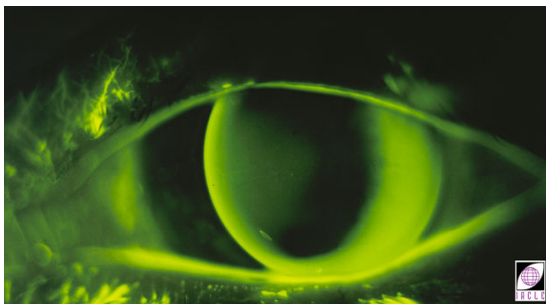
8L697781-45

**Contact Lens Selection for Tilted Graft Topography**

A graft that is tilted in relation to the host cornea provides a challenge to the contact lens practitioner. The tilt is usually due to variations in the host or graft margin thickness or to variations in the suture depth between graft and host (Phillips, 1990).

A large RGP lens is likely to cause a localized gutter over the recessed region of the graft (slide 191) and may produce a persistent bubble in this region.

191




8L60138-95

192

**TRIAL LENS SELECTION**

- Use simple designs for the first trial
- Try a flat BOZR (8.20 - 8.35 mm)
- Lens diameter about 9.60 – 10.0 mm
- Trial and error basis
- Consider aspheric and reverse geometry designs
- Expand trial lens sets with failed designs

97781-47S.PPT



8L697781-47

**Trial Lens Selection for Post-Penetrating Keratoplasty Fitting**

Trial lens fitting is essential for each post-PK case. Due to the irregular nature of the corneal topography, a trial RGP lens assessment of both the static and dynamic fitting characteristics is vital to the lens ordering process.


193

**FLUORESCEIN PATTERN ASSESSMENT**

Look for:

- Lens centration
- Topographic symmetry about the vertical and horizontal midlines
- Areas of bearing or clearance
- Excessive peripheral clearance
- Bubble formation

97781-48S.PPT



8L697781-48

**RGP Fitting Assessment Following Penetrating Keratoplasty**

The fluorescein pattern discloses regions of excessive clearance or bearing and forms the basis of lens choice and any subsequent changes in design aimed at achieving an acceptable lens fit.

Rarely is an optimal RGP lens fitting achieved on a post-PK cornea due to the induced irregular topography. To minimize the risk of epithelial cell damage, areas of lens bearing on the cornea must be prevented if possible. Unfortunately, some bearing may be unavoidable.

Factors that can contribute to greater lens-wearing success include:

- Use of high oxygen transmissibility RGP materials.
- Lens fenestrations.




194

**FITTING CHARACTERISTICS**  
**LID INFLUENCE**

- Position of the upper lid
- Lid tonus
- Effect on lens position

97781-51S.PPT



8L697781-51

- Flatter peripheral curves if large lens TDs are used.
- Tear supplements.


195

**FITTING CHARACTERISTICS**

Try to achieve:

- Stable fit
- Adequate centration
- Distribution of bearing pressures under the lens

97781-49S.PPT



8L697781-49

196

**FITTING CHARACTERISTICS**  
**ASTIGMATIC INFLUENCE**

- With-the-rule
- Against-the-rule
- Degree of astigmatism

97781-50S.PPT



8L697781-50

### Influence of Astigmatism on Lens Fitting Characteristics

A major factor influencing the quality of vision following PK is the degree of manifest and corneal astigmatism that results. It is relatively common for 10 to 15 D of astigmatism to be recorded in topographical measurements.

The suturing technique, skill, uniformity of suture tension, and the graft size can influence post-operative astigmatism. A large donor tissue graft (0.5 mm larger donor size is normal) placed into a small bed will result in steeper corneal graft topography (donor tissue steepens to reduce the 'skirt' diameter to match the trephine size used on the host). Irregular astigmatism can result if the graft is positioned eccentrically.

Current surgical techniques permit some control over the amount and axis of the astigmatism as the eye heals. Unfortunately, the result is not necessarily sustained once the sutures are removed and permanent or long-term suture placement is not an option.

In some respects, the axis of the resulting astigmatism is more important than the amount. WTR astigmatism is generally easier to fit with contact lenses than ATR or oblique astigmatism.

Abnormal graft shapes and topographies make contact lens fitting more difficult. The disparity between the back surface of the contact lens and the anterior cornea presents physical and optical challenges to fitting success.



In some cases of extreme astigmatism (>6 D), SCLs are reported to be more successful despite their thickness and relatively poor physiological performance. While RGP lenses can be fitted to highly astigmatic corneas, they require considerable skill, experience, and knowledge. Furthermore, highly astigmatic corneas are more likely to have an attendant irregular component that can make RGP lens fitting more difficult. This may also be the reason for SCL successes in these cases.


Often, a mini-scleral or scleral lens is found to be the most successful and easiest contact lens to fit over a graft. However, many practitioners do not have the skills, the experience, the motivation, or suitable trial lens sets to undertake the fitting of such lenses.

197

**SOFT CONTACT LENSES**

- Used when RGP lenses provide unsatisfactory comfort
- Intolerance of other lens types
- Sutures still in place
- Custom made toric designs
- Piggyback fitting

97781-53S.PPT



8L697781-53

**Hydrogel Lens use Following Penetrating Keratoplasty**

Under some circumstances, a hydrogel or silicone hydrogel lens may be appropriate. For example, if it is necessary to fit a contact lens while the sutures are still in place, a thin soft lens may be the best option as it will drape over the raised graft-host junction and not cause excessive rubbing or discomfort.

In typical cases with significant degrees of corneal astigmatism, the major disadvantage of soft lenses is the poor acuity obtained compared to that provided by RGP lenses. Custom-made toric SCLs may be an option in some cases.


198

**SOFT LENS FITTING**

Potential problems

- Uncorrected astigmatism
- Inadequate fitting
- Variable vision
- Poor oxygen transmissibility (except siloxane hydrogels for which custom designs are not available)

97781-54S.PPT



8L697781-54

A SCL slightly thicker than normal may provide a more stable fitting and better visual performance. However, the low oxygen transmissibility of conventional hydrogel contact lenses can result in corneal oedema and peripheral corneal vascularization. The growth of blood vessels into the graft can precipitate a rejection episode with the blood vessels acting as a conduit for the immunological system.

Siloxane hydrogels, by virtue of their relative rigidity (cf. conventional hydrogels) may provide the answer in some cases. However, their rigidity may also create some problems, e.g. elevated bearing pressures on proud corneal features.


Very careful follow-up is mandatory for any patient using soft lenses following PK.

199

**PIGGYBACK LENS FITTING**

- Soft lens acts as a foundation for an RGP lens
- Lenticulated plus power design
- High Dk RGP material
- Reduced oxygen supply
- consider a siloxane hydrogel

97781-55S.PPT



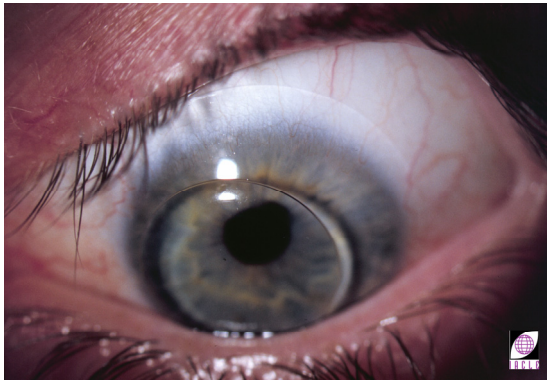
8L697781-55

**Piggyback Lens Fitting Following Penetrating Keratoplasty**

Use of a piggyback contact lens combination is generally an option of last resort. The major problem is the reduced oxygen transmissibility of the soft-RGP combination. The development of siloxane hydrogel lenses has provided the practitioner with a better material to use in these cases. Ideally, the RGP lens should also have a high oxygen transmissibility.

The SCL is used to provide a broad, more regular base on which to fit the RGP lens. This is most likely to be needed in cases such as proud or tilted grafts.

200

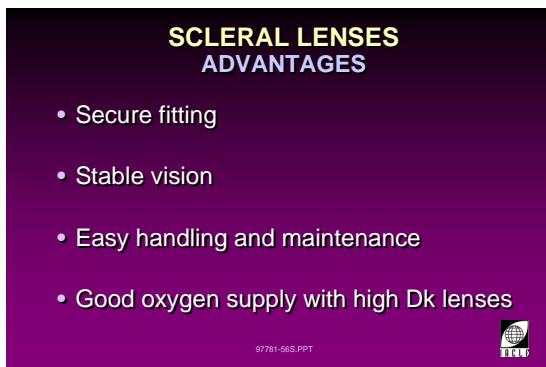


8L60463-02

If the soft lens achieves a desirable fitting characteristic, a standard RGP lens design can be placed on top of the soft lens and the overall fitting assessed (slide 200).

Maintaining lens centration and acceptable comfort is a major problem with the piggyback fitting technique. In the past, special recesses have been made in the front surface of the soft lens to receive and retain the RGP lens. This requires either custom lenses or modifications to standard soft lenses. Further, the recesses can harbour microorganisms, act as footholds for deposits, or be the weakest point of the lens making a lens fracture or tear more likely.

201




8L697917-56

### Scleral Lens Fitting Following Penetrating Keratoplasty

Although fitted by few contact lens practitioners, scleral lenses (slide 202) can play a major role in providing an optimal visual correction following PK. Their advantages include:

- Relatively easy handling characteristics compared with soft and small RGP lenses.
- Once on the eye they cannot be dislodged.
- Very stable on-eye fitting providing optimum centration (slide 203).
- Very good VA.
- Durability.
- Easy care and maintenance procedures.

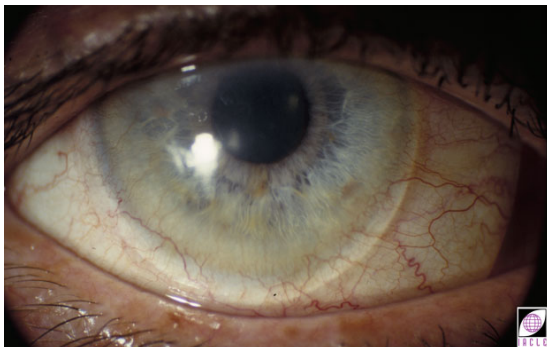
202



8L62079-95

Most modern scleral lenses are made from high oxygen permeability materials and cause minimal corneal hypoxia or oedema. Regardless of the foregoing, very careful follow-up of all PK patients is required if the risk of graft rejection is to be minimized.

203




8L6507-92

204

**HYBRID LENSES**

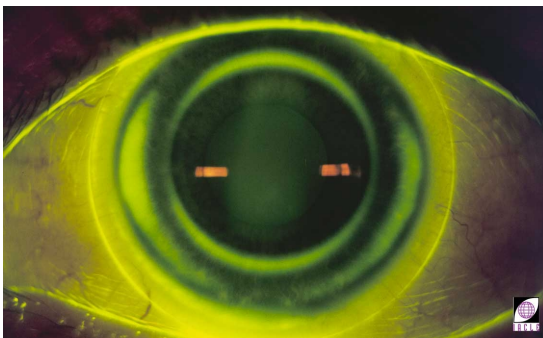
- Improved lens centration
- Stable vision
- Significant disadvantages
  - poor oxygen supply
  - limited parameters
  - relatively fragile
  - expensive

97781-57S.PPT



8L697781-57

205



8L61022-94

**Hybrid Lens Fitting Following Penetrating Keratoplasty**

The one-piece hybrid lens design with a hydrogel skirt and an RGP centre is a unique contact lens (slide 205). Potentially, it is an excellent lens design for the post-PK cornea as the hydrogel periphery promotes good lens centration and the RGP provides optimum VA.

The major disadvantage of such a lens is the relatively poor oxygen transmissibility of both the hydrogel and RGP zones.

Further, the relatively poor durability of the transition zone between the soft skirt and the rigid optic can lead to a concentric split occurring at the transition. While this occurrence is more likely during lens handling, a sudden decrease in wearer comfort may indicate that it has happened *in vitro*.


Lack of lens movement with such lenses can also cause problems for the wearer due to the limited removal of eye debris and/or tear film contaminants from behind the lens.

206

**PATIENT EDUCATION ISSUES**

- First-time wearer frustrations
  - application and removal
  - care and maintenance
  - requires patience
- Potential complications
  - reduced vision, discomfort
  - need for frequent after-care

97781-58S.PPT



8L697781-58

**Penetrating Keratoplasty Patient Education**

Fitting contact lenses after a PK is a considerable challenge for practitioners. It is necessary to assess the motivation and attitude of the patient prior to fitting and to provide support at all stages of the process of achieving an acceptable lens fit.

A key factor in the patient education process is to make them aware fully of the possible complications associated with contact lens wear following PK such as:

- Graft rejection.
- Variable or poor vision.
- Lens adaptation.
- Loss of tolerance to lens wear.
- Ocular infection.

207

**PATIENT AFTER-CARE**

Careful assessment of:

- Health of the graft
  - clarity
  - vascularization
- Fitting characteristics
- Corneal staining

97781-59S.PPT



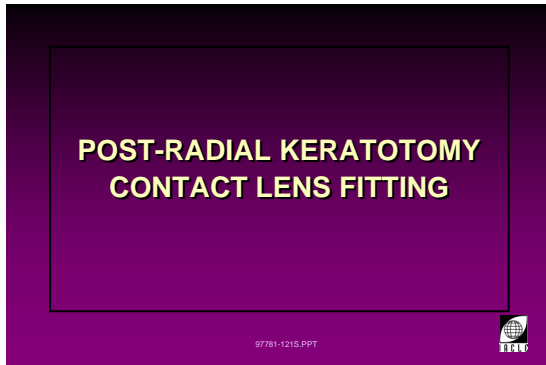8L697781-59

**Contact Lenses and Patient After-Care Following Penetrating Keratoplasty**

Careful follow-up is required once contact lenses are fitting to any eye that has been altered surgically. Complications can occur because of a less than optimum fit. An acceptable fitting is one that does not compromise corneal or conjunctival integrity further.

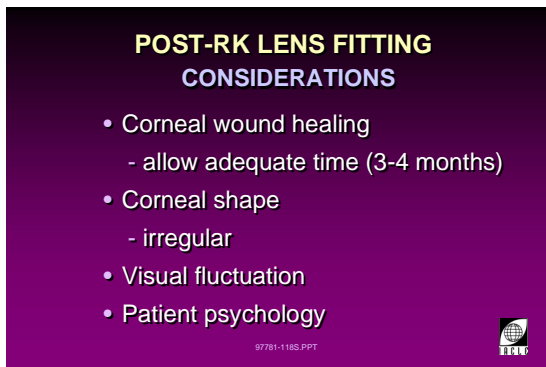
## XVI Contact Lens Fitting Following RK

208



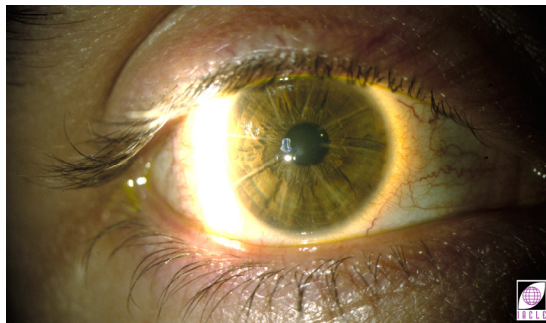8L697781-121

209



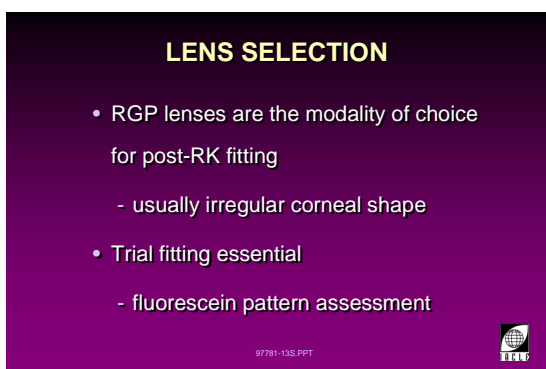
8L697781-118

210



8L62667-93

211



8L697781-13

### Contact Lens Fitting Following Radial Keratotomy (RK)

The post-RK patient (slide 210) is often a challenging case for a contact lens fitting. They may be disillusioned with the visual outcome of refractive surgery and their fluctuating vision over the course of the day may compound their dissatisfaction. Any unrealistic expectations on the part of the patient must be addressed prior to commencing contact lens fitting.

Many patients require some form of contact lens correction to realize their maximum visual potential. Due to the degree of irregular astigmatism that may be present, spectacles are usually incapable of providing a good visual result.

No contact lens fitting should be undertaken until the incisions have healed and the consulting surgeon has given their permission to proceed. During the healing phase, raised areas may be apparent over the incision. Fluorescein penetration into the incision indicates that the epithelium is not intact and that wound healing is still in progress. In such cases, contact lens fitting is contraindicated.

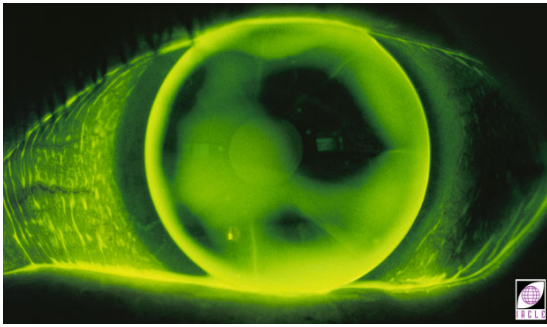
### Contact Lens Selection Following Radial Keratotomy

Generally, RGP contact lenses are the lens of first choice for post-RK fittings (slide 212). These lenses are more appropriate because they provide a smooth, regular, artificial anterior surface for the eye that masks the irregularities that exist at every incision. A rigid lens corrects any irregular astigmatism that may be present and also helps to reduce the flare that may result from the incisions in the cornea (incisions can produce local irregularities in the anterior surface of a normal [no contact lens] tear film).

Fluctuations in vision can occur because of changes in corneal shape that occur over the course of a day. The tear lens present under RGP lenses can mask these changes, at least partially, and result in more stable vision, i.e. little diurnal variation.



212

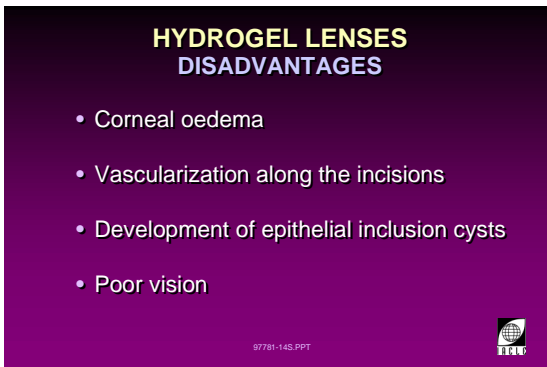


8L60564-97

The high oxygen transmissibility of some RGP lenses also promotes a healthy environment for an already compromised cornea.

Siloxane hydrogel lenses may prove useful in some cases because of their greater rigidity (cf. conventional hydrogels) and the high oxygen transmissibility they offer the eye. However, it is probable that their properties overall are too near those of other hydrogels to solve the optical problems posed by the post-RK eye.

213



8L697781-14

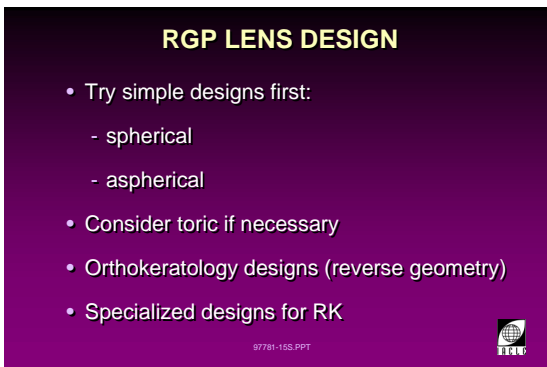
### Conventional Hydrogel Contact Lenses: Disadvantages

Spherical hydrogel lenses draped over the contours of post-RK corneas correct none or little of any astigmatism present. Unlike RGP lenses, the fluctuations in corneal shape that occur during the day are also unaffected by hydrogel lenses.

Conventional hydrogel lenses are likely to induce corneal oedema and a common result is the development of corneal vascularization along the radial incisions. The vessels may also leak lipids that are often accompanied by infiltrates, pannus formation and subsequently, corneal scarring.

Because of these limitations, conventional hydrogel lenses are not recommended for RK patients.

214



8L697781-15

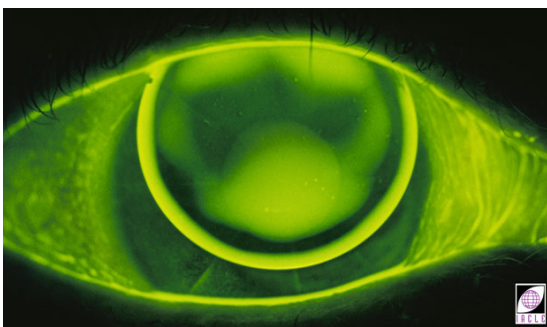
### RGP Lens Fitting Following Radial Keratotomy

The three main techniques that are employed when fitting the RK patient are:

- Superior corneal alignment with lid attachment (slide 215).
- Interpalpebral fitting using smaller and steeper lenses.
- Reverse geometry (Orthokeratology) designs that are flatter centrally and steeper peripherally.

Generally, the interpalpebral designs are too small to achieve satisfactory centration and are not the lenses of first choice.

215




8L6565-97

216

**LENS FITTING**

- Based on corneal shape analysis:
  - pre-surgical keratometry
  - videokeratoscope
- Based on the amount of myopia
- Large lens total diameter (TD)

97781-16S.PPT



8L697781-16

### Lens Fitting Following Radial Keratotomy

Videokeratometry provides the most accurate measurement of the corneal topography following RK. The degree of central corneal flattening and the transition to the peripheral cornea are important characteristics that dictate the design and fitting of contact lenses subsequently.

Following RK, the centre of the cornea is relatively flat and the mid-periphery can be irregular and relatively steep. The transition zone forms an 'elbow' or bend spanning the flatter centre and the steeper periphery. This makes RGP lens centration difficult and the degree of decentration varies from eye to eye.

Rarely is an ideal fitting achieved with post-RK patients. The practitioner's aims should be to achieve a stable lens fit that does not compromise ocular physiology.

Initial lens BOZR selection can be an alignment fitting based on the pre-operative keratometric readings, i.e. the initial BOZR is equal to the flattest original K value. This results in a lens that is significantly steeper overall than the post-surgical cornea, that is aligned with the mid-periphery, and which vaults the apical zone significantly.

The presence of a large central bubble under the initial lens indicates that it is too steep. In such a case, the BOZR should be flattened incrementally until the bubble is no longer present.

To optimize lens centration, large lens diameters are recommended. Typically, TDs ranging from 9.50 to 11.00 mm are used.


217

**LENS FITTING**

Desirable features:

- Adequate peripheral clearance
- No inferior bubbles
- Good tear exchange
- Large optical zone extending to the corneal periphery
- Larger than normal axial edge clearance

97781-17S.PPT



8L697781-17

### Post-Radial Keratotomy Lens Fitting Assessment

It is important for all RGP lens fittings to be assessed with sodium fluorescein. Because the corneal contour is unpredictable and heavy lens bearings undesirable, instilled fluorescein is probably the only means of disclosing any bearing areas.

In general, a good fitting lens will exhibit central pooling with a zone of mid-peripheral bearing. A lens that is too steep centrally can result in bubbles trapped behind the lens because of excessive central pooling (post-lens tear film too deep centrally).

The objective when fitting the post-RK eye is to achieve a satisfactory fit that the patient can tolerate and that provides acceptable vision.


218

**LENS FITTING ASSESSMENT**

Expect to see:

- Central fluorescein pooling
- Lens decentration
- Bubbles beneath lens

97781-18S.PPT



8L697781-18




219

**SOLVING FITTING PROBLEMS  
FLUCTUATING VISION**

- Diurnal variation
- Trial a flatter fitting
- Increase lens centre thickness

97781-24S.PPT



8L697781-24

**Problem Solving: Vision**

Because of the difficulty in achieving adequate lens centration (slide 221) on a post-RK cornea, it is likely that the patient will experience some problems associated with flare and glare from lights, especially at night.


Changes in lens design are required to provide better lens centration. This is generally achieved by increasing the lens TD and BOZD. An alternative is to trial an aspheric back surface design or a reverse geometry lens (slide 222).

220

**SOLVING FITTING PROBLEMS  
FLARE AND GLARE**

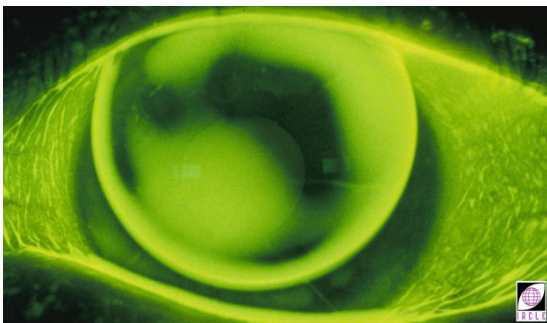
- Increased BOZD
- Increase lens diameter (TD)
- Trial an aspheric design

97781-19S.PPT



8L697781-19

221



222

**POST RK CONTACT LENS FITTING**



**LENS**  
**Contex OK-3**  
**BOZR: 8.2 mm**  
**TD: 10:00 mm**  
**BVP: +1.75 D**

97781-223S.PPT




8L697781-223 DCP

223

**SOLVING FITTING PROBLEMS  
DECENTRATION**

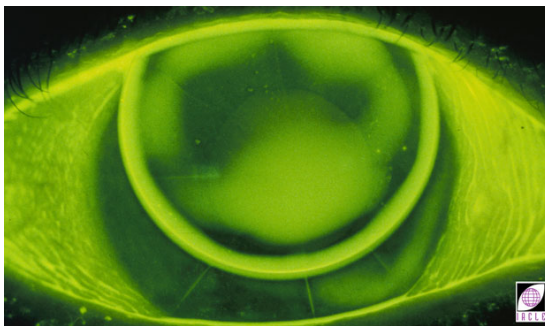
- Increase BOZD
- Modify peripheral curves
- Trial an aspheric design
- Add prism ballast for high riding lenses
- Reverse geometry designs

97781-20S.PPT



8L697781-20

224




8L61172-95

225

**SOLVING FITTING PROBLEMS  
INFERIOR DECENTRATION**

- Decrease lens mass
  - lenticulation
  - reduce lens total diameter (TD)
- Use lower specific gravity material
- Incorporate a minus lenticular design
- Large BOZD with flat peripheral curves
- Reverse geometry designs

97781-21S.PPT




8L697917-21

226

**SOLVING FITTING PROBLEMS  
PERIPHERAL CLEARANCE**

- Excessive
  - change to an aspheric design
- Inadequate
  - flatten/widen peripheral curves

97781-22S.PPT



8L697781-22

**Problem Solving: Lens Decentration**

Following RK, the corneal apex can be displaced significantly towards the corneal mid-periphery and this new location then becomes the steepest region of the cornea. Because an RGP lens has the tendency to centre over this steeper region, significant decentration can ensue. As a direct result, obtaining good centration can be difficult (slide 224).

Reverse geometry lenses, used primarily for orthokeratology, are a valuable alternative to conventional RGP designs and should be considered in cases of excessive decentration. Such designs more closely match the altered corneal shape of the post-RK patient and these may be able to maintain an acceptable more central position on the cornea.

**Problem Solving: Peripheral Clearance**

Peripheral clearance should be judged only after the best central fitting relationship is achieved. This may be achieved with an aspheric or reverse geometry design.

Once the optimum lens design is determined for the central region of the cornea, the remaining lens parameters, especially those relating to the edge fit (e.g. edge clearance), can be altered to improve the peripheral and edge fluorescein patterns.

227

**POST-FITTING COMPLICATIONS**

- Significant corneal staining
- Recurrent corneal erosions (RCE)
- Infection
- Vascularization

97781-23S.PPT



8L697781-23

**Post-Radial Keratotomy Contact Lens Fitting Complications**

Significant complications can result from fitting contact lenses to the post-RK eye.

Fitting of an RGP lens to an irregular cornea can induce significant epithelial staining due to the friction/rubbing/bearing effect of the lens back surface on areas of the cornea that stand proud of the local surface.

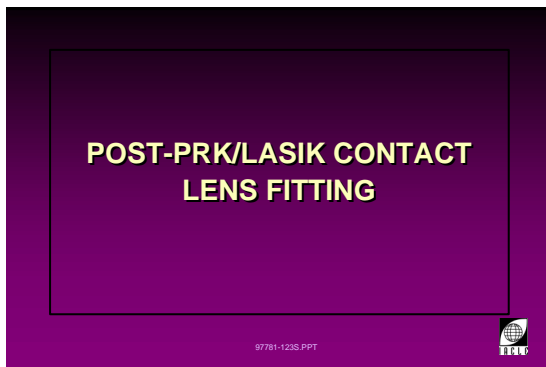Regular after-care visits are essential in the early stages of lens wear to assess the health of the epithelium and to rule out the development of significant epithelial staining (a portal of entry into the cornea) that has the potential to become a focal point for a corneal infection.

Post-RK, the epithelial basement membrane is disturbed and this may result in recurrent corneal erosions due to a weakening of the attachment of the epithelium's basal cells to the basal lamina and the basal lamina to Bowman's layer.

Vascularization of the post-RK cornea is common when conventional hydrogel lenses are employed, especially on an EW basis. The new vessels tend to follow the incision lines.

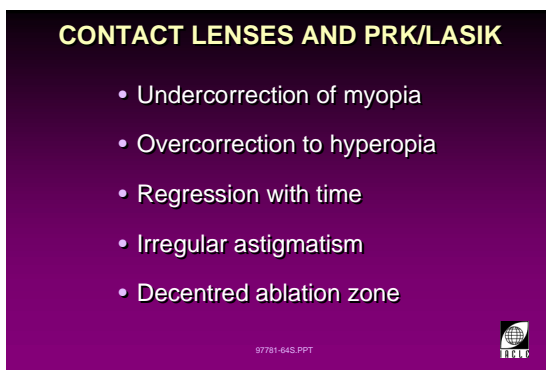
## XVII Contact Lens Fitting Following PRK and LASIK

228



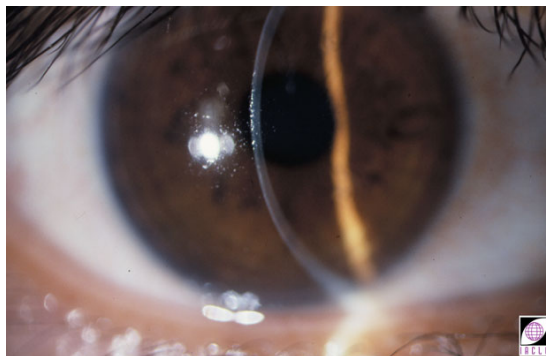
8L697781-123

229



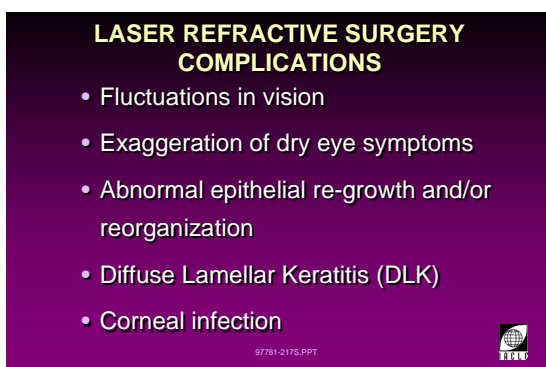
8L697781-64

230



8L60498-98

231



8L697781-217

### Contact Lens Fitting after PRK and LASIK

Complications associated with LASER refractive surgery (slide 230) can result in visual compromises that require contact lens correction.

Complications include:

- Eccentric ablation.
- Irregular corneal topography.
- Scars.
- Corneal ectasia.

Optical aberrations affecting visual function can result from altered topography and surface irregularities induced by flap striae or folds.

Hyperplasia may play a role in refractive regression and/or irregular corneal topography. Decentred ablations and central islands can result in decreased contrast sensitivity, monocular diplopia/polyopia, decreased vision, and irregular astigmatism.

Residual refractive errors that represent over or under-correction can persist after LASER refractive surgery. These may require a contact lens correction or a surgical 'enhancement' to maximize visual performance.

PRK can induce superficial scars that may affect vision adversely. In some cases, visual function may be improved by the use of a suitable contact lens. Contact lenses can also be used to promote epithelial healing following PRK and LASEK, as well as used to support LASIK flaps should complications arise (for more detail, see Lecture 8.7: **Therapeutic Contact Lenses** in this module).


Other complications that can follow any LASER refractive surgical procedure are listed in slide 231.

232

**LASER REFRACTIVE SURGERY  
OTHER CONSIDERATIONS**

- Patient motivation
- Patient psychology (mindset)
- Altered corneal topography
- Reduced corneal sensitivity
- Dry eye
- Topographical changes over time
  - regressive
  - other

97781-218S.PPT



8L697781-218

233

**LENS FITTING IN PRK/LASIK**

- RGPs are the lenses of choice
  - better vision
  - good physiology
- Need to bridge the central ablated zone
- Minimal patient motivation
- Hydrogel lens for intolerant cases

97781-65S.PPT



8L697781-65

234

**PRK/LASIK FITTING  
RGP CONSIDERATIONS**

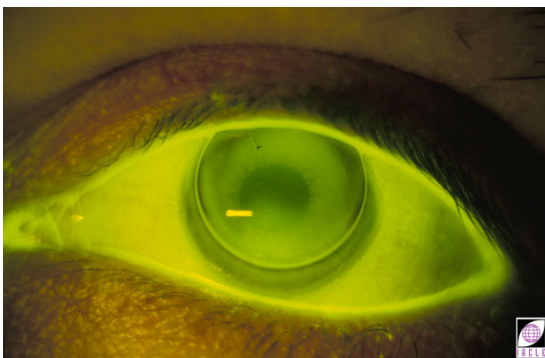
- Larger total diameter (TD) required
- Keep BOZD small to prevent:
  - adherence
  - excessive tear pooling
  - bubble formation
- Bearing on transition zone
- Edge clearance

97781-234S.PPT



8L697781-117

235



8L60292-95

**Contact Lens Fitting Considerations**

A key factor when fitting contact lenses after refractive surgery is the level of patient motivation. It needs to be borne in mind that the patient is being asked to consider resorting to a form of vision correction they chose to discard previously. It is important to allow sufficient time after surgery for the cornea to heal, the topography to stabilize, and maximum comfort to be achieved. Other factors are listed in slide 232.

RGP lenses (slide 235) are the lenses of choice to correct the refractive error induced by an irregular corneal shape. Tears fill the space between the smooth back surface of the contact lens and the irregular corneal surface thereby correcting (approximately 90%, see Lecture 2.3, Module 2 of this course) the vision problems induced by corneal irregularities.

236

### POST-PRK/LASIK LENS FITTING CONSIDERATIONS

- Allow for wound healing
- Ablation zone diameter
  - smaller is easier to fit
- Transition to normal cornea
  - smooth, gradual transition is easier to fit



8L697781-119

237

### RGP SELECTION CORNEAL TOPOGRAPHY

- Prolate
  - aspheric
  - bi-aspheric
  - bitoric
  - standard RGP design



8L697781-114

### Corneal Topography Following PRK/LASIK

Assessment of corneal topography using a videokeratoscope provides useful information about the shape of the central and peripheral cornea and may be of value in selecting an appropriate trial lens or in understanding the effect of corneal shape on the lens fitting characteristics.

The peripheral cornea outside the zone of ablation maintains a relatively normal shape. In these cases, the original peripheral design of an RGP lens may still provide a suitable fitting relationship with the cornea. Due to the cornea's flat central zone, a standard RGP lens will usually result in significant apical clearance, and a large pool of fluorescein being observed centrally.

Examples of the different corneal topographies that may exist following refractive surgery include:

- Eccentric ablation – although the ablation area may be round and regular it is off-centre. This results in a large dioptric shift across the central pupil zone and may cause reduced vision, glare, halos, monocular diplopia, vision that varies with pupil size, and decreased contrast sensitivity.
- Paracentral steep island – this is a well circumscribed area of greater refractive power. Topographic values show that power variations in the pupil zone range up to 20.00 D or more.
- Irregular ATR astigmatism with inferior corneal steepening – this pattern resembles PMD.
- Highly irregular corneal topography following flap dislocation.

A corneal topography map can assist the contact lens practitioner to determine the most appropriate lens design.

238

### RGP SELECTION CORNEAL TOPOGRAPHY

- Oblate
  - reverse geometry
  - aspheric
    - steepening ellipse
  - bitoric



8L697781-115




239

**TRIAL LENS DESIGN**

- BOZR 0.25 mm steeper than flattest K
- Use pre-op BOZR as starting point
- Provide central clearance
- Peripheral bearing for support
- BOZD large enough to cover ablation zone
- Lens TD (9.60 mm or larger)
- Consider aspheric design

97781-239S.PPT



8L697781-66

**Trial Lens Design and Fitting Following Laser Refractive Surgery**

Due to the irregular corneal shape that exists in some post-refractive surgery cases, keratometry may be difficult and the results unreliable. When fitting the PRK/LASIK patient, the pre-operative K readings or the original contact lens BOZRs can be used as a starting point for post-operative RGP lens fitting.

Contact lenses can be fitted at almost any time following refractive surgery. It is wise to allow sufficient time, probably at least 2–4 weeks, for the cornea to heal before applying lenses.

240

**TRIAL LENS FITTING**

Look for:

- Adequate centration
- Sufficient movement
- Stable fitting
- Tear exchange
- Stable vision

97781-67S.PPT



8L697781-67

There are no hard and fast rules when fitting RGP lenses after refractive surgery. In general, similar fitting philosophies for an RGP lens on a normal cornea are used. The desirable features include:

- Acceptable centration of the optic zone over the pupil.
- Adequate movement with each blink.
- Adequate tear exchange with each blink.
- Adequate edge lift providing 360° clearance.
- Absence of lens-induced corneal staining.


Generally, lenses with large back optic zones (BOZDs) and TDs provide a more satisfactory fitting as they are able to bridge or vault the ablation zone.

241

**FITTING DIFFICULTIES**

- Patient disappointment
- Intolerance
- Topographical changes with time

97781-68S.PPT



8L697781-68

**Post-LASIK Contact Lens Fitting Difficulties**

As with all post-refractive surgery contact lens fitting, many potential difficulties are faced by both the patient and the practitioner. It is essential that the wearer be warned in advance about the possible problems they may face both during lens fitting and after lens dispensing. The patient must have realistic expectations prior to contact lens fitting, otherwise they may be disappointed with the visual outcome or the comfort achieved with contact lenses.

Changes in both the corneal topography and contact lens fitting characteristics must be carefully assessed throughout the contact lens-wearing period.

## References

- Ambrosio R, Wilson SE (2001). *Complications of in situ keratomileusis: etiology, prevention, and treatment*. J Refract Surg. 17: 350 – 379.
- Aquavella JV, *et al.* (1990). Contact lens and refractive surgery. In: Harris MG (Ed). *Problems in Optometry: Contact Lenses and Ocular Disease*. Lippincott. Philadelphia.
- Assil KK (1994). *Radial keratotomy: the combined technique*. Int Ophthalmol Clin. 34 (4): 55 – 77.
- Astin CLK, *et al.* (1996). *Contact lens fitting after photorefractive keratectomy*. Br J Ophthalmol. 80: 597 – 603.
- Astin CLK (1996). *Post-photorefractive keratectomy contact lens fitting*. J Brit Cont Lens Assoc. 19: 55 – 57.
- Astin CLK (1997). Contact lenses in abnormal ocular conditions: Radial keratotomy and photorefractive keratectomy. In: Phillips AJ, Speedwell L, (Eds). *Contact Lenses (4th ed)*. Butterworth-Heinemann. London.
- Bennett ES, *et al.* (1999). *RGP lens management of the irregular cornea patient*. CL Spectrum. Dec: 21 – 25.
- Board of Directors, International Soc. of Refractive Keratoplasty (1988). *Statement on Radial Keratotomy in 1988*. J Ref Surg. 4(3): 80 – 90.
- Bufidis T, *et al.* (2000). *Contact lens fitting difficulties following refractive surgery for high myopia*. CLAO J. 26: 106 – 110.
- Bufidis T, *et al.* (2005). *Contact lens fitting in the refractive surgery patient*. [www.medscape.com/viewarticle/508288](http://www.medscape.com/viewarticle/508288).
- Buratto L, Ferrari M, Rama P (1992). *Excimer laser intrastromal keratomileusis*. Am J Ophthalmol. 113: 291 – 295.
- Buratto L, *et al.* (1993). *Myopic keratomileusis with the excimer laser: one-year follow up*. Refract Corneal Surg. 9: 12 – 19.
- Chou AC, *et al.* (1999). *Fitting contact lenses after myopic keratomileusis*. J Cataract Refract Surg. 25: 508 – 513.
- Cimberle M (2005). *Ferrara rings show long-term stability in keratoconus patients*. Oc Surg News (Euro/Asia-Pacific Ed.) 16(9): 13 – 14.
- Daya S (2005). *IntraLase – a review*. Optician. 229(5995) (April 1): 20 – 23.
- Donald T (2005). *Both wavefront and topography needed for optimum customization*. Oc Surg News. 2005-Dec-1: visit: [www.osnsupersite.com](http://www.osnsupersite.com).
- Eggink FAGJ, *et al.* (2001). *Rigid gas-permeable contact lens fitting in LASIK patients for the correction of multifocal corneas*. Graefe's Arch Clin Exp Ophthalmol. 239: 361 – 366.
- Gartry DS, *et al.* (1992). *Excimer laser photorefractive keratectomy; 18 month follow-up*. Ophthalmology. 99: 1209 – 1219.
- Geffen DI (1996). *A guide to prescribing contact lenses after refractive surgery*. CL Spectrum. Feb: 17 – 27.
- Gower M (1987). *Excimer LASERS*. Electronics Today International (Aust. edition) (April): 18 – 20.
- Guttman C (2004). *Epi-keratome brings Epi-LASIK into hands of refractive surgeons*. Ophthalmology Times Jan. 1, on-line newsletter ([www.opthalmologytimes.com/opthalmologytimes/article/articleDetail.jsp?id=82709](http://www.opthalmologytimes.com/opthalmologytimes/article/articleDetail.jsp?id=82709)).
- Hardten DR, Lundstrom RL (1997). *Surgical Correction of Refractive Errors After Penetrating Keratoplasty*. In: Friedlaender MH (Ed.), *International Ophthalmology Clinics: Current Concepts in Refractive Surgery*. Lippincott-Raven Publishers, Philadelphia. 4.
- Ho A, *et al.* (2004). *Modeling performance of pseudo-accommodation and accommodating IOL*. Paper presented to SPIE, January, 2004.

- Javadi MA, *et al.* (2005). *Outcomes of penetrating keratoplasty in keratoconus*. *Cornea*. 24(8): 941 – 946.
- Kanski JJ (1999). *Clinical Ophthalmology. A Systematic Approach*. 4<sup>th</sup> ed. Butterworth Heinemann, Oxford. 162 – 164.
- Kennedy RH, *et al.* (1986). *A 48-year clinical and epidemiologic study of keratoconus*. *Am J Ophthalmol*. 101(3): 267 – 273.
- Krueger RR, Burris TE (1996). *Intrastromal corneal ring technology*. *Int Ophthalmol Clin*. 36 (4): 89 – 106.
- Lee AM, Kastl PR (1998). *Rigid gas permeable contact lens fitting after radial keratotomy*. *CLAO J*. 24: 33 – 35.
- L'Esperance FA (1993). *Chapter 1: History and Development of the Excimer Laser*. In: Thompson FB, McDonnell (Eds), *Color Atlas/Text of EXCIMER LASER SURGERY*. Igaku-Shoin, New York. 1.
- Lim L, *et al.* (1999). *Contact lens wear after photorefractive keratectomy: comparison between rigid gas permeable and soft contact lenses*. *CLAO J*. 25: 222 – 227.
- Lim L, *et al.* (2000). *Reverse geometry contact lens wear after photorefractive keratectomy, radial keratotomy, or penetrating keratoplasty*. *Cornea*. 19: 320 – 324.
- Lin, P-Y, *et al.* (2001). *Combined phototherapeutic keratectomy and therapeutic contact lens for recurrent erosions in bullous keratopathy*. *Br J Ophthalmol*. 85: 908 – 911.
- Lindstrom RL (2005). *Introduction* (the editorial to the suppl.). In: *Wavefront-Designed IOLs*, a Suppl. to *Oc Surg News Euro/Asia-Pacific Ed*. 16(9).
- Maini R, Loughnan MS (2002). *Phototherapeutic keratectomy re-treatment for recurrent corneal erosion syndrome*. *Br J Ophthalmol*. 86: 270 – 272.
- McDonald MB, Frantz MJ, Klyce SD, *et al.* (1990). *Central photorefractive keratectomy for myopia: the blind eye study*. *Arch Ophthalmol*. 108: 799 – 808.
- McDonnell JM, *et al.* (1992). *Unsuccessful excimer laser phototherapeutic keratectomy. Clinicopathologic correlation*. *Arch Ophthalmol*. 110(7): 977-979.
- Mc Ghee CNJ, *et al.* (1997). *Current and future trends in the surgical correction of ametropia*. *Optom Today*. Sept 19: 26 – 31.
- Neumann AC, *et al.* (1990). *Radial thermokeratoplasty for the correction of hyperopia*. *Refract Corneal Surg*. 6: 404 – 412.
- Nosé W, *et al.* (1996). *Intrastromal corneal ring: 12-month sighted myopic eyes*. *J Refract Surg*. 12: 20 – 28.
- Pallikaris IG, *et al.* (1990). *Laser in-situ keratomileusis*. *Lasers Surg Med*. 10: 463 – 468.
- Pallikaris IG, Siganos DS (1997). *Laser in situ keratomileusis to treat myopia: early experience*. *J Cataract Refract Surg*. 23: 39 – 49.
- Patel SV, *et al.* (2004). *Corneal endothelium and postoperative outcomes 15 years after Penetrating keratoplasty*. *Trans Am Ophthalmol Soc*. 2004;102: 57 – 66.
- Phillips AJ (1990). *Postkeratoplasty contact lens fitting*. In: *Problems in Optometry – Contact Lenses and Ocular Disease* (Harris MG Ed.). Lippincott. 664 – 684.
- Rinehart JM (1999). *A new option for refractive surgery patients*. *CL Spectrum*. Dec: 40 – 43.
- Salah T, *et al.* (1996). *Excimer laser in situ keratomileusis under a corneal flap for myopia of 2 to 20 dioptres*. *Am J Ophthalmol*. 121: 143 – 155.
- Schipper I, Bursinger U, Pfarrer R (1995). *Fitting contact lenses after excimer laser photorefractive keratectomy for myopia*. *CLAO J*. 21: 281 – 284.
- Seiler T (1993). *Chapter 4: Photorefractive Keratectomy: European Experience*. In: Thompson FB, McDonnell (Eds), *Color Atlas/Text of EXCIMER LASER SURGERY*. Igaku-Shoin, New York. 53.

- Seiler T, Wollensak J (1991). *Myopic photorefractive keratectomy with the excimer laser. 1 year follow-up.* Ophthalmology. 98: 1156 – 1163.
- Sekundo W, et al. (2005). *Most patients report no benefit from bandage lens after LASIK.* Ophthalmology. 112(2): 180 – 183.
- Shovlin JP (1992). *A comparison between patients wearing contact lenses following radial keratotomy and myopic photorefractive keratectomy with the excimer laser.* Int Cont Lens Clin. 19: 141 – 142.
- Spalton DJ (1999). *Harold Ridley's first patient.* J Cataract Refract Surg. 25: 156.
- Stark WJ, et al. (1993). *Chapter 8. Therapeutic Keratectomy: Corneal Opacities.* In: Thomson FB, McDonnell PJ (Eds.), *Color Atlas/Text of EXCIMER LASER SURGERY: THE CORNEA.* Igaku-Shoin, New York. 105 - 119.
- Steinert RF (1993). *Chapter 9. Therapeutic Keratectomy: Corneal Smoothing.* In: Thomson FB, McDonnell PJ (Eds.), *Color Atlas/Text of EXCIMER LASER SURGERY: THE CORNEA.* Igaku-Shoin, New York. 121 - 129.
- Szczotka LB, Aronsky M (1998). *Contact lenses after LASIK.* J Am Optom Assoc. 69: 775 – 784.
- Thompson FB, et al. (1993). *Chapter 6: Photorefractive Keratectomy: High Myopia.* In: Thompson FB, McDonnell (Eds), *Color Atlas/Text of EXCIMER LASER SURGERY. THE CORNEA.* Igaku-Shoin, New York. 85.
- Trokel SL, et al. (1983). *Excimer laser surgery of the cornea.* Am J Ophthalmol. 96: 710 – 715.
- Vasavada AR, et al. (2005). *Hydrodissection combined with rotation cleans epithelial cells from capsular bag.* Oc Surg News Euro/Asia-Pacific Ed. 16(10): 15 – 19.
- Waknine Y, (2004). *Deep lamellar keratoplasty an effective alternative in keratoconus.* Medscape Medical News, visit: [www.medscape.com/viewarticle/489895](http://www.medscape.com/viewarticle/489895).
- Ward MA (1996). *Contact lens management after refractive surgery.* CL Spectrum. Oct: 23 – 31.
- Ward MA (2001). *Visual rehabilitation with contact lenses after laser in situ keratomiluesis.* J Refract Surg. 17: 433 – 440.
- Waring GO (1987). *The Lans distinguished refractive surgery lecture.* J Refract Surg. 3: 115 – 116.
- Weiner B (1987). *Contact lenses for post-corneal surgery patients.* CL Spectrum. Dec: 24 – 28.
- Wharton KR (1989). *Corneal stellate iron lines following radial keratotomy.* J Am Optom Assoc. 60(5): 362 – 364.
- Wilson SE (1998). *LASIK: Management of common complications.* Cornea. 17: 459 – 467.  
[www.emedicine.com](http://www.emedicine.com) (2004). *Excerpt from astigmatism, LASIK.*  
[www.emedicine.com/oph/byname/astigmatism-lasik.htm](http://www.emedicine.com/oph/byname/astigmatism-lasik.htm)
- Zadnik K (1999). *Contact lens management of patients who have had unsuccessful refractive surgery.* Curr Opin Ophthalmol. 10: 260 – 263.



# Unit 8.7

(2 Hours)

## Lecture 8.7: Therapeutic Contact Lenses



## Course Overview

### **Lecture 8.7: Therapeutic Contact Lenses**

- I Introduction to Therapeutic Contact Lenses and Their Use**
- II Specific Indications for Therapeutic Contact Lens Wear**
- III Post-Operative Uses for Therapeutic Hydrogel Lenses Including Topical Drug Delivery**
- IV Lens Selection and Design**
- V Complications Associated with Therapeutic Contact Lens Wear**

# Lecture 8.7

(2 Hours)

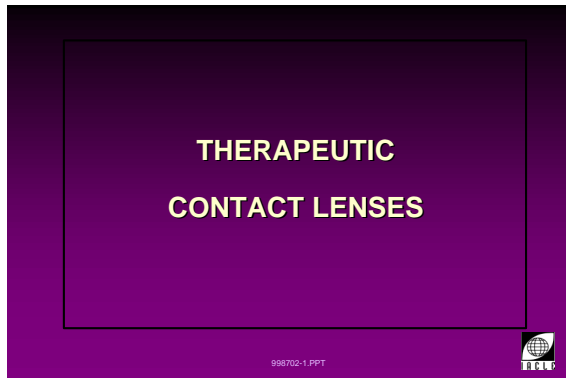## Therapeutic Contact Lenses

## Table of Contents

<b>I</b>	<b>Introduction to Therapeutic Contact Lenses .....</b>	<b>321</b>
<b>II</b>	<b>Use of Therapeutic Contact Lenses .....</b>	<b>322</b>
<b>III</b>	<b>Specific Indications for Therapeutic Contact Lens Wear.....</b>	<b>326</b>
<b>IV</b>	<b>Post-Operative Uses for Therapeutic Hydrogel Contact Lenses.....</b>	<b>336</b>
<b>V</b>	<b>Topical Drug Delivery .....</b>	<b>338</b>
<b>VI</b>	<b>Lens Selection and Design.....</b>	<b>339</b>
<b>VII</b>	<b>After-Care of Therapeutic Contact Lenses.....</b>	<b>341</b>
<b>VIII</b>	<b>Complications Associated with Therapeutic Contact Lens Wear .....</b>	<b>342</b>

## I Introduction to Therapeutic Contact Lenses

1



8L7998702-1

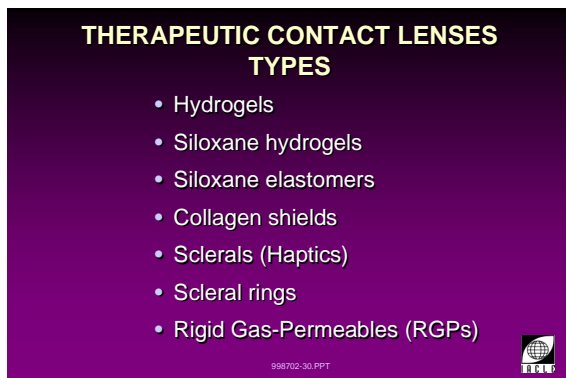
### Therapeutic Contact Lenses: Introduction

Therapeutic contact lenses, sometimes known as 'bandage' lenses because of one of their main applications, are special contact lenses worn for therapeutic reasons, e.g. treatment of a corneal or anterior eye disease. In this lecture, the terms 'bandage' and 'therapeutic' are used interchangeably.

The earliest contact lenses fitted in the 1880s were employed originally for bandage purposes, not vision correction (see Module 2, Lecture 2.1: **The History of Contact Lenses**). The advent of hydrogel lenses made possible an upsurge in therapeutic applications of contact lenses (Steele, 1997). John *et al.* (1994) credits Rycroft (1964) with the first use of hydrogel lenses for therapeutic purposes (for ocular pemphigoid and Stevens-Johnson syndrome).

Although therapeutic contact lenses can be used to correct refractive error, they are used primarily for physical therapeutics, eye protection, and as an aid to healing.

2



8L7998702-30

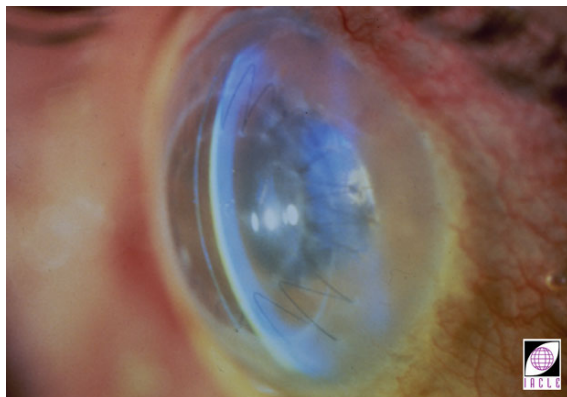
### Types of Therapeutic Contact Lenses

Most therapeutic lenses are hydrogels that are larger than the corneal diameter to ensure complete corneal coverage under all foreseeable circumstances. The development of highly oxygen permeable siloxane hydrogel lenses has provided another valuable option for fitting patients requiring a therapeutic contact lens (and vision correction if necessary). Although initially in an animal model, Sweeney and Holden (1988) demonstrated the potential of siloxane-containing contact lenses for therapeutic applications. The siloxane elastomer lenses they used had oxygen transmissibilities approximately half that of the current generation of siloxane hydrogels.

In addition to hydrogel and siloxane hydrogels, other materials used are siloxane elastomers, collagen, and RGP polymers in the form of scleral ('haptic') lenses (slide 3). Normal RGP lens designs are rarely used for eye protection or other therapeutic purposes.

Tinted contact lenses that assist colour defective wearers to discriminate between the colours they usually confuse are not covered here because they are not therapeutic. Such lenses are dealt with in Lecture 8.8 of this Module.

3



8L70724-95

## II Use of Therapeutic Contact Lenses

4

### GENERAL FUNCTIONS

- Comfort after Veys et al., 2001
  - pain relief
- Mechanical protection
- Promotion of healing
- Maintenance of ocular surface hydration
- Vision enhancement
- Sealing of corneal perforations
- Delivery of medications
- Structural support of the cornea

998702-2.PPT



8L7998702-2

### General Functions

The need for a therapeutic contact lens should be expected in general contact lens practice and the clinical issues involved are well within the abilities of any competent contact lens practitioner.

More advanced applications of these lenses are usually managed in a hospital setting by practitioners who are familiar with ocular diseases and the types of lenses best suited to managing these conditions.

Regardless of the severity or chronicity of the conditions requiring the application of such lenses, the contact lens practitioner should be well-versed in their appropriate use, the fitting decisions required, and the after-care needed by patients wearing therapeutic contact lenses.

Therapeutic lenses have wide-ranging applications. Some of these applications include:

5

### THERAPEUTIC CONTACT LENS WEAR CONSIDERATIONS

- Case analysis and selection
  - risks *versus* benefits
  - practitioner should try to remain objective
- Lens availability
- Conjunctive and adjunctive therapy
- Management plan
  - co-management requirements

998702-33.PPT



8L7998702-33

- Increased comfort – relief of pain from exposed nerve endings that can occur in conditions such as band keratopathy, corneal abrasions, and BK.
- Mechanical protection – protecting the cornea in cicatrizing ocular surface diseases, and from mechanical injury in conditions such as trichiasis (inverted eyelashes abrading the anterior eye).

6

### THERAPEUTIC CONTACT LENSES MISCELLANEOUS ISSUES

- Use clean, lint-free hands after Astin, 1991
- Avoid small, physical threats, e.g. metal cap fragments
  - reduced corneal sensitivity may not disclose threat
- Use sterile procedures if eye perforated or viral transmission possible
- Avoid preserved LCPs and medications
- Use siloxane hydrogels where possible
  - fragile epithelia may require a high-water hydrogel

998702-41.PPT



8L7998702-41

- Wound healing – assisting epithelial defect healing by protecting migrated and/or newly formed cells from dislodgement by the blinking action of the eyelids.
- Vehicle for drug delivery – allowing prolonged drug delivery, albeit at a lower dosage rate for better permeation and absorption. The drug remains in the eye longer and the eye is not exposed to the very high initial dose [pulse dose] that accompanies the conventional application of therapeutic eyedrops.
- Maintaining ocular surface hydration – preventing tear evaporation or providing a moisture reservoir for the ocular surface in cases of severe dry eye.

7

### THERAPEUTIC CONTACT LENSES MISCELLANEOUS ISSUES

- If thin lenses used, inform other relevant practitioners
  - presence of such lenses may be missed by others
- If keratometer mires unusable, use other eye (if present)
- If graft or limbal inflammation, use TDs of 14.5 to 16 mm
- If tissue disturbed beyond limbus, TDs 18 to 20 mm
- Use tear supplements to lubricate eyes and ↓ deposits
- Replace damaged or deposited lenses without hesitation

998702-42.PPT



8L7998702-42

- Vision enhancement – while this is not the primary purpose of therapeutic contact lenses, vision can be improved in some cases simply by the presence of a plano or powered contact lens, e.g. by smoothing an irregular corneal surface.
- Occlusion for amblyopia therapy – amblyopia, secondary to differences in ocular image quality between the eyes (e.g. in anisometropia), can be treated by occluding the 'better eye' using an opaque patch, translucent filter or refractive blur (i.e. conventional or so-called direct occlusion).

8

### FITTING CONSIDERATIONS

- Wearing schedule
  - DW, EW, CW
- Level of dexterity
- Patient's age
- Help available
  - family, friends, other health professionals
- General health and medical history

998702-31.PPT



8L7998702-31

This stimulates the 'neglected eye' by endeavouring to make it the 'better' eye practically or by default. Refractive blur can be produced monocularly simply by modifying the power of the contact lens. While the BVP of the contact lens can be an excess of plus or minus power, it is more usual to pursue excess plus or insufficient minus. Once the maximum vision improvement is attained, contact lenses with the optimum Rx for best binocular vision can be prescribed for each eye for regular use.

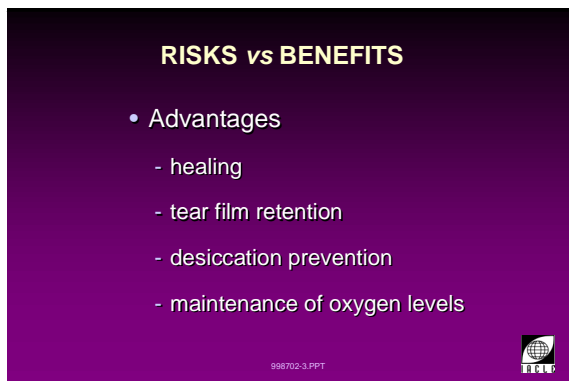
Often, therapeutic lenses have to be fitted with more than one indication presenting (after Veys *et al.*, 2001). The practitioner must seek to address all issues if possible.

Astin (1991) recommends the following be noted when fitting therapeutic contact lenses:

- Use clean, lint-free hands.
- Avoid metal fragments when uncapping crimped-lid lens vials and when removing the lens from such vials (patient's reduced corneal sensitivity may not indicate a problem initially).
- If eye is perforated or viral transmission is a possibility, sterile procedures should be followed, e.g. use surgical swabs and sterile, non-powdered surgical gloves).
- Avoid preserved lens care products and medications because they might have an affinity for lens materials.
- Use high water lenses:
  - for fragile epithelia;
  - for EW;
  - to reduce risk of vascularization and corneal oedema (siloxane hydrogels are now preferred but are not always suitable).
- If very thin lenses are used (difficult to see *in situ*), inform other practitioners who may deal with the patient at a later stage.
- If keratometer mires are distorted or unclear, measure the fellow eye as a starting point for initial lens selection.
- In cases of corneal grafting or limbal inflammation, consider lenses with TDs of 14.5 to 16 mm.
- In cases of disturbed tissue, including beyond the limbus, consider lenses with TDs of 18 to 20 mm.
- Use tear supplements to lubricate the eyes and discourage lens deposits.
- Damaged or deposited lenses should be replaced without hesitation.



9



**RISKS vs BENEFITS**

- Advantages
  - healing
  - tear film retention
  - desiccation prevention
  - maintenance of oxygen levels

998702-3.PPT

8L7998702-3

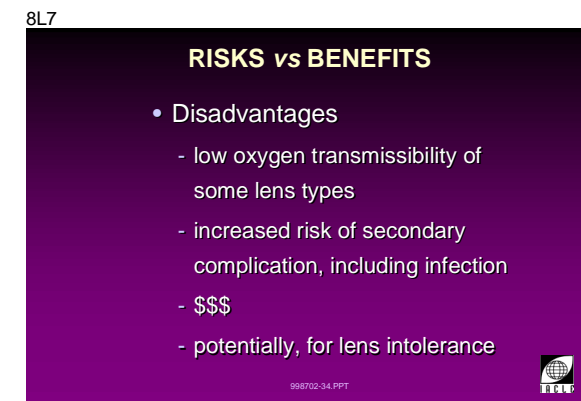
**Risks versus Benefits**

**Advantages**

Some advantages of fitting a therapeutic contact lens include:

- Aid in healing of epithelial defects by protecting migrating surface cells from the shearing forces of the lids during a blink.
- Retaining/maintaining the tear layer on the cornea. This occurs by preventing evaporation as well as by acting as a water reservoir.
- Siloxane hydrogel and elastomer lenses maintain oxygen levels at the cornea that virtually prevent hypoxia and oedema.

10



**RISKS vs BENEFITS**

- Disadvantages
  - low oxygen transmissibility of some lens types
  - increased risk of secondary complication, including infection
  - \$\$\$
  - potentially, for lens intolerance

998702-34.PPT

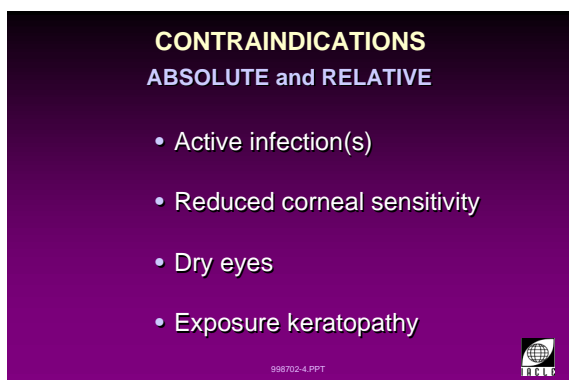
998702-34

**Disadvantages**

Some disadvantages of fitting a therapeutic contact lens include:

- Low oxygen transmissible lenses can induce corneal oedema due to hypoxia. Since therapeutic lenses usually remain on the eye on an EW basis, oxygen transmissibility should be maximized to reduce the risk of corneal oedema.
- Siloxane elastomer lenses are usually slightly more expensive, may not be as comfortable as a custom hydrogel lens because they do not offer the option of a larger diameter if required, and may have problems with surface wettability.
- Tear stagnation under hydrogel lenses decreases the flushing and cleansing action of each blink (Thoft, 1983).

11



**CONTRAINDICATIONS**  
ABSOLUTE and RELATIVE

- Active infection(s)
- Reduced corneal sensitivity
- Dry eyes
- Exposure keratopathy

998702-4.PPT

8L7998702-4

**Contraindications**

Contraindications are either absolute, where a lens should not be fitted, or relative, where lenses should be worn only with careful after-care and management. Regardless of the foregoing, any patient with the need to wear a bandage contact lens probably has a compromised eye and would be predisposed to potentially major infectious complications. Therefore, all patients wearing such lenses should be fitted and monitored very carefully.

Bandage lenses should not be fitted to an eye with an active infection unless the lens is to be worn for drug delivery or to promote healing as an adjunct to the medical treatment already in place.

Hypoaesthetic corneas (i.e. herpes simplex keratitis) or anaesthetized corneas (i.e. neuroparalytic keratitis) would be fitted with bandage lenses to protect the cornea from harm due to persistent epithelial defects. However, these patients should only be fitted with extreme care and diligent after-care since they may not be able to sense the discomfort or pain of a problem such as a corneal ulcer.

Patients with dry eyes are generally not good candidates for soft lens wear unless their condition is so advanced that lenses are worn truly as a 'bandage' to protect the cornea from further exposure to the air or to control corneal filaments and the discomfort associated with them.

Patients with exposure keratopathy will probably not do well with hydrogel lenses because the lenses succumb to the effects of exposure and consequent dehydration.

Patients who cannot attend regular after-care appointments are not good candidates for bandage lenses.

### III Specific Indications for Therapeutic Contact Lens Wear

12

**SPECIFIC INDICATIONS**

- Protection
- Relief from pain
- Stimulation of healing

998702-5.PPT



8L7998702-5

#### Corneal Oedema, Bullous Keratopathy (BK)

Bullae form at the corneal surface in advanced corneal oedema (slide 14) and, as the bullae rupture (slide 15), the patient experiences significant pain. Other common causes of BK are pseudophakia (in which the corneal endothelium is damaged during cataract surgery, an increasingly uncommon complication) and Fuchs' dystrophy.


Aphakic BK was one of the first diseases in which a bandage contact lens was employed to manage the pain resulting from exposed corneal nerve endings. Aphakic BK is not a common problem now because the need to protect the endothelium during cataract surgical procedures is better understood.

13

**BULLOUS KERATOPATHY**

- Bullae accompanying a very significant level of corneal oedema
- Common causes
  - pseudophakia
  - Fuchs' dystrophy
- Bandage lenses prevent pain caused by exposed corneal nerve endings

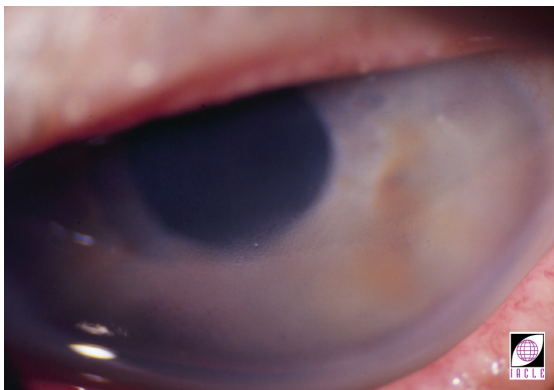
998702-6.PPT



8L7998702-6

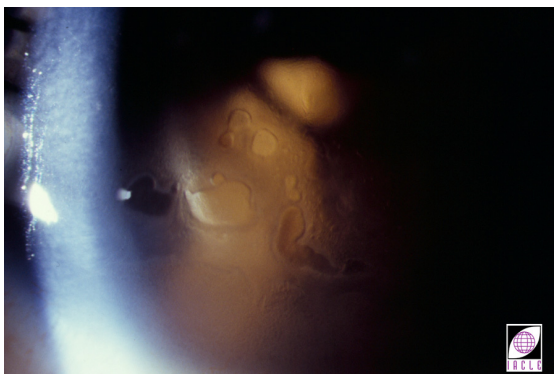
Use of siloxane hydrogel or mid-water content hydrogel lenses is recommended. Usually, these lenses are used on an EW basis and are replaced regularly. If the bullae subside, lens wear should be discontinued.

14



8L70515-97

15




8L0144-95

16

**CORNEAL ABRASION**

- Disruption of basement membrane can inhibit cell adhesion
- Management
  - cycloplegia
  - antibiotics
  - bandage lenses

998702-9.PPT



8L7998702-9

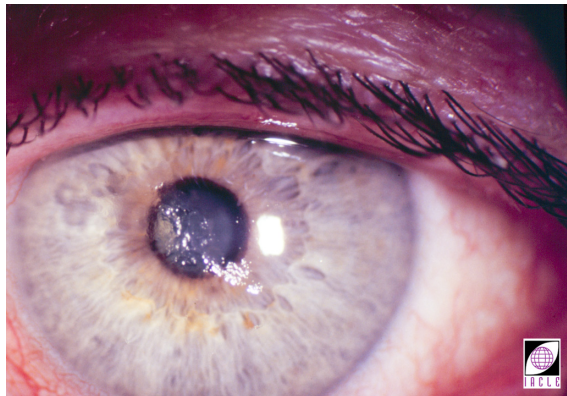
**Corneal Abrasion**

Corneal abrasions may be classified generally as mild, moderate, or severe. The management of mild to moderate corneal abrasions would likely include an oral analgesic, cool compress, cycloplegia, prophylactic antibiotics, and sunglasses to minimize photophobia. This treatment should allow for complete re-epithelialization within 24 hours.

A bandage contact lens may be fitted for three reasons:

- To promote healing.
- Aid patient comfort.
- Allow for normal visual function and normal activities.

17



8L70563-94

It is also common to have the patient wear the lens until the after-care visit the following day. Most topical drops can be administered while the bandage lens is in place. An after-care visit the following day is always part of the management protocol to evaluate the eye and determine if, and what, further treatment may be necessary.

Mild abrasions can heal sufficiently within a 24-hour period while moderate abrasions may require 2 to 3 days for complete healing and resolution.


With severe corneal abrasions, the basement membrane may be disrupted. This may inhibit epithelial cell adhesion (slide 17), leading to recurrent corneal erosions. In this case, a lens may be fitted and the patient managed as discussed above in relation to recurrent corneal erosion management.

18

**RECURRENT CORNEAL EROSION  
AETIOLOGY**

- Corneal dystrophies
- Oedema
- Post-vitreotomy in diabetic patients
- Idiopathic causes

998702-7.PPT



8L7998702-7

**Recurrent Corneal Erosion**

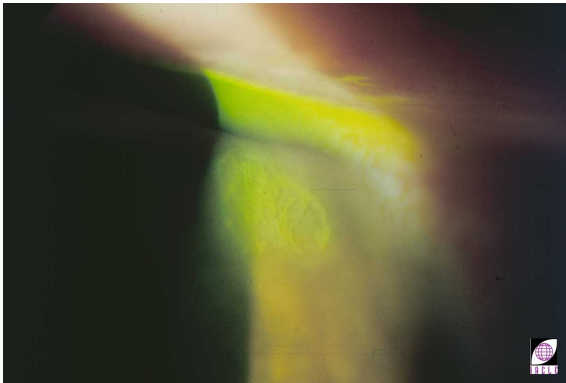
The aetiology of recurrent corneal epithelial erosion (slide 19) may be:

- Dystrophies involving the epithelial basement membrane (basal lamina) and Bowman's layer.
- Corneal trauma.
- Post-vitreotomy epithelial sloughing in patients with diabetes mellitus.
- Idiopathic.

The hallmark of the classic recurrent corneal erosion is the timing of the episode. It typically occurs in the middle of the night with the patient suddenly awakening because of intense ocular pain.

Initial treatment strategies include frequent lubrication with hypertonic saline drops, use of ointment at bedtime, and often a bandage lens for comfort and to protect the fragile epithelium while encouraging healing. Erosions from a dystrophy (slide 20) or idiopathic causes usually respond better to bandage lens therapy than recurrent corneal erosions that are secondary to trauma or post-surgical corneal oedema.

19



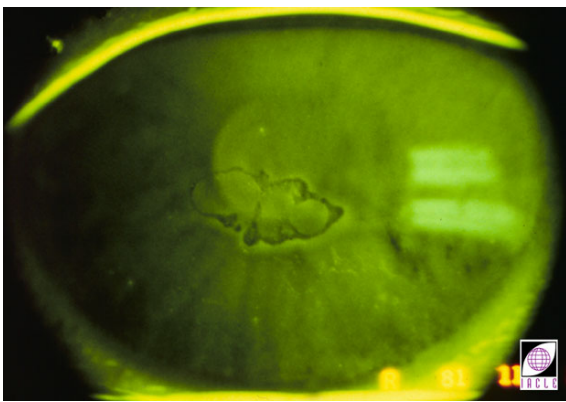
8L70220-91

A bandage lens is fitted if erosions occur on a weekly basis or more frequently. The treatment plan includes lens wear for up to 4 months while the epithelial hemidesmosomes reform and securely re-establish links with the basement membrane.

If long-term use of a bandage lens does not resolve the chronically recurrent nature of the erosions adequately, more aggressive treatment needs to be employed. In these cases consider:

- Debridement of the affected epithelium.
- Cauterization of the basement membrane.
- Stromal puncture.
- Possibly, PTK.

20



8L71104-96

A bandage lens will almost always be used after treatments involving epithelial removal. Similarly, bandage lenses are used in the short-term during recovery from routine refractive surgical procedures such as PRK and LASIK.

21

**CHEMICAL (ALKALI) INJURY**

- High pH of alkalis causes cell saponification resulting in its disruption
- Associated with epithelial cell loss
- Bandage lenses may provide comfort

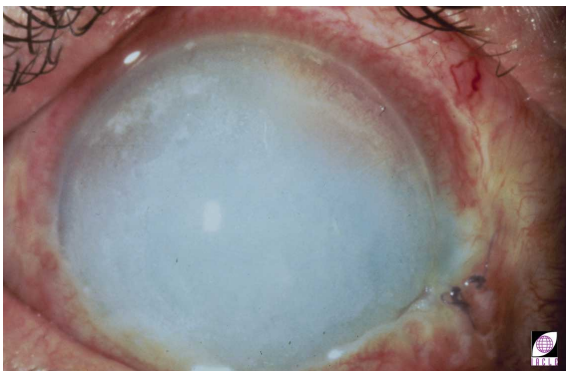8L7998702-8

**Chemical (Alkali) Injury**

Usually, initial treatment involves profuse irrigation, cycloplegia, and the application of anti-inflammatory and antibiotic agents.

Secondarily, chemical injuries are frequently associated with corneal epithelial loss. A persistent epithelial defect may respond well to the wearing of a bandage lens and in some instances patients may be more comfortable with such a lens. Slide 22 shows total opacification of the cornea with conjunctival vascularization and inflammation due to a chemical burn.

22



8L70722-95




23

**INFECTION**

- Bacterial
- Viral
- Metaherpetic
- Fungal

998702-10.PPT



8L7998702-10

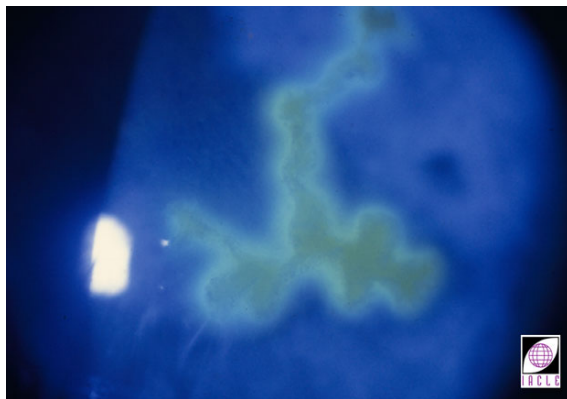
**Infection**

- Bacterial – a hydrogel lens should not be worn during active bacterial infection of the eye. It may be worn to enhance drug delivery in the management of a corneal ulcer or to encourage the healing of an ulcer after antibiotics is instituted.
- Viral (e.g. herpes simplex) – contact lens wear is rarely an adjunct to the treatment of active herpes simplex virus infection (slide 24). However, hydrogel lenses can be worn to manage a ‘trophic’ or ‘metaherpetic’ condition, in which the corneal epithelium breaks down (despite no virus being present) subsequent to an active herpes infection. It is often associated with epithelial erosion and always occurs over an old and inactive scar, especially a herpes simplex infection (hence the term ‘metaherpes’) (Lamberts, 1988). The pattern is no longer dendritic (slide 24 is a dendritic form) and, obviously, there is no response to antiviral medical therapy. This condition often leads to a persistent epithelial defect that is managed with the use of a bandage lens for improved patient comfort and perhaps enhancement of the healing process.
- Fungal – similar to a bacterial infection, a hydrogel lens should not be worn during active fungal infection of the eye but may be worn to enhance drug delivery in the management of a corneal ulcer or to encourage the healing of an ulcer after antibiotics is instituted.

Microbial infections may also be a consequence of the wearing of a therapeutic contact lens.

If a tissue adhesive is required, a contact lens can be used as a bandage over the treated eye.

24




8L71859-93

25

**DRY EYE SYNDROME**  
**AETIOLOGIES**

- Keratoconjunctivitis sicca
  - aqueous deficiency
- Sjögren’s syndrome
  - aqueous deficiency
- Stevens-Johnson syndrome
  - mucus deficiency
- Ocular pemphigoid
  - mucus deficiency

998702-11.PPT



8L7998702-11

**Dry Eye Syndrome**

Causes include:

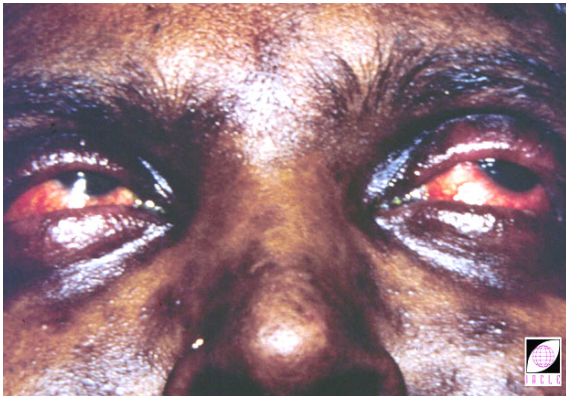- KeratoConjunctivitis Sicca (aqueous deficiency).
- Sjögren’s syndrome (aqueous deficiency).
- Ocular pemphigoid (mucus deficiency).
- Stevens-Johnson syndrome (mucus deficiency, slides 26, 27).

Treatments such as ocular lubricants, ointments, moisture-chamber spectacles, and punctal occlusion should be attempted before considering bandage contact lens therapy for the dry eye patient. However, if the patient’s condition is so advanced that lenses are worn truly as a ‘bandage’ to protect the cornea from exposure to the air or to control corneal filaments and the discomfort associated with them, then therapeutic contact lens wear may be considered.

Because of the hydrophilic nature of hydrogel lenses, a dry ocular surface will rarely, if ever, be



26



8L70306-95

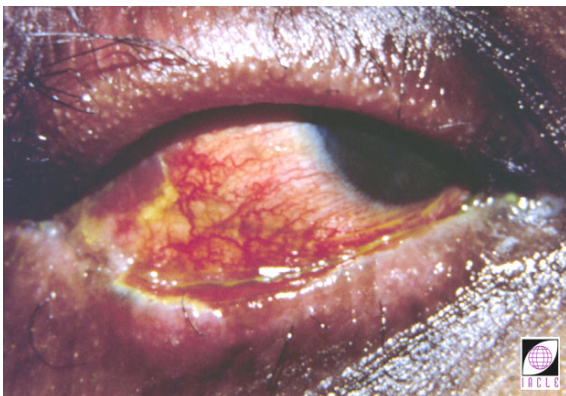
able to support adequately the thirsty nature of the polymer of the soft lens (i.e. evaporation of water from and via the lens to the atmosphere). Consequently, the lenses can dehydrate significantly on the eye, may deposit more easily, and ocular infection potential may be enhanced. Lubricating drops for use with contact lenses may be used to maintain lens hydration. However, the positive effect is short-lived requiring the very frequent instillation of drops to maintain lens-wearing comfort. Punctal occlusion may improve the retention of the patient's available tears on the ocular surface, and help maintain the hydration of the lens.

The choice of lens water content for dry eye patients is often debated. One opinion is that a higher water content hydrogel lens should be worn because the lens has more moisture to lose and may be greatly affected by dehydration. The other opinion is that a lower water content lens should be fitted in a thicker design. This lens would present a greater barrier (and possibly better bandaging effect) to lens dehydration and may be more comfortable for the patient, albeit with lower oxygen transmissibility. There is no clear direction on which of these is the best choice and it may be highly patient-dependent.

Scleral lenses (in a gas permeable material) may be considered as they have no significant water content (therefore no water to lose) and they may also serve as an on-eye moisture chamber to some extent.

For more details on dry eye see Module 7, Lecture 7.4: **Diagnosis and Management of Dry Eye in Contact Lens Wear**

27




8L70301-95

28

NEUROPARALYTIC KERATITIS

- Caused by facial nerve (N7) palsy and corneal exposure
- Requires a large TD hydrogel lens
  - frequent instillation of artificial tears
- Lateral tarsorrhaphy may be required

998702-12.PPT



8L7998702-12

### Neuroparalytic Keratitis


This condition is caused by palsy of the facial nerve (N7) and is a consequence of exposure of the cornea to the environment leading to corneal desiccation. A hydrogel lens will dehydrate significantly on the eye and requires almost constant instillation of artificial tears during the day with the lids taped shut at night. A large diameter lens should be fitted to ensure some of the lens rests under the upper and lower eyelids. A lateral tarsorrhaphy may be required.

29

**NEUROTROPHIC KERATITIS**

- Caused by lesions of the trigeminal nerve (N5) accompanied by corneal epithelial breakdown
- Use low water content hydrogel lens
- Requires good patient education and after-care
- Lateral tarsorrhaphy may be required

998702-13.PPT



8L7998702-13

**Neurotrophic Keratitis**


Neurotrophic keratitis is caused by lesions of the first division of the trigeminal nerve (N5) that lead to an anaesthetized cornea with epithelial breakdown. A low water content hydrogel lens may be fitted with good patient education and careful monitoring. A lateral tarsorrhaphy may be required.

30

**THYGESON'S SUPERFICIAL PUNCTATE KERATITIS**

- Chronic and recurrent bilateral disorder
- Characterized by discrete and elevated epithelial opacities
- Treatment
  - lubrication
  - steroids
- Bandage lenses alleviate foreign body sensation, tearing, and photophobia

998702-14.PPT



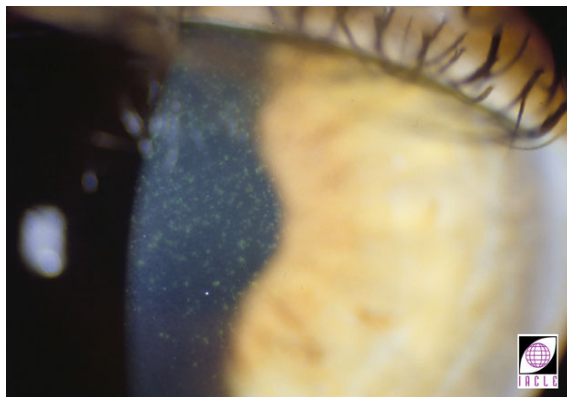
8L7998702-14

**Thygeson's Superficial Punctate Keratitis**

Frequently, Thygeson's SPK is a chronic corneal disease for which steroids are often part of the treatment, especially during periods of exacerbation that are characterized by discrete and elevated oval epithelial opacities (slide 31) and punctate staining (slide 32).

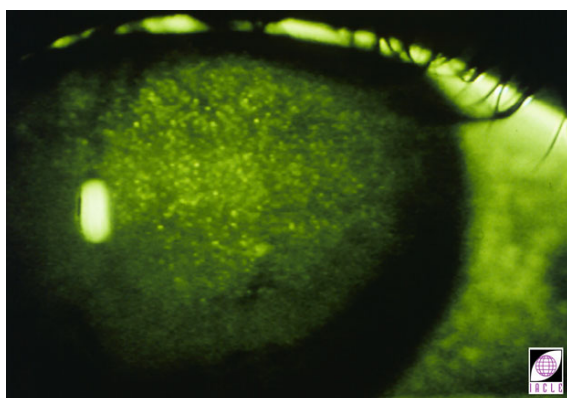
The foreign body sensation, tearing, and photophobia of Thygeson's SPK may be alleviated during these active periods (that can last for weeks at a time) by the wearing of a bandage contact lens.

31



8L72927-93

32




8L72053-95

33

**OTHER PERSISTENT EPITHELIAL DEFECTS**

- Radiation keratitis
- Diabetes
  - particularly after epithelial debridement
- Topical anaesthetic abuse
- Herpes simplex
- VKC ulcer (often shield-shaped)

998702-15.PPT



8L7998702-15

**Other Persistent Epithelial Defects**

Other causes of persistent epithelial defects that can be managed by the wearing of hydrogel bandage lenses for improved patient comfort and promotion of healing include:

- Radiation keratitis.
- Diabetes (particularly after debridement).
- Topical anaesthetic abuse.
- Herpes simplex keratitis (slide 24 is a high-magnification image of a dendritic ulcer).
- The shield-shaped ulcers of Vernal KeratoConjunctivitis.

The clinical management for all of the above generally follows the same clinical protocol as presented earlier for mild to moderate corneal abrasions.

Most herpes patients approach their physician because neuralgia is the first symptom, and skin lesions are the first signs of the infection. The management for herpes involves prompt systemic treatment with antivirals and perhaps corticosteroids.

In the shield-shaped ulcers of Vernal KeratoConjunctivitis, a bandage contact lens not only mechanically protects the affected cornea from the large papillae of the tarsal conjunctiva but also promotes epithelial healing. However, this approach alone is insufficient and definitive treatment of the Vernal KeratoConjunctivitis itself must be instituted in conjunction with the bandage contact lens.


When the eyelids and cornea are affected, patient management can often be a cooperative effort between the general medical practitioner and the eye-care practitioner. Ocular treatment may include an erythromycin ointment and perhaps a topical steroid. If herpes keratitis is symptomatic and severe, a bandage lens may be prescribed with the usual goals of enhancing patient comfort and promoting healing.

34

**FILAMENTARY KERATITIS**  
**AETIOLOGY**

- Idiopathic keratitis sicca
- Superior Limbic Keratitis (SLK)
- Corneal abrasion(s)
- Ocular surgery
- Viral infection

998702-16.PPT

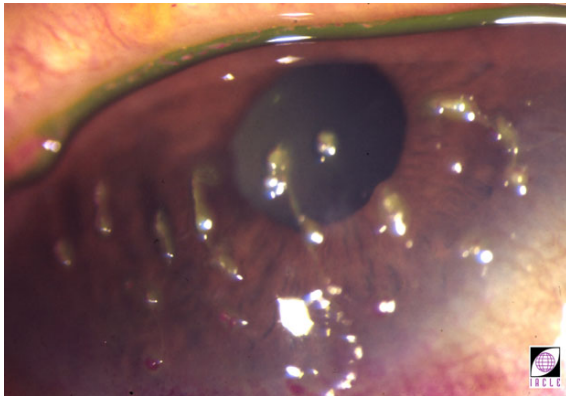


8L7998702-16

**Filamentary Keratitis**

The filaments seen in this condition are strands of mucus that adhere to small breaks in the corneal epithelium. These strands are covered with viable epithelial cells (slide 35) and can be associated with any process that damages the epithelium including KeratoConjunctivitis Sicca, superior limbic keratitis, recurrent corneal erosions, corneal abrasions, corneal oedema, ocular surgery, and viral infection (after John *et al.*, 1994). Characteristically, the filaments move freely at one end and are attached to the cornea at the other. Mucus strands on the other hand float about freely and demonstrate no such attachment.

35



8L72012-93

Filaments are painful because the corneal nerves in the epithelium are stimulated (pulled by the deformation of the epithelium adjacent to the attachment) with each blink and eye movement. A bandage soft lens not only relieves the pain immediately but the filaments disappear within hours.

The chances of a dry eye patient with filamentary keratitis being able to wear a hydrogel bandage lens for the management of the filaments may be improved by the insertion of punctal plugs, i.e. punctal occlusion.

36

**STROMAL MELT**

- Caused by collagenase dissolving the stromal lamellae
- Bandage contact lenses aid in the healing process

988702-17.PPT



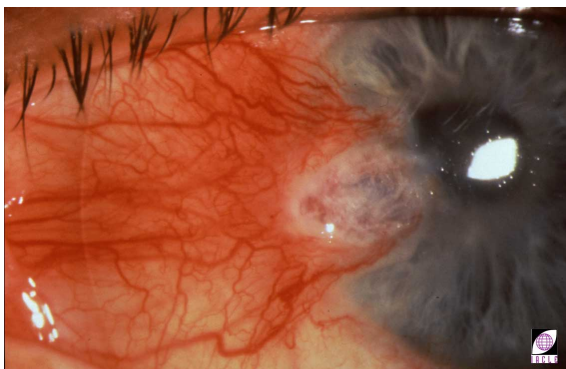8L7998702-17

**Stromal Melt**

The corneal stroma will ‘melt away’ if a persistent epithelial defect is allowed to remain unhealed for a long period of time. The mechanism is thought to be collagenase dissolving the stromal lamellae. Slide 37 shows corneal melting after a perforating injury. The loss of sutures and wound leakage was accompanied by gross conjunctival injection (as seen under medium magnification with diffuse illumination).

While bandage contact lenses have a positive effect on the healing of persistent epithelial defects, they are not an appropriate treatment for stromal melts once collagenolysis has started.

37



8L70721-95

Bandage contact lenses are an appropriate treatment of persistent epithelial defects and may help prevent a melt commencing. However, once a melt has started, bandage contact lenses are not an appropriate treatment by themselves. Furthermore, bandage contact lenses can be used over a tissue adhesive, the definitive treatment for stromal melts.


Similarly, other conditions such as Mooren's ulcer and peripheral rheumatoid melting are not helped by bandage contact lenses and these conditions require more aggressive treatment, e.g. tissue adhesives.

38

**CORNEAL PERFORATION AND PENETRATING CORNEAL WOUNDS**

- Bandage lenses
  - can be used to ‘seal’ corneal perforations and lacerations
- Used after application of surgical glue or corneal suturing

988702-18.PPT



8L7998702-18

**Corneal Perforation/Penetrating Corneal Wounds**

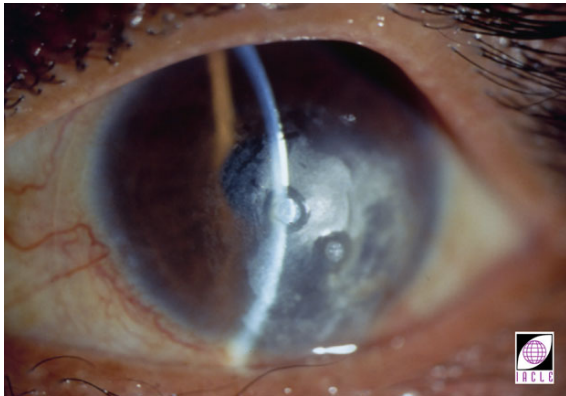
Although surgical glue or suturing is the usual treatment of choice for repairing such defects, a bandage lens may be used to ‘seal’ small corneal perforations or lacerations. A bandage lens may be used after gluing (slide 39) or suturing of the defect to increase patient comfort by smoothing over the rough surface of the suture or glue.

Slide 40 shows a perforating corneal laceration caused by a metal foreign body. A pressure bandage was applied to assist healing.

Therapeutic contact lenses can also be used to maintain wound edges in close apposition (Ehrlich, 2001).

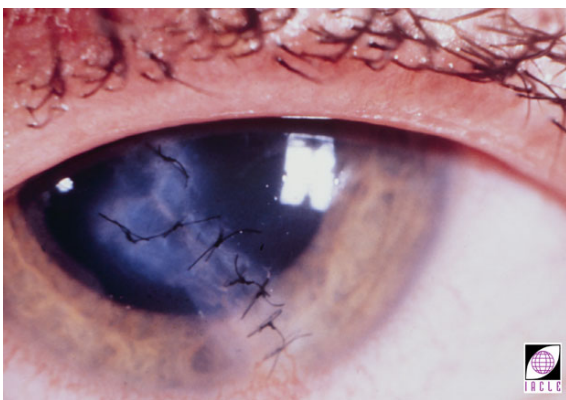


39



8L72138-95

40




8L7382-95

41

**ENTROPION AND TRICHIASIS**

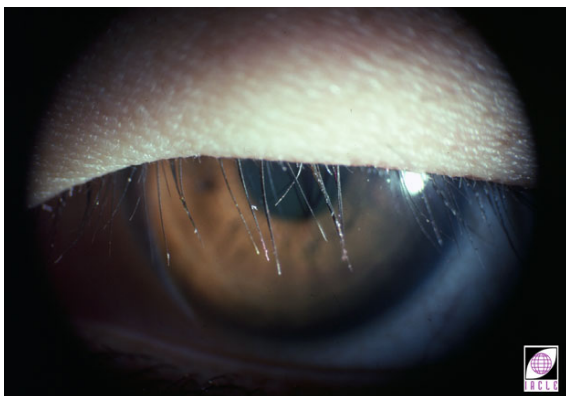
- Turning in of lids and/or eyelashes
  - can abrade cornea/anterior eye
  - can cause pain
- Common in cases of:
  - entropion
  - ocular pemphigoid
  - Stevens-Johnson syndrome
  - lid trauma
  - chronic blepharitis
- Bandage contact lenses protect the cornea from irritation

998702-19.PPT



8L7998702-19

42



8L7987-91

### Entropion/Trichiasis

Trichiasis is an abnormal turning in of the eyelashes and this may be quite painful. Trichiasis is related to such cases as ocular pemphigoid, Stevens-Johnson syndrome, lid trauma and chronic blepharitis. Entropion has normal positioning of the eyelashes but the eyelid itself turns inward, directing the lashes inward toward the cornea (slide 42).

A characteristic of trichiasis and entropion is that the patient's eyelashes contact, and may abrade, the anterior eye, especially the cornea.

Entropion is treated by surgical means and trichiasis is treated by ablation of the aberrant lashes.

A bandage contact lens may be used for either condition to protect the cornea from the eyelashes. Relief from irritation by the lashes is immediate and complete while the lens is worn and continues until the primary reason for the problem is resolved. The upper lid can easily roll up a thin lens and, therefore, a relatively thick hydrogel lens is recommended. RGP lenses can alleviate trichiasis as long as the lens diameter is sufficiently large to protect the threatened corneal area.

43

**THERAPEUTIC CONTACT LENSES  
MISCELLANEOUS CONDITIONS**

Lamberts, 1988

- Salzmann's Nodular Degeneration
  - usually after a severe keratitis
    - most often phlyctenular keratitis
  - or after other types of keratitis
    - vernal conjunctivitis
    - measles
    - herpes simplex

998702-40.PPT



8L7998702-40

**Miscellaneous Conditions**

Another less common application of bandage contact lenses is as a mount for a ptosis crutch or prop (Ehrlich, 2001). Frequently, a form of scleral lens is used as the mounting 'platform' for a loop, ledge, or step intended to hold the upper eyelid up. Indications for a crutch include ocular myopathy, myasthenia gravis, eyelid trauma, and neurological conditions such as 3<sup>rd</sup> nerve palsy.

Other conditions are listed in the slide opposite.



## IV Post-Operative Uses for Therapeutic Hydrogel Contact Lenses

44

### POSTOPERATIVE APPLICATIONS

- Postoperative conditions in which therapeutic lenses may be useful:
  - vitrectomy
  - epikeratophakia
  - cataract surgery
  - epithelial debridement
  - wound leaks
  - protection from sutures
  - surgical glue application

898702-20.PPT



8L7998702-20

### Post-Operative Healing

Surgery of the cornea and other ocular structures such as epikeratophakia, cataract surgery, corneal epithelial debridement, etc. requires a period of healing to allow time for cell growth and adhesion. Therapeutic contact lenses aid the healing process by protecting new corneal cells *in situ* from the action of blinking eyelids. This allows cellular adhesion and tissue relationships to develop normally.

Suture knots from surgery can also be a source of irritation of the lids. Therapeutic lenses can provide a smooth interface between the cornea and lids.

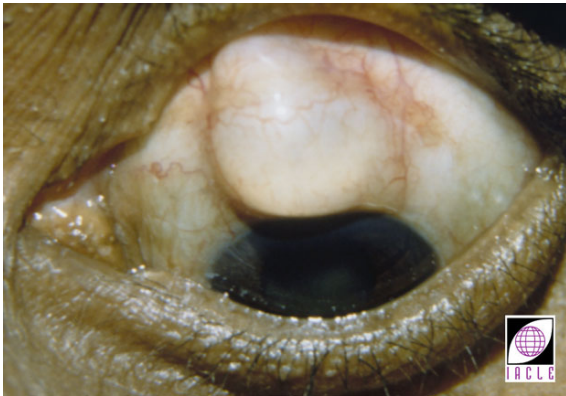### Photo-Refractive Keratectomy (PRK)

Photoablation using an excimer LASER (emitting high-energy, UV radiation) removes several microns of corneal tissue (the epithelium, Bowman's layer, and superficial anterior stroma) within a controlled, circumscribed area. Post-surgical management of PRK routinely involves using a disposable contact lens as a bandage lens for at least 24 hours post-operatively to assist the healing process and corneal re-epithelialization.

### Post-Operative Wound Leakage

Penetrating ocular injuries or full thickness incisions during PK require tight suturing to prevent leakage of ocular contents. Should the tight suturing be inadequate, leakage leading to lowered IOP and a shallow anterior chamber can result. Such wound leakage is evidenced by dilution (and streaming) of fluorescein applied to the area of leakage (the so-called Seidel's test). Any leakage from a filtering bleb (slide 45) can be arrested by the use of a pressure bandage in the form of a large diameter hydrogel contact lens covering the wound.

45



8L7315-95

46

### PROTECTION FROM SUTURES

- Suture materials can cause irritation during blinking and eye movement
- Bandage contact lenses provide comfort and protect the conjunctiva

898702-21.PPT



8L7998702-21

### Protection From Lid Sutures

Surgical procedures requiring full-thickness suturing of the eyelid, e.g. a lid biopsy or a repair of a lid laceration, often leave suture material in apposition to the cornea. The irritation and abrasion that follow are often exaggerated by the greater blink frequency and tighter lid closures stimulated by the sutures. Normal eye movements can contribute to the abrasion. A bandage contact lens can protect the cornea from these insults until the sutures are removed.

After a corneal transplant, a bandage lens may be helpful in restoring useful vision, especially if the patient is monocular. Such a lens also improves comfort while protecting the conjunctiva from the multiple nylon corneal sutures, and helps heal any persistent epithelial defect(s).

47

**CORNEAL GLUE**

- N-butyl cyanoacrylate
- Used to seal corneal perforations
- Bandage lenses protect the palpebral conjunctiva from the rough glue surface

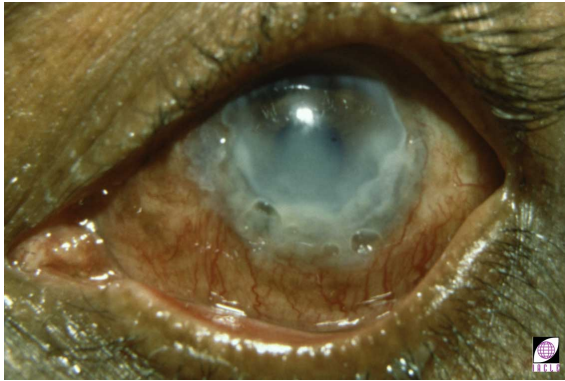
998702-22.PPT 

8L7998702-22

**Corneal Glue**

Corneal glue such as *n-butyl cyanoacrylate* may be used to seal small corneal perforations or be placed on a 'sterile' corneal ulcer to prevent perforation. Due to the rough surface of the glue once polymerized, irritation and abrasion of the palpebral conjunctiva occurs with blinking and eye movements. A bandage contact lens can protect the palpebral conjunctiva from this insult until the glue eventually falls off or is removed surgically. Slide 48 shows a Mooren's ulcer that has been glued and covered by a bandage lens.

48



8L70297-95

## V Topical Drug Delivery

49

### TOPICAL DRUG DELIVERY

- Bandage lenses ↑ drug contact time
- Gels, solutions, etc. that can stain contact lenses should not be used
  - remove the lens(es) first if necessary

998702-23.PPT



8L7998702-23

### Topical Drug Delivery

By means of standard hydrogel, collagen, or siloxane hydrogel contact lens, drug delivery and drug effectiveness can be enhanced by prolongation of the contact between the drug and the ocular/corneal surface. The uptake and release of various drugs is quite variable and depends on the lens polymer, its water content, the physicochemical characteristics of the drug and its vehicle, and other factors. Consequently, the dosage delivered to the eye with a lens *in situ* is usually difficult to predict accurately. Drug-impregnated collagen shields/lenses can also be used for topical drug delivery.

Unfortunately, prolonged contact times with the eye, while useful therapeutically, also expose the eye to the potentially adverse effects of any preservatives and excipients accompanying the drug's active component(s). Potentially this can lead to a toxic keratopathy. Where available, unpreserved drops and medications should be used to minimize the potential for a toxic keratitis. With moderate to long-term use of preserved drugs with hydrogel lenses, frequent replacement of the lenses, perhaps on a daily to weekly basis, is another way to decrease the chances of a toxicity response occurring.

Gels and ointments should not be used while lenses are worn because they will foul the lens surfaces and blur vision significantly.

50

### COLLAGEN SHIELDS & LENSES

- Fabricated from porcine or bovine collagen
- Biodegradable
  - dissolve in 12–72 hours
- May be impregnated with medication
- Typically used for short-term treatment of acute conditions

998702-24.PPT



8L7998702-24

## VI Lens Selection and Design

51

### THERAPEUTIC CONTACT LENSES REQUIREMENTS

Veys et al., 2001

- High oxygen transmissibility
- Parameter range:
  - choice of BOZR
  - choice of TD
- Parameter stability
- Deposit management
- Economical

998702-38.PPT



8L7998702-38

### Lens Selection

The choice of lens type and lens design for use on a diseased eye is often based upon speculation and depends upon the specific disease in question. Typically, hydrogel lenses are the lenses of choice because their large diameter 'bandages' the entire cornea and their soft, supple nature, contribute to enhanced wearer comfort. However, hydrogel lenses dehydrate on the eye and the resulting water movement across the lens may result in drawing water from an oedematous cornea. This water movement may also challenge an eye that is already tending to be 'dry'.

Additionally, the relatively low oxygen permeability (Dk) of common hydrogel lens materials may induce corneal oedema if the lenses are not sufficiently thin. Often, a mid-water content (approximately 50 to 60% water) disposable hydrogel lens may not only be a good choice for parameter, design, and comfort considerations but also because it allows frequent lens replacement at minimum cost.

Siloxane hydrogel lenses provide the practitioner with an opportunity to fit a therapeutic lens that has very high oxygen transmissibility.

Scleral lenses (slide 53) now available in oxygen-permeable materials, may be the most durable, inert and optically advantageous lens for some patients requiring vision correction, such as those with corneal hydrops or distorted corneas following trauma.

RGP lenses, due largely to their small diameter, are only rarely considered for use as bandage or therapeutic lenses.

In addition to their therapeutic drug applications, collagen shields/lenses may also be used for bandage purposes.

52

### LENS SELECTION

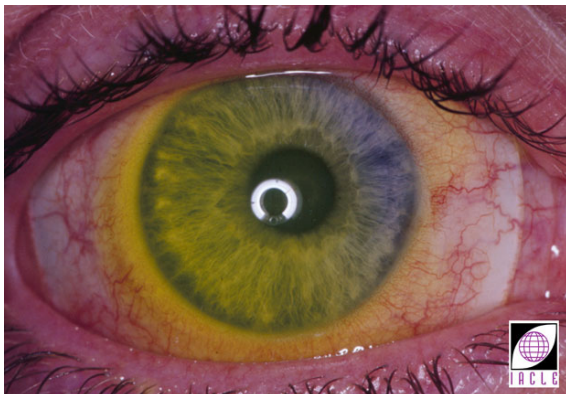
- Selection based on type of disorder
- Hydrogel lenses
  - water content considerations
    - e.g. pervaporation staining
  - oxygen transmissibility
- Disposables
- Scleral lenses

998702-25.PPT



8L7998702-25

53




8L72077-95

54

**LENS DESIGN**

- May need custom designs in some cases
- Large TD
- Maximum oxygen transmissibility
- Ring designs
  - prevent tissue adhesion

998702-26.PPT



8L7998702-26

**Lens Design**

Hydrogel lenses are usually fitted with a large diameter (TDs of 14.0 to 15.0 mm) and a back surface curvature (BOZR) that together provide for moderate lens movement, corneal coverage, and good patient comfort. Occasionally a bigger lens with a diameter as large as 20 mm may be required for protection of areas beyond the limbus, e.g. control of wound leaks or protection from proud sutures.

A lens that is too loose and moves excessively may be uncomfortable and can lead to mechanical abrading of the underlying corneal epithelium. Alternatively, a lens that is too tight and has too little movement may be comfortable initially but may become less comfortable as wearing time increases. A tight lens may also lead to a red-eye inflammatory response to cellular debris and corneal metabolic waste trapped under the lens. A compromised eye may also lead to an infection.

Since therapeutic lenses usually remain on the eye on an EW basis, oxygen transmissibility should be maximized to minimize corneal oedema.

Scleral lenses are approximately 25 mm in diameter and probably should incorporate at least one fenestration to assist tear exchange.


Sometimes a scleral ring is called for, e.g. patients with symblepharon. Scleral rings have no central portion. This allows the cornea to remain uncovered and to function normally.

55

**LENS FITTING CONSIDERATIONS**

- Adequate movement & centration
- Comfortable
- Parameter stability
- Deposit resistance
- Replacement rate
- Cost to the patient

998702-27.PPT



8L7998702-27

**Lens Fitting Considerations**

The basic fitting criteria for hydrogel bandage/therapeutic lenses are the same as with any other hydrogel lens fitting:

- Objectively, the lenses must centre well and move adequately.
- Subjectively, the patient must be comfortable.
- For bandage lenses, the vision should be no worse than with no lens at all. Obviously, if better vision can be achieved, it should be pursued.

A 'one size fits all' approach to fitting should be avoided and lens design/parameters selected to optimize on-eye lens performance. Attention to detail in the fitting relationship and fitting performance may be particularly critical for the compromised eye. Abnormally-shaped or 'degenerating' eyes may lead to an unpredictable fitting relationship that cannot be fitted satisfactorily.

Build-ups of surface deposits can cause further problems in therapeutic contact lens wear, e.g. discomfort, increased movement, decentration, etc. Wherever possible, it is desirable to use lenses that are replaced frequently.

## VII After-Care of Therapeutic Contact Lenses

56

### THERAPEUTIC CONTACT LENSES AFTER-CARE

- Similar to normal EW patient follow-up
- Patient interview
- VA
- Slit-lamp examination of the lens *in situ*
- Detailed inspection of the lens *in vitro* if and when appropriate
- Ongoing follow-up via after-care visits

998702-37.PPT



8L7998702-37

Estimating the likely duration of treatment with therapeutic contact lenses is dependent on many factors, including the condition being treated, the chronicity and severity of the condition, and the individual healing response of the patient.

After-care visits should be conducted as with normal EW patients. If appropriate, after-care visits may be scheduled more often than normal.

Essential features of an after-care visit include:

- A patient interview.
- Vision testing.
- Contact lens evaluation on-eye with a slit-lamp.
- Assessment of the cornea through the contact lens.

If appropriate (see below), removal of the lens and evaluation of the cornea with sodium fluorescein.

In some circumstances, removal of the lens may disrupt the healing epithelium and the practitioner may be well advised to leave the lens undisturbed until a following evaluation.

57

### THERAPEUTIC CONTACT LENSES TREATMENT DURATION

- Short-term (<2 months) → Corneal abrasions  
Vernal keratoconjunctivitis  
Wound leakage  
Entropion  
Post-surgical surface irregularities  
Delayed corneal epithelialization
- Short to medium-term & recurrent conditions → Recurrent Corneal Erosions (RCE)  
Thygeson's SPK

998702-35.PPT



8L7998702-35

58

### THERAPEUTIC CONTACT LENSES TREATMENT DURATION

- Medium-term (2-12 months) → Bullous keratopathy,  
Corneal exposure,  
Corneal thinning disorders
- Long-term (>12 months) → Chemical burns,  
Bullous keratopathy,  
Mucous membrane pathology

998702-36.PPT



8L7998702-36



## VIII Complications Associated with Therapeutic Contact Lens Wear


59

**THERAPEUTIC CONTACT LENSES  
COMPLICATIONS** Veys et al., 2001

**Patient Related**

- Severity of pathology
- Concurrent dry eye
- Concurrent topical corticosteroids
- Poor compliance
  - ocular hygiene
  - general hygiene
- Poor general health
- Lack of motivation
- Absence of carer

998702-39.PPT



8L7998702-39


60

**THERAPEUTIC CONTACT LENSES  
COMPLICATIONS** Veys et al., 2001

**Lens Related**

- Hypoxia
  - low water
  - thick lens
- Deposition
- Mechanical insult
  - poor fit

998702-43.PPT




8L7998702-43

61

**MINOR COMPLICATIONS**

- Lens intolerance
- Redness and irritation
- Corneal oedema
- Vascularization
- Lens deposits

998702-28.PPT



8L7998702-28

### Minor Complications

The same complications that can occur with hydrogel lenses worn on healthy eyes can also occur with bandage lenses. Corneal infection is of particular concern in cases of therapeutic contact lens wear because the epithelium is already compromised and the risks of infection are probably greater.

For a full discussion of complications associated with contact lens wear refer to Module 7, Lectures 7.2 and 7.3.

Management of complications depends on their severity. Examples of minor complications include:

- Lens intolerance – this is reported frequently as dryness or irritation. Intolerance encompasses all subjective symptoms that consistently bother the patient.
- Mild inflammation (Asymptomatic corneal infiltrates) – this is a mild reaction, occurring typically with diffuse or isolated focal infiltrates that may be accompanied by slight to moderate ocular redness. Usually, the cornea is intact and the patient remains comfortable. Increased caution must be exercised whenever asymptomatic infiltrates occur in wearers using therapeutic contact lenses.
- Redness – bulbar conjunctival injection can be induced by contact lens wear. Significant injection should be regarded as unacceptable and the lens type, fit, care regimen, and wear schedule should be re-evaluated.
- Corneal vascularization – mild corneal vascularization may be an expected consequence of long-term, low oxygen transmissibility, soft lens wear, especially in an already compromised cornea. While some encroachment (up to 1 to 1.5 mm) may be acceptable, vascularization should be discouraged by optimizing oxygen transmission and assuring free lens movement without limbal impingement (conjunctival or vascular).
- Lens deposits – contact lenses worn by 'diseased' or compromised eyes with a challenged lacrimal system can develop deposits very rapidly. A lens with surface deposits generally has reduced wettability and may become a mechanical and immunological problem to the eye. More frequent lens replacement, along with an enhanced cleaning regimen, should be considered.

62

### MAJOR COMPLICATIONS

- Corneal oedema
- Extensive vascularization
- Sterile infiltrates
- Microbial infections
- Hypopyon



998702-29.PPT

8L7998702-29

### Major Complications

- Acute corneal oedema – should the cornea swell to the extent that striae and folds are evident in the posterior stroma (see Module 7, Lecture 7.2), the patient will usually experience cloudy vision and perhaps some mild to moderate discomfort. These are indicative of inadequate lens oxygen transmissibility and/or the lens being too tight. EW should be avoided and a lens with a higher transmissibility should be fitted.
- Advanced or advancing corneal vascularization – any vascularization greater than 1.5 mm should be a cause for concern, especially if vessel(s) do not loop back and the corneal stroma, adjacent to the tip of the encroaching vessels, is hazy (i.e. a sign of oedema with a loss of tissue compactness). When this area is viewed in retro-illumination, the appearance is similar to that of wet, finely ground glass. The lens should be refitted to promote greater oxygen supply to the cornea.
- Corneal infection – contact lens induced peripheral ulcer, contact lens induced acute red eye and infiltrative keratitis may be pre-cursors to microbial keratitis (MK) and should be managed accordingly. Because of the potential for infection, prophylactic antibiotics may, in some cases, be used during therapeutic contact lens wear to minimize the chances of an ocular infection. However, MK can still occur in patients wearing bandage lenses who are being treated concurrently with prophylactic antibiotics. Chances of MK are increased in an already compromised eye, particularly in EW. Optimal fitting and patient education are essential to minimizing the chances of infection. As in all contact lens cases, prompt evaluation and appropriate treatment are essential to the management of corneal infection.

 **References**

- Acheson JF, et al. (1987). *Use of soft contact lenses in an eye casualty department for the primary treatment of traumatic corneal abrasions*. Br J Ophthalmol. 71: 285 – 289.
- Ajamian PC, Winski F (1990). *The management of filamentary keratitis and dry eye using bandage contact lenses and punctal occlusion*. Clin Eye Vis Care. 2: 90 – 92.
- Aquavella JV, et al. (1987). *The effect of a collagen bandage lens on corneal wound healing: a preliminary report*. Ophthalmic Surg. 18: 570 – 573.
- Astin CLK (1989). *Therapeutic contact lenses – An overview of some lens types*. J Brit Cont Lens Assoc. 14(3): 129 – 133.
- Astin C (2001). *Clinical appraisal of therapeutic contact lenses*. J BCLA. 17: 186 – 189.
- Christie CL (1999). *Therapeutic contact lenses*. Cont Lens Ant Eye. (Suppl.). 22: S20 – S25.
- Ehrlich D (2001). *Therapeutic contact lenses*. Optician. 222(5808): 28 – 32.
- Hayworth NAS, Asbell PA (1990). *Therapeutic contact lenses*. CLAO J. 16: 137 – 142.
- Hickson SB (1997). *Contact lenses in other abnormal ocular conditions*. In: Contact Lenses 4<sup>th</sup> ed. Phillips AJ, and Speedwell L (Eds). Butterworth-Heinemann, Oxford.
- Jain MR (1988). *Drug delivery through soft contact lenses*. Br J Ophthalmol. 72: 150 – 154.
- John T, et al. (1994). *Therapeutic soft contact lenses*. In: Ruben M, and Guillon M (Eds.), *Contact Lens Practice*. Chapman & Hall, London.
- Kaufman HE (1984). *Therapeutic use of soft contact lenses*. In: *Contact Lenses: The CLAO Guide to basic Science and Clinical Practice*. Dabeszies OH (Ed.). Grune and Stratton, New York.
- Kok JHC, Visser R (1992). *Treatment of ocular surface disorders and dry eyes with high gas-permeable scleral lenses*. Cornea. 11: 518 – 522.
- Lamberts DW (1988). Chapter 23: *Therapeutic (Bandage) Contact Lenses*. In: Mandell RB (Ed.), *Contact Lens Practice* 4<sup>th</sup> ed. Charles C Thomas Publisher, Springfield. 647.
- McDermott ML, Chandler JW (1989). *Therapeutic uses of contact lenses*. Surv Ophthalmol. 33: 381 – 394.
- McMahon TT, et al. (1997). *Contact lens use after corneal trauma*. J Am Optom Assoc. 68: 215 – 224.
- Rehim MHA, Samy M (1989). *The role of therapeutic soft contact lenses in treatment of bullous keratopathy*. Cont Lens J. 17: 119 – 125.
- Rehim MHA, et al. (1990). *Management of corneal perforation by therapeutic contact lenses*. Cont Lens J. 18: 107 – 111.
- Ros FE, et al. (1991). *Bandage lenses: collagen shield vs. hydrogel lens*. CLAO J. 17: 187 – 190.
- Sawusch MR, et al. (1988). *Use of collagen corneal shields in the treatment of bacterial keratitis*. Am J Ophthalmol. 106: 279 – 281.
- Schein OD, et al. (1989). *A gas permeable scleral contact lens for visual rehabilitation*. Am J Ophthalmol. 109: 318 – 322.
- Smiddy WE, et al. (1989). *Contact lenses for visual rehabilitation after corneal laceration repair*. Ophthalmology. 96: 293 – 298.
- Smiddy WE, et al. (1990). *Therapeutic contact lenses*. Ophthalmology. 97: 291 – 295.
- Speedwell L (1991). *A review of therapeutic lenses*. Optician. 5321: 25 – 29.
- Steele C (1997). *Indications for therapeutic contact lenses*. Optometry Today. 37: 28 – 33.
- Sulewski ME, Krachmer GP, et al. (1991). *Use of disposable contact lens as a bandage contact lens*. Arch Ophthalmol. 109: 318.



Sweeney DF, Holden BA (1988). Chapter 51: *Silicone elastomers enhance corneal physiology*. In: Cavanagh HD (Ed.), *The cornea: Transactions of the World Congress on the Cornea III*. Raven Press, New York. 293 – 296.

Thoft RA (1983). Chapter 17: *Therapeutic Soft Contact Lenses*. In: Smolin G, Thoft RA (Eds.), *The Cornea: Scientific Foundations and Clinical Practice*. Little, Brown and Company, Boston. 482.

Veys J, et al. (2001). *Basic contact lens practice. Part 12 – Therapeutic contact lenses*. *Optician*. 221 (5790): 20 – 28.

Zadnik K (1990). *Post-operative use of bandage soft contact lenses*. *Contact Lens Update*. 9: 1 – 4.



# Unit 8.8

(2 Hours)

## Lecture 8.8: Tinted Contact Lenses



## **Course Overview**

### **Lecture 8.8: Tinted Contact Lenses**

- I Introduction to Tinted Contact Lenses**
- II Types of Tints**
- III Cosmetic and Therapeutic Applications of Tinted Contact Lenses**
- IV Ordering Procedures and Specifications**
- V Patient and Lens Management**

# Lecture 8.8

(2 Hours)

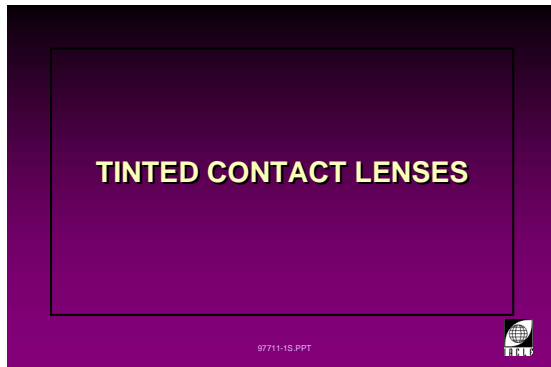
## Tinted Contact Lenses

## Table of Contents

<b>I</b>	<b>Introduction to Tinted Contact Lenses.....</b>	<b>351</b>
<b>II</b>	<b>Types of Tints.....</b>	<b>357</b>
	II.A Transparent Tints .....	360
	II.B Opaque Tints .....	368
<b>III</b>	<b>Cosmetic and Therapeutic Applications of Tinted Contact Lenses .....</b>	<b>374</b>
<b>IV</b>	<b>Ordering Procedure and Specifications.....</b>	<b>380</b>
<b>V</b>	<b>Patient and Lens Management.....</b>	<b>383</b>

## I Introduction to Tinted Contact Lenses

1



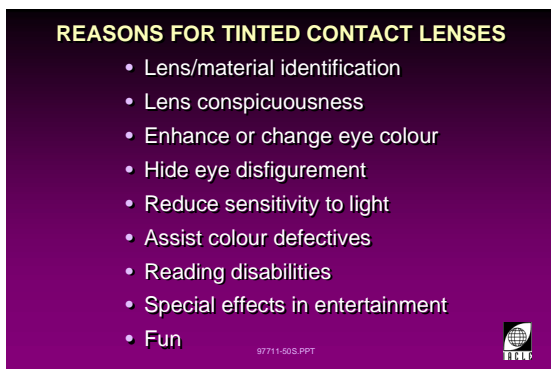8L897711-1

### Tinted Contact Lenses

Most types of tinted contact lenses currently marketed are relatively recent additions to manufacturers' ranges. However, tints for material identification and/or photosensitivity reduction were available in the era of PMMA lenses.

Early in the hydrogel era, attempts were made to tint contact lenses using food dyes, many of which were vegetable based (Newcomer and Janoff, 1977).

2




8L897711-50

### Reasons for Tinted Contact Lenses

Contact lens tinting is usually done for one or more of the following reasons:

- Lens series and/or lens material identification.
- To improve the conspicuousness of lenses as an aid to their location and handling.
- To enhance or change the eye's natural colour.
- To disguise or hide an eye disfigurement in the interests of appearance.
- To reduce sensitivity to light such as in albinism (some studies have cast doubt on the effectiveness of this approach).
- To assist colour defective wearers to differentiate between colours they routinely confuse, by inducing a brightness difference between the eyes (e.g. X-Chrom [Zeltzer, 1971] [slide 3], JLS [Schlanger, 1985]).
- As an aid to those with reading difficulties. Relatively recently claims have been made that tinted spectacles and contact lenses of selected colours may reduce reading difficulties in wearers so affected (e.g. Irlen, ColorMax and ChromaGen lenses).
- To provide special effects for the entertainment industry (cinema, television and live theatre) with transparent, opaque or even mirrored contact lenses. It is conceivable that in the era of digital special effects, the need for such lenses may decrease for applications in cinema productions.
- Fun.
  - recently, lenses incorporating a range of non-essential artwork have been marketed just for 'fun' (slide 4). They include patterns, pictures and/or words or phrases and the lenses are usually hydrogels. They have been marketed with such series names as 'wild', 'crazy', 'glamour' or 'fantasy' attached to them and are sold as a party, or an attention-getting, attraction.

3



8L82049-93

4



8L8L105-99

Unfortunately, these lenses are often sought by people unsuited to contact lenses and/or for frivolous reasons with plano prescriptions being the most common. The lenses are manufactured by reputable and experienced companies, the product in itself poses no threat to either patient or practitioner. However, their misapplication poses a problem, or even a threat, rather than an opportunity for contact lens practitioners.

- trading in 'used' contact lenses of this type has occurred. Worse, wearers have been known to swap such lenses at social functions and to encourage non-wearers to 'try' them. The potential consequences of such behaviour should be obvious to contact lens practitioners, although they may not be obvious to the average person. To address this issue, all contact lenses were declared 'medical devices' in the US in 2005 (Decorative Contact Lens Safety Bill). Several other countries are contemplating similar legislation to forestall the adverse events that are likely to follow the unrestrained and unprofessional supply of plano 'fun' lenses.

**Practitioner Knowledge of Tinted lenses**

A range of tint types and colours is used in the manufacture of tinted lens. Practitioners should understand the following:

- Different types of tints available.
- Manufacturing processes in current use.
- Applications of each type.
- Potential difficulties that may arise when inappropriate lens care products are applied.
- Potential adverse effects on corneal physiology.

Most tinted contact lenses that are made for purposes other than lens localization or identification are soft (hydrogel) lenses. Hydrogels are preferred because their overall diameter provides full coverage of the visible iris/cornea and good centration. Consequently, much of this lecture is devoted to tinted hydrogel contact lenses.

5

**TINTED CONTACT LENSES**  
**LENS TYPE**

- PMMA/RGP (corneal)
- Soft (hydrogel)
- Scleral (haptic)

97711-2S.PPT 

**Types of Tinted Contact Lenses**

All lens types have been tinted: PMMA/RGP (corneal), soft (hydrogel) and scleral (haptic). Regardless of type, many lenses incorporate a light tint to make the lens more visible when off the eye, assisting the patient in lens handling. These so called 'visibility' or 'handling' tints, i.e. tints of low density (high transmittance), are a typical standard lens feature. In many cases, an untinted version of the same basic lens is not available. Should the need arise, almost all types of contact lenses can be tinted in some way.

8L897711-2

Should a tint density greater than a handling tint be required, the practitioner should first evaluate the needs of the patient and determine the basic type of contact lens required. Once this has been done, a decision on the type of tint can then be made. For example, a darkly tinted lens would not be suitable for full-time wear, as the ability of the wearer to drive at night would be seriously compromised.

In choosing the colour and density of a tint, it may be relevant to assess the normalcy of the prospective wearer's colour vision. While there is no tint that will 'improve' the ability to discern colours, some tints may improve the ability to differentiate between colours by altering their apparent brightness.

6

**TINTED HYDROGEL LENSES**

- Most common cosmetic lens
- Wide range of tints available
- Large diameter and limited movement are advantageous:
  - centration
  - location of tint, esp. with clear pupil

97711-3S.PPT



8L897711-3

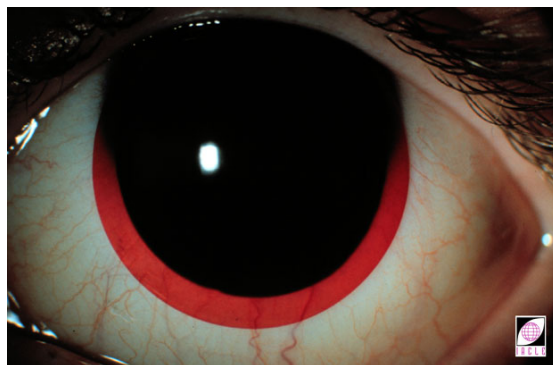
### Tinted Hydrogel Contact Lenses

Hydrogel lenses are the most commonly prescribed tinted contact lens. This is due largely to the market dominance of hydrogel lenses. However it is also due, at least partially, to the relative ease with which they can be tinted. Furthermore, most tinting processes can be applied to hydrogel materials. This characteristic provides the practitioner with an almost unlimited range of options for wearers.

A major advantage of hydrogel lenses over other tinted lens types is that they tend to remain centred and exhibit relatively little movement on the eye.

Cosmetically, this is advantageous because the tinted portion of the lens remains over the iris of the wearer. If the lens were to move excessively, the tinted portion would become visible against the white sclera, giving the appearance of a coloured crescentic halo beyond the limbus (slide 7). This would detract from the cosmetic acceptability of the lens and disclose the presence of an otherwise inconspicuous contact lens.

7




8L8 2100-95

8

**TINTED RGP LENSES**

- Limited applications:
  - material or manufacturer identification
  - handling/visibility
- Incomplete corneal coverage
- Frequently, location is eccentric:
  - decentration/movement
  - visibility of iris
- Less suited to occasional wear
- Range of tints is limited

97711-4S.PPT



8L897711-4

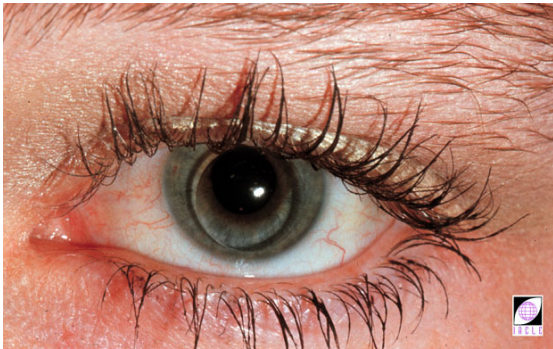### Tinted Rigid Gas Permeable Lenses

The long-established use of tints in RGP contact lens materials is restricted typically to the need to increase the visibility of the lenses for handling. The most obvious limitation of an RGP lens is that, generally, it has a diameter smaller than the cornea (slide 9). Furthermore, it is more mobile on the eye, making the high visibility resulting from tinting a distinct cosmetic disadvantage (slide 10).

As some adaptation to the presence of RGP lenses is usually required, such lenses are not well suited to occasional wear for whatever reason, including special visual effects for entertainment.



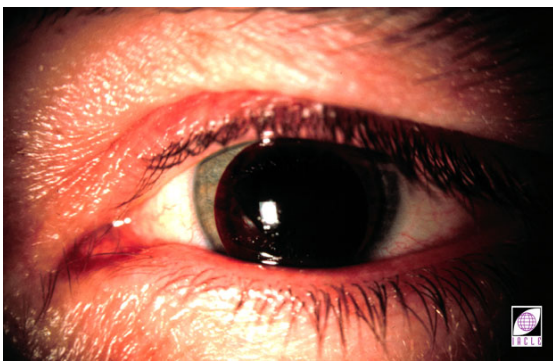
9



8L800E2-88

On occasions, special applications require a feature that only an RGP lens can deliver. An example is the need for a lens whose front surface is to be mirrored for use theatrically (e.g. Yul Brunner in the film *Westworld* wore mirrored contact lenses) or for psychophysical experiments to monitor eye position and movement (or for stabilized retinal imagery). In both of these examples, attention would need to be paid to the lens' TD, especially if close viewing was anticipated (film) or lens movement was unacceptable (psychophysics).

10




8L82847-93

11

**TINTED SCLERAL LENSES**

- First contact lenses used for cosmetic enhancement
- Wide range of 'artwork':
  - hand-painted
  - photographic
  - machine printed
- Clear pupil option available
- Very limited movement
- Well suited to prosthetic applications

97711-SS PPT



8L897711-5

### Tinted Scleral Lenses

Scleral (haptic) lenses have a long history of use for prosthetic correction, although only a few specialist practitioners use them now. This is due to the complex trial lens fitting or impression molding required, the difficulty of making and modifying the lenses, and the creation and matching of the 'artwork' to be incorporated.

A wide range of tints and a clear pupil option are available in scleral lens designs. The tinting technologies employed range from hand painting to photomechanical reproduction. Scleral lenses have the advantage of being relatively immobile *in situ* so any tinted area remains located appropriately. Furthermore, eccentric artwork can be reliably located on such lenses making them well suited to prosthetic applications.

When PMMA scleral lenses were used in motion picture production during the PMMA era, a central hole about the size of the pupil was often cut into the centre of the lens to enable prolonged wearing times.

12

### TINTED CONTACT LENSES LENS SELECTION

- Patient needs:
  - cosmetic
  - therapeutic
  - vocational
- Type of problem(s)
- Patient history and symptoms
- Previous lens-wearing experience

97711-6S PPT



8L897711-6

### Selection of Tinted Contact Lenses

Clinically, the patient must be assessed comprehensively prior to fitting tinted contact lenses. The responsibility of the practitioner to a tinted lens wearer is the same as when the primary motivation is vision correction, even if only a plano-powered tinted lens is to be dispensed.

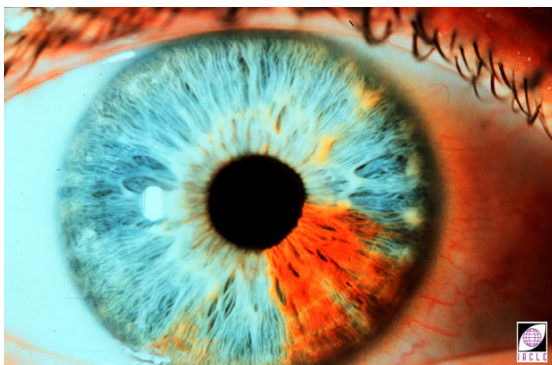Before any cosmetic contact lens fitting, the practitioner must:

- Assess the patient's needs.
- Examine their ocular health and determine their Rx.
- Discuss their previous lens-wearing experience.
- Assess their expectations.

All prospective wearers of tinted lenses need to be clearly and firmly told that tinted lenses are not 'playthings'. Such a message probably bears repeating at every subsequent opportunity, including every after-care visit. Unfortunately, some wearers do not think they need to attend after-care visits once satisfactory lens wear is achieved. Such non-compliant wearers place the practitioner in a difficult position, as little control can be asserted over them. If an inappropriate attitude is demonstrated from the start, steps should be taken by the practitioner to re-orient the patient's thinking or actively discourage the prospective wearer from proceeding with tinted lenses.

It is less likely that existing lens wearers, i.e. those whose primary motivation is or was vision correction, will take an unsuitable stance on tinted lenses. However, the published studies on general contact lens wearer compliance (see Collins and Carney, 1986; Chun and Weissman, 1987; Radford *et al.*, 1993; Phillips and Prevade, 1993) suggest that all contact lens wearers should be regarded as potentially non-compliant (unless proved otherwise).

13



8L8L110-99

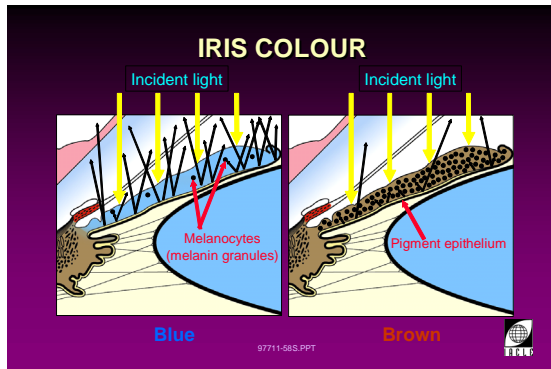
### Eye (Iris) Colour

The apparent colour of an eye is largely dependent on the colour of its iris. Differences may exist between the colours of each eye (heterochromia irides) or, less commonly, within the same eye (slide 13).

Despite the range of colours seen, all irides have the same essential structure and features. Iris colour differences are a function of the number of melanocytes they contain and the quantity of granular melanin (pigment) the melanocytes contain (Snell and Lemp, 1998).

Blue irides have less pigment than their brown counterparts (slide 14). The blue colour results from the absorption of the longer wavelengths (red end) and the reflection of the shorter (blue) wavelengths. Race also has a significant influence, with fair-skinned races generally having less melanin pigment in their melanocytes (Snell and Lemp,

14



8L897711-58

1998). Further, the irides darken with increasing age but the final eye colour is revealed well before adulthood is reached. People with the condition of general or ocular albinism have melanocytes that are devoid of pigment producing the characteristic translucent eye appearance. The colour of the blood's haemoglobin in the vasculature of the iris and retina present a reddish glow (after Snell and Lemp, 1998).

Iris colour is determined genetically but is not sex linked. Brown eyes are inherited as an autosomal dominant trait while blue eyes are an autosomal recessive trait (Davies, 1989).

15

**TINTED CONTACT LENSES  
PRACTICAL CONSIDERATIONS**

- One or both eyes to be fitted?
- Same or different lens in each eye?
- Trial lens availability
- Assess the options before ordering
- Custom lens design
- Cost of lenses
- Long delivery time for some lenses

8L897711-8

**Practical and General Considerations for Tinted Contact Lenses**

Although a substantial number of tinted contact lenses are available to the practitioner, it is important to consider the benefits and costs of using them. The patient should be informed fully of suitable lenses available, along with their advantages and disadvantages.

In most cases, fitting and demonstrating a few different lens types and viewing them under a range of lighting conditions may reveal problems that might have arisen later. When a tinted lens is only fitted to one eye, usually in prosthetic work, the iris colour matching to the other eye is most accurately performed in outdoor daylight (unless the light is controlled to match the colour temperature of outdoor lighting).

Problems may include:

- Tint (opaque) anterior to the plane of the natural iris (depth and parallax) (explained further in next section).
- Unacceptable appearance of the lenses.
- Wearer expectations that cannot be met.
- Lens fitting characteristics that may be a barrier to success.

16

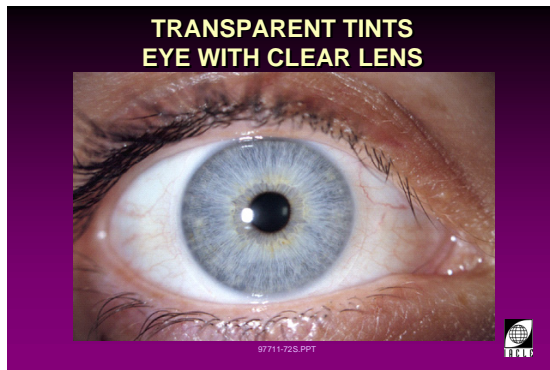**TINTED CONTACT LENSES  
GENERAL CONSIDERATIONS**

- Tint is anterior to the plane of the natural iris (depth & parallax)
- Iris colour matching
  - difficult
- Manufacturing variability:
  - reproducibility of custom designs?
- Non-toxic materials required

8L8997711-7

## II Types of Tints

17



8L897711-72

### Types of Tinted Lenses

Selection of the most appropriate type of tinted lens from the range available is based on many factors. Selection factors include:

- Patient desires.
- Patient needs.
- Iris colour.
- Pupil size.
- Tints available.
- Acceptability of the cosmetic appearance.

The two main types of tinted contact lenses in use are termed transparent and opaque, with transparent tints being the most common. The transparent tinted lenses have a large-diameter tint area that approximates the patient's visible iris diameter (slide 18, see colour rendition for more detail).

The second main type of tinted lens is described as an opaque tint (slide 19). Artwork or images that do not transmit light are incorporated in the opaque lens.

Other types exist, e.g. translucent (slide 20). While the terms 'transparent' and 'opaque' are unambiguous, the term translucent used in slide 19 may need some explanation. Generally, translucent is taken to mean the passage of light through an object with diffusive rather than regular transmission properties. This usually means that, although colour and possibly some texture may be apparent through such a lens, most detail will be obliterated by the diffusive nature of the lens' light transmission.

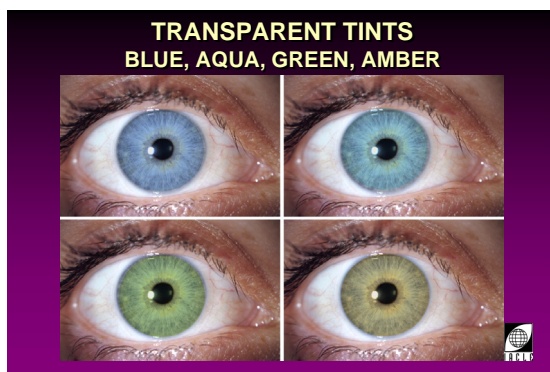### Transparent Hydrogels

Applications for transparent lenses include:

- As an aid to handling the lenses.
- Enhancing the eye's natural colour.
- Altering the colour of light irides.
- An aid for colour vision deficiency.


Transparent tinted lenses, having a very light tint present only for aiding in handling the lenses, typically have the tint incorporated across the entire lens diameter. Those which have a deeper tint in order to enhance or slightly shift natural eye colour appearance will typically have the diameter of the tinted area somewhat less than the visible iris diameter so that the limbus and sclera do not appear tinted. These enhancement tinted lenses may have the entire iris diameter tinted or may have a clear central pupillary zone.

18



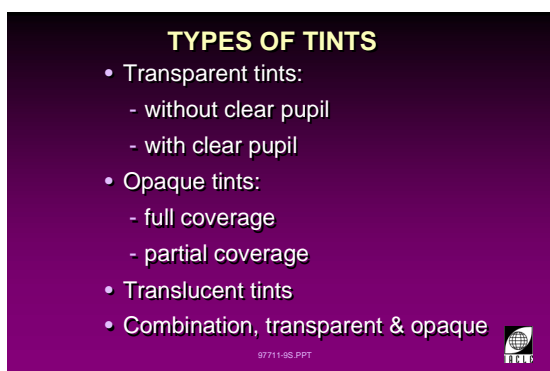
8L897711-70

19



8L8L104-99

20



8L897711-9




21

**TYPES OF TINTS DESIGNS**

**Transparent:**

- Iris-diameter tint
  - no clear pupil zone
  - diameter: 0.5mm < visible iris diameter
- Clear pupil with iris-diameter tint
  - clear pupil diameter *may* be selectable

97711-10S.PPT



8L897711-10

22

**TRANSPARENT TINTS CLEAR PUPIL, TRANSPARENT TINT**



97711-73



8L897711-73


23

**TYPES OF TINTS DESIGNS**

**Opaque:**

- Clear pupil with iris colour
- Black pupil with clear iris
- Black pupil with iris colour
- Pupil concentric with iris
- Decentred pupil and/or iris

97711-11S.PPT




8L897711-11

24



97711-92



8L81441-92

### Opaque Hydrogels

Opaque tinted lens applications include:

- Cosmetic change of eye colour.
- Concealing scar tissue in the cornea or deeper layers of the eye (slide 23).
- Hiding iris defects (slide 24) including aniridia (surgical or traumatic) (Azizi, 1996).
- Patching for the treatment of amblyopia, and intolerable diplopia (Astin, 1998).

More recent cosmetic opaque lenses use tints that only partially cover the area of the iris. This partial coverage is designed to display a 'mixture' of the natural underlying iris and the artwork of the lens. This is done to make the lens appear more realistic by giving its appearance some real depth supplied by the underlying anatomical iris.

A major consideration when fitting darker transparent or opaque tinted contact lenses is that the plane of the lens, and therefore the tint, is located significantly in front of the natural iris and the 'iris' plane will always appear to be mislocated, i.e. located too far anteriorly (slide 25, 26 and 27). This can cause a somewhat unnatural appearance of the eye to all observers with normal stereopsis and reasonable powers of observation. It is common for casual observers of such lenses to pass comments about the eye's appearance, many unflattering.

Prosthetic opaque lenses may be made with an element that is pupil-sized, intended to conceal a hyper-mature cataract or act as an occluder (slide 29 – a computer simulation).

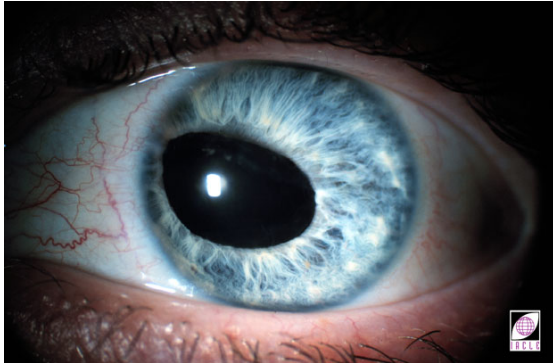
### Scleral Lenses

It is probable that a scleral lens incorporating suitable artwork is required when:

- Concealment of an eye disfigurement is desired because of some abnormality of the globe's shape.
- A strabismus requires disguise.
- Some eccentric positioning of the artwork is required.
- Some special effects are needed in the entertainment industry, especially if the sclera needs to be hidden.

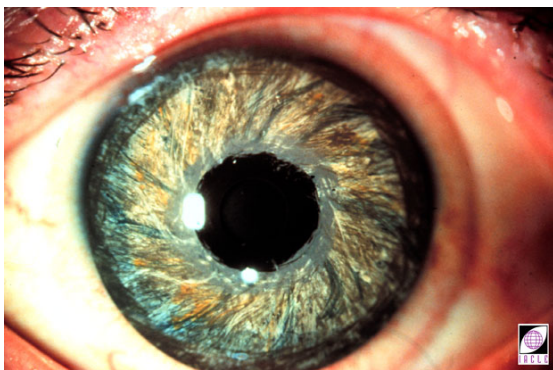
If the globe shape is abnormal, a molded prosthetic shell will be required, as it is unlikely a scleral lens will provide a satisfactory fit. This topic is covered in Module 9, Lecture 9.5: **Fitting an Ocular Prosthesis.**

25



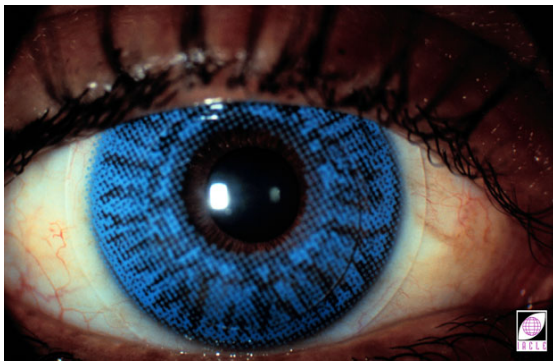
8L80596-94

26



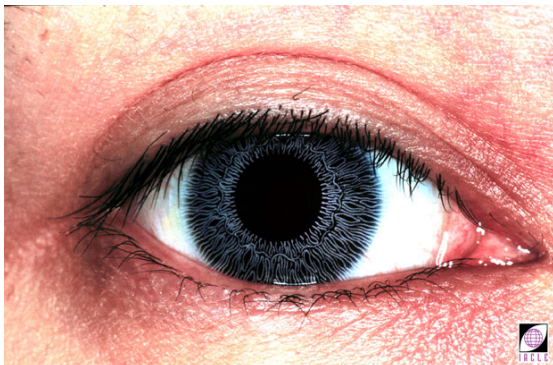
8L816B11

27



8L8 0517-94

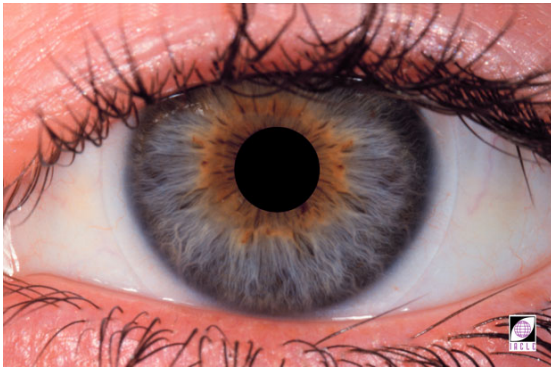28



8L8L103-99



29



8L81174a-91

**II.A Transparent Tints**

30

**TRANSPARENT TINTS CONSIDERATIONS**

- Diameter of tinted zone
- Pupil zone:
  - clear
  - tinted
  - diameter?
- Range of colours
- Density of tinting
- Non-toxic dyes
- Light transmission?

97711-12S.PPT



8L897711-12

**Transparent Tints: Considerations**

Transparent tinted lenses have either a complete central tint over the lens almost to the extent of the visible iris diameter, or they have a clear pupil surrounded by a tinted zone, i.e. an annular tint.

Lenses with tints covering the pupil area decrease and alter the spectral characteristics of the light entering the eye. However the cosmetic effect is often better because the natural iris colour cannot be seen when viewed obliquely, as happens with a clear pupil tint.

Regardless of the type of transparent tint employed, the tint is doubly effective, because not only does it alter the light entering the eye, it also affects any light reflected from intraocular structures on leaving the eye (after Mandell, 1974). For example, a red tinted contact lens fitted on an eye with a blue iris will make the iris appear somewhat purple.

Under certain viewing conditions, some tinted lenses may cause problems for wearers performing demanding visual tasks. Therefore, it is important for the light transmission characteristics of the different tints and technologies to be understood.

In addition to knowing the lens' luminous transmission factor (based on Illuminant C, the eye's relative luminous efficiency and the tint's transmission at each wavelength) for pupil-covering tints, it is also useful to know the lens' spectral transmission characteristics. This information is required when determining whether the lens is likely to cause problems in particular applications/occupations.


Luminous transmissions are generally in the range 75-85%, except for handling tints that are usually of the order of 95% (see slide 32). However, while the transmission at the peak of absorption gives one characteristic of a tint, the data can mislead because the transmissions at other wavelengths may approach 100%. The wavelengths of a tint's peak absorption and peak transmission also dictate its characteristic colour (see slides 33 to 36). These slide are based on an amalgamation of the spectral transmission curves in Hammack and Lowther (1986).

31

**TRANSPARENT TINTED LENSES LUMINOUS TRANSMITTANCE**

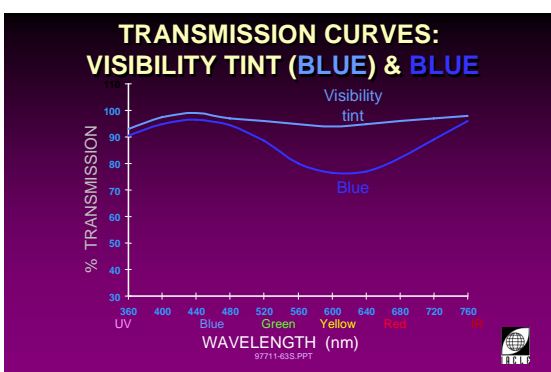
TINT	RANGE (%)
Light	90 - 96
Medium	81 - 89
Dark	70 - 80

97711-13S.PPT



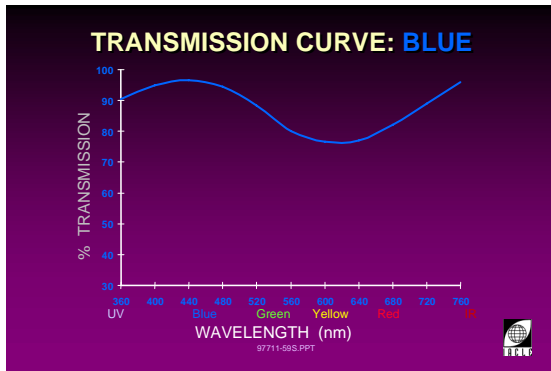
8L897711-13

32



8L897711-63

33



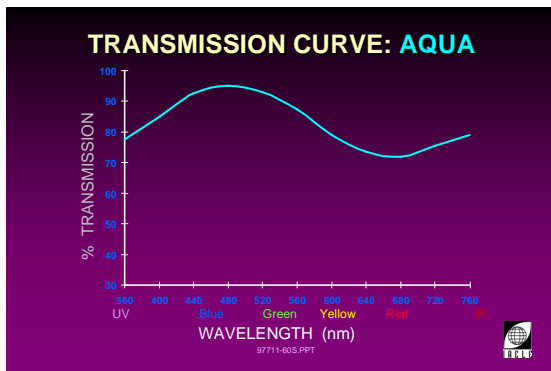
8L897711-59

Amber tints can transmit as little as about 20% at 460 nm and the green lenses as low as 50% at 410 nm (Lowther, 1987) (slide 36 shows this tendency).

There may be industrial situations in which patients wearing these lenses are required to detect light sources in the peak absorption wavelengths under low illumination conditions. This can present problems, and lenses with clear pupils should be employed in such cases.

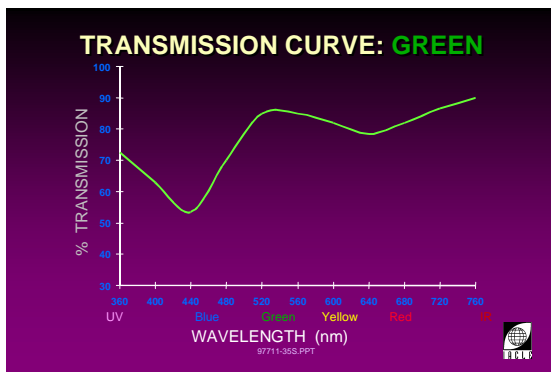
Other industrial situations requiring differentiation of subtly different colours or shades may preclude the use of pupil-covering tints at work.

34



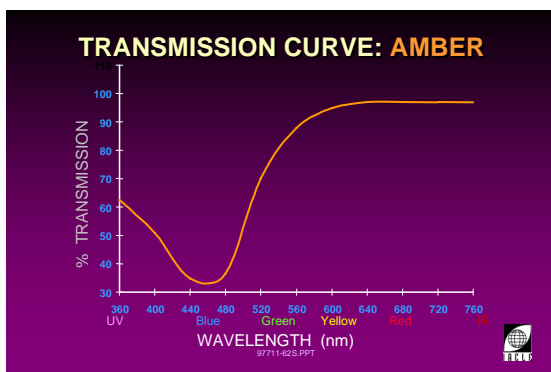
8L897711-60

35



8L897711-61

36




8L897711-62

37

**TRANSPARENT TINTS  
COLOUR PERCEPTION**

- Generally, colour perception with transparent handling tints is not affected:
  - high light transmission
  - high transmission across visible spectrum
- Dark amber reduces perception of red:
  - marine navigation
  - safety issues
- Dark aqua may make the red end of the spectrum difficult to see

97711-14S.PPT



8L897711-14

**Colour Perception with Transparent Tinted Lenses**

Generally, colour vision through transparent handling tints is not affected perceptibly because of their high light transmissions (Mandell, 1974).

The following studies all failed to show any significant deleterious effect on colour vision:

- Using the Farnsworth-Munsell 100 Hue Test (Harris and Cabrera, 1976).
- Using the Lanthony New Colour Test (Tan *et al.*, 1987).
- Using the 100 Hue Test and the Desaturated D-15 Test (Laxer, 1990).
- Using the 100 Hue Test and Ishihara Plates (Hovis and Sirkka, 1990).

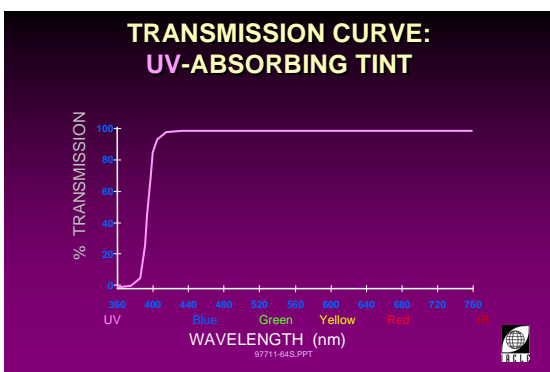
However, Grimm *et al.* (1977) showed that tinted hard lenses affected the 100 Hue Test results.

In colour defectives, Pun *et al.* (1986) showed a significantly increased reaction time when protanopes, protanomals, and deuteranopes wore dark aqua, amber, blue and green transparent tinted contact lenses.

There are some circumstances in which caution may be required when using other types of transparent tints. For example in marine navigation, the wearing of dark amber tinted contact lens may compromise the ability to detect red signal lights especially under difficult visual conditions, e.g. fog, mist and light rain.

Dark aqua tinted contact lenses can also be expected to adversely affect the ability to perceive red and near-red wavelengths under difficult conditions. Traffic lights are usually not a problem for users of tints because of the standardization of the positions of the light's colours, at least within a particular country.

38



8L897711-64

**Ultraviolet Absorption by Transparent Tints**

A generalized transmission curve for a UV-absorbing tint is presented in slide 38 (after Bruce and Dain, 1988). Many current day hydrogel and RGP lens materials incorporate a UV blocker in the material. This 'value added' feature is not normally visible with normal contact lens inspection because the light that is blocked is just below the lower (violet) end of the visible spectrum (that is, ultraviolet).

Ultraviolet absorption by contact lenses is of interest to both practitioners and patients. However, lenses incorporating UV blockers are usually not able to protect the cornea and crystalline lens completely. Further, while some lenses block UV radiation better than others, no contact lens can protect the conjunctival tissue beyond the cornea, as the lens does not cover it.

39

**TRANSPARENT TINTS  
ULTRA-VIOLET ABSORPTION**

- Greater than with untinted lenses
- May help reduce glare sensitivity
- Levels do not meet sunglass standards
- Lenses do not protect the conjunctiva

97711-15S.PPT

8L897711-15

Bruce *et al.* (1986) examined several common transparent tinted soft lenses and presented data for near UV and erythema UV (slide 39). It should be obvious that the tint process has an effect on effectiveness of UV blocking with 'reactive' tint process allowing more transmittance of UV and 'vat' processing being more effective in blocking UV radiation. The tinting processes featured are covered later (opposite slide 43).

UV-blocking RGP lenses offer even less protection because they cover much less of the eye than hydrogel lenses. In a study by Bruce and Dain (1988), an RGP material (Boston Equalens™) was found to have effective UV blocking up to 380 nm, i.e. the commencement of the visible spectrum.

40

**TRANSMITTANCE: UV  
TRANSPARENT TINTS**

Tint Type	Near UV	Erythema UV
Reactive	62-79%	54-72%
Vat	31-75%	15-54%

97711-40S.PPT

8L897711-68

It has been argued that it is desirable for some UV, especially UV-A, to enter the eye, however, the arguments put forward are more speculative than scientific (see discussion in Sliney, 1997).

Patients must not be allowed to conclude that UV-blocking contact lenses are an alternative to appropriate sunglasses and/or suitable headwear.

41

**TRANSPARENT TINTS  
CLEAR PUPIL ZONE**

- Selecting appropriate diameter
- Limited parameter range
- Iris visibility (oblique view)
- Iris may become visible through the clear pupil in miosis

97711-16S.PPT

897711-16

**Clear Pupil Zone with Transparent Tints**

Hydrogel lenses incorporating a tint can be produced with a clear pupil zone. Such a feature can be useful when darker tints are employed. A clear pupil would minimize potentially adverse effects related to full pupil coverage tints, such as:

- Difficulty seeing in dim lighting.
- Difficulty seeing wavelengths in particular regions of the visible spectrum.
- Perceived 'coloration' of lightly coloured objects.

One of the disadvantages of a clear pupil zone is the visibility of the natural iris under the contact lens when the patient's pupil constricts or when the wearer's eye is viewed obliquely (see slide 41). If the diameter of the clear zone is made too large, this problem will be more pronounced. The wearer may also become aware of the problem if the lens moves excessively with each blink.

42

**TINTED LENS: CLEAR PUPIL ZONE**

97711-52S.PPT

8L897711-52

43

**TRANSPARENT TINTS  
VAT TINTING PROCESS**

- Performed after lens fabrication/hydration
- Water-soluble dye used
- Pupil and/or peripheral zones (clear) masked
- Dye enters a swollen lens matrix
- Dye rendered insoluble within matrix
- When lens returned to normal, dye is trapped
- Tint density influenced by BVP



8L897711-18

44

**TRANSPARENT TINTS  
REACTIVE DYE PROCESS**

- Performed after lens fabrication/hydration
- Pupil and/or peripheral zones (clear) masked
- Lens exposed to dye
- Dye fixed to lens material chemically
- Surface tint with minimal penetration
- Tint density not affected by BVP



8L897711-51

**Transparent Tints: Production Processes**

A number of processes can be used to tint contact lenses. The main types are vat tinting and reactive dyeing.

**Vat Tinting:**

In the vat tinting process, the lens matrix is swollen as a preliminary step. A dispersing dye is then introduced. The dye enters the lens matrix in a water-soluble form and is subsequently rendered insoluble *in situ* by chemical means. Once the lens parameters are returned to their normal dimensions, the dye is trapped physically rather than chemically within the lens matrix.

The resulting tint tends to be more stable and less susceptible to the action of some components of lens care products than tints applied with the alternative reactive dyeing process. However, vat tints are subject to density variations across the lens due to the thickness differences induced by lens BVP. The name 'vat' is derived from a similar textile industry dyeing process that is usually carried out in vats.

**Reactive Dyeing:**

The alternative technique, reactive dyeing, uses covalent bonding, i.e. the dye is bonded chemically to the lens polymer, thereby forming a new, and coloured, polymer at the lens surface just a few microns in depth. Usually the tint is applied to the front surface.

In some special cases involving dense special tints (e.g. opaque pupils or deep reds, i.e. simulating an X-Chrom lens), it is necessary to tint both sides of the lens if lens distortion and/or curling is to be prevented. Alterations in a surface carrying a dense tint result in lens curl away from that surface. This is due largely to the forced 'packing' of tint chemistry into the surface. To counter this tendency to curl, a similar tint must be applied to the opposite side. In this way an undistorted lens results. These measures are not usually required in the vat tinting process.

It seems that the reactive dye molecules compete with water dipoles for the charged sites within the lens polymer that usually bind water (see Su, 1992), e.g. the hydroxyl tail in HEMA-containing materials or the charged sites on the pyrrolidone ring in PVP-based materials. Because this process is located at and near the surface only, the material's water content is not decreased significantly but some of the physical and chemical properties of the tinted surface are altered.

Reactive tints are not subject to BVP-induced tint density variations but are generally more susceptible to bleaching by lens care products, particularly chlorine-based systems. Further, because the tint is largely located on or near the surface, the tint density decreases over time because of surface wear and tear, i.e. abrasion of the coloured polymer surface results in a physical loss of tint. This 'fading' can amount to a 10% loss per year of lens wear.



The possibilities that the tinted surface is more susceptible to scratching (Lowther, 1987) and spoilage and crazing (Phillips, 1994) have been raised. The crazing issue is usually related to aqua lenses and affects reactive tinted lenses more frequently than vat tinted ones. Regardless of the tint technology, many companies use the same reactive dyes, and as such there is probably a common basis to the problem. Usually, judicious alterations to the tinting process eliminate most problems.

Interestingly, there is evidence that the problem is somewhat patient-specific, with certain individuals able to repeatedly craze lenses in as little as 2 weeks of DW. The advent of disposable lenses has decreased the significance of these potential disadvantages.

Regardless of the tinting process employed, a leaching process is required after the dyeing step is completed. This removes all unreacted and/or unbound tinting process chemistry from the lens before product packaging and sterilization is undertaken.


For the manufacturer, a prime consideration when choosing a tint family is the cytotoxicity of the family in general and of the tints selected in particular. Many industrial dyes that might otherwise be suitable are toxic, or even extremely toxic, to the anterior eye. Most dyes in common use come from just a few companies, and even fewer dye families.

45

**TRANSPARENT TINTS  
CLINICAL ASPECTS**

- No significant effect on visual performance
- Less to little effect on darker/dark irides
- Night time use
  - a hazard to driving?

97711-20S.PPT




8L897711-20

46

**TRANSPARENT TINTS  
CLINICAL ASPECTS**

- More susceptible to deposits than clear lenses?
- Lessening of tint with lens disinfection/age
- Bilateral lens replacement when needed
- Natural versus artificial colour effects
- No reduction in oxygen transmission

97711-46S.PPT



8L897711-21

#### Transparent Tints: Clinical Aspects

Transparent contact lenses are by far the most commonly prescribed tinted lens. They are available in many colours and each comes in a range from light to dark, usually in two, sometimes three, steps.

If the wearer is to be advised and managed appropriately, there are a number of clinical aspects that a practitioner needs to consider when prescribing transparent tints.

Tests of visual performance with transparent tinted lenses should indicate no significant changes in the following parameters:

- VA.
- Contrast sensitivity function.
- Glare sensitivity.
- Colour discrimination.

Tinted lenses with a luminous transmittance less than 85% should not be dispensed to patients who intend to use them at night, especially for night driving. This is because lenses with such low transmittance pose a safety risk.

Many factors may cause the transparent tint to fade over time. These include:

- Chlorine-based care and maintenance systems (Liebetreu *et al.*, 1986), normal hydrogen peroxide (Lutzi *et al.*, 1985; Janoff, 1988), and thermal disinfection systems have each been



shown to not have a significant affect on contact lens tints (Stanek and Yamane, 1985)].

- Chlorinated swimming pools.
- Topical medications, especially those containing organic peroxides, e.g. benzoyl peroxide (Lowther, 1987). The latter is commonly used in preparations for complexion problems such as acne. It is also used as the catalyst in some car body and building fillers.
- Surface abrasion (covered previously).

Some reports have indicated that the tinted areas of contact lenses are more prone to deposit formation than the untinted equivalent. This is probably more the case with reactive dyes, since the tint constitutes a surface alteration.

Long-term deposit build-up may also cause the lens to become more rigid. It is believed that this may contribute to the central corneal distortion sometimes observed with conventional lenses. Alternatively, deposition may be implicated in lens distortion, curling or even rolling, i.e. the lens rolls up into a tube-like form. Frequent replacement of tinted lenses minimizes most of these problems.

The reactive dyeing process has been shown to result in localized lens swelling, corneal distortion and visual disturbance (see next section). Alterations to the tinting process are required to resolve such issues.

In some cases the effect on appearance created by the tinted lens may appear very artificial, e.g. the colour violet does not occur naturally in eyes. Patient expectations must be realistic and different combinations of tints should be trialled to determine the best lens colour/eye colour combination.

Significantly, unlike some tinting technologies, transparent tints result in immeasurable decreases in lens oxygen transmissibility. Interestingly, one tint process actually claimed to improve lens transmissibility, a claim subsequently disproved (Benjamin and Rasmussen, 1986).

47

### CORNEAL IMPRINTING

- Disturbances of vision have been reported with tinted lenses
- Lenses:
  - had annular transparent tints (i.e. clear pupils)
  - showed a step at pupil margin (SEM)
- Corneas showed :
  - distorted topography
  - irregular astigmatism
  - rapid recovery following refitting



97711-965.PPT

8L897711-56

### Corneal Imprinting and/or Distortion

There are reports in the literature of disturbances of vision resulting from tinted contact lens-induced corneal shape changes. These corneal alterations are analogous to an imprint and are indirectly due to changes in the physical properties of hydrogel lenses produced by the tinting process. Most reports involve annular tints, i.e. transparent tints with clear pupils (Lobby, 1987; Clements *et al.*, 1988; Schanzer *et al.*, 1989; Bucci *et al.*, 1997). Clements *et al.* (Clements *et al.*, 1988) were able to demonstrate the optical effect of the imprint with retro-illumination of a fundus camera. They postulated that the effects were due to a reduction in the level of hydration in the tinted zone.

Schanzer *et al.* (Schanzer *et al.*, 1989) used scanning electron microscopy to examine the contact lenses involved and showed deformations in

the lenses causing the visual disturbances. They postulated that internal stresses produced by the tinting process 'matured' into physical deformations, causing irregular astigmatism.

Bucci *et al.* (Bucci *et al.*, 1997) used corneal topographical analysis to demonstrate the corneal distortion produced by annular tinted lenses. They found no support for the theory that the  $Dk/t$  of the lens' tinted zones was reduced or a factor in the resulting distortion. All disturbances resolved rapidly when alternative lenses or similar, but with iris diameter tints were used.

Although the reports relate to transparent tints, it is conceivable that opaque lenses, especially those incorporating laminated artwork or full-coverage, front-surface iris prints, could produce similar effects.

48

### TRANSPARENT TINTS TRIAL FITTING

- Standard lens fitting considerations
- Movement and centration are key factors
- Lighting conditions:
  - affect tint appearance
  - assess under daylight conditions

97711-22S.PPT



8L897711-22

### Trial Fitting Transparent Tinted Lenses

Tinted contact lenses, with or without a prescription, must be fitted with the same degree of care and responsibility as untinted lenses. Further, the tinted lenses themselves must meet all the standards normally applicable to other RGP, soft and scleral contact lenses.

Fitting requirements include:

- Good centration and relocation.
- Adequate, but not excessive movement.
- With SCLs, acceptable 'tightness' *in situ* (e.g. as assessed by the lower lid push-up test).
- With RGP lenses, avoidance of the limbal region at all times.
- With scleral lenses, minimal apical clearance, limbal clearance and uniform scleral bearing.
- Good and stable vision.
- Comfort.

Good centration is essential to prevent the tinted area of the lens appearing over the sclera, thereby marring the cosmetic effect and disclosing the presence of the contact lenses.

Assessment of the effect of a tinted lens on eye colour should be performed under bright or daylight conditions. The colour temperature of the light source may also be important, as the overall appearance of the tint may vary depending on the illuminant. It is possible for the wearer to be disappointed with the final appearance if the lens was only ever seen on their eye under consulting room lights.

49

### UNINTENDED LENS TINTING

- Insertion of a SCL too soon after sodium fluorescein instilled into the eye
- Instillation of sodium fluorescein into an eye already wearing a SCL
- Usually reversible
  - lenses that 'acquire' an unintended tint readily, often release it readily
  - however, strongly ionic materials may bind dye molecules
- Other vital stains may also tint hydrogels

97711-74S.PPT



8L897711-74

### Lens Tinting: Unintentional

Unintentional tinting can result from the use of topical sodium fluorescein dye in the consulting room when hydrogel lenses, especially ionic hydrogels, are inserted too soon after fluorescein has been instilled into the eye. Fluorescein tinting can also occur when the dye is mistakenly applied to the eye of a patient already wearing a hydrogel lens. Typically, such tinting of hydrogels with fluorescein is reversible and does little or no other harm to the lens(es). However, some strongly ionic hydrogel polymers may retain fluorescein by binding the dye molecules. In such cases, the discoloration may never disappear completely.

Other vital stains can also tint hydrogel lenses.

## II.B Opaque Tints

50

### OPAQUE TINTS

- Opaque dye within or on lens
- Reflect light
- Block light
- Clear pupil zone if vision is required

97711-23S.PPT



8L897711-23

### Opaque Tinted Contact Lenses

Opaque tinted contact lenses can be used for vision correction as well as for altering the eye's appearance.

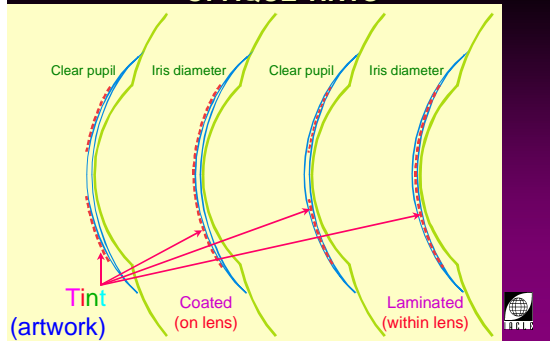
Unless the lenses are intended to conceal a cosmetic problem, they are usually made with a clear pupil. Lenses with clear pupils must provide the same optical quality and prescription accuracy normally expected of other, more conventional, prescription contact lenses.

Relatively recent innovations in opaque lenses have sought to achieve a more natural appearance for lenses used only for cosmetic effect. Innovations include:

- Partial rather than total coverage of the underlying iris.
- A graduated rather than a sharp demarcation of the 'mechanical' pupil edge.
- Multiple colours within the one printed iris.
- Light or dark rings at the outer edge of the 'mechanical' iris.

51

### OPAQUE TINTS



8L897711-54

52

### OPAQUE TINTS TINTING PROCESS

- Diffusive back-surface treatment
- Full opaque coverage
  - laminated
  - hand-painted appearance
  - machine processed (printed) pattern
- Opaque patterned:
  - dot matrix
  - iris simulation

97711-24S.PPT



8L897711-24

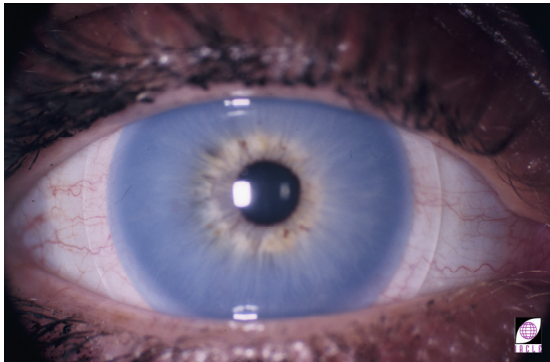
### Opaque Tinted Lenses: Production Processes

- Diffusive: An early attempt at mass-producing an opaque tint resulted in an almost translucent tinted zone. The 'tint' was a diffusive layer of material incorporated into the lens matrix. In this way the underlying iris colour was concealed (slide 53).

A homogenous opaque tint, i.e. a tint that is featureless, can be applied in the same way as transparent lenses, but the appearance is flat, featureless, lifeless and unnatural.

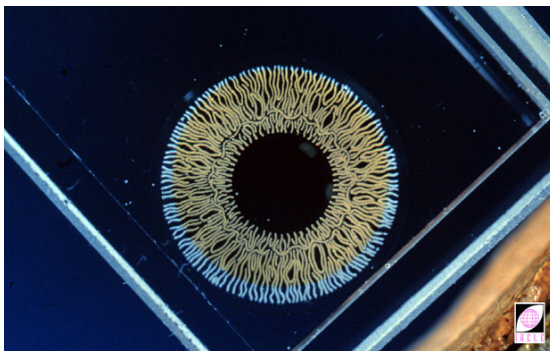
- Laminating: Another process adopted quite early is laminating. In this process the 'artwork' is sandwiched between two thin hydrogel

53




8L80530-94

54



8L8L28-91

55



8L8L104-99

56



8L8L107-99

lenses and the 'assembly' is bonded into a lens (slide 54).

The advantage of this process is the protection afforded the artwork by the lens layers covering both its sides.

Disadvantages include:

- Poorer physiological performance due to greater lens thickness.
- Greater lens rigidity.
- Difficulty getting the BVP accuracy desired.
- The possibility of delamination.

The iris portion of such lenses can:

- Be totally opaque and occlusive (slide 55).
- Be hand-painted or reproduced by mechanical reprographic, computer graphic or photographic means.
- Include a clear or an occlusive pupil depending on the application.

The thickness and rigidity of laminated lenses also alter the fitting characteristics of these lenses. Generally, laminated lenses are more difficult to reproduce and are expensive.

The back surface of the lens can be made black (slide 56 shows the reverse side of a hand-painted lens while slide 57 shows the reverse side of a 'fun' lens with a hint of the dense matrix pattern just visible).

A novel manufacturing process has been developed in which opaque colour pigment is incorporated within a spin-cast soft lens (Chen, 1999). In the first variant the artwork is applied to the female front-surface mold, the liquid lens material is poured into the mold (over the artwork), the mold spun and polymerization initiated by UV light.

In another novel approach, the pigment is mixed and partially dissolved into the liquid lens material. Although the pigment disperses uniformly, due to centrifugal force and different specific gravities, it still locates at or near the front surface.


The lenses resulting from either process have smooth front surfaces even though the artwork is located at or near the front surface.

- Coated, Dot Matrix: Coating the front surface of lenses is a relatively recent innovation. Frequently, the process is applied to an existing lens series. This makes supplying trial lenses easier and less expensive.

The opaque 'ink' pattern is usually sprayed, jetted or stamped onto the lens front surface (slide 58). Sometimes the front surface of the lens is then 'lacquered' to protect the artwork from the eye's environment and lens care products.




57



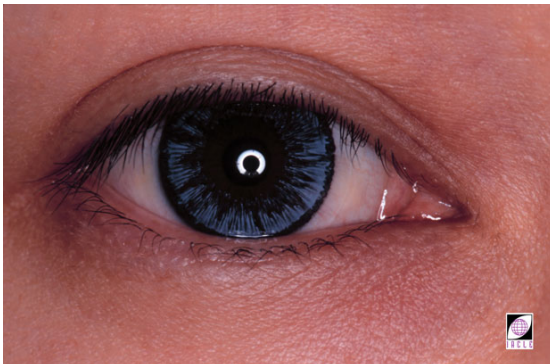
8L8L106-99

58



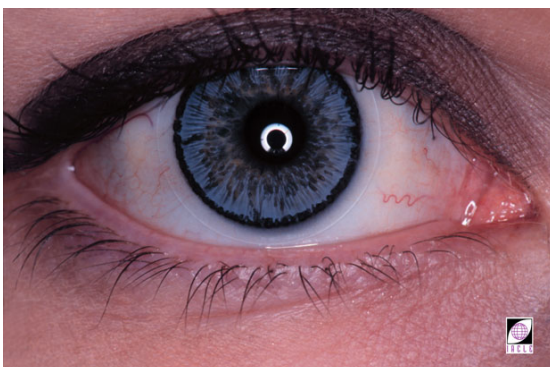
8L8L101-99

59



8L81654-96

60



8L81655-96

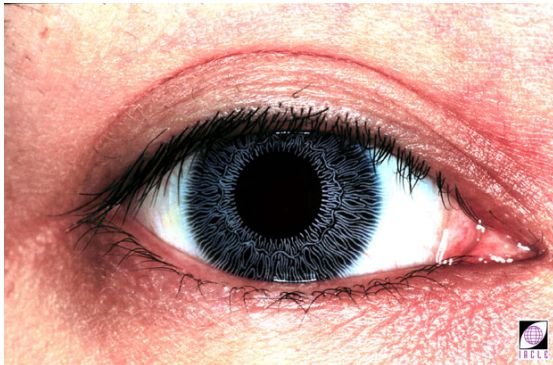
The data available on the chemistry of the process suggests that the dots consist mainly of standard hydrogel monomers with titanium oxide as the opaque agent. The latter is well known for its 'covering' power, i.e. the ability to block and/or reflect light. Any agent that is less capable of blocking/reflecting light is unsuitable because the dots would have to be thicker to perform adequately. This would inevitably lead to reduced comfort and possibly aberrant fitting behaviour.

Slide 59 shows such a lens on an eye with a dark iris, while slide 60 shows the same lens over a light iris. The difference due to the colour of the underlying iris is most noticeable in the pupil zone and adjacent areas. Slide 60 also demonstrates the effect of a dark ring at the outer edge of the mechanical iris. Slide 61 shows the alternative light edge *in vivo*. A lighter edge is intended to maintain the effect of real iris depth on the appearance, all the way to the edge. On the other hand, the dark-ring approach aims to hide the peripheral zone. The strategy is made more effective by the fact that the depth differences between the mechanical iris and the anatomical iris at the periphery is minimal.

Dot matrix manufacturing technology also allows a controlled reduction of the dot density in the region of the pupil, leading to a less obvious transition from artificial to real pupil.

Dot matrix lenses can be expected to demonstrate a more acceptable (less obvious) cosmetic performance in bright light, i.e. when the anatomical iris is visible through the mechanical pupil due to the resulting miosis. Similarly, oblique viewing of the natural iris will probably still result in some of the dots modifying the appearance of the underlying iris.

61




8L8L103-99

62

**OPAQUE TINTS  
CLEAR PUPIL DIAMETER**

- Limited choice
- Miotic vs dilated underlying pupil
  - cosmetic detractor
  - visibility of underlying iris

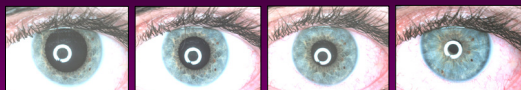
97711-25S.PPT




8L897711-25

63

**PUPIL SIZE**



97711-55S.PPT



8L897711-55

64



8L8DCP-1

**Opaque Tinted Lenses: Clinical Aspects**

Opaque tinted lenses have a fixed-diameter clear pupil zone. As described previously, the pupil edge may have a sharp cut-off to the artwork or a gradual tapering-off of the density and size of dots used to form the artwork (see Melton, 1987). Since the underlying pupil constricts and dilates in varying light levels (slide 63, use the reflection of the ring-flash in the cornea as a guide) it is difficult to select the most appropriate diameter for a clear pupil. A prudent choice is required if the chance of the anatomical pupil becoming visible to an observer is to be minimized.

In general, the clear pupil zone of the lens should be centred on the cornea and made slightly larger than the patient's pupil (actually the entrance pupil).

The Wesley-Jessen Durasoft Colors dot matrix opaque lenses have a nominal 5 mm pupil diameter and a 12.5 mm iris diameter (Melton, 1987).

Usually, eccentric pupil locations are not possible except in scleral lenses. Theoretically, it is possible to place an eccentric pupil on a prism ballasted or a double slab-off spherical lens. However, this is not normally done. One exception (Phillips, 1988) is covered later.

With the obvious exception of 'fun' lenses (slides 64, 65, 68), the problem with many opaque tinted contact lenses is their artificial appearance *in situ*. This is often apparent to observers who are in close viewing range of the wearer. Each case must be evaluated individually and, if possible, a range of lenses assessed before making a final decision.

While dot matrix opaque lenses have been shown to be less comfortable statistically, such findings were found to have little clinical significance (Steffen and Barr, 1993). Intuitively, this was felt to be due to the dots protruding from the front surface.

It has also been claimed that deposits and decreased oxygen transmission are implicated (Daniels *et al.*, 1989). There is little support for the latter claim in the literature and other studies have shown no difference in comfort between clear and dot matrix lenses (Gauthier *et al.*, 1992).



65



8L8DCP-2

The opaque nature of these lenses can also produce some visual discomfort for the patient. Often the patient's vision, as measured on a Snellen-type letter chart, is satisfactory but they may still complain of a feeling of 'ghosting' or haziness, which is also lens type-dependent (Gauthier *et al.*, 1992). This is probably due to decentration of the mechanical pupil relative to the patient's pupil and/or to the dispersion of light if the lens is not completely opaque, i.e. one involving partial coverage.


Some studies have shown that opaque lenses may decrease the wearer's field of view (Daniels *et al.*, 1989), although most show no effect (Trick and Egan, 1990; Lee *et al.*, 1990).

66

**OPAQUE TINTS  
CLINICAL ASPECTS**

- Diameter selection
- Fixed pupil size
- Artificial appearance, lens ≠ iris plane
  - cosmetic concerns
- Slight constriction of the visual field?

97711-26S.PPT



8L897711-26

Field of view restriction may be due to the mechanical pupil of the lens. Due to the location of this artificial stop, the edge of the field may be blurred rather than clearly defined. This characteristic depends on the tinting technology, the 'sharpness' of the pupil edge and the pupil diameter. Potentially, this issue can decrease wearer acceptance significantly and has been known to result in discontinuation of lens wear.

Driving at night while wearing opaque tinted contact lenses may be discouraged in some cases because of the reduction in low contrast vision as well as the possibility of a slight reduction in the extent of the visual field.

Lens care products containing hydrogen peroxide have been shown not to have any deleterious effect on dot matrix opaque lenses (Gentsch and Edrington, 1990).


Regardless of the flippant advertising and risky behaviour associated with so-called 'fun' lenses (plano or Rx), all such lenses are medical devices and all require professional involvement in the prescribing, supplying, and patient education chain just as for any other type of contact lens.

67

**OPAQUE TINTS  
DISADVANTAGES**

- Reduced oxygen transmissibility
- Limited wearing time
  - physiological issues
- Required BVP may be different to clear lens
  - slight difference
  - BVP more difficult to control/predict
- Decreased peripheral visual field (?)

97711-28S.PPT



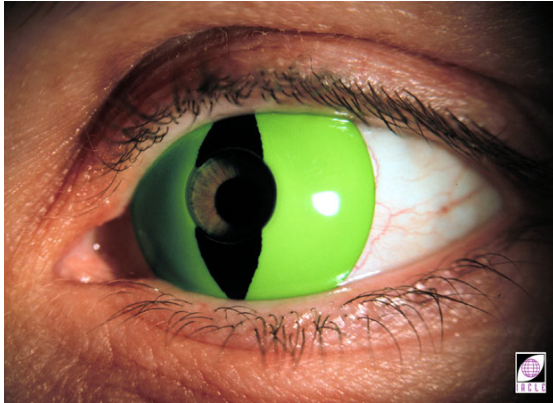8L897711-28

**Opaque Tinted Lenses: Disadvantages**

The lens BVP required to correct the refractive error with some laminated opaque lenses may be slightly different to that needed in a thinner, more flexible clear lens. This is due largely to the greater rigidity (greater thickness) of opaque lenses producing tear lens effects through the lack of conformance with the cornea's shape.

A reduction in the level of oxygen reaching the cornea through some opaque lenses may be a concern in some cases. This could limit the time these opaque lenses may be worn successfully due to resultant corneal oedema.

68



8L8DCP-4

As with transparent tints with clear pupils, a decentering opaque lens with a clear pupil also produces a cosmetic problem when the anatomical pupil shows through the mechanical pupil (slide 68).

### III Cosmetic and Therapeutic Applications of Tinted Contact Lenses

69

#### TINTED CONTACT LENSES APPLICATIONS

- Lens handling/visibility
- Light absorption to reduce photophobia
- Cosmetic enhancement
- Therapeutic
- Prosthetic

97711-28S.PPT



8L897711-29

#### Uses of Tinted Contact Lenses

Tinted contact lenses can be used in a wide range of applications for a variety of reasons. While the majority of tinted lens fitting is routine, the fitting of scleral lenses, for example, requires considerable practitioner expertise. For this reason scleral lenses are relatively uncommon and are fitted by only a few highly specialized and experienced practitioners.

Where the practitioner does not fabricate their own lenses (a common scenario), close liaison between the practitioner and the manufacturer is usually required to achieve a satisfactory outcome.

70

#### LENS HANDLING

- Easier location when handling/cleaning
- Better visibility for low vision patients
- Easier to locate if dropped
  - e.g. wash basin
- Help to differentiate right and left lenses

97711-30S.PPT



8L897711-30

#### Lens Handling

Many SCLs have a light transparent tint as an aid to handling. Handling tints enable the patient to locate the lens more easily if it is dropped, for example into a sink or on to a bench top. Handling tints also help disclose the location of a lens in the palm of the hand. A typical handling tint has a luminous transmission factor of about 95%.

Lenses can be tinted to make it easier for low vision patients to detect their location in storage containers and/or to differentiate between right and left lenses. One alternative is to tint the lenses, e.g. green for the right eye and blue for the left eye.

71

#### LIGHT ABSORPTION

- Selective absorption for colour vision defects
- Decreases photophobic reaction in light sensitive individuals:
  - glare sensitivity
  - is an opaque tint required?
- Occupational or recreational purposes
  - reduces need for very dark sunglasses

97711-31S.PPT



8L897711-31

#### Light Absorption by Tinted Contact Lenses

Photophobia, or any generalized photosensitivity (decreased tolerance to light), is a symptom that may arise from contact lens wear, especially rigid lens wear, and several ocular conditions.

A reduction in symptoms may be possible using an appropriately tinted SCL. However, it has been reported that even darkly tinted contact lenses (absorption > 58%) do not reduce symptoms of glare and light sensitivity (Lutzi *et al.*, 1985b).

72

#### COSMETIC ENHANCEMENT DESIGN TYPES

- Coloured opaque
- Black opaque
- Central and/or peripheral tinted zones
- Decentred tint zone
- Scleral designs

97711-32S.PPT



8L897711-32

#### Cosmetic Enhancement Contact Lens Designs

Currently, a wide range of lenses is available for the cosmetic enhancement of the eye's appearance.

Each case must be evaluated individually before selection of a suitable lens can be made. The reasons for pursuing an alteration in appearance, as well as the motivation to do so, should be determined as early in the trial procedure as possible. If the reasons presented are inappropriate, or a commitment to the concept is lacking, the prospective wearer should be discouraged from proceeding or an attempt should be made to re-educate the patient and modify their attitude.

73

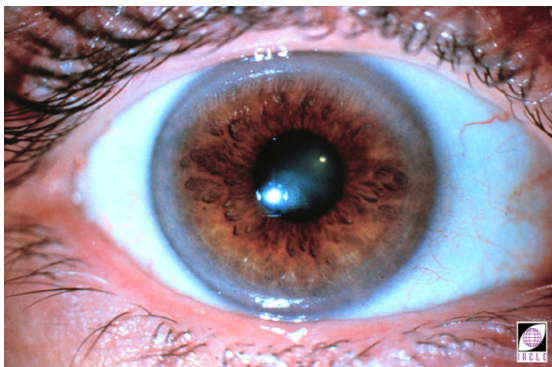
### COSMETIC ENHANCEMENT TRANSPARENT TINTS

- Dictated by:
  - colour and density of tint
  - underlying iris colour (colour mixing effect)
  - external lighting conditions
- Generally effective for minimally visible defects
  - mild scars, arcus senilis



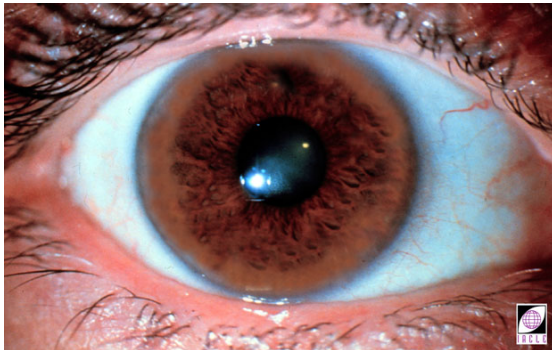
8L897711-33

74



8L80653-96

75



8L8653AMB-96

### Transparent Tints for Cosmetic Enhancement

Transparent tinted contact lenses can enhance ocular appearance in certain cases. A number of factors, other than the effect sought, warrant consideration before settling on a final lens. An important factor is the outcome of the combination of lighting condition, tint colour and natural iris colour.

Most patients use transparent tints to change or enhance their eye colour and may even have a series of lenses in various colours to use as fashion accessories.

Although the range of iris colours and their frequency of occurrence varies according to the population in question, Soni and Neuhoff (1985) showed that brown (39.7%), blue (35.4%), and green (10.7%) were the most common iris colours in the USA. The remaining eyes had colours that were more difficult to describe, i.e. required compound colour descriptions, e.g. blue-green.

In cases where there is a mild corneal scar/opacity, corneal arcus (slide 74) or similar corneal anomaly, a transparent tint can hide or minimize it to cosmetic advantage (slide 75).

Transparent tints are less effective at disguising iris anomalies such as iris coloboma, surgically-induced features such as a Peripheral Iridectomy and traumatic effects such as iridodiolysis.

76

### COSMETIC ENHANCEMENT CONSIDERATIONS

- Patient expectations
- Expectations of family and friends
- Patient education
- Functional eyes?
  - non or poorly-seeing eyes?



8L897711-34

### Cosmetic Enhancement Considerations

Patient, partner or family expectations can play a significant role in initiating the desire for cosmetic enhancement, acquiring tinted contact lenses and maintaining wearer motivation once initial success is achieved. Should a third party be central to the enhancement goal, it may be prudent to involve them in the subsequent steps, including patient education on lens insertion/removal and lens care.

If normal vision is attainable, it is probably unwise to give any other factor, including appearance, a higher priority than VA when choosing the lenses to be dispensed. Other factors may also need to be considered.




77

**COSMETIC ENHANCEMENT CONSIDERATIONS**

- Corneal health/physiology
- Psychological factors
- Greater expense
- Supplementary spectacles

97711-36S.PPT



8L897711-35

78

**COSMETIC ENHANCEMENT APPLICATIONS**

- General disorders
  - albinism
- Globe abnormalities
  - microphthalmos
- Corneal abnormalities
  - scars, dense arcus
  - failed grafts

97711-36S.PPT



8L897711-36

**Cosmetic Enhancement Lenses: Applications**

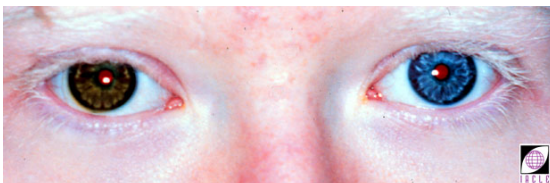Albinotic patients often gain much greater symptomatic relief from tinted contact lenses than from tinted spectacles. Improvement in both VA and cosmesis are the norm for such patients (slide 79 shows a tinted lens on the right eye only). The improvement in VA with these patients may be as good with a transparent tinted lens as with an iris-occluding design (Abadi and Papas, 1987).

Opaque tinted contact lenses are more suitable in cases of substantial scarring or ocular disfigurement such as iris or pupil anomalies. A lens with only a black pupil can be effective when there is a small central scar or a hypermature (white and obvious through the pupil) cataract (slide 80 and 81 are computer simulations to show the potential effect). A well-centred SCL is a suitable lens type.

Many iris disorders can cause diplopia or polyopia. The use of an opaque tinted lens, with or without a clear pupil, may reduce the visual disturbance experienced in these cases.

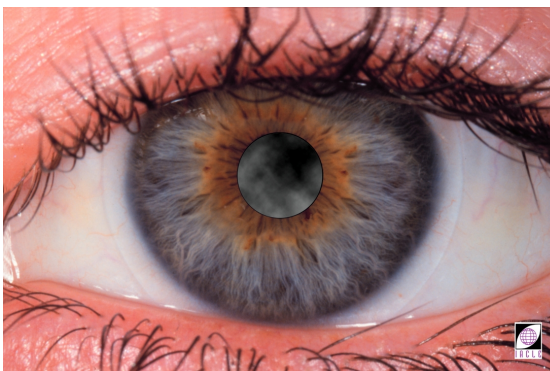Strabismic patients can also benefit from opaque tinted lenses. Phillips (1988) presented a case in which a strabismus was disguised by a soft lens incorporating an eccentric opaque hand-painted iris. A double-slab-off lens design was used to locate the lens reliably.

79



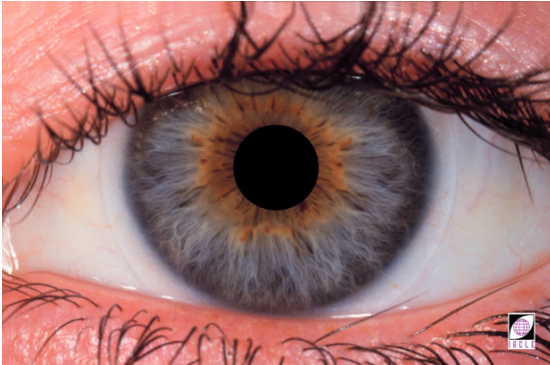8L80187-91

80



8L81174C-91

81



8L81174A-91

82

### COSMETIC ENHANCEMENT LENSES APPLICATIONS

- Crystalline lens:
  - cataracts
- Iris disorders:
  - aniridia, heterochromia, coloboma, iridectomy
- Pupil disorders:
  - displaced pupils, mydriasis

97711-37S.PPT



8L897711-37

83

### THERAPEUTIC APPLICATIONS

- Colour vision deficiencies
- Amblyopia
- Dyslexia

97711-39S.PPT



8L897711-39

### Tinted Contact Lenses: Therapeutic Applications

There are many applications for tinted contact lenses in therapeutic cases. This topic is covered in greater detail in Lecture 8.7 of this module.

84

### THERAPEUTIC APPLICATIONS COLOUR VISION

- Red-green deficiency
  - X-Chrom
  - ChromaGen
  - ColorMax
- Achromatopsia
  - red-tinted lenses

97711-40S.PPT



8L897711-40


### Colour Vision and Tinted Contact Lenses

For some patients with colour vision defects, the use of an appropriate tinted contact lens can assist discrimination of coloured objects. Discrimination is achieved by inducing a brightness difference between the colours confused by the colour defective observer.

For quite some time the use of a red-tinted contact lens in *one* eye has been proposed for patients with a red-green deficiency, i.e. an anomalous trichromacy or dichromacy. However, when the contact lens form of such a lens is used, e.g. an X-Chrom lens, blurred vision and interference with depth perception have been reported (Hartenbaum and Stack, 1997, Hartenbaum, 1998).

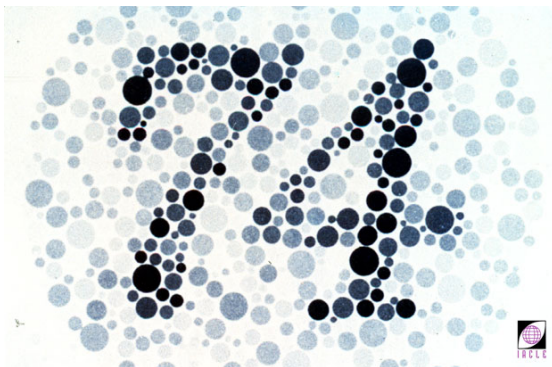

85



8L80144-92

86



8L80143-92

The Pulfrich Effect is also easy to demonstrate with such lenses because of the density of the red tint in front of one eye only.

The original X-Chrom lens was made in PMMA material. A soft X-Chrom lens made in the hefilcon A material was announced in 1987 (anonymous, 1987). It is possible to simulate the deep-red tint with a reactive dye on an SCL.

Slides 85 and 86 simulate colour confusion without a tint, and brightness differentiation with a suitable tint, on the same Ishihara plate. Despite its effects on the Ishihara Test, the X-Chrom lens has been found to offer little improvement in AO's Holmgren's wool test, especially in dim illumination (LaBissioniere, 1974).

Achromats can also benefit from wearing a red-tinted SCL in each eye. Such a lens has been shown to increase the achromat's ability to discriminate objects from one another by brightening the red-coloured objects while darkening the blue or green coloured objects.


The market for contact lenses that assist colour discrimination is potentially large since about 8% of all males have some form and degree of colour vision deficiency.

87

**THERAPEUTIC APPLICATIONS  
AMBLYOPIA**

- Occlusion therapy
  - offers advantages over patching
- Opaque, iris-diameter, tinted SCLs

97711-41.S.PPT



8L897711-41

### Amblyopia and Tinted Contact Lenses

The use of occlusion therapy in cases of amblyopia is common. With some young patients, it is difficult to keep the occluding device, e.g. a patch or frosted spectacle lens, in front of the eye to be patched. In other cases, just keeping the prescribed appliance on poses a problem.

A black opaque contact lens can provide an occlusive environment and the child is less likely to be bothered by this form of occlusion, provided the contact lens is comfortable. It must be remembered that the tint is not 100% occlusive. The appliance is also more difficult to dislodge accidentally or remove intentionally, thereby improving the level of compliance.

Alternatively, a non-tinted soft lens in a relatively high plus power can offer a reasonably effective occlusive effect with less effort and at a lower cost. Such an approach to "occlusion" uses defocus for its effect while retaining light perception and some degree of peripheral vision during the treatment periods.

88

**PROSTHETIC APPLIANCES**

- Following enucleation
- Conformers
- Impression technique
- Pre-formed shells

97711-428.PPT



8L897711-42

**Tinted Scleral Lenses: Prosthetic Applications**

Scleral lenses offer a number of advantages when used as a prosthetic correction. Advantages include:

- Available in various thicknesses.
- Eccentric iris images are possible and are useful in tropias.
- Hand-painted artwork is available if needed:
  - images of both iris and sclera;
  - image of iris only.

Combinations of opaque pupil and transparent tinted iris zones are also possible for special purposes, e.g. to occlude the eye while matching the tinted lens in the other eye.

Scleral lens applications are discussed more fully in Unit 9.4 of Module 9.

## IV Ordering Procedure and Specifications

89

### LENS ORDERING

Prior to ordering:

- Ensure lenses fit correctly
- Use trial lenses wherever possible
- Ensure correct tint:
  - colour desired?
  - a match for the other eye?
  - is the effect the one desired?

97711-43S.PPT



8L897711-43

### Ordering Tinted Contact Lenses

In all cases resulting in tinted contact lenses being dispensed, the practitioner should use appropriate trial lenses to ensure that the fitting characteristics of the lenses are acceptable.

In cases involving a unilateral fit, it is often difficult to match the appearance of the contralateral eye. Furthermore, a tinted lens that apparently matches the contralateral eye under certain lighting conditions may not match well under other conditions. (Remember to perform colour matches in outdoor or equivalent lighting.)

Generally, specialty tinted lenses take longer to manufacture, leading to longer delivery times and the prospective wearer should be made aware of this. Spare lenses should be ordered as soon as practicable after the successful completion of the initial lens fitting process. Many modern custom lens laboratories retain key lens data on file for as long as the patient's case remains active.

90

### LENS ORDERING

Prior to ordering:

- Use proper lighting when making colour comparisons
- Check availability of tints and designs
- Determine occupational and recreational considerations:
  - night driving
  - safety issues

97711-44S.PPT



8L897711-44

91

### LENS SPECIFICATIONS

- Provide proper colour code or realistic photo of iris to be matched
- Specify tinting style and design
  - laminated
  - hand-painted
  - printed
- Pupil size required (if any)

97711-45S.PPT



8L897711-45

### Specifications for Ordering Tinted Lenses

Lenses ordered from a manufacturer's stock require only the lens parameters and the type of tint. When lenses are to be custom-made, it is important for the practitioner to provide the tint details as accurately and as comprehensively as possible. The practitioner's requirements must be absolutely clear. Failure to make them clear will result in unnecessary delays, lens remakes or even an aborting of the process.

92

### LENS SPECIFICATIONS

- Iris diameter
- Colour density for custom-made transparent lenses
- Lens design and relevant parameters

97711-46S.PPT



8L897711-46

93

### IN-OFFICE TINTING

- Never particularly popular
- Few systems available currently
- Allows prompt delivery
- Makes non-standard tints possible
- Makes tinting of 'used' lenses possible
- Gives practice a marketable advantage

97711-575.PPT



8L897711-57

### In-Office Systems

Several in-office tinting systems have been offered to contact lens practitioners in the past. Examples include systems from American Hydron (the Hydron® OfficeTint™ System) and Softchrome (Softchrome® In-Office Tint System).

Precision-Cosmet Co. Inc developed a soft lens marking and identification system (Softmark®) for practitioners. Although described as having a photographic basis, it is essentially a form of lens tinting.

Features offered included:

- A clear pupil option.
- A choice between pupil-sized and iris-sized tints.
- Optional pupil sizes (for both clear and tinted).

In-office tinting did offer some potential advantages. These included:

- Prompt delivery of tinted lenses.
- The ability to provide non-standard tint shades and colours.
- The ability to tint lenses *after* lens fit and vision quality had been verified (see below).
- The ability to tint lenses in-house offers the practice a marketable advantage.
- It 'puts a little fun' into a contact lens practice (Koetting, 1986).

Few such systems are still available (the Softchrome system is detailed at: <http://www.softchrometinting.com/> as at: 2005-November). The reasons for their withdrawal include:

- Failure to gain approval from the relevant regulatory authorities.
- Tinting proved to be a time-consuming distraction to the core business of the practice, despite the fact that low spoilage rates were claimed (Koetting, 1986).
- The process proved to be less reproducible than desired in the hands of staff.
- The advent of opaque cosmetic lenses that often delivered what wearers really wanted, i.e. a change of eye colour. The latter was not possible with the transparent tints produced in-house.
- Process was limited initially to only one manufacturer-approved lens material (HEMA) (Akerman, 1986).
- Cost of equipment.

Occasionally, the need to mark soft lenses arises. Usually, this becomes necessary because toric lens rotational behaviour needs to be assessed or because a wearer has difficulty differentiating between their R and L lenses. One way is to use a marking pen whose ink is known to be stable, non-'bleeding' and heat resistant. One such marker is the Sanford Sharpie #3000-C, in black (Hallock, 1980). Other colours in the range are not suitable.

94

**TINTING 'USED' LENSES:  
A SAFETY ISSUE !**

- 'Used' (worn) lenses constitute a safety threat to any lens they may come in contact with, in any tinting process
- The threat is the same for all operators, in-office or commercial
- The ramifications are potentially greater for operators supplying national or international markets
- Labs should not be 'pressed' for favours

97711-69S.PPT



8L897711-69

**Tinting of 'Used' Lenses: A Safety Issue!**

Prudent commercial lens tinters refuse to handle 'used' contact lenses (clear or tinted) because they represent a serious threat to the safety and reputation of their business. Should a contaminated lens pass through their tinting system, there is the real possibility that other lenses may become contaminated, especially during the fixing/leaching step in which many lenses share a common bath. Large operators could find themselves an unwitting national, or even international, distributor of ocular disease. For this reason alone, contact lens practitioners should not pressure tinting laboratories to process 'used' (worn) lenses.

## V Patient and Lens Management

95

### PATIENT MANAGEMENT

- Confirm expectations are realistic
- Confirm motivation is strong enough
- Emphasize practical benefits

97711-47S.PPT



8L897711-47

### Management of Tinted Lens Wearers

It is important for the practitioner to identify and confirm the wearer's primary motivation for the wearing of tinted contact lenses. Factors relevant to patient management include:

- The need for vision correction/improvement.
- Cosmetic benefits.
- A wide choice of appearance options.
- Mode of wear: occasional or full-time.
- Evolutionary improvements made to a previously successful lens type.
- Cost factors.

While the emphasis is usually directed towards satisfying the patient, the practitioner must ensure that the expectations of the patient are realistic.

96

### TINTED CONTACT LENSES: REPLACEMENT CONSIDERATIONS

- Matching appearance difficult (original or replacement lenses)
- Many lenses not disposable
- Tinted lenses may be more expensive
- Lens care should be the most efficacious available, especially if lens is not replaced regularly
- Extending lens life is undesirable

97711-66S.PPT



8L8997711-66

### Tinted Contact Lenses: Replacement Considerations

A significant issue confronting the practitioner when fitting cosmetic opaque lenses arises when a lens is required for one eye that matches the colour and appearance of the contralateral eye.

Hand-painted irides, matching the normal iris of the contralateral eye, are placed on, or in, a cosmetic lens. In the vast majority of cases, the eye to be matched is not seen by the artist. This makes matching difficult due partly to the vagaries of the only alternative, i.e. the photographic process. Not only is this difficult with the first lens but it is equally or more difficult with subsequent lenses when lens replacement is contemplated. This leads to the temptation to prolong the 'life' of tinted lenses. Further, these lenses are invariably more expensive, adding another powerful reason to postpone replacement. Ultimately, the health of the eye can be placed in jeopardy by extending lens life beyond that which is prudent.

Extra care is required when prescribing lens care products and procedures in cases where lenses are not going to be replaced regularly. In such cases the practitioner should also pay particular attention to lens care and compliance issues at subsequent after-care visits.

97

### COMPLICATIONS DURING WEAR

- A wide range of complications are possible
- Consider oxygen transmissibility issues:
  - overwear
  - oedema
  - vascularization
- Keratitis
- Irregular astigmatism
  - corneal warpage

97711-48S.PPT



8L897711-48

### Complications Associated with Tinted Lenses

Tinted contact lenses must be treated in the same manner as any other type of lens. In some cases, cosmetic tinted lenses, especially those designed solely to change eye colour, may be treated with less respect by the wearer.


Laminated full-coverage opaque tinted lenses are necessarily thicker than transparent lenses. Their greater thickness results in reduced oxygen transmissibility. Signs of corneal oedema, such as stromal striae, are important indicators of an unsatisfactory physiological lens performance.



98

**LENS MANAGEMENT**

- Risk of tint discoloration with:
  - chlorine
  - organic peroxides
- Compliance with care and maintenance instructions
  - patient education
- Is frequent replacement possible?

97711-49S.PPT 

8L897711-49

### Lens Care and Maintenance

Appropriate care and maintenance instructions must be provided to the contact lens wearer.

Consideration must be given to the possibility that the tint may change over time due to the effects of lens care solutions and/or inappropriate use by the patient. Furthermore, the life expectancy of custom tinted lenses is usually greater. This necessitates a more serious approach to the selection and use of lens care products and procedures.

Where feasible, the frequent replacement of tinted hydrogel lenses should be considered. Frequent replacement is especially desirable in cases of full-time wear. This is based on the need to minimize the risk of CLPC.

Another consideration is the possibility of delamination of laminated opaque lenses by the release of gaseous oxygen at the laminate interfaces in H<sub>2</sub>O<sub>2</sub>-based lens care systems that use a liquid neutralizer. In such a system, the neutralizer may find its way into a laminated lens. The oxygen liberated within the lens can pry the lens layers apart. The obvious starting points for such parting are the interfaces between component layers.

99

**TINTED CONTACT LENSES: SUMMARY**

- Represent both an opportunity & a threat
- Most lens types can be tinted in some way
- Most needs can be satisfied by the wide range of tint types and colours available
- Lenses may be from stock or custom made

97711-65S.PPT 

8L897711-65

### Tinted Contact Lenses: Summary

The range of lenses available in stock form satisfies most of the legitimate tinted contact lens requirements. A custom lens can normally meet any special need that may arise.


Provided prudent standards are applied to the prescribing and supplying of tinted contact lenses, their potential for practice consolidation and expansion is significant.

Tinted contact lenses offer the wearer a greater array of lens options even to the extent of having different types of lenses for different occasions or applications.

100

**TINTED CONTACT LENSES: SUMMARY**

- Prescribing involves consideration of a greater number of factors than clear lenses
- Require the same standard of care and compliance on the wearer's part
- Costs differences range from nil to high

97711-67S.PPT 

8L897711-67

To the contact lens practitioner, tinted lenses offer practice opportunities not provided by clear lenses as well as adding another interesting facet to their professional activities.

 **References**

- Abadi RV, Papas E (1987). *Visual performance with artificial iris lenses*. J Brit Cont Lens Assoc. 10: 10 – 15.
- Ackerman DH (1986). *Hydron's new approach to tinting*. CL Forum. 11(3): 50 – 53.
- Anonymous (1987). *Soft X-Chrom lens developed*. CL News in: CL Forum. 12(8): 12.
- Astin CLK (1998). *The use of occluding tinted contact lenses*. CLAO J. 24(2): 125 – 127.
- Astin CLK (1998). *Practical hints when fitting tinted contact lenses for vision occlusion*. Clin Eye Vision Care. 10:85 – 88.
- Azizi RS (1996). *Cosmetic contact lens fit for traumatic aniridia*. Int Cont Lens Clin. 23(2): 72 – 75.
- Benjamin WJ, Rasmussen MA (1986). *EOP's of tinted gel lenses*. CL Spectrum. 1(2): 12 – 16.
- Bruce AS, Dain SJ (1988). *Spectral transmittance of UV-absorbing and colored contact lenses*. Int Cont Lens Clin. 15(9): 276 – 281.
- Bruce AS, et al. (1986). *Spectral transmittance of tinted hydrogel contact lenses*. Am J Optom Physiol Opt. 63: 941 – 947.
- Bucci FA, et al. (1997). *The annular tinted contact lens syndrome: Corneal topographic analysis of ring-shaped irregular astigmatism caused by annular tinted contact lenses*. CLAO J. 23(3): 161 – 167.
- Burger DS, London R (1993). *Soft opaque contact lenses in binocular vision problems*. J Am Optom Assoc. 64: 176 – 180.
- Chen T (1999). *Comfortable, safe, natural and beautiful: Innova's C.S.N.B. soft contact lenses*. Global Contact 22: 13 – 14.
- Chun MW, Weissman BA (1987). *Compliance in contact lens care*. Am J Optom Physiol Opt. 64(4): 274 – 276.
- Clements D, et al. (1988). *Corneal imprinting associated with wearing a tinted hydrogel lens*. CL Spectrum. 3: 65 – 67.
- Collins MJ, Carney LG (1986). *Compliance with care and maintenance procedures amongst contact lens wearers*. Clin Exp Optom. 69(5): 174 – 177.
- Cox ND (1991). *Pigmented contact lenses for prosthetic applications*. J Brit Cont Lens Assoc. 14: 145 – 147.
- Dain SJ, et al. (1993). *Transmittance characteristics of tinted hydrogel contact lenses intended to change iris colour*. Clin Exp Optom. 76: 74 – 79.
- Daniels K, et al. (1989). *Clinical evaluation of dot matrix hydrogel tinted lenses*. CL Spectrum. 4(8): 69 – 72.
- Davies I (1989). *The effect of tinted hydrogel lenses on iris colour*. Optician. 197(Oct. 6): 21 – 24.
- Gauthier CA, et al. (1992). *Clinical performance of two opaque, tinted soft contact lenses*. J Am Optom Assoc. 63(5): 344 – 349.
- Gentsch TF, Edrington TB (1990). *The bleaching effect of hydrogen peroxide on DuraSoft 3 Colors*. CL Spectrum. 5(7): 53 – 56.
- Grimm W, et al. (1977). *Tinted contact lenses and color discrimination*. Contacto. 21(6): 9 – 14.
- Hallock SJ (1980). *Dotting soft contact lenses*. J Am Optom Assoc. 3(3): 237.
- Hammack GG, Lowther GE (1986). *Transmission curves of tinted hydrogel lenses*. Int Eyecare. 2(10): 520 – 531.
- Hanks AJ (1984). *Cosmetic tinted contact lenses: a new soft lens option*. Eye Contact. 1(2): 5 – 10.
- Harris MG, Cabrera CR (1976). *Effect of tinted contact lenses on color vision*. J Optom Physiol Opt. 53(3): 145 – 148.

- Hartenbaum NP (1998). *Can corrective lenses effectively improve a color vision deficiency when normal color vision is required?* J Occup Environ Med. 40: 518 – 519.
- Hartenbaum NP, Stack CM (1997). *Color vision deficiency and the X-Chrom lens.* Occup Health Safety. 66(9): 36 – 40.
- Hovis JK, Sirkka D (1990). *Color discrimination of deutan and protan observers through tinted soft contact lenses.* Int Cont Lens Clin. 17(6): 287 – 295.
- Janoff LE (1988). *The effect of thirty cycles of hydrogen peroxide disinfection on Ciba Softcolor lenses.* Int Cont Lens Clin. 15(5): 155 – 164.
- Jurkus JM, et al. (1985). *The effect of tinted soft lenses on colour discrimination.* Int Eyecare. 1: 371 – 375.
- Key JE, Mobley CA (1987). *Cosmetic hydrogel lenses for therapeutic purposes.* Cont Lens Forum. 4: 18 – 22.
- Koetting RA (1986). *The business and pleasure of in-office tinting.* CL Spectrum. 1(3): 23 – 24.
- LaBissioniere PE (1974). *The X-Chrom lens.* Int Cont Lens Clin. 1(Winter): 48 – 55.
- Laxer M (1990). *Soft tinted contact lenses and color discrimination.* Int Cont Lens Clin. 17(2): 88 – 91.
- Lee DY, et al. (1990). *Effect of the opaque, colored dot-matrix contact lens on visual field.* Int Cont Lens Clin. 17(4): 188 – 191.
- Liebetreu M, et al. (1986). *Effect of chlorine on tinted hydrogel lenses.* Int Eyecare. 2(10): 525 – 531.
- Lobby P (1987). *Tinted lenses responsible for corneal distortion.* Rev Optom. 124(2): 114 – 118.
- Lowther G (1987). *A review of transparent hydrogel tinted lenses.* Contax. March: 6 – 9.
- Lutzi FG, et al. (1985). *Tinted hydrogel lenses permanency of tint.* Am J Optom Physiol Opt. 62(5): 329 – 333.
- Lutzi FG, et al. (1985b). *Tinted hydrogel lenses: An assessment of glare sensitivity reduction.* Am J Optom Physiol Opt. 62(7): 478 – 481.
- Mandell RB (as Ed.) (1974). *Why does the color look different on my eye?* Int Cont Lens Clin. 1(Winter): 36 – 37.
- Melton J (1987). *How and why DuraSoft Colors work.* CL Forum. 12(4): 71 – 75.
- Newcomer PC, Janoff LE (1977). *Methods of tinting Soflens® contact lens.* Am J Optom Physiol Opt. 54(3): 160 – 164.
- Phillips AJ (1989). *The use of a displaced, tinted zone, prosthetic hydrogel lens in the cosmetic improvement of a strabismic, scarred cornea.* Clin Exp Optom. 72(1): 1 – 2.
- Phillips AJ (1994). *Surface deposition and cracking of a tinted hydrogel contact lens.* Clin Exp Optom. 77(5): 210 – 214.
- Phillips LJ, Prevade SL (1993). *Replacement and care compliance in a planned replacement contact lens program.* J Am Optom Assoc. 64(3): 201 – 205.
- Pun HW, et al. (1986). *Tinted contact lenses slow reaction time in colour defective observers.* Clin Exp Optom. 69(6): 213 – 218.
- Radford CF, et al. (1993). *Contact lens hygiene compliance in a university population.* J Brit Cont Lens Assoc. 16(3): 105 – 111.
- Schlanger JL (1985). *The JLS lens: An aid for patients with color vision problems.* Am J Optom Physiol Opt. 62(2): 149 – 151.
- Schanzer MC, et al. (1989). *Irregular astigmatism induced by annular tinted contact lenses.* CLAO J. 15(3): 207 – 211.
- Sliney DH (1997). *Ocular injury due to light toxicity.* Optom Today. (UV Compendium Suppl. Nov/Dec): 17 – 23.

- Snell RS, Lemp MA (1998). *Clinical Anatomy of the Eye*. Blackwell Science Inc., Malden.
- Soni PS, Neuhoff LS (1985). *The distribution of iris coloration in the population*. *Int Cont Lens Clin*. 12(3): 170 – 174.
- Stanek SR, Yamane SJ (1985). *Do thermal disinfection systems harm tinted soft lenses?* *CL Forum*. 10(3): 35 – 39.
- Steffen RB, Barr JT (1993). *Clear versus opaque soft contact lenses: Initial comfort comparison*. *Int Cont Lens Clin*. 20(5): 184 – 185.
- Su KC (1992). *Chapter 30. Chemistry of Soft Contact Lens Materials*. In: Bennett ES, Weissman BA (Eds.), *Clinical Contact Lens Practice*. J.B. Lippincott Company, Philadelphia.
- Tan A, *et al.* (1987). *Colour vision and tinted contact lenses*. *Clin Exp Optom*. 70(3): 78 – 81.
- Trick LR, Egan DJ (1990). *Opaque tinted contact lenses and the visual field*. *Int Cont Lens Clin*. 17(4): 192 – 196.
- Zeltzer H (1971). *The X-Chrom lens*. *J Am Optom Assoc*. 42: 933 – 939.



## **Module 8: *Special Contact Lens Fitting***

---

# Unit 8.9

(1.5 Hours)

## Unit 8.9: Orthokeratology



## Course Overview

### Lecture 8.9: Orthokeratology

- I Introduction
- II Patient selection
- III Range and limitations of treatment
- IV Lens designs and fitting philosophies
- V After-care and ongoing treatment
- VI Problem solving

# Lecture 8.9

(1.5 Hours)

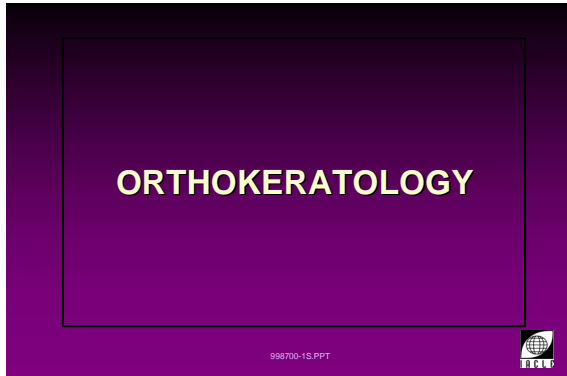
## Orthokeratology

## Table of Contents

I	Introduction to Orthokeratology .....	393
II	Orthokeratology: Patient Selection .....	408
III	Fitting Orthokeratology Lenses .....	413
IV	Orthokeratology: Adverse Responses and Infections .....	425
V	Recovery and Regression from Orthokeratology Lens Wear .....	429
VI	Orthokeratology: Myopia Control? .....	431
VII	Orthokeratology: Problem Solving .....	434

## I Introduction to Orthokeratology

1



8L9998700-1

### Orthokeratology

Orthokeratology is the logical extension of the early (in the late 1950s/early 1960s) observation by contact lens practitioners that rigid contact lenses (PMMA originally) can modify the shape of the cornea and/or alter the eye's refractive state.

In its original form, orthokeratology sought to flatten the cornea progressively using a series of contact lenses to effect a reduction in myopia and an improvement in unaided vision.

Once the desired level of vision was achieved, or the maximum effect possible was reached, a schedule of so-called 'retainer' lens wear was instigated. Such a schedule aimed to maintain the gains achieved. Subsequently, retainer-lens usage was reduced by decreasing the duration and/or frequency of lens wear.

Ultimately, the goal was to minimize the use of any lenses, particularly during the day, while maintaining good vision at all other times.

Orthokeratology in its original form was introduced in the early 1960s. The technique has had a chequered history with claims that it is a 'cure' for myopia tempered by the data from controlled clinical trials (one of the earliest being by Holden [1970]).

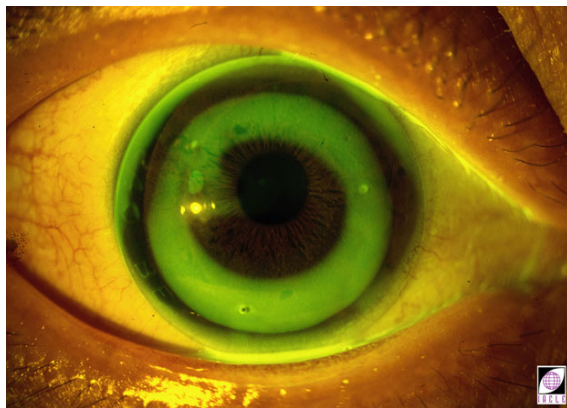
The advent of computer-controlled contact lens manufacturing technology stimulated the development of new and better RGP lens designs for orthokeratology. These lens designs offer greater stability in fitting and more controlled refractive changes, usually requiring fewer lenses (often only one pair [Swarbrick, 2004]).

Slide 2 shows a modern orthokeratology contact lens (Mountford's BE lens in this particular case, the fenestrations are uncommon in other lens designs) for the treatment of myopia. A large central zone of benign bearing is surrounded by an annular ring of fluorescein pooling commonly known as the tear reservoir.

In a recent study (Lipson *et al.*, 2005), overnight corneal reshaping (OCR) was compared with SCLs. At the end of the study almost 68% of subjects chose to continue with OCR and 32% preferred two-weekly, DW SCLs.

Lipson *et al.* reported that SCLs gave better acuity and less glare in mildly myopic subjects, while OCR subjects had fewer symptoms, were less dependent on an optical correction, and experienced fewer limitations on their activities. The authors also reported that those that preferred OCR tended to be less myopic and had steeper corneas.

2




8L9FIG01

3

**ORTHOKERATOLOGY**

- **ORTHO** | **KERAT** | **LOGY**
- Straight | cornea | knowledge
- Greek derivation
- Aim is to 'reshape' the cornea
- a non-surgical, topographical approach to effecting a correction

998700-2S.PPT



8L9998700-2

4

**ORTHOKERATOLOGY**  
**ALTERNATIVE TERMINOLOGY**

- Corneal Reshaping Therapy™ (CRT™)
- Vision Shaping Treatment™ (VST™)
- Corneal Refractive Therapy™
- Accelerated Orthokeratology
- Corneal Corrective Contacts
- Eccentricity Zero Molding™
- Gentle Vision Shaping System™
- Overnight Corneal Reshaping

998700-56S.PPT 

8L9998700-56

5

**ORTHOKERATOLOGY**  
**ALTERNATIVE TERMINOLOGY**

- Reversible Corneal Therapy
- Compression Ortho-K
- Controlled Kerato-Reformation (CKR)
- Corneal Molding System (CMS)
- CL Corneal Reshaping
- Overnight Orthokeratology (OOK)


998700-78S.PPT 

8L9998700-78

6

**ORTHOKERATOLOGY**  
**RESULTS**

- Effective and relatively safe way of reducing or eliminating manifest refractive error
  - mainly for myopia (hyperopia not yet treated routinely)
  - impermanent
- Subject to significant variability
  - within an individual
  - between individuals


998700-137S.PPT 

8L9998700-137

7

**ORTHOKERATOLOGY**  
**DEFINITION**

**Ziff (1968):**  
‘the systematic and purposeful designing of contact lenses to change corneal curvature, which will result in emmetropia of the eye, as applied to patients with myopia, hyperopia, and astigmatism’

998700-138S.PPT 

8L9998700-138

**Definition of Orthokeratology**

Orthokeratology aims to reduce myopia and improve unaided VA. This is achieved by using an RGP lens (usually, although the possible role siloxane hydrogels may play is being investigated) to induce a regular change in corneal shape so that the prolate (usually) elliptical cornea becomes flatter centrally. Reductions in corneal astigmatism can also be effected.


Mountford (1997B) defined orthokeratology as ‘the reduction, modification or elimination of a visual defect by the programmed application of contact lenses’, i.e. a definition, similar to that of Grant and May (1971). However, orthokeratologists do not consider hyperopia to be a routine pursuit, yet.

8

**ORTHOKERATOLOGY  
DEFINITION**

Grant and May, 1971

- 'The reduction, modification, or elimination of a visual defect by the programmed application of contact lenses or other related procedures'
- Achieved by remodeling the anterior refracting surface of the eye



8L9998700-4


Orthokeratology provides the practitioner with a reversible, temporary, contact lens option that can compete with refractive surgery, albeit over a narrower range of refractive errors.

The continued clinical development of RGP lens designs and advances in lens manufacturing technology may result in the application of orthokeratology techniques routinely to the correction of low degrees of hyperopia.

9

**ORTHOKERATOLOGY  
DEFINITION**

- Kerns (1976): 'a purposeful attempt to modify the corneal curvature to result in a reduction or elimination of a refractive anomaly by a programmed application of contact lenses'




8L9998700-139

10

**ORTHOKERATOLOGY  
HISTORY** after Coon, 1982

- Reportedly, the Chinese applied loads (small sand bags) to closed eyelids during sleep to ↓ myopia
- E.Kalt (1888), glass sclerals to 'flatten' keratoconic apices
- 1950s and 1960s, CL practitioners observed CL-induced refractive changes (↑ & ↓)
- 1959: Farnum: corneal distortion often ← decentered lens
- 1962: Jessen reported on his 'deliberate effort' (his orthofocus techniques) to harness these changes beneficially (for both myopia & hyperopia)
- 1962: Jessen founds the *Society of Orthokeratology*



8L9998700-67

**Orthokeratology: History**


Some of the history of orthokeratology (after Coon, 1982) appears in the slides opposite along with one of the lens designs used in a major university-based study (1976–1979) (slide 20) of orthokeratology (Coon, 1984). It is recorded that Jessen (1962) was the first to present information on the use of RGP lenses to reduce myopia. Jessen (1964) also reported on his hyperopia treatment trials using steeper-than-K lenses claiming up to 3.50 D of correction, albeit with corneal oedema (PMMA lenses were the only lenses available at that time). Recently, Swarbrick *et al.* (2004) studied apical clearance lens fittings and found (as many contact lens practitioners have observed) that corneal steepening resulted. The steepening was postulated to be due to molding, corneal oedema, and post-lens tear film pressures.

11

**ORTHOKERATOLOGY  
'ORTHOFOCUS' TECHNIQUE**

Jessen, 1962

- First to attempt to change refractive error deliberately
- Technique used plano PMMA lenses
- Flat central fitting



8L9998700-5


It is noteworthy that much of this early work has little relevance to orthokeratology as we now know it, because the fitting philosophies, lens designs, and lens materials in use today bear little resemblance to those used before about 1990. A major limiting factor at the time was the relatively limited range and complexity of lens surface shapes that were possible with the manufacturing technology of the day.



12

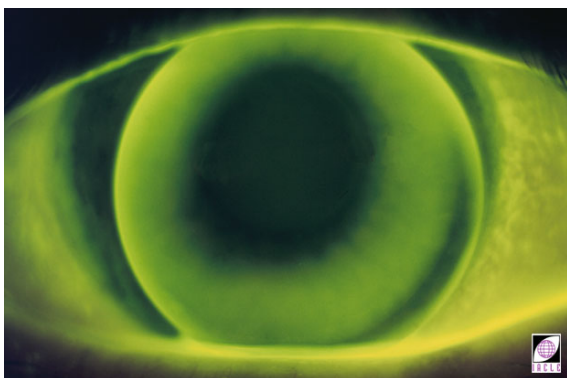
**ORTHOKERATOLOGY HISTORY**

- 1963: Neilson, May, and Grant present paper *Emmetropization through Contact Lenses*
- 1964: Neilson, May, and Grant publish paper *Emmetropization through Contact Lenses*
  - use lenses only slightly (0.12 – 0.37 D) flatter than Ks
  - subsequent lenses 'track' changing Ks, maintaining a similar (i.e. slightly flat) fitting relationship at each step
- 1964: Jessen uses his 'cycon' lens to ↓ astigmatism
- Hyperopia correction largely abandoned because of the significant corneal oedema induced

998700-68S.PPT 

8L9998700-68

13




8L9 FLAT-FITTING CONVENTIONAL 1960S

14

**ORTHOKERATOLOGY HISTORY**

- 1965: Ziff reported the first study of orthokeratology's predictability based on original Ks
  - steeper eyes flattened the most
  - some flatter eyes steepened
  - some remained unchanged
- 1966: Ziff reports tailoring the orthokeratology lens to the original Ks
  - initially, BOZD 7.6 mm, TD 9 mm
  - both parameters ↓ by 0.1 mm for each 0.5 D of corneal flattening achieved
  - first to advocate night retainer lenses (multiple fenestrations [using a LASER] to improve Dk/t)
- 1970: Nolan used flat lenses on myopes <-2.25 D


998700-69S.PPT 

8L9998700-69

15

**ORTHOKERATOLOGY HISTORY**

- 1971: Paige alternated between very flat lenses and aligned or slightly-flat lenses
  - claimed this sped-up the process
- 1971 - 1973: Gates & Freeman fitted lenses just 1.5 D flatter than flattest K (other workers used much flatter lenses)
- 1972: Fontana used a modified C-N bifocal CL (centre 1 D flatter than nominal BOZR)
  - 48 of 50 patients showed ↓ in myopia & ↑ in VA
  - arguably, this was the first step towards 'modern' Ortho-K lens design
- 1972: Nolan switched to using steeper rather than flatter lenses

998700-70S.PPT 

8L9998700-70

In the early 1960s, Jessen recorded what lens features were required to effect a good orthokeratological outcome. His suggestion approximated current designs, indicating he had a sound understanding of what he was trying to achieve and how it might be realized in practice. Unfortunately for the discipline, the lens designs envisaged by Jessen (and possibly his contemporaries) could not be made with the manufacturing technologies available at the time.

Interestingly, despite the various early approaches used, the outcomes were almost always very similar:

- About a 1 D reduction in myopia on average.
- The results were not especially predictable.
- Lens wear could induce corneal astigmatism.
- Large individual variations in final results were exhibited (Swarbrick, 2004).

Arguably, the orthokeratology lenses employed before the modern generation of lenses could be referred to collectively as being of 'conventional geometry', i.e. their back peripheral curves were all progressively flatter (longer radii) than the central (optical) curve (slide 13).

16

### ORTHOKERATOLOGY HISTORY

- Early 1970s: Limit of change about  $-1.5$  D
  - $-2$  D myopes could not be given 6/6 VA
- 1970 – 1975: Grant & May:  $-3$  to  $-4$  D the 'practical limit'
- 1970 – 1974: May & Grant use photokeratoscopy to monitor corneal changes and as an aid to CL fitting
  - their Ortho-K data over 6 years suggested myopia reduction
- 1975 – 1977: May & Grant: 58% of wearers need 'retainer' lenses full-time to retain gains

998700-71S.PPT



8L9998700-71

17

### ORTHOKERATOLOGY HISTORY

- 1976 – 1978: Kerns publishes articles on orthokeratology
  - used progressively flatter CLs
  - $\Delta$  corneal thickness identified
  - generally, shown to be safe
- 1976: Freeman uses lenses with a flatter, aspheric periphery and either an alignment or slightly steeper central zone
  - claims  $\downarrow \leq 2.5$  D
  - spherical corneas did not respond well
  - believed orthokeratology changes were mid-peripheral

998700-72S.PPT



8L9998700-72

18

### ORTHOKERATOLOGY HISTORY

- 1977: May & Grant report that orthokeratology  $\leftarrow$  central corneal flattening and mid-peripheral steepening - they called this 'sphericalization'
- 1977: By calculation, Erickson & Thorn estimate 90% of orthokeratology Rx changes are corneal
- 1978: Shed reported that greater success was possible with non-astigmatic, prolate corneas
- 1980: Binder (with May & Grant) publishes reports on orthokeratology – generally, shown to be safe

998700-73S.PPT



8L9998700-73

19

### ORTHOKERATOLOGY HISTORY

- 1981: Coon reports that Tabb used slightly steeper than K lenses successfully (as did Nolan in 1972)
  - achieved better centration than flat-fitting lenses
  - changed BOZD rather than BOZR  $\rightarrow$  more subtle changes
  - effect was due to mid-peripheral/peripheral steepening
    - this is the partial basis of modern Ortho-K
- 1982: Report published on Pacific U. orthokeratology study (1976–1979) using the Tabb method
  - corneal shape changed from prolate to spherical or even oblate sections
  - experimental group included 'good' and 'poor' responders
  - no predictors of responder type were identified

998700-74S.PPT



8L9998700-74

20

**ORTHOKERATOLOGY HISTORY: TABB LENS**

Apical clearance fit PMMA (1976-1979)

BOZR

BOZR + 1 mm  
0.2 mm wide

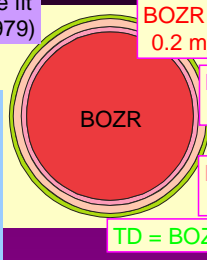
BOZR + 2 mm  
0.35 mm wide

BOZR + 3 mm  
0.2 mm wide

TD = BOZR + 1 mm

BOZD<sub>Initial</sub> calculated to cover 32.5% of total lens area. This is increased progressively in 2.5% steps to a maximum of 45%

998700-75S.PPT



8L9998700-75

21

**ORTHOKERATOLOGY HISTORY**

- 1983: *The Berkeley Orthokeratology Study* published
  - 40 treated, 40 controls (data from 31 & 28 respectively)
  - 1.5 years
  - treated: 6 lenses per eye controls: 3 lenses per eye
  - treatment lenses: larger, thicker, fitted flatter
  - $\Delta$  treated:  $\downarrow$  1.01 D controls:  $\downarrow$  0.54 D (after 444 days)
  - corneal curvature  $\downarrow$  by about half the Rx change
  - most change occurred in the first 132 days
  - $\Delta$ s fluctuated, greatest fluctuation in those showing most  $\Delta$
  - 95 days after wear cessation, 75% recovery shown for Rx, VA and K changes (69% in the control group)
  - concluded: changes not permanent &  $\downarrow$ 1D was possible
  - VA during non-wear periods (no retainer) was unstable
  - orthokeratology was safe but required more after-care

998700-77S.PPT

8L9998700-77

22

**ORTHOKERATOLOGY HISTORY: THE MODERN ERA**

- 1992: Harris & Stoyan publish *A new approach to orthokeratology*
- 1993: Wlodyga & Harris publish *Accelerated Orthokeratology*
- 1997: Mountford publishes 'corneal sag matching' fitting method ( $Sag_{lens} = Sag_{cornea} + 10 \mu m$ )
- 1997: DreamLens™ introduced (DreimLens Inc.)
- 1998-Apr-8: Contex® OK® Airperm (siflufocan A) 'reverse geometry' lens approved DW,  $\leq 3$  D myopia

998700-79S.PPT

8L9998700-79

23

**ORTHOKERATOLOGY HISTORY: THE MODERN ERA**

- 2002: Paragon CRT approved for O/N corneal reshaping
- 2004: Euclid Orthokeratology lens approved for O/N corneal reshaping
- 2004: B&L acquires Euclid (and its FDA approval)
- 2004: JZS Orthokeratology lens licensed from Euclid

998700-80S.PPT

8L9998700-80

**Accelerated Orthokeratology: The Rise of 'Reverse Geometry' Lenses**

Jessen (1962) hypothesized that the ideal lens was one that was flatter in the centre (to flatten the corneal apex) and steeper in the periphery (to centre the lens). Such a design was, and still is, referred to as a 'reverse geometry' contact lens because the peripheral curves are the reverse of a 'conventional' RGP lens design in which the radii of the peripheral curves are *flatter* than the BOZR. However, because such lenses were difficult or impossible to manufacture, it was Fontana (1972 cited in Barr *et al.* [2003] and [Caroline, 2005 - personal communication]) who was the first to use a 'reverse' geometry lens for orthokeratology. Fontana used lenses whose BOZR was 1 D flatter than K but with the periphery fitted on K. While these lenses were of 'reverse' geometry, they were not of the 'reverse geometry' designs now in use.

In the period 1989 to 1992, Harris, Wlodyga, Bryla, and Stoyan (slide 25), but especially Wlodyga and Stoyan (Swarbrick, 2004), investigated the efficacy of orthokeratology using RGP lenses whose peripheral curves had radii *steeper* than their BOZRs. The early lenses were so-called 3-zone designs (see slide 27).

Further work on reverse geometry lenses of a 4-zone design (see slide 28) was done independently by El Hage (CKR), Blackburn (OrthoFocus), and Reim (DreamLens™).

24

**REVERSE GEOMETRY LENSES**  
Examples of *Contex* OK lenses

Designation	BOZD (mm)	BPR, steeper than BOZR (D)
605	6.00	5.00
651	6.50	1.00
704	7.00	4.00
758	7.50	8.00
809	8.00	9.00

998700-9S.PPT

8L9998700-9

25

**ACCELERATED ORTHO-K**

- Technique developed by Wlodyga and Stoyan
- Reverse geometry RGP lenses
  - first peripheral curve **steeper** than BOZR
- Improved centration
- Produces a rapid and stable change in corneal curvature
  - closer to an ideal result
- Fewer lenses required (often one pair only)

998700-6S.PPT

8L9998700-6

The steeper peripheral curves allow greater control of lens centration and minimization of unwanted induced irregular astigmatism or WTR astigmatism, common 'complications' with early orthokeratology lens designs.

Modern reverse geometry lenses, especially 4-zone lenses:

- Induce rapid changes in the corneal shape.
- Centre well.
- Have relatively large treatment zones.
- Show good retention of effect, e.g. all day when treatment lens is worn overnight.
- Are referred to generically as 'accelerated orthokeratology' designs.

Many such lens designs are now available to the orthokeratology practitioner. The development of these lenses has enabled the practitioner to simplify the process of changing the corneal shape.

In many cases, a single lens fitting can achieve the desired reduction in myopia very rapidly (over a few days, e.g. 7 days [Nichols *et al.*, 2000; Soni *et al.*, 2003], 7 to 10 days [Swarbrick, 2004, Sorbara *et al.*, 2005] with the greatest change often occurring over the first episode of overnight wear [75% of the maximum effect after just 1 night of treatment lens wear [Swarbrick, 2004]). The use of numerous lenses each progressively flatter than the previous lens, has been largely relegated to the history books.

26

**ORTHOKERATOLOGY**  
**EARLY REVERSE GEOMETRY LENSES**

- Fitted 0.3 - 0.5 mm flatter than  $K_{flat}$ 
  - depends on corneal cyl
- Width of the tear reservoir may indicate the extent of possible further corneal change
- Steep periphery aids tear exchange and centration
- Larger diameters may be required
- Maximum effect may take some time

998700-7S.PPT

8L9998700-7

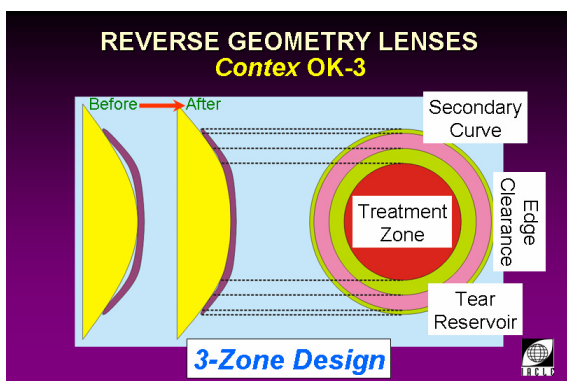
**Early Reverse Geometry Lens Design**

Reverse geometry RGP lenses can be produced in a range of back surface shapes. An OK-3, 3-curve design (ignoring the edge finish), an example of an early reverse curve lens, appears in slide 27. Slide 27 includes the fitting pattern as well as the lens and corneal profiles.

A typical range of early lenses would be:

- BOZD from 6.0 to 8.0 mm.
- $PCW_1$  from 0.5 to 1.8 mm.
- $BPR_1$  from 0.2 to 1.8 mm *steeper* than the BOZR.
- $PCW_2$  is about 0.5 mm.
- $PCR_2$  is about 0.6 mm *flatter* than the BOZR.
- TD ranges from 8.5 to 12.2mm.

27



8L9998700-84


The peripheral curves may be spherical or aspherical. In one design (Paragon CRT), the peripheral curves are tangential to the cornea and a cone-angle is used to describe/define the design of that zone of the lens.

One example of such early designs, the Contex Ortho-K 60, was claimed to achieve its effects in 30 to 60 days (Wlodyga and Bryla, 1989). Central and peripheral keratometry were performed with a standard, one-position keratometer using the '+' signs on the keratometer's mire object plate as


28

**REVERSE GEOMETRY LENSES**

- Centre well
- Apply little or no load to the corneal apex (5 µm clearance)
- Are supported by their periphery



**4-Zone Design**



8L9998700-141

fixation targets. Using Contex OK-3 lenses, Harris and Stoyan (1992) suggested that up to 5 to 6 D of myopia could be treated successfully and the approximate amount achievable could be predicted by doubling the difference between central and peripheral K readings.


Some current 4-zone designs (slide 28) retain the concept of the lens mid-periphery having a tangential fitting relationship to the cornea locally.

29

**MODERN ORTHOKERATOLOGY DRIVING TECHNOLOGIES**

- Advances in RGP orthokeratology lens design
- Advances in numerical control of lens lathes allowing greater design complexity & better reproducibility
- Development of stable, wettable, high-Dk RGP materials
- Advances in corneal topographers & lens fitting software
- Greater understanding of the orthokeratology process

998700-142S.PPT



8L9998700-142

**Modern Orthokeratology: Stimuli to Progress**


The slide opposite summarizes Caroline and Choo's (2003) views on the technologies that made modern orthokeratology possible.

30

**ORTHOKERATOLOGY EFFECTS**

- Significant change in corneal curvature
- Accompanying topographical change in corneal thickness:
  - primarily epithelial
  - central thinning
  - mid-peripheral thickening
  - possible alteration to corneal sagittal height

998700-40S.PPT



8L9998700-40

**Effects of Orthokeratology**

The current understanding of orthokeratology, according to Caroline (2001), indicates that the flatter central fitting relationship results in a positive pressure or applanating force on the cornea. The thin tear film beneath the centre of the lens (5 µm is considered the minimum acceptable thickness [Caroline, 2005 personal communication]). It creates thin-layer shear forces beneath the lens that move tangentially across the epithelium. The flat lens-to-cornea fitting relationship induces a possible compression and/or redistribution of the corneal tissue.


The enclosed space beneath a contact lens combined with lens rigidity also means that pressure applied to or by the lens at one location has effects in some or all other locations under the lens.

31

**ORTHOKERATOLOGY POSSIBLE MECHANISMS: MYOPIA**

- Corneal 'bending'
- Epithelial thinning (centre)
  - compression thinning (applied pressure)
  - decrease in number of cell layers
- Epithelial thickening (mid-periphery)
  - cell enlargement
  - increase in number of cell layers
- Tissue redistribution/cell migration centre → ?
  - ↑ or ↓ cell retention
  - ↓ or ↑ cell sloughing (apoptosis)
  - ↓ or ↑ cell mitosis
- ↑ or ↓ stromal thickness (location dependent)
- Water movement/cell dehydration?

998700-61S.PPT



8L9998700-61

Within an enclosed liquid, e.g. the tear fluid in the space beneath the treatment zone, the pressure is uniform at all locations (assuming a homogenous fluid and no turbulence within it). This means that under an orthokeratology lens there may be higher pressure points, e.g. the centre and peripheral zones of bearing and possibly lower pressure points, e.g. the uniform pressure applied to the cornea by the tears under the treatment zone where there is no direct lens bearing.

Sealing of the space under a lens is effected by the mucin layer of the tears whose viscosity tends




32

**ORTHOKERATOLOGY**  
**POSSIBLE MECHANISMS: HYPEROPIA**

- Corneal 'bending'
- Epithelial thickening (centre)
  - increase in number of cell layers
- Epithelial thinning (mid-periphery)
  - compression thinning (applied pressure)
- Tissue redistribution/cell migration centre ← ?
  - ↑ or ↓ cell retention
  - ↓ or ↑ cell sloughing (apoptosis)
  - ↓ or ↑ cell mitosis
- ↑ or ↓ stromal thickness (location dependent)
- Water movement/cell dehydration?

998700-63S.PPT




8L9998700-63


33

**CORNEAL EPITHELIUM**

Layer	Thickness (µm)
Epithelium	60
Bowman's layer	6
Stroma	450
Descemet's membrane	10
Endothelium	6



998700-132S.PPT




8L9998700-132

34

**ORTHOKERATOLOGY EFFECTS**

- Thickness changes are sufficient to explain myopia reduction
  - anterior corneal phenomenon
  - not an overall bending of the cornea
- Munnerlyn's formula
  - estimates the amount of tissue displaced

998700-41S.PPT



8L9998700-41

35


**THE MUNNERLYN FORMULA**

$$S = t_d^2 \times \frac{D}{3}$$

S = Change in corneal sagittal height (µm)  
 t<sub>d</sub> = Treatment zone diameter (mm)  
 D = Desired dioptric change (dioptries)

**An example:**  
 For a 1 D effect over a 6 mm zone, you will 'lose' (or redistribute) 12 µm of corneal tissue

998700-128S.PPT



8L9998700-128

to slow (dampen) any tendency for the tears to be expelled from under the lens. It is conceivable that under some circumstances, e.g. external pressure applied to the centre of a lens, lens flexure may result in a reduction in the pressure applied to the cornea in the treatment zone (assuming the sealing of the enclosed space is maintained). However, it is highly unlikely that the resulting pressure applied to the cornea in the treatment zone would be 'less than external atmospheric pressure', a common definition of 'negative' pressure. Therefore, although the pressure applied to the treatment zone may be less positive than other areas under the lens, it is not 'negative'. The lids are the most likely source of external lens pressures, causing pressure to rise with each blink. Eye movement may affect this applied pressure positively or negatively.

Swarbrick *et al.* (1998) and later, Alharbi and Swarbrick (2003) and Sridharan and Swarbrick (2003) demonstrated that accelerated orthokeratology induces a rapid change (VA improved in just 10 minutes, see also Jackson *et al.*, 2004 for a similar finding) in anterior corneal curvature that is accompanied by a significant change in topographical corneal thickness. These changes include *thinning* of the central epithelial zone and *thickening* of the mid-peripheral stroma at the edge of the flattened zone. Importantly, this results in a reduction in the corneal sagittal height and therefore a decrease in manifest myopia.

When the amount of change in (epithelial) thickness of the cornea in orthokeratology treatments is mentioned, it is appropriate to remember that the corneal epithelium has a normal thickness of approximately 50 to 60 µm (slide 33, section courtesy Dr Meg Evans, Sydney).


Soni *et al.* (2003) reported an epithelial change (thinning) of 19 µm after 3 months of overnight orthokeratology lens wear.

The magnitude of these changes suggests that the posterior corneal curvature does not change during orthokeratology (see below). The refractive shift is due to the change in corneal curvature. While it was initially thought that this amounted to corneal sphericalization, i.e. to a more spherical shape, more recent research suggests that meridional differences are largely retained, e.g. Soni *et al.*, 2003, Soni *et al.*, 2004. However, Garner and Owen (2004) did report posterior corneal changes in orthokeratology while Berke (2005) reported no change.

Originally, the sphericalization was believed to be a result of a redistribution of anterior corneal epithelial and stromal tissue. It has been suggested (Mountford, 1997) that the epithelium is sensitive to stress and will 'flow' to bring about an equalization of force. This, Mountford suggests, occurs over the smallest possible surface area and that is a sphere.



36



8L9FIG02

The amount of tissue displaced in orthokeratology can be calculated using Munnerlyn's formula (originally developed for PRK ablation depth computations) that relates the change in corneal sagittal height to the treatment zone diameter and the power change required. The simplified version of the formula is:

$$s = t_d^2 \times \frac{D}{3}$$

$s$  is the absolute sagittal height change ( $\mu\text{m}$ ),  $t_d$  is the treatment zone diameter (mm), and  $D$  is the intended refractive change (dioptres). An assumption is made that the posterior cornea does not alter shape during the process (Caroline and Choo, 2003, also see Garner and Owen, 2004 for an opposing finding).

37

**ORTHOKERATOLOGY TREATMENT ZONE DIAMETER**

- Controls degree of myopia reduction
- Smaller zone required for higher Rx's
- Cornea remains spherical ( $e = 0$ ) over the treatment zone diameter

998700-42S.PPT

8L9998700-42

According to Mountford, the mean maximum sag change for the cornea in orthokeratology is approximately  $20 \mu\text{m}$ . The limit of the orthokeratology procedure occurs when the cornea takes on a spherical shape. The degree of myopia reduction achieved is dependent on the diameter over which the cornea is spherical; with completely spherical corneas ( $e = 0$ ) generally not amenable to orthokeratology. Higher refractive changes are possible if the spherical treatment zone is made smaller (slide 38 and 39). Likewise, less sagittal change is required for a specific target dioptric change as treatment diameter decreases (slide 38). Slide 40 shows 'per dioptre' data *versus* zone size. By inspection it can be seen that across a 6 mm optic zone/treatment diameter it takes approximately  $12 \mu\text{m}$  of flattening per dioptre.

38

**TREATMENT DIAMETER VS DIOPTRIC CHANGE FOR A FIXED SAGITTAL DEPTH CHANGE (i.e. A FLATTENING/THINNING)**

Treatment depth (Flattening / thinning)	Treatment diameter (Optic zone)	Expected change
20 $\mu\text{m}$	6.0 mm	-1.75 D
20 $\mu\text{m}$	5.0 mm	-2.50 D
20 $\mu\text{m}$	4.0 mm	-3.75 D
20 $\mu\text{m}$	3.0 mm	-6.75 D

998700-125S.PPT

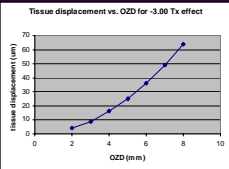
8L9998700-129

A very small treatment zone is not desirable due to the vision problems associated with larger pupil sizes especially under conditions of reduced illumination. High refractive changes with orthokeratology lenses are an exception rather than the norm and usually require the use of a second set of lenses to maintain and extend the change achieved with the first set of lenses.

39

**ORTHOKERATOLOGY -3.00 D TREATMENT**

Tissue displacement vs. OZD for -3.00 Tx effect



BOZD	Tissue Displacement
3 mm	9 $\mu\text{m}$
4 mm	16 $\mu\text{m}$
5 mm	25 $\mu\text{m}$
6 mm	36 $\mu\text{m}$
7 mm	49 $\mu\text{m}$

998700-131S.PPT

8L9998700-131

Improvements in unaided vision following overnight orthokeratology are sustained for at least 6 hours after lens removal (Rah *et al.*, 2002).


Slide 41 tabulates some literature results achieved in studies reported.

40

**TREATMENT DIAMETER VS SAGITTAL DEPTH CHANGE TO ACHIEVE A FIXED DIOPTRIC CHANGE**

Treatment depth (Flattening/thinning)	Treatment diameter (‘Optic zone’)	Expected change
5 µm	2-3 mm	-1.00 D
7 µm	3-4 mm	-1.00 D
9 µm	4-5 mm	-1.00 D
11 µm	5-6 mm	-1.00 D
13 µm	6-7 mm	-1.00 D
15 µm	7-8 mm	-1.00 D

998700-130S.PPT



8L9998700-130


41

**ORTHOKERATOLOGY**  
WHAT REDUCTION CAN BE ACHIEVED?

Summary from: Swarbrick, 2004

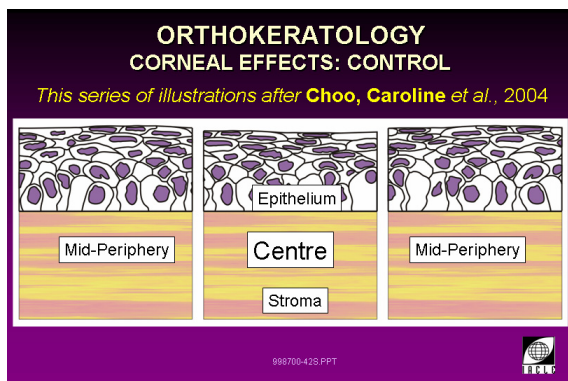
• Mountford, 1997	2.19 ±0.57 D
• Nichols <i>et al.</i> , 2000	1.83 ±1.23 D
• Rah <i>et al.</i> , 2002	2.08 ±1.11 D
• Soni <i>et al.</i> , 2003	2.12 D
• Tahhan <i>et al.</i> , 2003	≈2 D
• Alharbi & Swarbrick, 2003	2.63 ±0.57 D

998700-143S.PPT



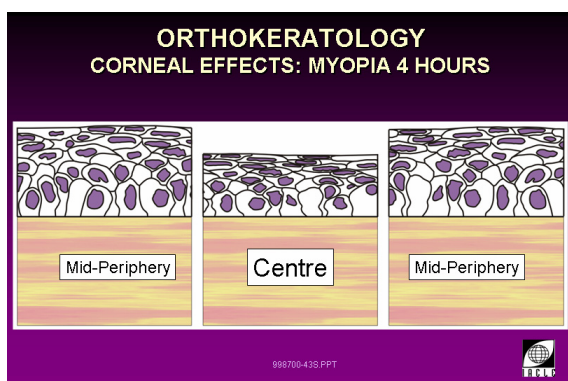
8L9998700-143

42



8L9998700-113

43



8L9998700-114

**Orthokeratology: Results of Current Research**

The first report that orthokeratology effects may involve a redistribution of corneal tissue was made by Soni and Horner (1997) who stated “Some researchers and eye-care practitioners believe that the space in the mid-periphery [note: this was the space provided by the reverse curve of the original Contax OK lenses] is critical for displaced central corneal tissue and that this movement of tissue creates changes to the fluorescein pattern behind the mid-periphery of the contact lens.”

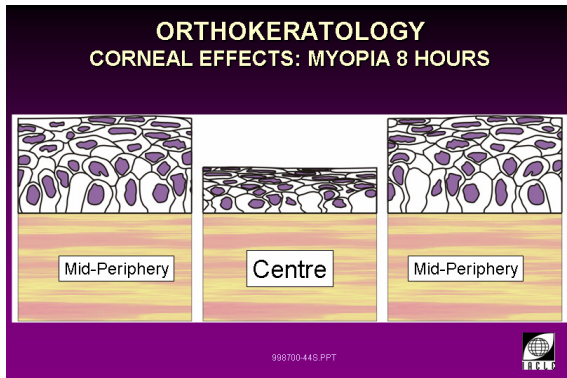
The recent work of Choo, Caroline, and co-workers is summarized in slides 42 to 54.

Alharbi *et al.* (2005) studied the overnight oedema response during orthokeratology and reported that, compared with a control group wearing conventional RGP lenses, the orthokeratology group exhibited inhibition of overnight central corneal swelling. Interestingly, both groups showed adaptation to corneal swelling in that the response decreased over the 30 days of the study. This has not been reported previously. Treatment lenses were postulated to act as a ‘clamp’ on corneal swelling.

Becherer and Kempf (2004) reported that OCR had no untoward effects on the corneal endothelium.

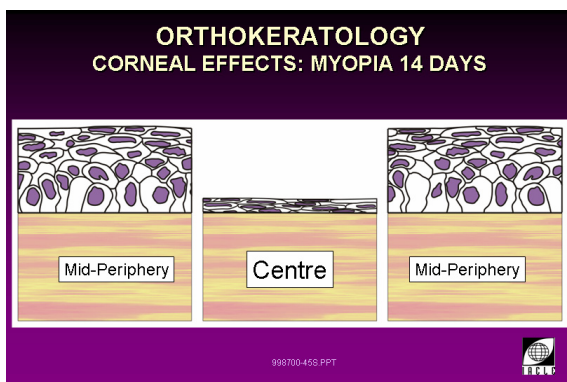
Garner and Owen (2004) studied overnight orthokeratology in a young population for 1 month and reported corneal thinning and anterior corneal

44



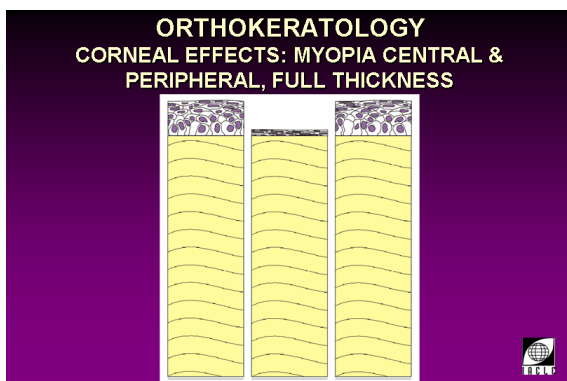
8L9998700-115

45



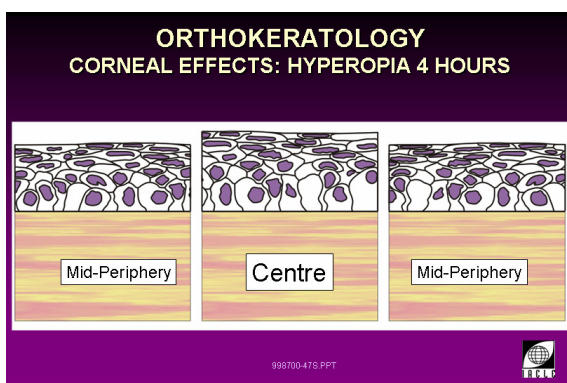
8L9998700-116

46



8L9998700-117

47



8L9998700-118

flattening, as have others. However, they also reported significant posterior corneal flattening both centrally and mid-peripherally after 1 week. Optically, this is counterproductive because posterior corneal flattening *decreases* the contribution of minus power the posterior cornea-anterior aqueous interface makes to the total power of the eye (slide 55). In myopia, any decrease in minus power means that additional minus power will have to be provided by other means to compensate, e.g. more anterior corneal flattening. Conversely, should orthokeratology be used for treating hyperopia, any posterior corneal steepening will *increase* the minus contribution of the posterior cornea-aqueous interface which means that more plus power will have to be contributed by other means, e.g. an even steeper anterior cornea.

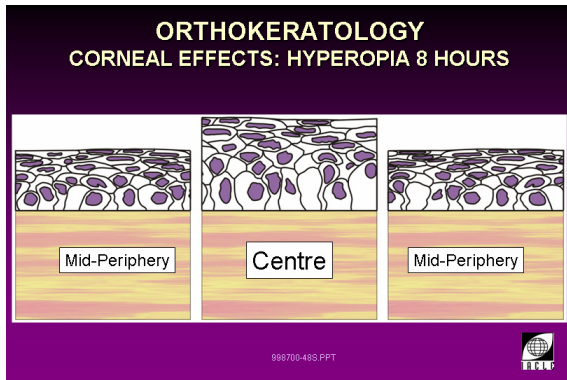
### Tear Composition

Choy *et al.* (2004) found that after just 1 night of orthokeratology lens wear there was evidence of some additional hypoxic stress as measured indirectly by tear albumin and lactate dehydrogenase levels. There was little evidence of corneal cell disturbance as measured by tear ascorbate levels.

### Epithelial Cell Proliferation

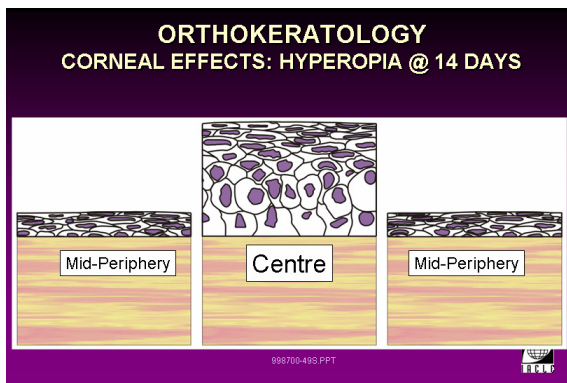
Shin *et al.* (2004) studied the epithelial cell proliferation rate in the rabbit using orthokeratology and conventional RGP lenses. Orthokeratology lenses had the greater effect (58% suppression of proliferation rate at day 7, 63% at day 14 *versus* 32% suppression at day 14 for the RGP lenses). Also using rabbits as an animal model, Matsubara *et al.* (2004) reported that orthokeratology did not appear to alter the function of epithelial cells histochemically. A shortcoming of these studies is the use of an animal model. Our knowledge of the relevance of animal studies to humans is incomplete.

48



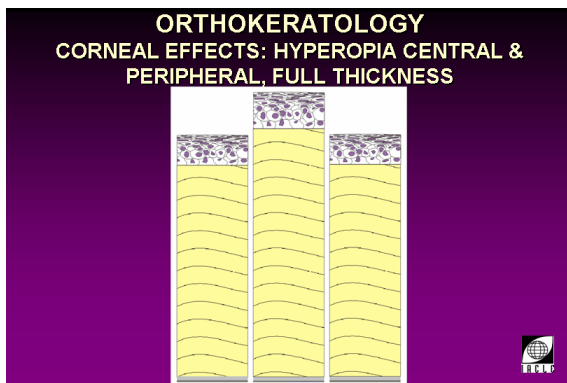
8L9998700-119

49



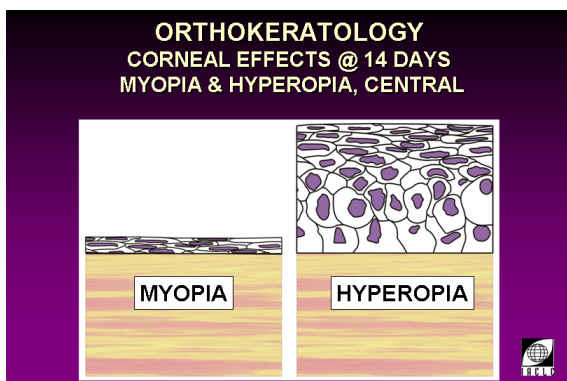
8L9998700-120

50



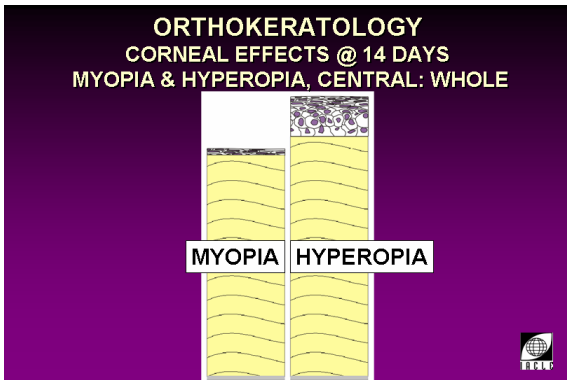
8L9998700-121

51



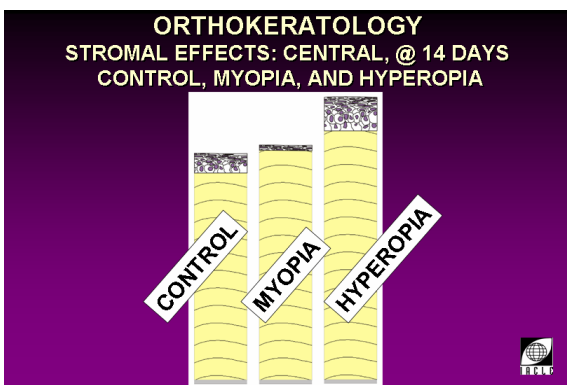
8L9998700-122

52



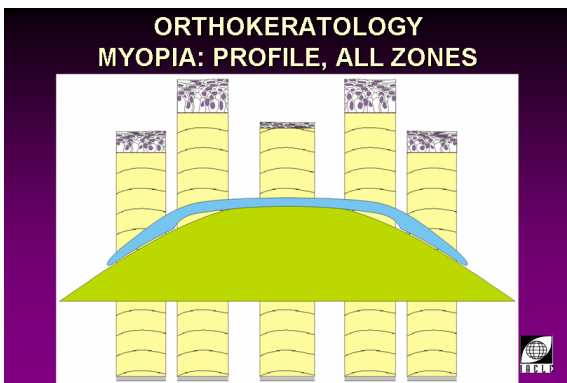
8L9998700-123

53



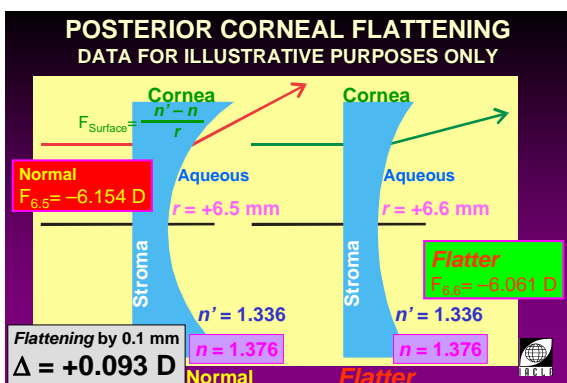
8L9998700-125

54



8L9998700-124

55



8L9998700-150




56

**ORTHOKERATOLOGY**  
**RETAINER OR TREATMENT LENSES**

- Determine that the 'end point' has been reached
- Finalize the treatment lenses
- Determine the wear schedule
- Consider ordering a spare pair
  - cessation of wear for whatever reason will result in regression of gains

998700-126S.PPT



8L9998700-126

**Orthokeratology: Retainer or Treatment Lens**

Before settling on a retainer lens, the practitioner, with the patient's help, must determine that the stage has been reached by which no further myopia reduction is occurring, i.e. the 'end point' has been reached (after Soni and Horner, 1997).

Soni and Horner (1997) stated, "The final contact lens that allows adequate tear exchange and stable uncorrected vision is considered to be the retainer lens."

Essentially, the retainer lens is the lens the orthokeratology patient uses part-time (usually for the minimum necessary amount of time) to 'retain' their best orthokeratology result achieved.

Rah and Jackson (2005) suggest that, once routine lens wear is undertaken, a spare pair of 'treatment lenses' as they call them, should be ordered as a hedge against loss or breakage of the main pair of lenses. This suggestion is based on the fact that, unlike conventional contact lens wearers, orthokeratology patients cannot resort to the use of a pair of back-up spectacles.

Furthermore, time out of treatment lenses leads to corneal 'recovery' (regression, reversion). These corneal changes may make a subsequent return to lens wear problematic.



## II Orthokeratology: Patient Selection

57

**ORTHOKERATOLOGY**  
**DESIRABLE PATIENT FEATURES**

- Rx -0.50 to -4.00 D Sph
  - higher Rx's are possible but outcome is less predictable
  - avoid a 'cowboy' approach to how much 'change' is possible
- < 1.50 D Cyl of corneal astigmatism
  - consider lenticular astigmatism when predicting vision
  - purely lenticular cyl is problematic
- Central  $K_{\text{flat}}$  readings  $\geq 42.00\text{D}$
- Corneas that flatten in the periphery
  - i.e. non-spherical, esp. prolate elliptical corneas

998700-10S.PPT

8L9998700-10

58

**PATIENT SELECTION**

- High motivation is required
- Level of patient's desire for 6/6 (20/20)
  - expectations (realistic?)
- Previous contact lens wear
- Pupil diameter
  - measure under a range of illuminations
  - large pupils are problematic

998700-11S.PPT

8L9998700-11

59

**CONIC SECTIONS**  
**DESCRIPTORS OF ASPHERICITY: p, e, or Q**

$r_0$  = Apical Radius of Curvature

- $Y_a = 2r_0X_a - pX_a^2$
- $p = 1 - e^2$
- $Q = -e^2$  or  $p = 1 + Q$

**Therefore:**

- $Y_a = 2r_0X_a - (1 - e^2)X_a^2$
- $Y_a = 2r_0X_a - (1 + Q)X_a^2$

Where:

- p = p-value or p parameter
- e = eccentricity
- Q = asphericity

Sometimes, p is called a 'pigeon parameter' and e is called 'shape factor' 998700-55S.PPT

8L9998700-103

60

**CONIC SECTIONS**  
**DESCRIPTORS OF ASPHERICITY: p, e, or Q**

	<0	>1	<-1
	0	1	-1
	>0 & <1	<1 & >0	<0 & >1
	1	0	0
	>1	<0	>0
	<b>p</b>	<b>e</b>	<b>Q</b>

Some refer to e<sup>2</sup> as the 'shape factor' 998700-60S.PPT

8L9998700-104

### Patient Selection Process

As with all contact lens fitting, motivation is a key to long-term success with orthokeratology treatment plans. It is also very important to establish accurate and appropriate patient expectations for the orthokeratology process and procedures. If the expectation is too high, the practitioner must explain the limitations involved so that the wearer clearly understands the likely range of outcomes.

It may be helpful to develop a 'pre-treatment' form upon which practitioner and patient definitions of a successful outcome can be recorded, as well as the anticipated time frame and whether vision will need to be supported by supplementary means in defined circumstances.

The amount of ametropia that can be corrected using orthokeratology is approximately 4.0 D of myopia and 1.0 D of astigmatism (e.g. Koffler *et al.* [2004] gives a range of -1 to -6 D myopia with 1.5 D of astigmatism while Mika *et al.* [2005] gives -1 to -5 D myopia, 1.50 D of WTR astigmatism and 0.75 D of ATR astigmatism), though considerable individual variation exists. A small amount of uncorrected astigmatism is generally acceptable to the patient.

Higher degrees of ametropia can be reduced. In these cases the patient must be aware that their unaided vision will *not* reach 6/6. Many high myopes are happy to achieve a level of vision that makes them functional and with which they can resort to a low-powered prescription for optimal vision.

The research of Mountford has shown a relationship between corneal eccentricity and the potential refractive correction that is possible with orthokeratology contact lenses. His work indicates that, for each change of 0.21 in the eccentricity value (e), a 1.00 D reduction in myopia is possible (slide 65).

This relationship suggests that for a -3.00 D effect, orthokeratology should only be attempted if the e value is at least 0.6. However, not all data supports the predictive utility of corneal eccentricity, e.g. Marsden *et al.* (1993 and later, Joe *et al.* [1996] from the same research group), Lowe (2004).

Age has also been shown to be a significant factor in the success of orthokeratology (Jayakumar and Swarbrick, 2004). Generally, older corneas are not as 'compliant' as younger corneas and tend to show smaller and/or slower changes. It is likely, therefore, that attempts to use orthokeratology to assist presbyopes are unlikely to be successful. Interestingly, Rao *et al.* (2000) also showed older refractive surgery candidates responded differently. This information led Jayakumar and Swarbrick to speculate that there is less vigorous corneal tissue response in older patients.

61

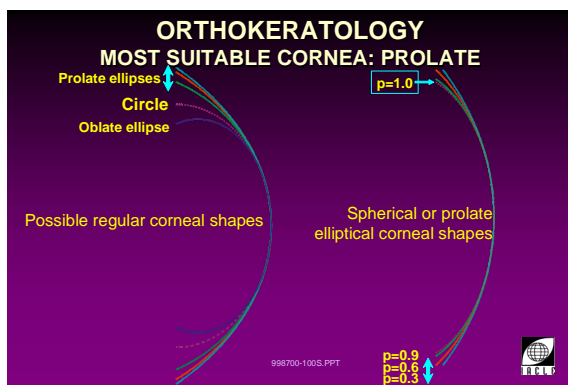
**NORMAL CORNEAL SHAPE  
SOME PUBLISHED FIGURES**

References	Descriptors	p	e <sup>2</sup> /SF	Q
Townsley		0.70	0.30	-0.30
Mandal & St Helen		0.77	0.23	-0.23
Kiely <i>et al.</i>		0.74	0.26	-0.26
Guillon <i>et al.</i>		0.82	0.18	-0.18
Patel <i>et al.</i>		0.97	0.03	-0.03
Eghbali <i>et al.</i>		0.82	0.18	-0.18
Carney <i>et al.</i>		0.67	0.33	-0.33
Holden		0.72H/0.66V	0.28/0.34	-0.28/-0.34

$\bar{x}_p = 0.77$  (PROLATE) after Lindsay *et al.*, 1998

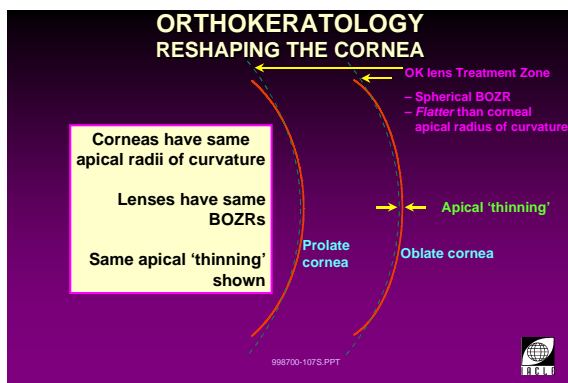
8L9998700-105

62



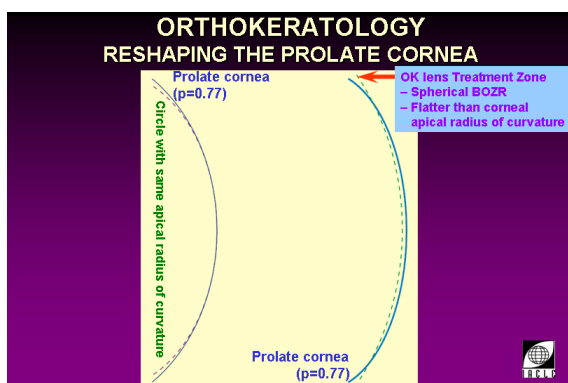
8L9998700-100

63



8L9998700-107

64



8L9998700-106

Wlodyga (1992) also reported on the successful treatment of less-than-successful post-RK patients using orthokeratology. At the time, he predicted that contact lens practitioners would be seeing more of these cases. Arguably, the rise of PRK, and then LASIK and derivatives as the preferred refractive surgery techniques, has reduced the need for orthokeratology post-surgically.

However, Caroline (2005) reported using orthokeratology (CRT), piggyback lens combinations, and siloxane hydrogel lenses (+6 D) on LASIK patients who had less-than-hoped-for outcomes post-surgically.

In a comparison of overnight orthokeratology and DW SCLs, 71% of those who experienced both modes of correction elected to stay with overnight orthokeratology (Lipson *et al.* 2004).

Carkeet *et al.* (1995) found that initial refractive error was the only useful predictive factor of success in orthokeratology (high myopia was less likely to respond successfully). Somewhat surprisingly, ocular biomechanical factors, e.g. ocular rigidity, epithelial fragility, or biometric attributes such as corneal thickness and corneal diameter were not useful.


65

**CORNEAL ECCENTRICITY and ORTHOKERATOLOGY**  
 Mountford, 1997

- Relationship between change in eccentricity and change in refraction

$$\Delta e = 0.21 \Delta Rx$$

998700-37S.PPT



8L9998700-37


66

**ORTHOKERATOLOGY ECCENTRICITY & APICAL RADIUS**

- The greater the E, the greater the potential Rx  $\Delta$
- The steeper the cornea, the greater the potential Rx  $\Delta$

Initial K	E = 0.4	E = 0.5	E = 0.6
	Rx Reduction	Rx Reduction	Rx Reduction
41	-1.39	-2.08	-2.86
42	-1.50	-2.23	-3.07
43	-1.62	-2.41	-3.30
44	-1.75	-2.60	-3.54
45	-1.88	-2.79	-3.79
46	-2.02	-2.99	-4.06

998700-151S.PPT  
 from: The BE™ System by Mountford & Noack




8L9998700-151

67

**CONTRAINDICATIONS**

- Previous failure(s) with RGP lens wear
- Diseases of the cornea, conjunctiva, or adnexa
  - e.g. dry eye
- Anterior chamber inflammation/infection
- Systemic disease that affect the eye or can be exacerbated by lens wear
  - e.g. diabetes
- Keratoconus

998700-12S.PPT




8L9998700-12

68

**CONTRAINDICATIONS**

- Older patients (long-term CL wearers?)
  - cornea less likely to respond well
- Unrealistic patient expectations
- Against the rule cylinder > 0.75 D Cyl
- Low sphere power with high cylinder
- Limbus to limbus astigmatism
- Very steep or flat K values

998700-35S.PPT



8L9998700-35

**Contraindications for Orthokeratology**

In practice, many factors can hinder the success of orthokeratology for an individual patient. The practitioner should establish strict inclusion/exclusion criteria to offer the greatest chance of a successful outcome.

As with all contact lens fitting, any active acute or chronic ocular disease is a contraindication for contact lens wear. In particular, any irregular corneal shape such as keratoconus or warpage induced by long-term PMMA lens wear is likely to result in failure.

The level of motivation of the patient must be evaluated fully. Those candidates with poor motivation are less likely or unlikely to succeed.

Any factor likely to limit achieving good lens centration is likely to result in a poor orthokeratology effect. Such limitations include ATR astigmatism and deep-set eyes combined with loose upper lids (reduced lid tonus).

Although accelerated orthokeratology is more successful than conventional orthokeratology at reducing WTR astigmatism, it only reduces pre-existing astigmatism by about 50% and even then, not reliably for either magnitude or direction (Mountford and Pesudovs, 2002).


A key factor in the determination of a patient's suitability to orthokeratology lens wear is the interpretation of the pre- and post-lens wear

69

**CONTRAINDICATIONS**

- When the cornea is spherical (i.e.  $e = 0$ )
- Where the  $e$  value and the refractive error do not correlate
  - e.g.  $-4.00D$  and  $e = 0.25$  (see previous slide)
- Deep-set eyes
- Very loose/flaccid lids
- Poor responder to initial lens wear trial

998700-38S.PPT



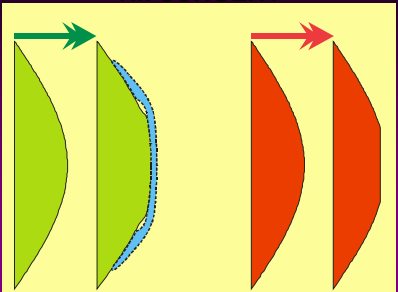
8L9998700-38

corneal topography measurements. The practitioner must be able to assess the corneal shape prior to lens fitting and to determine the effects of lens wear on the cornea. This is the logical role for a corneal topographer (videokeratoscope).


Large pupil sizes also have the potential to cause problems with excessive flare, especially in mesopic or scotopic light levels (Boneham, 2001).

70

**ORTHOKERATOLOGY  
vs  
Rx SURGERY**



998700-140



8L9998700-140

**Advantages of Orthokeratology versus Refractive Surgery**

The major advantage of orthokeratology compared to current refractive surgical techniques is its reversibility. Should an intractable problem such as chronic 3 & 9 o'clock epithelial staining arise, the practitioner can discontinue lens wear to allow the cornea to recover fully.

The orthokeratology technique maintains binocular vision and also corrects the vision to 6/6 during lens wear.

Other possible advantages include:

- Not age-dependent.
- Lower cost.
- Long-term effects of contact lenses are well understood.
- Effect can be modified to incorporate monovision as and when needed.

There is some early evidence to support the claim that orthokeratology controls or limits myopia progression in children (Lowe, 2001). Much work is still required in this area and the current thinking is covered in more detail later in this lecture (Section VI **Orthokeratology: Myopia Control?**).

As mentioned earlier in this lecture, occasionally contact lens wear is required after a less than optimal outcome with refractive surgery, usually for reasons related to poor or variable vision.


Slide 72 shows how a reverse geometry lens may be used to improve post-operative VA in a case where the outcome following refractive surgery was less than optimal. This lens is worn during office hours by a patient whose RK surgery left him with a refraction of  $+6.00 / -2.50 \times 100$ . His VA with spectacle lens correction of 6/24 (20/80) improved to 6/4.5 (20/15) with the contact lens.

71

**ORTHOKERATOLOGY versus  
REFRACTIVE SURGERY  
ADVANTAGES OF OK**

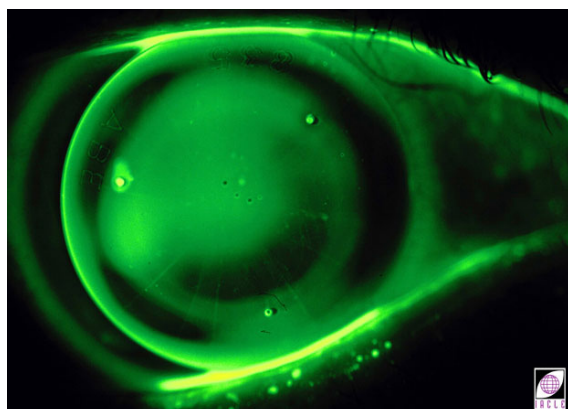
- Reversible
- Both eyes 'altered' at the same time
- No disruption to vision during treatment
- Less (or no) pain compared with PRK
- Therapy can be halted if untoward effects are experienced
- Option for children
  - may slow myopia progression

998700-13S.PPT



8L9998700-13

72



8L9FIG03

73

**ORTHOKERATOLOGY *versus*  
REFRACTIVE SURGERY  
DISADVANTAGES OF OK**

- Not a 'permanent' solution
- Patient may become a regular RGP lens wearer, i.e. uses OK lens conventionally
- Amount of refractive error correctable by OK is limited
- Potential for non-compliance

998700-14S.PPT



8L9998700-14

**Disadvantages of Orthokeratology versus Refractive Surgery**

The primary disadvantage of orthokeratology is the limited refractive correction available and the fact that it is not a permanent solution to the patient's vision problem.

The response of the cornea to orthokeratology lens wear shows a high degree of individual variation and this makes it difficult for the practitioner to predict the outcome. However, such a problem also applies to refractive surgery.

Other possible disadvantages include:

- Tolerance to RGP lenses may be problematic.
- Long-term RGP lens wear can induce ptosis and lid oedema (see Module 7, Lecture 7.3, Section **IV.D Ptosis**). This applies only to those patients who use their orthokeratology lenses for some period of daytime wear.



### III Fitting Orthokeratology Lenses

74

#### REQUIREMENTS FOR ORTHO-K

- Corneal topographer
  - → axial, tangential, and refractive maps
- Precision fitting
  - extensive knowledge of RGP lens fitting
- Large set of special OK trial lenses
  - expensive

998700-15S.PPT



8L9998700-15

#### Fitting Orthokeratology Lenses

When practitioners enter the field of orthokeratology, they need to be aware of the significant extra costs involved and need to structure their fee schedule accordingly. Costs are incurred through:

- Extra trial lenses.
- Supplementary lens fittings.
- Corneal topographer.
- Considerable time devoted to fitting and follow-up.

A key factor in successful fitting of orthokeratology lenses is the use of a corneal topographer and the interpretation of the images derived from this instrument. The topographer enables the practitioner to monitor accurately the effects of the lens on the cornea, and to follow the progressive alteration in corneal shape with each lens change.

Eccentricity and apical radius values are an essential requirement in orthokeratology fitting as they are used to determine the initial trial lens. Some topographers may display the corneal shape in terms of (see earlier in this lecture):

- e, the eccentricity.
- Q, the asphericity.
- p, the p-value.

The corneal shape may also be described in terms of elevation. This is a measure of the corneal sag over a given diameter.

Axial (sagittal) maps show the sagittal radius of the cornea in terms of colour contour maps that are used to illustrate the optical (power) effect of the corneal surface. The axial power data is used to describe the corneal shape in terms of the e, Q or p-values. A disadvantage of the axial map is that it cannot analyze small, discrete changes in local corneal contour caused by localized distortions.

Tangential maps describe the localized corneal shape as radius measurements are not biased towards the optical axis of the cornea. These maps represent a surface point as having its radius at a tangent to the curvature at that point, in the meridional plane. However, the centre of the radius of curvature does not lie along the optic axis. A major benefit of tangential maps is that they show small changes of corneal curvature at localized points or areas in greater detail.

Refractive power maps represent the actual refractive power of the cornea from the centre to the periphery. In contrast to axial and tangential maps, the cornea increases in power on a refractive map as the periphery is approached. The refractive power maps are mainly used to measure the treatment zone diameter on the post-orthokeratology cornea.

75

#### ORTHOKERATOLOGY LENS SELECTION METHODOLOGIES

- Lens laboratory technique:
  - supply Ks & Rx
  - no trial lenses, no trial fitting
- Topographical fitting:
  - topographical data & lens-fitting software suggests initial trial lens
  - trial lens fitting
- Inventory:
  - using Ks & Rx, choose trial lenses from inventory (100+ lenses, typically 130-140)

998700-85S.PPT



8L9998700-85

76

#### CORNEAL TOPOGRAPHY REQUIREMENTS

- Eccentricity (e) measurements
- Corneal difference maps
  - interpretation is important
- Apical radius of curvature values
- Sagittal and tangential maps

998700-36S.PPT



8L9998700-36

77

#### CORNEAL TOPOGRAPHY REQUIREMENTS

- In-depth understanding of topography measurements
  - limitations of the technique
  - accuracy and repeatability
- Accurate instrument calibration
- Take multiple measurements on the eye to obtain mean and standard deviation

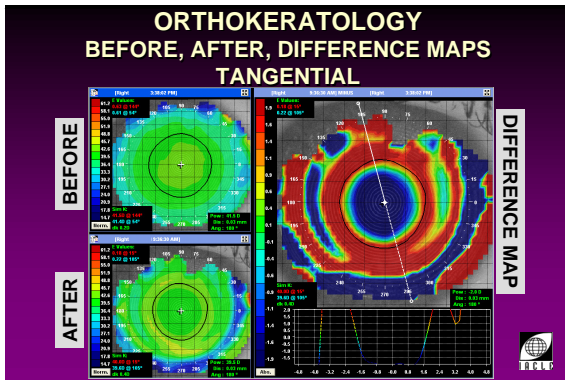
998700-44S.PPT



8L9998700-44

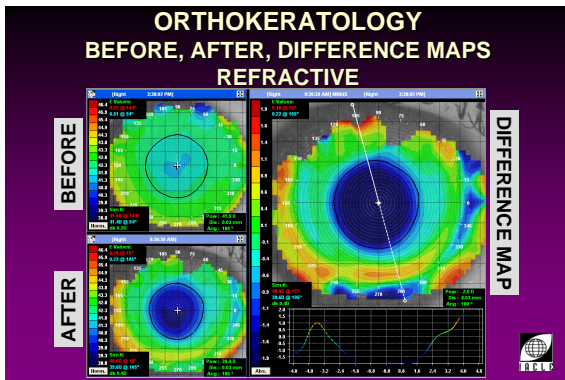


78



8L9998700-157

79



8L9998700-158

Difference maps (subtractive plots) generated by most corneal topographers, permit the practitioner to compare pre- and post-treatment changes as well as the effects the lens is having on the corneal surface.

Tangential (true) curvature maps showing Before, After, and Difference plots before and after orthokeratology appear as slide 78. For comparison purposes, refractive (power) maps of the same eye appear as slide 79. The reorganization of surface power into a concentric pattern (slide 79) is a typical result of orthokeratology treatment.

The accuracy of these maps is vital to the orthokeratology practitioner's determination of the efficacy of the lens in reducing refractive error.

- Subtractive axial maps represent the refractive change where the change in apical corneal power is equal to the refractive change.
- Subtractive tangential maps show the shape change.
- Subtractive refractive maps show the treatment zone diameter most accurately.

While difference maps are often helpful, they also have the potential to mislead. An option is to inspect absolute maps rather than the relative information given by difference maps. This is done by choosing the absolute maps of tangential curvature before and after treatment, and the refractive power maps before and after treatment. The reason for this is that, quite commonly, the before treatment maps show significant asymmetry/distortion/undesirable optical qualities. Should the after-treatment maps for such eyes show greater regularity, i.e. more desirable optically, it follows that the difference map will show asymmetry that may be judged erroneously to be an undesirable 'effect' of treatment.

Assessment of the lens fit and understanding of the effects of lens wear on the corneal shape is possible only when the practitioner has a good understanding of the limitations of the corneal topographer used. The instrument must be calibrated accurately and an assessment of systematic errors made, e.g. the measurements permit a mean and standard deviation to be calculated.

To assess the accuracy of the topographer, it is extremely valuable to measure the mean and standard deviation of the elevation data for each eye being measured. Errors in elevation data are believed to be largely patient-dependent and they can be increased further by instability of the pre-corneal tear film.

To assess and quantify the error, it is recommended that at least three and preferably six maps per eye be analyzed when calculating input data. Careful inspection of each map also helps identify errors due to artifacts in the reconstruction of the reflected ring patterns.

Accuracy in topographical measurements can be improved by:

- Changing the patient's head position to increase the area of the cornea that is measured (exposed). This is particularly important with deep-set eyes.
- Instructing the patient to keep their fixation as steady as possible.
- Keeping the patient's head position steady and having them maintain contact with the instrument's forehead rest at all times.
- Encouraging the patient to blink fully to spread the tear film uniformly over the cornea.
- Optimizing the focus prior to taking the measurement.

Time spent in obtaining accurate topography plots and fitting information is time well spent and will minimize the need for repeat fitting through inaccurate or inappropriate lens parameter selection.

According to Lipson (2005), SCL wear should cease 3 days before orthokeratology and RGP lens wear should cease 2 weeks before orthokeratology.

80

**FITTING ADVICE**

- The *larger* the BOZD, the *looser* the fit
- The *steeper* the tear reservoir (BPR<sub>1</sub>), the *tighter* the fit
- The *larger* the total diameter (TD), the *tighter* the fit
- Don't consider the BOZR in isolation
  - 'fitting' is a combination of effects, especially of back surface design factors/parameters

998700-16S.PPT

8L9998700-16

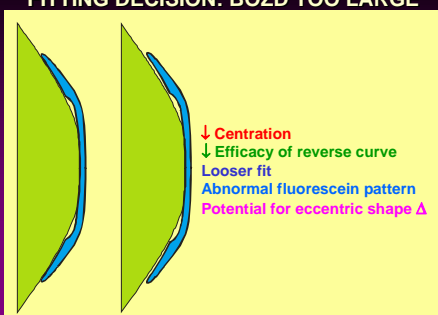
**General Lens Fitting Relationships**

The key fitting guidelines in orthokeratology must be understood fully by the practitioner. The relationship between the size of the BOZD and its effect on the tightness of the fitting are the reverse of the normal RGP philosophy. In orthokeratology, a larger lens BOZD results in a looser on-eye fitting relationship (slide 81).

When a reverse geometry lens is designated as a 3.00 D lens, its secondary curve radius (SCR) is 3.00 D steeper than the BOZR. When it is a 5.00 D lens, the SCR is 5.00 D steeper than the BOZR. Consequently, the higher the dioptric steepness of the SCR, the more 'reverse' the curve is (and the more 'grip' it will exhibit).

81

**ORTHOKERATOLOGY**  
**FITTING DECISION: BOZD TOO LARGE**



- ↓ Centration
- ↓ Efficacy of reverse curve
- Looser fit
- Abnormal fluorescein pattern
- Potential for eccentric shape Δ

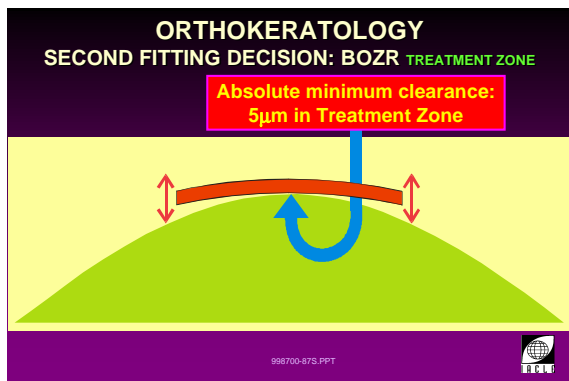
998700-98S.PPT

8L9998700-98

The selection of lens TD should be based on the measured corneal diameter (e.g. the HVID). For smaller corneal diameters, the lens diameter (TD) must be reduced.

Tahhan *et al.* (2003) compared four orthokeratology lens designs (BE Retainer, DreamLens, Rinehart-Reeves and Context D Series 4) in a 1-month, overnight study and found all to be similarly effective. Similarly, also in short-term studies, Soni *et al.* (2004) and Maldonado-Codina *et al.* (2005) found few differences between various lens designs fitted using empirical or trial lens fits even when fabricated in identical materials.

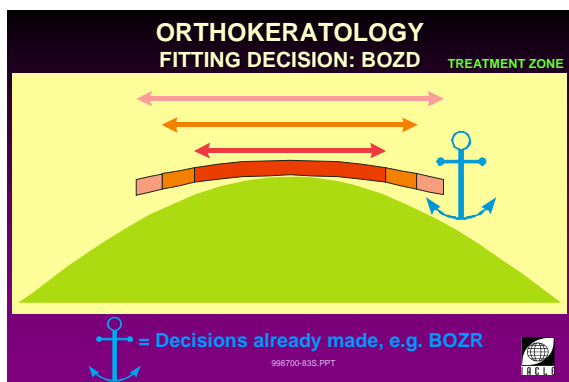
82



8L9998700-87

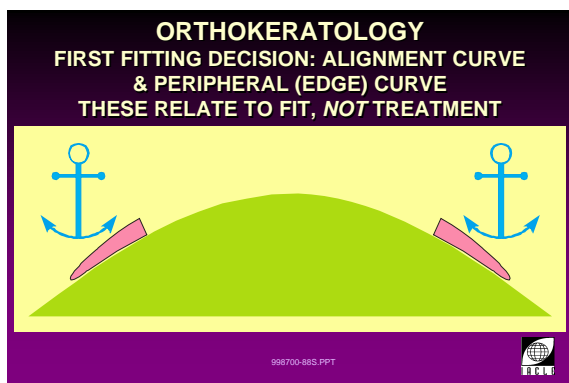
Some of the decisions that need to be made are presented diagrammatically in slides 81 to 91. As all lens designs differ in various ways, it is appropriate to follow the suggestions of the lens manufacturer or, if available, the suggestions provided by the lens-specific design software provide with some topographers (videokeratoscopes).

83



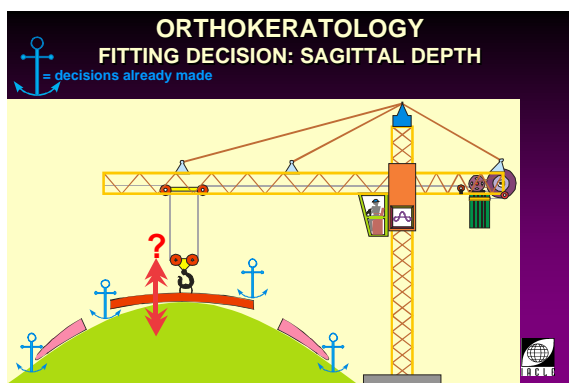
8L9998700-97

84



8L9998700-88

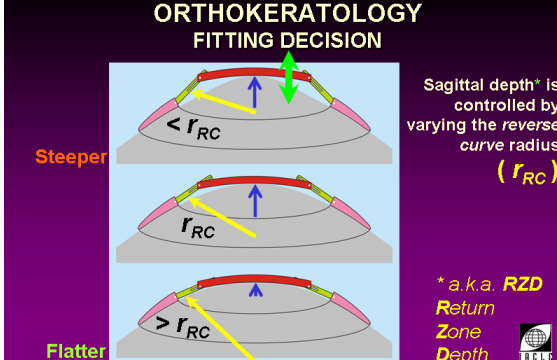
85



8L9998700-159

86

**ORTHOKERATOLOGY**  
FITTING DECISION



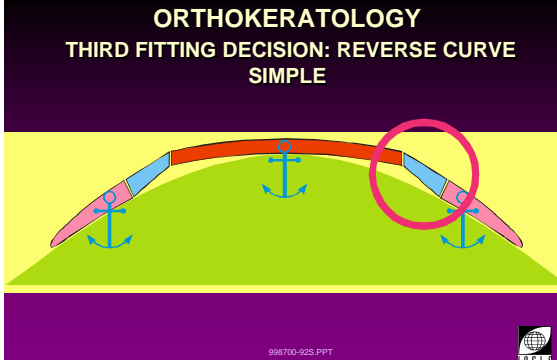
Sagittal depth\* is controlled by varying the reverse curve radius ( $r_{RC}$ )

\* a.k.a. RZD  
Return Zone Depth

8L9998700-96

87

**ORTHOKERATOLOGY**  
THIRD FITTING DECISION: REVERSE CURVE SIMPLE

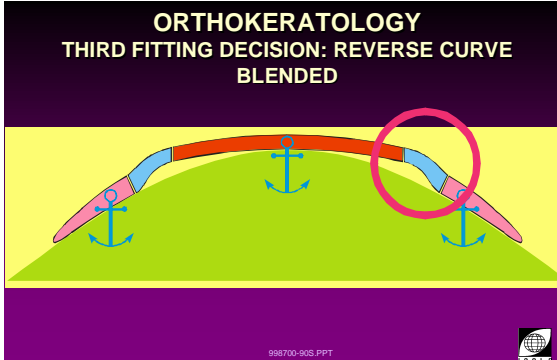


998700-92S.PPT

8L9998700-92

88

**ORTHOKERATOLOGY**  
THIRD FITTING DECISION: REVERSE CURVE BLENDED

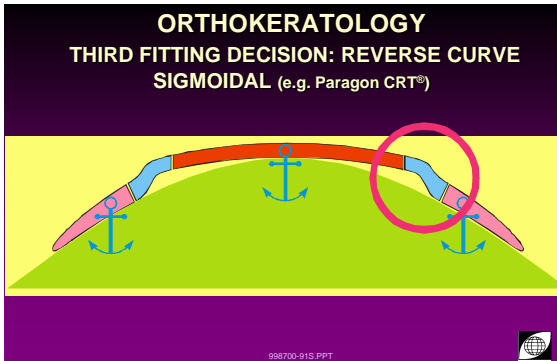


998700-90S.PPT

8L9998700-90

89

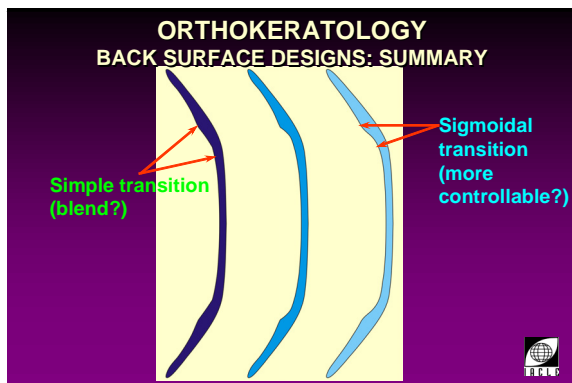
**ORTHOKERATOLOGY**  
THIRD FITTING DECISION: REVERSE CURVE SIGMOIDAL (e.g. Paragon CRT®)



998700-91S.PPT

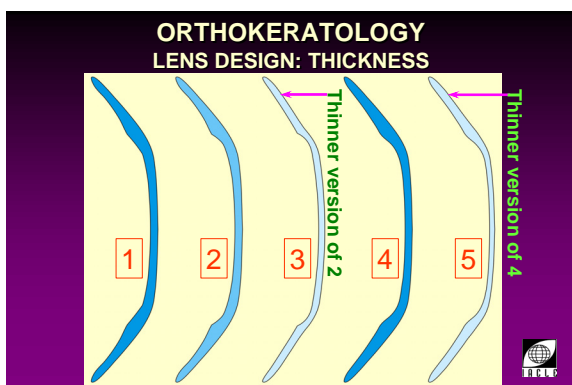
8L9998700-91

90



8L9998700-65

91



8L9998700-66

92

**FITTING ADVICE**

- Assess lens after 5-10 minutes
  - closed eye wear is preferred
- Assess lens with white light first, then with sodium fluorescein
- Keep OK lenses that are no longer required
  - build an extensive 'trial set'

998700-18S.PPT



8L9998700-18

93

**TRIAL FITTING ROUTINE**

- Select initial lens' radius/design
  - 0.3 to 0.5 mm flatter than  $K_{lat}$
  - based on topography measurements
- Use topical anaesthetic
  - prevents excessive tearing
- Assessment of fluorescein pattern
  - central bearing
  - tear reservoir (paracentral zone)
  - edge width and edge clearance
  - assess quality of lens centration
- Overnight-wear trial

998700-19S.PPT



8L9998700-19

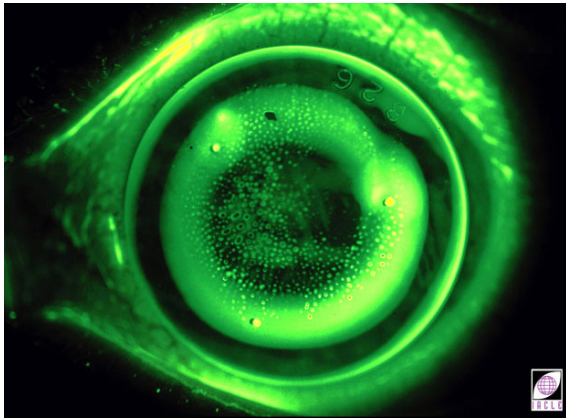
### Trial Fitting Orthokeratology Lenses

The trial fitting assessment period is potentially a key indicator of whether success can be achieved with orthokeratology lenses. The selected trial should be applied following the use of a topical anaesthetic to minimize lacrimation and lid spasm, both of which make the judgement of the sodium fluorescein pattern and the lens centration much less reliable.

Following the trial fitting with orthokeratology lenses to establish the optimum lens, a wearing schedule can be undertaken on either a daily or overnight basis.

An extended period of lens wear of up to 6 hours is recommended when the DW option is used. In

94



8L9FIG05

cases where there is little change in refractive error or unaided vision after an extended trial period with an optimum fitting lens, the patient should be advised that orthokeratology is unlikely to be successful.

In some orthokeratology fittings, the optimum first choice lens may show a change in the fluorescein pattern over time. The main change is that the flat central fitting (which remains largely unchanged), as seen with fluorescein, becomes relatively steeper (because of further flattening of the periphery). The fitting should still show a wide intermediate tear reservoir with the presence of a wider (than before) peripheral contact band. Such a change in fluorescein pattern suggests that there is the possibility of further changes in corneal shape with the use of further orthokeratology lenses, i.e. corneas that show further changes are indicating that the full potential of orthokeratology has not been reached.

At this point, a lens with a BOZR 0.2 mm flatter than the original trial lens can be fitted and assessed to determine if any further change in corneal shape is possible.

In modern orthokeratology, the first lens often provides the refractive correction required while maintaining good centration and an appropriate fitting pattern. In such cases, the first lens becomes the retainer and it is worn overnight as frequently as required to provide satisfactory daytime unaided VA.

In some cases following overnight wear, numerous small bubbles (dimple veiling) may appear in the post-lens tear film (slide 94) within an hour of eye opening, should the lenses not be removed. Although dimple veiling may cause a small, temporary decrease in VA, the condition is otherwise harmless generally and does not indicate a need to change the lens design.

95

### TRIAL FITTING ROUTINE

- Overnight wear advantages
  - minimizes need for adaptation
  - reduces discomfort
  - maximizes orthokeratology effect
  - high Dk/t lenses are available
  - easier for patients

998700-39S.PPT



8L9998700-39

96

### TRIAL FITTING ASSESSMENT

- Ideally, the initial lens produces a:
  - rapid change
  - flattening of the central cornea
  - reduction in myopia
  - change in the fluorescein fitting pattern
    - what was acceptable *becomes* less acceptable
    - if apical clearance is noted, this suggests
      - a flatter lens is required, and...
      - further shape changes are possible

998700-20S.PPT



8L9998700-20

97

### IDEAL FITTING PATTERN

- 3 - 4.5 mm of central bearing
- Wide, deep tear reservoir around central bearing zone
- Good lateral centration
  - vital for wearing success
  - pupil coverage
  - good vision
- Minimal movement with blink
  - depends on total diameter
- Active tear exchange
  - no or small bubbles in the tear reservoir
    - larger bubbles suggest reservoir too deep

998700-21S.PPT



8L9998700-21

### Ideal Fluorescein Pattern for Orthokeratology

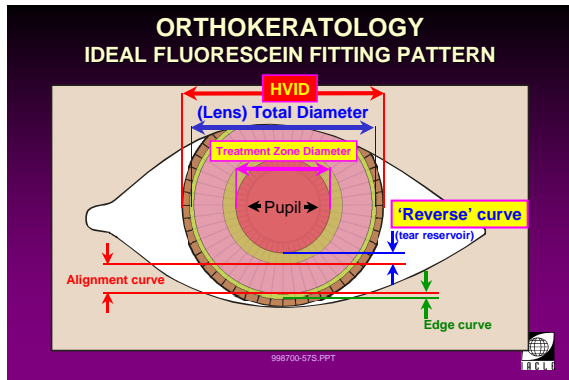
The BOZR of the first trial lens is typically 0.3 to 0.6 mm flatter than the flattest K value. Selection is based on the corneal shape and the eccentricity value. Mountford recommends that lenses be fitted with a flatter BOZR if the eccentricity value is greater than normal.

An ideal fluorescein pattern (slide 98) is one that shows a wide central touch approximately 3 mm in diameter. This is the main bearing zone of the lens on the central cornea and, therefore, should be centred as well as possible.

Note: The term 'touch' can be misleading. In relation to contact lenses, true touch does not

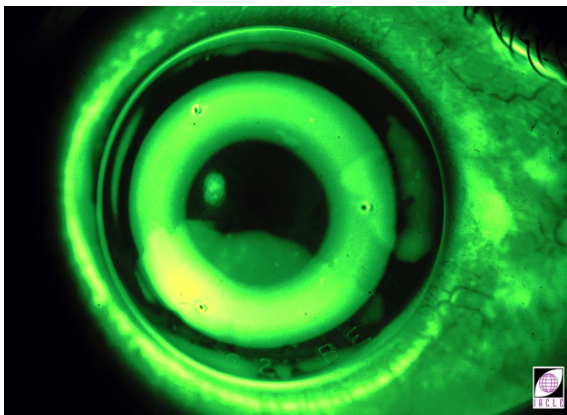


98



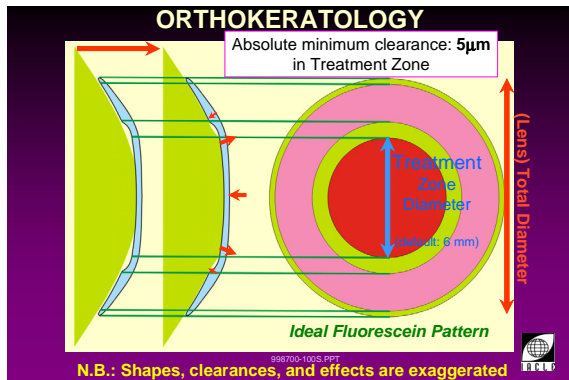
8L9998700-57

99



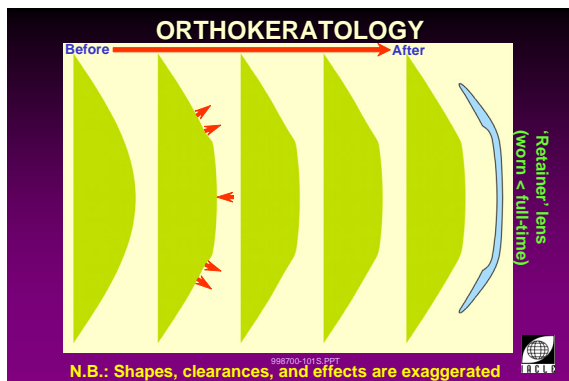
8L9FIG06

100



8L9998700-58

101



8L9998700-60

occur, i.e. the contact lens is not in direct contact with the epithelial cell membranes. Rather, a thinned, viscous, mucin layer (the deepest tear film component) remains between the contact lens and the epithelium. Perhaps the term 'bearing' would be more descriptive.

The tear reservoir should show a wide and deep fluorescein pattern that surrounds the flat central zone. This reservoir should taper (become shallower) to a narrow band of peripheral touch at the edge of the secondary curve.

As with all RGP lenses, the peripheral fluorescein pattern should show acceptable width and clearance. The width should be of the order of 0.2 to 0.4 mm as this allows adequate tear exchange along with some lens movement. In slide 99, the edge clearance band is notably absent (compare with slide 36). This is an example of a 'tight' or 'steep' periphery, indicating the value of corneal eccentricity has been under-estimated from the topographical data. However, the overall estimate of sagittal depth may still be correct as evidenced by the appearance of the apical bearing zone.

Such a fluorescein pattern, combined with adequate lens movement and good tear exchange, provides the greatest chance of a successful orthokeratology fitting. This fitting will cause central corneal flattening with a band of mid-peripheral corneal steepening. The topography plot results in the optimal bulls-eye pattern.

If the lens is too flat, it will tend to decentre superiorly and the area of central bearing will appear larger than expected and will not be centred over the pupil zone. If the lens is not flat enough, bubbles and froth will appear in the tear reservoir and the central bearing zone will appear smaller than expected.

Note: Generally, the use of the term 'bulls-eye' is used to describe topographical patterns rather than sodium fluorescein patterns.

### Progression of Orthokeratology Fittings

To establish a logical progression of lenses when multiple lenses are required, careful fitting and monitoring of lens effects on the cornea are required if a successful outcome is to be achieved. Once the correct initial lens is determined, the following measurements should be made to assess the effects of the lens on corneal shape and any change in unaided vision:


- Over-refraction.
- Corneal topography.
- Keratometry.
- BCVA.

102

**FITTING PROGRESSION**

- Initial lens selection and fitting
- Monitor effects of the first lens
  - $\Delta$  refractive error
  - $\Delta$  keratometry
  - computerized corneal topography
- New lens to modify corneal flattening
  - not always required
  - change in BOZR
  - lens centration must be maintained

998700-22S.PPT



8L9998700-22

103

**FITTING PROGRESSION**

- Review after first night of wear
  - determine if lens is bound
  - educate wearer about the technique for loosening an adherent lens
  - slit-lamp examination
  - determine unaided vision
  - perform retinoscopy and refraction
  - measure corneal topography
    - subtractive plot analysis to disclose change

998700-45S.PPT




8L9998700-45

104

**FITTING PROGRESSION  
OLDER METHOD**

- Order lenses for delivery
  - two pairs needed
  - second pair 0.1 to 0.4 mm flatter than first
- First lens pair is dispensed
  - monitor effects
- Second lens pair dispensed within 1-3 days
- New lens pairs ordered in advance
  - based on effects of previous lens pairs

998700-23S.PPT

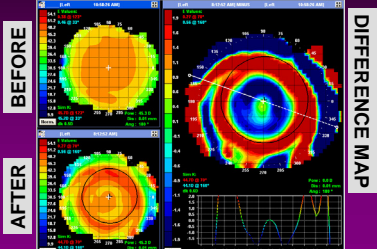


8L9998700-23


105

**ORTHOKERATOLOGY  
CENTRAL ISLAND**

NOTE: Some authors apply the term 'central islands' to indicate that the central cornea has STEEPENED cf. its pre-treatment curvature



998700-160



8L9998700-160

- Unaided vision.
- Subjective refraction.
- Retinoscopy.

In the early practice of orthokeratology, the practitioner ordered the first two sequential lenses required for the patient at the same time. This allowed for an immediate transition from the initial lens to the next (flatter) lens.

Each subsequent lens had to be appropriate to the new corneal shape induced by the wearing of its predecessor. A lens that was too steep could cause an unpredictable change in corneal shape.

If a flatter third lens was likely to be required, it was ordered once wear of the second lens had commenced.

In modern orthokeratology practice, the orthokeratology RGP lens designs used often provide a successful outcome with just one lens fitting, i.e. the initial pair of lenses.

A key to successful orthokeratology is an accurate assessment of the effects of the trial lens after its first night of wear. Of greatest importance is the calculation of the refractive change induced by the lens and the determination of a subtractive topography plot of the topographical changes achieved.

In an ideal case, the refractive change, as determined from an axial power subtractive plot, would exhibit a bulls-eye plot. Such a plot indicates optimum lens centration.

When the axial power subtractive plot indicates a result other than a bulls-eye pattern, the trial lens is not optimal and a repeat overnight wear trial is recommended with an alternative lens. The two major plot patterns that indicate a sub-optimal lens fitting are:

- Central island appearance (slide 105).
- 'Smiley face' appearance (slide 106).

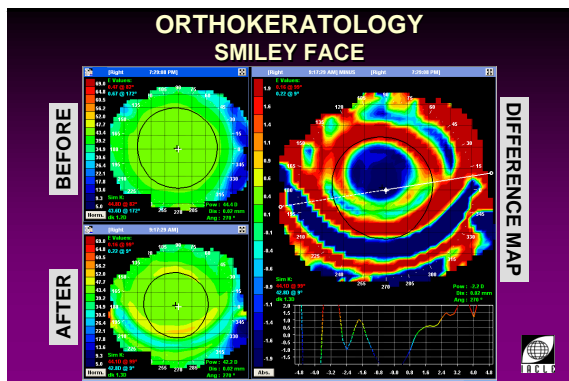
Other issues than can occur are detailed later in Section **VI Orthokeratology: Problem Solving**.

Once a satisfactory orthokeratology result is achieved, the practitioner must determine what type of retainer lens is required. The options for the wearer include:

- Part-time DW of a lens with an appropriate BVP.
- Overnight wear only.

Modern orthokeratology practice is dominated by the use of lenses on an overnight wear basis. The length of wear after waking is dictated by the rate of regression. For some patients, the lenses should remain on the eyes for a longer period of time after waking to provide the maximum lens-free wearing period compatible with an acceptable standard of vision.

106



8L9998700-161


Wearers who are new to contact lens use must be given appropriate instructions to enable them to handle, clean and maintain their lenses in the usual way. Even though most orthokeratology patients use their lenses for very limited periods of time, they must be aware of the need for adequate cleaning and disinfection after each period of lens wear.

107

**FITTING PROGRESSION**  
MODERN METHOD

- Order lenses for delivery
  - single pair needed
  - based on trial fitting results
  - a bulls-eye topography plot is essential
- First lens pair is dispensed
  - monitor effects
  - may take some time to achieve maximum change
- Second lens pair dispensed if required
  - based on topography plots and refractive changes achieved with the first pair

998700-48S.PPT




8L9998700-48

108

**FITTING PROGRESSION**

- Achieve maximum effect possible or required
- Use retainer lens when cornea has stabilized
- Overnight wear of retainer is ideal
- Determine minimum wear of retainer for acceptable visual result
  - minimum number of nights
  - daily wear in some cases
- Frequent after-care to monitor the eyes

998700-24S.PPT



8L9998700-24


109

**FITTING PROGRESSION**

Ideal orthokeratology end point:

- Uncorrected VA of 6/6 or better
- Slight hyperopia of 0.50D
- Regular corneal topography
  - bulls-eye pattern
- Minimal regression over 10 -12 hrs after lens removal
- Stable results over a 2 - 3 month period

998700-25S.PPT



8L9998700-25


110

**ORTHOKERATOLOGY  
AFTER-CARE**  
from Cheung & Cho, 2004

The important facets of an after-care visit are:

- History
- Subjective refraction
- Slit-lamp biomicroscopy
- Corneal topography

998700-153S.PPT



8L9998700-153

**After-Care**

Cheung and Cho (2004) studied the after-care of orthokeratology patients to determine which clinical tests were appropriate. They concluded that the following were the most suitable:

- History.
- Subjective refraction.
- Slit-lamp biomicroscopy.
- Corneal topography.

They also observed that the common findings were:


- Pigmented arcs (iron rings/arcs).
- Ocular discharge in the morning.
- Lens binding.

111

**RETAINER LENSES**

- Final set of lenses used to achieve and maintain desired result
- Overnight wear capability
  - fitting characteristics
  - need good centration
  - oxygen supply
  - lens adherence a consideration
  - lenses removed in the morning after one hour open eye

998700-26S.PPT



8L9998700-26

**Retainer Lenses for Orthokeratology**

Once the stage is reached where further change is either impossible or not required, the treatment phase of the orthokeratology program is complete and the retainer phase is commenced.

When a good result is achieved with orthokeratology, the lenses employed to attain this status can be used on a limited basis to maintain the high level of unaided vision. For many wearers, the most convenient way to use a retainer lens is on an overnight schedule. The unaided vision attained following lens removal, usually at about 1 hour after waking, should be maintained during the day. The wearer should monitor any change in vision during the day. In cases that demonstrate minimal regression, the retainer lenses can be deployed on alternate nights or even less often if so desired.

The practitioner must consider slight changes to the overnight retainer lens design if they induce an unacceptably high degree of hyperopia (over-correction) or cause the lens to become adherent to the cornea. Such changes may include:

- Reduced wearing time.
- Slightly steeper BOZR.

If lenses are required for overnight wear, the practitioner must consider the importance of lens oxygen transmission to corneal health/integrity. Selection of a lens with a sufficiently high oxygen transmissibility is of paramount importance. Another key consideration for overnight wear at any time during orthokeratology is the level of comfort experienced by the patient. As a general rule to follow, it is undesirable that lenses be worn overnight if they cause any irritation.

Requirements for a successful retainer design are based on:


- Corneal shape.
- Good lens centration.
- Even distribution of pressure over the pupillary zone.
- High oxygen transmissibility to the cornea.

112

**ORTHO-K LENS CARE  
REQUIREMENTS**

- Important to maintain lens in optimum condition
  - minimize back surface deposits to prevent epithelial damage/staining
- Replace lenses annually

998700-53S.PPT




8L9998700-53

113

**REVERSE GEOMETRY LENSES**

- **Fargo Series**  
(*Contex*: Airperm material, Dk =88)
- **BE Retainer**  
(*UltraVision*: various materials)
- **Paragon CRT, ZCRT**  
(*Paragon Vis. Sci.*: pafufocon B & D, tisilfocon A )
- **Bausch & Lomb VST**  
(*Bausch & Lomb Inc.* : oprifocon A)




8L9998700-54

114

**REVERSE GEOMETRY LENSES**

- **R&R Design (Reinhart & Reeves)**  
(*R&R Lens Design*: various materials)
- **Emerald™ & Jade™**  
(*Euclid Systems Corp.*: oprifocon A)
- **Nightmove® Nightform** (Tabb)  
(*Advanced Corneal Engineering Inc.*:)
- **The OK® E-System** (Compression Ortho-K)  
- (*Contex Inc.* hexafocon A)




8L9998700-55

115

**REVERSE GEOMETRY LENSES**

- **Vipok™, Vipok II™ & Vipok XC™**  
(*Vipok Inc.*: oprifocon A)
- **OSEIRT Ortho-K**  
(*Mitsui Med. Clinic*: various materials)
- **Correctech**  
(*Correctech Inc.*: various materials)
- **EZM**  
(*Gelflex Laboratories*: various materials)




8L9998700-81

116

**REVERSE GEOMETRY LENSES**

- **Reversible Corneal Therapy**  
(*Abba Optical*: pafufocon D)
- **DreamLens®**  
(*Dreimlens Inc.*: hexafocon A)
- **OrthoFocus (Blackburn)**  
(*Metro Optics*: various)
- **Free Dimension / e Lens**
- **Alignment Series Falcon**
- **Wave System**  
(*linked to Keratron Scout topographer*)



8L9998700-83

**Orthokeratology: The Current Market**



## IV Orthokeratology: Adverse Responses and Infections

117

### COMPLIANT CONTACT LENS WEARERS INFECTIONS (in SCLs)

Najjar *et al.*, 2004

- Corneal ulcers, July 1999 – June 2002 (4 years)
- 30% of CL ulcer patients were 'compliant'
- 54% cultured *Pseudomonas* sp.
- 8% cultured *Serratia* sp.
- 2% fungus
- 23% culture-negative
- None cultured *Acanthamoeba* sp.

998700-146S.PPT



8L9998700-146

### Orthokeratology: Anterior Eye Infections

Relatively recently, reports of eye infections occurring in orthokeratology patients have appeared in the literature (see slide 120). Given that in most fundamental aspects the lenses used differ little from conventional RGP contact lenses, these reports should not be surprising. The real issue is whether their aetiology is related to orthokeratology *per se* or whether they are simply the result of RGP lens wear and the small risk attached to this type of lens wear. Even when wearers are compliant, their eyes are still susceptible to infection, albeit infrequently (Najjar *et al.*, 2004, SCL cases presented in slide 117).

118

### ORTHOKERATOLOGY SOME COMMON OBSERVATIONS

after Watt &amp; Swarbrick, 2005

- Overnight lens adherence is common
- Some mild corneal punctate staining seen
- No serious adverse responses observed, e.g. corneal infections

998700-134S.PPT



8L9998700-134

Early reports on MK causing central corneal scarring were made by Chen *et al.* (2001), Lu *et al.* (2001), Hutchinson and Apel (2002), Poole *et al.* (2003), Wang and Lim (2003), and Xuguang *et al.* (2003).

An analysis by Watt and Swarbrick (2005, 2005B) suggested that three common findings ran through most reports on routine orthokeratology patients (slide 118). Potentially, these are pre-disposing factors for an adverse event. Watt and Swarbrick found 46 reports of serious corneal infections in the orthokeratology literature since 2000. Most infections reported were caused by either *Pseudomonas aeruginosa* or *Acanthamoeba* spp. and the young (<20 years) figured disproportionately among the infected patients (e.g. Lau *et al.*, 2003; Young *et al.*, 2004; Tseng *et al.*, 2005). The bacterium *Serratia marcescens* is the most common 'other' microorganism mentioned in the literature, e.g. Yepes *et al.* (2005). Coagulase-negative *Staphylococcus* spp. have also been reported in the aetiology of orthokeratology-related MK (see Hsiao *et al.*, 2005).

119

### ORTHOKERATOLOGY PREDISPOSING FACTORS?

after Watt &amp; Swarbrick, 2005

- OK effect from:
  - central epithelial thinning
  - mid-peripheral stromal thickening
- OK ↑ bacterial adherence cf. 'normal' RGPs (at least in rabbits) – Cavanagh *et al.*, 2004
- Infective organisms suggest epithelial compromise, hypoxia, tear stagnation (O/N wear), poor lens care, and inadequate patient instructions (*P. aeruginosa*) or exposure to tap water (*Acanthamoeba* keratitis)

998700-135S.PPT



8L9998700-135

Lang and Rah (2004) reported two cases of microbial infection as well as infiltrates, toxic keratitis, and corneal abrasion in overnight orthokeratology patients in North America.

Lu *et al.* (2001), Xuguang *et al.* (2003), and Wilhelmus (2005) concluded that *Acanthamoeba* spp. is an emerging complication of orthokeratology in young adults, a fact confirmed by Watt and Swarbrick (2005B) whose survey of published reports on MK in orthokeratology suggested a 30% incidence. *Pseudomonas aeruginosa* accounted for a further 30% of cases reported (Swarbrick, 2005B increased this to 52%).

120

### ORTHOKERATOLOGY INFECTIONS/ADVERSE RESPONSES

- Chen *et al.*, 2001: *Serratia marcescens*
- Hutchison & Apel, 2002: *Pseudomonas aeruginosa*, *Acanthamoeba* sp., *Escherichia coli*
- Rah, 2003: Iron deposition line
- Young *et al.*, 2003, Lau *et al.*, 2003: *Pseudomonas aeruginosa*
- Lang & Rah, 2004: ulcer (culture-negative), *Serratia marcescens*, central stromal infiltrates, corneal abrasions
- Hsiao *et al.*, 2004: *Pseudomonas aeruginosa*
- Young *et al.*, 2004: *Pseudomonas aeruginosa*, *Xanthomonas maltophilia*, ulcer (culture-negative)
- Wilhelmus 2005: *Acanthamoeba* sp

998700-145S.PPT



8L9998700-145

Most studies report that mycotic (fungal) disease is less common in orthokeratology patients. Arguably, *Acanthamoeba* spp. are the most preventable infective agents.




121

**ORTHOKERATOLOGY  
CONTAMINATION CONTROL  
RECOMMENDATIONS**

after Cho *et al.*, 2004

- Clean, disinfect, and replace lens cases
- Hand/finger hygiene
- Do not store LCPs in bathroom
- Prepare cases, etc. before cleaning hands and handling lenses
- Wipe hands dry after rinsing
- Lens-handling finger should not touch anything, e.g. LCP bottles, other hand, spectacles, face, etc.
- Avoid eye rubbing

998700-136S.PPT 

8L9998700-136

Many cases of infection were reported to have reduced acuity at the end of their treatment, some significantly so, e.g. Lu *et al.* (2001). Furthermore, surgery, e.g. lamellar keratoplasty, was required by a significant number of cases.

A review of the countries of origin of these reports showed south-east Asia represented disproportionately, especially China (including Hong Kong) and Taiwan. Countries with extensive and historic orthokeratology experience were not exempt but contributed few cases collectively.

In a prospective Hong Kong study to investigate this issue further, Cho *et al.* (2004) found that most compliant orthokeratology lens wearers showed little or no contamination of eyes, lenses, or lens cases, while Cho (2005) reported no change in lens flora. Lens cases were the major sources of contamination and not surprisingly, failure to replace, clean, or disinfect them resulted in increasing contamination levels in all aspects tested. Compliance with lens case care instructions and/or regular replacement reduced contamination levels.

Cho *et al.*'s other recommendations included advice on finger hygiene, avoiding the storage of lens care products in bathrooms, and avoiding eye rubbing which they believed transferred organisms from the lashes and lids into the eye (slide 121).

Cho *et al.* failed to show that orthokeratology affected the eyes' normal flora. Although the normal flora may be unaltered, the characteristics of those microorganisms present may be altered.

Araki-Sasaki *et al.* (2005) reported that *Pseudomonas aeruginosa* recovered from a 17 year-old male orthokeratology patient was more resistant to antibiotics under hypoxic test conditions and the isolates formed a glycocalyx slime on the orthokeratology lens *in vitro*.

Given the incidence of *Acanthamoeba* keratitis in orthokeratology, it is imperative that strict instructions be issued about not using any form of tap water or other non-sterile rinsing solution.

Currently, the US FDA appears to be taking a cautious evidence-based approach to the reports of MK in orthokeratology and, to date, has not taken any action against the use of orthokeratology as a routine, unrestricted contact lens practice pursuit (see Saviola, 2005). The suggestion has been made that orthokeratology be limited to those 18 years and over (see Saviola, 2005; Schein, 2005) but, to date, this has not been enacted by health authorities in any country.

122

### ORTHOKERATOLOGY ADVERSE RESPONSES IN CHILDREN

- In relation to several cases of infection in Hong Kong orthokeratology children, Young *et al.*, 2004 raised issues of:
  - information availability
  - inter-professional cooperation
  - reluctance to supply information
  - practitioner inexperience
  - failure to inform patients/parents of the risks
  - unsupportable claims of 'myopia control'
  - inability of children to comprehend what they are undertaking

998700-147S.PPT



8L9998700-147

### Infections in Orthokeratology: Child Patients

Watt and Swarbrick (2005B) reported that in East Asia at least, the peak ages for MK in orthokeratology was 9 to 15 years. Even when the location is not East Asia, most MK sufferers were of Asian ethnicity (Swarbrick, 2005B). However, it is probable that, given the prevalence of myopia among Asians, there is a prevalence of Asians among those undergoing orthokeratology.

In relation to a controversial paper on infections in Hong Kong children undergoing orthokeratology treatment (Young *et al.*, 2004), issues of information availability, interprofessional cooperation, non-uniform paper publication standards, and sub-optimal information supply were raised (Byrne, 2004). The paper referred to ophthalmological follow-up to corneal ulceration in children undergoing orthokeratology in Hong Kong. Suggestions of inexperienced practitioners, commercial vested interests, poor or absent communications between the prescribing professionals and those charged with treating the adverse events that ensued, inadequate or lack of information of attendant risks, unsupportable claims of 'myopia control', and the ability of young wearers to know or understand what they are undertaking, were raised. Cho *et al.* (2005) responded to the original paper by raising issues of the usage of superceded orthokeratology lens designs and an apparent resistance on the part of the prescribers to provide lens information freely. Young *et al.* (2005) rejected this response.

Regardless of the age of the orthokeratology patient and because they were unable to determine the exact cause of infections in orthokeratology and the extent to which orthokeratology *per se* was involved in their aetiology, Watt and Swarbrick (and Swarbrick, 2004) suggested that international minimum clinical standards for safe orthokeratology be developed and promoted. Such standards are proposed to include aspects of instrumentation, patient selection, patient instruction, lens care, lens material selection, lens manufacture, and after-care.

123

### ORTHOKERATOLOGY IRON RINGS/ARCS

- Cho *et al.*, 2002
  - incomplete ring or arc similar to Fleischer's ring in keratoconus, Fe ?
  - adjacent to edge of treatment zone below tear pool
  - apparent by 2 weeks
  - may become more apparent over time
  - reversible (2-4 weeks)
- More cases reported by Rah 2003, Cho *et al.*, 2004, Hiraoka *et al.*, 2004, Cheung *et al.*, 2005

998700-149S.PPT



8L9998700-149

### Corneal Iron Lines/Rings in Orthokeratology

Cho *et al.* (2002) reported bilateral corneal iron rings in a previous SCL wearer who was moved to an orthokeratology program. The incomplete, inferior, mid-peripheral rings were apparent 2 weeks after treatment commenced and over time, progressed to nearly complete rings that were more obvious. In all other clinical aspects, the case was a little different from others undergoing orthokeratology.

The location of the rings coincided with the margins of the 'bulls-eye' apparent in the topographical maps. The authors likened the appearance to that of Fleischer's rings in keratoconus. Similar findings, including the location, were reported by Rah (2003), Liang *et al.*,

2003, and Hiraoka *et al.* (2004). Rah reviewed other corneal 'lines' (Fleischer's, Hudson-Stahli, Stocker's, Ferry's, and those appearing after refractive surgery and PK) and gave the common factors as abrupt changes in corneal curvature and the subsequent tear pooling in the adjacent space.

Cho *et al.* (2003) reported two more cases of corneal iron arcs in an orthokeratology trial. At after-care visits 2 months after treatment cessation, the arcs were no longer detectable suggesting full reversal. Rah (2005) believes the rings disappear over a 2 week to 1 month period.

More recently, a white lesion associated with a pigmented corneal ring during orthokeratology was reported by Cheung *et al.* (2005). They postulated that local stress within the cornea was the likely cause.

124

**ORTHOKERATOLOGY  
INDUCED ASTIGMATISM**

- ↑ irregular astigmatism
- Trend towards ↑ with-the-rule astigmatism
  - ↑ against-the-rule astigmatism also possible
- Even in successful orthokeratology, ↑ irregular astigmatism to be found

898700-124S.PPT



8L9998700-152

**Astigmatism**


Although irregular astigmatism and WTR astigmatism (Kerns, 1976) were identified early as an unwanted outcome of orthokeratology, Hiraoka *et al.* (2004B) showed that even in clinically successful orthokeratology, irregular corneal astigmatism was increased by the treatment. Kohnen (2004) also reported a similar finding.

125

**ORTHOKERATOLOGY  
ABERRATIONS**

- Joslin *et al.*, 2003
  - following Corneal Refractive Therapy (CRT) there was:
    - ↑ in higher-order wavefront aberrations
    - ↑ in spherical aberration especially
    - rarely an ↑ in coma-like aberrations
- Berntsen *et al.* (2005)
  - also used CRT:
    - ↑ in higher-order wavefront aberrations
    - ↑ in spherical aberration especially
    - ↓ in best-corrected VA (dilated & non-dilated pupils)
      - due partly to ↓ higher-order aberrations
- Yanai *et al.*, (2005)
  - ↓ contrast sensitivity to higher spatial frequencies

898700-148S.PPT



8L9998700-148

**Aberrations After Orthokeratology**

Joslin *et al.* (2003) reported that after Corneal Refractive Therapy (CRT) there was an increase in higher order wave-front aberrations, especially spherical aberration. Interestingly, Joslin *et al.* found one subject (of nine subjects) with an atypical outcome (relative to the rest of the group) in whom significant coma-like aberrations were noted with only slight (much less than expected) lens decentration (decentred treatment zone). They believed this suggested involvement of the deeper layers of the cornea and/or the posterior cornea in the optical outcome of the treatment.

Berntsen *et al.* (2005) also studied the effects of higher order aberrations and pupil size on BCVA after CRT and came to similar conclusions to Joslin *et al.* They also found that low contrast BCVA decreased after CRT for both dilated and non-dilated pupils. This decrease was attributed partly to the increased higher order aberrations.

Asbell (2004) also reported that orthokeratology resulted in increased higher order aberrations but that these were lower than those measured after LASIK.

Yanai *et al.* (2005) showed that following overnight orthokeratology, the contrast sensitivity for high spatial frequencies was decreased while the low spatial frequencies remained unchanged.

## V Recovery and Regression from Orthokeratology Lens Wear

126

### ORTHOKERATOLOGY REGRESSION FOLLOWING CESSATION

- Mountford, 1997B by 3 months, = 0.38 D over 8 hours
- Soni *et al.*, 2004 Cor. thick. – 1 night, curve – 1 week, Rx – 2 weeks
- Sridharan and Swarbrick (2003) 72 hours
- Barr *et al.*, 2004 72 hours
- Zhu, 2005 <3 months

998700-144S.PPT



8L9998700-144

### Overnight Orthokeratology: Recovery After Discontinuation

In an early study using early orthokeratology lenses, Horner *et al.* (1992) reported the following recoveries of the induced changes:

- After 1 hour of treatment lens wear, the corneal recovery was 95% complete by 4.21 hours.
- After hours of lens wear, 95% recovery took 6.57 hours.
- After 4 hours of lens wear, 95% recovery took 8.22 hours.

Mountford (1998) studied orthokeratology retention and regression and concluded that the first 30 days of overnight lens wear had the most significant effect in the course of orthokeratology treatment. He also found that the level of retention of the orthokeratology effects increased significantly over the first 90 days of treatment by which time the regression had stabilized at some 0.50 to 0.75 D decrease during the day.

In a short-term study of 10 low myopes, the full effects of accelerated overnight orthokeratology using reverse geometry lenses were achieved within the first week (Soni *et al.*, 2004).

Soni *et al.* then stopped lens wear for all 10 subjects. Their recovery was followed. They reported that both corneal thickness (taking just 1 night) and curvature (taking just 1 week) recovered rapidly while the Rx and binocular, uncorrected acuity recovered fully after 2 weeks. Monocular, uncorrected acuity proved to be the slowest to recover and had not recovered fully after 2 weeks.

Supporting an earlier report (Horner *et al.*, 1996) cited in their paper, Soni *et al.* showed that in short-term studies, corneal topography recovery took about twice as long as it took to effect the changes initially. The apparent discrepancy between early and full thickness and topographical recovery, and the lag in recovery of Rx and uncorrected VA, was attributed to the involvement of corneal tissue deeper than the epithelium or a change in epithelial refractive index.

Sridharan and Swarbrick (2003) showed that up to 72 hours was required for complete corneal recovery from just 1 night of orthokeratology lens wear. Similarly, Barr *et al.* (2004) reported that after 6 to 9 months of orthokeratology (using the CRT system), most of the regression following the cessation of wear occurred in the first 72 hours. The authors were unable to report on whether any residual orthokeratology effect found disappeared after their study finished or if their findings at 72 hours represented a changed refractive state, i.e. had orthokeratology altered the eyes' manifest refractive state 'permanently'? Barr *et al.* also

showed that the greater the magnitude of the change recorded, the more rapid was the recovery to baseline refraction.

The relevance of these findings to ongoing, long-term orthokeratology remains unknown. However, Zhu (2005) reported that following cessation of lens wear after 3 to 12 months of orthokeratology, the corneal curvature returned to baseline within 3 months suggesting impermanent corneal changes.

## VI Orthokeratology: Myopia Control?

127

### ORTHOKERATOLOGY MYOPIA CONTROL?

- Stone (1976) among first to raise the issue of rigid lenses 'controlling' myopia progression
- Axial elongation the main 'vehicle' of myopia progression
- Progression rate slower after puberty
- 'Case-control' studies difficult with RGP lenses – SCLs suggested for control group rather than spectacles



8L9998700-154

### Myopia: General

Apart from the early workers in orthokeratology, Stone (1976) was among the first to raise the subject of myopia control using contact lenses.

Over a 5-year period, Lin *et al.* (1996) showed that, among Taiwanese medical students, myopia progression occurred at a slower rate after puberty and that axial elongation was the primary cause of the myopic progression measured.

Walline (2004) concluded that axial length would be the best measure of myopia control in well-controlled orthokeratology studies. Since SCLs have been shown to have no effect on myopia progression (Horner *et al.*, 1999), he proposed that SCLs rather than spectacles should be used in the control groups for such studies.

128

### ORTHOKERATOLOGY MYOPIA CONTROL: THE CLAIMS

- Perrigin *et al.* (1990): RGP lenses resulted in 1/3rd the myopia  $\Delta$  cf. the spectacle group
  - only 1/2 the  $\Delta$  could be explained by corneal flattening
- Khoo *et al.* (1999): recommended RGP lenses for children exhibiting rapidly  $\uparrow$  myopia
- Cho *et al.* (2002): orthokeratology  $\downarrow$  growth of axial length significantly cf. spectacle group
- Cho *et al.* (2005): orthokeratology halves  $\uparrow$  myopia cf. spectacle wearers
- Walline (2005): RGP lenses  $\downarrow$  myopia progression significantly and corneal curvature accounts for only 1/2 the decrease recorded



8L9998700-155

### Myopia Control Using Orthokeratology: The Claims

Following a 3-year conventional RGP lens study on myopia progression, Perrigin *et al.* (1990) reported that, while the contact lens-wearing subjects showed a 0.48 D reduction in myopia *versus* 1.53 D in the spectacle wearing controls, only about half (0.37 D) the change could be explained by corneal flattening. They attributed the apparent disparity between refractive and corneal curvature findings to an inability of a keratometer to measure 'flattened' corneas.

After a 3-year study of young conventional RGP lens wearers, Khoo *et al.* (1999) recommended that RGP lenses could be used in children exhibiting rapid progression of myopia. However, only 10 of the 100 children who started the trial showed arrest of myopia. Further, Khoo *et al.* reported that when lens wear was discontinued for more than 2 months, the refractive states of the children changed minimally, indicating that the controlling effect from lens wear was not purely corneal.

Cho (2004) and Cho *et al.* (2005) reported initial findings on their LORIC (Longitudinal Orthokeratology Research in Children) study undertaken in Hong Kong. They reported:

- Myopia reduction up to 4.00 D (2004) and 4.50 D (2005).
- A mean eye elongation in the orthokeratology children that was about half the spectacle wearing children.
- Substantial individual variation in the degree of elongation (multifactorial myopia aetiology?).

They suggested that orthokeratology was an option for slowing myopic progression in children but there was no way of predicting the degree of an individual's progression slowing.



Yee (2000), in a report published only on the Hong Kong Ortho-K Society website, recorded a slowing down of myopia progression with RGP lenses in general (97% 'success' rate claimed) and 4-zone orthokeratology lenses in particular, providing that the lenses centred well and were fitted at least 1.00 D flatter than the flattest K. Yee reported that 14 of the 519 patients in his study actually experienced an increase in myopia, nine of whom responded beneficially to a change in lens design (from a 3-zone to a 4-zone design).

Cho *et al.* (2002B) found that orthokeratology reduced the growth of eyeball axial length significantly compared with a spectacle-wearing control group. Since then, Cheung *et al.* (2004) (Cho was a co-author) reported a case of unilateral overnight orthokeratology whose results suggested that orthokeratology had slowed the rate of axial length increase in the treated eye only.

A study of orthokeratology in adolescents by Reim *et al.* (2003) concluded that the DreamLens<sup>®</sup> orthokeratology lenses used had a similar effect on myopia progression as RGP DW lenses, i.e. the rate of progress was reduced but not eliminated. However, the authors stopped short of claiming that orthokeratology slowed myopia progression and advised practitioners against making such an assertion.


Walline (2005) reported that RGP lenses slow myopia progression significantly and as others had already reported, corneal curvature accounts for about half of the decrease recorded.

129

**ORTHOKERATOLOGY  
MYOPIA CONTROL: THE COUNTER-CLAIMS**

- Polse *et al.* (1983): using early orthokeratology reported that ↓ myopia did not persist once orthokeratology treatment ceased
- Saw *et al.* (2002): reviewed the literature and concluded that no conclusive evidence existed to support the claim
- Walline *et al.* (2004): RGP lens wearers progressed less than SCL wearers. Concluded: RGPs not to be prescribed primarily for myopia control

898700-156S.PPT



8L9998700-156

### Myopia Control Using Orthokeratology: The Counter-Claims

From the Berkeley study using early orthokeratology techniques, Polse *et al.* (1983C) reported that any reduction of myopia seen in orthokeratology did not persist once orthokeratology treatment ceased.

Andreo (1990) studied the long-term effects of SCLs on myopia and concluded that there was no statistically significant difference between the contact lens-wearing group and spectacle wearers. However, Caroline and Campbell (1991) chose to disagree with Andreo's study outcome despite finding little supporting information in the literature. Caroline and Campbell proposed that from their own experiences, there was evidence of 'myopic creep', i.e. the frequent requirement to increase minus BVP in long-term SCL wearers.

The issue was never resolved although a report from Fulk *et al.* (2003) is more supportive of the Caroline and Campbell proposal and the conclusions from Santodomingo-Rubido *et al.* (2005) lend weak support in relation to siloxane hydrogel lens wearers.

Grosvenor *et al.* (1991) studied myopic children who wore RGP lenses for 44 months who were discontinued subsequently for 2.5 months before

resuming lens wear. The authors suggested that the 2.5 month break from lens wear diminished the effect RGP lens wear had on myopia progression, cf. spectacle lens wear for a similar period.

Because the refractive effects they were monitoring were not explained by keratometer reading changes, they postulated them to be due to corneal apical flattening inside the corneal zone measure by keratometers, i.e. the zone not measurable with keratometers. It is possible that some videokeratoscopes have similar limitations and the central data presented is the result of interpolation rather than true central measurements.

Saw *et al.* (2002) reviewed the literature on arresting myopia progression and concluded that no conclusive evidence existed that any of the extensive array of methods employed previously or currently were effective.

Walline *et al.* (2004B) studied the effect of conventional RGP lenses on myopia progression. While finding that RGP wearers progressed less than SCL wearers (SCL wearers steepened more than RGP wearers while the axial length remained insignificantly different and the effects were limited to the first year of wear), they concluded that RGP lenses should not be prescribed primarily for myopia control. Andreo (1990) and Horner *et al.* (1999) had already shown that SCLs had no effect on myopia progression in children.


## VII Orthokeratology: Problem Solving

130

**ORTHO-K PROBLEMS FITTING**

- Tight lens fitting
  - BOZR too steep
  - total diameter too large
  - tear reservoir too deep
  - rapid corneal response (too rapid?)
- Loose lens fitting
  - BOZR too flat
  - total diameter too small

998700-27S.PPT




8L9998700-27

131

**ORTHO-K PROBLEMS BASED ON TOPOGRAPHY**

- Central islands
  - indicate that the lens BOZR is not flat enough
  - excessively tight mid-peripheral bearing
  - a refit is required

998700-47S.PPT




8L9998700-47

132

**ORTHO-K PROBLEMS BASED ON TOPOGRAPHY**

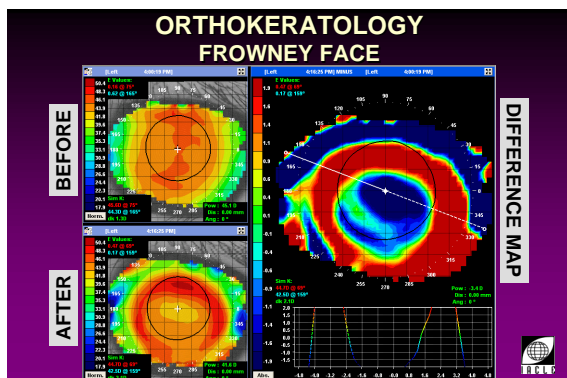
- Inferior 'smile' pattern
  - indicates a superior decentration
  - lens fitting is too flat
  - total diameter is too small
  - underestimate of corneal sag
  - a refit is required

998700-46S.PPT



8L9998700-80

133



8L9998700-162

### Problems Associated with Orthokeratology Fitting

A number of problems can occur when fitting orthokeratology lenses. These include:

- Excessively tight fitting.
- Excessively loose fitting.
- Superior/inferior lens decentration.
- Lateral decentration.
- Poor unaided vision.
- Rapid regression of the refractive error.

An assessment of the appropriateness of lens fit should be based on corneal topography findings or fluorescein pattern analysis, or both.

### Problems: Topography

Excessively tight or loose fitting lenses can be determined by analyzing the subtractive topography plots.

If trial lens wear results in a subtractive topography plot suggestive of the formation of a central island, the lens BOZR is not sufficiently flat. This results in an inadequate central compression of the corneal epithelium. The subtractive topography plot should show a relatively steeper central zone (the island or central island, slide 105) surrounded by a deep circle of flattening.

If the trial lens results in a subtractive topography plot showing a 'smiley face' pattern, then the BOZR is too flat. The topography plot should show a superiorly decentered flat zone with a partial ring below it with a relatively steeper zone (the smile).

An inverted pattern to the 'smiley face' (slide 106) is referred to as a 'frown' or 'frowney' pattern (slide 133). In this case the relatively steeper zone is located superiorly (the frown) with an inferiorly placed flat zone. The cause of a 'frown' pattern is a total lens diameter (TD) that is too small.

### Problems: Fluorescein Pattern

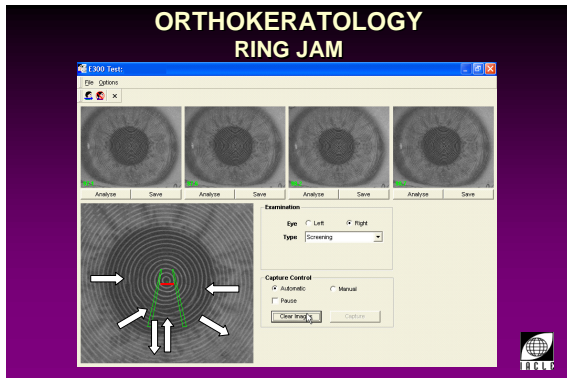
Lens centration is an important factor in successful orthokeratology. Any decentration produces an off-axis irregular flattening of the cornea.

According to Yang *et al.* (2003), lens decentration depends on:

- Initial refractive error.
- Astigmatism.
- Orthokeratology lens design.

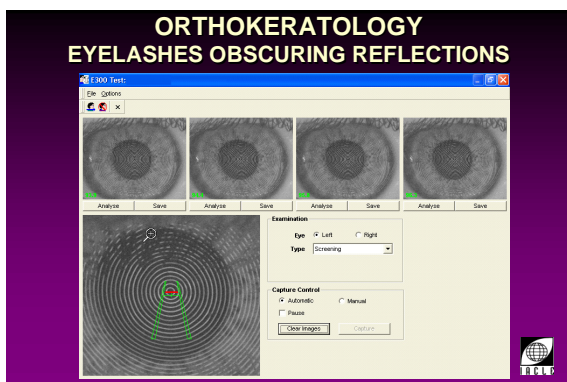
In cases of superior decentration, the superior cornea flattens and the inferior cornea steepens. If this occurs over the pupil zone, the uncorrected vision suffers from ghost images.

134



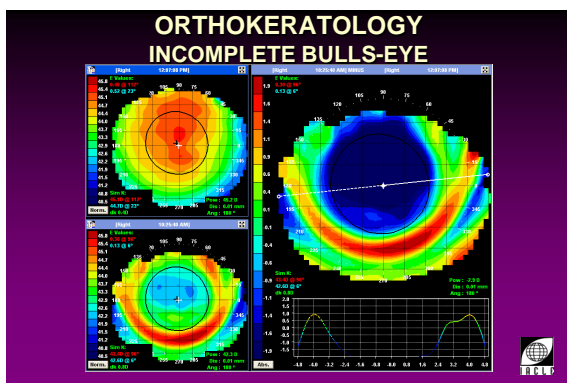
8L9998700-163

135



8L9998700-165

136



8L9998700-164

137

**ORTHO-K PROBLEMS  
CENTRATION**

- Superior decentration
  - BOZR too flat
  - total diameter too small
  - high minus lens power

998700-28S PPT

8L9998700-28

The appearance of a superior inverted 'smiley face' pattern, i.e. the so-called 'frowney face' pattern (slide 133), is indicative of a lens that has decentred inferiorly. This is most often due to an alignment/fitting curve that is too steep or a lens TD that is too small.

Slide 139 shows a conventional tricurve design retainer lens exhibiting decentration in all four possible directions, i.e. superior, nasal, inferior, and temporal. Despite appearances, this lens gave surprisingly good results with stable and repeatable uncorrected VA of 6/4.5 (20/15).

Some difficulties include:


- 'Ring Jam' – local topographical irregularities that result in crowding of rings, incomplete rings, ring irregularity, etc. (slide 134).
- Eyelashes obscuring the corneal ring reflections (slide 135).
- Incomplete bulls-eye plots (slide 136).

138

**ORTHO-K PROBLEMS  
CENTRATION**

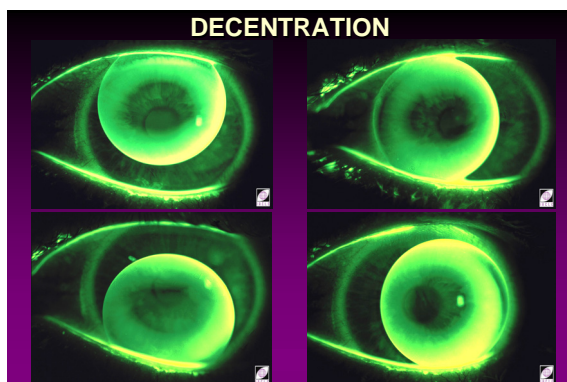
- Inferior decentration
  - BOZR too steep
  - total diameter too small
  - loose lid
  - corneal apex too low

998700-29S.PPT



8L9998700-29

139




8L9FIG07ABCD

140

**ORTHO-K PROBLEMS  
CENTRATION**

- Lateral decentration
  - lid force
  - eccentric corneal apex position
    - shows as a decentred topography plot
  - total diameter too small

998700-30S.PPT




8L9998700-30

141

**ORTHO-K PROBLEMS  
CORNEAL CHANGES**

- Corneal staining
  - lens has too much central bearing
  - trapped debris under lens
  - roughened lens surface
    - deposits on back surface
    - manufacturing defect(?)
- Corneal distortion
  - lens decentred

998700-31S.PPT



8L9998700-31

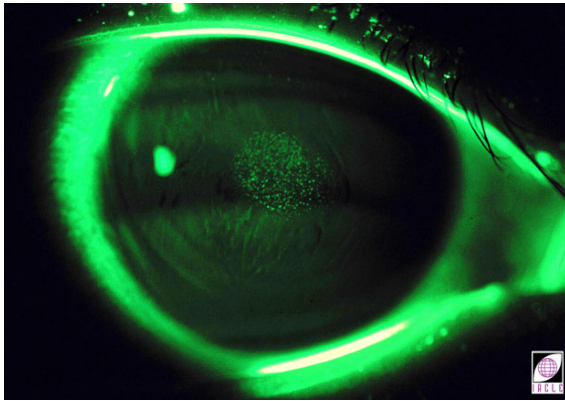
### Corneal Staining and Distortion

In general, there is less corneal staining induced by orthokeratology lenses than might be expected given the flatness of the fittings being attempted. However, staining can occur in up to 45% of young subjects especially in those with existing tear problems (Fan *et al.*, 1999). When corneal staining occurs, the possible causes include:

- Underlying dry eye problem.
- Back surface debris and deposits.
- Trapped foreign body.
- Lens surface scratches.
- Lens adherence.

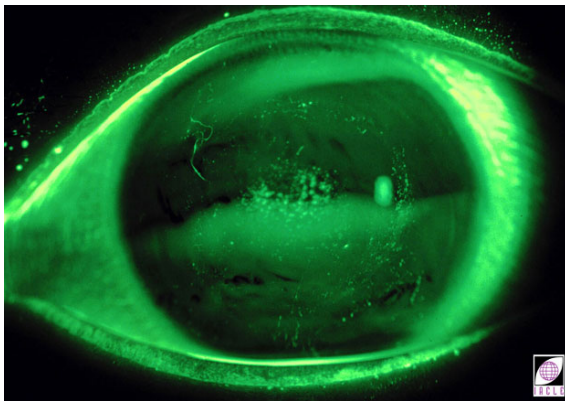


142



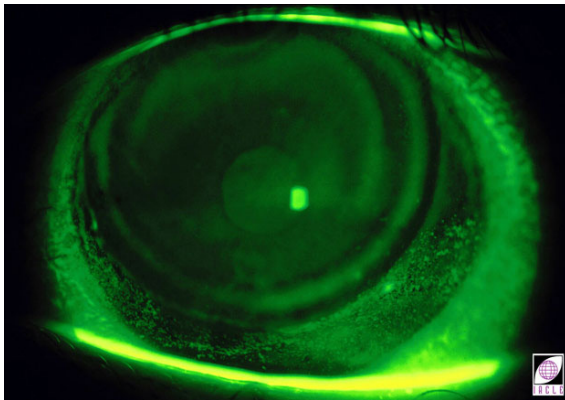
8L9FIG09A

143



8L9FIG09B

144



8L9FIG09C

- Improper removal of an adherent lens.
- BOZR too flat.

Care must be taken to distinguish between true corneal staining and the appearance of thickened mucus on the epithelium following removal of an adherent orthokeratology lens. It may take some minutes for the mucus to dilute and for the appearance of the epithelium to normalize.

The back surface shape of an orthokeratology lens can make it difficult to remove all surface deposit with regular digital cleaning techniques. Any build-up of deposits, especially in the return zone, can cause epithelial staining. In such cases, an alternative cleaning technique such as the careful, routine use of cotton buds (cotton tips) soaked in the recommended RGP cleaning solution can be recommended for cleaning the back surface.

Any dense, coalescent epithelial staining should be reviewed after a few hours without lens wear to ensure adequate healing has taken place. Slide 142 shows mild central punctate staining that will resolve fully several hours after lens removal. This is a commonly encountered adaptive response to overnight lens wear requiring no specific intervention.


If it is determined that the lens design contributes to the staining, then another lens must be fitted to ensure that chronic epithelial damage does not occur. Slide 143 shows moderate, coalesced corneal staining that may be indicative of excessive central bearing. Slide 144 shows severe corneal indentation, grooving, and peripheral punctate staining (there was no lens on the eye when the picture was taken), indicating the potential consequences of an excessively flat fit with resultant lens decentration.

145

**ORTHO-K PROBLEMS**  
**CORNEAL CHANGES**

- Corneal erosions
  - excessive central lens bearing
  - lenses over-worn ?
  - assess with a topographer and by use of sodium fluorescein stain

998700-49S.PPT



8L9998700-49




146

**ORTHO-K PROBLEMS**  
**LENS ADHERENCE**

- Common after overnight RGP lens wear
  - aqueous thinning and increased tear viscosity
- Not dictated by lens parameters
- Patient education is vital
  - detect a bound lens
  - method of release
- Removing a bound lens causes epithelial trauma and pain

996700-50S.PPT



8L9998700-50

**Lens Adherence in Orthokeratology**

Lens adherence to the cornea (slide 147) following overnight wear is an expected event. Thinning of the post-lens aqueous tear film and an increase in its viscosity during the overnight wear period causes this phenomenon (see Swarbrick, 1991).

Lens adherence (binding) prevents sodium fluorescein from readily permeating the post-lens space, resulting in a largely dark zone other than a small region where the dye has entered via one of the fenestrations (inferior) (slide 147). If lens binding is a result of applying an overly 'aggressive' orthokeratology lens design, it may be that the application of a less 'aggressive' design may resolve the recurring problem (Chui and Cho, 2003).

The wearer must be educated in advance of overnight lens wear to detect a bound lens and know how to remove it safely. It is important that complete, free lens movement is restored before attempts are made to remove the lens from the eye. Actions taken to remove a lens while bound may lead to epithelial trauma and ocular pain.

Recommended instructions include:

- Instillation of artificial tears.
- Digital manipulation of the lens at or near the lens edge using the lower lid margin to promote flow of tear fluid under the lens.
- Add more artificial tears if needed.
- Continue gentle digital manipulation until adequate lens movement is detected.
- If in doubt, manipulate the lens longer.

Fenestrations in the lens may be placed in the region of the tear reservoir to promote tear exchange, however, they do affect the likelihood of the lens adhering during overnight wear. The venting effect of the fenestrations is clearly evident in slide 148 as fluid escapes from the tear reservoir onto the anterior lens surface (from top left fenestration).

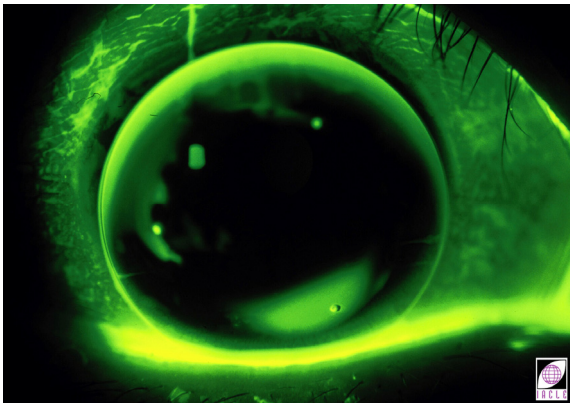
Although fenestrations will not prevent lens binding, they play an important role in the control of fluid dynamics under the lens. The fenestration may make it easier to loosen a bound lens by digital manipulation.

It is not necessary to redesign the lens in cases of lens adherence. Patient education regarding proper lens removal technique is all that is required usually.

Some orthokeratology lenses are thinner by virtue of their design. It is probable that thinner lenses are more:

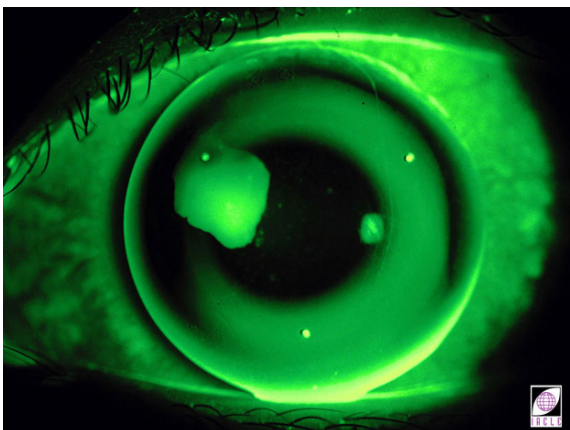
- prone to lens adherence (because they are less rigid).
- 'conforming' (to corneal shape).
- fragile (despite their greater flexibility).

147



8L9FIG10

148




8L9FIG11

149

**ORTHO-K PROBLEMS**  
VISION

- Poor unaided VA
  - distortion from lens decentration
  - treatment zone too small
  - large pupil diameter
  - tight lens effects
  - lens changes made too rapidly

998700-32S.PPT



8L9998700-32

These issues suggest that patients using thin designs and prone to episodes of lens adherence should be educated more carefully about dealing with lens adherence to reduce the risk to their lenses.

### Vision Problems in Orthokeratology

The relative size of the orthokeratology treatment zone to the normal pupil diameter is crucial to obtaining satisfactory unaided vision. If the treatment zone is too small relative to the pupil diameter, the vision is likely to be compromised by ghost images, flare, and haloes around lights. This can occur during daylight hours but is more likely in dim illumination when the pupil dilates.

In cases in which adequate vision was achieved but the vision became worse subsequently, the practitioner should consider the following possibilities:


- Lenses are worn in the incorrect eyes, i.e. they were swapped over.
- Lens has become warped.
- Corneal distortion has occurred.

150

**ORTHO-K PROBLEMS**  
REGRESSION

- Rapid regression
  - insufficient central bearing
  - poor retainer lens design
  - lens changes occurred too rapidly

998700-33S.PPT



8L9998700-33

### Refractive Regression Following Lens Removal

A degree of refractive regression should be anticipated following lens removal. In many cases the amount of regression is relatively small and occurs over a number of hours of no lens wear. Mountford (1997B) predicted a regression effect of approximately 0.38 D over an 8-hour period by the third month of orthokeratology lens wear.


If possible, the refractive change induced should result in approximately 0.5 D of hyperopia to account for the regression. When a rapid regression occurs, the target refractive error should be a slightly higher degree of hyperopia. A change in the retainer lens design may be required to achieve this effect as well as maintaining an every-night wear schedule.

151

**ORTHO-K PROBLEMS**  
STROMAL OEDEMA

- Presence of oedema following overnight RGP lens wear
  - striae
  - folds
- Consider lens  $Dk/t$ 
  - always use high  $Dk$  lens materials
  - increase  $Dk$  if possible

998700-52S.PPT



8L9998700-52

### Corneal Oedema and Overnight Wear

It is important for RGP lenses with a high oxygen permeability ( $Dk$ ) to be used for orthokeratology. The design required for orthokeratology results in a relatively thick lens, thus, reducing the oxygen transmission ( $Dk/t$ ) to the cornea. In some cases, the reduced oxygen supply results in stromal oedema that presents as striae or, if the oedema is significant enough, endothelial folds (see Module 7, Lecture 7.2, Section *II.A.I Striae and II.A.II Folds and Black Lines*).


The morning after-care visits should be scheduled to occur as soon as practicable after the lens wearer wakes up. This maximizes the opportunity for their practitioner to observe the cornea and to detect the presence of any striae or folds.

152

**ORTHO-K PROBLEMS**  
**LACK OF SUCCESS**

- With repeated trials
  - unrealistic to expect 100% success rate
  - some patients become 'grief' cases
  - poor patient selection in the first case?
    - deep set eyes
    - inaccurate topography measurements
  - consider alternative lens manufacturer/design

998700-51S.PPT



8L9998700-51

**Repeated Lack of Success**

It is important for the orthokeratology practitioner to work within well-defined boundaries when attempting to fit a strongly motivated patient. It is rare for a successful result to occur 'unexpectedly'. Success occurs as a result of diligent work by the practitioner based on a thorough understanding of what can be achieved, how it can be achieved, the limitations of the process, and how the actual results achieved were reached.

To maximize success with orthokeratology, use of an alternative lens design is recommended when the practitioner's first choice lens design proves incapable of achieving a satisfactory fit.


Orthokeratology is a time-consuming and involved lens fitting procedure. In some cases it is in the practitioner's best interest to cease fitting a potential wearer if the preliminary measurements and results indicate that a successful fitting is unlikely.

153

**ORTHO-KERATOLOGY**

- Safe procedure but the effect on refractive error is variable
  - within individuals
  - between individuals
- Not permanent
- Myopia control in children?

998700-34S.PPT



8L9998700-34

**Summary of Orthokeratology**

Orthokeratology is a proven technique for managing the mild to moderate myope. The development of advanced high Dk RGP lens designs and materials (see Sakamoto and Sugimoto, 2004; Swarbrick *et al.* 2005C) for the procedure has resulted in a better understanding of the orthokeratology process and has enabled the practitioner to employ a relatively predictable procedure based on corneal topography measurements and other clinical observations and measurements.

Although there is only limited evidence that orthokeratology can retard myopia development in children (see earlier), it is a technique that can be used to provide an alternative correction to spectacles, contact lenses, and refractive surgery in its various forms.

In the future, in addition to the myopia targeted currently, hyperopia (Reeder, 2005; Mitsui *et al.*, 2005), astigmatism in selected cases (Berke and Starfinger, 2005), high astigmatism (Baertschi, 2005), and presbyopia (Calossi, 2005) may be the targets of successful future orthokeratology treatments.

## References

- Alharbi A, Swarbrick HA (2003). *The effects of overnight orthokeratology lens wear on corneal thickness*. Invest Ophthalmol Vis Sci. 44(6): 2518 – 2523.
- Alharbi A, et al. (2005). *Overnight orthokeratology lens wear can inhibit central stromal edema response*. Invest Ophthalmol Vis Sci. 45(7): 2334 – 2340.
- Andreo LJ (1990). *Long term effects of hydrophilic contact lenses on myopia*. Annals Ophthalmol. 22(6): 224 - 229.
- Araki-sasaki K, et al. (2005). *Characteristics of Pseudomonas corneal infection related to orthokeratology*. Cornea. 24(7): 861 - 863.
- Asbell PA (2004). *Quality of vision with corneal refractive therapy*. Eye & CL. 30(4): 234 – 235.
- Baertschi M (2005). *Correction of high astigmatism with orthokeratology*. Paper presented at the 2005 Global Orthokeratology Symposium, Chicago.
- Barr JT, et al. (2003). *Orthokeratology and corneal refractive therapy: A review and recent findings*. Eye & CL. 29(1S): S49 – S53.
- Barr JT, et al. (2004). *Recovery of refractive error after corneal refractive therapy*. Eye & CL. 30(4): 247 – 251.
- Becherer PD, Kempf JA (2004). *Endothelial response to overnight corneal reshaping*. Eye & CL. 30(4): 207 – 210.
- Berke A, Starfinger A (2005). *Astigmatism after orthokeratology*. Paper presented at the 2005 Global Orthokeratology Symposium, Chicago.
- Berntsen DA, et al. (2005). *The effect of higher-order aberrations and pupil size on best corrected visual acuity after corneal refractive therapy (CRT)*. Paper presented at the 2005 Global Orthokeratology Symposium, Chicago.
- Binder PS, et al. (1980). *An evaluation of orthokeratology*. Ophthalmology. 87: 729 – 744.
- Boneham G (2001). *Orthokeratology in practice*. Lecture Notes in OPTM 8011: School of Optometry, UNSW.
- Brand RJ, et al. (1983). *The Berkeley Orthokeratology Study, Part I: General conduct of the study*. Am J Optom Physiol Opt. 60(3): 175 – 186.
- Byrne J (2004). *Small study claims ortho-K caused infection, vision loss in children*. Prim Care Optom News. 6/1/2004.
- Calossi A (2005). *Orthokeratology and presbyopia*. Paper presented at the 2005 Global Orthokeratology Symposium, Chicago.
- Carkeet NL, et al. (1995). *Predicting success with orthokeratology lens wear: a retrospective analysis of ocular characteristics*. Optom Vis Sci. 72: 892 – 898.
- Caroline PJ (2001). *Contemporary orthokeratology*. Cont Lens & Ant Eye. 24: 41 – 46.
- Caroline PJ (2005). *Orthokeratology after refractive surgery*. Paper presented at the 2005 Global Orthokeratology Symposium, Chicago.
- Caroline P, Campbell R (1991). *Long term effects of hydrophilic contact lenses on myopia*. CL Spectrum. 5(6): 68.
- Caroline PJ, Choo JD (2003). *Modern corneal reshaping with contact lenses*. Ophthalmol Clin Nth Am. 16: 405 – 413.
- Chen KH, et al. (2001). *Serratia marcescens corneal ulcer as a complication of orthokeratology*. Am J Ophthalmol. 132(2): 257 – 258.
- Cheung SW, Cho P (2004). *Subjective and objective assessments of the effect of orthokeratology – a cross-sectional study*. Curr Eye Res. 28(2): 121 – 127.

- Cheung SW. *et al.* (2004). *Asymmetrical increase in axial length in the two eyes of a monocular orthokeratology patient.* *Optom Vis Sci.* 81: 653 – 656.
- Cheung SW. *et al.* (2005). *White lesion in the corneal pigmented ring associated with orthokeratology.* *Ophthalmol Physiol Opt.* 25(3): 264 – 268.
- Cho P (2004). *The Longitudinal Orthokeratology Research in Children (LORIC) study in Hong Kong.* Paper presented at the 4<sup>th</sup> Conference, Orthokeratology Society of Australia, Gold Coast.
- Cho P (2005). *Microbial flora of tears of children wearing orthokeratology lenses and microbial contamination of lenses and lens accessories.* Paper presented at the 2005 Global Orthokeratology Symposium, Chicago.
- Cho P. *et al.* (2002). *Corneal iron ring associated with orthokeratology lens wear.* *Optom Vis Sci.* 79(9): 565 – 568.
- Cho P. *et al.* (2002B). *Ocular changes and myopia progression after 12 months orthokeratology lens wear.* Paper presented at the 9<sup>th</sup> International Conference on Myopia (Hong Kong Section), Nov, 2002, Hong Kong.
- Cho P. *et al.* (2003). *Reversibility of corneal pigmented arc associated with orthokeratology.* *Optom Vis Sci.* 80(12): 791 – 795.
- Cho P. *et al.* (2004). *Microbial flora of tears of Ortho-K patients, and microbial contamination of contact lenses and contact lens accessories.* Paper presented at the Orthokeratology Society of Australia, Gold Coast.
- Cho P. *et al.* (2004). *Letter to the editor. Orthokeratology lens-related corneal ulcers in children.* *Ophthalmology* 112(1): 167 – 168.
- Cho P. *et al.* (2005). *Myopia control with orthokeratology.* Paper presented at the 2005 Global Orthokeratology Symposium, Chicago.
- Choy CK. *et al.* (2004). *Effect of one overnight wear of orthokeratology lenses on tear composition.* *Optom Vis Sci.* 81(6): 414 – 420.
- Chui WS, Cho P (2003). *Recurrent lens binding and central island formations in a fast-responding orthokeratology lens wearer.* *Optom Vis Sci.* 80(7): 490 – 494.
- Coon LJ (1982). *Orthokeratology, Part 1: Historical perspective.* *J Am Optom Assoc.* 53: 187 – 195.
- Coon LJ (1984). *Orthokeratology, Part 2: Evaluating the Tabb method.* *J Am Optom Assoc.* 55: 409 – 418.
- Dave T, Ruston D (1998). *Trends in modern orthokeratology.* *Optician.* 215(5645): 20 – 24.
- Dave T, Ruston D (1998B). *Current trends in modern orthokeratology.* *Ophthalmol Physiol Opt.* 18(2): 224 – 233.
- Erickson PM (1978). *Accounting for refractive change in orthokeratology.* *Contacto.* 22: 9 – 12.
- Fan L *et al.* (1999). *Clinical study of orthokeratology in young myopic adolescents.* *Int Cont Lens Clin.* 26(5): 113 – 116.
- Fulk GW *et al.* (2003). *The effect of changing from glasses to soft contact lenses on myopia progression in adolescents.* *Ophthalmol Physiol Opt.* 23: 71 – 77.
- Grant SC, May CH (1970). *Orthokeratology – a therapeutic approach to contact lens procedures.* *Contacto.* 14: 3 – 16.
- Grosvenor T, *et al.* (1991). *rigid gas-permeable contact lenses for myopia control: Effects of discontinuation of lens wear.* *Optom Vis Sci.* 68(5): 385 – 389.
- Harris DH, Stoyan N (1992). *A new approach to orthokeratology.* *CL Spectrum.* 7(4): 37 – 39.
- Hiraoka T, *et al.* (2004). *Corneal iron ring formation associated with overnight orthokeratology.* *Cornea.* 23(8): S78 – S81.
- Hiraoka T, *et al.* (2004B). *Quantitative evaluation of regular and irregular corneal astigmatism in patients having overnight orthokeratology.* *J Cataract Refract Surg.* 30(7): 1425 – 1429.

- Holden BA (1970). *PhD Thesis* The City University, London.
- Horner DG, *et al.* (1992). *Corneal molding recovery after contact lens wear*. *Optom Vis Sci.* 69 (12) (Suppl.): 156 – 157.
- Horner DG, *et al.* (1999). *Myopia progression in adolescent wearers of soft contact lenses and spectacles*. *Optom Vis Sci.* 76: 474 – 479.
- Hsiao C-H, *et al.* (2004). *Pseudomonas aeruginosa corneal ulcer related to overnight orthokeratology*. *Chang Gung Med.* 27: 182 – 187.
- Hsiao C-H, *et al.* (2005). *Infectious keratitis related to overnight orthokeratology*. *Cornea.* 24(7): 783 – 788.
- Hutchinson K, Apel A (2002). *Infectious keratitis in orthokeratology*. *Aust NZ J Ophthalmol.* 30: 49 – 51.
- Jackson JM, *et al.* (2004). *Short-term corneal changes with corneal refractive therapy*. *Invest Ophthalmol Vis Sci. Abstracts:* 1547/B358.
- Jayakumar J, Swarbrick HA (2004). *Age is a significant contributing factor in the corneal response to orthokeratology lens wear*. Paper to the annual conference of the Orthokeratology Society of Australian, Gold Coast, Australia.
- Jessen GN (1962). *Orthofocus techniques*. *Contacto.* 6: 200 – 204.
- Joe JJ, *et al.* (1996). *The relationship between corneal eccentricity and improvement in visual acuity with orthokeratology*. *J Am Optom Assoc.* 67: 87 – 97.
- Joslin CE, *et al.* (2003). *Higher-order wavefront aberrations in corneal refractive therapy*. *Optom Vis Sci.* 80(12): 805 – 811.
- Kerns KL (1976). *Research in orthokeratology, Part III; Results and observations*. *J Am Optom Assoc.* 47(12): 1505 – 1515.
- Khoo CY, *et al.* (1999). *A 3-year study on the effect of RGP contact lenses on myopic children*. *Singapore Med J.* 40(4): 230 – 237.
- Koffler BH, *et al.* (2004). *myopia reduction using corneal refractive therapy contact lenses*. *Eye & CL.* 30(4): 223 – 226.
- Kohnen T (2004). *Overnight orthokeratology induces irregular corneal astigmatism*. *J Cataract Refract Surg.* 27(3): 182 – 187.
- Lang J, Rah MJ (2004). *Adverse corneal events associated with corneal reshaping: A case series*. *Eye & CL.* 30(4): 231 – 233.
- Lau LI, *et al.* (2003). *Pseudomonas corneal ulcer related to overnight orthokeratology*. *Cornea.* 22(3): 262 – 264.
- Liang JB, *et al.* (2003). *Corneal iron ring associated with orthokeratology*. *J Cataract Refract Surg.* 29(3): 624 – 626.
- Lin L (L-K), *et al.* (1996). *Changes in ocular refraction and its components among medical students – A 5-year longitudinal study*. *Optom Vis Sci.* 73(7): 495 – 498.
- Lipson MJ (2004). *Overnight corneal reshaping versus soft daily wear. A visual quality of life study (interim results)*. *Eye & CL.* 30(4): 214 – 217.
- Lipson MJ, *et al.* (2005). *Overnight corneal reshaping versus soft disposable contact lenses; Vision-related quality-of-life differences from a randomized clinical trial*. *Optom Vis Sci.* 82(10): 886 – 891.
- Lowe R (2001). *Ortho-K slows myopia progression in children?* Presentation to the International Society for Contact Lens Research, Sun Valley, Idaho.
- Lowe R (2004). *Corneal refractive therapy, uncorrected visual acuity, and “E” values: Personal experiences*. *Eye & CL.* 30(4): 238 – 241.
- Lu L, *et al.* (2001). *Orthokeratology induced infective corneal ulcer*. *Zhonghua Yan Ke Za Zhi.* 37(6): 443 – 446.



- Maldonado-Codina C, et al. (2005). *Empirical versus trial fitting systems for accelerated orthokeratology*. Eye & CL. 31(4): 137 – 147.
- Marsden HJ, et al. (1993). *The relationship between corneal eccentricity and improvement in visual acuity orthokeratology*. Optom Vis Sci. 70(12s)(Supl.): 139.
- Matsubara M, et al. (2004). *Histologic and histochemical changes in rabbit cornea produced by an orthokeratology lens*. Eye & CL. 30(4): 198 – 204.
- Mika R, et al. (2005). *Safety and efficacy of overnight orthokeratology in myopic children*. Paper presented at the 2005 Global Orthokeratology Symposium, Chicago.
- Mitsui I, et al. (2005). *OSEIRT/Ortho-K indications for the hyperopia patients*. Paper presented at the 2005 Global Orthokeratology Symposium, Chicago.
- Mountford J (1997B). *Orthokeratology Chapter 19*. In: *Contact Lenses 4<sup>th</sup> ed*. Phillips AJ and Speedwell L (Eds). Butterworth-Heinemann, Oxford.
- Mountford J (1997). *An analysis of the changes in corneal shape and refractive error induced by accelerated orthokeratology*. Int Cont Lens Clin. 24: 128 – 144.
- Mountford J (1998). *Retention and regression of orthokeratology with time*. Int Cont Lens Clin. 25(2): 59 – 64.
- Mountford J, Pesudovs K (2002). *An analysis of the astigmatic changes induced by accelerated orthokeratology*. Clin Exp Optom. 85(5): 284 – 293.
- Najjar DM, et al. (2004). *Contact lens-related corneal ulcers in compliant patients*. Am J Ophthalmol. 137(1): 170 – 172.
- Nichols JJ, et al. (2000). *Overnight orthokeratology*. Optom Vis Sci. 77(5): 252 – 259.
- Nyquist GW (1968). *Rheology of the cornea: experimental techniques and results*. Exp Eye Res. 7: 183 – 188.
- Owens H, et al. (2004). *Posterior corneal changes with orthokeratology*. Optom Vis Sci. 81(6): 421 – 426.
- Patterson TC (1975). *Orthokeratology: changes to the corneal curvature and the effect on refractive power due to sagittal length change*. J Am Optom Assoc. 46: 714 – 729.
- Perrigin J, et al. (1990). *Silicone-acrylate contact lenses for myopia control: 3-year results*. Optom Vis Sci. 67(10): 764 – 769.
- Phillips AJ (1995). *Orthokeratology – an alternative to excimer laser*. J BCLA. 18: 65 – 71.
- Polse KA, et al. (1983). *The Berkeley Orthokeratology Study, Part II: Efficacy and duration*. Am J Optom Physiol Opt. 60(3): 187 - 198.
- Polse KA, et al. (1983B). *The Berkeley Orthokeratology Study, Part III: Safety*. Am J Optom Physiol Opt. 60(4): 321 – 328.
- Polse KA, et al. (1983C). *Corneal changes accompanying orthokeratology. Plastic or elastic?* Arch Ophthalmol. 101: 1873 – 1878.
- Poole TR, et al. (2003). *Microbial keratitis following orthokeratology*. Eye. 17(3): 440 – 441.
- Rah MJ, et al. (2002). *Overnight orthokeratology: preliminary results of the Lenses and Overnight Orthokeratology (LOOK) study*. Optom Vis Sci. 79(9): 598 – 605.
- Rah MJ (2003). *Iron deposition in Ortho-K patients*. CL Spectrum. on-line: [www.clspectrum.com/article.aspx?article=12273](http://www.clspectrum.com/article.aspx?article=12273).
- Rah MJ (2005). *Iron deposition rings: Now you see them...Now you don't*. CL Spectrum. on-line: [www.clspectrum.com/article.aspx?article=12758](http://www.clspectrum.com/article.aspx?article=12758).
- Rao SN, et al. (2000). *The effect of age on the refractive outcome of myopic photorefractive keratectomy*. J Cat Refract Surg. 26:543 - 546.

- Reeder K (2005). *Correction of hyperopia with orthokeratology*. Paper presented at the 2005 Global Orthokeratology Symposium, Chicago.
- Reim TR, et al. (2003). *Orthokeratology and adolescent myopia control*. CL Spectrum. 18(3): 40 – 42.
- Rengstorff RH (1965). *Corneal curvature and astigmatic changes subsequent to contact lens wear*. J Am Optom Assoc. 36: 996 – 1000.
- Sakamoto R, Sugimoto K (2004). *Will higher-Dk materials give better corneal refractive therapy results and fewer complications*. Eye & CL. 30(4): 252 – 253.
- Santodomingo-Rubida J, et al. (2005). *Refractive and biometric changes with silicone hydrogel contact lenses*. Optom Vis Sci. 82(6): 481 – 489.
- Saviola JF (2005). *The current FDA view on overnight orthokeratology*. Cornea. 24(7): 770 – 771.
- Saw SM, et al. (2002). *Myopia: attempts to arrest progression*. Br J Ophthalmol. 86: 1306 – 1311.
- Schein OD (2005). *Microbial keratitis associated with overnight orthokeratology. What we need to know*. Cornea. 24(7): 767 – 769.
- Shin YJ, et al. (2004). *Change of proliferation rate of corneal epithelium in the rabbit with orthokeratology lens*. Ophthalmol Res. 37: 94 – 103.
- Soni P, Horner D (1997). *Chapter 49: Orthokeratology*. In: Bennett ES, Weismann B (Eds.), *Clinical Contact Lens Practice*. Lippincott-Raven, Philadelphia. 4.
- Soni PS, et al. (2003). *Overnight orthokeratology: Visual and corneal changes*. Eye & CL. 29(3): 137 – 145.
- Soni PS, et al. (2004). *Overnight orthokeratology: Refractive and corneal recovery after discontinuation of reverse-geometry lenses*. Eye & CL. 30(4): 254 – 262.
- Sorbara L, et al. (2005). *Reduction of myopia from corneal refractive therapy*. Optom Vis Sci. 82 (6): 512 – 518.
- Sridharan R, Swarbrick HA (2003). *Corneal response to short-term orthokeratology*. Optom Vis Sci. 80: 791 – 799.
- Stone J (1976). *The possible influences of contact lenses on myopia*. Br J Physiol Opt. 31: 89 – 114.
- Swarbrick HA (2004). *Orthokeratology (Corneal Refractive Therapy) What is it and how does it work?* Eye & CL. 30(4): 181 – 185.
- Swarbrick HA, et al. (1998). *Corneal response to orthokeratology*. Optom Vis Sci. 75: 791 – 799.
- Swarbrick HA, et al. (2004). *Apical clearance rigid contact lenses induce corneal steepening*. Optom Vis Sci. 81: 427 – 435.
- Swarbrick HA, et al. (2005). *Mind your P's and Q's! (or describing corneal shape)*. Paper presented at the 2005 Global Orthokeratology Symposium, Chicago.
- Swarbrick HA, et al. (2005B). *MK in OK: An update*. Paper presented at the 2005 Global Orthokeratology Symposium, Chicago.
- Swarbrick HA, et al. (2005C). *Is Dk/t important? The influence of ON corneal edema on the short-term clinical response to OK lens wear*. Paper presented at the 2005 Global Orthokeratology Symposium, Chicago.
- Tahhan N, et al. (2003). *Comparison of reverse-geometry lens designs for overnight orthokeratology*. Optom Vis Sci. 80(12): 796 – 804.
- Tseng C-H, et al. (2005). *Overnight orthokeratology-associated microbial keratitis*. Cornea. 24(7): 778 – 782.
- Walline J (2004). *Study design issues in a corneal reshaping contact lens myopia progression study*. Eye & CL. 30(4): 227 – 229.
- Walline J (2004B). *A randomized trial of the effects of rigid contact lenses on myopia progression*. Arch Ophthalmol. 122(12): 1760 – 1766.

- Walline J (2005). *The CLAMP study Results. Finally*. Paper presented at the 2005 Global Orthokeratology Symposium, Chicago.
- Wang JC, Lim L (2003). *Unusual morphology in orthokeratology contact lens-related cornea ulcer*. Eye & CL. 29(3): 190 – 192.
- Watt K, Swarbrick HA (2005). *Corneal infections in OK – a survey*. Lecture to the 2005 Global Orthokeratology Symposium, Chicago.
- Watt K, Swarbrick HA (2005B). *Microbial keratitis in overnight orthokeratology: Review of the first 50 days*. Eye & CL. 31(5): 201 – 208.
- Wilhelmus KR (2005). *Acanthamoeba keratitis during orthokeratology*. Cornea. 24(7): 864 – 866.
- Wilson SC, et al. (1992). *Accuracy and precision of the Corneal Analysis System and the Topographical Modeling System*. Cornea. 11: 28 – 35.
- Wlodyga RJ (1992). *Orthokeratology: A case in point*. CL Spectrum. 7: 28 – 30.
- Wlodyga RJ, Bryla C (1989). *Corneal molding: The easy way*. CL Spectrum. 4: 14 – 16.
- Wlodyga RJ, Harris D (1993). *Accelerated Orthokeratology. Techniques and Procedures Manual, Part 1*. National Eye Research Foundation, Chicago. Cited in: Dave and Ruston, 1998B.
- Xuguang S, et al. (2003). *Acanthamoeba keratitis as a complication of orthokeratology*. Am J Ophthalmol. 136(6): 1159 – 1161.
- Yanai R, et al. (2005). *Negative influence of orthokeratology with reverse-geometry contact lens on contrast sensitivity*. Paper presented at the 2005 Global Orthokeratology Symposium, Chicago.
- Yang X, et al. (2003). *Topographical evaluation on decentration of orthokeratology lenses*. Zhonghua Yan Ke Za Zhi. 39(6): 335 – 338.
- Yee T (2000). *Myopia control study. Myopia control study by using orthokeratology (reverse geometry) lenses*. Visit: [www.ortho-k.org.hk/member/myopia-report1.html](http://www.ortho-k.org.hk/member/myopia-report1.html).
- Yepes N, et al. (2005). *Infectious keratitis after overnight orthokeratology in Canada*. Cornea. 24(7): 857 – 860.
- Young AL, et al. (2003). *Orthokeratology lens-related Pseudomonas aeruginosa infectious keratitis*. Cornea. 22(3): 265 – 266.
- Young AL, et al. (2004). *Orthokeratology lens-related corneal ulcers in children: A case series*. Ophthalmology. 111: 590 – 595.
- Young AL, et al. (2005). *Orthokeratology lens-related corneal ulcers in children: Author reply*. Ophthalmology. 112(1): 168 – 169.
- Zhu S-Q (2005). *The regression of corneal curvature after orthokeratology*. Chinese J Optom Ophthalmol. 7(2): 107 – 109.