

# Anatomy of Conjunctiva

Sourav

HOD

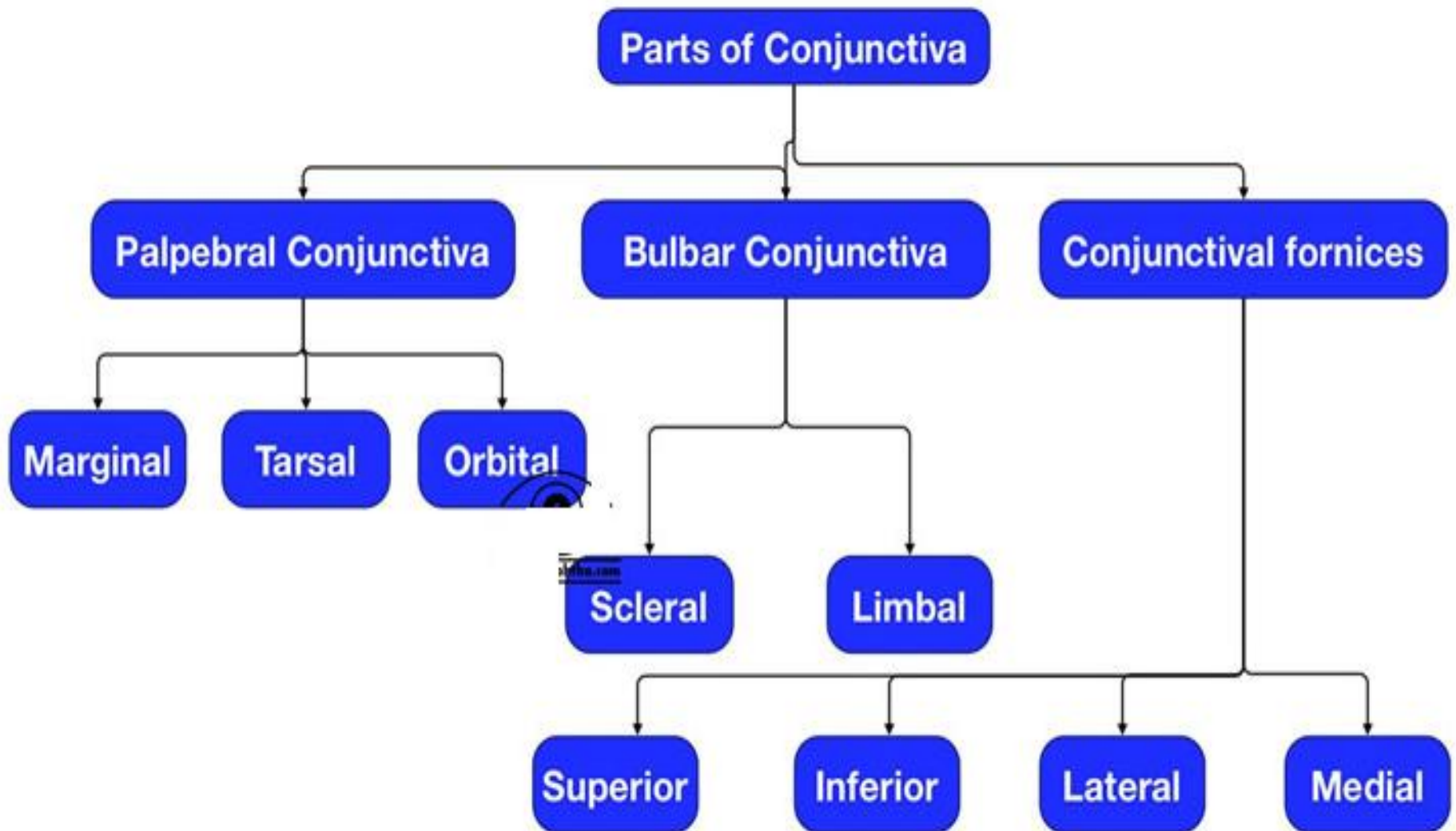
- The name “conjunctiva” has originated from the term “conjoin” which means “to join”



# Introduction

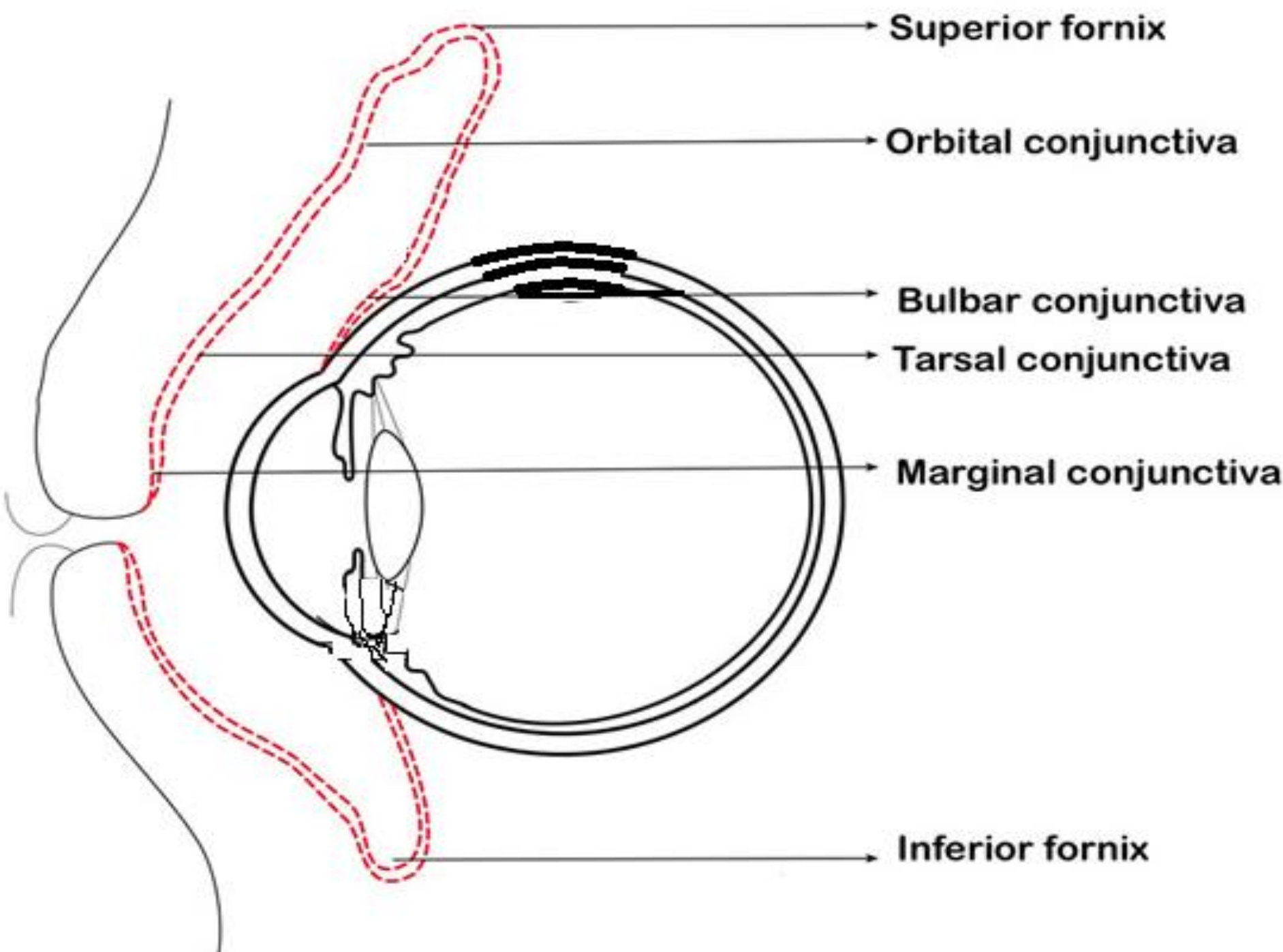
- Conjunctiva is a fine, translucent mucous membrane which joins and covers the anterior surface of eyeball and posterior side of the eyelids. It covers the posterior surface of the lids and reflects to cover the anterior part of the sclera, then becomes continuous with the corneal epithelium.
- At the lid margin conjunctiva is continuous with the skin.

# Parts of conjunctiva



# A. Palpebral conjunctiva

- It is the part of the conjunctiva which lines the undersurface or posterior surface of the eyelid.
- **Marginal conjunctiva** is a transitional zone between the skin of the eyelid and conjunctiva proper.
- It starts from the intermarginal strips of the eyelid as a continuation of the skin.



# Marginal conjunctiva

- It is made up of stratified epithelium. Marginal conjunctiva continues in to the back or posterior surface of the lid for a short distance of 2 mm, up to a shallow groove or fold, where it merges with the conjunctiva proper.
- This groove is called sub tarsal sulcus or sulcus subtarsalis.

# Tarsal conjunctiva

- is a very vascular and adherent to the tarsal plates.
- Adherence is less marked in lower than the upper eye lid where it is fully adherent to the whole tarsal plate.
- Tarsal glands are visible through the transparent tarsal conjunctiva as yellow line running parallel to each other in a vertical direction.



# Orbital conjunctiva

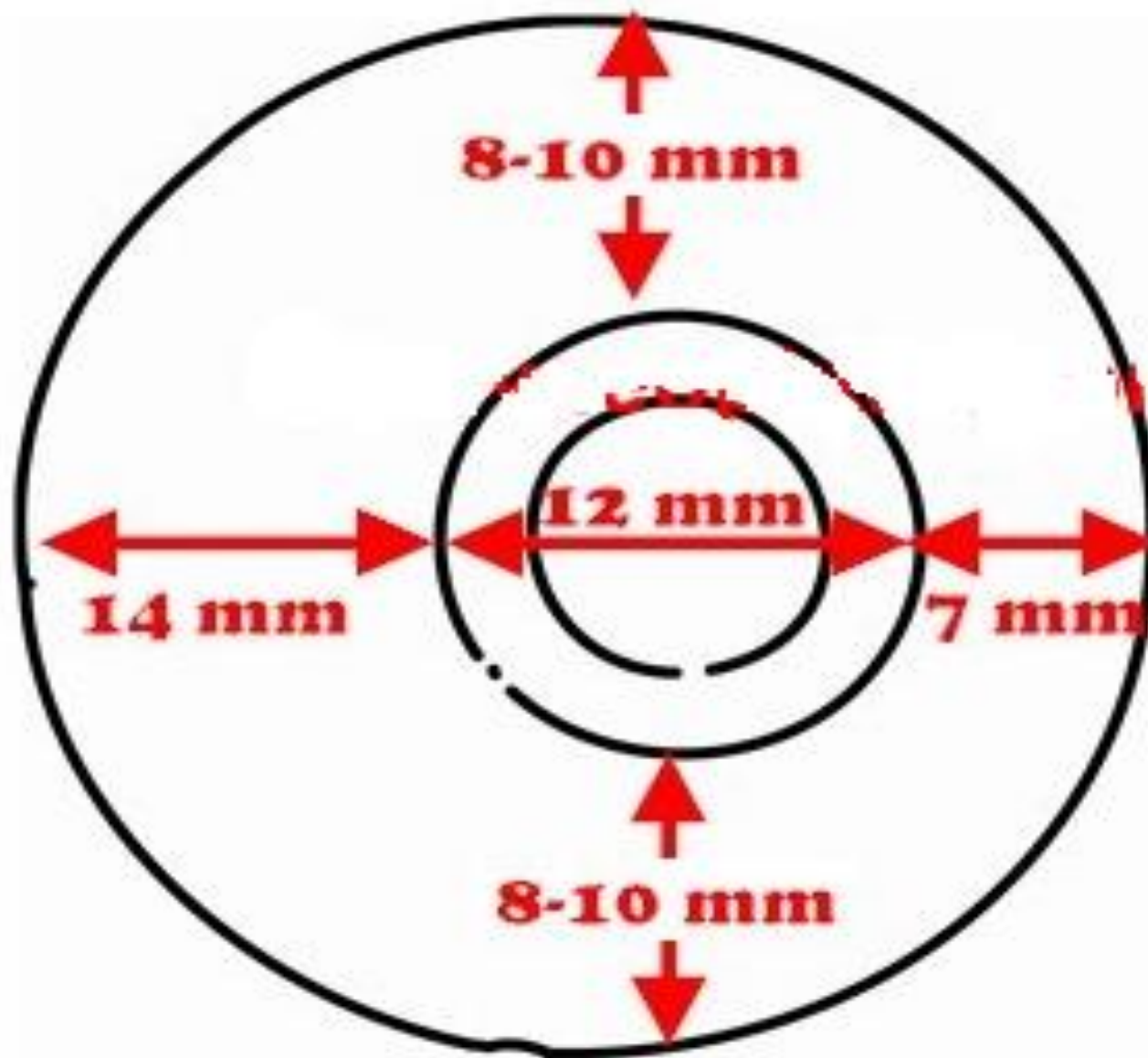
- is loosely covering between the tarsal plate and fornix. It is thrown in to horizontal folds during eye movements. In upper eyelid it lies over the Muller's muscle.

## B. Conjunctiva of the Fornix

- It is fold lining the cul-de-sac formed by conjunctiva covering the posterior surface of the lids to the conjunctiva covering the anterior surface of the globe.
- The conjunctiva here is comparatively thicker and loosely attached in order to allow free movement of the globe.
- It is divided into 4 regions

# Continue...

- Superior fornix lies between upper lid and the globe. It extends 8 to 10 mm from the upper border of the limbus.
- Inferior fornix lies between lower lid and the globe .It extends up to a distance of 8 mm below the lower part of limbus.



**Dimension of conjunctival sac from limbus**

# Continue...

- Lateral fornix lies between the lateral canthus and the globe. It extends for a distance of 15 mm from the lateral part of the limbus.
- Medial fornix is the shallowest and contains caruncle and the plica semilunaris.

# Conjunctival sac

- The conjunctiva while lining the structures like posterior part of the lids and anterior part of the globe forms a sac which opens at the palpebral fissure.
- Conjunctival sac contains about  $7\mu\text{l}$  of tear fluid, but has the capacity to accommodate fluid up to  $30\mu\text{l}$ .

# Bulbar conjunctiva

- It is the thinnest of all the parts of conjunctiva and so transparent that underlying white sclera and vessels are seen clearly.
- It is loosely attached except for a zone of 3mm near the limbus and near insertions of the recti

# Continue...

- muscles. Limbal conjunctiva is the part of the bulbar conjunctiva which covers the limbal region and fuses with the corneal epithelium.



# Microscopic structure of conjunctiva

- Microscopically conjunctiva consists of three layers-
  1. epithelium,
  2. adenoid layer and
  3. fibrous layer.

# A. Conjunctival Epithelium

- At the junctions of skin of the lids and marginal conjunctiva (mucocutaneous junction), keratinised squamous epithelium of the epidermis transforms into nonkeratinised squamous epithelium of conjunctiva.
- Morphology of conjunctival epithelium varies from region to region

The different regions of conjunctiva and their epitheliums are described below.

Conjunctiva	Number of layers	Cells in the layers
<b>Marginal</b>	5 layers of 5 layered non-keratinised stratified squamous epithelium	Superficial layer: Squamous cells
		Middle three layers: Polyhedral cells
		Deepest layer: Cylindrical cells
<b>Tarsal</b>	2 layers of Stratified cuboidal epithelium	Superficial layer: Cylindrical cells
		Deepest layer: cubiodal cells
<b>Fornix and bulbar</b>	3 layers of Stratified, squamous epithelium	Superficial layer: Cylindrical cells
		Middle layer: polyhedral cells
		Deepest layer: Cuboidal cells
<b>Limbal</b>	10 layers of stratified squamous epithelium	Superficial layer: squamous cells
		Middle layer: polygonal cells
		Basal- cubical

# 1. Goblet cells

- Goblet cells are seen throughout the conjunctiva lying in between the cells of conjunctival epithelium.
- These cells are actually unicellular glands which secret mucin.

# Continue...

- They gradually enlarge, become larger as they reach the surface of the conjunctiva.
- On reaching the surface they discharge their mucin content and finally shed away.
- These cells are round and oval in shape and 10-20  $\mu\text{m}$  in size.

# Continue...

- Goblet cells may produce up to 2.2 mL of mucus daily.
- Mucus is essential for ocular surface integrity as it lubricates and protects the epithelial cells.
- Mucin reduces the surface tension of the tear film to ensure its stability.

## 2. Melanocytes

- Melanocytes are primarily seen in limbus, fornix, plica semilunaris, caruncle and at the sites of perforation of the anterior ciliary vessels.
- Sometimes they give the conjunctiva a brownish tinge.

# 3.Langerhans cells

- Langerhans cells are actually dendritic cells, immune cells that form part of the immune system. Their main function is to process antigen material and present it on the surface to other cells of the immune system. Thus they function as antigen-presenting cells.



# Continue...

- The highest density of Langerhans cells has been found in tarsal conjunctiva followed by fornix and bulbar conjunctiva.
- The number of the cells decreases with age. These cells contain rod shaped or "tennis-racket" shaped cytoplasmic organelles known as Birbeck granule, which stains positively for ATPase.

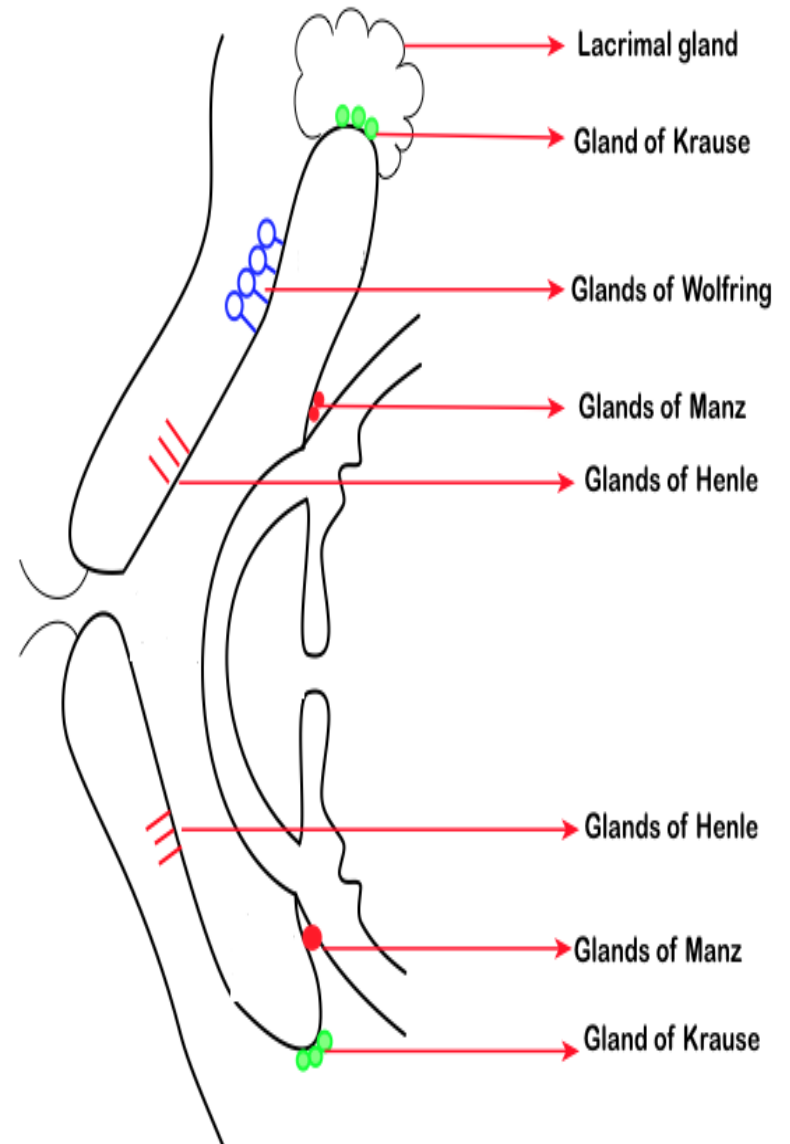
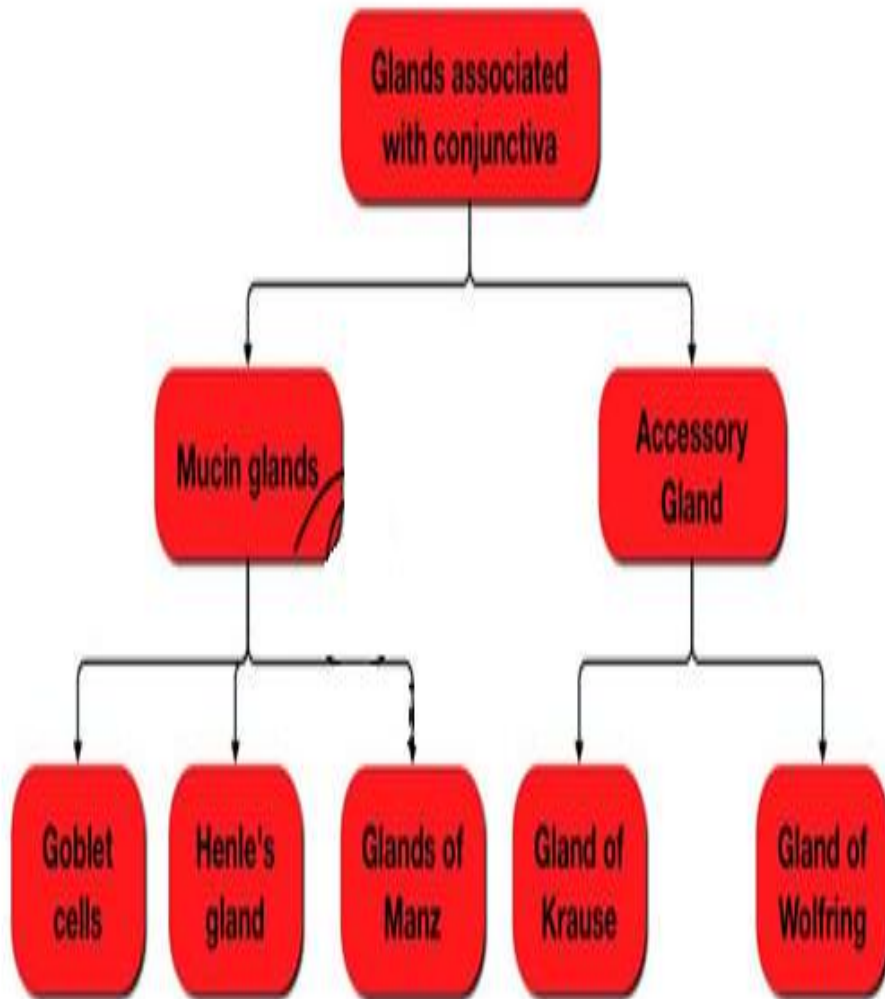
## B. Adenoid layer

- It is also called lymphoid layer
- Consist of fine connective tissue recticulum in the meshes of which lie lymphocytes
- This layer develops in the fornices and end at the subtarsal folds
- It is not present at birth but develops after 3-4 months of life.

## C. Fibrous layer

- This layer contains the vessels and nerves of conjunctiva and glands of Krause.
- Except for the tarsal part of conjunctiva, where it is very thin and blends with the tarsal plates, the fibrous layer is thicker than the lymphoid layer.

# Accessory lacrimal glands

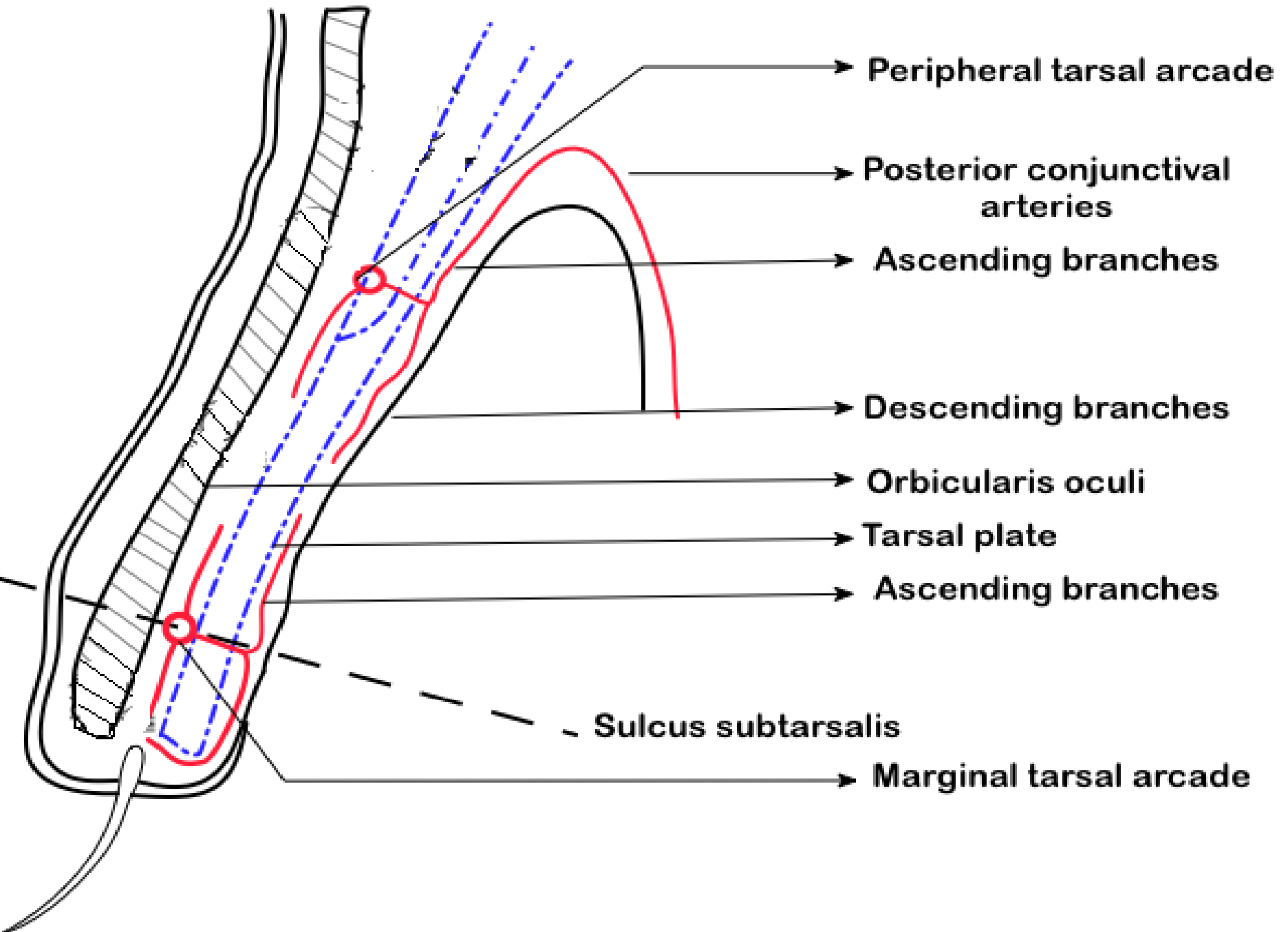


# Blood supply of Conjunctiva

- Arterial supply of conjunctiva derives from
  1. peripheral Tarsal arcades,
  2. marginal Tarsal arcades
  3. The anterior ciliary arteries

# 1. Palpebral arcades

- There are two palpebral arcades which are the major source of the blood supply of conjunctiva.
- These are marginal tarsal arcade & peripheral tarsal arcade. Marginal tarsal arcades are larger than peripheral tarsal arcade.



Peripheral tarsal arcade

Posterior conjunctival arteries

Ascending branches

Descending branches

Orbicularis oculi

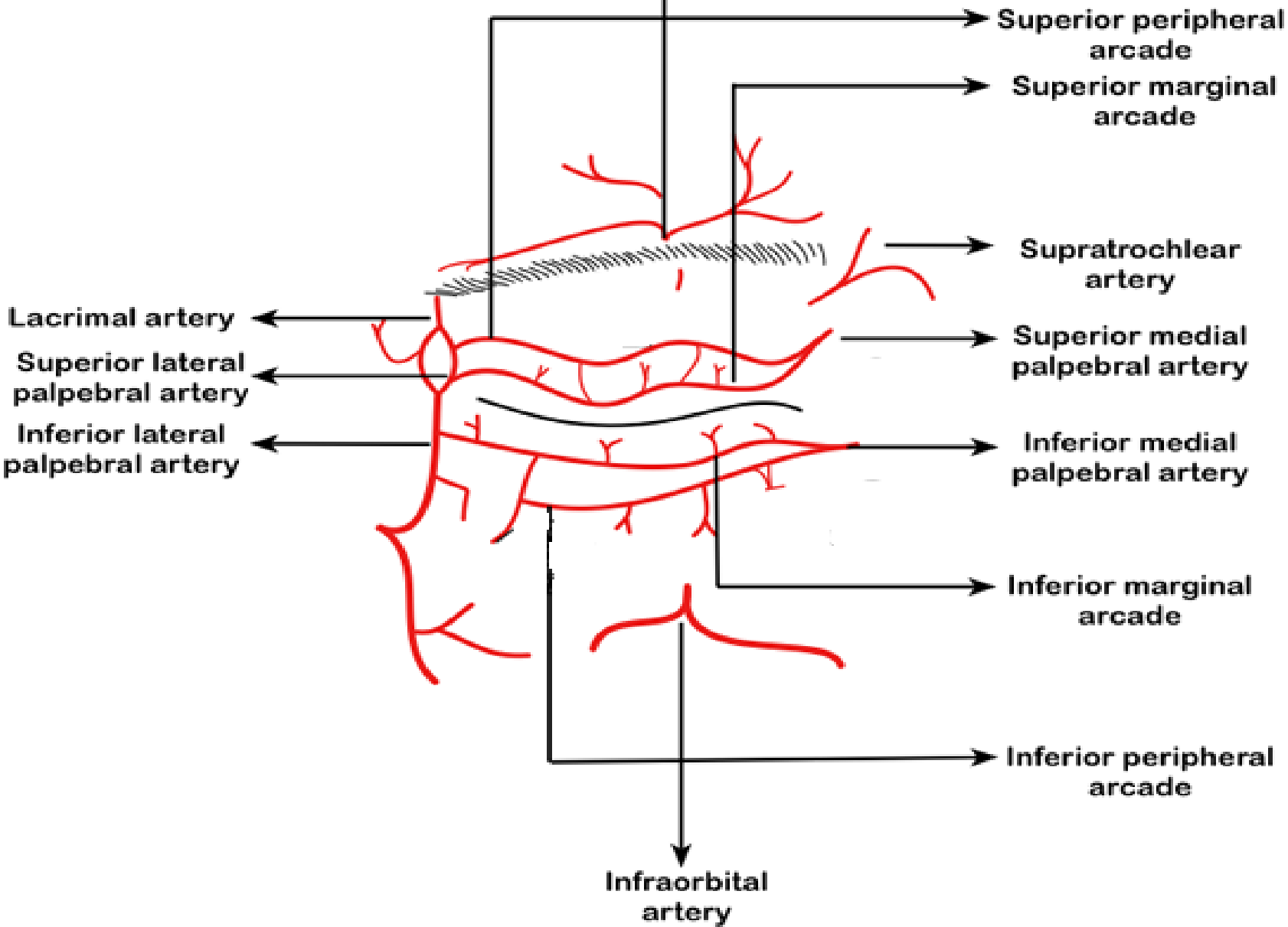
Tarsal plate

Ascending branches

Sulcus subtarsalis

Marginal tarsal arcade

Supraorbital artery





# Continue...

- The medial and lateral palpebral branches of the nasal and lacrimal arteries of the lid supply the eyelid.
- The superior and inferior branches from these arteries enter the eyelid by piercing orbital septum.
- Each branch of medial palpebral artery then anastomoses with corresponding lateral palpebral artery and this is how they form the marginal arcade.

## 2. Marginal Arcade

- Marginal tarsal arcade lies in the sub muscular plane in front of the tarsal plate, 2mm away from the margin of the eyelids.
- Perforating branches of the marginal tarsal arcade pierce the tarsal plate at the region of sulcus subtarsalis and enter the conjunctiva to supply the palpebral part of the conjunctiva.

# Continue...

- Peripheral marginal arcade lies near the peripheral border of the tarsal plate.
- Peripheral tarsal arcade is formed by the superior branch of the medial palpebral artery, in front of the upper margin of the tarsal plate.
- Perforating branches of the peripheral tarsal arcade pierce the Mullers muscle, reach the conjunctiva and give off two branches –ascending and descending.

# Continue...

- Descending branches supply the tarsal conjunctiva and also anastomoses with vessels from the marginal arcade
- ascending branches pass into the superior fornix to continue around the fornices to the bulbar conjunctiva as the posterior conjunctival arteries.

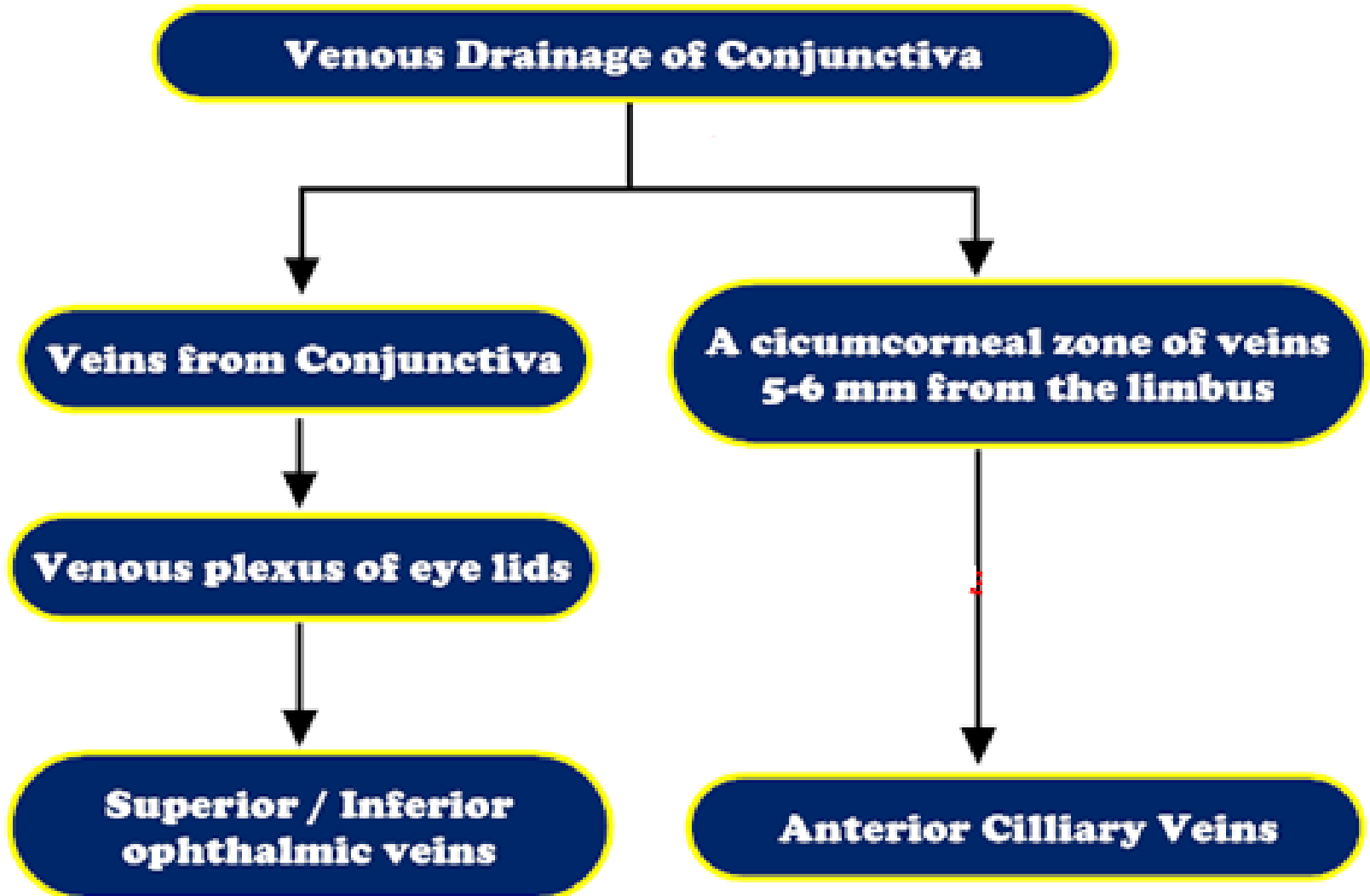
# Anterior ciliary arteries

- The anterior ciliary arteries travel along the tendon of the rectus muscles and give off anterior conjunctival arteries just before piercing the eyeball.
- The anterior ciliary arteries send branches to the pericorneal plexus and to the surrounding regions of the bulbar conjunctiva in the limbal area.

# Continue...

- Free anastomosis occurs in this area between the anterior conjunctival vessels and the terminal branches of the posterior conjunctival vessels.
- Thus, the superficial and deep systems of vessels are closely connected in the limbal area. Clinically, this is an area of diagnostic importance.

# The venous supply of conjunctiva



# The nerve supply to the conjunctiva

- Derived from the first division of the trigeminal nerve.
- The nerves to the lid supply most of the conjunctiva.



# Continue...

- These nerves comprise **the infratrochlear branch of the nasociliary nerve, the lacrimal nerve,** the supratrochlear and **supraorbital** branches of the frontal nerve, and the **infraorbital** nerve from the maxillary division of the trigeminal nerve.
- The limbal area is supplied by branches from the ciliary nerves.

# Continue...

- The majority of nerve endings in the conjunctiva are free, unmyelinated nerve endings. They form a sub-epithelial plexus in the superficial part of the substantia propria.
- Many of these fibers end on blood vessels, and others form an intraepithelial plexus around the base of epithelial cells and send free nerve endings between cells.

Part of conjunctiva	Blood supply	Nerve supply
<b>Palpebral Conjunctiva, Tarsal Conjunctiva</b>	Marginal tarsal arcade and descending branches of the peripheral tarsal arcade	<p>Superior: Supraorbital, supratrochlear, infratrochlear, and lacrimal nerves</p> <p>Inferior: Lacrimal and infraorbital nerves</p>
<b>Fornices</b>	Peripheral tarsal arcade	<p>Superior: Supraorbital, supratrochlear, infratrochlear, and lacrimal nerves</p> <p>Inferior: Lacrimal and infraorbital nerves</p>
<b>Bulbar</b>	Anterior conjunctival and posterior conjunctival arteries	Ciliary nerves

- Thank you