



Centurion
UNIVERSITY
Shaping Lives...
Empowering Communities...

OCULAR DISEASE

CORNEAL DEGENERATIONS



Centurion
UNIVERSITY

Shaping Lives...
Empowering Communities...

CLASSIFICATION

[A] *Depending upon location*

1. Axial corneal degenerations

1. Fatty degeneration
2. Hyaline degeneration
3. Amyloidosis
4. Calcific degeneration (Band keratopathy)
5. Salzmann's nodular degeneration.



Centurion
UNIVERSITY

*Shaping Lives...
Empowering Communities...*

Continue...

II. *Peripheral degenerations*

1. Arcus senilis
2. Vogt's white limbal girdle
3. Hassal-Henle bodies
4. Terrien's marginal degeneration
5. Mooren's ulcer
6. Pellucid marginal degeneration
7. Furrow degeneration (senile marginal degeneration).



Centurion
UNIVERSITY

Shaping Lives...
Empowering Communities...

Continue...

[B] Depending upon etiology

- I. *Age related degenerations. Arcus senilis, Vogt's white limbal girdle, Hassal-Henle bodies, Mosaic degeneration.*
- II. *Pathological degenerations: Fatty degeneration, amyloidosis, calcific degeneration, Salzmann's nodular degeneration, Furrow degeneration, spheroidal degeneration, Pellucid marginal degeneration, Terrien's marginal degeneration, Mooren's ulcer.*



Centurion
UNIVERSITY

Shaping Lives...
Empowering Communities...

Arcus senilis

- Arcus senilis refers to an annular lipid infiltration of corneal periphery.
- This is an age-related change occurring bilaterally in 60 percent of patients between 40 and 60 years of age and in nearly all patients over the age of 80.
- Sometimes, similar changes occur in young persons (*arcus juvenilis*) which may or may not be associated with hyperlipidemia.



Centurion
UNIVERSITY

*Shaping Lives...
Empowering Communities...*

Continue...

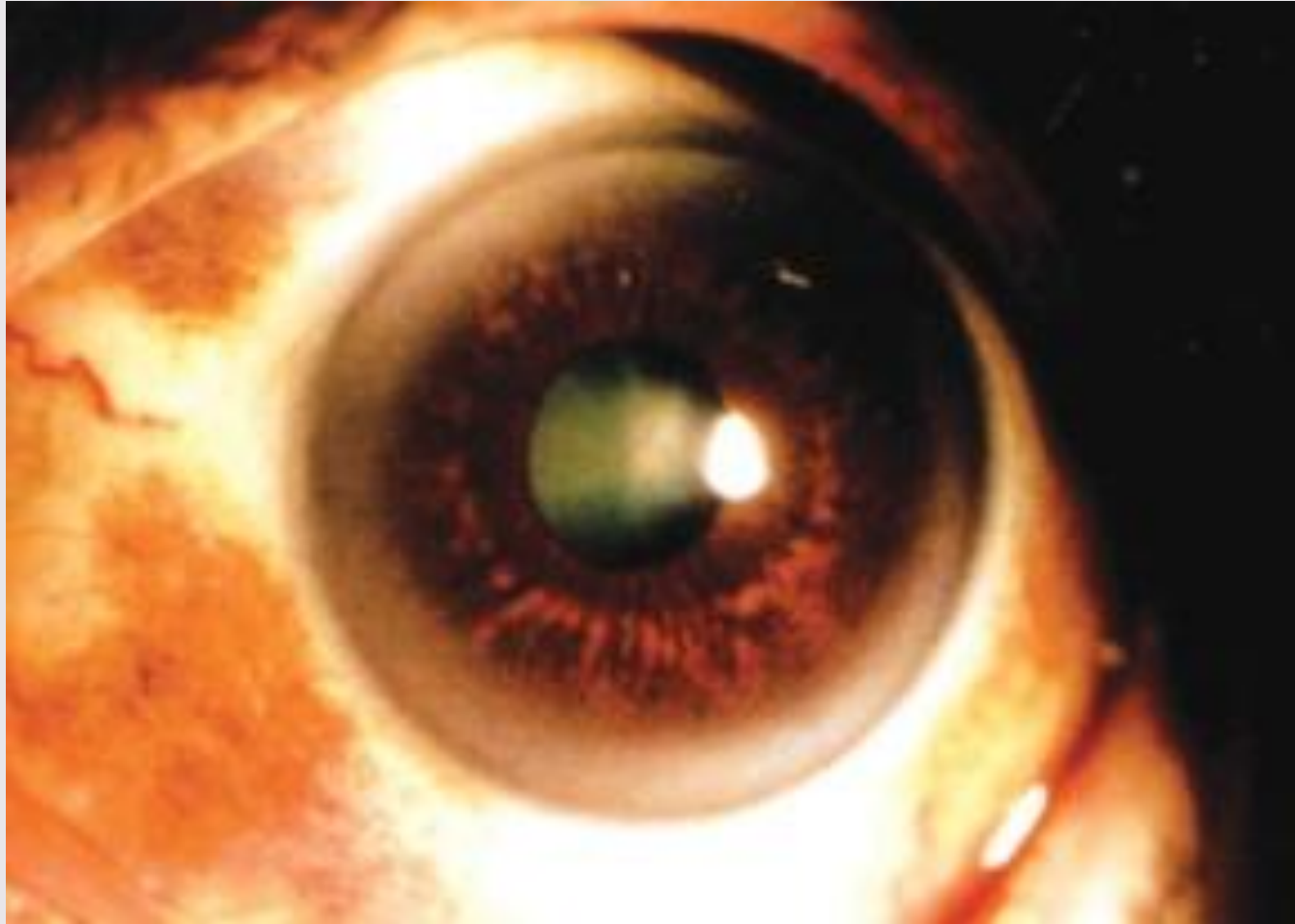
- The arcus starts in the superior and inferior quadrants and then progresses circumferentially to form a ring which is about 1 mm wide.
- This ring of opacity is separated from the limbus by a clear zone



Centurion
UNIVERSITY

*Shaping Lives...
Empowering Communities...*

Arcus senilis





Centurion
UNIVERSITY

*Shaping Lives...
Empowering Communities...*

Vogt's white limbal girdle

- It is also an age-related change seen frequently in elderly people. It appears as bilateral chalky white opacities in the interpalpebral area both nasally and temporally.
- There may or may not be a clear area between opacity and the limbus. The opacity is at the level of Bowman's membrane.



Centurion
UNIVERSITY

Shaping Lives...
Empowering Communities...

Hassal-Henle bodies

- Hassal-Henle bodies are drop-like excrescences of hyaline material projecting into the anterior chamber around the corneal periphery.
- These arise from Descemet's membrane. These form the commonest senile change seen in the cornea.
- In pathological conditions they become larger and invade the central area and the condition is called ***cornea guttata***.



Centurion
UNIVERSITY

Shaping Lives...
Empowering Communities...

Lipoid keratopathy

- Fatty degeneration of cornea is characterised by whitish or yellowish deposits.
- The fat deposits mostly consist of cholesterol and fatty acids.
- Initially fat deposits are intracellular but some become extracellular with necrosis of stromal cells.
- Lipidkeratopathy can be primary or secondary.



Centurion
UNIVERSITY

Shaping Lives...
Empowering Communities...

Continue...

1. *Primary lipid keratopathy is a rare condition* which occurs in a cornea free of vascularization. Serum lipid levels are normal in such patients.
2. *Secondary lipid keratopathy occurs in vascularised corneas secondary to diseases such as corneal infections, interstitial keratitis, ocular trauma, glaucoma, and chronic iridocyclitis.*



Centurion
UNIVERSITY

*Shaping Lives...
Empowering Communities...*

Treatment

- The condition when it causes visual disturbance is keratoplasty.



Centurion
UNIVERSITY

*Shaping Lives...
Empowering Communities...*

Band Shape keratopathy

- Band shape keratopathy (BSK) is essentially a degenerative change associated with deposition of calcium salts in Bowman's membrane, most superficial part of stroma and in deeper layers of epithelium.



Centurion
UNIVERSITY

Shaping Lives...
Empowering Communities...

Etiology

- *Ocular diseases. Band keratopathy is seen in association with: chronic uveitis in adults, children with Still's disease, phthisis bulbi, chronic glaucoma, chronic keratitis and ocular trauma.*
- *Age related BSK is common and affects otherwise healthy cornea.*
- *Metabolic conditions rarely associated with BSK include hypercalcaemia and chronic renal failure.*



Centurion
UNIVERSITY
*Shaping Lives...
Empowering Communities...*

Clinical features

- It typically presents as a bandshaped opacity in the interpalpebral zone with a clear interval between the ends of the band and the limbus
- The condition begins at the periphery and gradually progresses towards the centre.
- The opacity is beneath the epithelium which usually remains intact. Surface of this opaque band is stippled due to holes in the calcium plaques in the area of nerve canals of Bowman's membrane.



Centurion
UNIVERSITY
Shaping Lives...
Empowering Communities...

Treatment

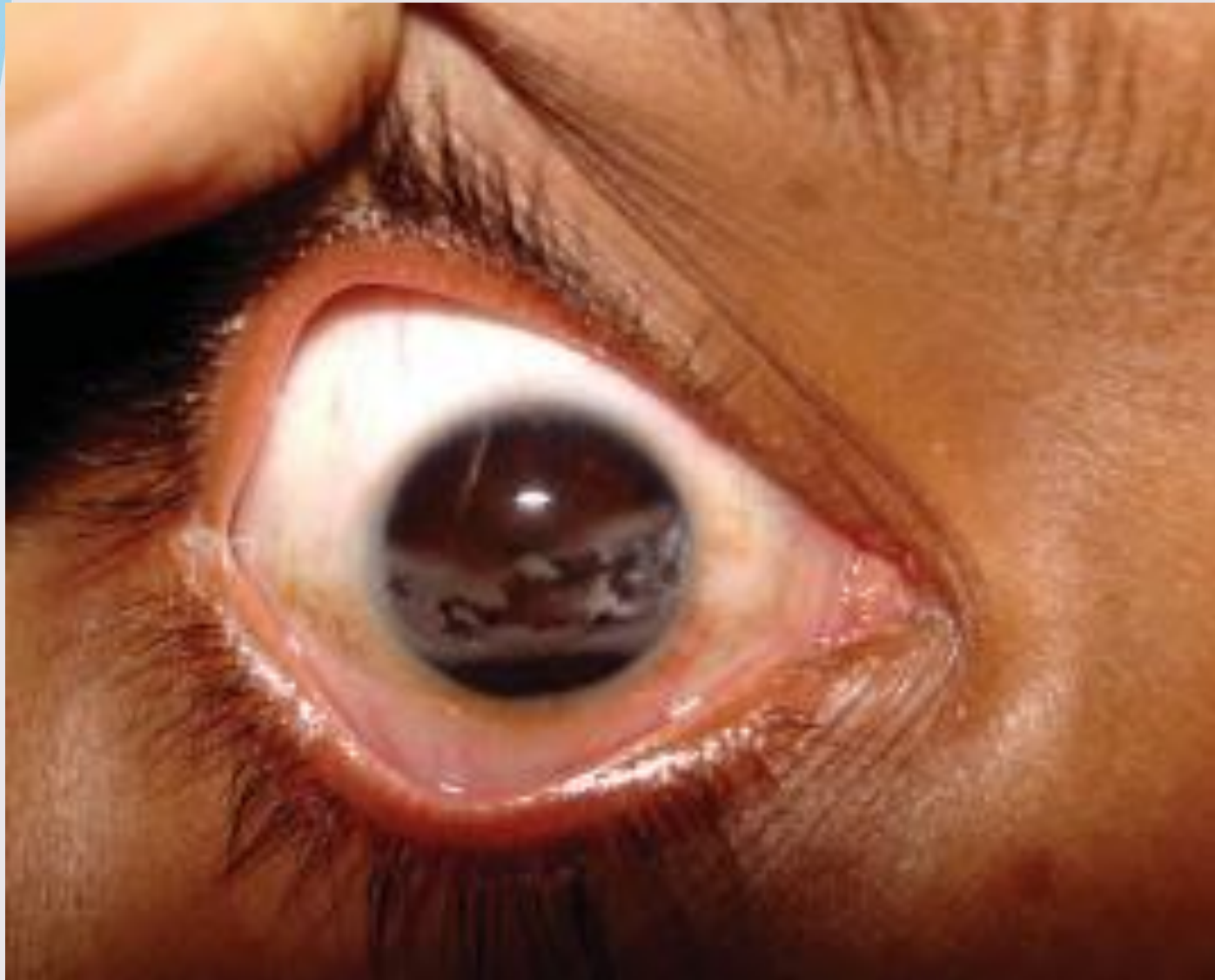- **Chelation**: *chemical removal of deposited* calcium salts is an effective treatment.
- *First of all* corneal epithelium is scraped under local anaesthesia. Then 0.01 molar solution of EDTA is applied to the denuded cornea with the help of a cotton swab for about 10 minutes.
- This removes most of the deposited calcium.
- Pad and bandage is then applied for 2-3 days to allow the epithelium to regenerate.



Centurion
UNIVERSITY

*Shaping Lives...
Empowering Communities...*

Band-shaped keratopathy in a patient with chronic uveitis.





Centurion
UNIVERSITY

Shaping Lives...
Empowering Communities...

Continue...

2. *Phototherapeutic keratectomy (PTK) with excimer laser* is very effective in clearing the cornea.
3. *Keratoplasty may be performed when the band keratopathy* is obscuring useful vision.



Centurion
UNIVERSITY

Shaping Lives...
Empowering Communities...

Salzmann's nodular degeneration

- ***Etiology:*** This condition occurs in eyes with recurrent attacks of phlyctenular keratitis, rosacea keratitis and trachoma. The condition occurs more commonly in women and is usually unilateral.



Centurion
UNIVERSITY

*Shaping Lives...
Empowering Communities...*

Pathogenesis

- In Salzmann's nodular degeneration, raised hyaline plaques are deposited between epithelium and Bowman's membrane.
- There is associated destruction of Bowman's membrane and the adjacent stroma.



Centurion
UNIVERSITY
*Shaping Lives...
Empowering Communities...*

Clinical features

- Clinically, one to ten bluish white elevations (nodules), arranged in a circular fashion, are seen within the cornea.
- Patient may experience discomfort due to loss of epithelium from the surface of nodules.
- Visual loss occurs when nodules impinge on the central zone.



Centurion
UNIVERSITY
*Shaping Lives...
Empowering Communities...*

Treatment

- Essentially by keratoplasty.



Centurion
UNIVERSITY

Shaping Lives...
Empowering Communities...

Droplet keratopathy

Etiology.

- It typically occurs in men who work outdoors, especially in hostile climates. Its occurrence has been related to exposure to ultraviolet rays and/ or ageing and /or corneal disease.



Centurion
UNIVERSITY

*Shaping Lives...
Empowering Communities...*

Clinical features

- In this condition amber-coloured spheroidal granules (small droplets) accumulate at the level of Bowman's membrane and anterior stroma in the interpalpebral zone.
- In marked degeneration, the vision is affected.



Centurion
UNIVERSITY

*Shaping Lives...
Empowering Communities...*

Treatment

- ***Treatment in advanced cases is by corneal transplantation.***



Centurion
UNIVERSITY

*Shaping Lives...
Empowering Communities...*

Pellucid marginal degeneration

- Pellucid marginal degeneration is a rare progressive peripheral corneal thinning disorder, typically involving the inferior cornea in both eyes.
- Presentation is usually in adulthood.



Centurion
UNIVERSITY
*Shaping Lives...
Empowering Communities...*

Symptoms and sign

- Slowly progressive blurring due to astigmatism.

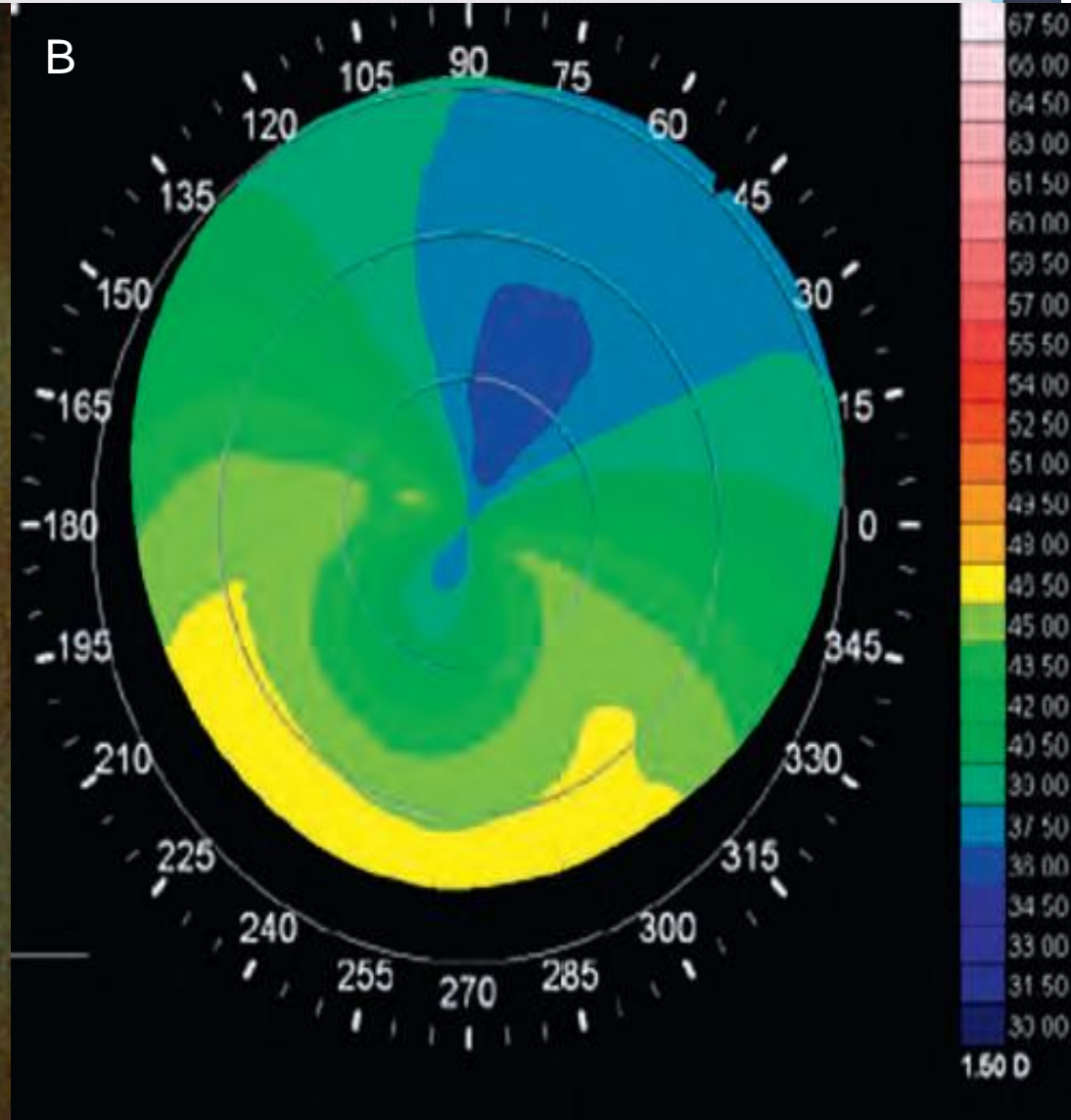
Signs:

- Bilateral, slowly progressive, crescentic 1–2 mm band of inferior corneal thinning extending from 4 to 8 o'clock, 1 mm from the limbus



Centurion

(A) Pellucid marginal degeneration;
(B) topography shows severe astigmatism and diffuse steepening of the inferior cornea





Centurion
UNIVERSITY

Shaping Lives...
Empowering Communities...

Continue...

- The epithelium is intact, and the cornea above the thinned area is ectatic and flattened.
- In contrast to keratoconus, Fleischer rings and Vogt striae do not occur and acute hydrops is rare.
- **Corneal topography** shows a 'butterfly' pattern, with severe astigmatism and diffuse steepening of the inferior cornea



Centurion
UNIVERSITY
*Shaping Lives...
Empowering Communities...*

Treatment

- Early cases are managed with spectacles and contact lenses.
- Surgical options, none of which is ideal, in patients intolerant to contact lenses include large eccentric penetrating keratoplasty, thermocauterization, crescentic lamellar keratoplasty, wedge resection of diseased tissue, epikeratoplasty and intracorneal ring segment implantation.
- Results of collagen cross-linking are encouraging.