



**Centurion**  
**UNIVERSITY**  
*Shaping Lives...*  
*Empowering Communities...*

# OCULAR DISEASE

## Eye Lid



**Centurion**  
**UNIVERSITY**  
*Shaping Lives...*  
*Empowering Communities...*

# Squamous cell carcinoma



Centurion  
UNIVERSITY

Shaping Lives...  
Empowering Communities...

# Introduction

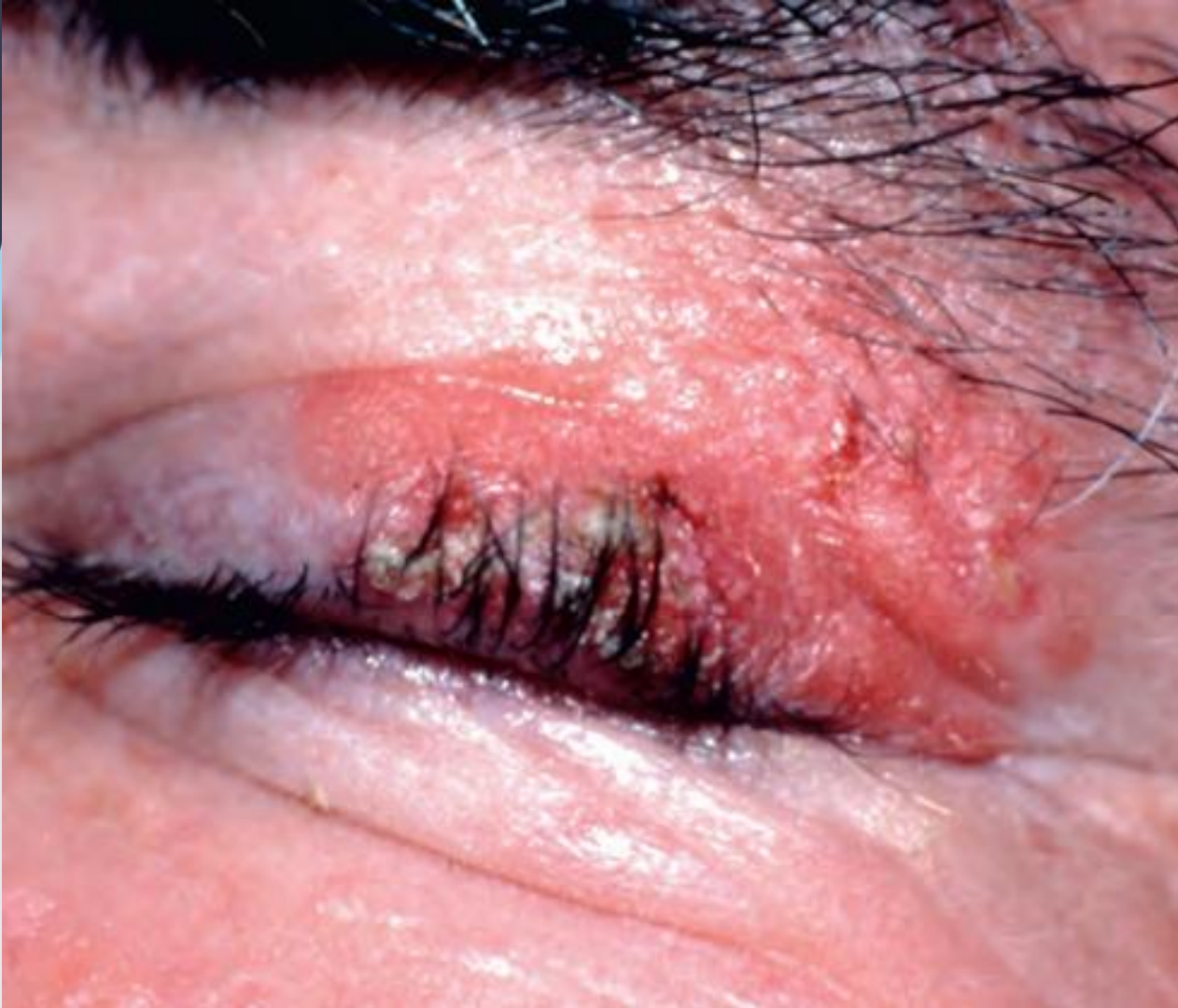- SCC is a much less common, but typically more aggressive tumour than BCC with metastasis to regional lymph nodes in about 20% of cases.
- SCC accounts for 5–10% of eyelid malignancies and may arise *from* Bowen disease.



Centurion  
UNIVERSITY

Shaping Lives...  
Empowering Communities...

# *Carcinoma in situ*





**Centurion**  
**UNIVERSITY**

*Shaping Lives...  
Empowering Communities...*

# Continue...

- Immuno compromised patients, such as those with acquired immunodeficiency syndrome (AIDS) or following renal transplantation are at increased risk, as are those with a predisposing syndrome such as xeroderma pigmentosum.
- It occurs most commonly in older individuals with a fair complexion and a history of chronic sun exposure.



**Centurion**  
**UNIVERSITY**

*Shaping Lives...  
Empowering Communities...*

# *Histopathology*

- The tumour arises from the squamous cell layer of the epidermis.
- It is composed of variably sized groups of atypical epithelial cells with prominent nuclei and abundant eosinophilic cytoplasm within the dermis

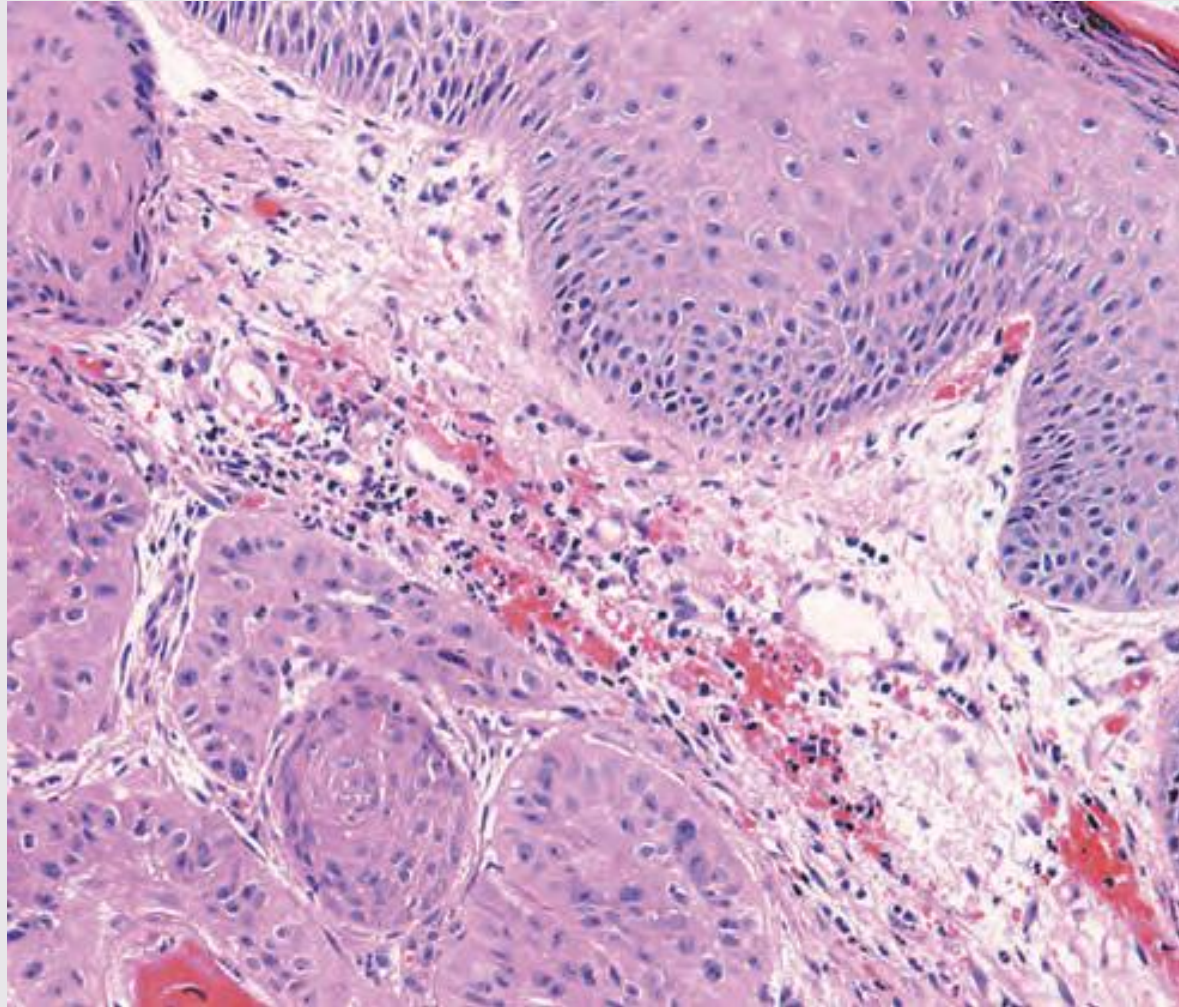




**Centurion**  
**UNIVERSITY**

*Shaping Lives...  
Empowering Communities...*

*Histopathology shows acanthotic squamous epithelium and eosinophilic (pink) islands of dysplastic squamous epithelium within the dermis*





**Centurion**  
**UNIVERSITY**

*Shaping Lives...  
Empowering Communities...*

# Continue...

- Well-differentiated tumours may show characteristic keratin 'pearls' and intercellular bridges





**Centurion**  
**UNIVERSITY**  
*Shaping Lives...  
Empowering Communities...*

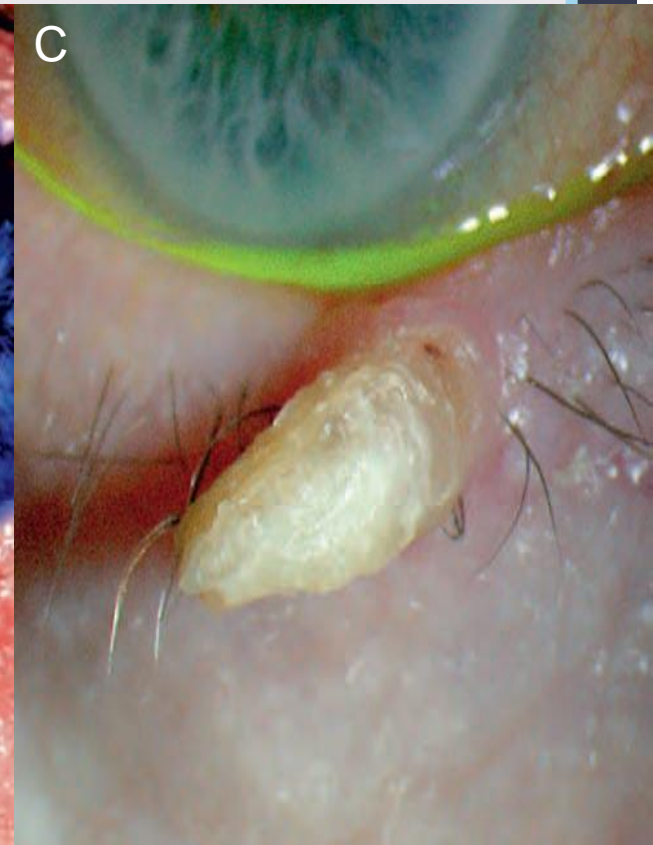
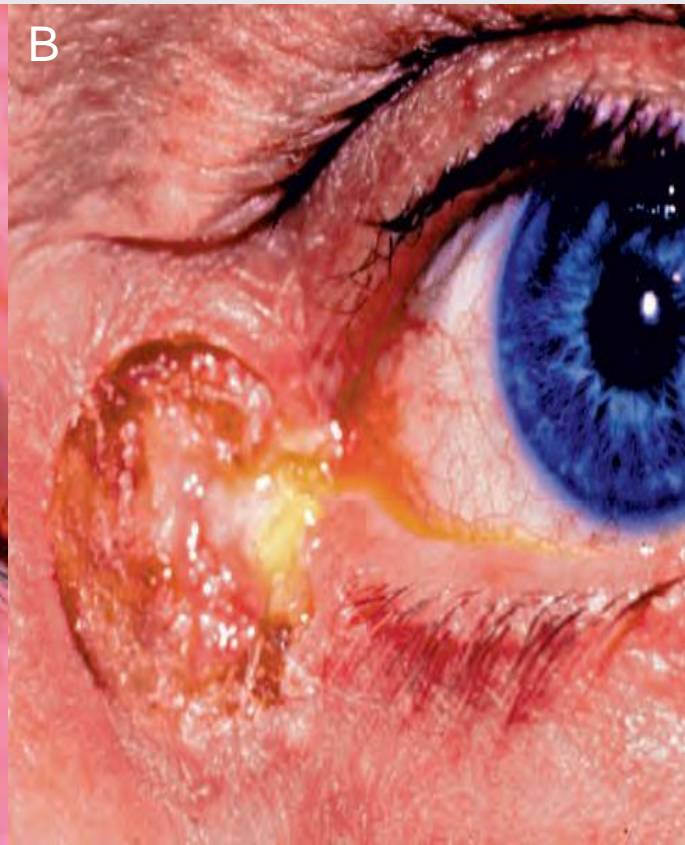
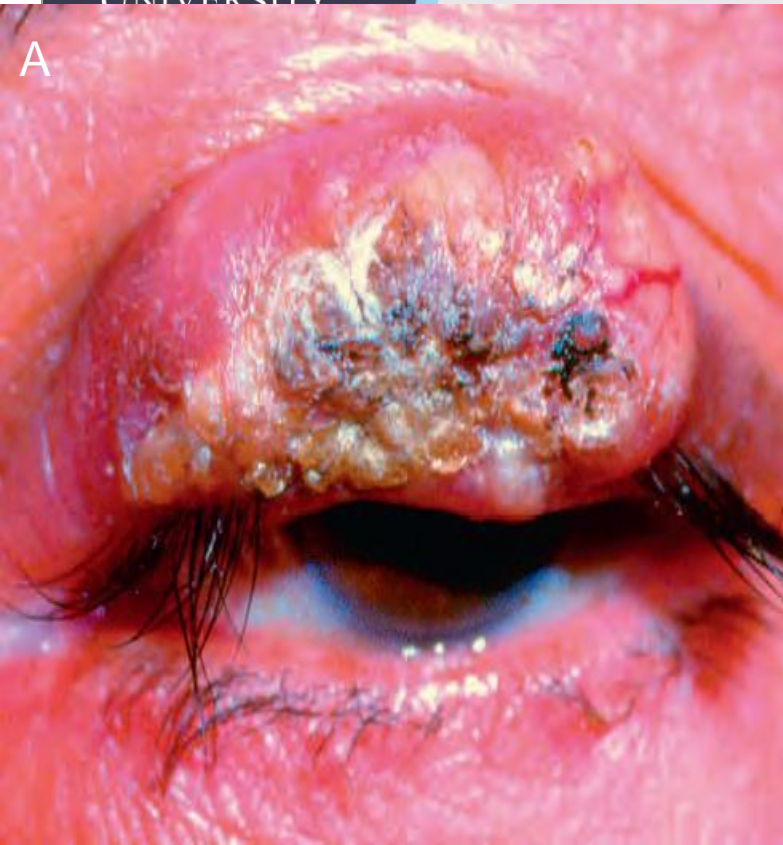# *Clinical features*

- **Nodular SCC** is characterized by a hyperkeratotic nodule that may develop crusting, erosions and fissures
- **Ulcerating SCC** has a red base and sharply defined, indurated and everted borders, but pearly margins and telangiectasia are not usually present
- **Cutaneous horn** with underlying invasive SCC



Centurion  
UNIVERSITY

*(A) nodular tumour with surface keratosis; (B) ulcerating tumour; (C) cutaneous horn*





**Centurion**  
**UNIVERSITY**  
*Shaping Lives...*  
*Empowering Communities...*

# Sebaceous gland carcinoma



**Centurion**  
**UNIVERSITY**

*Shaping Lives...  
Empowering Communities...*

# *Introduction*

- Sebaceous gland carcinoma (SGC) is a very rare, slowly growing tumour that most frequently affects the elderly, with a predisposition for females.
- It usually arises from the meibomian glands, although on occasion it may arise from the glands of Zeis or elsewhere.



**Centurion**  
**UNIVERSITY**

*Shaping Lives...  
Empowering Communities...*

# Continue...

- The tumour consists histopathologically of lobules of cells with pale foamy vacuolated lipid-containing cytoplasm and large hyperchromatic nuclei.
- Overall mortality is 5–10%; adverse prognostic features include upper lid involvement, tumour size of 10 mm or more and duration of symptoms of more than 6 months.

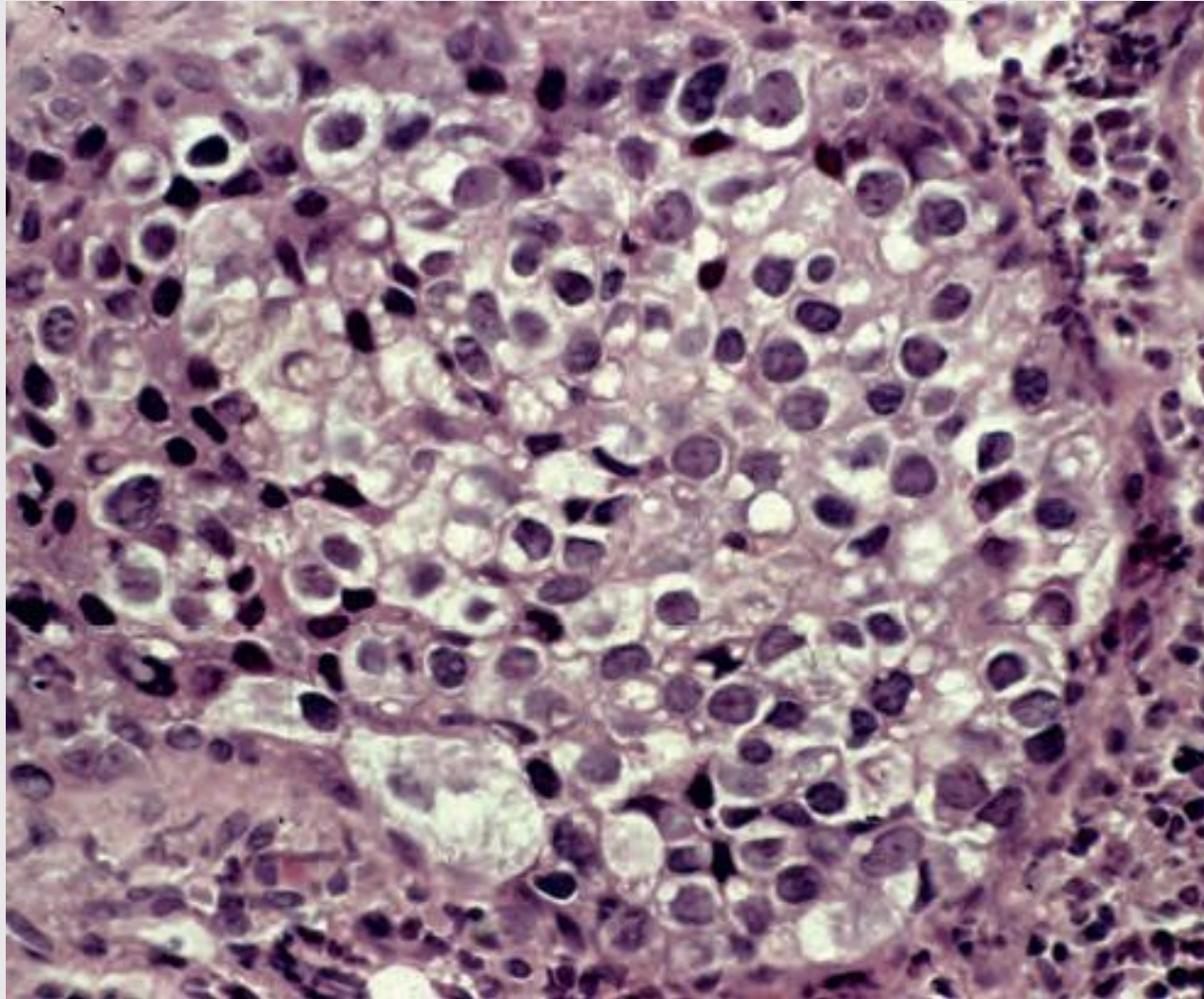




**Centurion**  
**UNIVERSITY**

*Shaping Lives...  
Empowering Communities...*

*Histopathology shows cells with large hyperchromatic nuclei and vacuolated cytoplasm*





**Centurion**  
**UNIVERSITY**

*Shaping Lives...  
Empowering Communities...*

# *Clinical features*

- In contrast to BCC and SCC, SGC occurs more commonly on the upper eyelid where meibomian glands are more numerous
- there may be simultaneous involvement of both lids on one side (5%).



Centurion  
UNIVERSITY

Shaping Lives...  
Empowering Communities...

# Continue...

- **Yellowish material** within the tumour is highly suggestive of SGC.
- **Nodular SGC** presents as a discrete, hard nodule, most commonly within the upper tarsal plate, and may exhibit yellow discoloration due to the presence of lipid; it can be mistaken for a chalazion.

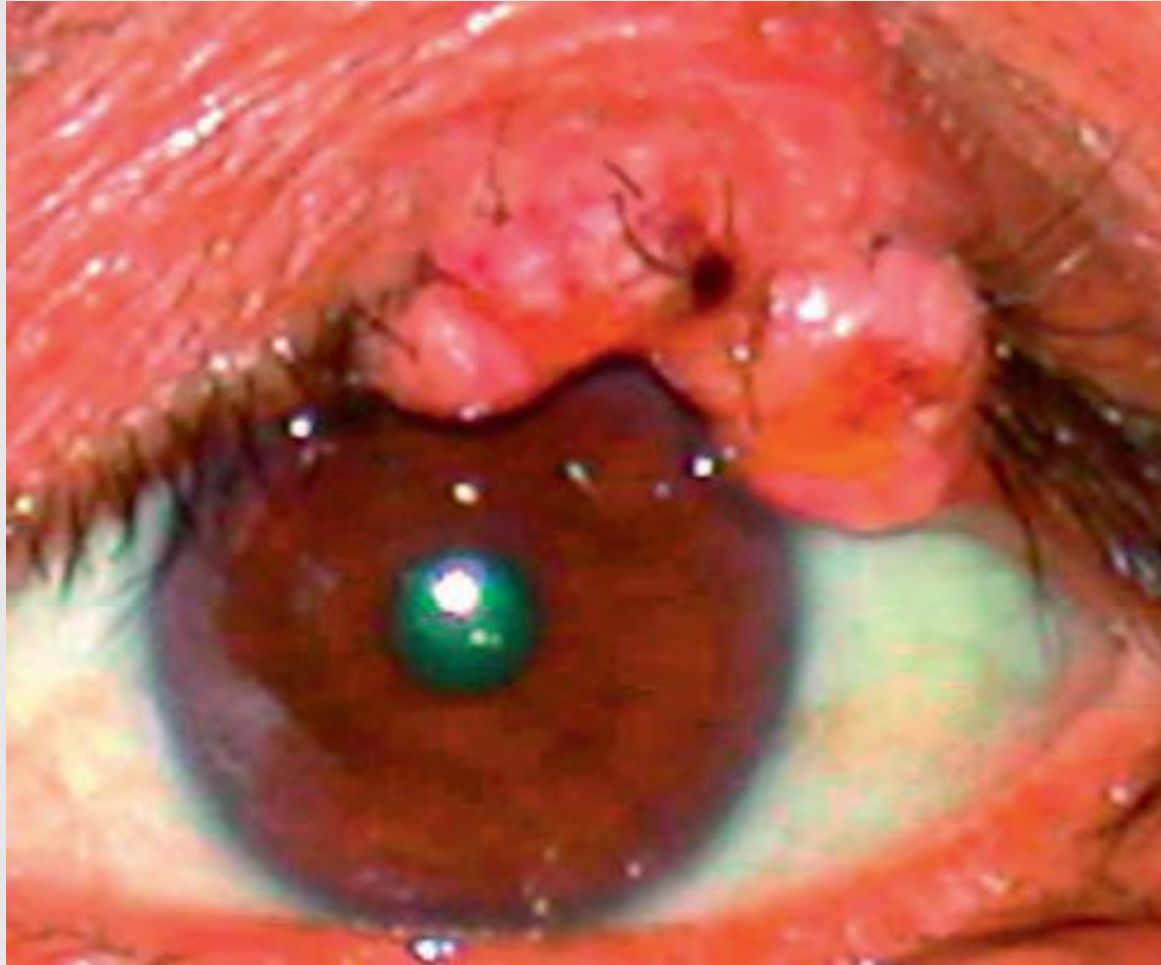




Centurion  
UNIVERSITY

Shaping Lives...  
Empowering Communities...

# *nodular tumour*





**Centurion**  
**UNIVERSITY**

*Shaping Lives...  
Empowering Communities...*

# Continue....

- **Spreading SGC** infiltrates into the dermis and causes a diffuse thickening of the lid margin often with eyelash distortion and loss, and can be mistaken for blepharitis

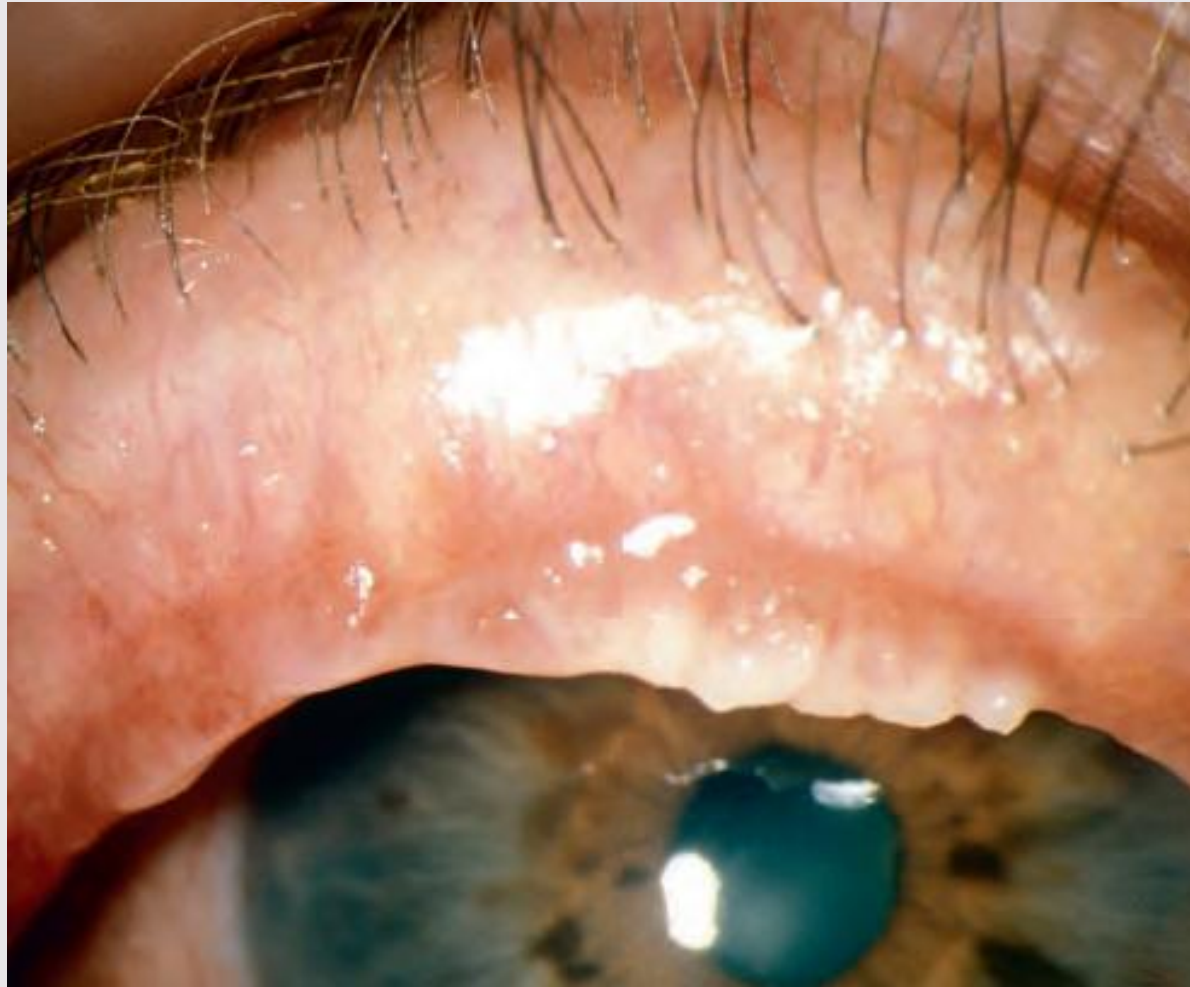



**Centurion**  
**UNIVERSITY**

*Shaping Lives...  
Empowering Communities...*

# *Spreading tumour*





**Centurion**  
**UNIVERSITY**

*Shaping Lives...*  
*Empowering Communities...*

# ECTROPION

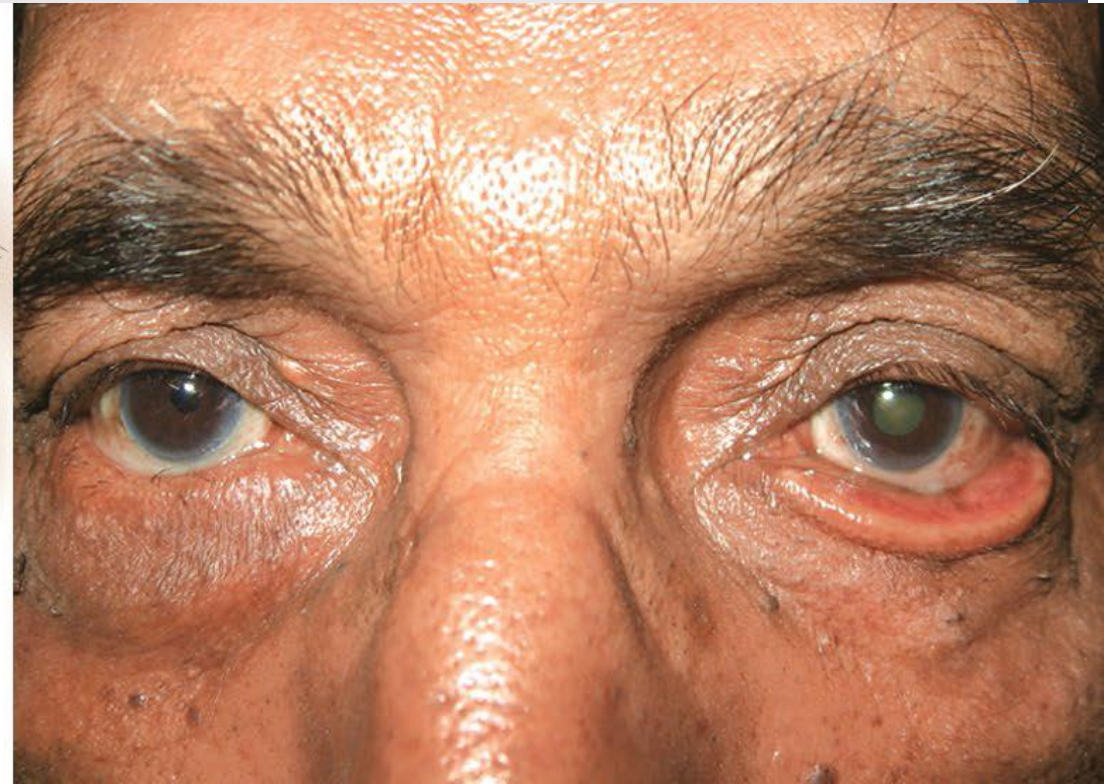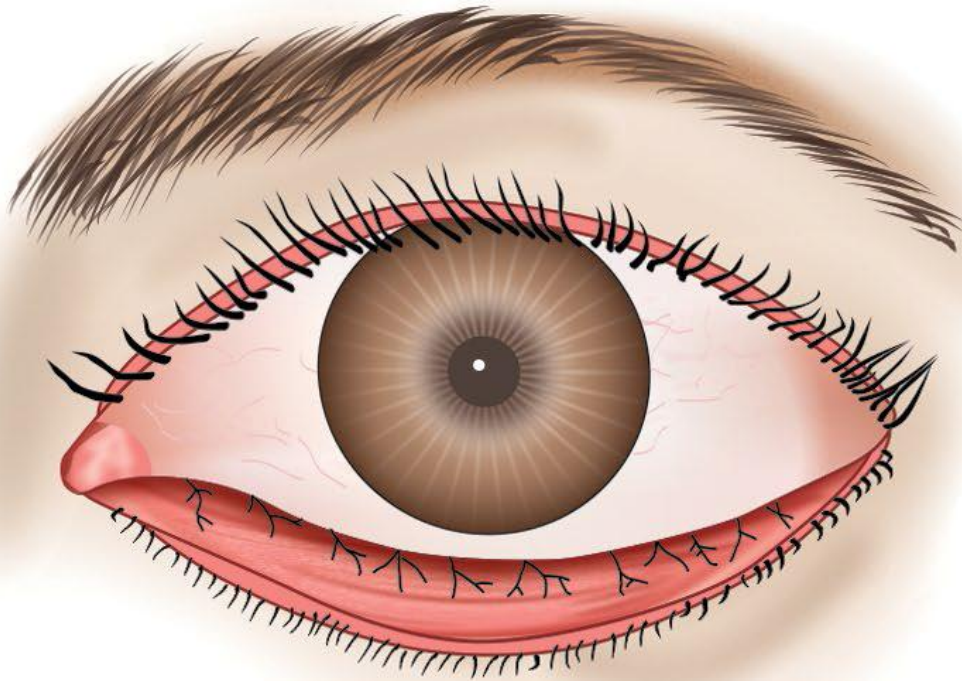


Centurion  
UNIVERSITY

Shaping Lives...  
Empowering Communities...

# Introduction

- It is an outward turning of the eyelid away from the globe.





**Centurion**  
**UNIVERSITY**

*Shaping Lives...  
Empowering Communities...*

# ***Classification***

- **Involutional (Senile):**
- It is the most common form, which affects the lower lid in elderly. It is due to excessive horizontal lid-length with weakness of the preseptal portion of the orbicularis.





**Centurion**  
**UNIVERSITY**

Shaping Lives...  
Empowering Communities...

# CONTINUE...

- The lid laxity can be assessed with the ***snap test***. *Pull the lower eyelid downward and assess how long it takes to return to a normal position.*
- A return of less than 1 second (without blinking) is normal.
- ***Treatment:*** *It is corrected by reducing the horizontal lid laxity:*





**Centurion**  
**UNIVERSITY**

Shaping Lives...  
Empowering Communities...

- ***Zeigler's cautery to correct the medial lid*** laxity with punctal eversion.
- ***Medial conjunctivoplasty*** for mild cases of medial ectropion.
- ***Horizontal lid shortening*** to correct ectropion involving the whole lid.

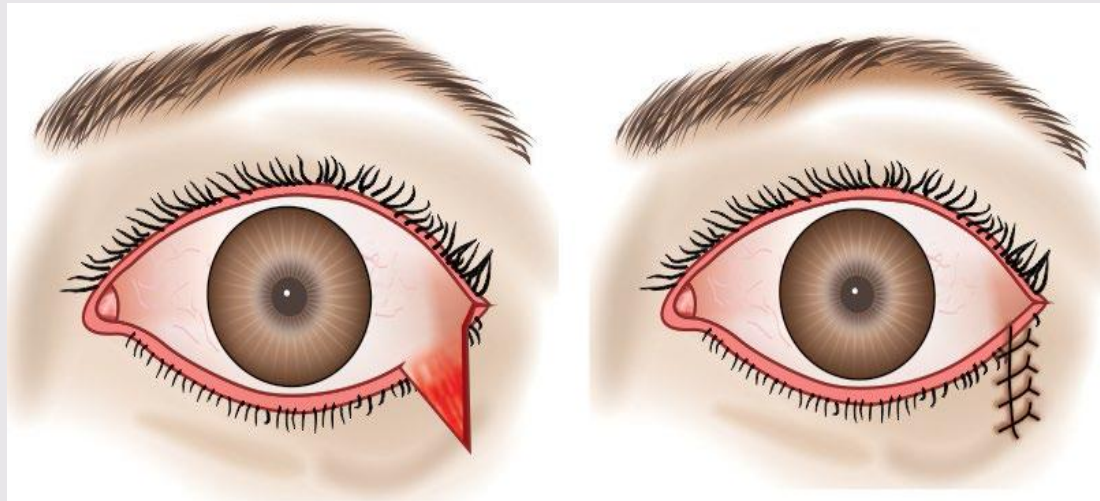


Centurion  
UNIVERSITY

Shaping Lives...  
Empowering Communities...

# CONTINUE...

- ***Bick's procedure excision of a full-thickness triangular wedge of lid at the outer canthus and then suture vertically.***



**Bick's procedure**



Centurion  
UNIVERSITY

Shaping Lives...  
Empowering Communities...

# CONTINUE...

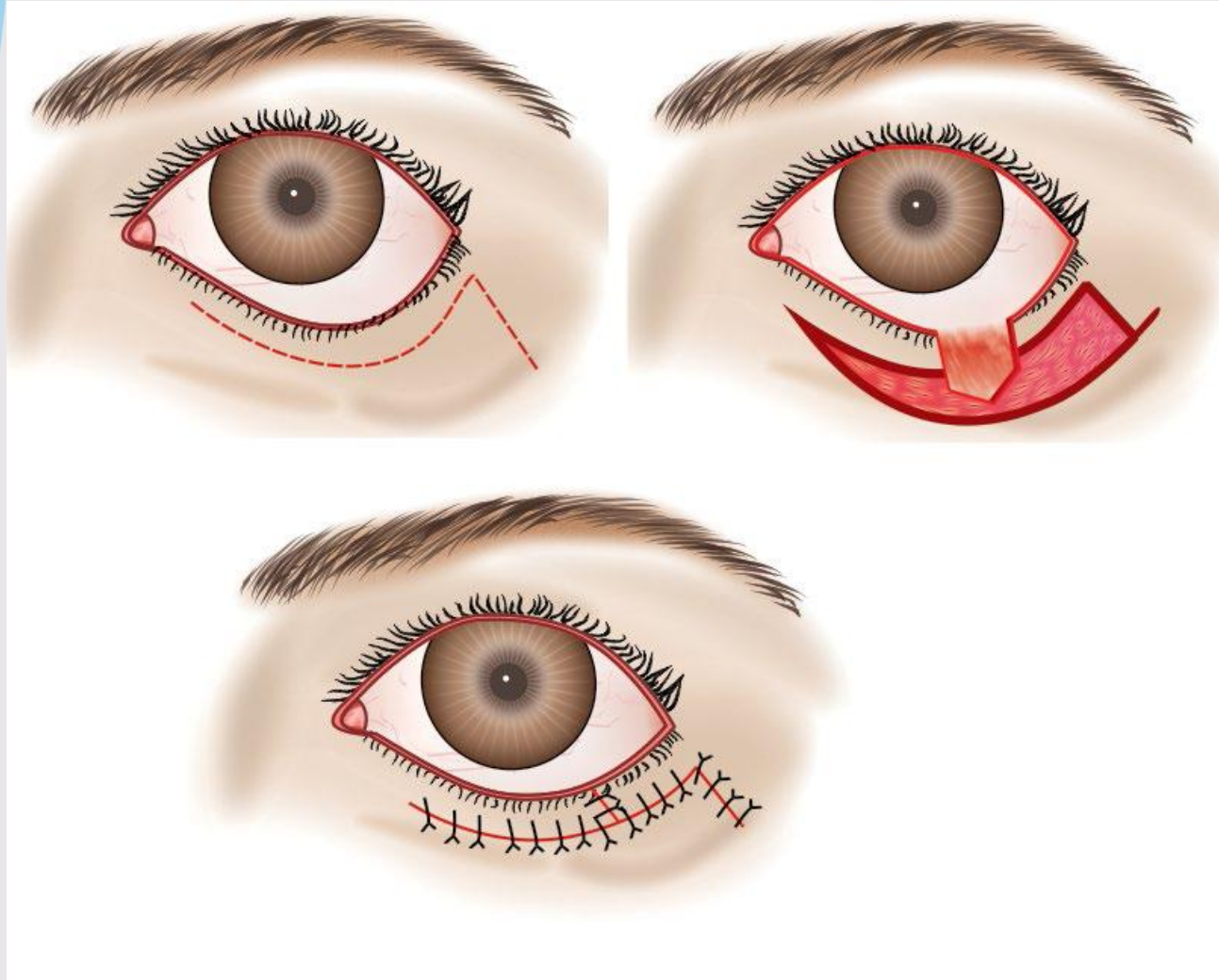
- ***Byron-Smith modification of Kuhnt-Szymanowski procedure:***
- Pentagonal wedge resection of the lid margin, along with excision of a triangular skin flap laterally.



Centurion  
UNIVERSITY

Shaping Lives...  
Empowering Communities...

# Modified Kuhnt-Szymanowski's procedure





Centurion  
UNIVERSITY

Shaping Lives...  
Empowering Communities...

# Cicatricial

- It is caused by contracture of the skin and underlying tissues.

## **Causes**

- Burns (chemical/thermal)
- Trauma
- Inflammation.
- It affects either the upper or lower lid.

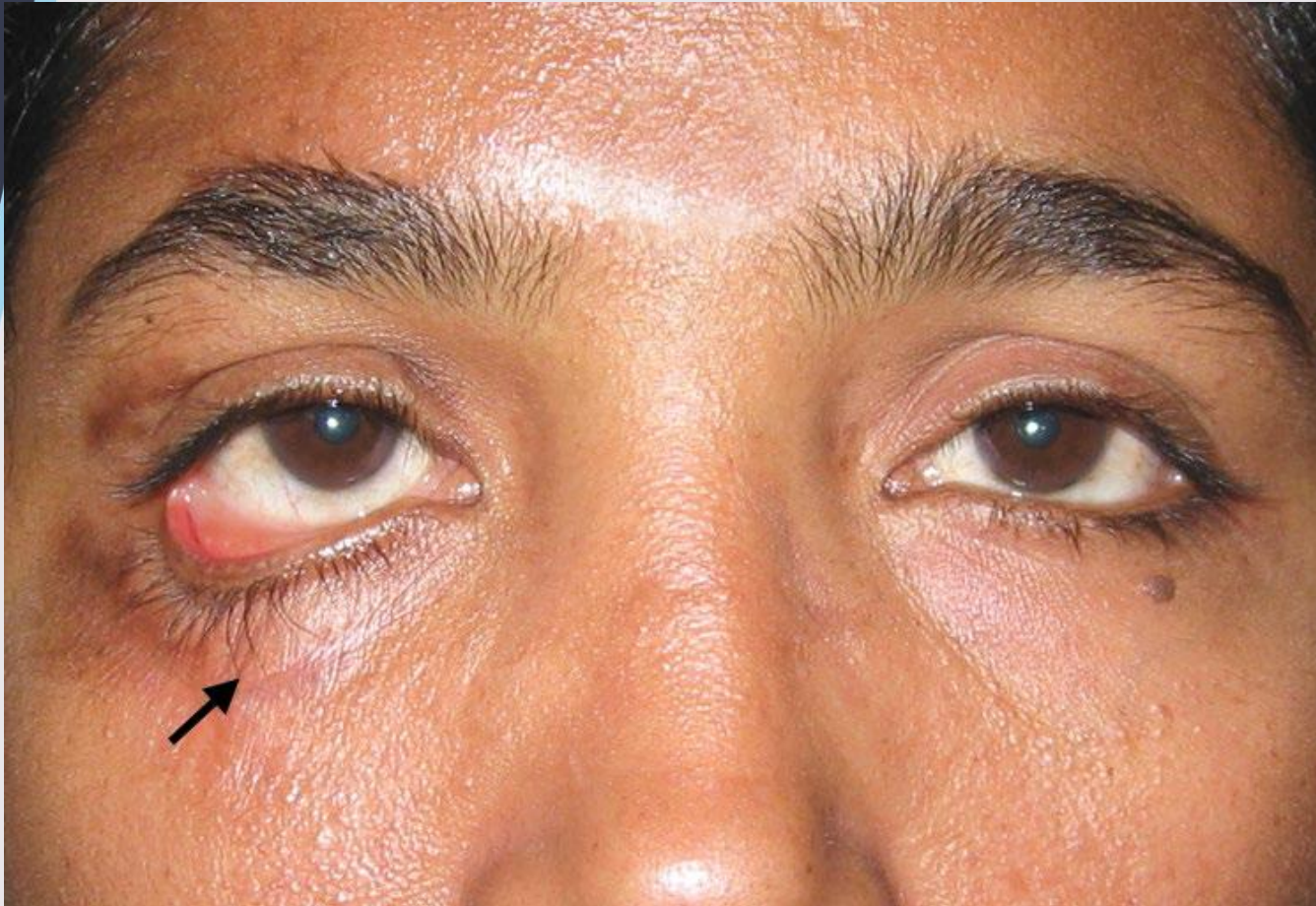



**Centurion**  
**UNIVERSITY**

*Shaping Lives...  
Empowering Communities...*

# Cicatricial ectropion of the right lower lid after chemical injury





**Centurion**  
**UNIVERSITY**

*Shaping Lives...  
Empowering Communities...*

# ***Treatment***

- Excision of the scar with a skin-graft to the raw area. Skin of the opposite upper eyelid is ideal for this purpose.
- Lengthening of the vertical-shortening of the lid—by Z-plasty.



Centurion  
UNIVERSITY

Shaping Lives...  
Empowering Communities...

# Paralytic

- It follows the paralysis of the orbicularis and is also associated lagophthalmos.
- ***Treatment:*** *The main aim is to prevent exposure keratitis.*



Centurion  
UNIVERSITY

Shaping Lives...  
Empowering Communities...

# CONTINUE...

- ***In mild cases***

Frequent instillation of artificial tears— to prevent corneal drying.

- Antibiotic ointment, or an adhesive tape to close the lid at night to prevent corneal exposure.





Centurion  
UNIVERSITY

Shaping Lives...  
Empowering Communities...

# CONTINUE...

- ***In severe cases***

***Tarsorrhaphy: Shortening of the palpebral aperture by lateral tarsorrhaphy, while awaiting any spontaneous recovery.***

- ***Lateral canthoplasty is more acceptable*** cosmetically.
- ***Correction by silicone-slings.***



Centurion  
UNIVERSITY

*Shaping Lives...  
Empowering Communities...*

# Congenital

- Rare, and may be associated with blepharophimosis. In severe cases—surgery is necessary.
- **Mechanical**
- Just the sequel to a swelling of the lower lid, e.g. a large chalazion, a tumor, or even lid edema. It can be easily rectified.



**Centurion**  
**UNIVERSITY**

*Shaping Lives...*  
*Empowering Communities...*

# Entropion



**Centurion**  
**UNIVERSITY**

*Shaping Lives...  
Empowering Communities...*

# INTRODUCTION

- Entropion is an inward turning of the eyelid with rubbing of the eyelashes on the conjunctiva and/or cornea.





Centurion  
UNIVERSITY  
*Shaping Lives...  
Empowering Communities...*

# ***Classification***

- **Involutional**
- Most common type and affects the lower lid only.
- ***Etiopathology:***

## ***Due to four changes:***

1. Upward movement of preseptal part of orbicularis oculi of the lower lid.
2. A thinning of the tarsal plate with subsequent atrophy—leading to horizontal lid laxity.



**Centurion**  
**UNIVERSITY**

*Shaping Lives...  
Empowering Communities...*

# Continue...

3. Thinning of the orbital septum and weakening of the lower lid retractors—lead to decrease in vertical lid stability.
4. A relative disparity between lid and globe (enophthalmos) from atrophy of the adipose tissue.

## ***Symptoms***

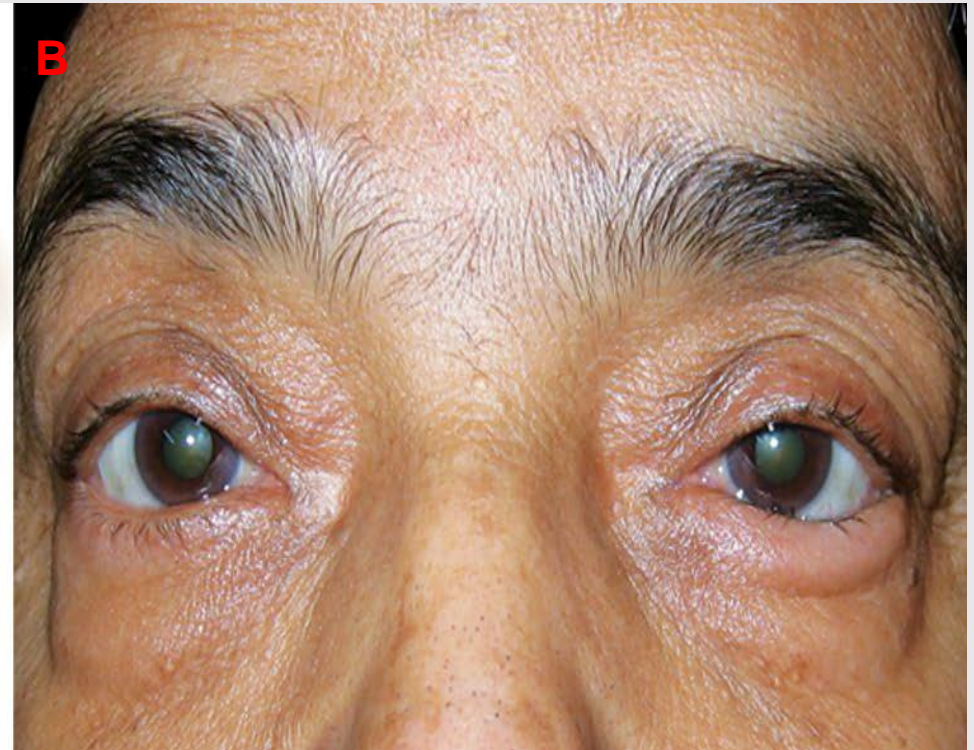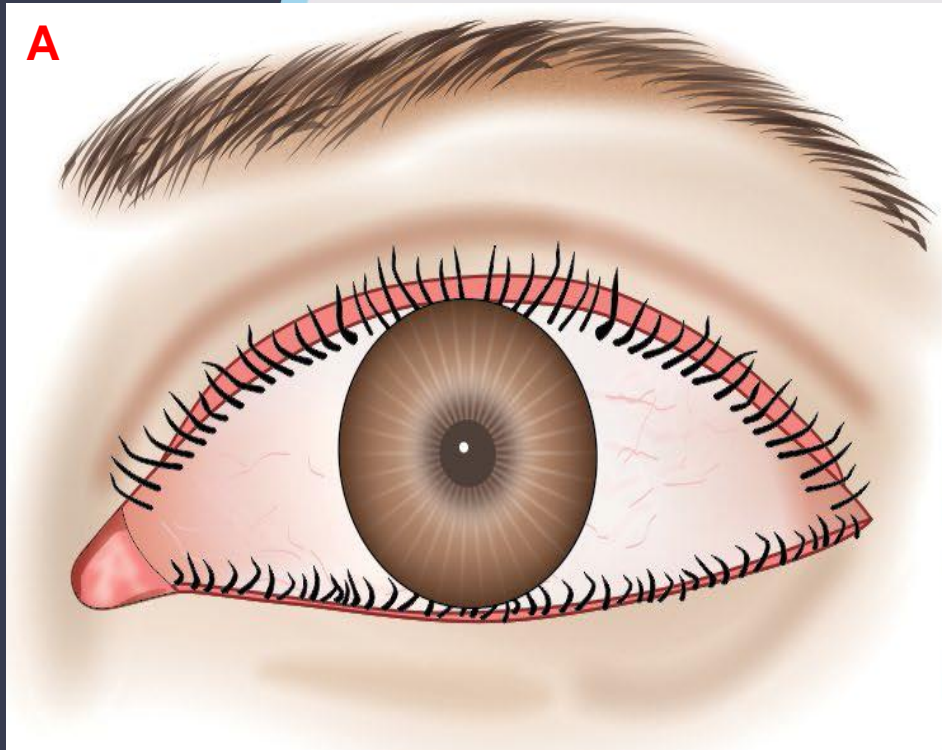
- **Foreign body sensation**
- **Pain**
- **Lacrimation and discharge.**



**Centurion**  
**UNIVERSITY**

*Shaping Lives...  
Empowering Communities...*

# A. Entropion of the lower eyelid (schematic representation); B. Senile entropion—left lower lid





**Centurion**  
**UNIVERSITY**

*Shaping Lives...  
Empowering Communities...*

# ***Signs***

- Inturning of the lower eyelid
- Conjunctival congestion
- Discharge with matting of the eyelashes
- Blepharospasm
- Superficial corneal opacities and distortion of the window reflex
- Sometimes, corneal ulceration.





Centurion  
UNIVERSITY

Shaping Lives...  
Empowering Communities...

# Treatment

## 1. *Temporary procedures*

- ***Adhesive tape***—*pulling the skin outwards* with a strip of adhesive tape.
- ***Cautery***—*over the skin below the lashes.*
- ***Transverse lid everting suture.***
- ***Alcohol injection***—*along the edge of the lid.*



Centurion  
UNIVERSITY

Shaping Lives...  
Empowering Communities...

# Continue...

## 2. *Permanent procedures*

- ***Weis' procedure:*** *A full-thickness horizontal lid splitting with marginal rotation.*
- ***Horizontal lid shortening:*** *An excision of full-thickness trapezoid-shaped area of the lid at the lateral canthus and then suturing the margins, to treat horizontal lid laxity.*



Centurion  
UNIVERSITY

Shaping Lives...  
Empowering Communities...

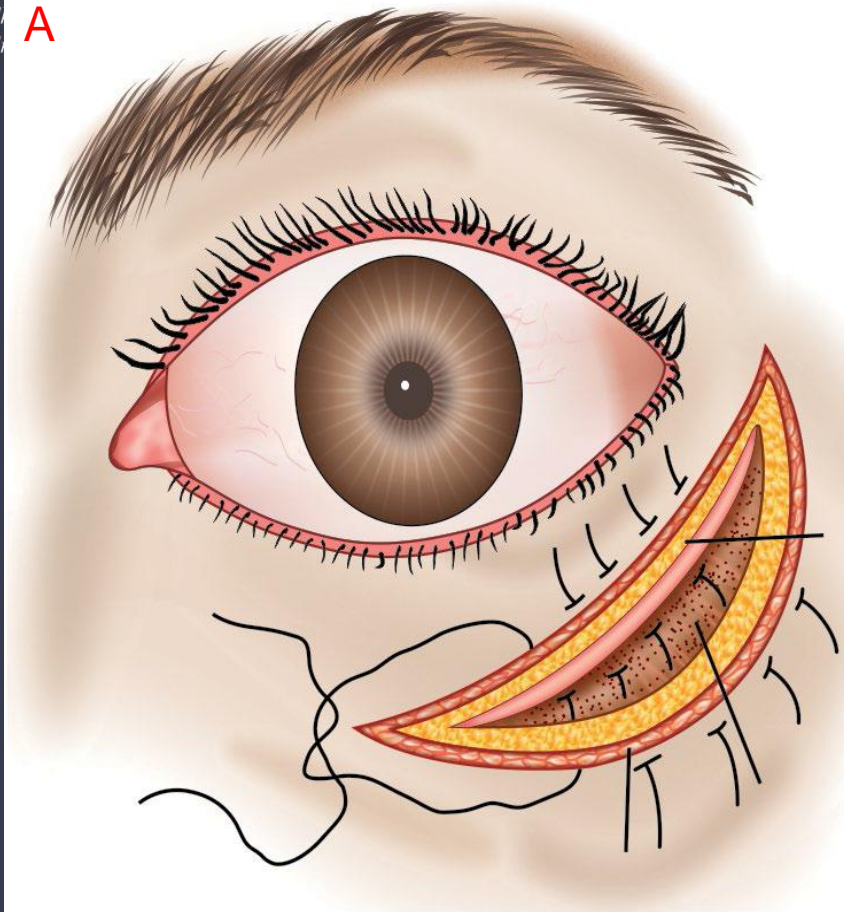
# Continue...

- ***Tucking of inferior lid retractors*** : It may be done as a primary procedure, or in recurrent cases.
- ***Fox procedure***: Excising a base-down triangle of the tarsus and conjunctiva, and then sutured together.

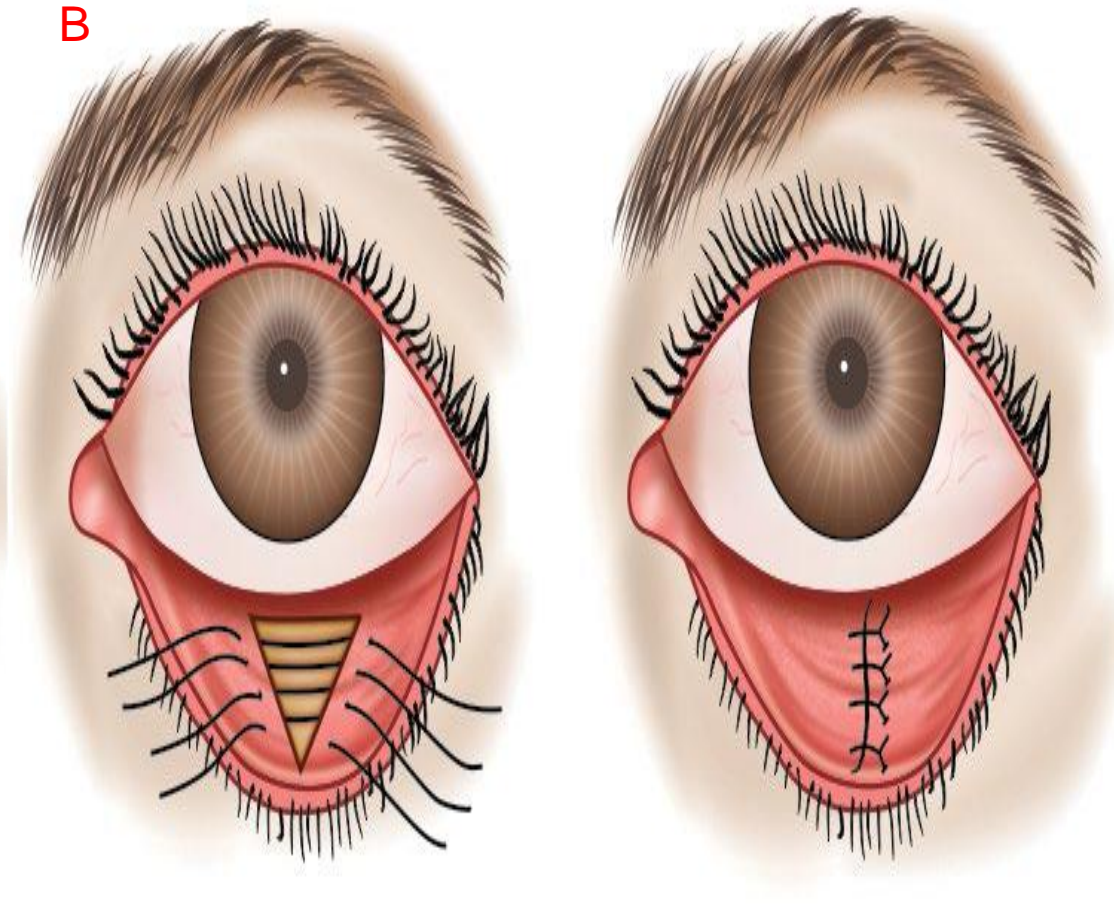


Centurion  
UNIVERSITY

S  
E  
A



Tucking of inferior lid retractors



Fox procedure



**Centurion**  
**UNIVERSITY**

*Shaping Lives...  
Empowering Communities...*

## 2. Cicatricial

- It is due to scarring of the palpebral conjunctiva. It may involve both the upper and lower lids. Frequently, the tarsus is deformed and thickened.





**Centurion**  
**UNIVERSITY**

*Shaping Lives...  
Empowering Communities...*

# ***Causes***

- **Chemical injuries**
- **Lacerated injuries**
- **Trachoma**
- **Radiation**
- **Stevens-Johnson syndrome**
- **Ocular cicatricial pemphigoid.**
- ***Treatment:*** *Aim of the treatment, is to keep the eyelashes away from the globe.*



**Centurion**  
**UNIVERSITY**

*Shaping Lives...  
Empowering Communities...*

# Treatment

- **Soft contact lens.**
- **Various plastic operations, and the ideas are:**
  - ✓ To alter the direction of the lashes,
  - ✓ To transplant the lashes and
  - ✓ To straighten the distorted tarsus.
- **Mucous membrane grafting** (from buccal mucosa) to replace the scarred conjunctiva.



**Centurion**  
**UNIVERSITY**

*Shaping Lives...  
Empowering Communities...*

## 3. Acute Spastic

- It results from excessive contraction of the orbicularis oculi (blepharospasm). It affects mainly the lower lid.
- ***Causes***
- **Chronic conjunctivitis**
- **Keratitis**
- **Postoperative.**



**Centurion**  
**UNIVERSITY**

Shaping Lives...  
Empowering Communities...

# *Treatment*

- Removal of the cause and it resolves spontaneously.
- Removal of bandage in postoperative cases.
- ***Temporary relief by—***
  - . Lid everting suture
  - . Adhesive tape (lid taping).



**Centurion**  
**UNIVERSITY**

*Shaping Lives...  
Empowering Communities...*

## 4. Congenital

- It is rare and usually caused by deformity of the tarsal plate. It may be associated with microphthalmos or anophthalmos.
- Sometimes, epiblepharon may occur with congenital entropion. It is an abnormal skinfold usually at the medial one-third of lower lid, and turns the lid margin inward.

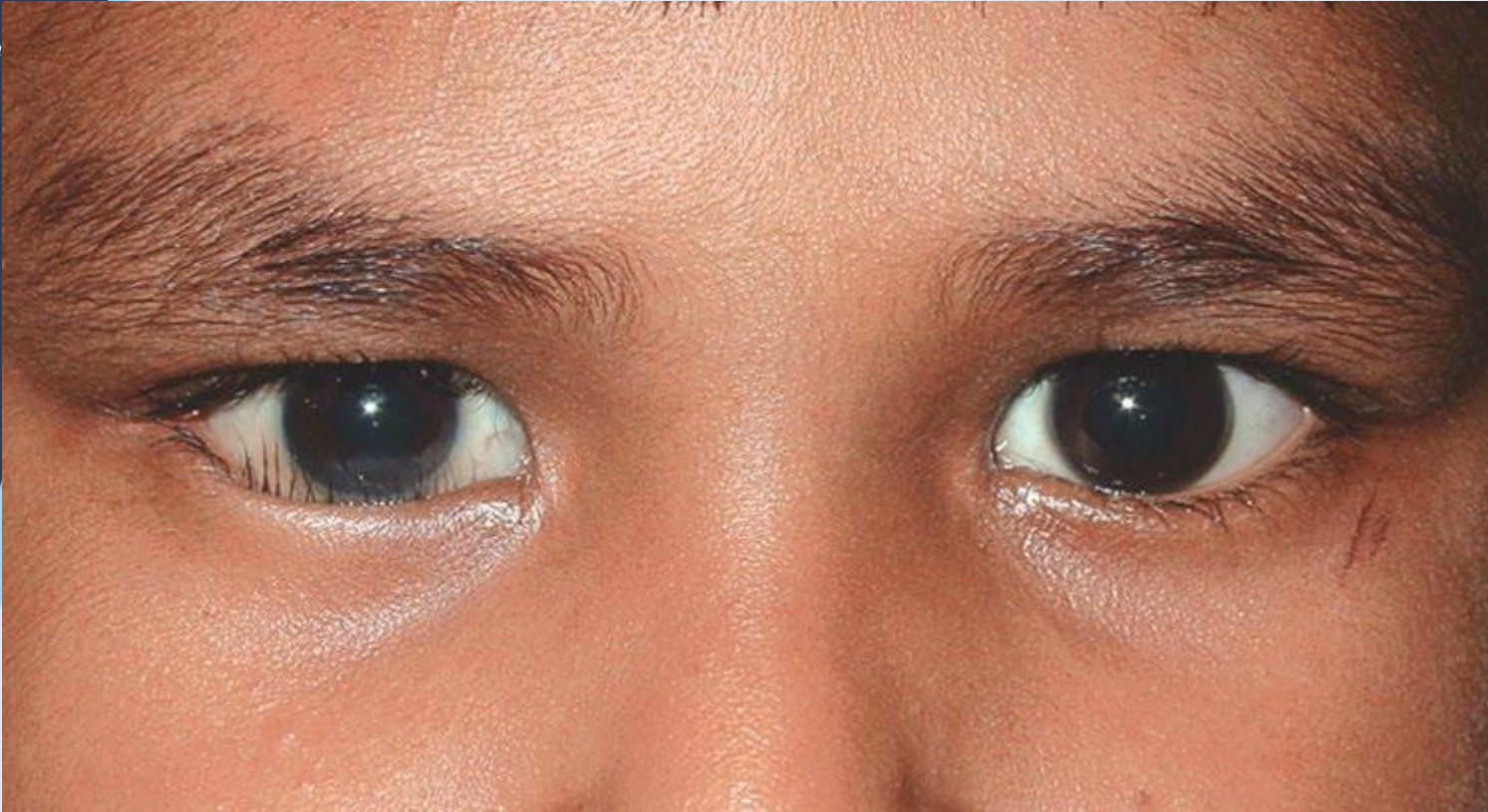



Centurion  
UNIVERSITY

Shaping Lives...  
Empowering Communit

# Congenital entropion—right lower lid





**Centurion**  
**UNIVERSITY**

*Shaping Lives...  
Empowering Communities...*

# ***Treatment***

- Resection of the abnormal portion of the tarsus.
- Excess skin may be excised if there is epiblepharon.



**Centurion**  
**UNIVERSITY**

*Shaping Lives...*  
*Empowering Communities...*

# Epicanthus



**Centurion**  
**UNIVERSITY**

*Shaping Lives...  
Empowering Communities...*

# Introduction

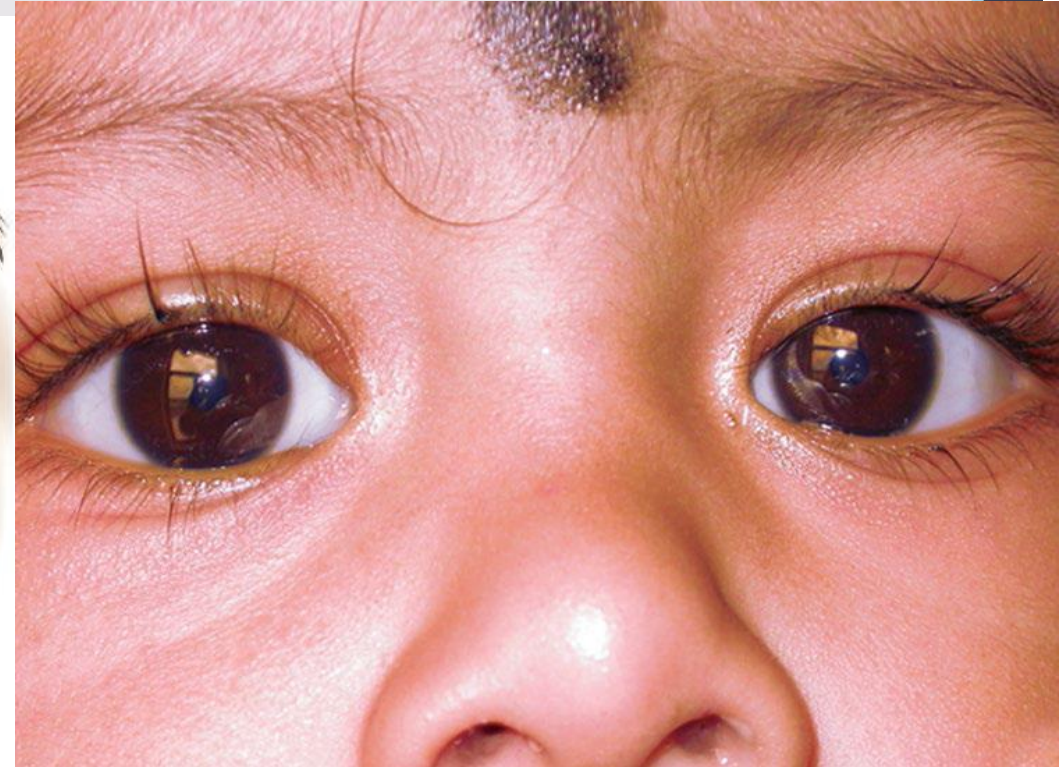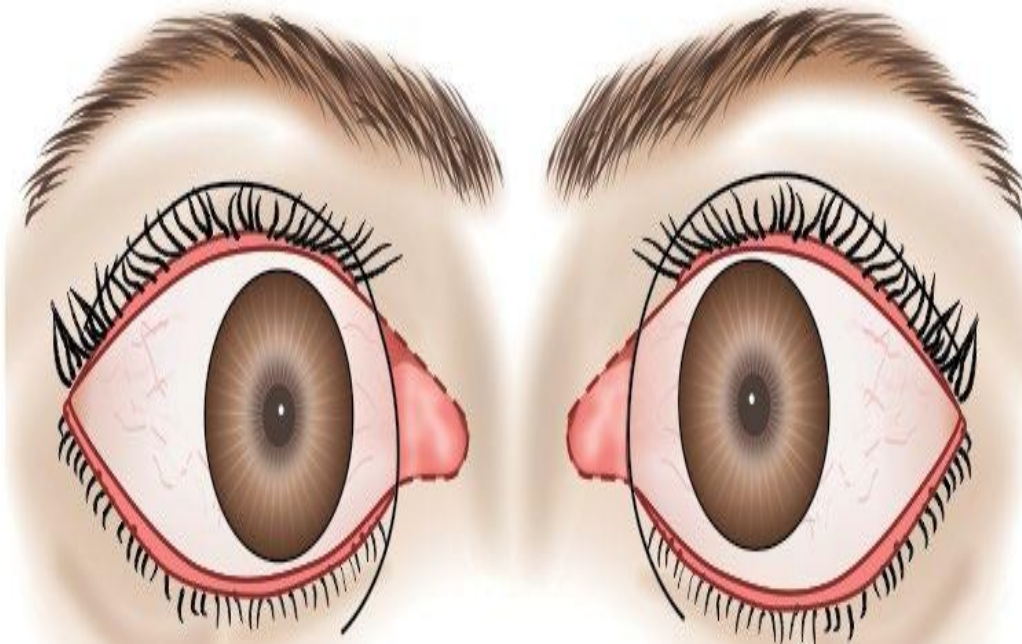
- Most common congenital condition.
- **A semilunar skin fold, situated above and sometimes covering the inner canthus.**





Centurion  
UNIVERSITY

Epicanthus, note the appearance of pseudo-convergent squint. **A. Schematic representation;** **B. Photograph**







**Centurion**  
**UNIVERSITY**

*Shaping Lives...  
Empowering Communities...*

# Continue...

- Usually bilateral, and simulate the appearance of pseudoconvergent squint.
- It is normal in Mongolian races.
- Easily treated by plastic repair



**Centurion**  
**UNIVERSITY**  
*Shaping Lives...*  
*Empowering Communities...*

# Coloboma of the Eyelid



Centurion  
UNIVERSITY

Shaping Lives...  
Empowering Communities...

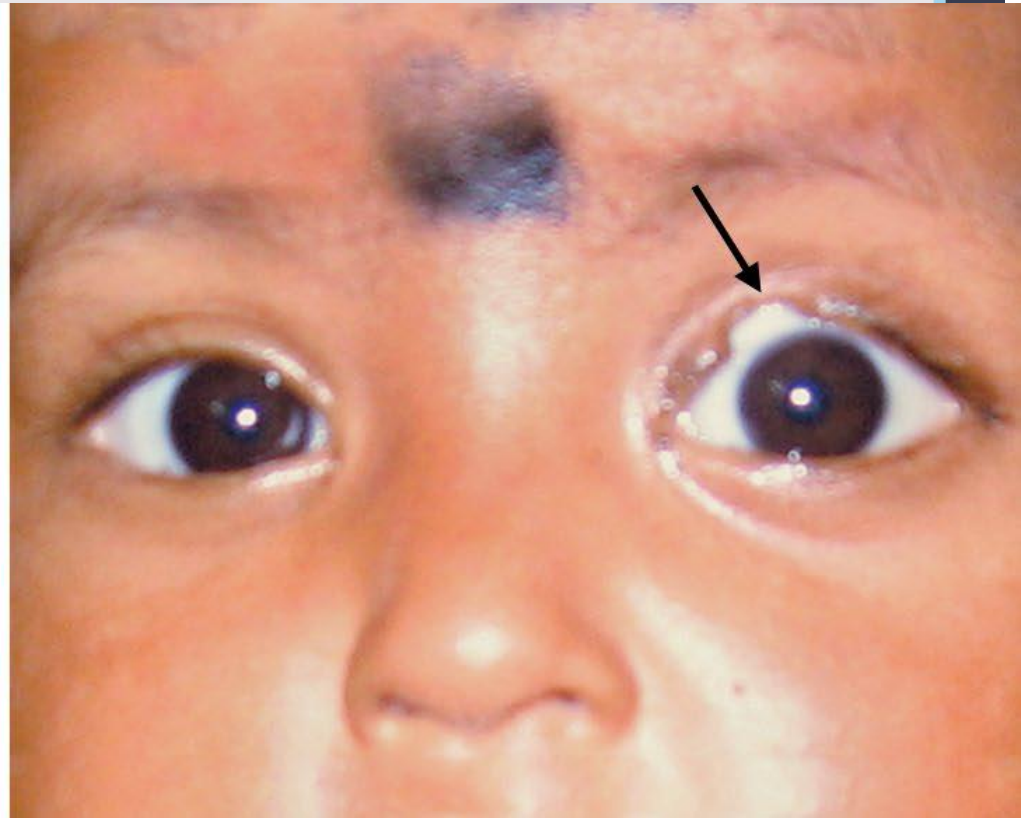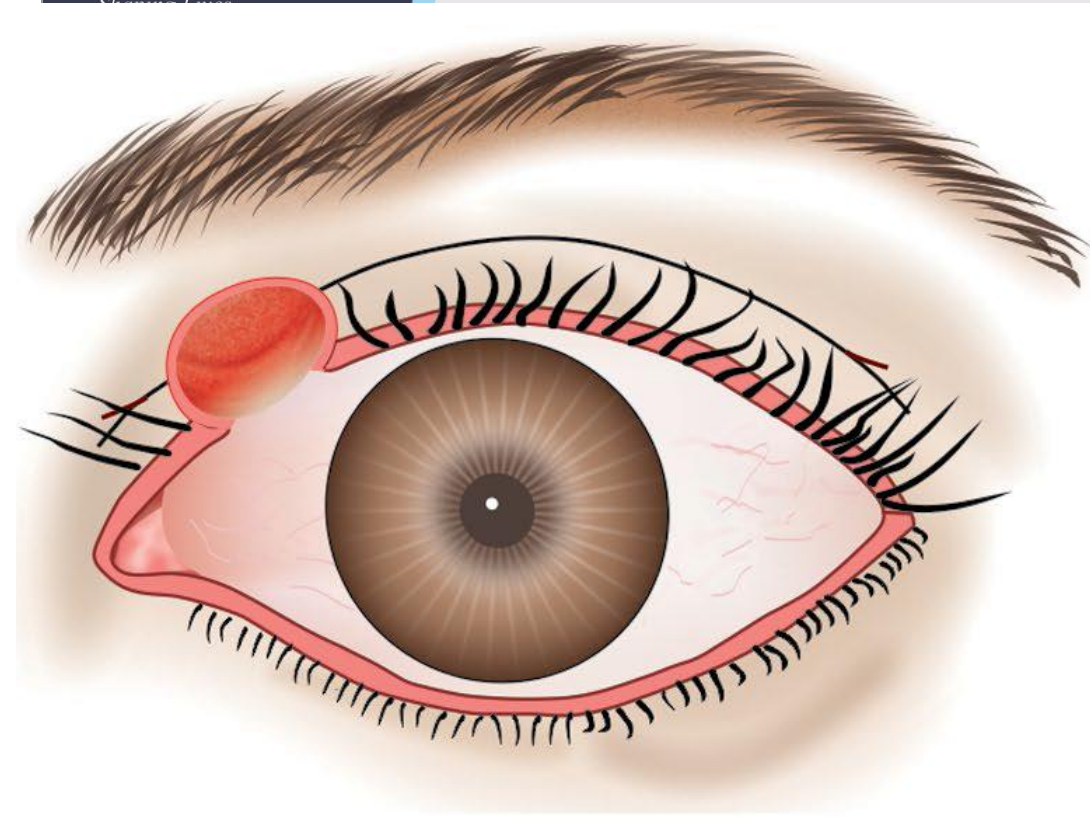
# Introduction

- A notch at the edge of the lid.
- Most commonly in the middle of the upper lid.
- Often associated with underlying dermoid cyst.
- *Treatment is by plastic repair at a very early age to prevent exposure keratitis*



Centurion  
UNIVERSITY

## Coloboma of the upper eyelid.





**Centurion**  
**UNIVERSITY**

*Shaping Lives...*  
*Empowering Communities...*

# Blepharophimosis





**Centurion**  
**UNIVERSITY**

Shaping Lives...  
Empowering Communities...

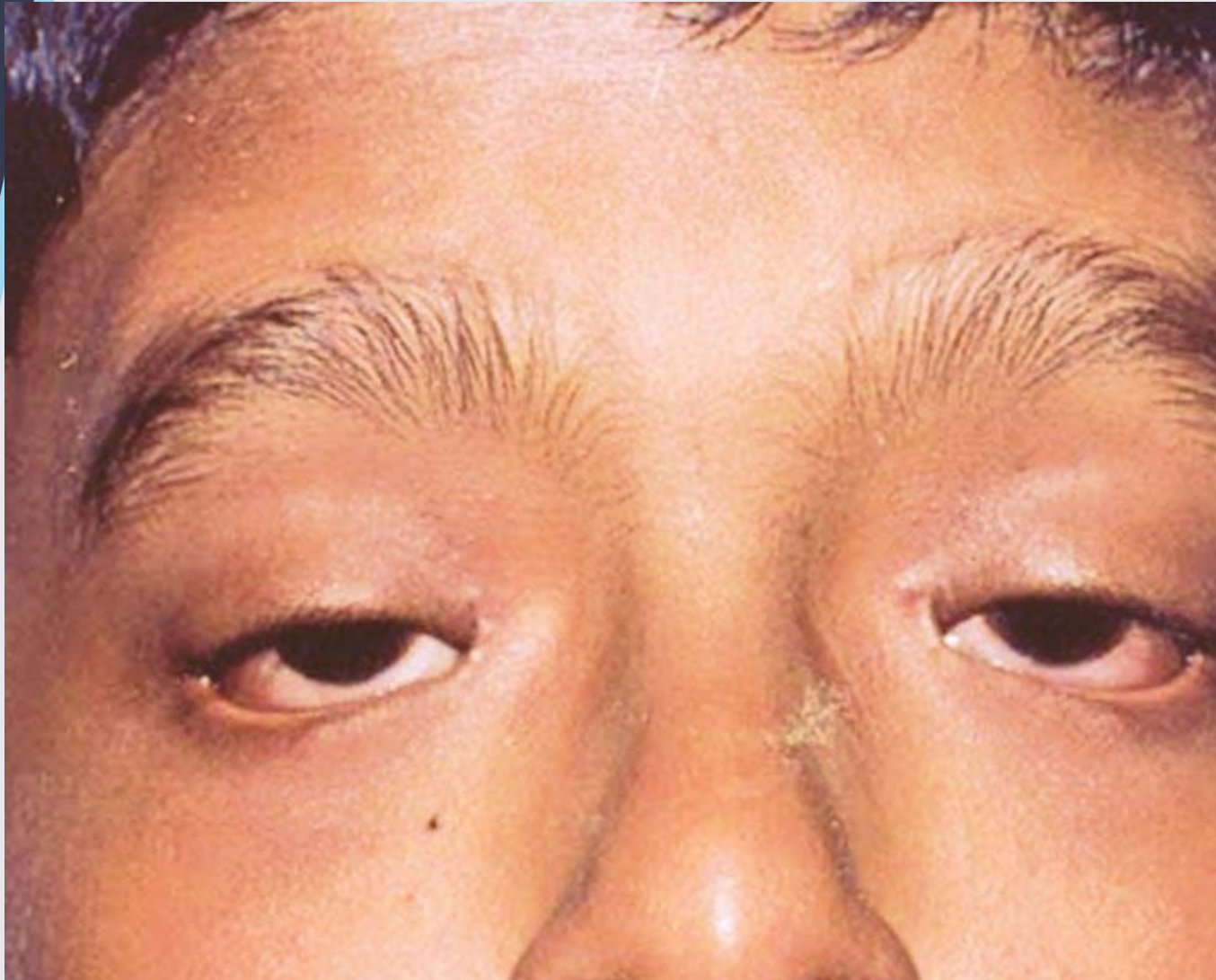# Introduction

- ***It is a syndrome consists of following***
- ***clinical features:***
  - . Narrowing of the vertical and horizontal palpebral apertures
  - „ Telecanthus
  - „ Inverse epicanthus fold and
  - „ Ptosis.
- **Autosomal dominant inheritance.**



**Centurion**  
**UNIVERSITY**  
*Shaping Lives...  
Empowering Communities...*

# Blepharophimosis syndrome





**Centurion**  
**UNIVERSITY**

*Shaping Lives...*  
*Empowering Communities...*

# Distichiasis



Centurion  
UNIVERSITY

Shaping Lives...  
Empowering Communities...

# Introduction

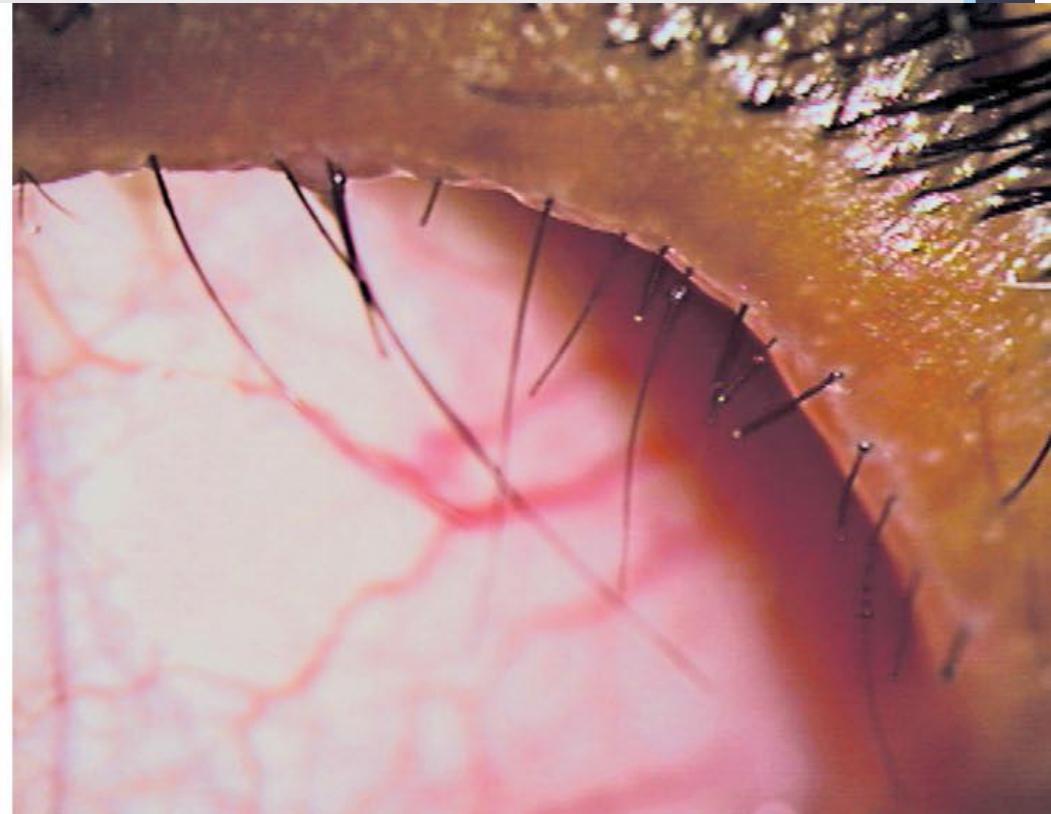
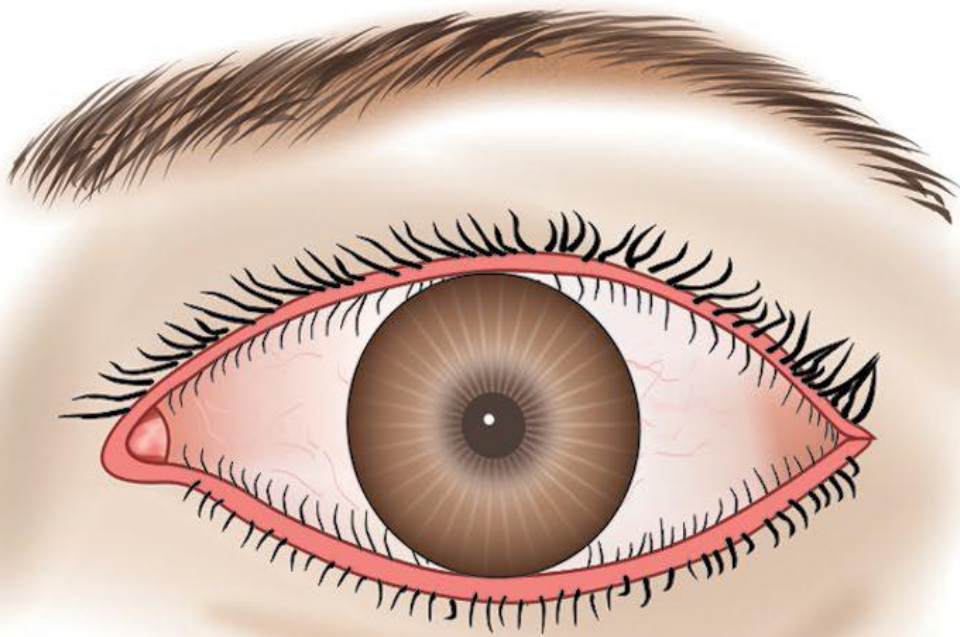
- Extra posterior row of cilia, occasionally present in all four lids:
- This posterior row occupies the position of meibomian glands.
- Meibomian glands change to ordinary sebaceous glands in this condition.
- The eyelashes may irritate the cornea.
- ***Treatment is done by cryotherapy or excision with grafting.***





**Centurion**  
**UNIVERSITY**  
*Shaping Lives...  
Empowering Communities...*

# Distichiasis of the upper lid







**Centurion**  
**UNIVERSITY**

*Shaping Lives...*  
*Empowering Communities...*

# Trichiasis



Centurion  
UNIVERSITY

Shaping Lives...  
Empowering Communities...

# Introduction

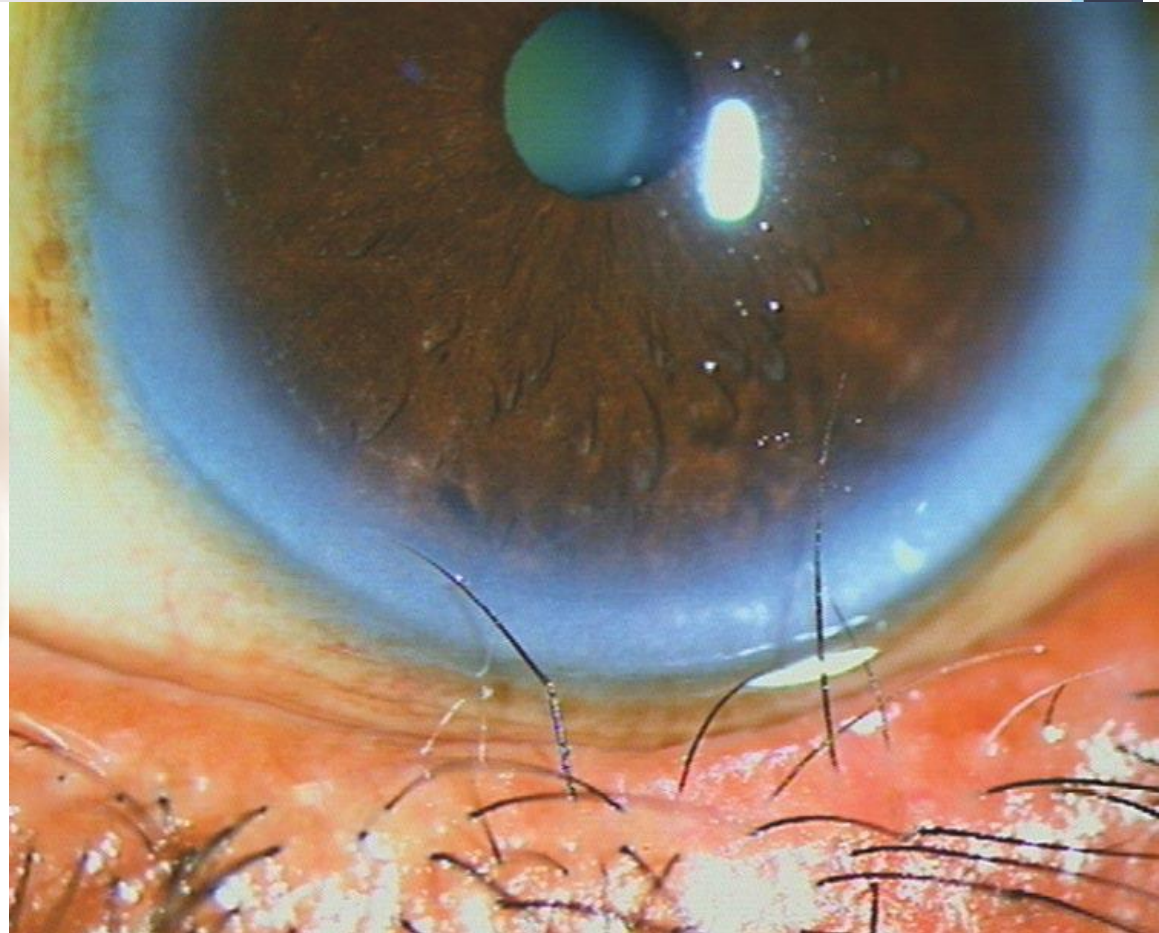
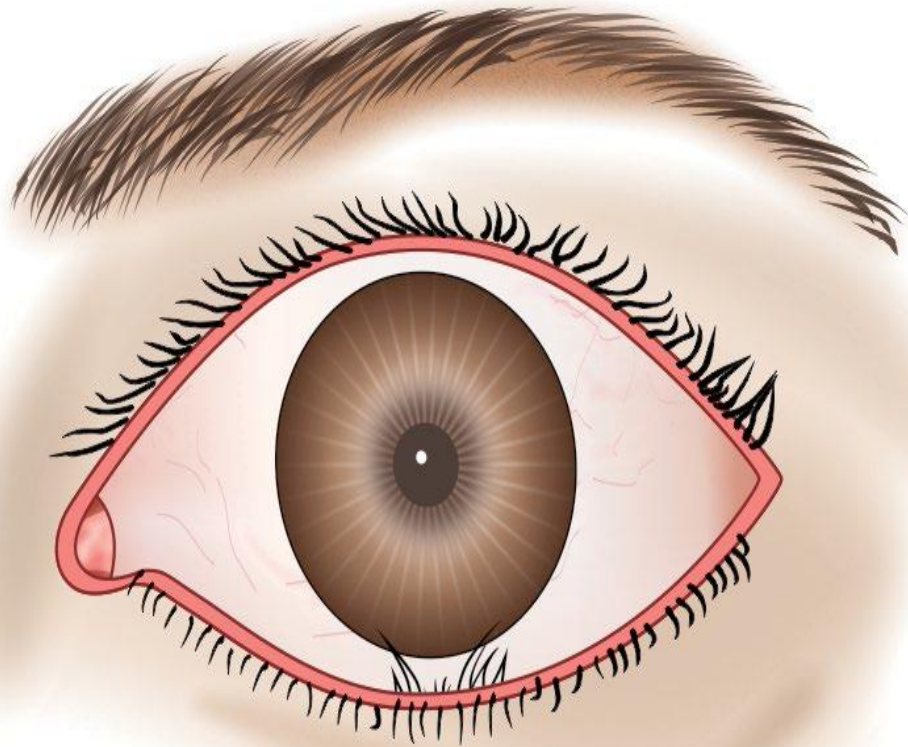
- Trichiasis is the inward misdirection of the eyelash(es) which irritate the cornea and/or the conjunctiva.
- ***Pseudotrachiasis:*** *When the misdirection is secondary to entropion.*



Centurion  
UNIVERSITY

Shaping Lives...  
Empowering Communities

# Trichiasis





Centurion  
UNIVERSITY

Shaping Lives...  
Empowering Communities...

# ***Etiology***

- ***Congenital***—known as *distichiasis*.
- ***Acquired***—due to diseases those cause scarring of the eyelid margin, e.g. stye, ulcerative blepharitis, membranous conjunctivitis, trachoma and post-traumatic.



**Centurion**  
**UNIVERSITY**  
*Shaping Lives...  
Empowering Communities...*

# ***Symptoms and Signs***

## ***Symptoms***

- Foreign body sensation
- Lacrimation and pain.

## ***Signs***

- Conjunctival congestion
- Reflex blepharospasm
- Ciliary congestion





**Centurion**  
**UNIVERSITY**

*Shaping Lives...  
Empowering Communities...*

# Continue...

- Recurrent erosions of the cornea
- Superficial corneal opacities
- Vascularization of the cornea.



Centurion  
UNIVERSITY

Shaping Lives...  
Empowering Communities...

# Treatment

- ***Epilation:*** Removal of the offending eyelashes with cilia forceps. This must be repeated every 6–8 weeks.
- ***Soft bandage contact lens:*** To protect the cornea temporarily.
- ***Permanent procedures:*** By destroying the hair roots.
- ***Electrolysis***
- ***Electrodiathermy***
- ***Cryotherapy***



**Centurion**  
**UNIVERSITY**

*Shaping Lives...  
Empowering Communities...*

# OEDEMA OF THE EYELIDS

- Owing to the looseness of the tissues, oedema of the lids is of common occurrence. It may be classified as inflammatory, solid and passive oedema.



Centurion  
UNIVERSITY

Shaping Lives...  
Empowering Communities...

# 1 *Inflammatory oedema*

1. **Inflammations of the lid itself**, which include dermatitis, stye, hordeolum internum, insect bites, cellulitis and lid abscess.
2. **Inflammations of the conjunctiva**, such as acute purulent, membranous and pseudo-membranous conjunctivitis.
3. **Inflammations of the lacrimal sac**, i.e., acute dacryocystitis and lacrimal abscess.



Centurion  
UNIVERSITY

Shaping Lives...  
Empowering Communities...

## Continue...

4. **Inflammations of the lacrimal gland**, i.e., acute dacryoadenitis.
5. **Inflammations of the eyeball**, such as acute iridocyclitis, endophthalmitis and panophthalmitis.
6. **Inflammations of the orbit**, which include orbital cellulitis, orbital abscess and pseudo-tumour.
7. **Inflammations of the paranasal sinuses**, e.g., maxillary sinusitis.





**Centurion**  
**UNIVERSITY**

*Shaping Lives...  
Empowering Communities...*

## **II. *Solid oedema of the lids.***

- It is chronic thickening of the lids, which usually follows recurrent attacks of erysipelas. It resembles oedema of the lids but is harder in consistency.



**Centurion**  
**UNIVERSITY**  
*Shaping Lives...  
Empowering Communities...*

### III. *Passive oedema of the lids*

- It may occur due to local or general causes.
- 1. *Local causes are: cavernous sinus thrombosis, head injury and angioneurotic oedema.*
- 2. *General causes are congestive heart failure, renal failure, hypoproteinaemia and severe anaemia.*



**Centurion**  
**UNIVERSITY**

*Shaping Lives...*  
*Empowering Communities...*

# BLEPHARITIS



**Centurion**  
**UNIVERSITY**

*Shaping Lives...  
Empowering Communities...*

# BLEPHARITIS

- It is a subacute or chronic inflammation of the lid margins. It is an extremely common disease which can be divided into following clinical types:
  1. **Seborrhoeic or squamous blepharitis,**
  2. **Staphylococcal or ulcerative blepharitis,**
  3. **Mixed staphylococcal with seborrhoeic blepharitis,**
  4. **Posterior blepharitis or meibomitis, and**
  5. **Parasitic blepharitis.**



Centurion  
UNIVERSITY

Shaping Lives...  
Empowering Communities...

# Seborrhoeic or squamous blepharitis: *Etiology*

- It is usually associated with seborrhoea of scalp (dandruff).
- Some constitutional and metabolic factors play a part in its etiology.
- In it, glands of Zeis secrete abnormal excessive neutral lipids which are split by *Corynebacterium acne* into irritating free fatty acids.





**Centurion**  
**UNIVERSITY**

*Shaping Lives...  
Empowering Communities...*

# ***Symptoms***

- Patients usually complain of deposition of whitish material at the lid margin associated with mild discomfort,
- Irritation,
- Occasional watering
- A history of falling of eyelashes.



**Centurion**  
**UNIVERSITY**  
*Shaping Lives...  
Empowering Communities...*

# *Signs*

- **Accumulation of white dandruff-like scales** are seen on the lid margin, among the lashes.
- On removing these scales underlying surface is found to be **hyperaemic**.
- **The lashes fall out easily** but are usually replaced quickly without distortion.
- In long-standing cases **lid margin is thickened and the sharp posterior border tends to be rounded** leading to epiphora.



Centurion  
UNIVERSITY  
Shaping Lives...  
Empowering Communities...

# Treatment

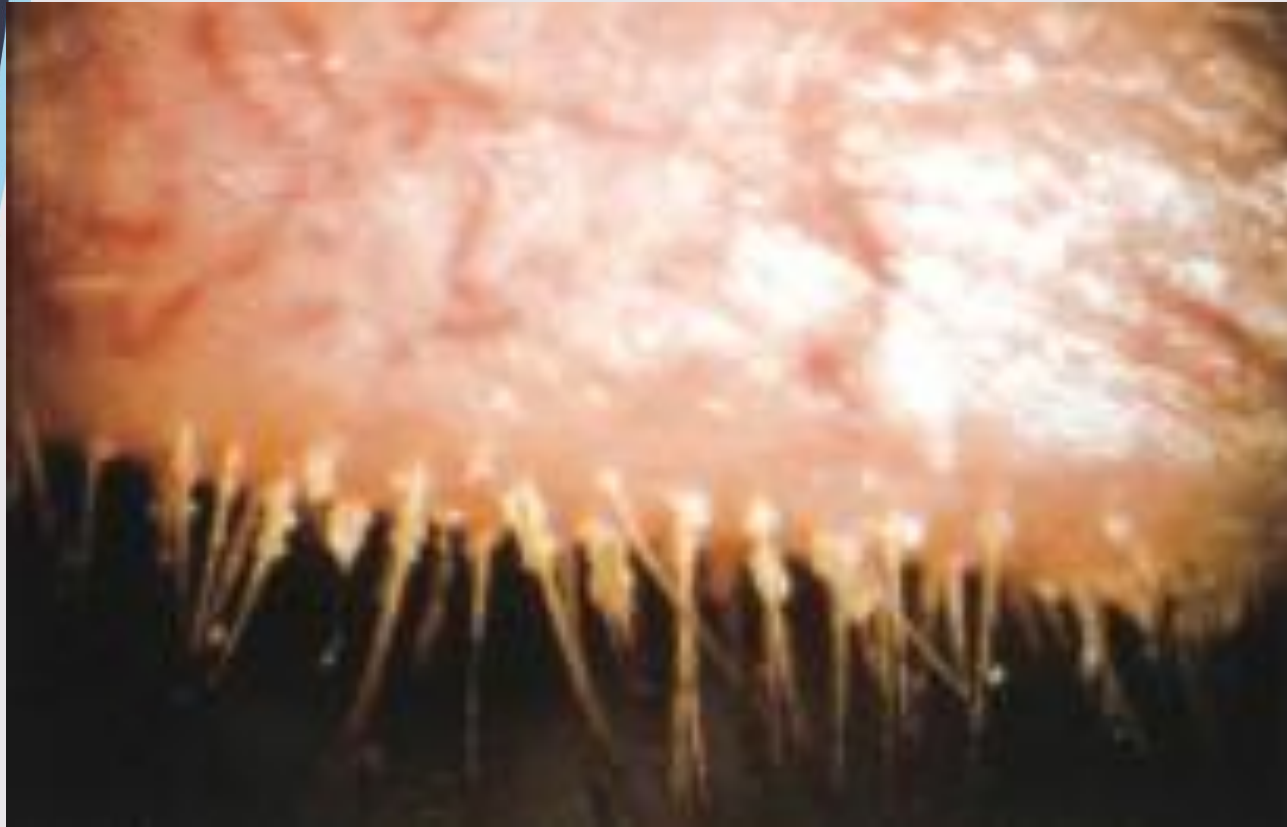- *General measures include **improvement of health and balanced diet.***
- *Associated **seborrhoea of the scalp** should be adequately treated.*
- *Local measures include **removal of scales from the lid margin** with the help of **lukewarm solution of 3 percent soda bicarb or baby shampoo** and frequent application of **combined antibiotic and steroid eye ointment** at the lid margin.*



**Centurion**  
**UNIVERSITY**

*Shaping Lives...  
Empowering Communities...*

# Seborrhoeic blepharitis





Centurion  
UNIVERSITY

Shaping Lives...  
Empowering Communities...

# Ulcerative blepharitis

- ***Etiology.*** It is a **chronic staphylococcal** infection of the lid margin usually caused by coagulase positive strains.
- The disorder usually starts in **childhood** and may continue **throughout life.** **Chronic conjunctivitis and dacryocystitis** may act as predisposing factors.





Centurion  
UNIVERSITY

Shaping Lives...  
Empowering Communities...

# *Symptoms*

- These include...
- Chronic irritation,
- Itching,
- Mild lacrimation,
- Gluing of cilia,
- Photophobia.
- The symptoms are characteristically **worse in the morning.**



Centurion  
UNIVERSITY

Shaping Lives...  
Empowering Communities...

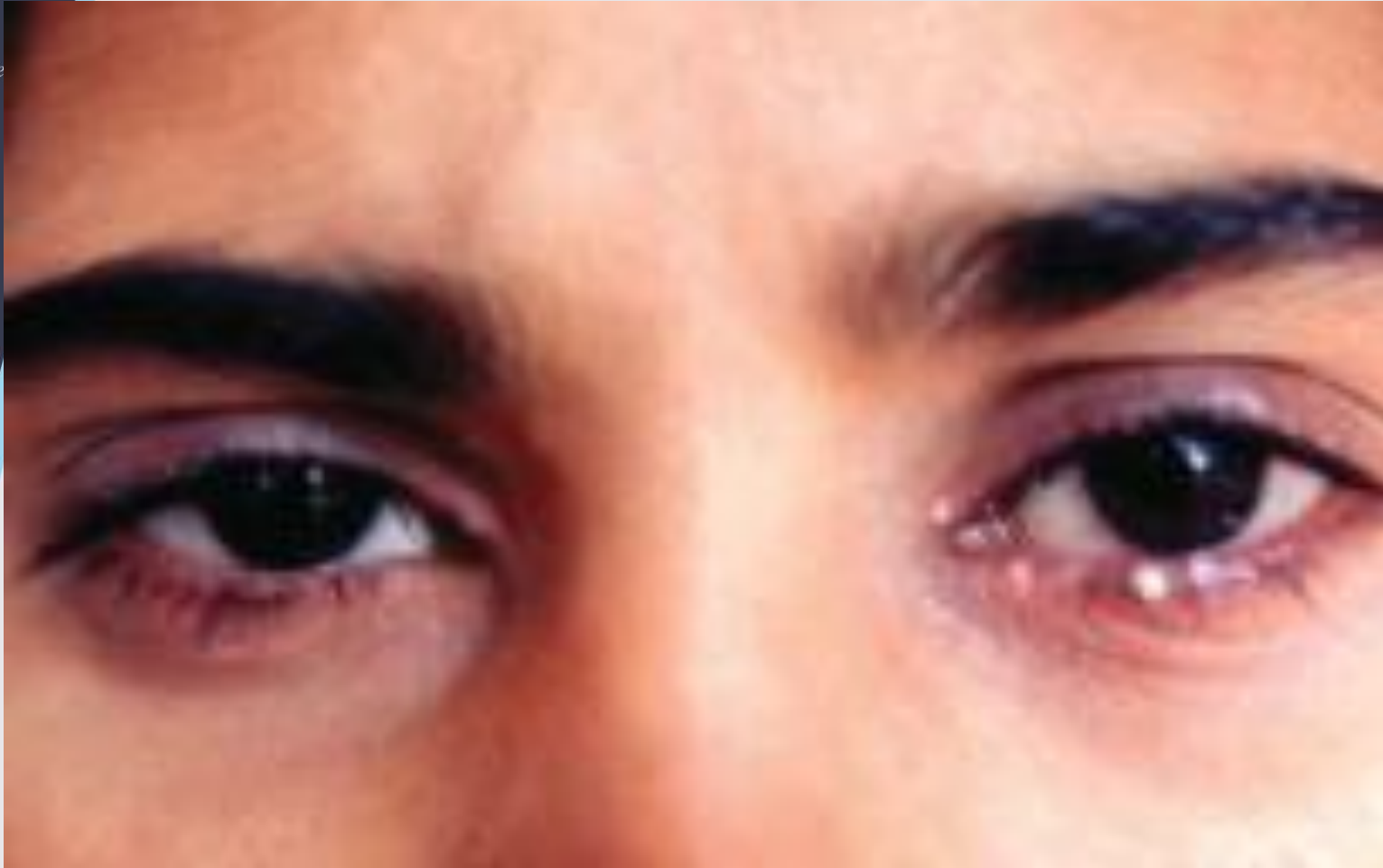# Signs

- **Yellow crusts** are seen at the root of cilia which **glue them together**.
- **Small ulcers**, which bleed easily, are seen on removing the crusts.
- In between the crusts, the anterior lid margin may show **dilated blood vessels (rosettes)**.



**Centurion**  
**UNIVERSITY**  
*Shaping Lives...  
Empowering Communities*

# Ulcerative blepharitis





**Centurion**  
**UNIVERSITY**  
*Shaping Lives...  
Empowering Communities...*

# ***Complications and sequelae***

- These are seen in longstanding (non-treated) cases and include **chronic conjunctivitis, madarosis** (sparseness or absence of lashes),
- **Trichiasis, poliosis** (greying of lashes), **tylosis** (thickening of lid margin) and eversion of the punctum leading to epiphora.
- **Eczema of the skin and ectropion** may develop due to prolonged watering. Recurrent styes is a very common complication.



Centurion  
UNIVERSITY

Shaping Lives...  
Empowering Communities...

# *Treatment*

- It should be treated promptly to avoid complication and sequelae.
- *Crusts should be removed after softening and **hot compresses with solution of 3 percent soda bicarb.***
- ***Antibiotic ointment** should be applied at the lid margin, immediately after removal of crusts, at least twice daily.*





**Centurion**  
**UNIVERSITY**

Shaping Lives...  
Empowering Communities...

# CONTINUE...

- ***Antibiotic eyedrops*** should be instilled 3-4 times in a day. Avoid rubbing of the eyes or fingering of the lids.



Centurion  
UNIVERSITY

Shaping Lives...  
Empowering Communities...

# CONTINUE...

- **Oral antibiotics** such as erythromycin or tetracyclines may be useful.
- Oral **anti-inflammatory drugs like ibuprofen** help in reducing the inflammation



Centurion  
UNIVERSITY  
Shaping Lives...  
Empowering Communities...

# Posterior blepharitis (Meibomitis)

## 1. Chronic meibomitis:

- It is a **meibomian gland dysfunction**, seen more commonly in middle-aged persons with acne rosacea and seborrhoeic dermatitis.
- It is characterized by white **frothy (foam-like) secretion on the eyelid margins and canthi** (meibomian seborrhoea).



**Centurion**  
**UNIVERSITY**

*Shaping Lives...  
Empowering Communities...*

# CONTINUE...

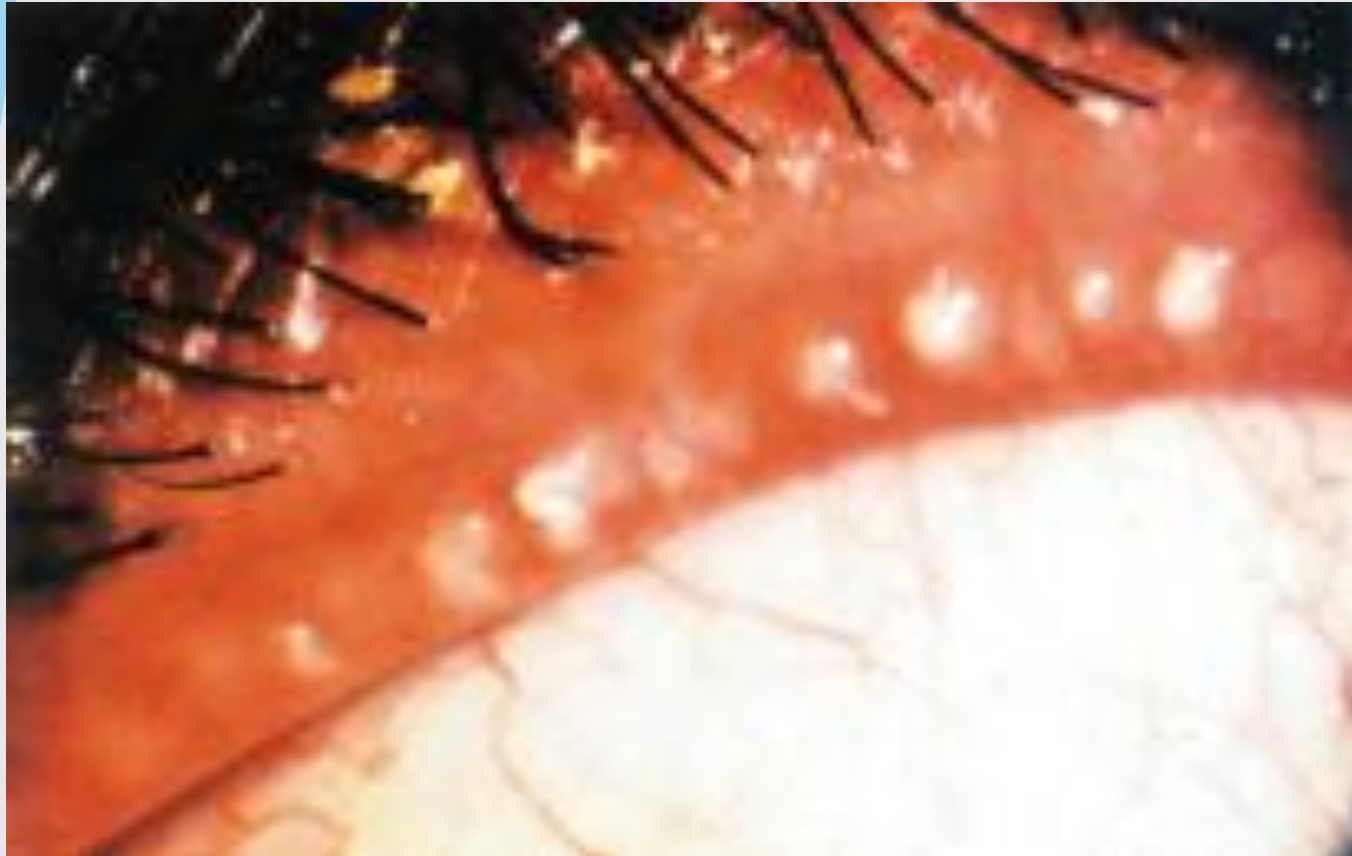
- On eversion of the eyelids, **vertical yellowish streaks shining** through the conjunctiva are seen.
- At the lid margin, openings of the meibomian glands become prominent with **thick secretions**



**Centurion**  
**UNIVERSITY**

*Shaping Lives...  
Empowering Communities...*

# Chronic meibomitis







Centurion  
UNIVERSITY

Shaping Lives...  
Empowering Communities...

## 2. *Acute meibomitis*

- Occurs mostly due to **staphylococcal infection**.
- **Treatment:**
  - ✓ Meibomitis consists of *expression of the glands by repeated vertical lid massage*.
  - ✓ Followed by rubbing of *antibiotic-steroid ointment at the lid margin*.
  - ✓ *Antibiotic eyedrops should be instilled 3-4 times*



Centurion  
UNIVERSITY

Shaping Lives...  
Empowering Communities...

# Continue...

- ***Systemic tetracyclines*** for 6-12 weeks remain the mainstay of treatment of posterior blepharitis.
- **Erythromycin** may be used where tetracyclines are contraindicated.



Centurion  
UNIVERSITY

Shaping Lives...  
Empowering Communities...

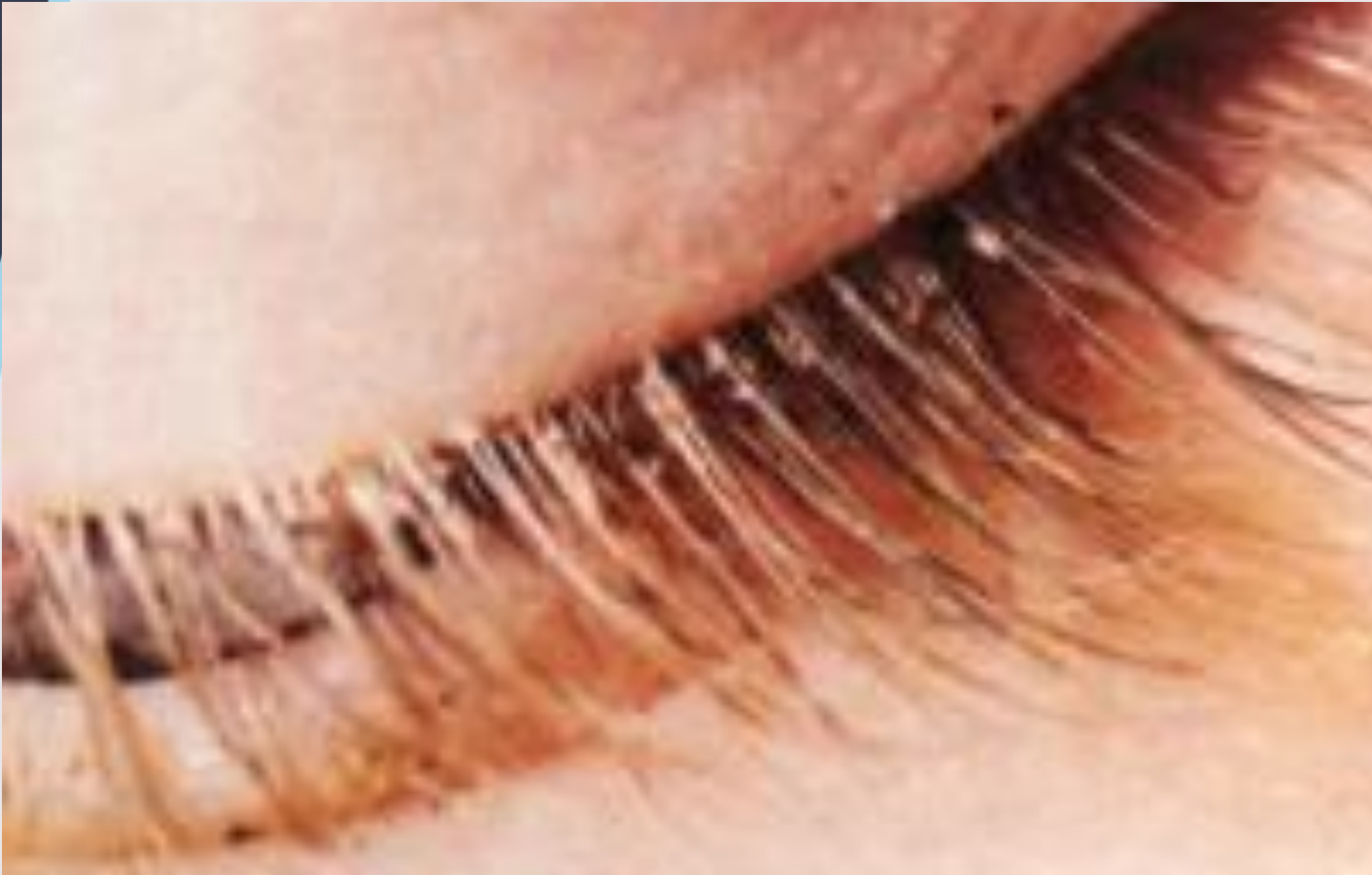### 3. Parasitic blepharitis

- ***Blepharitis acrica*** refers to a **chronic blepharitis** associated with ***Demodex folliculorum*** infection and ***Phthiriasis palpebram*** to that due to crab-louse, very rarely to the head-louse.
- In addition to features of chronic blepharitis, it is characterized by presence at the **lid margin and at roots of eyelashes.**



**Centurion**  
**UNIVERSITY**  
*Shaping Lives...  
Empowering Communities...*

# Phthiriasis palpebram





**Centurion**  
**UNIVERSITY**

*Shaping Lives...  
Empowering Communities...*

# ***Treatment***

- **Mechanical removal of the nits with forceps followed by rubbing of antibiotic ointment on lid margins, and delousing of the patient, other family members, clothing and bedding.**





**Centurion**  
**UNIVERSITY**

*Shaping Lives...*  
*Empowering Communities...*

# **EXTERNAL HORDEOLUM (STYE)**



**Centurion**  
**UNIVERSITY**

*Shaping Lives...  
Empowering Communities...*

# EXTERNAL HORDEOLUM (STYE)

- It is an acute **suppurative inflammation** of gland of the **Zeis** or **Moll**.



Centurion  
UNIVERSITY

Shaping Lives...  
Empowering Communities...

# Etiology

## 1. Predisposing factors:

- It is more common in children and young adults (though no age is bar)
- Patients with eye strain due to muscle imbalance or refractive errors.
- Habitual rubbing of the eyes or fingering of the lids and nose, chronic blepharitis and diabetes mellitus are usually associated with recurrent styes.



**Centurion**  
**UNIVERSITY**

Shaping Lives...  
Empowering Communities...

# CONTINUE...

- ✓ Metabolic factors
- ✓ Chronic debility,
- ✓ Excessive intake of carbohydrates
- ✓ Alcohol also act as predisposing factors.
- *Causative organism commonly involved is **Staphylococcus aureus.***



Centurion  
UNIVERSITY

Shaping Lives...  
Empowering Communities...

# Symptoms & Signs

- These include **acute pain** associated with **swelling of lid**, **mild watering** and **photophobia**
  1. **Stage of cellulitis** is characterised by *localised*, hard, red, tender swelling at the lid margin associated with marked oedema





Centurion  
UNIVERSITY

Shaping Lives...  
Empowering Communities...

# CONTINUE...

**2. Stage of abscess formation is** *characterised by a visible pus point on the lid margin in relation to the affected cilia.*

- Usually there is one sty, but occasionally, these may be multiple.



**Centurion**  
**UNIVERSITY**

*Shaping Lives...  
Empowering Communities...*

# Hordeolum externum (stye) upper eyelid





Centurion  
UNIVERSITY

Shaping Lives...  
Empowering Communities...

# Treatment

1. **Hot compresses** 2-3 times a day are very useful in cellulitis stage. When the pus point is formed it may be evacuated by epilating the involved cilia.
2. **Surgical incision** is required rarely for a large abscess.
3. **Antibiotic eyedrops** (3-4 times a day) and **eye ointment** (at bed time) should be applied to control infection



Centurion  
UNIVERSITY

Shaping Lives...  
Empowering Communities...

# CONTINUE...

4. **Anti-inflammatory and analgesics** relieve pain and reduce oedema.

5. **Systemic antibiotics** may be used for early control of infection.

*In recurrent styes, try to find out and treat the associated predisposing condition*



**Centurion**  
**UNIVERSITY**

*Shaping Lives...*  
*Empowering Communities...*

# CHALAZION





Centurion  
UNIVERSITY

Shaping Lives...  
Empowering Communities...

# INTRODUCTION

- It is also called a *tarsal or meibomian cyst*.
- *It is a chronic non-infective **granulomatous inflammation** of the meibomian gland.*



Centurion  
UNIVERSITY

Shaping Lives...  
Empowering Communities...

# Etiology

1. ***Predisposing factors are similar to hordeolum externum.***
- ***2. Pathogenesis.*** Usually, first there occurs mild grade infection of the meibomian gland by organisms of very low virulence there occurs proliferation of the epithelium and infiltration of the walls of the ducts, which are blocked.



Centurion  
UNIVERSITY

Shaping Lives...  
Empowering Communities...

# CONTINUE...

- Consequently, there occurs retention of **secretions (sebum) in the gland**, causing its enlargement.
- The **pent-up secretions** (fatty in nature) act like an irritant and **excite non-infective granulomatous inflammation** of the meibomian gland.



**Centurion**  
**UNIVERSITY**

*Shaping Lives...  
Empowering Communities...*

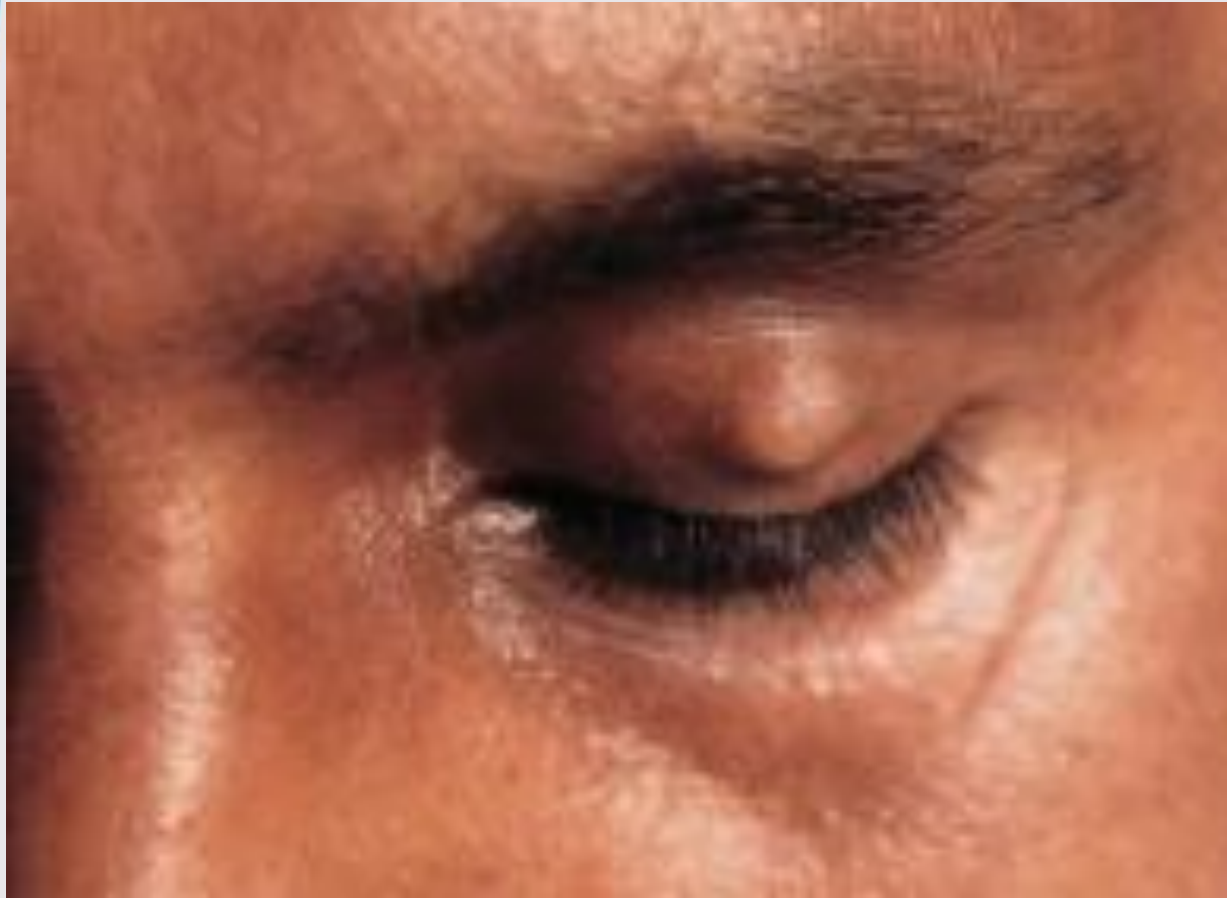# Clinical picture

- Patients usually present with a painless swelling in the lid and a feeling of mild heaviness.
- Examination usually reveals small, firm to hard, non-tender swelling present slightly away from the lid margin



**Centurion**  
**UNIVERSITY**  
*Shaping Lives...  
Empowering Communities...*

# Chalazion upper eye lid





Centurion  
UNIVERSITY

*Shaping Lives...  
Empowering Communities...*

# CONTINUE...

- It usually points on the conjunctival side, as a red, purple or grey area, seen on everting the lid.
- Rarely, the main bulk of the swelling project on the skin side.
- Occasionally, it may present as a reddish-grey nodule on the intermarginal strip (marginal chalazion).
- Frequently, multiple chalazia may be seen involving one or more eyelids.





Centurion  
UNIVERSITY

Shaping Lives...  
Empowering Communities...

# Clinical course and complications

- Complete *spontaneous resolution* may occur rarely.
- Often it slowly *increases in size and becomes* very large.
- A large chalazion of the upper lid may press on the cornea and cause blurred vision from induced astigmatism.
- Occasionally, it may burst on the conjunctival side, forming a fungating mass of granulation tissue.



Centurion  
UNIVERSITY

Shaping Lives...  
Empowering Communities...

# Continue...

- *Secondary infection leads to formation of hordeolum internum.*
- *Calcification may occur, though very rarely.*
- *Malignant change into meibomian gland carcinoma may be seen occasionally in elderly people.*



Centurion  
UNIVERSITY

Shaping Lives...  
Empowering Communities...

# Treatment

- **Conservative treatment.** *In a small, soft and recent chalazion, self-resolution may be helped by conservative treatment in the form of hot fomentation, topical antibiotic eyedrops and oral anti-inflammatory drugs.*



Centurion  
UNIVERSITY

Shaping Lives...  
Empowering Communities...

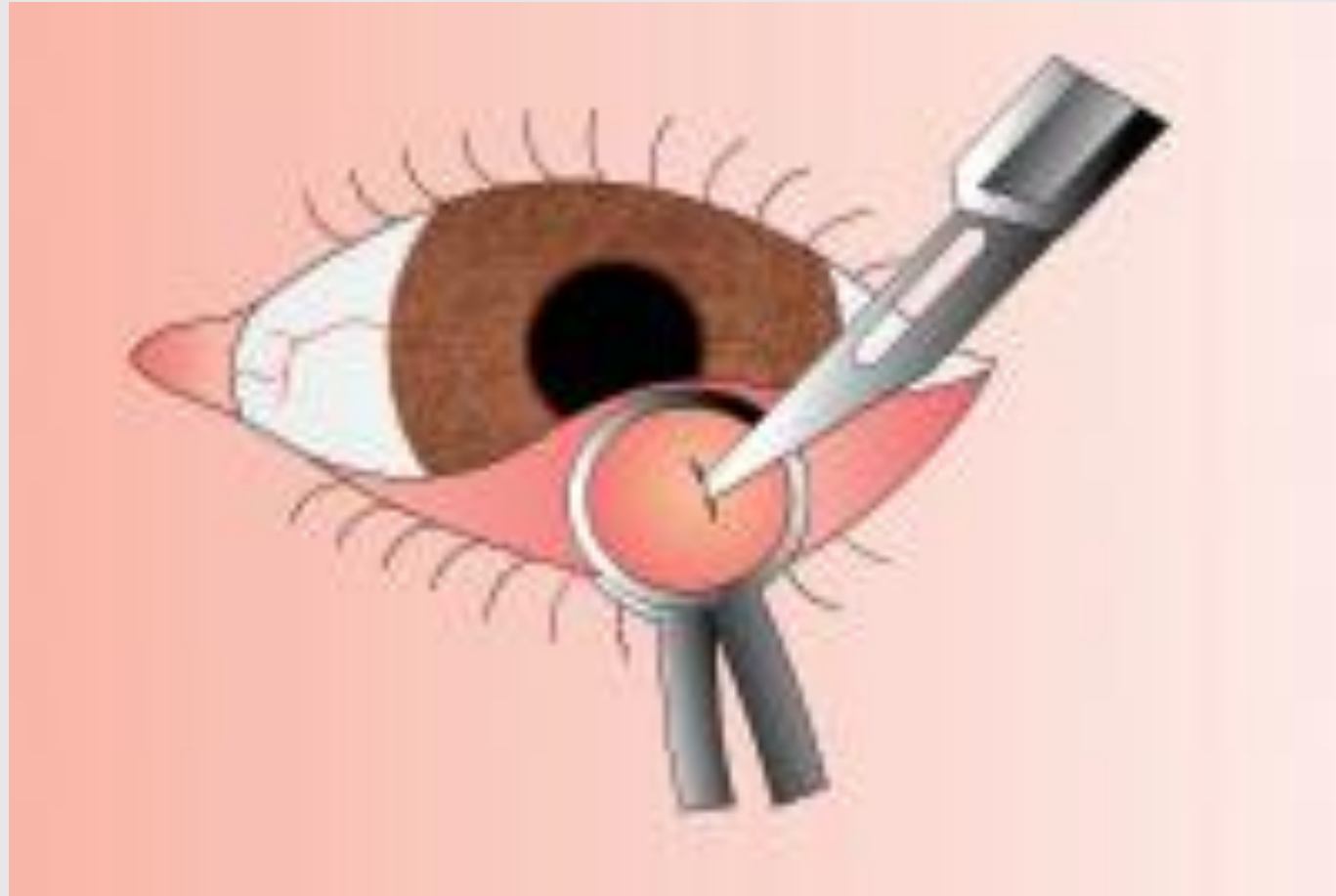## Continue...

- **Intralesional injection** of long-acting steroid (triamcinolone) is reported to cause resolution in about 50 percent cases, especially in small and soft chalazia.
- **Incision and curettage** is the conventional and effective treatment for chalazion.
- Surface anaesthesia is obtained by instillation of xylocaine drops in the eye and the lid in the region of the chalazion is infiltrated with 2 percent xylocaine solution.



**Centurion**  
**UNIVERSITY**  
*Shaping Lives...  
Empowering Communities...*

# Incision and curettage of chalazion from the conjunctival side





**Centurion**  
**UNIVERSITY**

*Shaping Lives...  
Empowering Communities...*

# Continue...

- An incision is made with a sharp blade, which should be vertical on the conjunctival side (to avoid injury to other meibomian ducts) and horizontal on skin side (to have an invisible scar).
- To avoid recurrence, its cavity should be cauterised with carbolic acid.
- An antibiotic ointment is instilled and eye padded for about 12 hours.





**Centurion**  
**UNIVERSITY**

*Shaping Lives...  
Empowering Communities...*

# Continue...

- To decrease postoperative discomfort and prevent infection,
- antibiotic eyedrops, hot fomentation and oral anti-inflammatory and analgesics may be given for 3-4 days.



**Centurion**  
**UNIVERSITY**

*Shaping Lives...*  
*Empowering Communities...*

# INTERNAL HORDEOLUM



Centurion  
UNIVERSITY

Shaping Lives...  
Empowering Communities...

# Introduction

- It is a suppurative inflammation of the meibomian gland associated with blockage of the duct.

## **Etiology:**

- It may occur as primary staphylococcal infection of the meibomian gland or due to secondary infection in a chalazion (infected chalazion).



Centurion  
UNIVERSITY

Shaping Lives...  
Empowering Communities...

## ***Clinical picture***

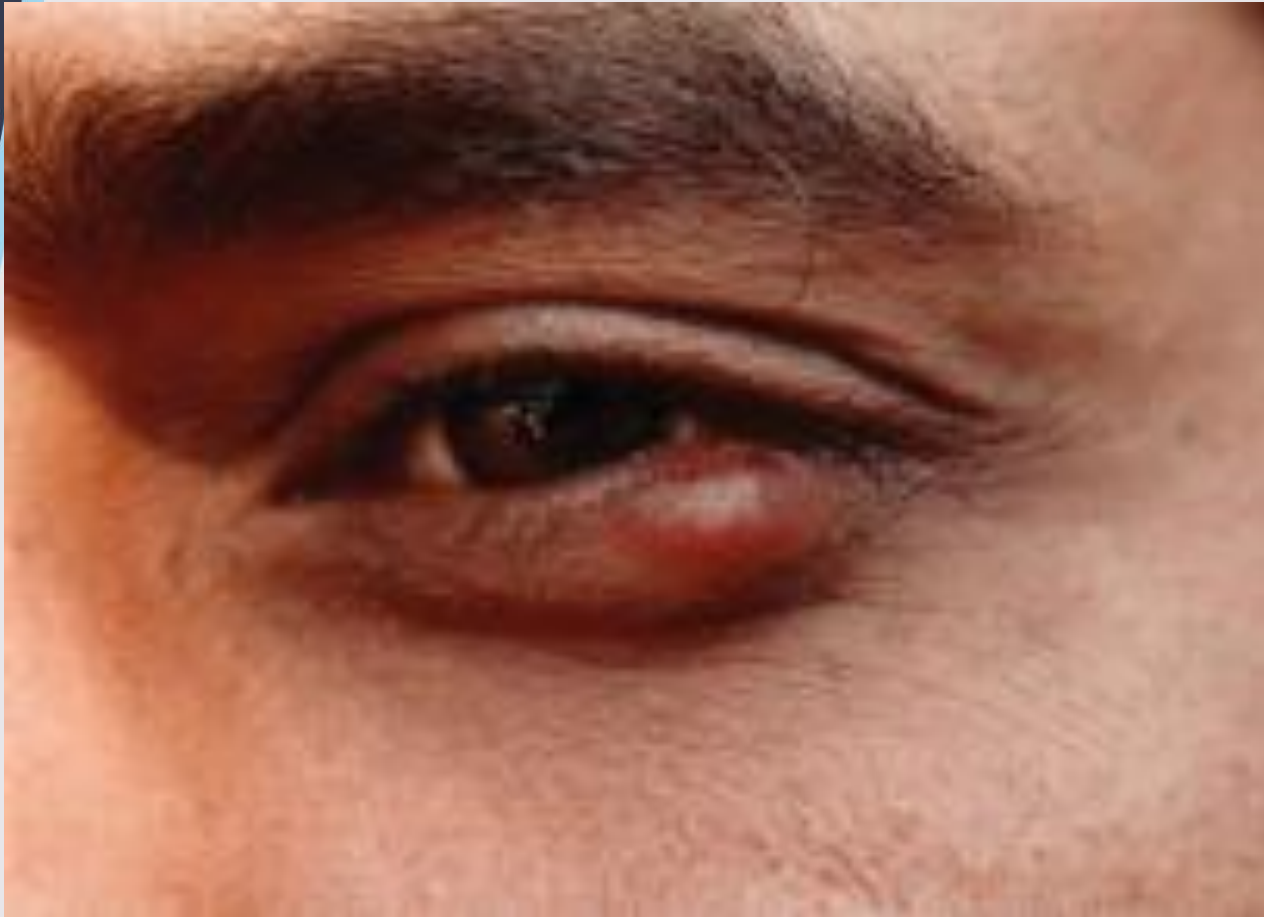- Symptoms are similar to hordeolum externum, except that pain is more intense, due to the swelling being embedded deeply in the dense fibrous tissue.
- On examination, it can be differentiated from hordeolum externum by the fact that in it, the point of maximum tenderness and swelling is away from the lid margin and that pus usually points on the tarsal conjunctiva (seen as yellowish area on everting the lid) and not on the root of cilia



**Centurion**  
**UNIVERSITY**

*Shaping Lives...  
Empowering Communities...*

# Hordrolum internum lower eyelid.





**Centurion**  
**UNIVERSITY**

*Shaping Lives...  
Empowering Communities...*

# ***Treatment***

- The skin lesions should be incised and the interior cauterised with tincture of iodine or pure carbolic acid.





**Centurion**  
**UNIVERSITY**

*Shaping Lives...*  
*Empowering Communities...*

# **MOLLUSCUM CONTAGIOSUM**



**Centurion**  
**UNIVERSITY**

Shaping Lives...  
Empowering Communities...

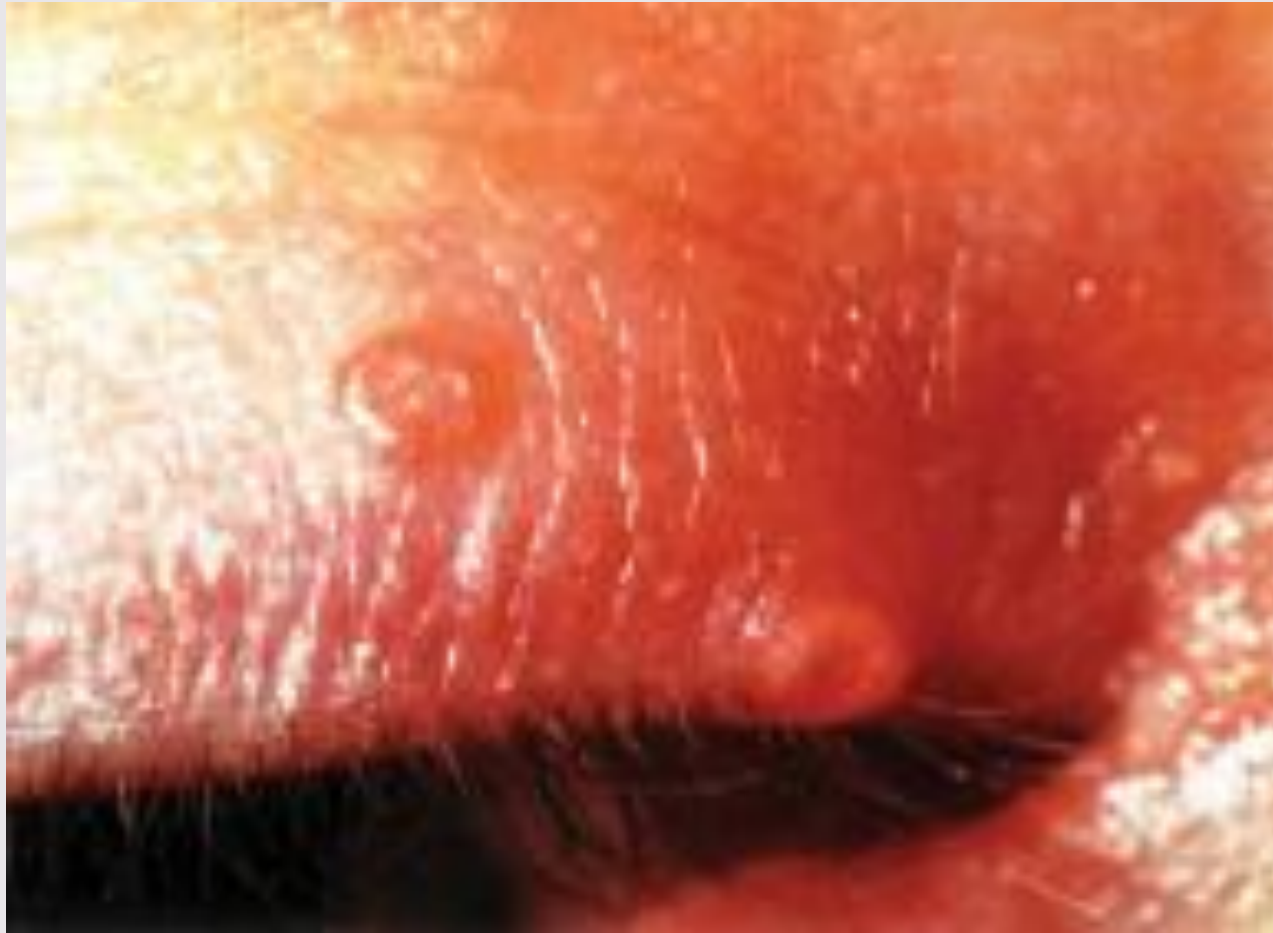# Introduction

- It is a viral infection of the lids, commonly affecting children.
- It is caused by a large poxvirus. Its typical lesions are multiple, pale, waxy, umbilicated swellings scattered over the skin near the lid margin.
- These may be *complicated by chronic follicular* conjunctivitis and superficial keratitis.
- These may be *complicated by chronic follicular* conjunctivitis and superficial keratitis.



**Centurion**  
**UNIVERSITY**  
*Shaping Lives...  
Empowering Communities...*

# Molluscum contagiosum of the lids





**Centurion**  
**UNIVERSITY**

*Shaping Lives...  
Empowering Communities...*

# ***Treatment***

- The skin lesions should be incised and the interior cauterised with tincture of iodine or pure carbolic acid.



**Centurion**  
**UNIVERSITY**

*Shaping Lives...*  
*Empowering Communities...*

# SYMBLEPHARON



**Centurion**  
**UNIVERSITY**

*Shaping Lives...  
Empowering Communities...*

# Introduction

- In this condition lids become adherent with the eyeball as a result of adhesions between the palpebral and bulbar conjunctiva.





**Centurion**  
**UNIVERSITY**

*Shaping Lives...  
Empowering Communities...*

# Etiology

- It results from healing of the kissing raw surfaces upon the palpebral and bulbar conjunctiva.
- Its common causes are thermal or chemical burns, membranous conjunctivitis, injuries, conjunctival ulcerations, ocular pemphigus and Stevens-Johnson syndrome.



**Centurion**  
**UNIVERSITY**

Shaping Lives...  
Empowering Communities...

# Clinical picture

- It is characterised by difficulty in lid movements, diplopia (due to restricted ocular motility), inability to close the lids (lagophthalmos) and cosmetic disfigurement.
- Fibrous adhesions between palpebral conjunctiva and the bulbar conjunctiva and/or cornea may be present only in the anterior part (*anterior symblepharon*), or *fornix* (*posterior symblepharon*) or the whole lid (*total symblepharon*).



**Centurion**  
**UNIVERSITY**

*Shaping Lives...  
Empowering Communities...*

# Complications

- These include dryness, thickening and keratinisation of conjunctiva due to prolonged exposure and corneal ulceration (exposure keratitis).



Centurion  
UNIVERSITY

Shaping Lives...  
Empowering Communities...

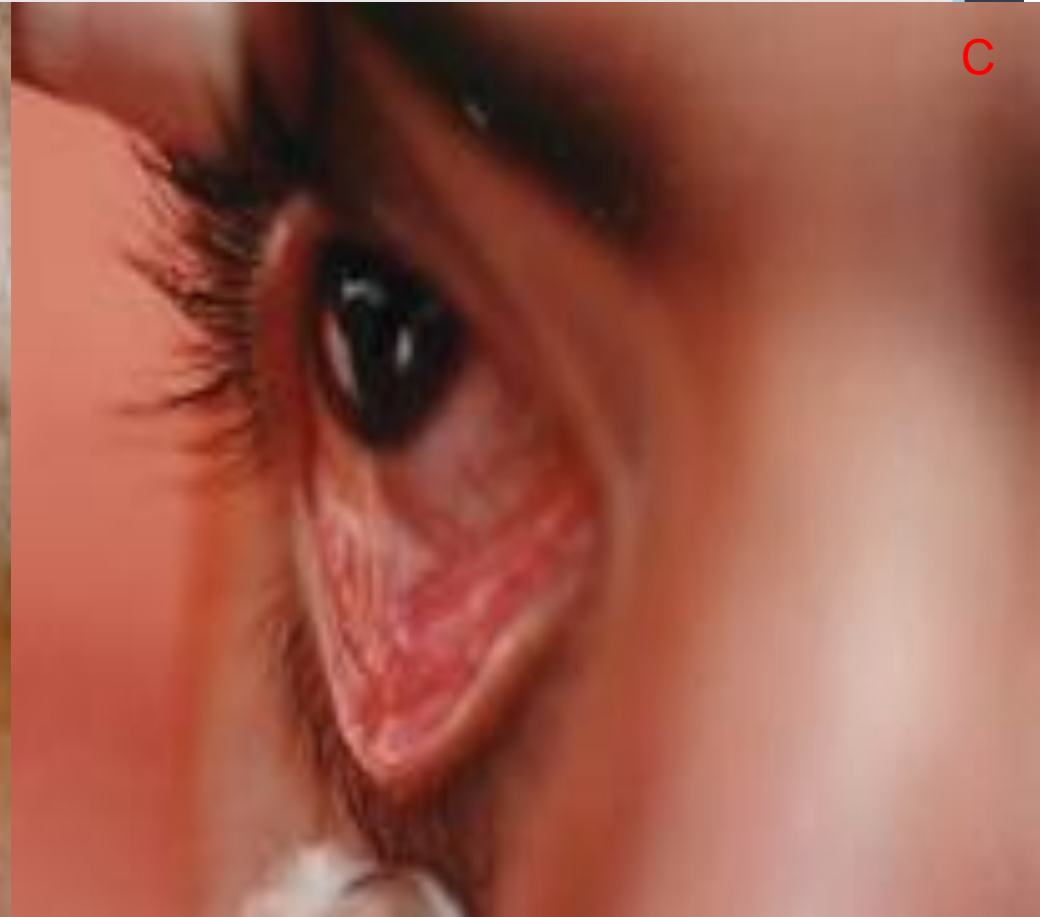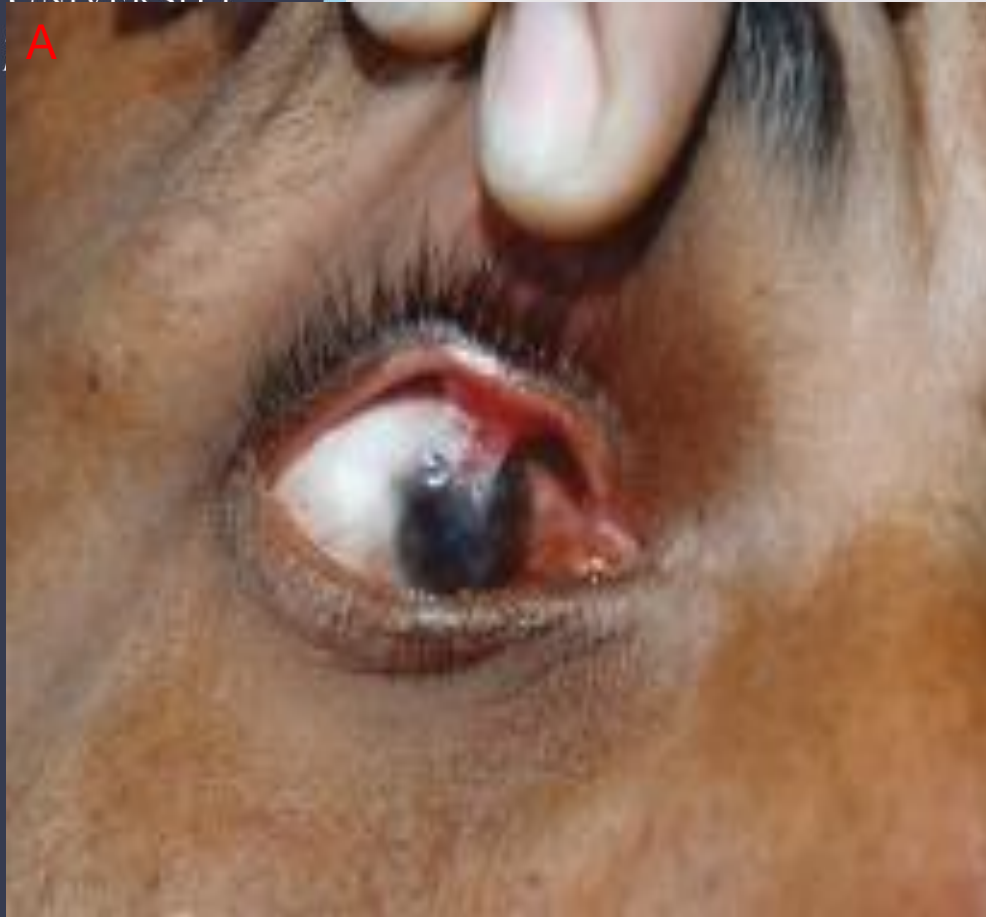# Treatment

1. **Prophylaxis.** *During the stage of raw surfaces, the adhesions may be prevented by sweeping a glass rod coated with lubricant around the fornices several times a day. A large-sized, therapeutic, soft contact lens also helps in preventing the adhesions.*
2. **Curative treatment** *consists of symblepharectomy. The raw area created may be covered by mobilising the surrounding conjunctiva in mild cases. Conjunctival or buccal mucosal graft is required in severe cases.*



Centurion  
UNIVERSITY

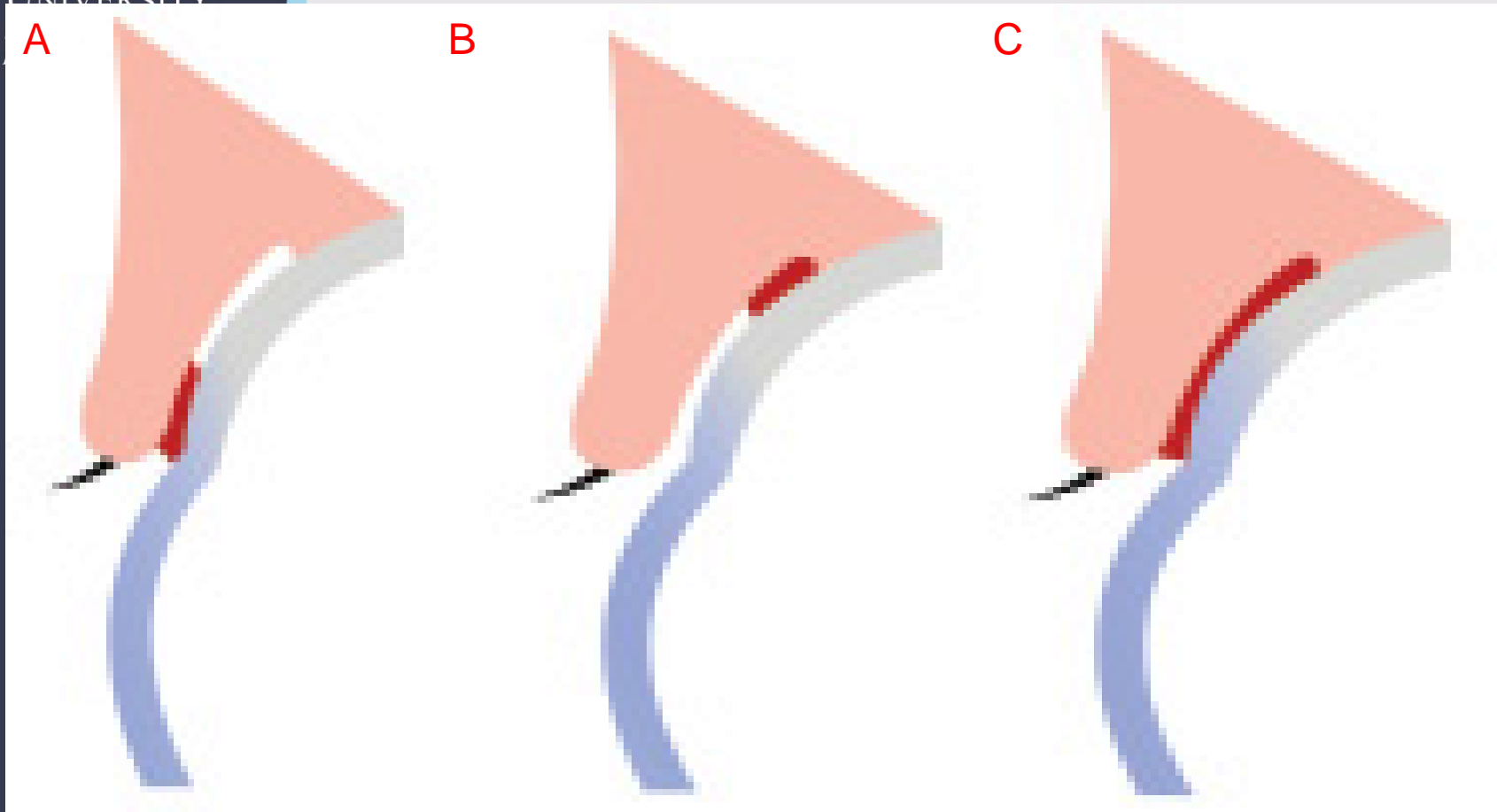
(A) posterior (B) symblepharon.





Centurion  
UNIVERSITY

(A), posterior (B) and total symblepharon (C); Clinical photographs of anterior







**Centurion**  
**UNIVERSITY**

*Shaping Lives...*  
*Empowering Communities...*

# ANKYLOBLEPHARON



**Centurion**  
**UNIVERSITY**

*Shaping Lives...  
Empowering Communities...*

# Introduction

- The adhesions between margins of the upper and lower lids. It may occur as a congenital anomaly or may result after healing of chemical burns, thermal burns, ulcers and traumatic wounds of the lid margins.
- Ankyloblepharon may be complete or incomplete. It is usually associated with symblepharon.



**Centurion**  
**UNIVERSITY**

*Shaping Lives...  
Empowering Communities...*

# ***Treatment***

- Lids should be separated by excision of adhesions between the lid margins and kept apart during healing process.
- When adhesions extend to the angles, epithelial grafts should be given to prevent recurrences.



**Centurion**  
**UNIVERSITY**

*Shaping Lives...*  
*Empowering Communities...*

# LAGOPHTHALMOS



Centurion  
UNIVERSITY  
Shaping Lives...  
Empowering Communities...

# Introduction

- This condition is characterised by inability to voluntarily close the eyelids.
- **Etiology:**
  - It occurs in patients with
    - ✓ paralysis of orbicularis oculi muscle,
    - ✓ cicatricial contraction of the lids,
    - ✓ symblepharon, severe ectropion,
    - ✓ Proptosis
    - ✓ Physiologically some people sleep with their eyes open (nocturnal lagophthalmos)



Centurion  
UNIVERSITY

Shaping Lives...  
Empowering Communities...

# ***Clinical picture***

- It is characterised by incomplete closure of the palpebral aperture associated with features of the causative disease.
- **Complications:**  
*Include conjunctival and corneal xerosis and exposure keratitis.*





**Centurion**  
**UNIVERSITY**

*Shaping Lives...  
Empowering Communities...*

# ***Treatment***

- To prevent exposure keratitis artificial tear drops should be instilled frequently and the open palpebral fissure should be filled with an antibiotic eye ointment during sleep and in comatosed patients.
- Soft bandage contact lens may be used to prevent exposure keratitis.



**Centurion**  
**UNIVERSITY**

*Shaping Lives...  
Empowering Communities...*

# Continue...

- *Tarsorrhaphy may be performed to cover the exposed cornea when indicated.*
- Measures should be taken to treat the cause of lagophthalmos, wherever possible.



**Centurion**  
**UNIVERSITY**

*Shaping Lives...  
Empowering Communities...*

- Thank You