



Centurion
UNIVERSITY
Shaping Lives...
Empowering Communities...

OCULAR DISEASE

KERATOPLASTY



Centurion
UNIVERSITY

Shaping Lives...
Empowering Communities...

KERATOPLASTY

- Keratoplasty, also called *corneal grafting* or *corneal transplantation*, is an operation in which the patient's diseased cornea is replaced by the donor's healthy clear cornea.



Centurion
UNIVERSITY

*Shaping Lives...
Empowering Communities...*

Types

- 1. Penetrating keratoplasty (full-thickness grafting)
- 2. Lamellar keratoplasty (partial-thickness grafting).



Centurion
UNIVERSITY
*Shaping Lives...
Empowering Communities...*

Indications

1. **Optical, i.e., to improve vision.**
Important indications are: corneal opacity, bullous keratopathy, corneal dystrophies, advanced keratoconus.
2. **Therapeutic, i.e., to replace inflamed cornea not responding to conventional therapy.**
3. **Tectonic graft, i.e., to restore integrity of eyeball e.g. after corneal perforation and in marked corneal thinning.**
4. **Cosmetic, i.e., to improve the appearance of the eye.**



Centurion
UNIVERSITY

*Shaping Lives...
Empowering Communities...*

Donor tissue

- The donor eye should be removed as early as possible (within 6 hours of death).
- It should be stored under sterile conditions.



Centurion
UNIVERSITY
*Shaping Lives...
Empowering Communities...*

Evaluation of donor cornea.

- Biomicroscopic examination of the whole globe, before processing the tissue for media storage, is very important.
- The donor corneal tissue is graded into excellent, very good, good, fair, and poor depending upon the condition of corneal epithelium, stroma, Descemet's membrane and endothelium



Centurion
UNIVERSITY

Grading of donor cornea on slit-lamp

Parameter	Grade of donor corneal tissue				
	Grade I (Excellent)	Grade II (Very good)	Grade III (Good)	Grade IV (Fair)	Grade V (Poor)
Epithelial defects and haze	None	Slight epithelial haze or defects	Obvious moderate epithelial defects		
Corneal stromal clarity	Crystal clear	Clear	Slight cloudiness	Moderate cloudiness	Marked cloudiness
Arcus senilis	None	Slight	Moderate (<2.5mm)	Heavy (>2.5mm-4mm)	Very heavy (>4 mm)
Descemet's membrane	No folds	Few shallow folds	Numerous shallow folds	Numerous deep folds	Marked deep folds
Endothelium	No defect	No defect	Few vacuolated cells	Moderate guttate	Marked guttate



Centurion
UNIVERSITY

Shaping Lives...
Empowering Communities...

Methods of corneal preservation

1. *Short-term storage (up to 48 hours).*
The whole globe is preserved at 4°C in a moist chamber.
2. *Intermediate storage (up to 2 weeks) of donor cornea can be done in McCarey-Kaufman (MK) medium and various chondroitin sulfate enriched media such as optisol medium.*
3. *Long-term storage up to 35 days is done by organ culture method.*



Centurion
UNIVERSITY

Shaping Lives...
Empowering Communities...

Surgical technique

1. *Excision of donor corneal button.* The donor corneal button should be cut 0.25 mm larger than the recipient.
- 2. *Excision of recipient corneal button.* With the help of a corneal trephine (7.5 mm to 8 mm in size) a partial thickness incision is made in the host cornea anterior chamber is entered with the help of a razor blade knife and excision is completed using corneo-scleral scissors



Centurion
UNIVERSITY

Shaping Lives...
Empowering Communities...

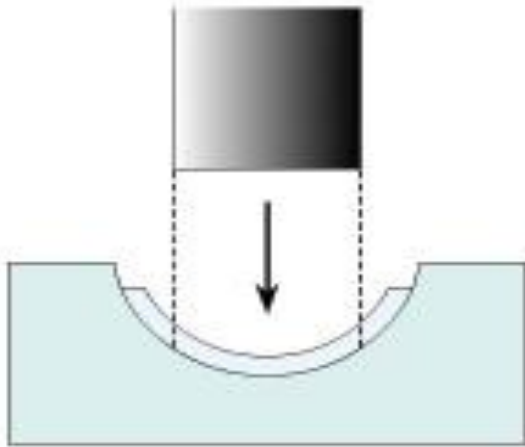
CONTINIUE...

3. *Suturing of corneal graft into the host bed* is done with either continuous or interrupted 10-0 nylon sutures.

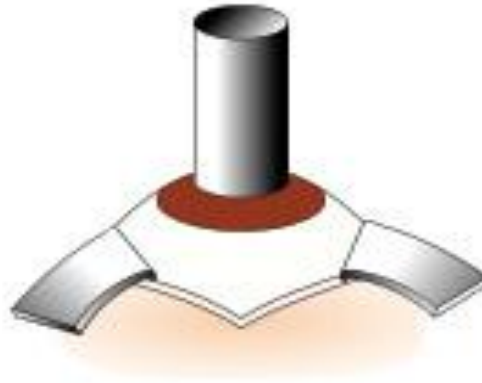


Centurion
UNIVERSITY

Technique of keratoplasty : **A**, excision of donor corneal button; **B & C**, excision of recipient corneal button; **D**, suturing of donor button into recipient's bed; **E**, showing pattern of continuous sutures in keratoplasty; **F**, Clinical photograph of a patient with interrupted sutures in keratoplasty.



A



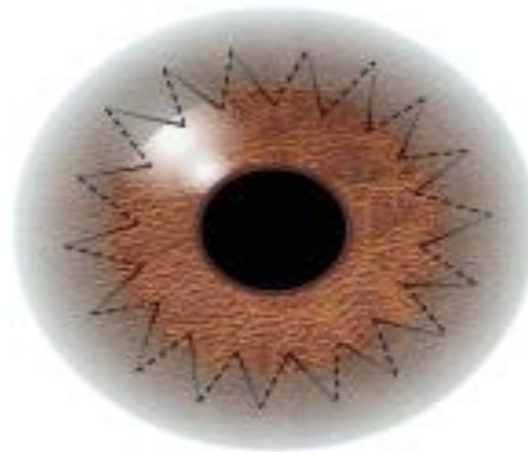
B



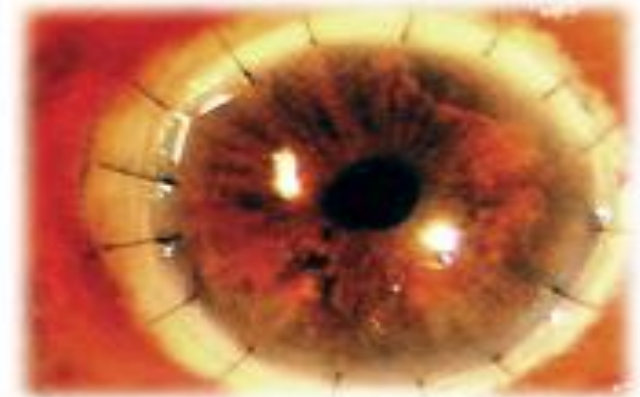C



D



E



F



Centurion
UNIVERSITY

Shaping Lives...
Empowering Communities...

Complications

1. ***Early complications.*** *These include flat anterior chamber, iris prolapse, infection, secondary glaucoma, epithelial defects and primary graft failure.*
2. ***Late complications.*** *These include graft rejection, recurrence of disease and astigmatism.*