



**Centurion**  
**UNIVERSITY**  
*Shaping Lives...*  
*Empowering Communities...*

# OCULAR DISEASE

## Keratoconus



**Centurion**  
**UNIVERSITY**

*Shaping Lives...  
Empowering Communities...*

# *Introduction*

- Keratoconus (KC) is a progressive disorder in which central or paracentral corneal stromal thinning occurs, accompanied by apical protrusion and irregular astigmatism.
- Approximately 50% of normal fellow eyes will progress to KC within 16 years.
- Both eyes are affected eventually, at least on topographical imaging, in almost all cases.



**Centurion**  
**UNIVERSITY**

*Shaping Lives...  
Empowering Communities...*

# Keratometry Grading

- It can be graded by the highest axis of corneal power on keratometry
- Mild (<48 D)
- Moderate (48–54 D)
- Severe (>54 D).



**Centurion**  
**UNIVERSITY**  
*Shaping Lives...  
Empowering Communities...*

- Presentation is commonly during the teens or twenties, with features initially in only one eye. Systemic associations include Down,
    - Ehlers–Danlos
    - Marfan syndromes
    - Osteogenesis imperfecta;
- Ocular associations include
- vernal keratoconjunctivitis, blue sclera, aniridia, Leber congenital amaurosis, retinitis pigmentosa, persistent eye rubbing



**Centurion**  
**UNIVERSITY**

*Shaping Lives...  
Empowering Communities...*

# ***Diagnosis-Symptoms***

- Unilateral impairment of vision due to
- progressive myopia and astigmatism; occasionally, initial presentation is with acute hydrops

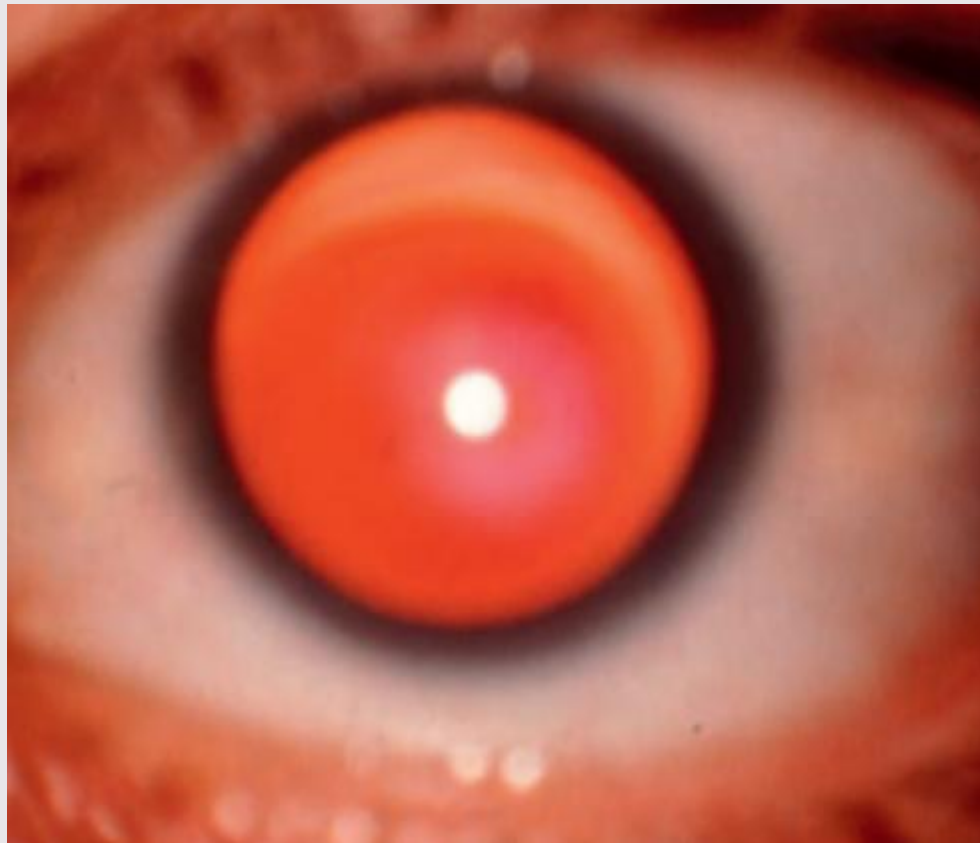

Centurion  
UNIVERSITY

Shaping Lives...  
Empowering Communities...

# Signs

- Direct ophthalmoscopy from a distance of half a metre shows a fairly well delineated **'oil droplet' reflex**



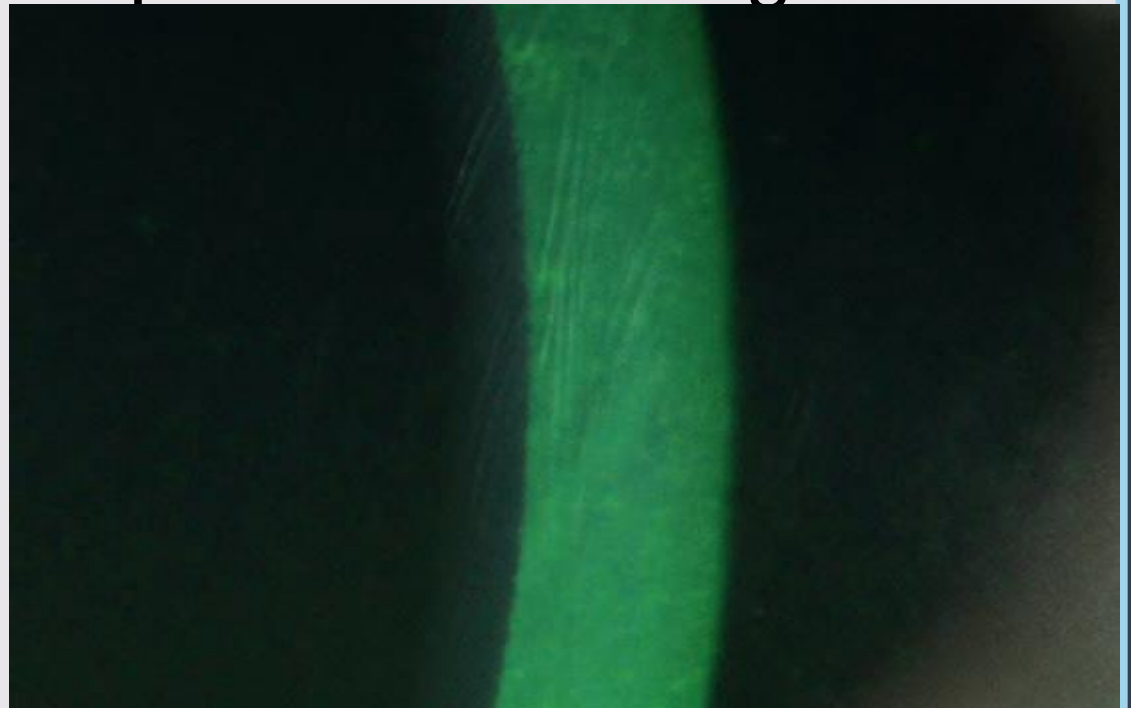


**Centurion**  
**UNIVERSITY**

*Shaping Lives...  
Empowering Communities...*

# Continue...

- Retinoscopy shows an irregular 'scissoring' reflex.
- Slit lamp biomicroscopy shows very fine, vertical, deep stromal stress lines, which disappear with pressure on the globe.



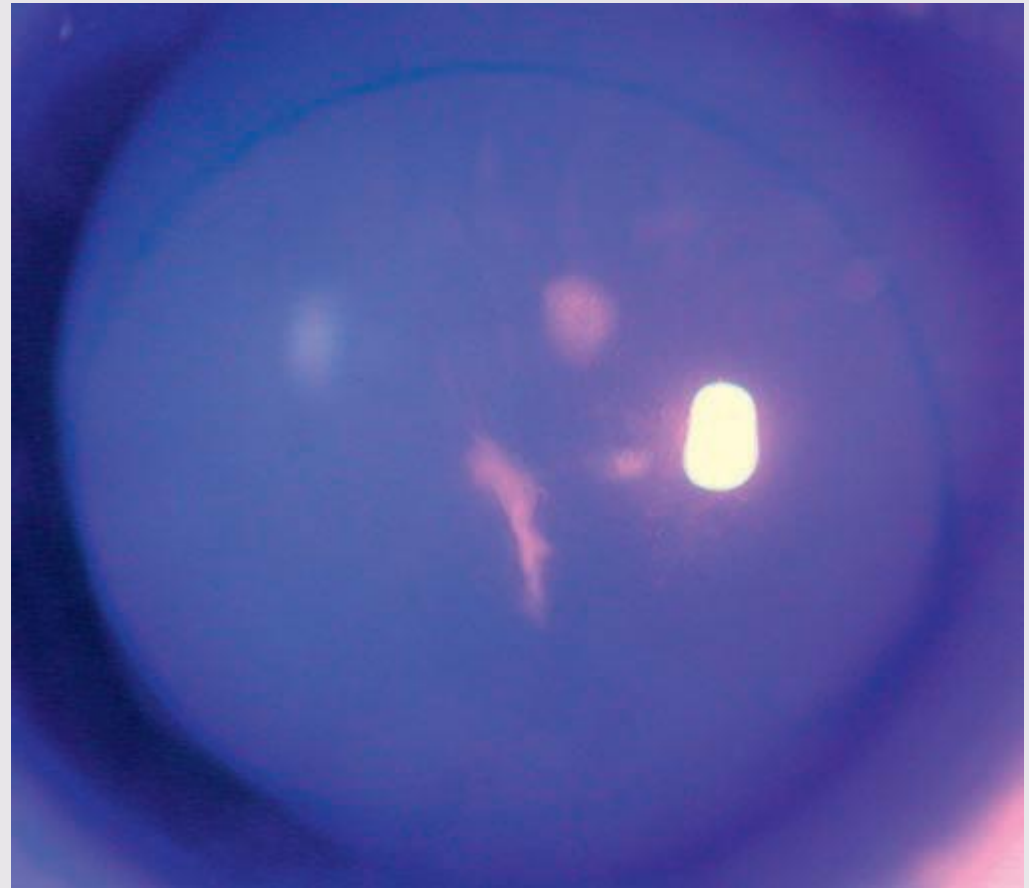


**Centurion**  
**UNIVERSITY**

*Shaping Lives...  
Empowering Communities...*

# Continue...

- Epithelial iron deposits, best seen with a cobalt blue filter, may surround the base of the cone





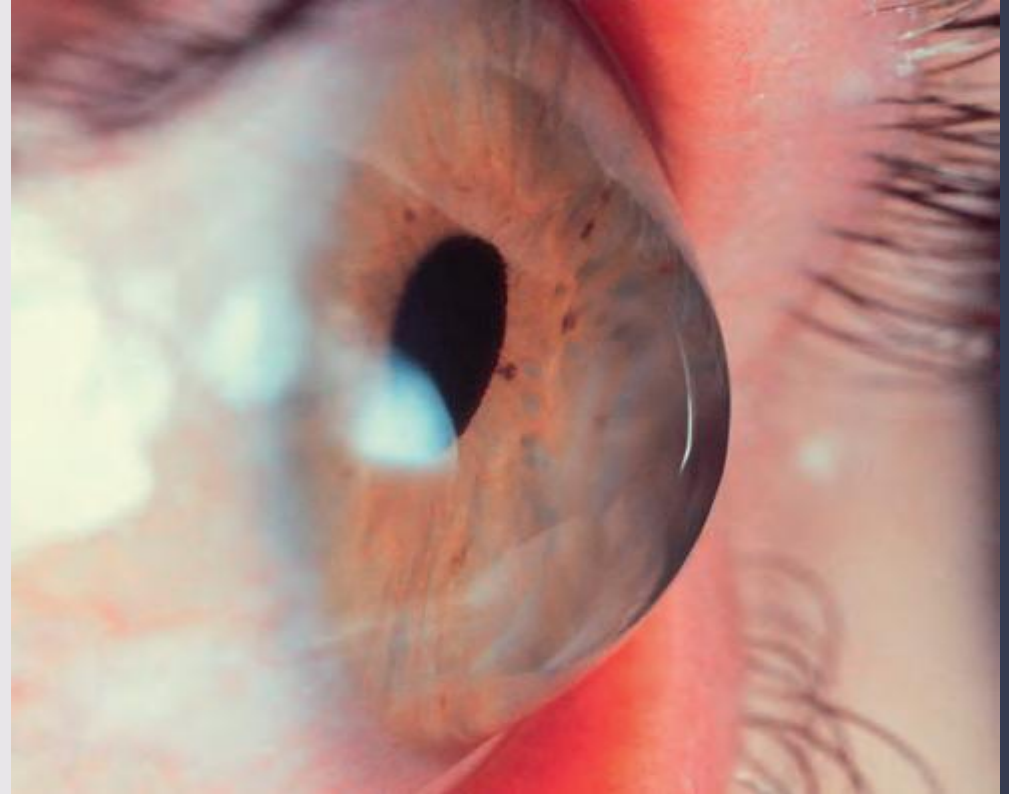

**Centurion**  
**UNIVERSITY**

*Shaping Lives...  
Empowering Communities...*

# Continue...

- Progressive corneal protrusion in a cone configuration, with thinning maximal at the apex.
- Bulging of the lower lid in downgaze (Munson sign).



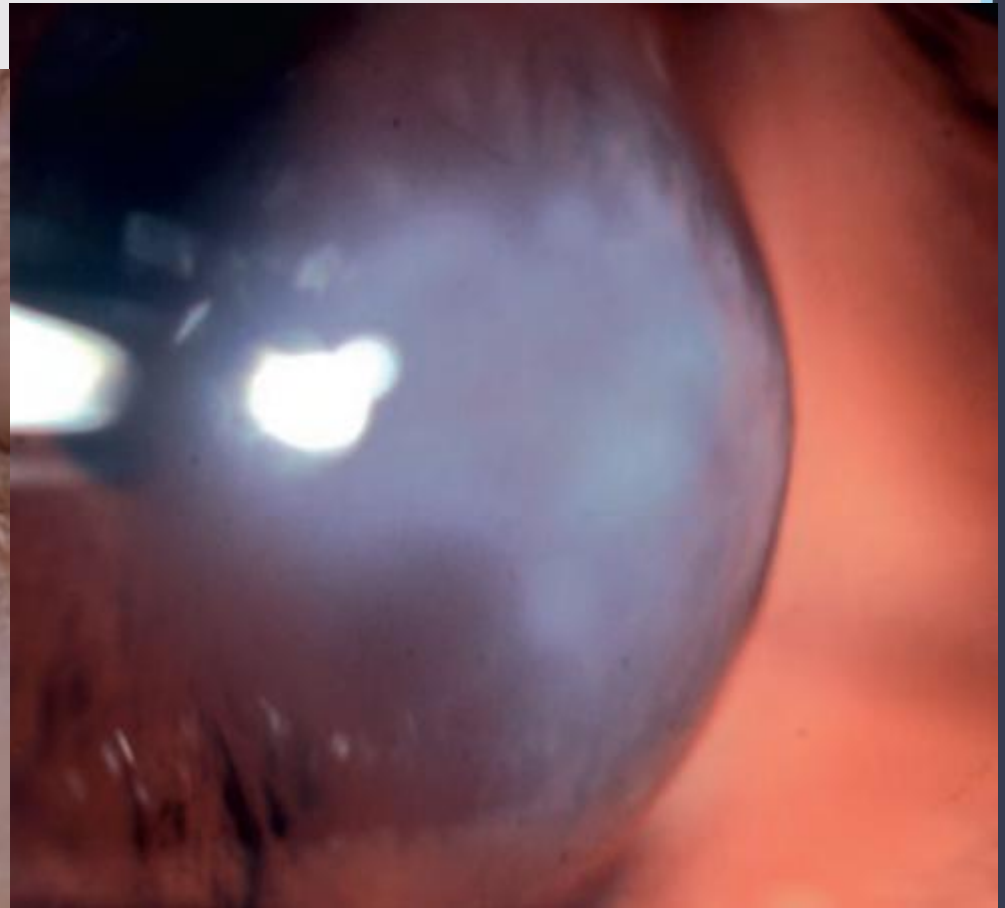
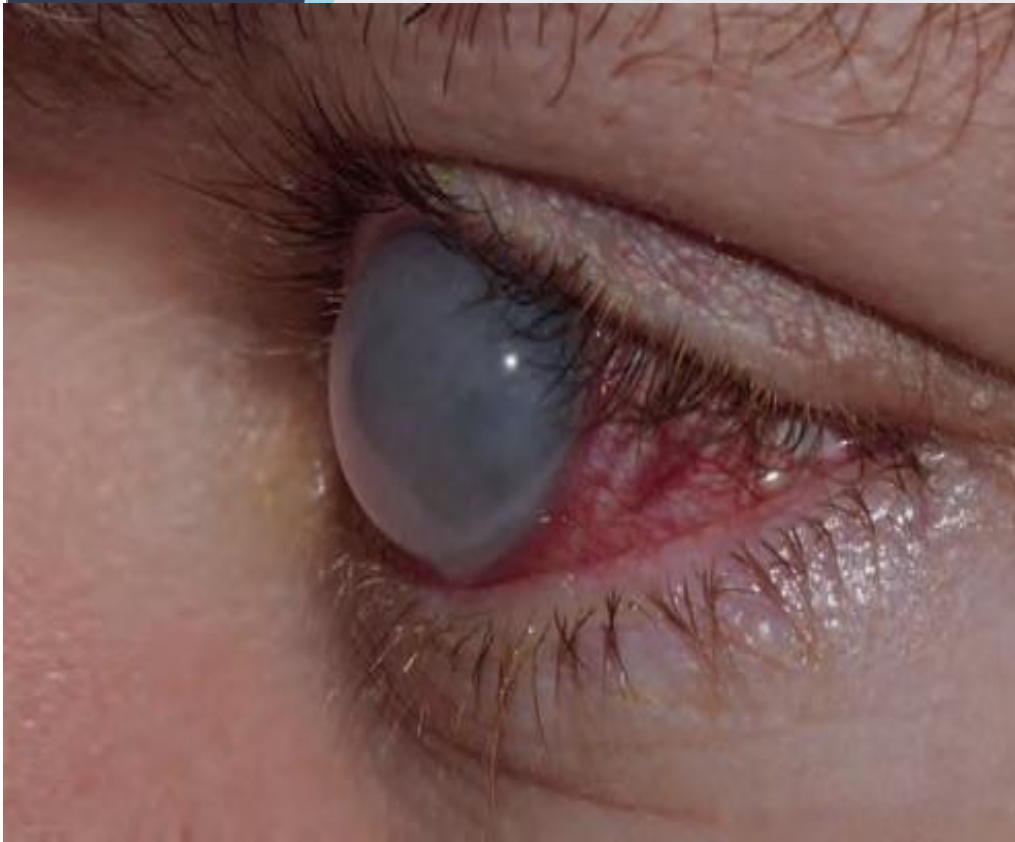

**Centurion**  
**UNIVERSITY**

*Shaping Lives...  
Empowering Communities...*

# Continue...

- Acute hydrops is caused by a rupture in the stretched Descemet membrane that allows a sudden influx of aqueous into the cornea





**Centurion**  
**UNIVERSITY**

*Shaping Lives...  
Empowering Communities...*

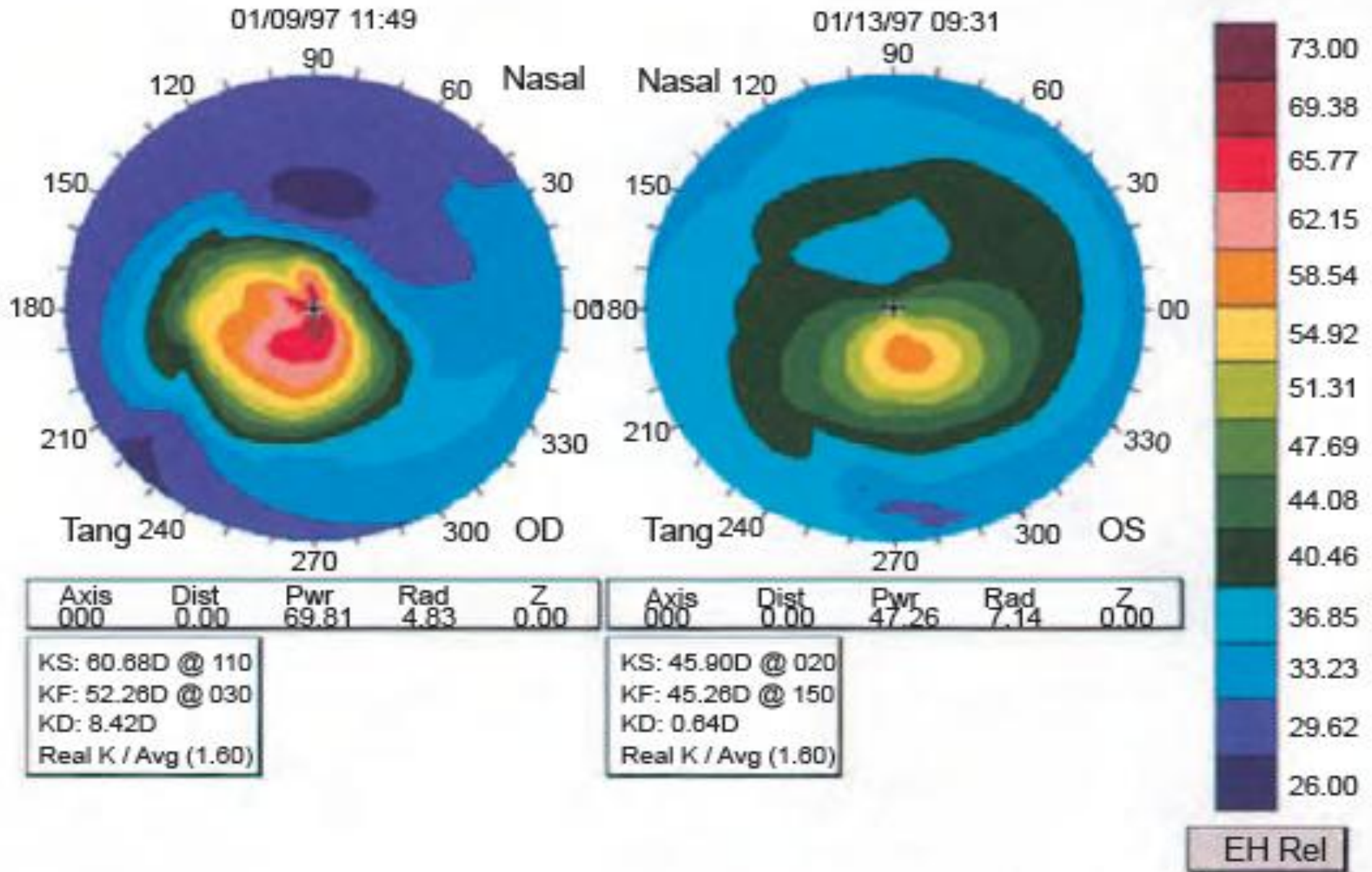
# Continue...

- **Keratometry** readings are steep.
- • **Corneal topography** (videokeratography) and various novel corneal profiling techniques are highly sensitive for detection and essential in monitoring.
- Characteristically, astigmatism progresses from a symmetrical bow-tie pattern, through an asymmetrical appearance to an inferotemporally displaced steep-sided cone



Centurion  
UNIVERSITY

# Corneal topography showing severe keratoconus in the right eye and an early paracentral cone in the left





**Centurion**  
**UNIVERSITY**

*Shaping Lives...  
Empowering Communities...*

# ***Treatment***

- **Eye rubbing should be avoided.**
- **Spectacles or soft contact lenses** are generally sufficient in early cases. If thinning is marked, it may be prudent to consider wearing safety spectacles over contact lenses.
- **Rigid contact lenses**, sometimes scleral, are required for higher degrees of astigmatism to provide a regular refracting surface.



**Centurion**  
**UNIVERSITY**

*Shaping Lives...  
Empowering Communities...*

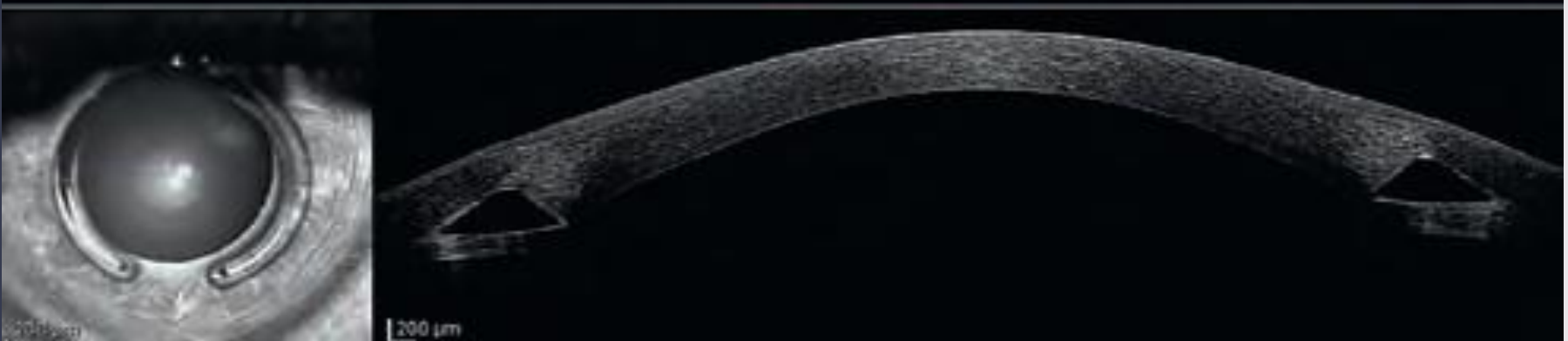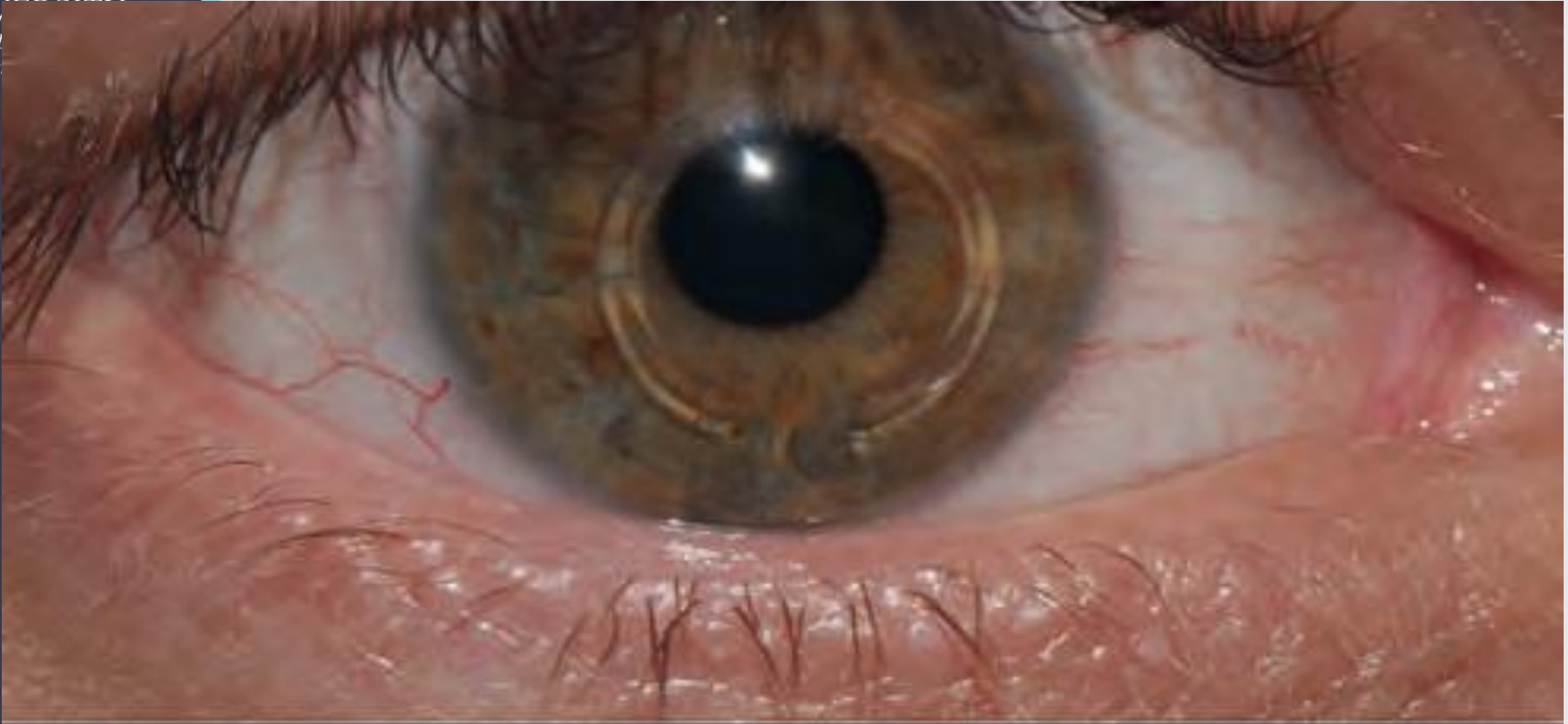
# Continue...

- **Corneal collagen cross-linking (CXL)**, using riboflavin drops to photosensitize the eye followed by exposure to ultraviolet-A light, may stabilize or even reverse ectasia, but is not without adverse effects.
- **Intracorneal ring segment implantation** using laser or mechanical channel creation is relatively safe, and typically provides at least a moderate visual improvement,



Centurion  
UNIVERSITY  
Shaping Lives  
Empowering  
Education

# *Intracorneal ring segments*





**Centurion**  
**UNIVERSITY**

*Shaping Lives...  
Empowering Communities...*

# Continue...

- **Keratoplasty, either penetrating or deep anterior lamellar (DALK), may be necessary in patients with severe disease.**
- A history of hydrops is a contraindication to DALK due to the presence of a Descemet membrane discontinuity.