



**Centurion**  
**UNIVERSITY**

*Shaping Lives...  
Empowering Communities...*

# Centurion university of technology and management

## EYE LID TUMOURS

(Basal Cell Carcinoma, Xanthelasma, Hemangioma, Papillomas)



**Centurion**  
**UNIVERSITY**

*Shaping Lives...  
Empowering Communities...*

# Learning outcome

- Basal cell carcinoma
- Xanthelasma
- Hemangioma
- Papillomas
- Diagnosis, etiology, treatment are included.



**Centurion**  
**UNIVERSITY**

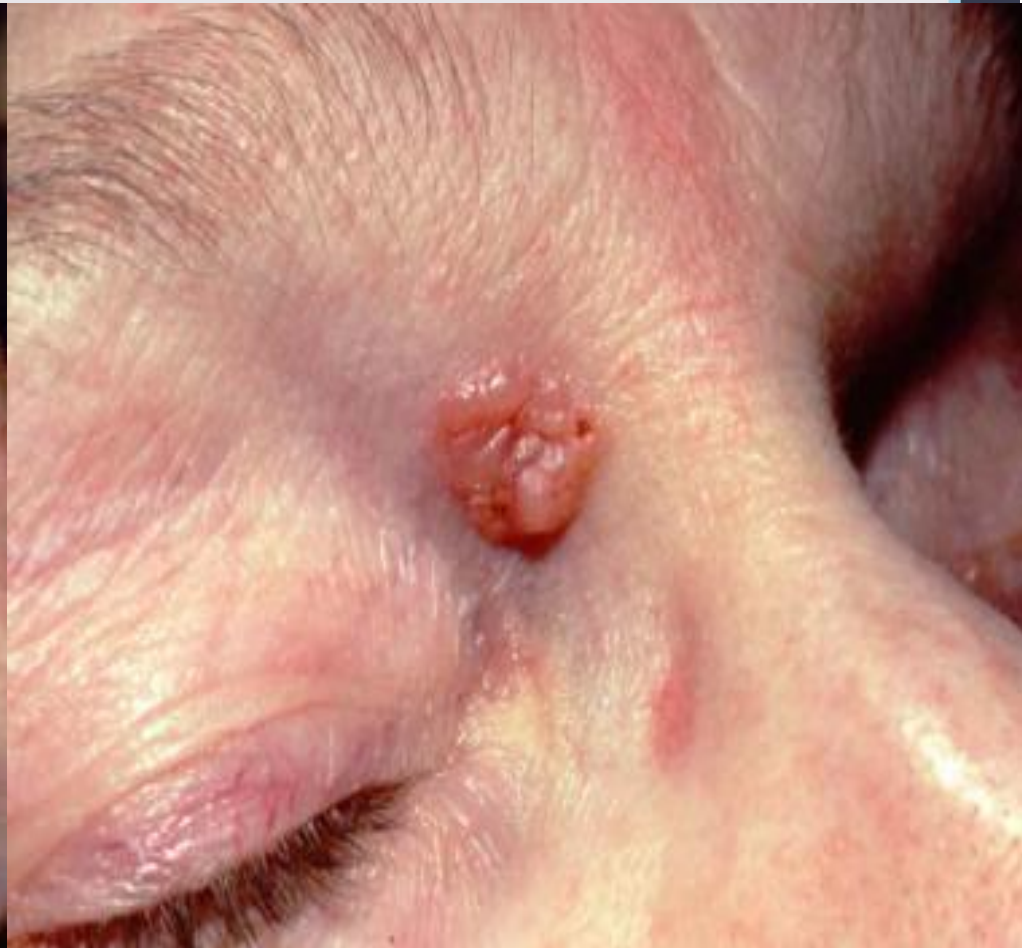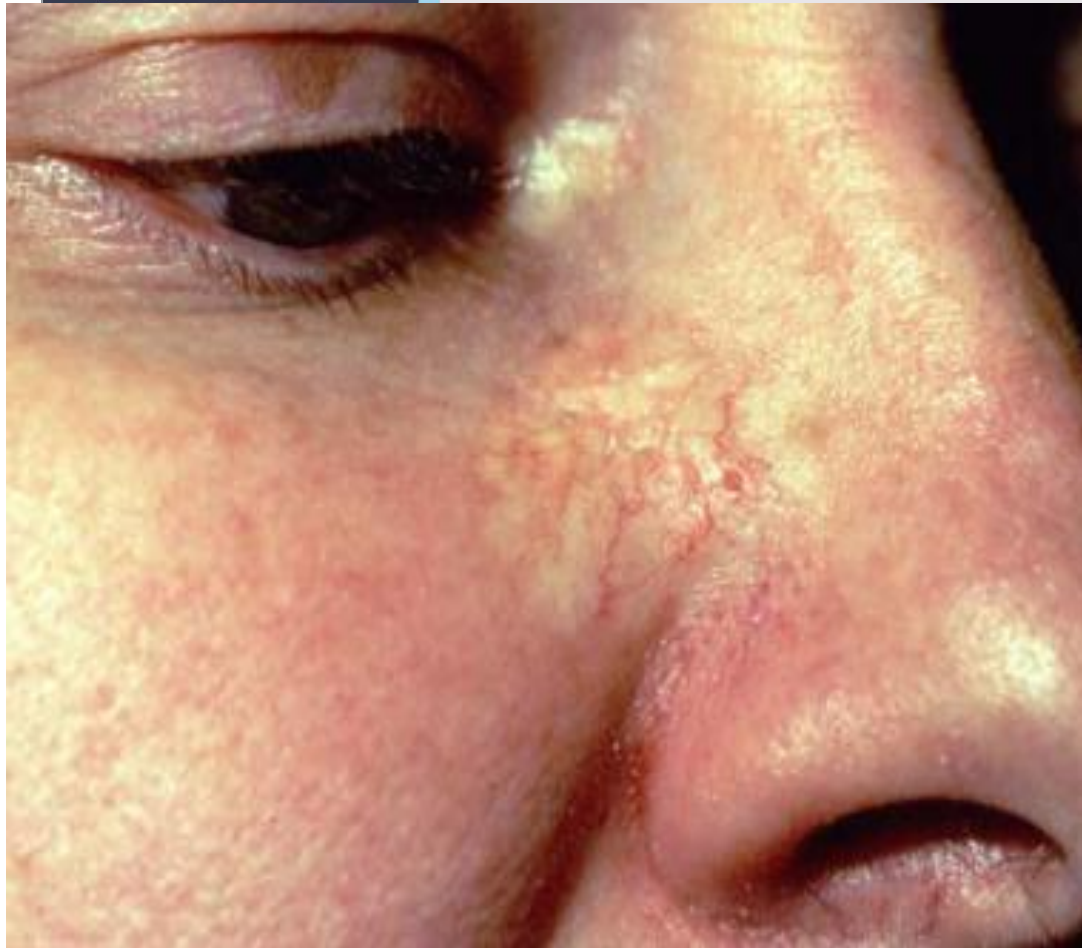*Shaping Lives...  
Empowering Communities...*

# Basal cell carcinoma

- Most common malignant tumour of the eyelid.
- Most frequently affects elderly patients.
- Most frequently arises from the lower lid, specially near the inner canthus.
- It does not metastasize.
- Ulcer spreads very slowly, and the growth extends under the skin in all directions and penetrates deeply.



Centurion



**Basal cell carcinoma**

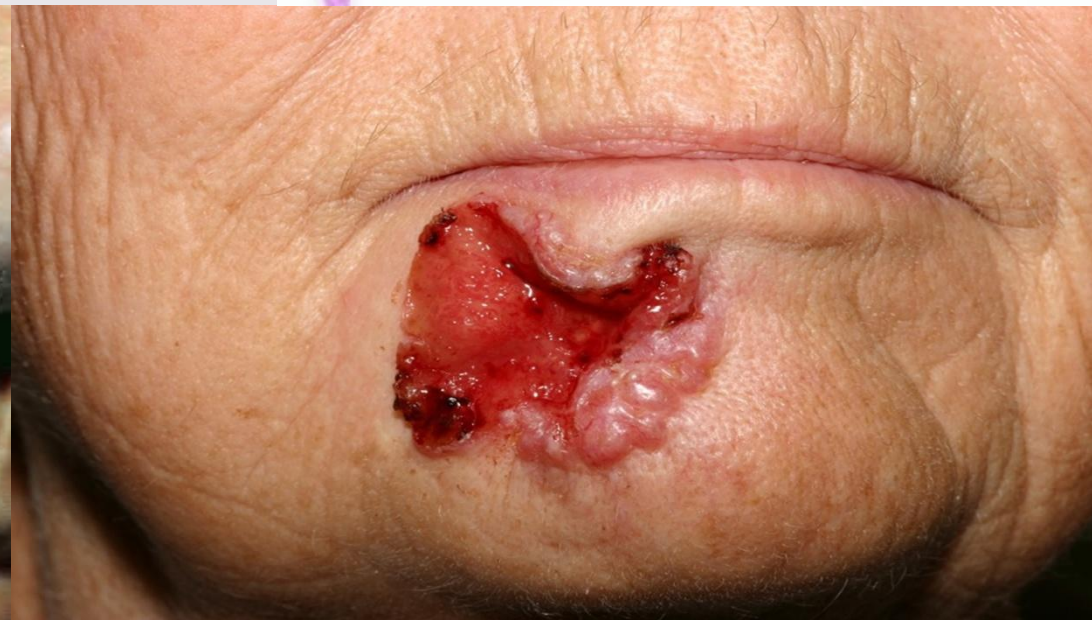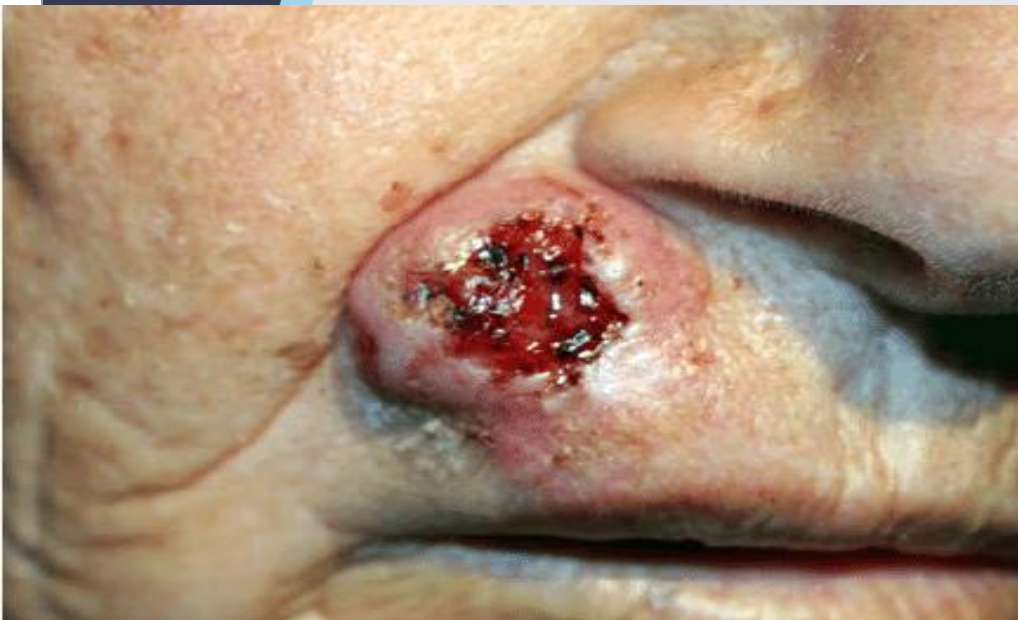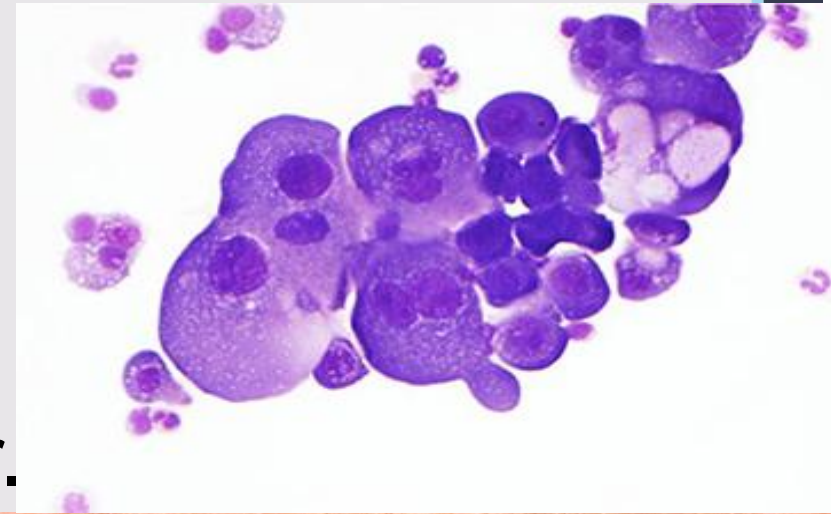


Centurion  
UNIVERSITY

Shaping Lives,  
Empowering Communities...

# CONTINUE...

- The tumor arises from the basal cell of the epidermis.
- Consists of islands of neoplastic cells (cell nests).
- It is also known as Rodent Ulcer.





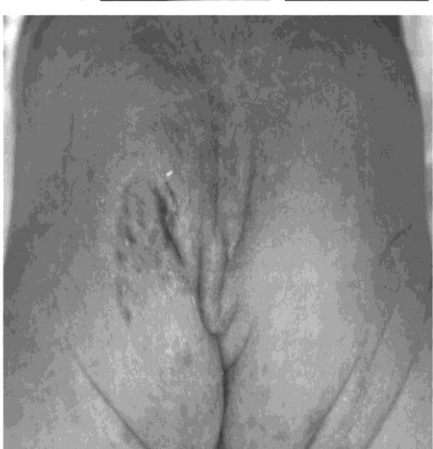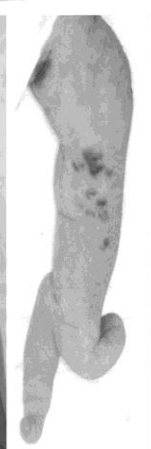
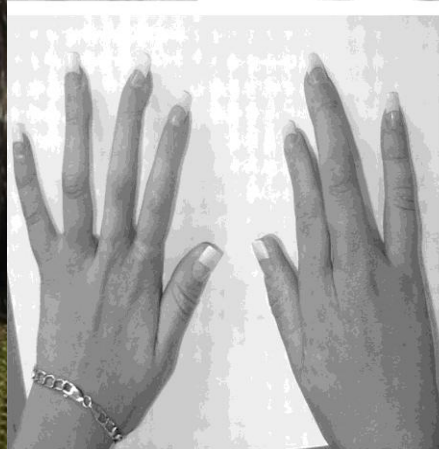
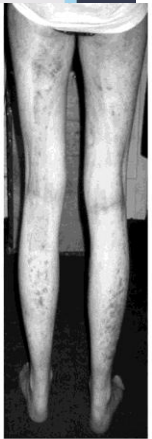
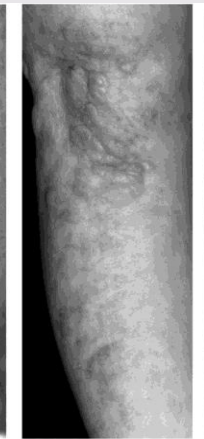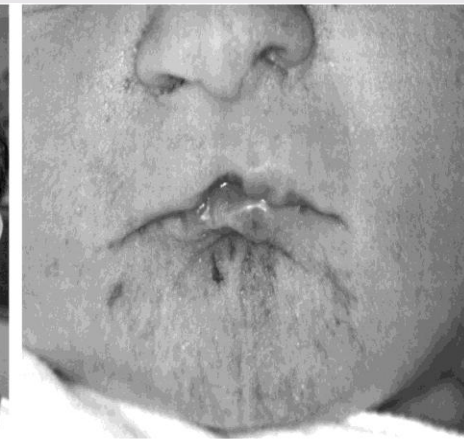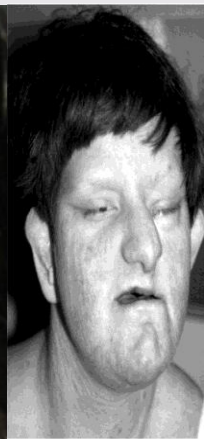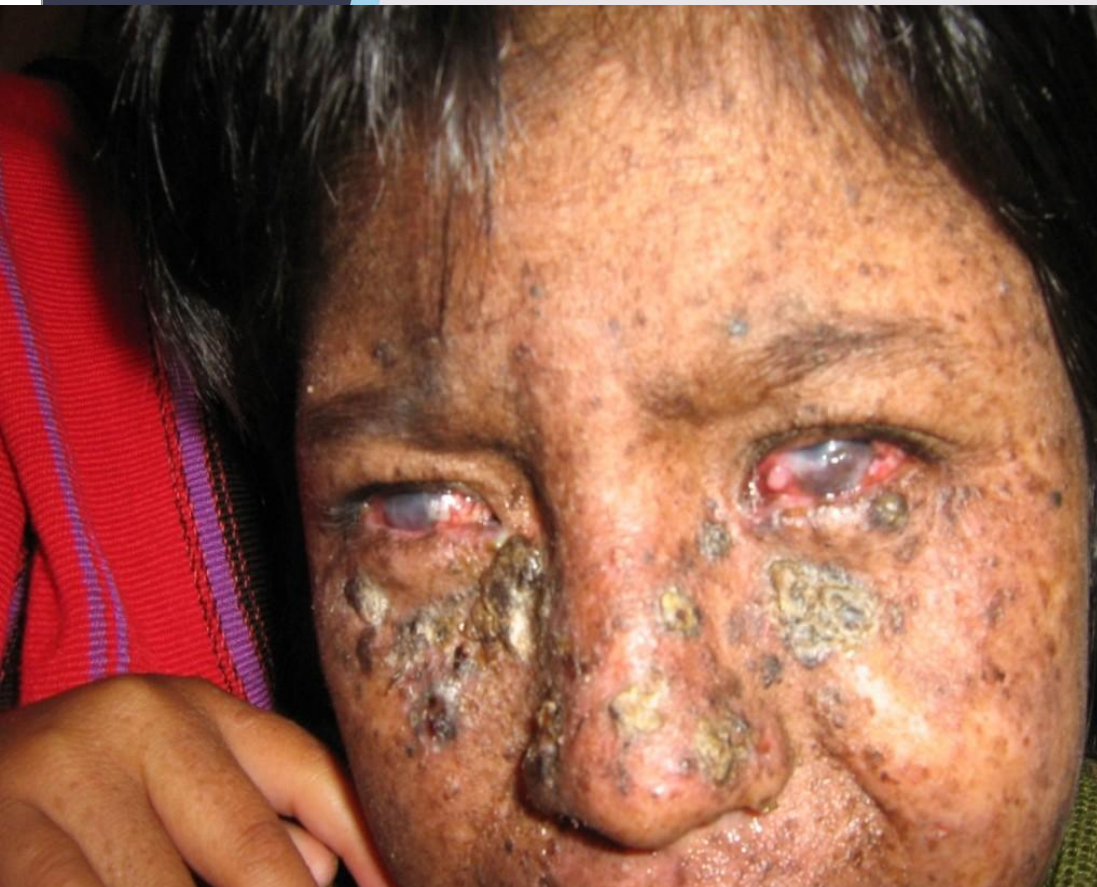Centurion  
UNIVERSITY

Saving Lives  
Empowering Communities...

# Rare predisposing conditions

- Young patients who suffer from one of these conditions can develop BCC.

(A) Xeroderma pigmentosum (B) Gerlin-Goitz syndrome.





Centurion  
UNIVERSITY

*Shaping Lives  
Empowering Communities*

# Treatment

## ❖ Surgical excision.

Where the tumour is removed surgically.

## ❖ Radiotherapy.

## ❖ Cryotherapy, or freezing off the tissue.

## ❖ Excentration, complete surgical removal of the eyeball and other contents of the eye socket, usually in cases of malignant cancer.

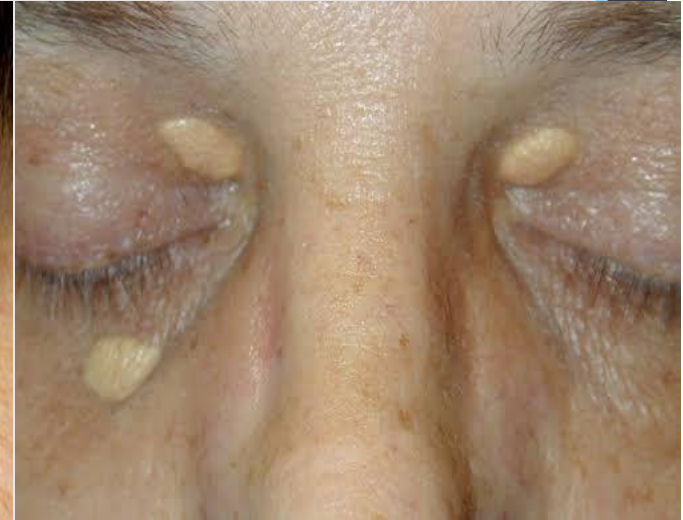
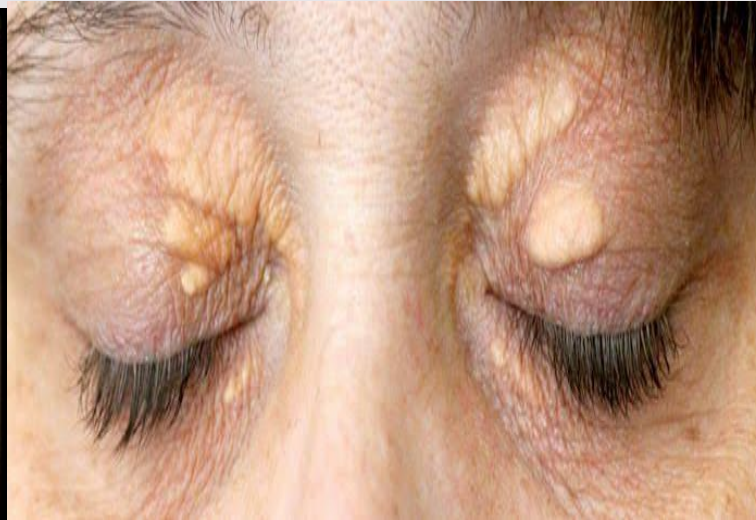
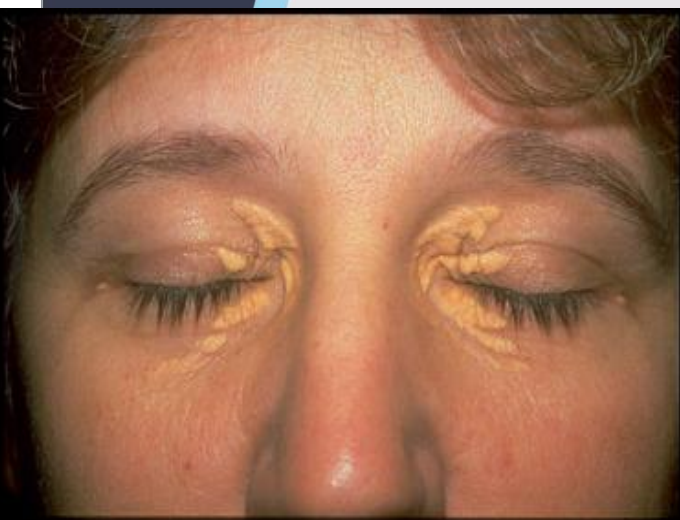Centurion  
UNIVERSITY

Shaping Lives,  
Empowering Communities...

# Xanthelesma

- It is a common, frequently bilateral condition.
- Found in middle-aged and elderly patients with hyperlipidaemia.
- This is slightly raised, yellow plaque, most commonly found in inner portion of the upper or lower eyelid.
- Most commonly in elderly female.





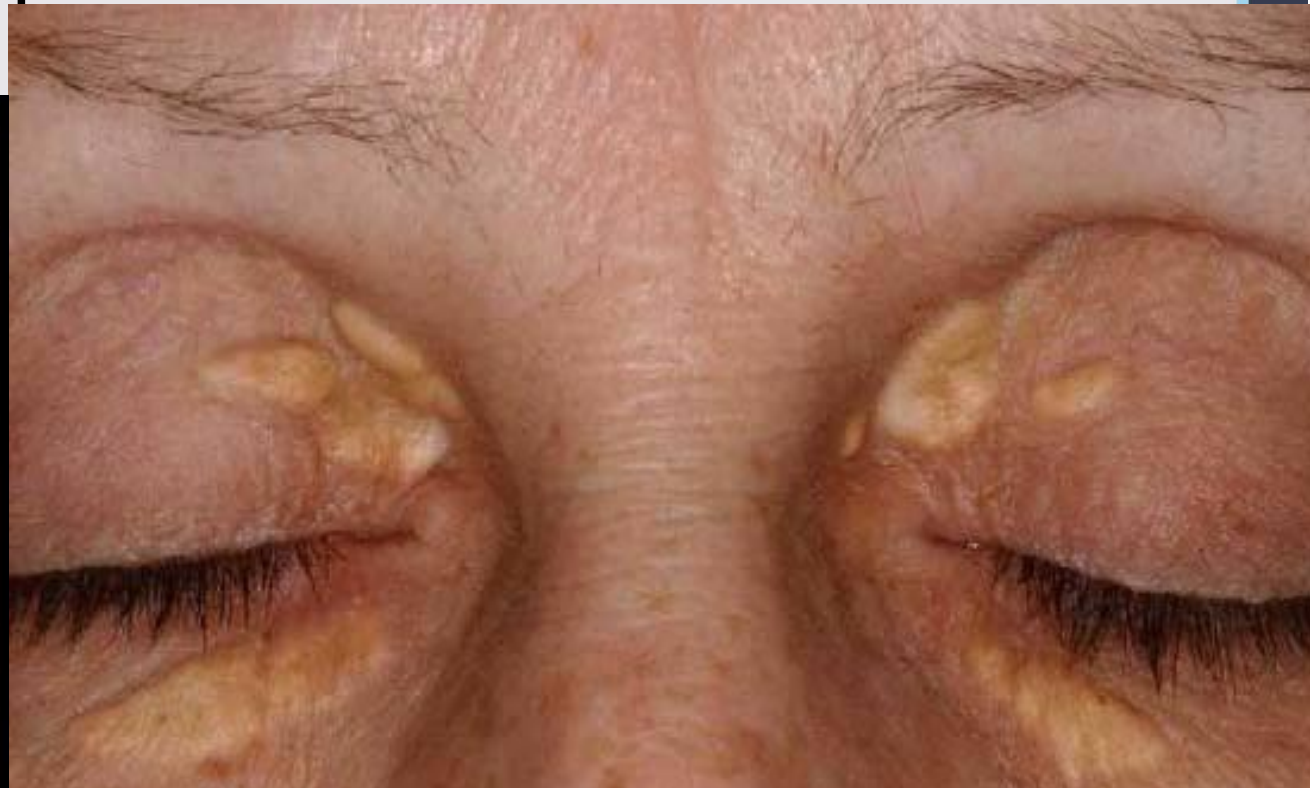
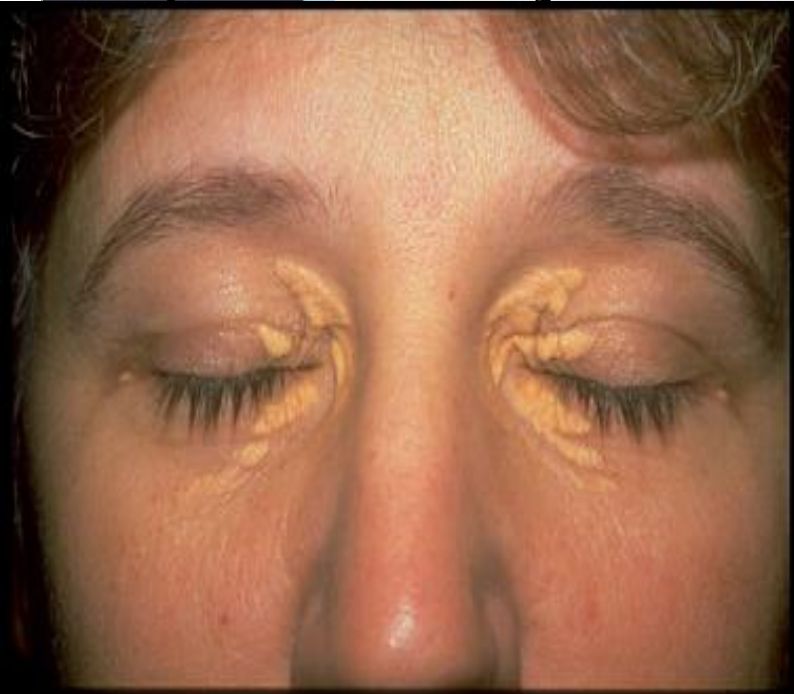
Centurion  
UNIVERSITY

Shaping Lives...  
Empowering Communities...

# CONTINUE...

- They grow slowly, and produce only a cosmetic defect.
- **Signs:** yellowish subcutaneous plaque consisting of cholesterol and lipid which located at the medial aspects of eyelids.



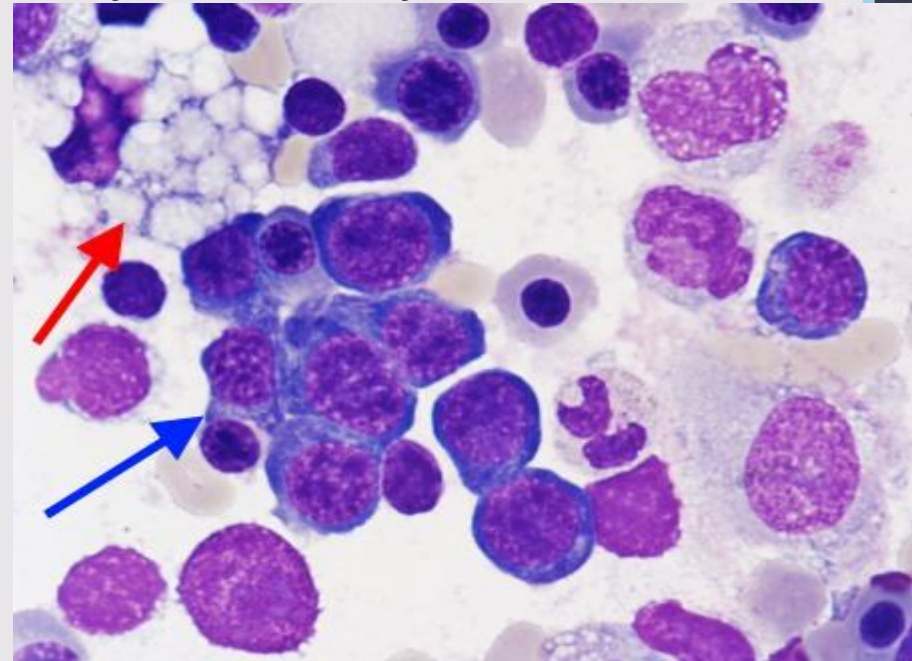
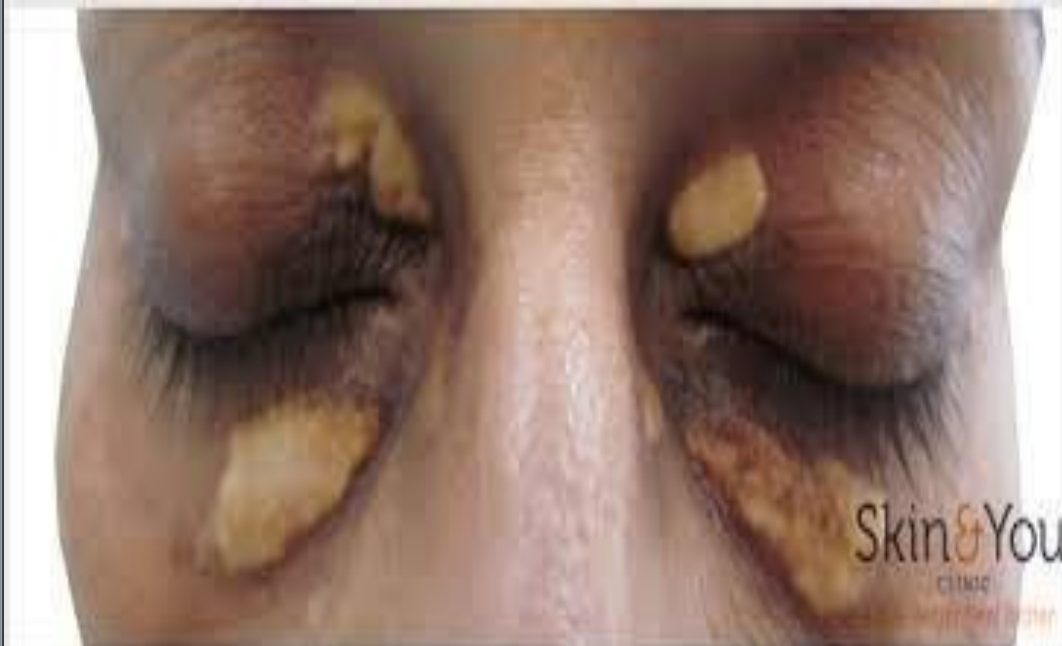

Centurion  
UNIVERSITY

Shining Lives...  
Embracing Communities...

# Predisposing factors

- More commonly, it is spontaneous.
- Associated with diabetes and excess serum cholesterol.
- Histologically, it is the cutaneous deposition of lipid material, being engulfed by histocytes.



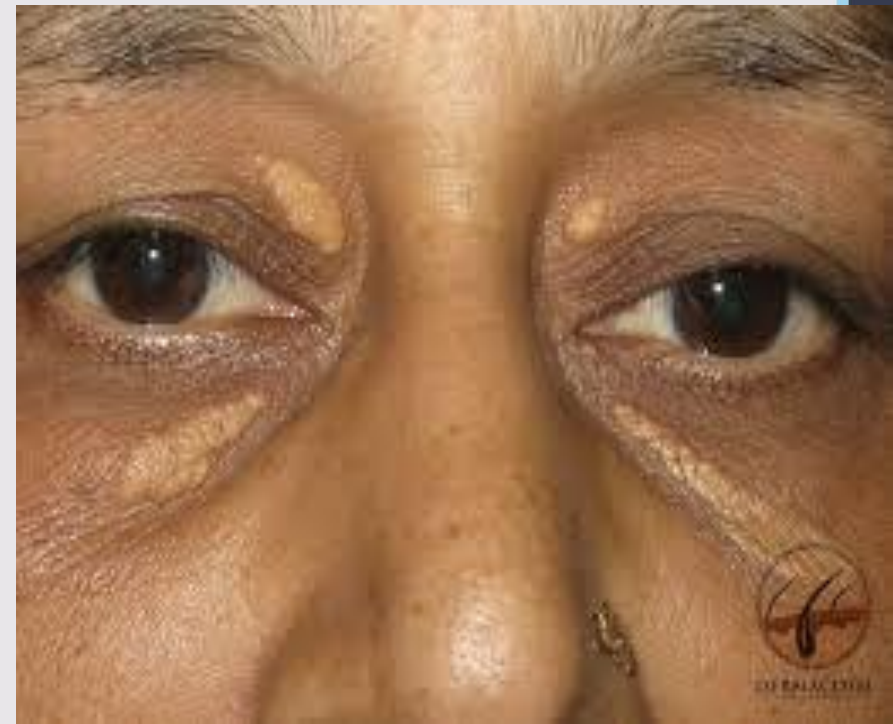
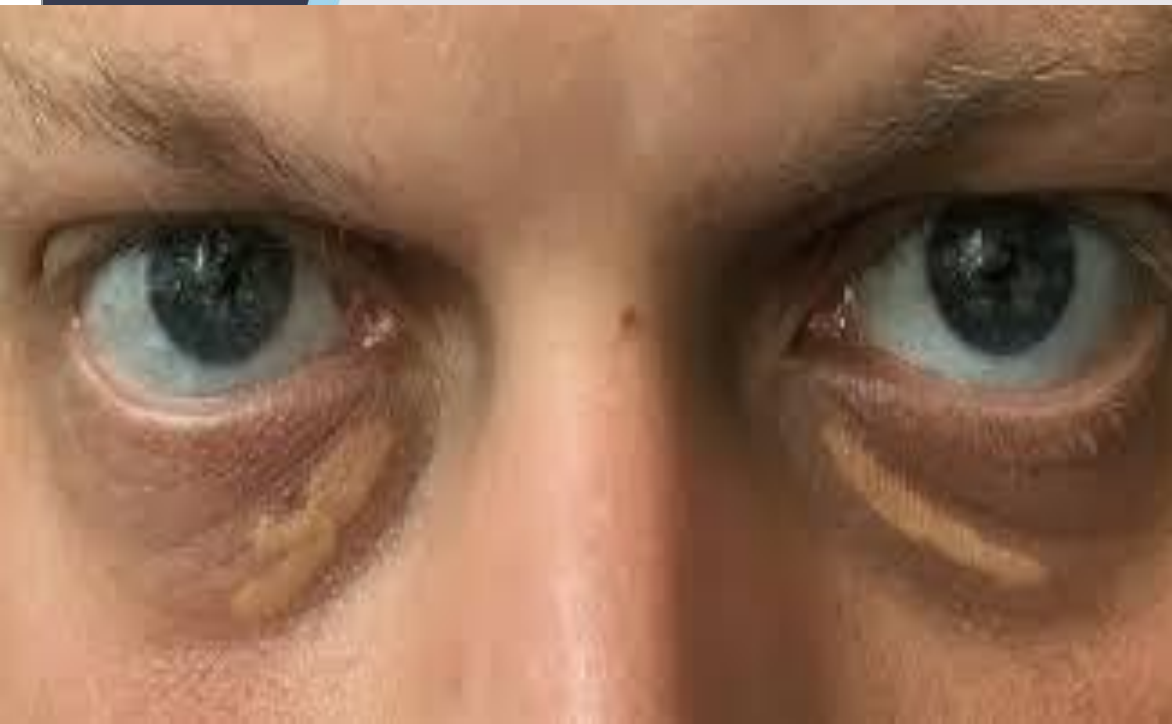
Centurion  
UNIVERSITY

*Shaping Lives...  
Empowering Communities.*

# Treatment

- ❖ Surgical excision.
- ❖ Destruction by chemicals (trichloroacetic acid), diathermy or photocoagulation.
- ❖ Recurrence is very common.



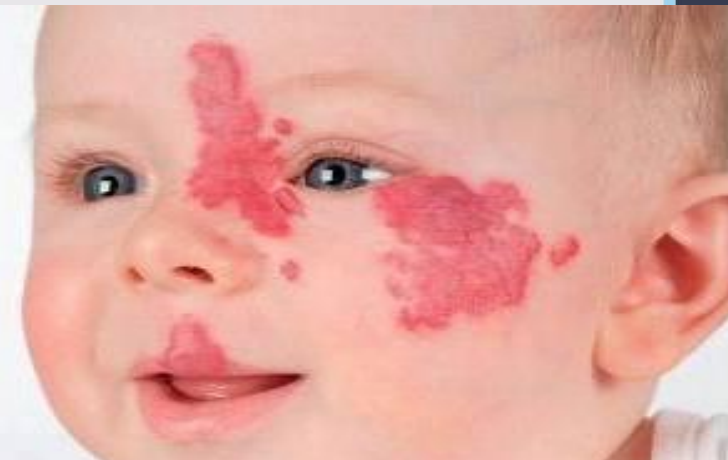
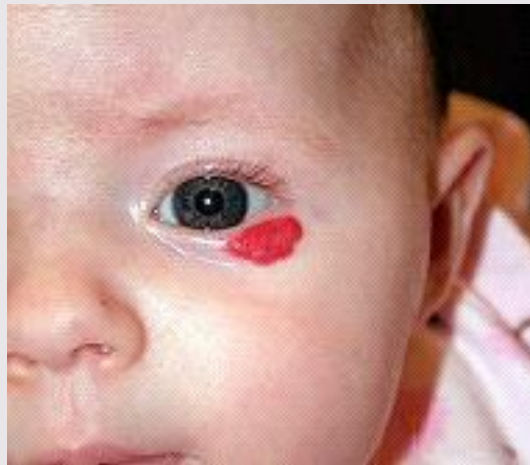
Centurion  
UNIVERSITY

*Shaping Lives...  
Empowering Communities...*

# Hemangiomas

- Cavernous hemangiomas are common in children.
- It is associated with hemangioma of the choroid and leptomeninges called sturge-weber syndrome.
- It appear bluish when seen through skin, and form swellings which increase in size on crying, on lowering the head.



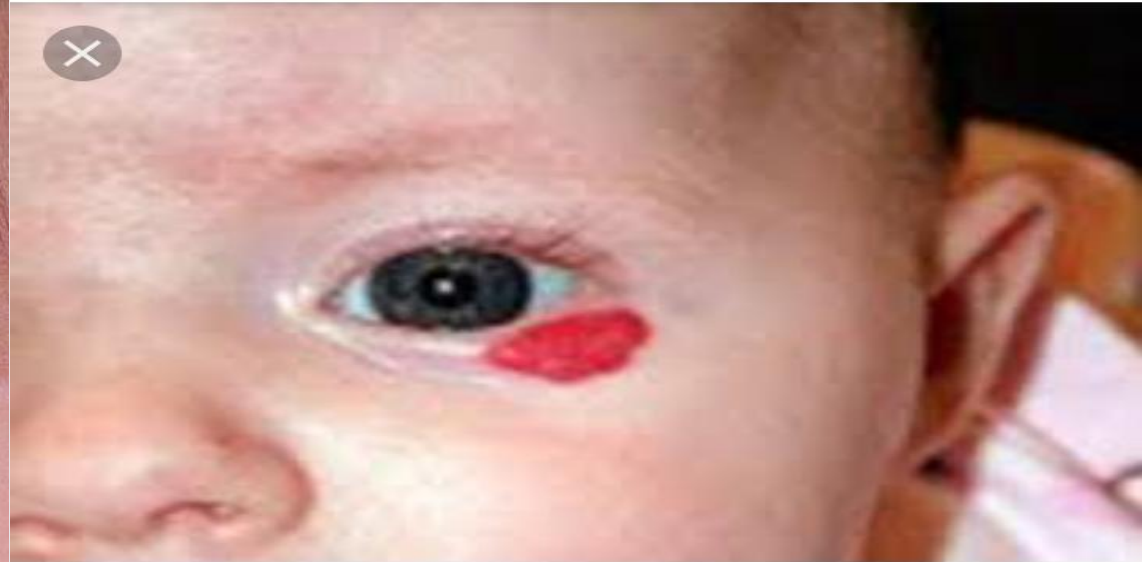
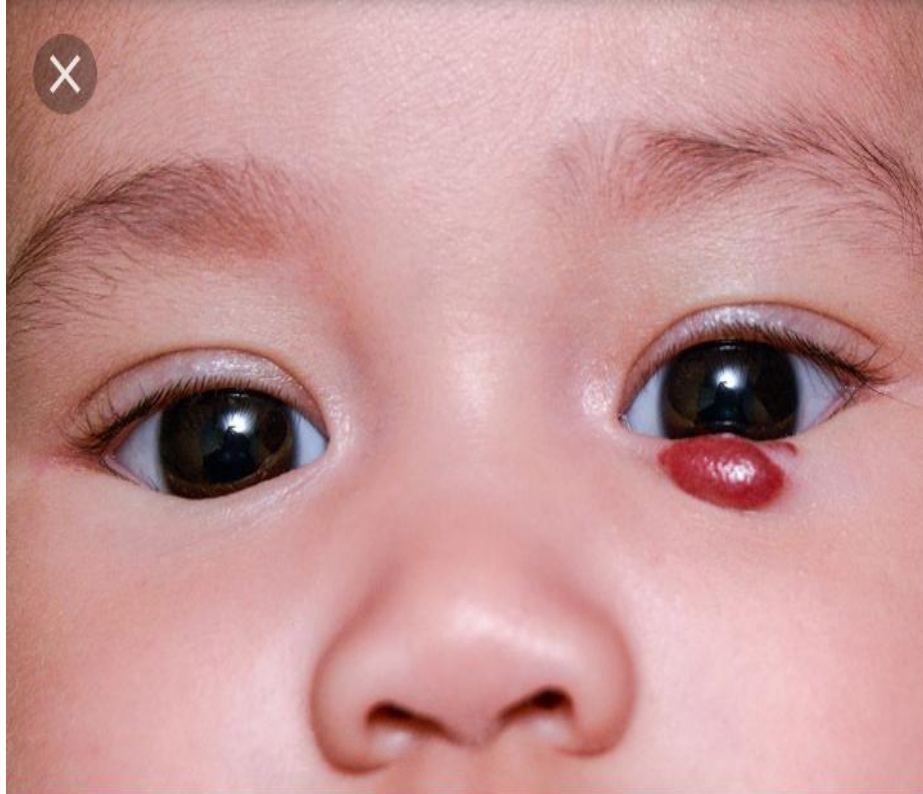
Centurion  
UNIVERSITY

Shining Lives  
Empowering Communities...

# Signs

- A unilateral, raised, red lesion which blanches with pressure and may swell on crying .
- A large tumour in the upper eyelid may cause mechanical ptosis.



**Fig. 1** A capillary hemangioma is an abnormal overgrowth of blood vessels that is sometimes referred to as a "strawberry" birthmark.

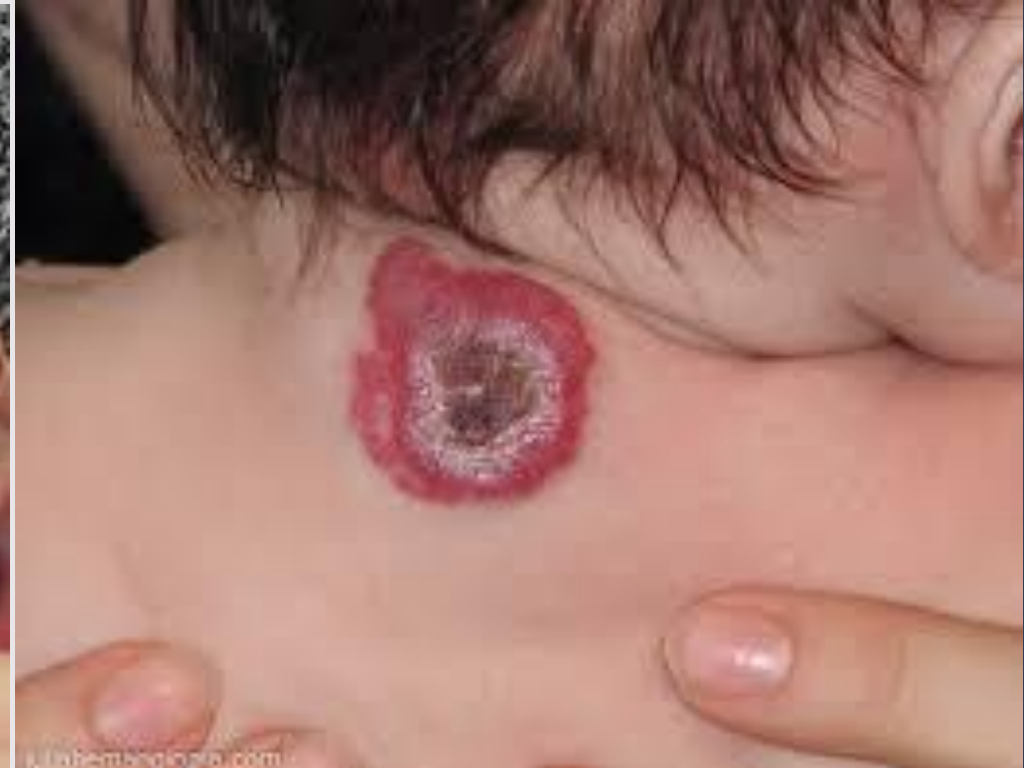
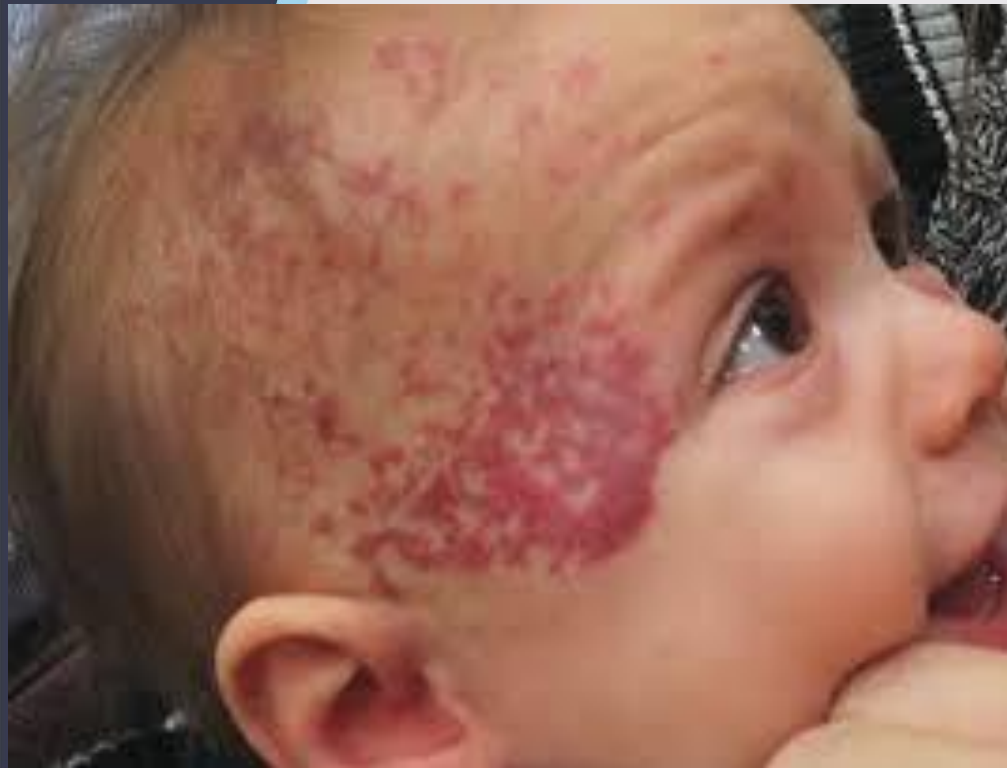
Centurion  
UNIVERSITY

*Shining Lives...  
Empowering Communities...*

# Treatment

- ❖ Small hemangiomas may well be left alone.
- ❖ Large hemangiomas require treatment by intralesional steroid injection, or by superficial radiotherapy.



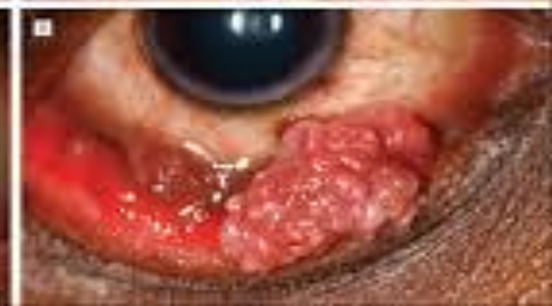
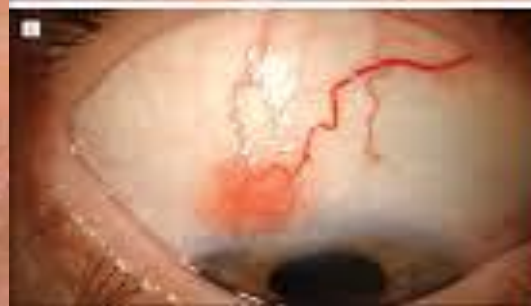
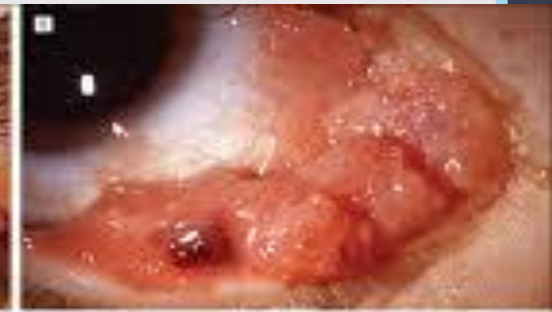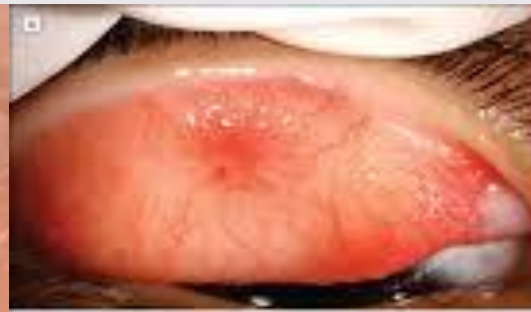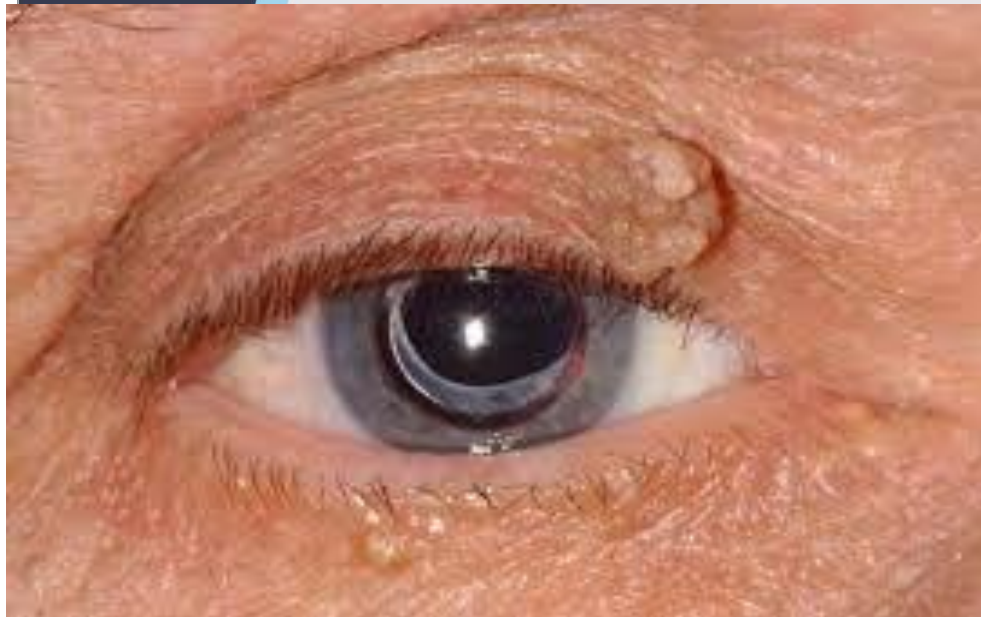Centurion  
UNIVERSITY

Shining Lives  
Empowering Formulations...

# Papillomas

- Also known as viral wart.
- They are benign growths.
- Generally it is caused by Human papilloma virus.
- Signs: A pedunculated or broad based lesion with a characteristic raspberry like surface.



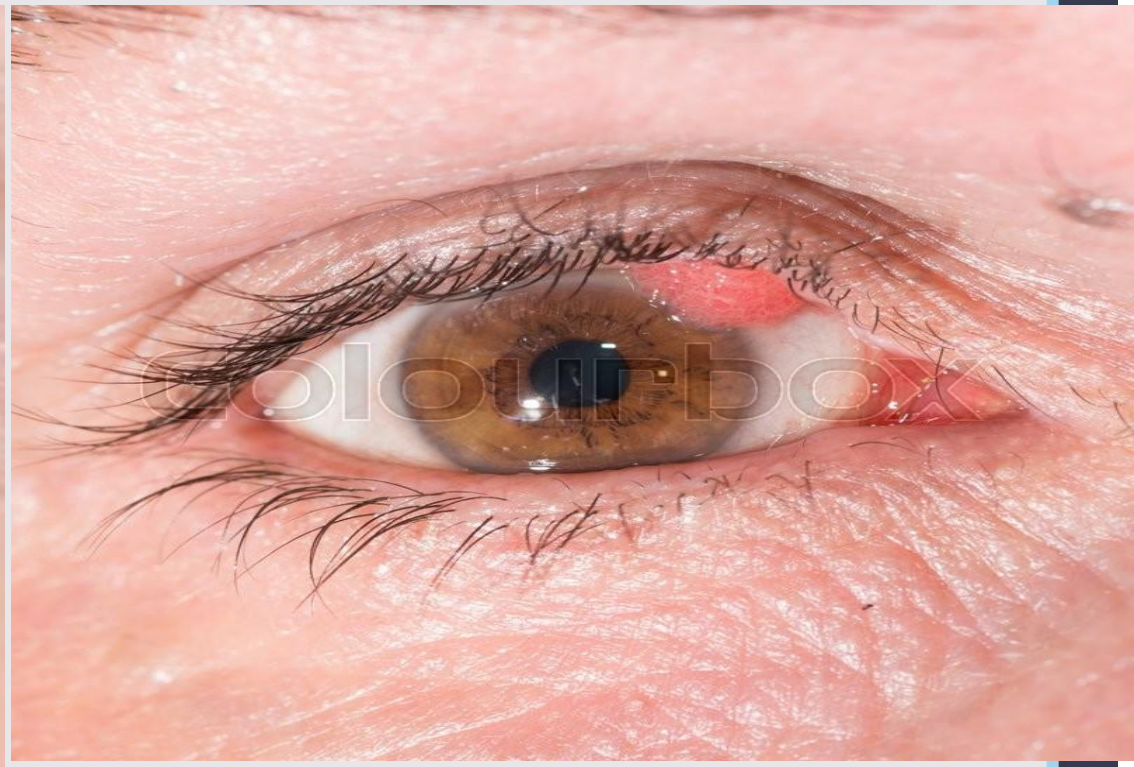
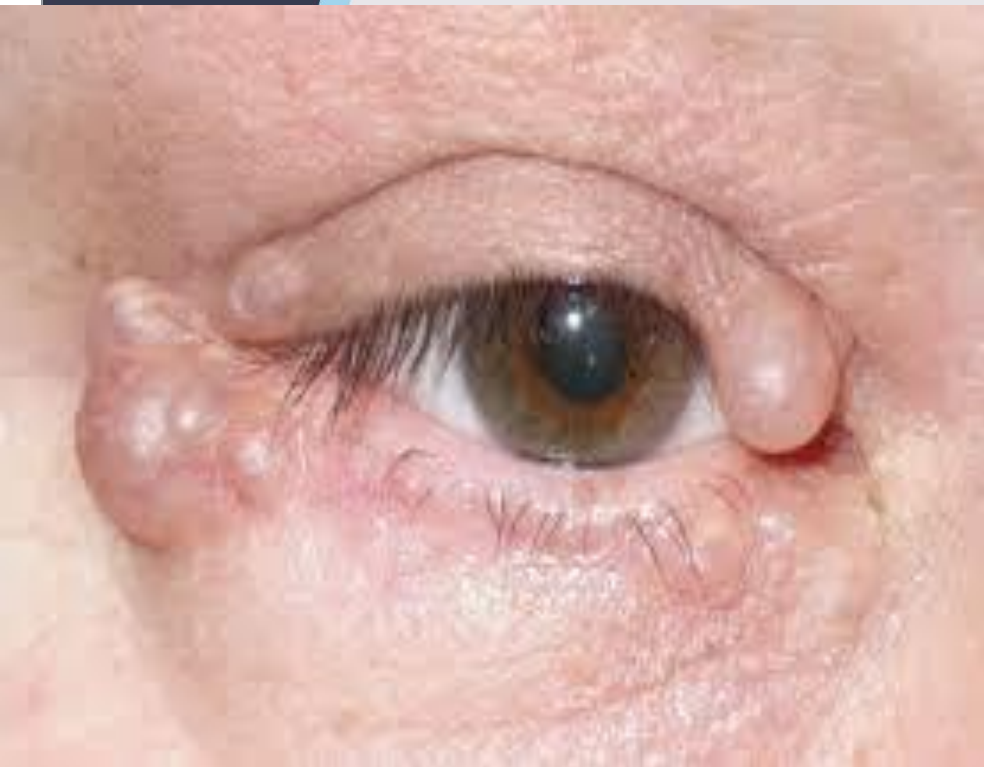
Centurion  
UNIVERSITY

*Sapientia Vivit  
Enproverit Connunilis*

# CONTINUE...

- **Symptoms:** They do not produce any symptoms beyond irritation.
- A papilloma is often harmless and does not require treatment.







**Centurion**  
**UNIVERSITY**

*Shaping Lives...  
Empowering Communities...*

# Treatment

- ❖ Excision, surgically removes the papilloma.
- Laser surgery.
- Cryotherapy, or freezing of the tissue.
- Cautery, which involves burning off the tissue.



**Centurion**  
**UNIVERSITY**

*Shaping Lives...  
Empowering Communities...*

# Books referred

- Clinical ophthalmology, Author: Jack J Kanski ; Publishers: Elsevier , Edition no: 8<sup>th</sup> edition , Pg no: 5,7,11,15,16.
- Essentials of ophthalmology. Author: Samar K Bosak. Publishers: Jaypee; Edition no: 6<sup>th</sup> edition, Pg no: 135,136,137.
- [www.medicalnewstoday.com](http://www.medicalnewstoday.com)



**Centurion**  
**UNIVERSITY**

*Shaping Lives...*  
*Empowering Communities...*

Thank you