



Centurion
UNIVERSITY
Shaping Lives...
Empowering Communities...

OCULAR DISEASE

PTOSIS



Centurion
UNIVERSITY

*Shaping Lives...
Empowering Communities...*

Classification

- **Neurogenic ptosis** is caused by an innervational defect such as third nerve paresis and Horner syndrome.
- **Myogenic ptosis** is caused by a myopathy of the levator muscle itself, or by impairment of transmission of impulses at the neuromuscular junction (neuromyopathic). Acquired myogenic ptosis occurs in myasthenia gravis, myotonic dystrophy and progressive external ophthalmoplegia.
- **Aponeurotic or involutinal ptosis** is caused by a defect in the levator aponeurosis.
- **Mechanical ptosis** is caused by the gravitational effect of a mass or by scarring



Centurion
UNIVERSITY

*Shaping Lives...
Empowering Communities...*

Clinical evaluation

- The age at onset of ptosis and its duration will usually distinguish
- congenital from acquired cases. If the history is ambiguous, old
- photographs may be helpful. It is also important to enquire about
- symptoms of possible underlying systemic disease, such as associated
- diplopia, variability of ptosis during the day and excessive fatigue.



Centurion
UNIVERSITY

Shaping Lives...
Empowering Communities...

Pseudoptosis

- A false impression of ptosis may be caused by the following:
- **Lack of support** of the lids by the globe may be due to an orbital volume deficit associated with an artificial eye, microphthalmos, phthisis bulbi, or enophthalmos.
- **Contralateral lid retraction**, which is detected by comparing the levels of the upper lids, remembering that the margin of the upper lid normally covers the superior 2 mm of the cornea.

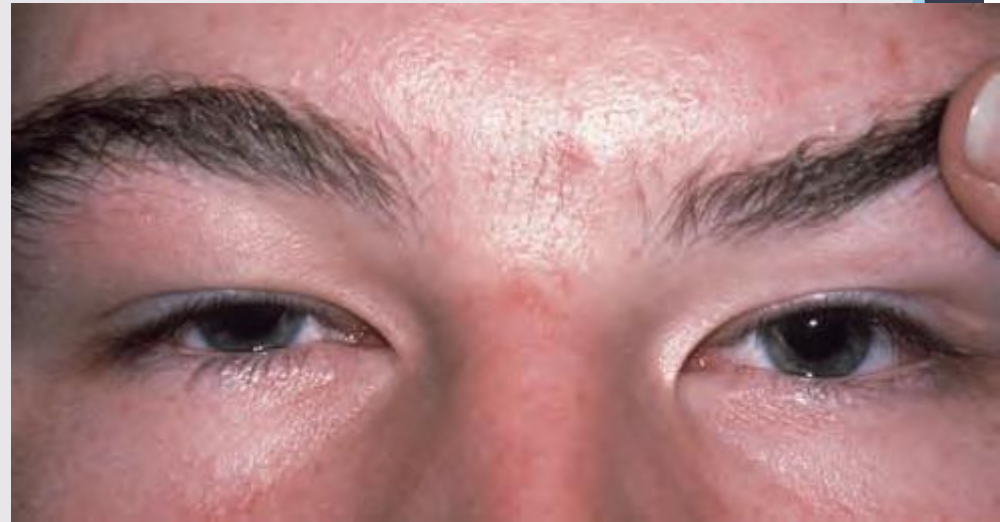
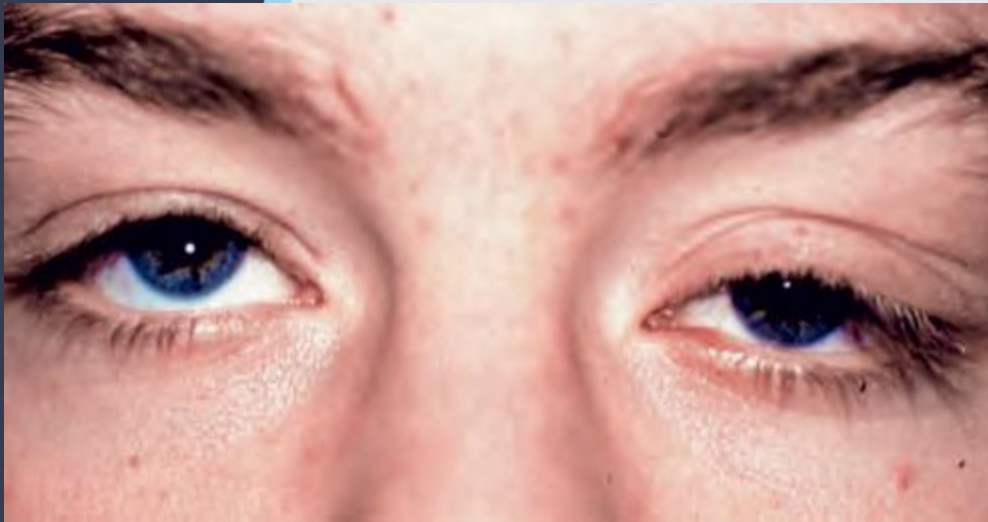
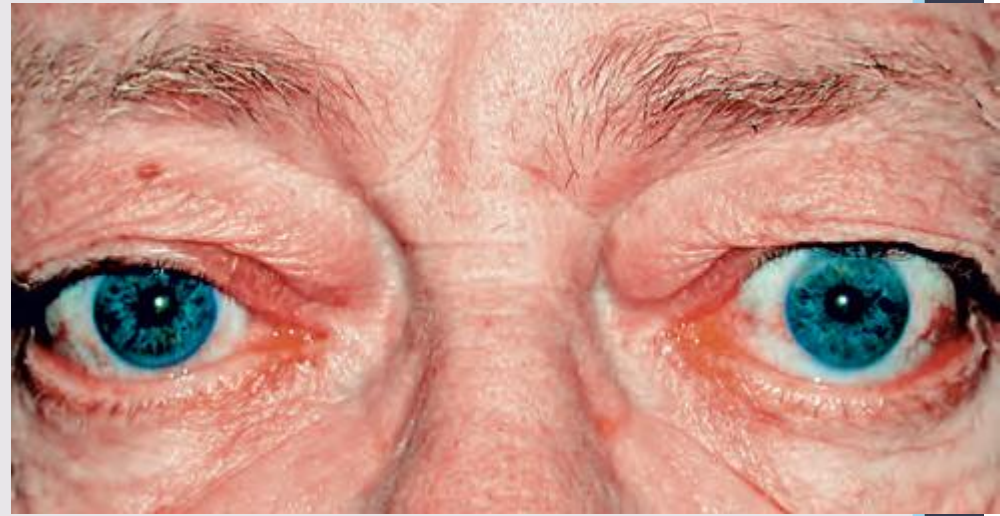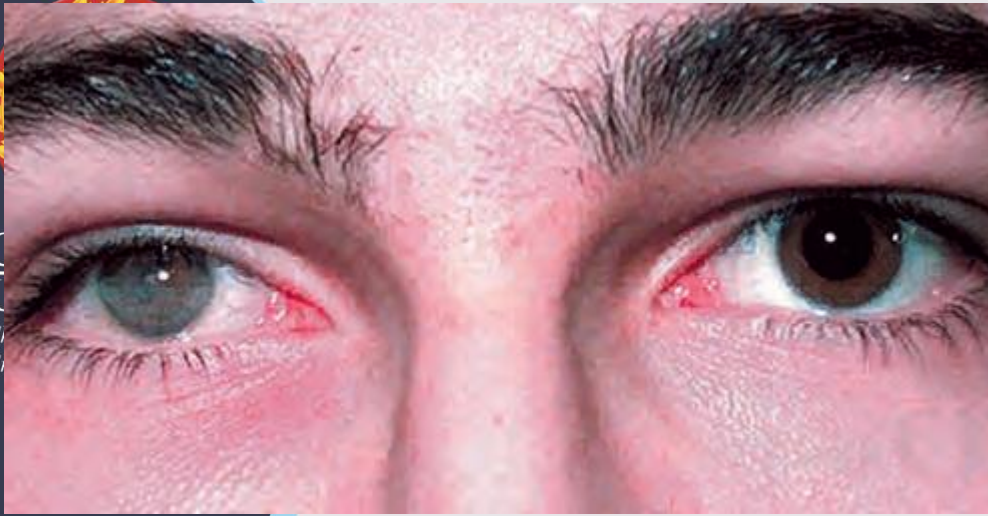Centurion
UNIVERSITY

*Shaping Lives...
Empowering Communities...*

Continue...

- **Ipsilateral hypotropia** causes pseudoptosis because the upper lid follows the globe downwards. It disappears when the hypotropic eye assumes fixation on covering the normal eye.
- **Brow ptosis** due to excessive skin on the brow, or seventh nerve palsy, which is diagnosed by manually elevating the eyebrow.
- • **Dermatochalasis.** Overhanging skin on the upper lids may be mistaken for ptosis, but may also cause mechanical ptosis.

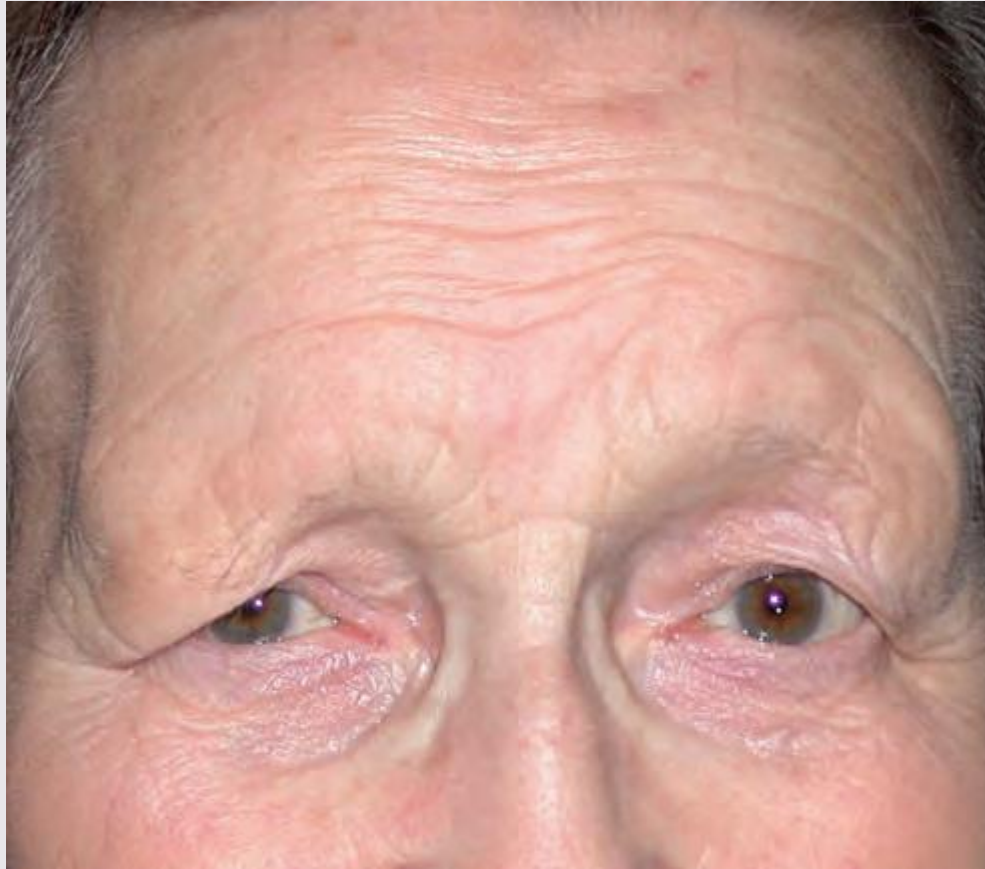

Causes of pseudoptosis. (A) Right phthisis bulbi; (B) contralateral lid retraction; (C) ipsilateral hypotropia; (D) bilateral brow ptosis



Centurion
UNIVERSITY

*Shaping Lives...
Empowering Communities...*



***Marked right dermatochalasis and
brow ptosis***



Centurion
UNIVERSITY

*Shaping Lives...
Empowering Communities...*

Measurements

- **Margin–reflex distance** is the distance between the upper lid margin and the corneal reflection of a pen torch held by the examiner on which the patient fixates; the normal measurement is 4–5 mm.
- **Palpebral fissure height** is the distance between the upper and lower lid margins, measured in the pupillary plane.
- The upper lid margin normally rests about 2 mm below the upper limbus and the lower 1 mm above the lower limbus.



Centurion
UNIVERSITY

*Shaping Lives...
Empowering Communities...*

Continue...

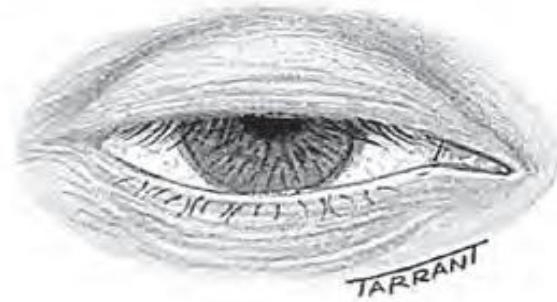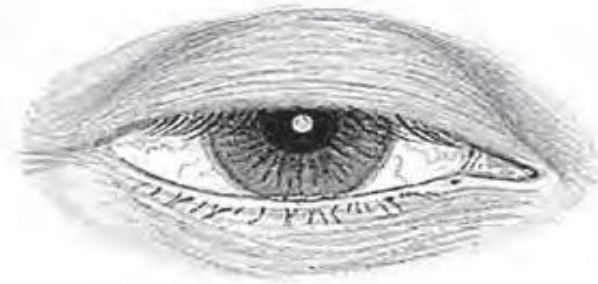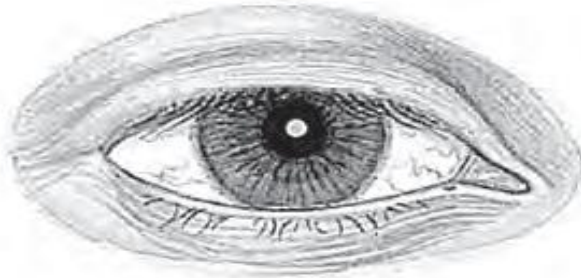
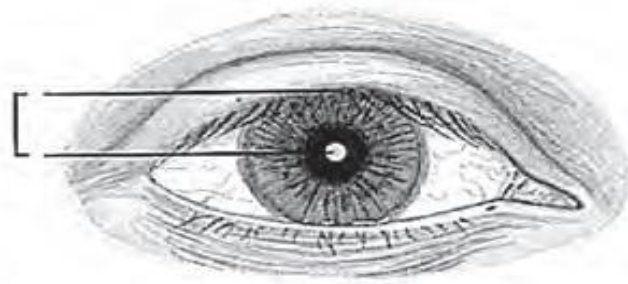
- This measurement is shorter in males (7–10 mm) than in females (8–12 mm).
- Unilateral ptosis can be quantified by comparison with the contralateral side.
- Ptosis may be graded as mild (up to 2 mm), moderate (3 mm) and severe (4 mm or more).



Centurion
UNIVERSITY

Shaping Lives...
Empowering Communities...

MRD

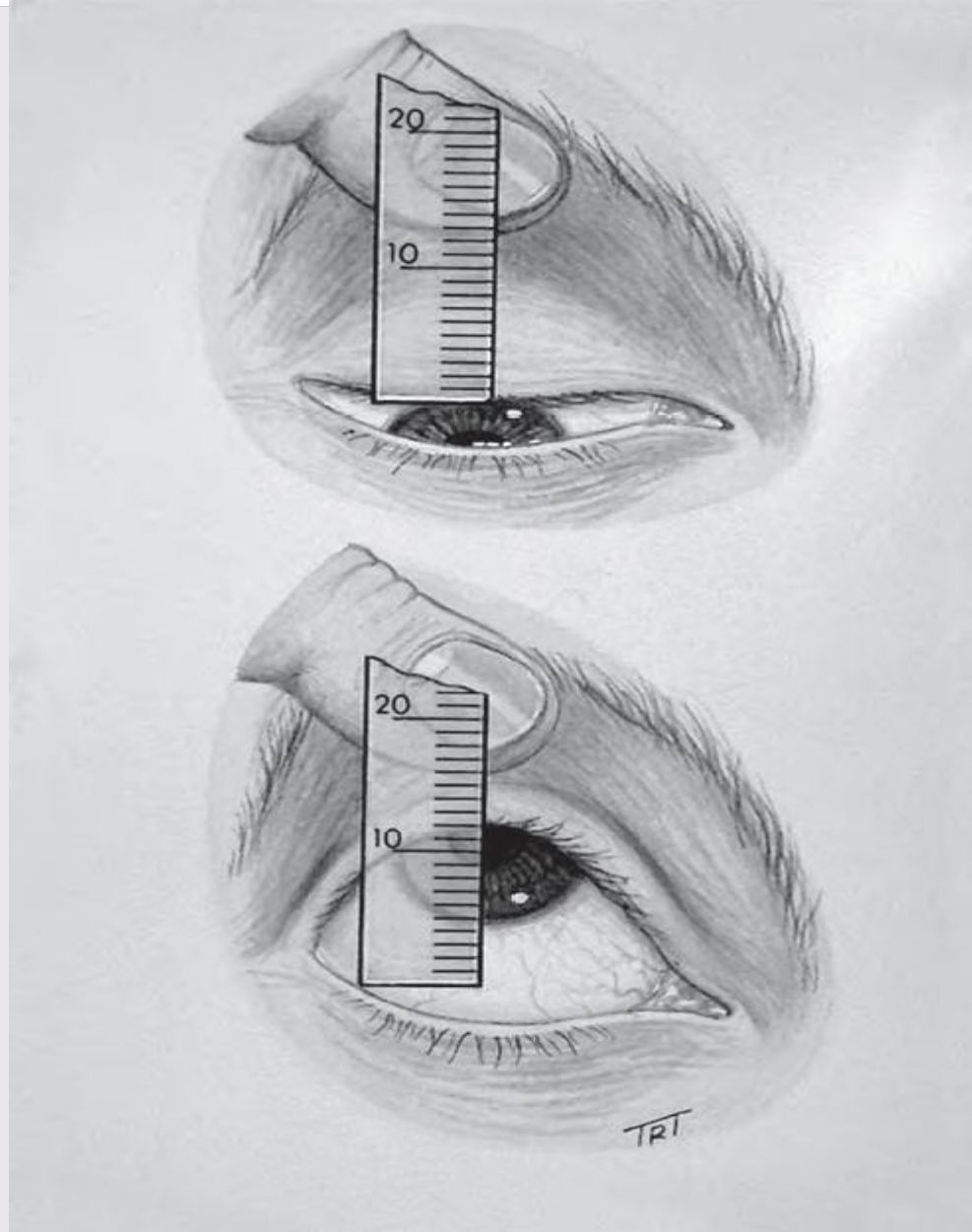


Margin-reflex distance. (A) Normal; (B) mild ptosis; (C) moderate ptosis; (D) severe ptosis



Centurion
UNIVERSITY

*Shaping Lives...
Empowering Communities...*



Measurement of levator function



Centurion
UNIVERSITY

*Shaping Lives...
Empowering Communities...*



*Measurement of palpebral fissure
height*



Centurion
UNIVERSITY

*Shaping Lives...
Empowering Communities...*

Continue...

- **Levator function (upper lid excursion)** is measured by placing a thumb firmly against the patient's brow to negate the action of the frontalis muscle, with the eyes in downgaze. The patient then looks up as far as possible and the amount of excursion is measured with a rule.
- Levator function is graded as
 1. normal (15 mm or more),
 2. good (12–14 mm),
 3. fair (5–11 mm) and
 4. poor (4 mm or less).



Centurion
UNIVERSITY

*Shaping Lives...
Empowering Communities...*

Continue...

- **Upper lid crease** is taken as the vertical distance between the lid margin and the lid crease in downgaze.
- In females it measures about 10 mm and in males 8 mm.
- Absence of the crease in a patient with congenital ptosis is evidence of poor levator function, whereas a high crease suggests an aponeurotic defect (usually involutional).
- The skin crease is also used as a guide to the initial incision in some surgical procedures.



Centurion
UNIVERSITY

*Shaping Lives...
Empowering Communities...*

Continue...

- **Pretarsal show** is the distance between the lid margin and the skin fold with the eyes in the primary position.



Centurion
UNIVERSITY

*Shaping Lives...
Empowering Communities...*

Associated signs

- **The pupils** should be examined to exclude Horner syndrome and a subtle pupil-involving third nerve palsy – the latter is an unlikely acute clinical presentation.
- **Increased innervation** may flow to the levator muscle of a unilateral ptosis, particularly in upgaze. Associated increased innervation to the contralateral normal levator will result in lid retraction.
- The examiner should therefore manually elevate the ptotic lid and look for drooping of the opposite lid. If this occurs, the patient should be warned that surgical correction may induce a lower position in the opposite lid.



Centurion
UNIVERSITY

*Shaping Lives...
Empowering Communities...*

Continue...

- **Fatigability** is tested by asking the patient to look up without blinking for 30–60 seconds. Progressive drooping of one or both lids, or an inability to maintain upgaze, is suggestive of myasthenia gravis. Myasthenic ptosis may show an overshoot of the upper lid on saccade from downgaze to the primary position (Cogan twitch sign) and a ‘hop’ on side-gaze.
- **Ocular motility defects**, particularly of the superior rectus, must be evaluated in patients with congenital ptosis. Correction of an ipsilateral hypotropia may improve the degree of ptosis. Deficits consistent with a subtle or partial third nerve paresis should be identified.



Centurion
UNIVERSITY

*Shaping Lives...
Empowering Communities...*

Continue...

- **Jaw-winking** can be identified by asking the patient to chew and move the jaws from side to side.
- **The Bell phenomenon** is tested by manually holding the lids open, asking the patient to try to shut the eyes and observing upward and outward rotation of the globe.
- A weak Bell phenomenon carries a variable risk of postoperative exposure keratopathy, particularly following large levator resections or suspension procedures.
- **The tear film** should be inspected – a poor volume or unstable film may be worsened by ptosis surgery and should be addressed preoperatively as far as possible.



Centurion
UNIVERSITY

*Shaping Lives...
Empowering Communities...*

Simple Congenital Ptosis



Centurion
UNIVERSITY

*Shaping Lives...
Empowering Communities...*

Diagnosis

- Congenital ptosis probably results from a failure of neuronal migration or development with muscular sequelae secondary to this; a minority of patients have a family history.

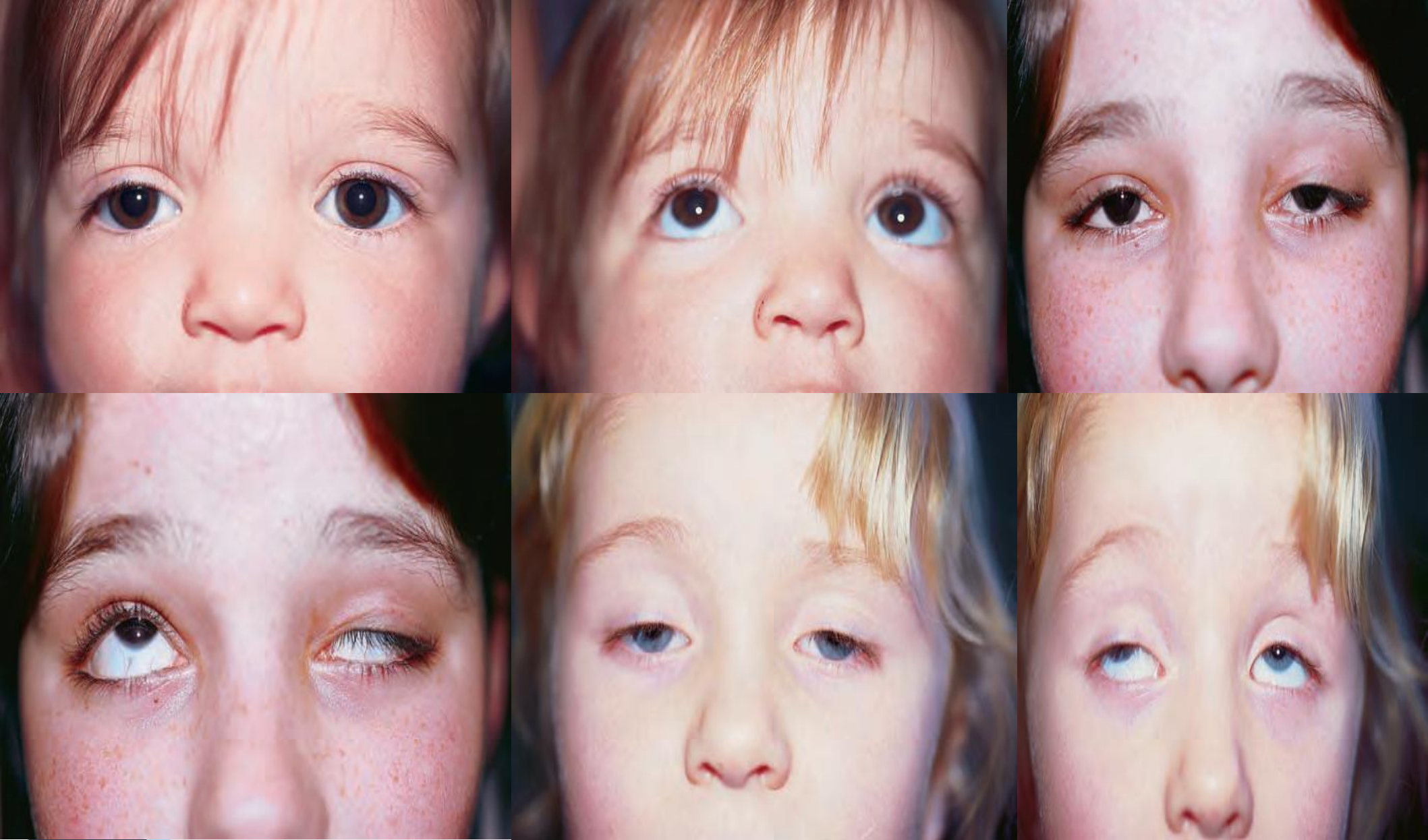

Centurion
UNIVERSITY

*Shaping Lives...
Empowering Communities...*

Signs

- Unilateral or bilateral ptosis of variable severity.
- Absent upper lid crease and poor levator function.
- In downgaze the ptotic lid is higher than the normal because of poor relaxation of the levator muscle. This is in contrast to acquired ptosis, in which the affected lid is either level with or lower than the normal lid on downgaze.
- Following surgical correction the lid lag in downgaze may worsen.



Congenital ptosis. (A) Mild right ptosis; (B) good levator function; (C) severe left ptosis with absent skin crease; (D) very poor levator function; (E) severe bilateral ptosis; (F) very poor levator function



Centurion
UNIVERSITY

*Shaping Lives...
Empowering Communities...*

Associations

- Superior rectus weakness may be present because of its close embryological association with the levator.
- Compensatory chin elevation in severe bilateral cases.
- Refractive errors are common and more frequently responsible for amblyopia than the ptosis itself.



Centurion
UNIVERSITY

Shaping Lives...
Empowering Communities...

Treatment

- Treatment should be carried out during the preschool years once accurate measurements can be obtained, but may be considered earlier in severe cases to prevent amblyopia. Levator resection is usually required.