



*SHOULDER JOINT & ELBOW JOINT*

*BY*

*S.S.SIVA SAGAR*

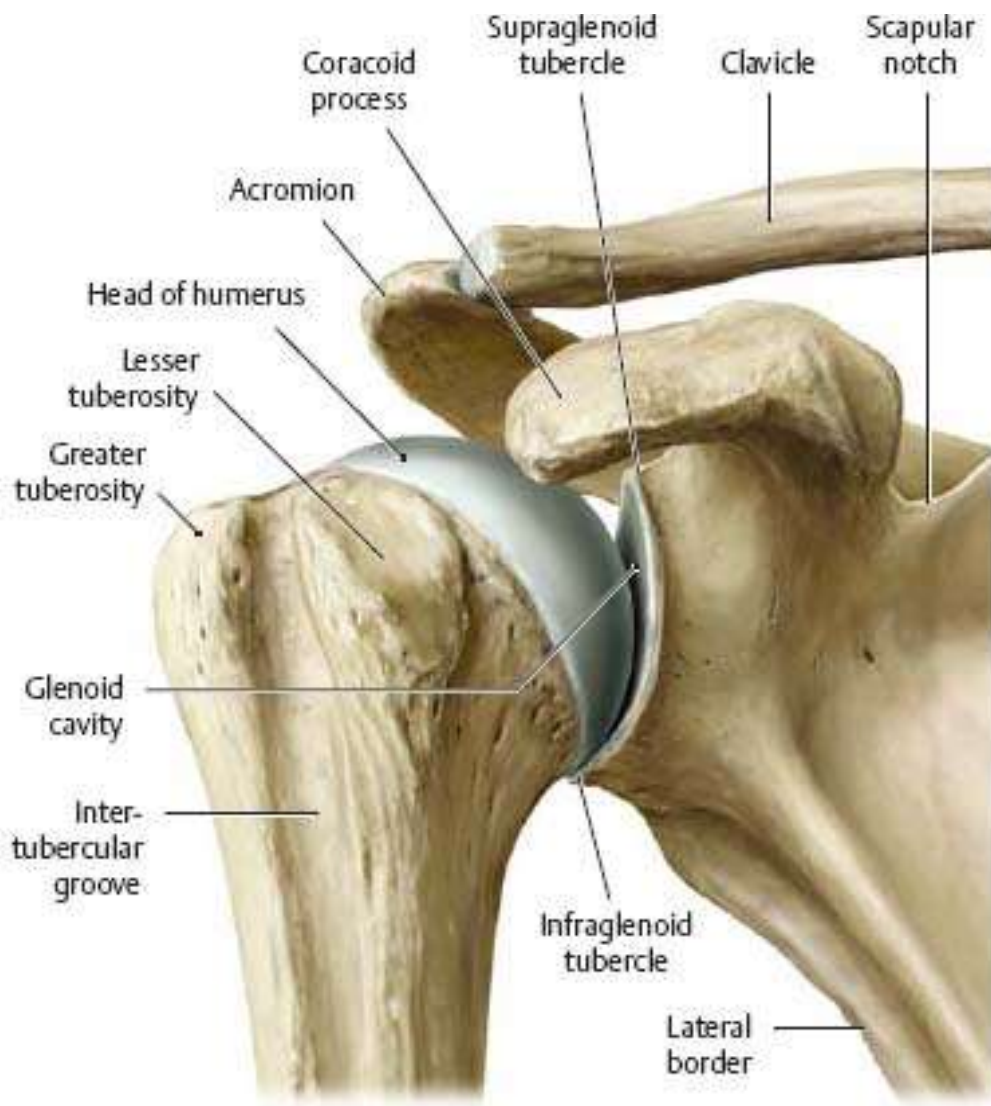*TEACHING ASSISTANT*

*RADIOLOGY*

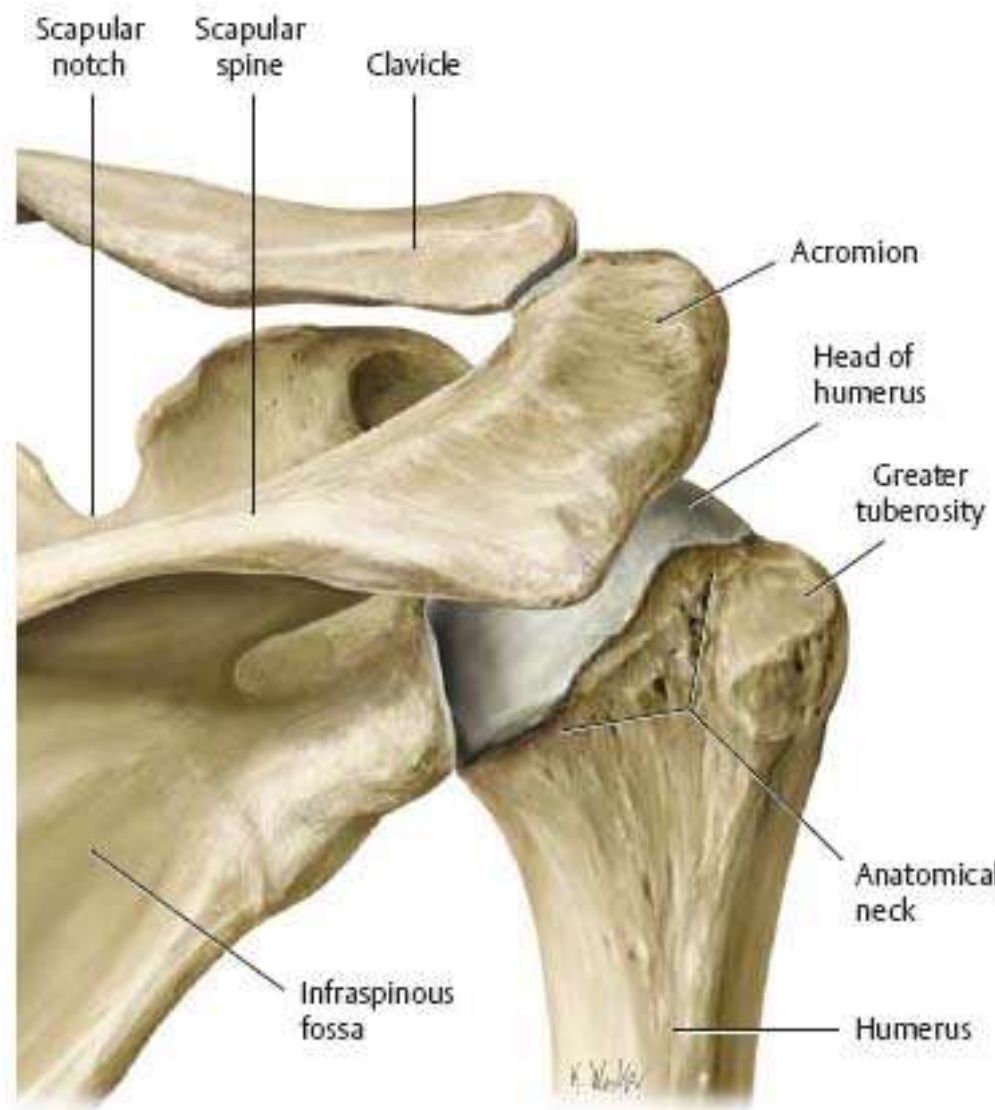
*CENTURIAN UNIVERSITY*

# Introduction of shoulder joint

- ❑ The shoulder is one of the largest and most complex joints in the body.
- ❑ The glenohumeral, or shoulder, joint is a synovial joint that attaches the upper limb to the axial skeleton. It is a ball-and-socket joint, formed between the glenoid fossa of scapula and the head of humerus.
- ❑ The shoulder joint allows for a wide range of movements; flexion, extension, abduction, adduction, external/lateral rotation, internal/medial rotation and circumduction
- ❑ The glenohumeral joint is the articulation between the spherical head of the humerus and the concave glenoid fossa of the scapula. Being a synovial joint, both articular surfaces are covered with hyaline cartilage.
- ▶ The humerus fits relatively loosely into the shoulder joint. This gives the shoulder a wide range of motion, but also makes it vulnerable to injury.



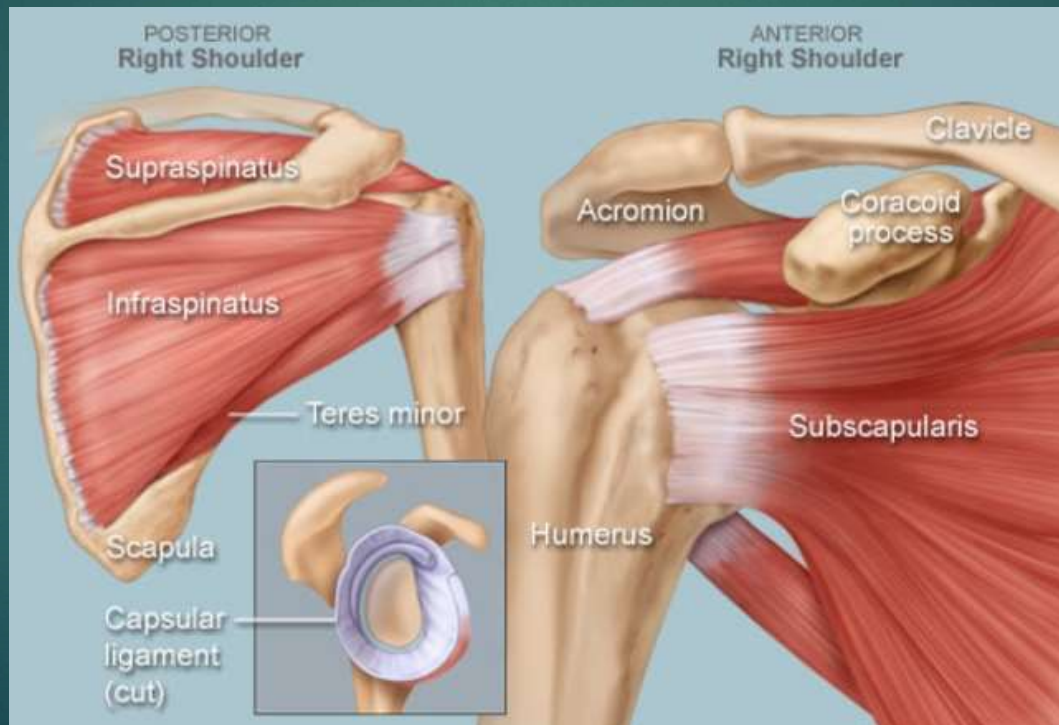
A Anterior view.



B Posterior view.

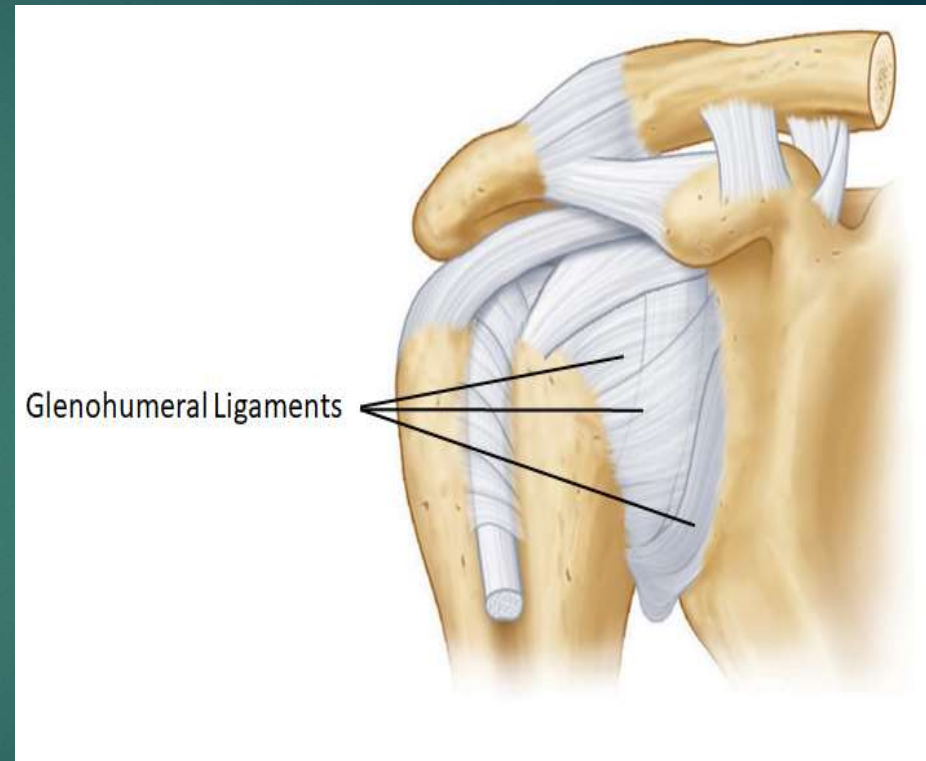
# MUSCLES – Rotator cuff - **SITS**

- ▶ Four muscles—the **supraspinatus, infraspinatus, teres minor, and subscapularis**—make up the **rotator cuff muscles**.
- ▶ It stabilizes the shoulder and holds the head of the humerus into the glenoid cavity to maintain the principal shoulder joint.



# Ligaments

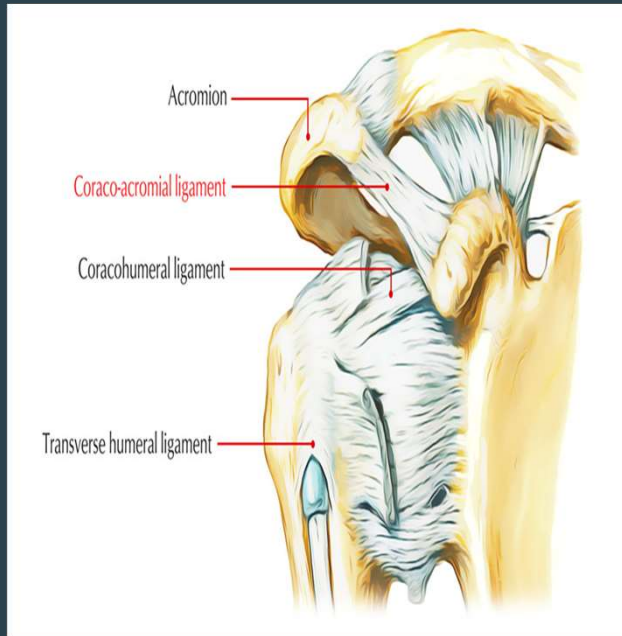
- ▶ Ligaments are soft tissue structures that connect bones to bones. There are several important ligaments in the shoulder.
- ▶ **Glenohumeral Ligaments (GHL):**
  - ❖ A joint capsule is a watertight sac that surrounds a joint.
  - ❖ In the shoulder, the joint capsule is formed by a group of ligaments that connect the humerus to the glenoid.
  - ❖ These ligaments are the main source of stability for the shoulder.
  - ❖ They are the **superior, middle and inferior glenohumeral ligaments.**
  - ❖ They help hold the shoulder in place and keep it from dislocating .



## Coracoid-acromial Ligament (CAL):

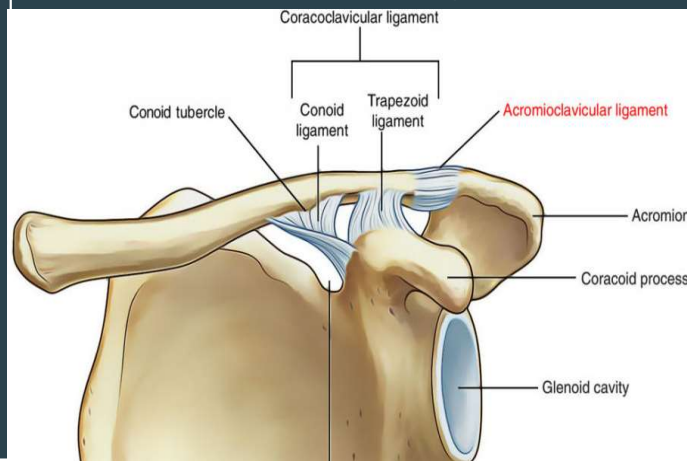
A strong triangular band, extending between the coracoid process and the acromion.

This ligament can thicken and cause **Impingement Syndrome**



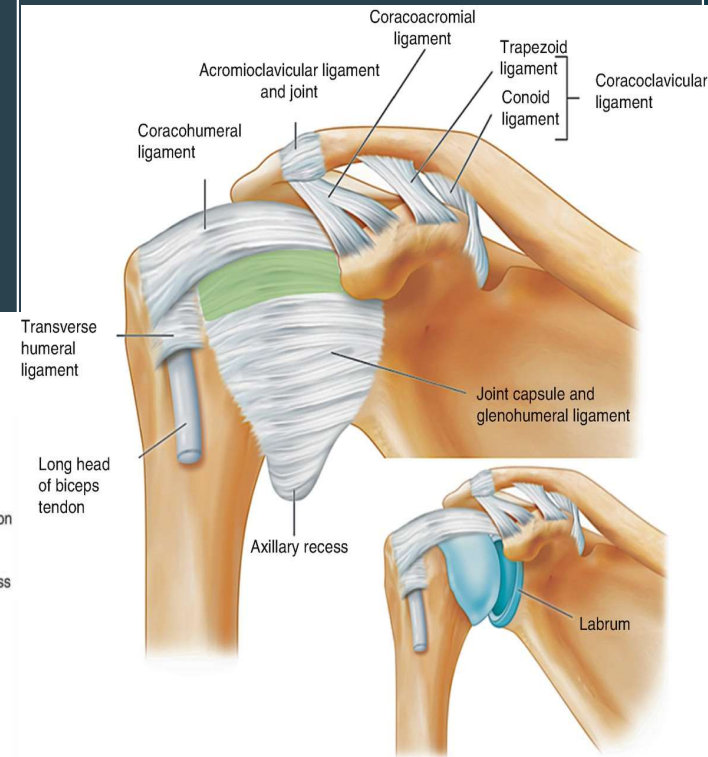
## Coraco-clavicular Ligaments (CCL):

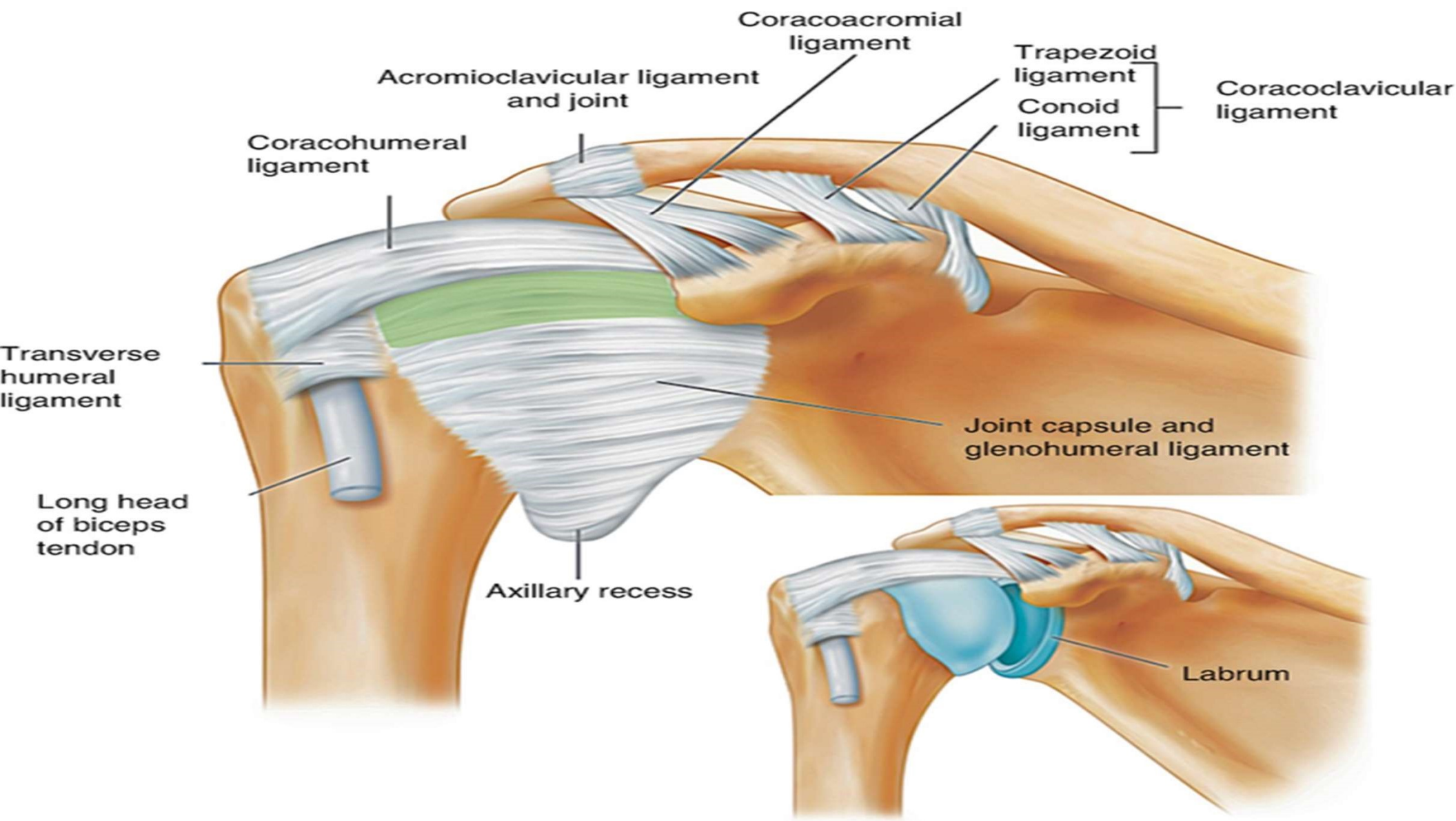
- These two ligaments (**trapezoid and conoid ligaments**) attach the clavicle and coracoid process of the scapula.
- These tiny ligaments with the acromioclavicular joint play an important role in keeping the scapula attached to the clavicle and thus keeping shoulder 'square'.
- They carry a massive load and are extremely strong.



## Transverse Humeral Ligament (THL) :

Holds the **tendon** of the long head of biceps brachii muscle in the groove between the greater and lesser tubercle on the humerus (intertubercular sulcus)

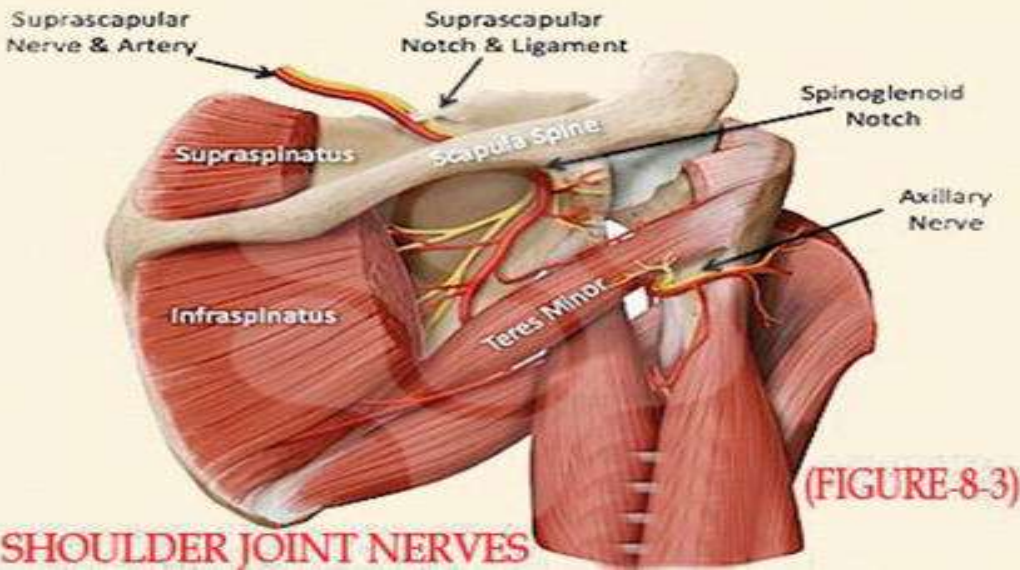
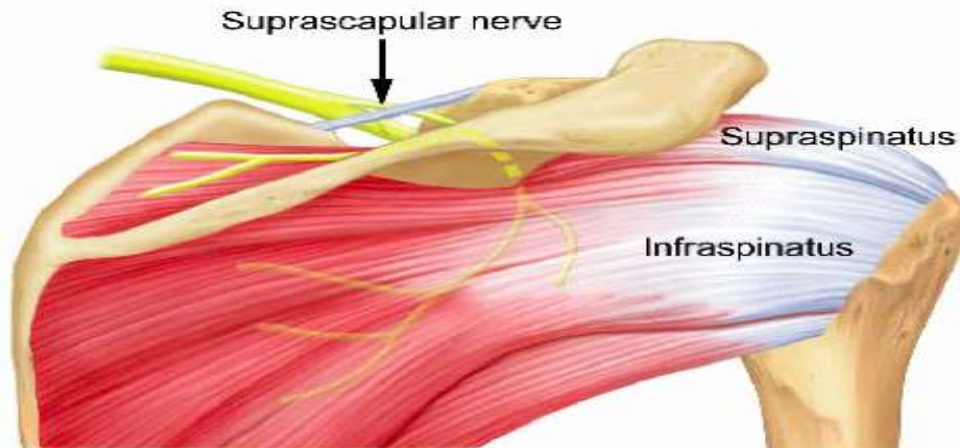




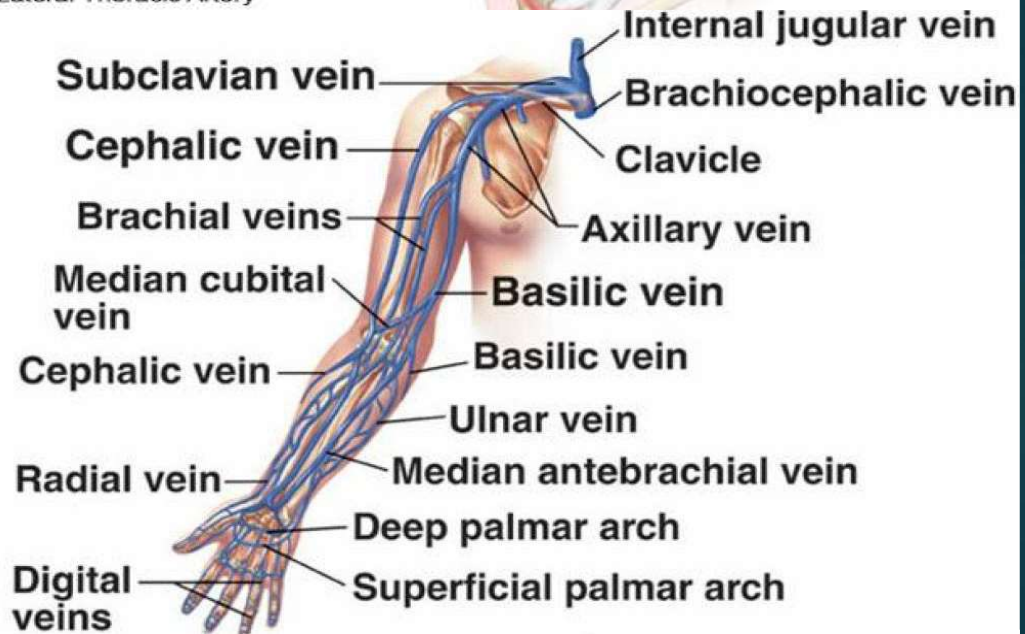
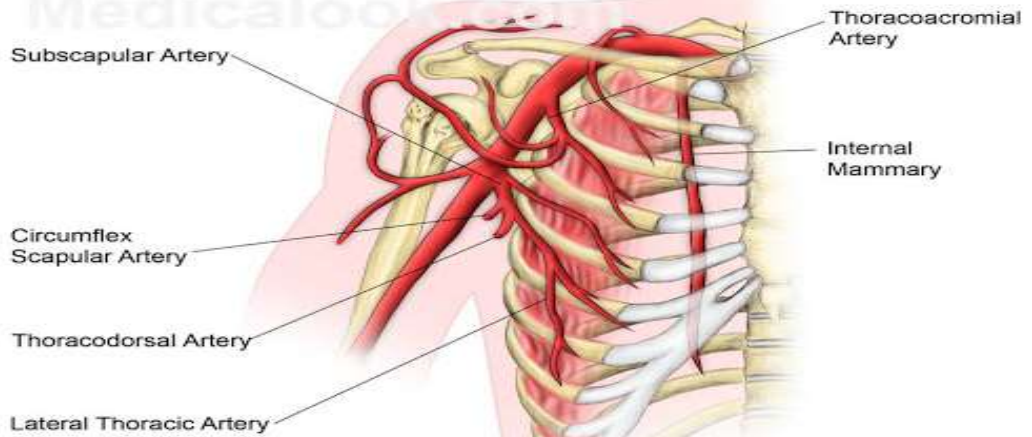
# Tendons of shoulder joint

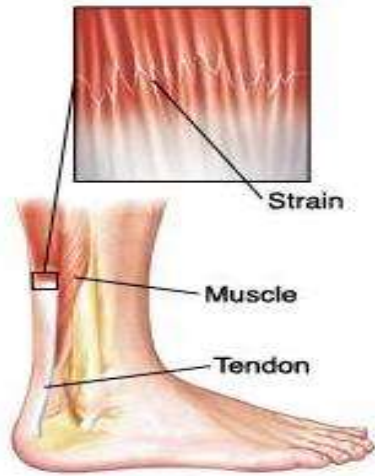


# NERVE SUPPLY

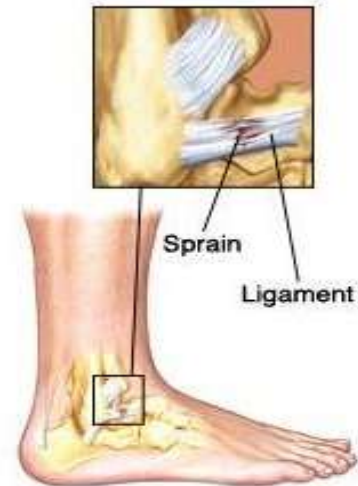

# BLOOD SUPPLY

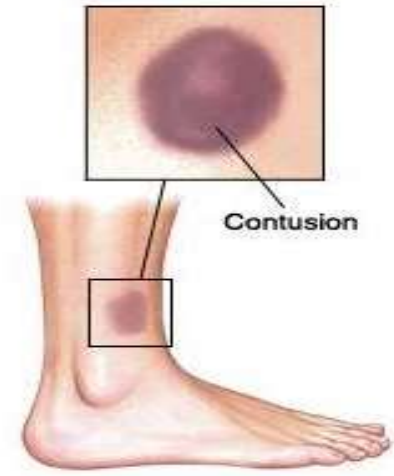




**A strain is damage to a muscle or tendon.**



**A sprain is damage to a ligament.**



**A contusion (bruise) is caused by damage to blood vessels in and under the skin.**

## **SPASMS :**

Involuntary contractions of a muscle, typically harmless and temporary, but can be painful.

# PATHOLOGY

- ▶ **Frozen shoulder**: Inflammation develops in the shoulder that causes pain and stiffness. As a frozen shoulder progresses, movement in the shoulder can be severely limited.
- ▶ **Osteoarthritis**: The common "wear-and-tear" arthritis that occurs with aging. The shoulder is less often affected by osteoarthritis than the knee.
- ▶ **Rheumatoid arthritis**: A form of arthritis in which the immune system attacks the joints, causing inflammation and pain. Rheumatoid arthritis can affect any joint, including the shoulder.
- ▶ **Gout**: A form of arthritis in which crystals form in the joints, causing inflammation and pain. The shoulder is an uncommon location for gout.
- ▶ **Rotator cuff tear**: A tear in one of the muscles or tendons surrounding the top of the humerus. A rotator cuff tear may be a sudden injury, or result from steady overuse.
- ▶ **Shoulder impingement**: The acromion (edge of the scapula) presses on the rotator cuff as the arm is lifted. If inflammation or an injury in the rotator cuff is present, this impingement causes pain.

- ▶ Shoulder dislocation: The humerus or one of the other bones in the shoulder slips out of position. Raising the arm causes pain and a "popping" sensation if the shoulder is dislocated.
- ▶ Shoulder tendonitis: Inflammation of one of the tendons in the shoulder's rotator cuff.
- ▶ Shoulder bursitis: Inflammation of the bursa, the small sac of fluid that rests over the rotator cuff tendons. Pain with overhead activities or pressure on the upper, outer arm are symptoms.
- ▶ Labral tear: An accident or overuse can cause a tear in the labrum, the cuff of cartilage that overlies the head of the humerus. Most labral tears heal without requiring surgery.

<https://radiologyassistant.nl/musculoskeletal/shoulder-mr-anatomy>

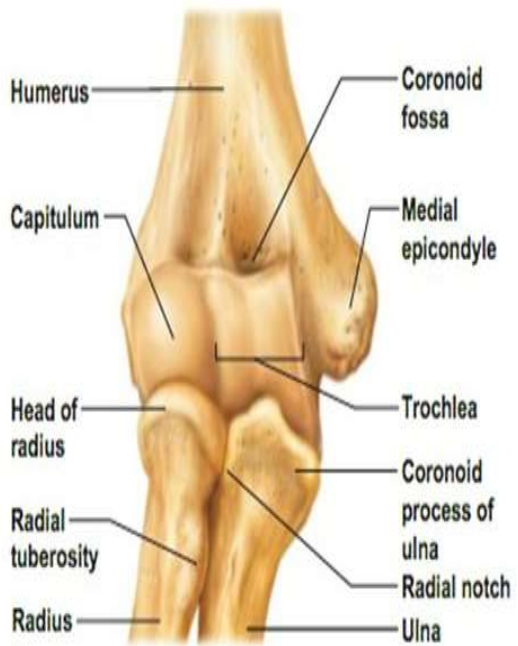<https://radiopaedia.org/cases/normal-shoulder-mri>

# INVESTIGATIONS

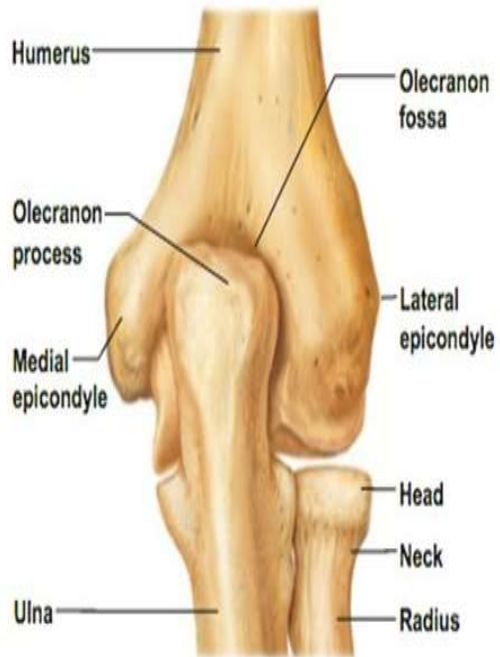- ▶ X RAY
- ▶ CT
- ▶ MRI
- ▶ ULTRASOUND

# Introduction of Elbow joint

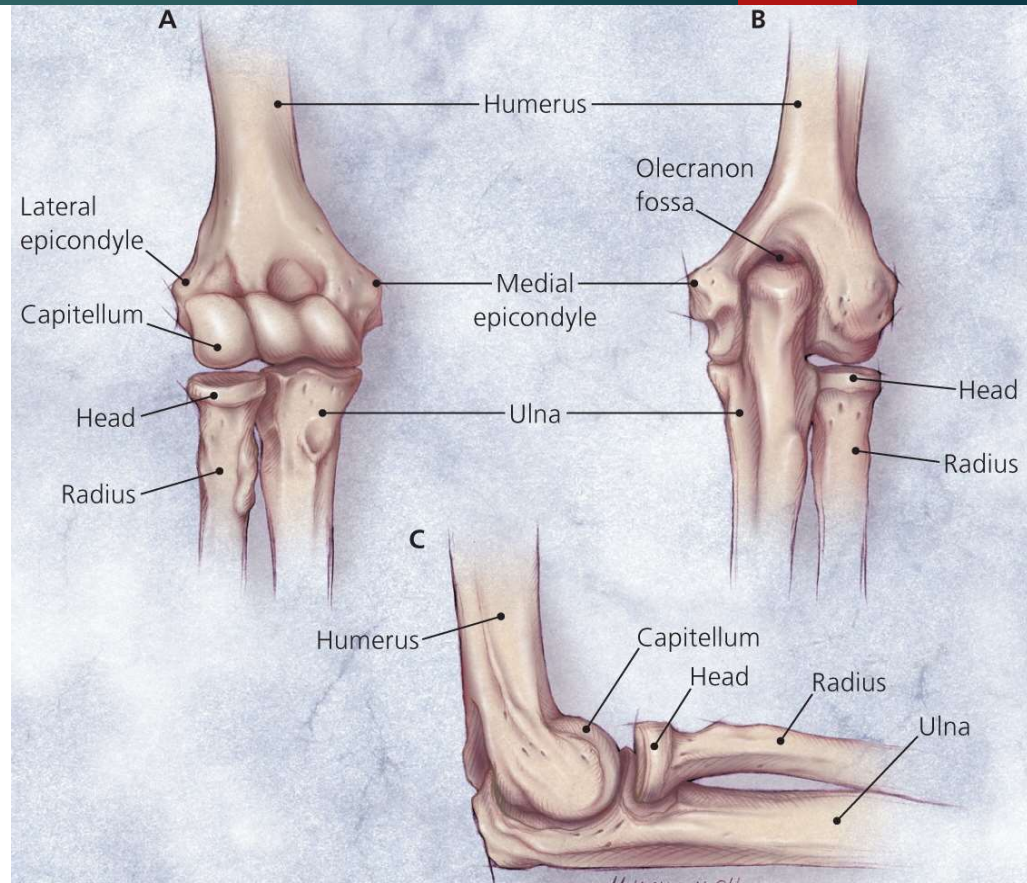
- ▶ The **elbow** is the joint connecting the upper arm to the forearm. It is classed as a hinge-type **synovial** joint.
- ▶ The orientation of the bones forming the elbow joint produces a hinge type synovial joint, which allows for extension and flexion of the forearm.
- ▶ There are three bones that comprise the elbow joint:
  - ❑ the humerus.
  - ❑ the radius.
  - ❑ the ulna.
- ▶ These bones give rise to two joints:
- ▶ **Humeroulnar joint** is the joint between the trochlea on the medial aspect of the distal end of the humerus and the trochlear notch on the proximal ulna.
- ▶ **Humeroradial joint** is the joint between the capitulum on the lateral aspect of the distal end of the humerus with the head of the radius.
- ▶ Mnemonic
  - ❑ Here are two memonics that can help you understand the elbow joint.
  - ❑ **CRAzy TULips**
  - ❑ Capitulum = RAdius
  - ❑ Trochlear = ULnar



(c) Anterior view at the elbow region

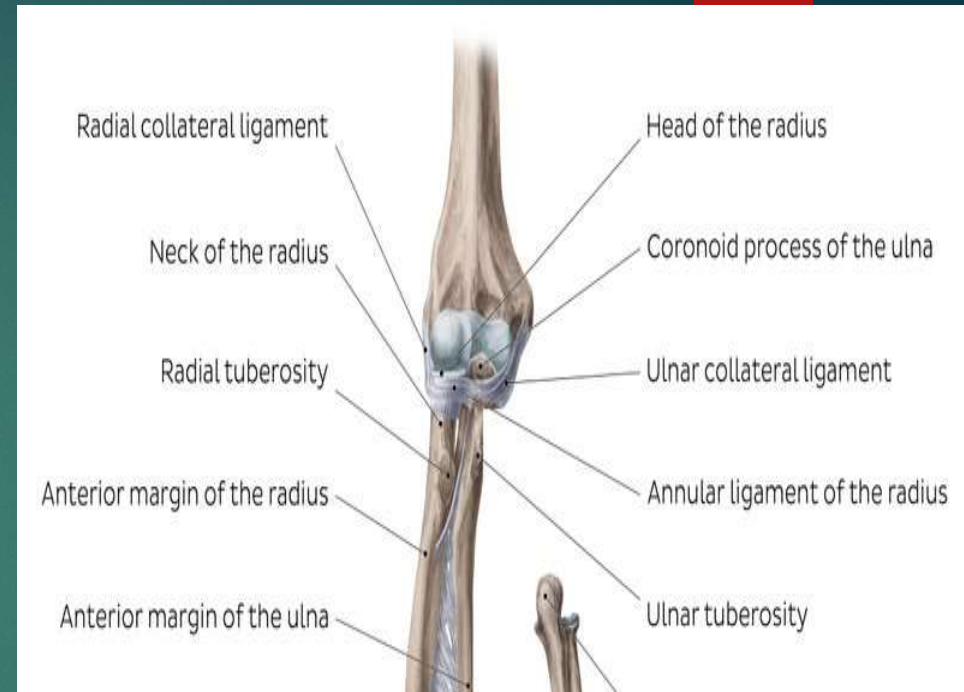


(d) Posterior view of extended elbow

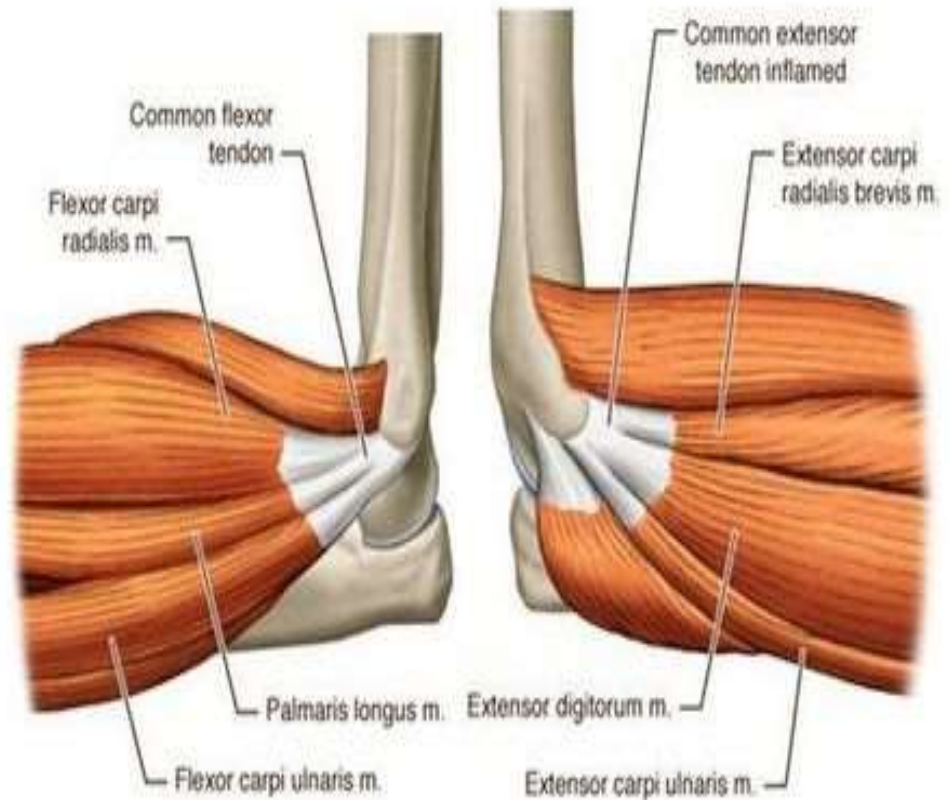
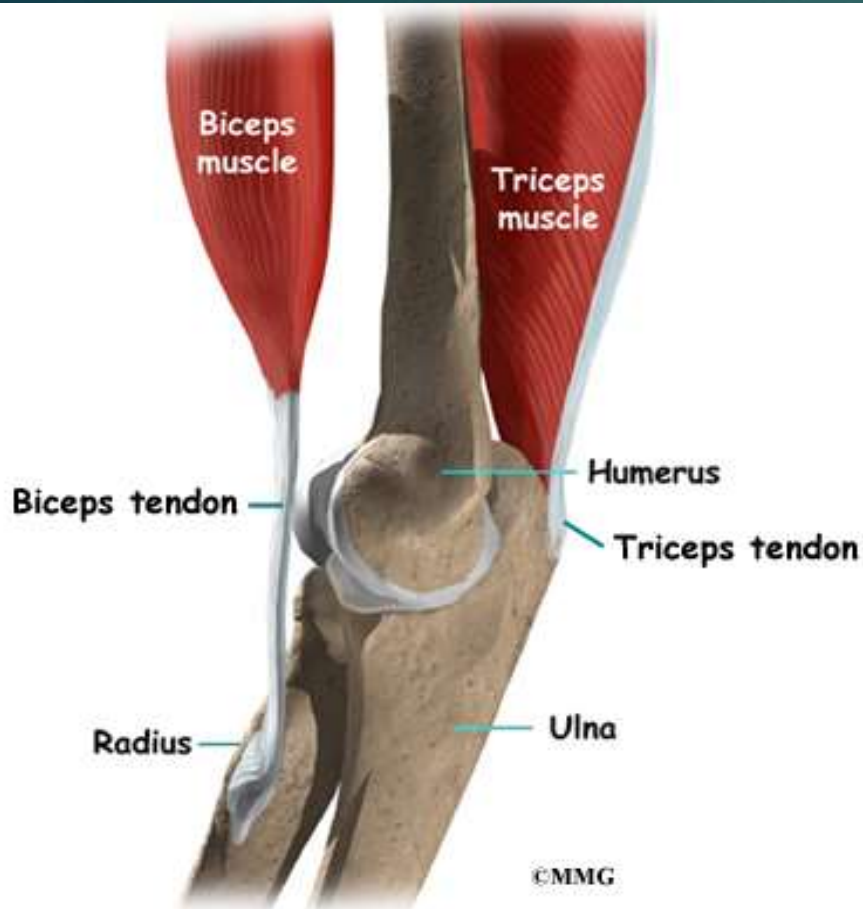

# Ligaments of elbow joint

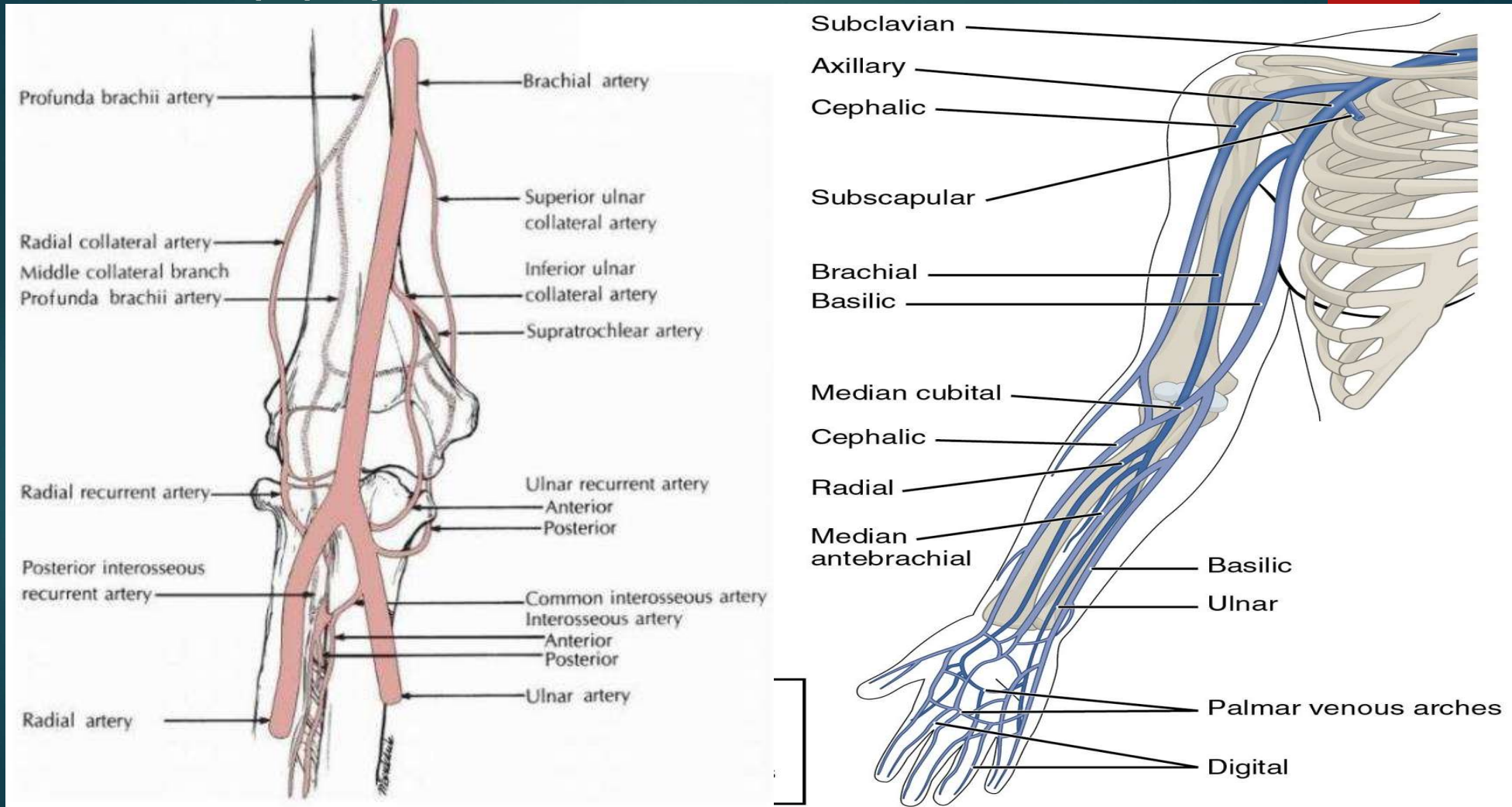
- ▶ **The ulnar collateral ligament** extends from the medial epicondyle of the humerus to the coronoid process of the ulna. It is triangular in shape.
- ▶ **The radial collateral ligament** has a low attachment to the lateral epicondyle of the humerus. The distal fibres blend with the annular ligament that encloses the head of the radius.
- ▶ **The annular ligament** also reinforces the joint by holding the radius and ulna together at their proximal articulation.
- ▶ **The quadrate ligament** is also present at this joint, and maintains constant tension during pronation and supination movements of the forearm.



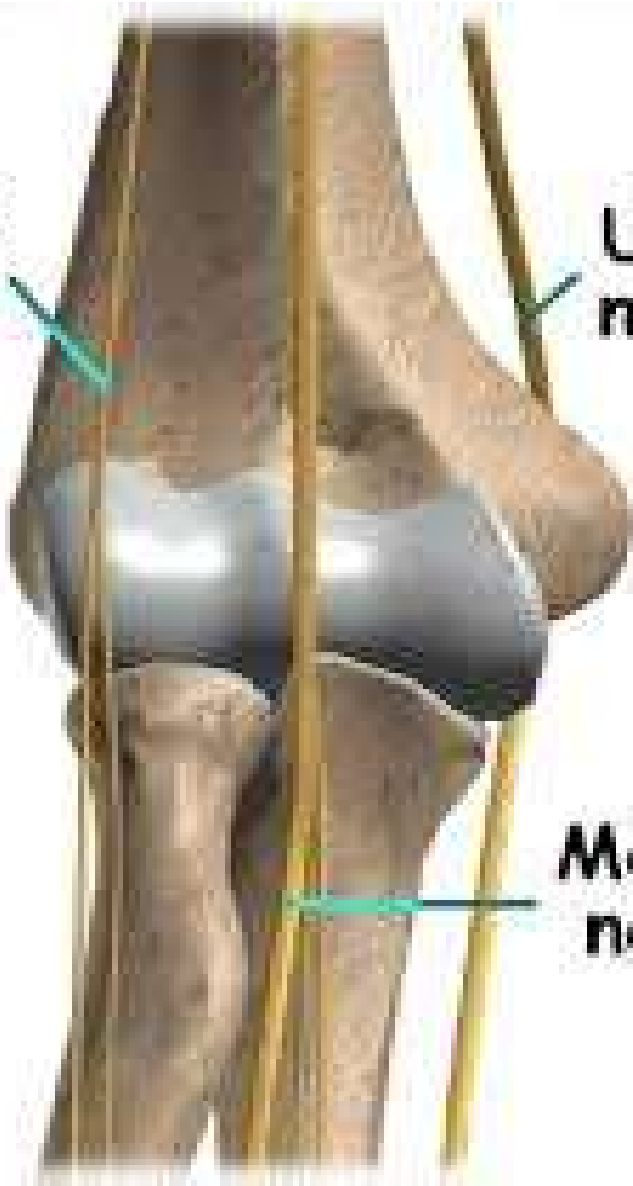# Tendons of elbow joint- 4



# Blood supply



**Radial  
nerve**



**Ulnar  
nerve**

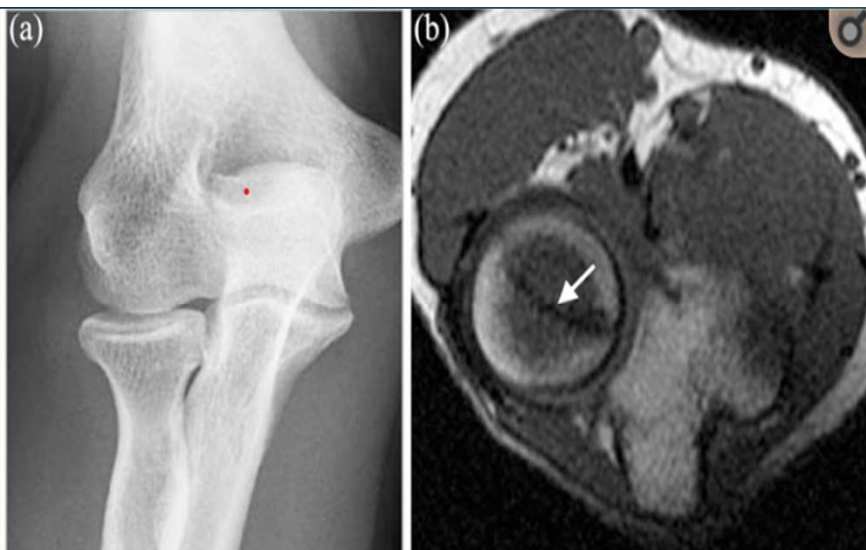
**Median  
nerve**

©2010

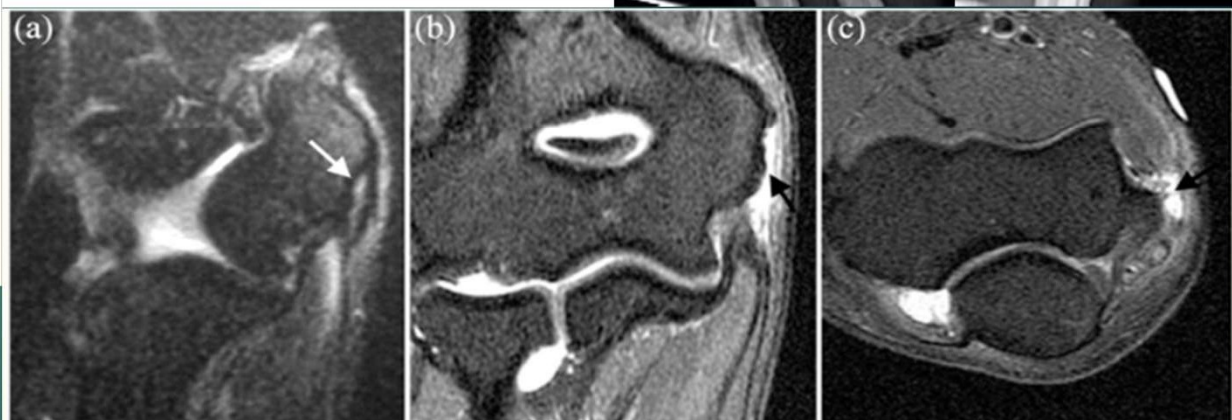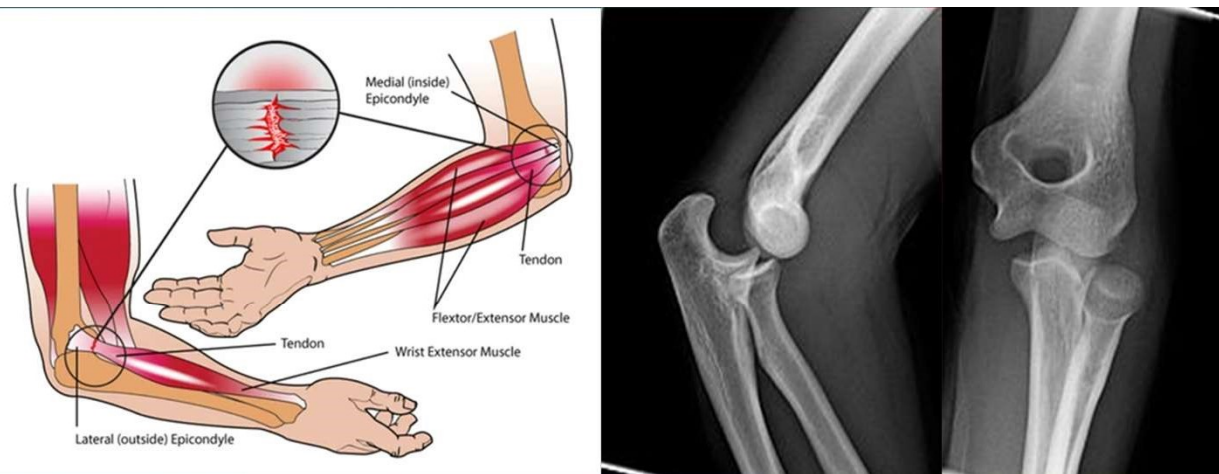
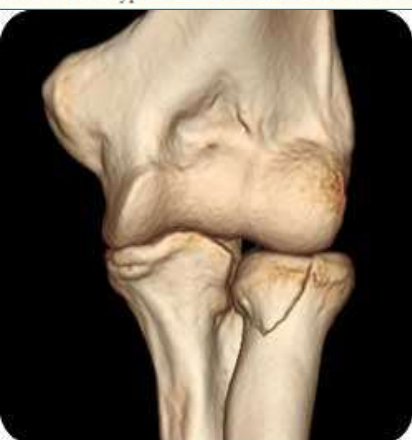Nerve  
supply

# PATHOLOGY

- ▶ **Tendonitis** - Two of the most common injuries at the elbow are overuse injuries: tennis elbow and golfer's elbow. **Golfer's elbow** involves the tendon of the common flexor origin. **Tennis elbow** is the equivalent injury, but at the common extensor origin.
- ▶ **Fractures**
- ▶ **Dislocation**
- ▶ **Infection**
- ▶ **Arthritis**
- ▶ **Bursitis - Olecranon bursitis**, pain in posterior part of elbow, tenderness, warmth, swelling, pain in both flexion and extension
- ▶ **Rheumatoid arthritis** - is a chronic disease that affects joints. It is very common in the wrist, and is most common at the radioulnar joint. It results in pain, stiffness, and deformities.



**Figure 6.**  
Radiographically occult radial head fracture. (a) Anteroposterior radiograph of the elbow in a patient who presented with elbow pain after a fall demonstrates no evidence of fracture. (b) Axial T1-weighted image demonstrates hypointense fracture line of the radial head (arrow).



**Figure 11.**  
Common flexor tendon injuries. (a) Coronal fat-saturated T2-weighted image demonstrates fluid signal within the common flexor tendon origin, consistent with partial tear (arrow). Coronal (b) and axial (c) fat-saturated T2-weighted images from a magnetic resonance arthrogram demonstrate full-thickness tear of the common flexor tendon from the medial epicondyle with tendon retraction and fluid signal in the expected location of the tendon (arrow).

<https://www.ncbi.nlm.nih.gov/pmc/articles/PMC3548664/>



# RADIOLOGICAL INVESTIGATIONS



X RAY

CT

MRI

ULTRASOUND

THANK YOU

