



**Centurion**  
**UNIVERSITY**

*Shaping Lives...*  
*Empowering Communities...*

# CENTURION UNIVERSITY OF TECHNOLOGY AND MANAGEMENT

## **Diseases of the Uveal Tract**



**Centurion**  
**UNIVERSITY**

*Shaping Lives...  
Empowering Communities...*

# Contents ...

- Uveitis
- Anterior Uveitis
- Posterior Uveitis
- Purulent Uveitis
- Rosacea keratitis



Centurion  
UNIVERSITY

Shaping Lives...  
Empowering Communities...

# Classification

- The **Standardization of Uveitis Nomenclature (SUN)** Working Group guidance on uveitis terminology, endorsed by the International Uveitis Study Group (IUSG), categorizes uveitis anatomically
  1. **Anterior**: the anterior chamber is the primary site of inflammation.
  2. **Intermediate**: primarily vitreous inflammation; includes pars planitis.
  3. **Posterior**: retina and/or choroid.
  4. **Panuveitis**: all uveal structures are involved.



Centurion  
UNIVERSITY

Shaping Lives...  
Empowering Communities...

- ✓ An **IUSG clinical classification** based on aetiology is also in use:
  1. **Infectious**: bacterial, viral, fungal, parasitic, others.
  2. **Non-infectious**: with and without a known systemic association.
  3. **Masquerade**: neoplastic and non-neoplastic.
    - **Onset**: sudden or insidious.
    - **Duration**: limited (3 months or less) or persistent.
    - **Clinical course**:
      - ✓ acute (of sudden onset and limited duration),
      - ✓ recurrent (repeated episodes separated by untreated inactive periods), or
      - ✓ chronic (persistent duration, with relapse less than 3 months after discontinuation of treatment).

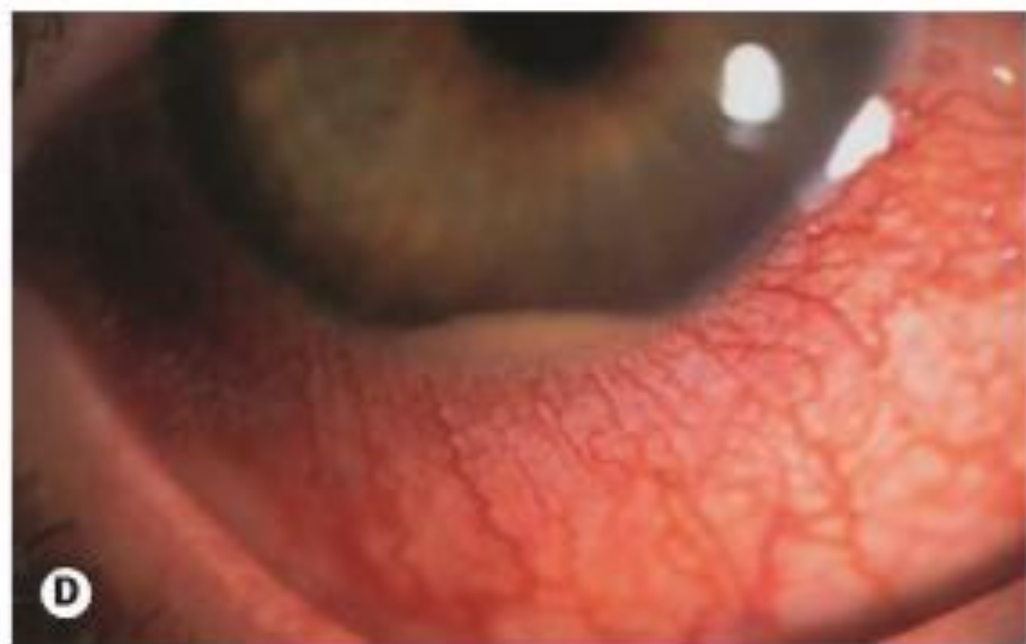
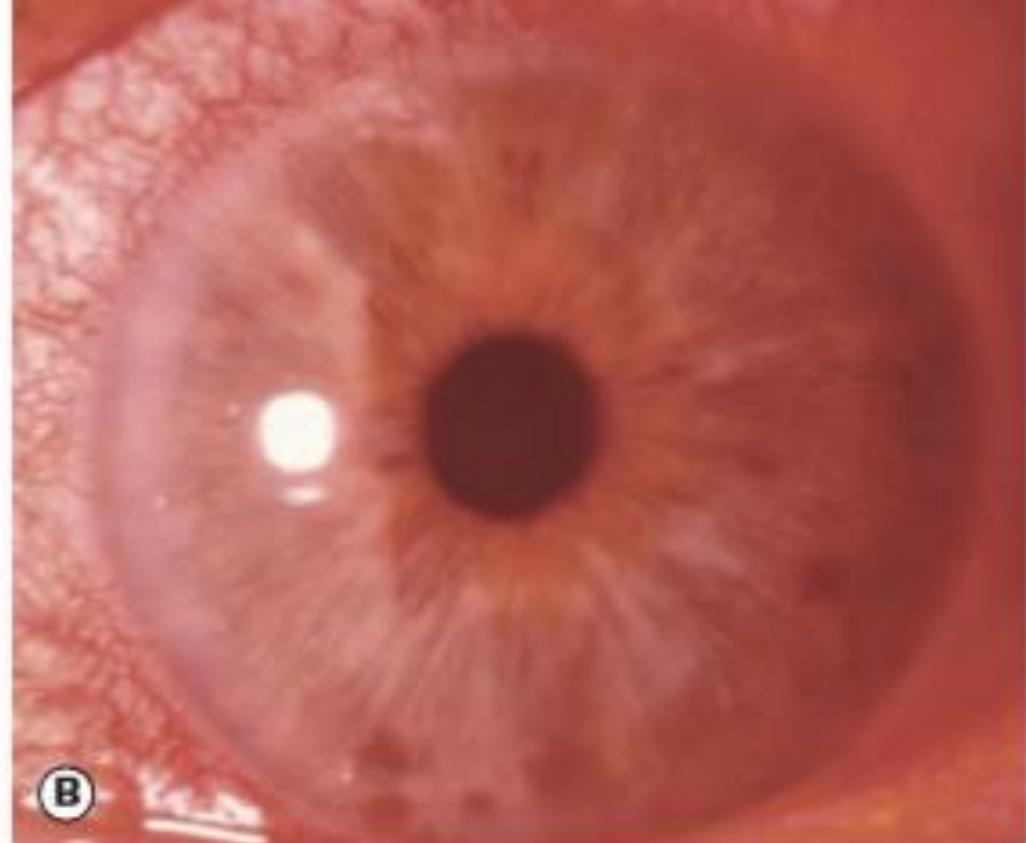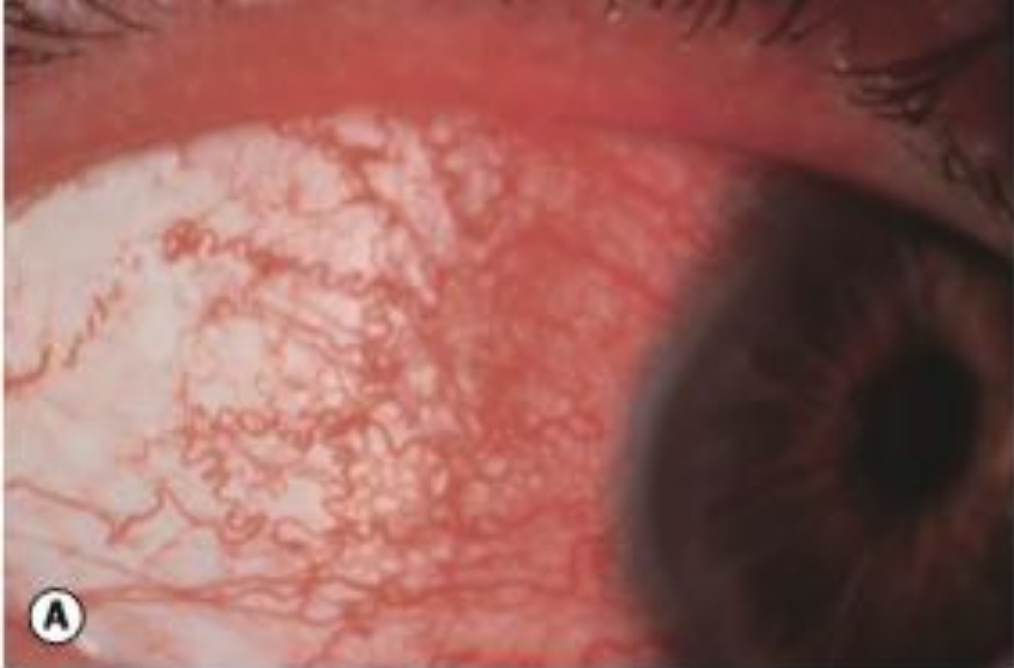


**Centurion**  
**UNIVERSITY**

*Shaping Lives...  
Empowering Communities...*

# ANTERIOR UVEITIS

- **Anterior uveitis** is inflammation involving the anterior uveal tract – the iris and the anterior part (pars plicata) of the ciliary body – and is the most common form of uveitis.
- **Iritis** refers to inflammation primarily involving the iris, and iridocyclitis to involvement of both the iris and anterior ciliary body; in practice these are interchangeable as they cannot be distinguished clinically.
- **Chronic anterior uveitis** (CAU) is less common than AAU. It is more commonly bilateral, and associated systemic disease is more likely. Granulomatous inflammatory signs (see below) are often present.



**Fig. 11.2** Signs of acute anterior uveitis. (A) Ciliary injection; (B) miosis; (C) anterior chamber cells in mild anterior uveitis; (D) hypopyon.



**Centurion**  
**UNIVERSITY**

*Shaping Lives...  
Empowering Communities...*

# Continue...

- Acute anterior uveitis (AAU) is the most common presentation, of which HLA-B27-related and idiopathic forms make up the largest proportion.
- Aetiology in these cases is uncertain, but may involve cross-reactivity with particular microbial antigens in genetically predisposed individuals.
- AAU can be a feature of a wide variety of ocular conditions such as trauma (including surgery), lens-related inflammation and herpes simplex infection, or can be secondary to inflammation elsewhere in the eye, such as bacterial keratitis and scleritis.
- AAU can also be the presenting clinical scenario, without accompanying intermediate or posterior uveitis, in a range of systemic conditions includ



**Centurion**  
**UNIVERSITY**

*Shaping Lives...  
Empowering Communities...*

# Continue...

- The prognosis is usually good in most idiopathic and HLA-B27 related AAU provided management is adequate. Outcomes are more variable in CAU and in cases where there is an underlying ocular or systemic disorder



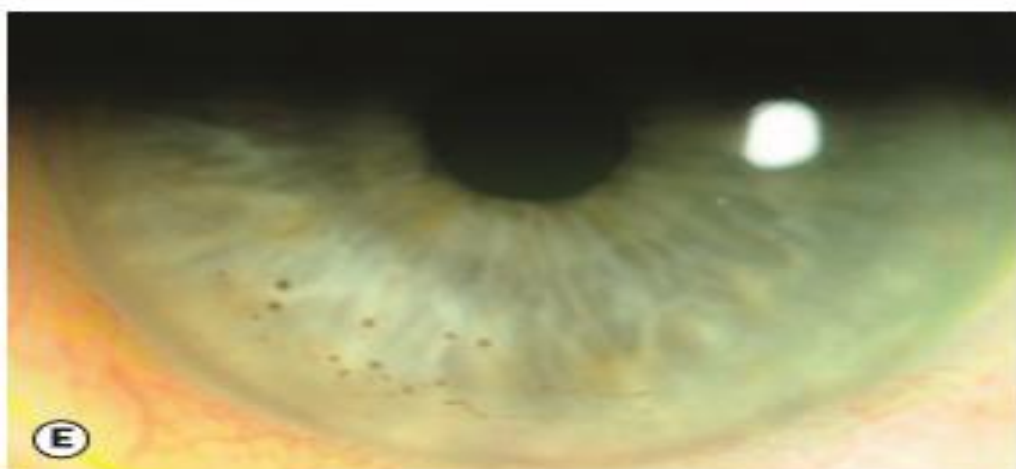
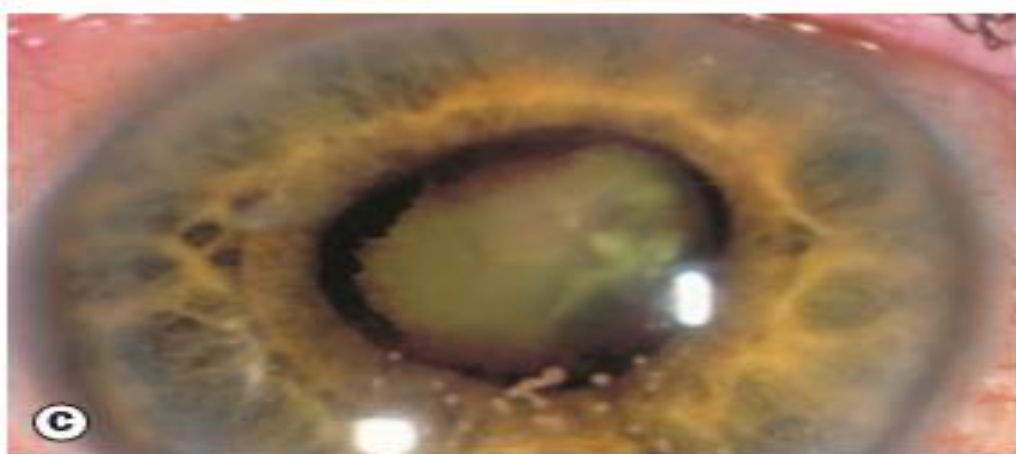
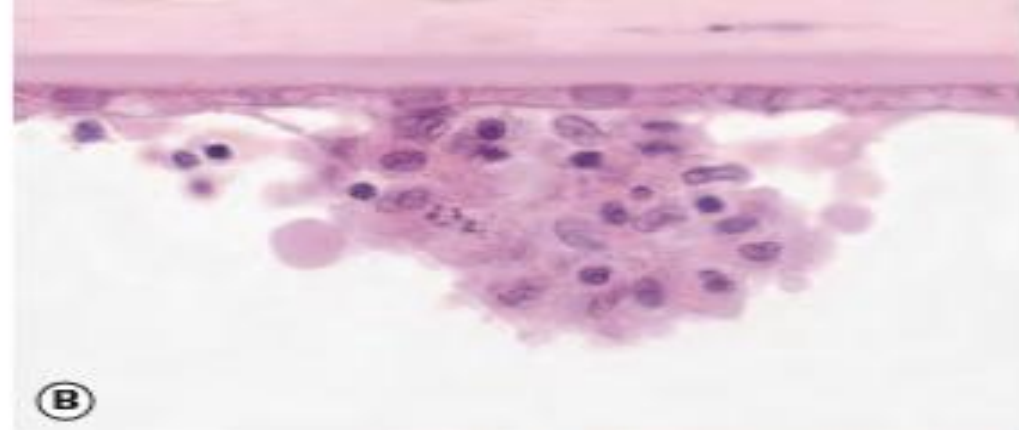


**Centurion**  
**UNIVERSITY**

*Shaping Lives...  
Empowering Communities...*

# Clinical features

- **Symptoms:** In AAU consist of the rapid onset of unilateral pain, photophobia, redness and watery discharge, sometimes preceded by mild ocular discomfort for a few days. Blurring of vision is related to severity.
- Visual acuity is variably impaired depending on the severity of inflammation and the presence of complications. It is frequently only mildly reduced in AAU.
- Miosis due to pupillary sphincter spasm predisposes to the formation of posterior synechiae.



**Fig. 11.3** Keratic precipitates (KP). **(A)** Highly magnified view of fresh KP in early anterior uveitis; **(B)** histology showing typical aggregate of inflammatory cells on the corneal endothelium; **(C)** large 'mutton fat' keratic precipitates; **(D)** stellate KPs in Fuchs uveitis syndrome; **(E)** old pigmented granulomatous KP; **(F)** endothelial cellular 'dusting' and early KP formation (Courtesy of J Harry and G Misson, from *Clinical Ophthalmic Pathology*, Butterworth-Heinemann 2001 - Fig. B)



**Centurion**  
**UNIVERSITY**

*Shaping Lives...  
Empowering Communities...*

# Continue...

- **Anterior chamber cells** are a dependable indicator of inflammatory activity. Grading (SUN Working Group) is performed by estimating the number of cells in a 1 mm by 1 mm slit beam field, employing adequate light intensity and magnification.
- This must be performed before pupillary dilatation, which can lead to shedding of pigment cells into the aqueous. Inflammatory cells are commonly also seen in the anterior vitreous.
- **Hypopyon** refers to a whitish purulent exudate composed of myriad inflammatory cells in the inferior part of the anterior chamber.



Centurion  
UNIVERSITY

Shaping Lives...  
Empowering Communities...

# Continue...

- **Keratic precipitates (KP)** are deposits on the corneal endothelium composed of inflammatory cells such as lymphocytes, plasma cells and macrophages.
- They are usually concentrated inferiorly, often in a triangular pattern with the apex pointing up (Arlt triangle) under the influence of gravity and aqueous convection currents; a notable exception is Fuchs uveitis syndrome (FUS), in which they are diffusely distributed.
- **Aqueous flare** is haziness of the normally clear fluid in the anterior chamber, reflecting the presence of protein due to breakdown of the blood–aqueous barrier.
- **Fibrinous exudate** in the anterior chamber is common in severe AAU, and as with hypopyon is often seen with HLA-B27-related inflammation.



Centurion  
UNIVERSITY

Shaping Lives...  
Empowering Communities...

# Continue...

- **Iris nodules:** Koeppe nodules are located on the pupillary margin, and may be the site of posterior synechiae formation.
- **Posterior synechiae (PS)** are inflammatory adhesions between the pupil margin and the anterior lens capsule (Figs 11.6A and B), and may be particularly likely to form at the location of koeppe nodule.
- **Iris atrophy** may offer useful diagnostic clues. Diffuse stromal atrophy is seen in FUS, and patchy or sectoral atrophy can occur in herpetic uveitis; both patterns may be seen in both simplex and zoster-related inflammation, though the latter is said to more commonly give a sectoral pattern.



Centurion  
UNIVERSITY

Shaping Lives...  
Empowering Communities...

# Continue...

- **Heterochromia iridis** refers to a difference in colour between the iris of the two eyes, best seen in daylight. In the context of uveitis, heterochromia characteristically occurs in FUS.
- **Iris neovascularization (rubeosis iridis)** can occur, particularly in chronic inflammation. The process tends to be less acute than with a primary vascular cause such as central retinal vein occlusion.
- **Intraocular pressure (IOP)** may be reduced as the result of impairment of aqueous secretion by the ciliary epithelium, or elevated due to a variety of mechanisms including therapeutic steroids.



**Centurion**  
**UNIVERSITY**

*Shaping Lives...  
Empowering Communities...*

# Continue...

- Posterior segment examination should always be performed to detect a masquerading cause of anterior uveitis.



**Centurion**  
**UNIVERSITY**

*Shaping Lives...  
Empowering Communities...*

# Investigation

- Investigations are often negative, with no clear underlying cause determined in many patients. Rather than performing a battery of screening tests, investigation is tailored to each patient, directed by clinical features.
- A single episode of unilateral mild/moderate (no hypopyon) non-granulomatous AAU with no ocular or systemic suggestion of underlying disease.
- Typical clinical features of a specific entity for which investigation is not usually indicated (e.g. FUS).
- A systemic diagnosis compatible with the clinical features (e.g. sarcoidosis) has already been confirmed.





**Centurion**  
**UNIVERSITY**

*Shaping Lives...  
Empowering Communities...*

# Continue...

- **Recurrent AAU.**
- **Severe AAU.**
- **Bilateral AAU.**
- Anterior uveitis that is persistent, chronic or resistant to treatment.
- Granulomatous inflammatory signs (note that granulomatous conditions may give non-granulomatous AAU).
- Associated intermediate or posterior uveitis.
- Ocular or systemic clinical features suggesting underlying disease.



**Centurion**  
**UNIVERSITY**

*Shaping Lives...  
Empowering Communities...*

# Continue...

- Some authorities advocate routine syphilis serology for all uveitis patients at first presentation; a history of high-risk sexual behaviour in particular must prompt this.
- Repeating targeted previously negative investigations several years later is sometimes fruitful.



Centurion  
UNIVERSITY

Shaping Lives...  
Empowering Communities...

# Syphilis serology

- **Treponemal antibody tests such as the ELISA** (enzymelinked immunosorbent assay) are highly sensitive and specific, but take around 3 months to become positive.
- **Non-specific titratable cardiolipin antibody tests such as the rapid plasma reagin (RPR) or venereal disease research laboratory (VDRL)** are more commonly positive in early infection, and are used to help monitor disease activity; they become negative over time, typically in treated disease. False-positive results can occur.
- **Serum angiotensin-converting enzyme (ACE)**: a nonspecific test that indicates the presence of a granulomatous disease such as sarcoidosis, tuberculosis and leprosy. Elevation occurs in up to 80% of patients with acute sarcoidosis but may be normal during remissions.



**Centurion**  
**UNIVERSITY**

*Shaping Lives...  
Empowering Communities...*

- **Lysozyme** is a group of enzymes found in polymorphonuclear neutrophils and numerous secretions including tears.
- **Erythrocyte sedimentation rate (ESR) and C-reactive protein (CRP)**: acute-phase reactants that are probably of limited value, but may be elevated in a range of systemic inflammatory disorders.
- **Complete blood count**: leukocytosis may raise suspicion of infection and, exceptionally, haematological malignancy. Eosinophilia may occur in parasitic infection.
- **Lyme disease**: serology may be considered, particularly in endemic areas. Serology for other infectious diseases such as brucellosis and leptospirosis can be requested if relevant risk factors are present.



Centurion  
UNIVERSITY

Shaping Lives...  
Empowering Communities...

- **Antinuclear antibody (ANA)**: limited use, except in children. In those with juvenile idiopathic arthritis (JIA) its presence is associated with a higher risk of CAU.
- **Antineutrophil cytoplasmic antibody (ANCA)**: limited use in anterior uveitis unless associated with scleritis and/or peripheral ulcerative keratitis, when cytoplasmic ANCA (c-ANCA) testing should be considered.
- **Interferon-gamma release assay** (e.g. QuantiFERON-TB Gold) blood test for tuberculosis.
- **HIV serology**: indicated for selected patients, usually those in whom an opportunistic infection has been diagnosed or is suspected.
- **Sacroiliac joint X-ray** may show evidence of sacroiliitis in ankylosing spondylitis and other seronegative spondyloarthropathies.



**Centurion**  
**UNIVERSITY**

*Shaping Lives...  
Empowering Communities...*

# Continue...

- **Chest X-ray** may show evidence of sarcoidosis or tuberculosis; a high level of suspicion for both of these treatable conditions (as well as syphilis) should always be adopted, particularly if inflammation is granulomatous.



Centurion  
UNIVERSITY

Shaping Lives...  
Empowering Communities...

# Ocular imaging

- **B-scan ultrasonography**, if the posterior segment view is compromised by very small pupils or opaque media.
- **Optical coherence tomography (OCT)** may reveal posterior segment complications such as cystoid macular oedema and epiretinal membrane.
- **Fundus autofluorescence (FAF)** may demonstrate suspected posterior segment pathology as the lesions of several inflammatory conditions, such as multiple evanescent white dot syndrome (MEWDS), which may give mild anterior chamber inflammation, are often shown more effectively than on clinical examination.



**Centurion**  
**UNIVERSITY**

*Shaping Lives...  
Empowering Communities...*

- **Fluorescein angiography (FA)** is useful in some cases of anterior uveitis such as the confirmation or exclusion of suspected posterior segment pathology, e.g. vasculitis, white dot syndromes, or identifying macular ischaemia as the cause of reduced vision if no macular abnormality is visible on OCT.
- **Indocyanine green angiography (ICGA)** is rarely indicated in anterior uveitis, but might be used to look for subtle associated choroidal pathology.
- **Ultrasound biomicroscopy (UBM)** is particularly indicated in cases of hypotony, and may demonstrate pathology such as subtle choroidal effusion, cyclodialysis cleft and cyclitic membrane.
- **Iris biopsy** is rarely performed.
- **Vitreous biopsy** tends to be confined to the investigation of obscure posterior segment inflammation and suspected infectious endophthalmitis.





Centurion  
UNIVERSITY

Shaping Lives...  
Empowering Communities...

# Continue...

- **Aqueous tap:** historically rarely performed in anterior uveitis, but viral causes are now recognized as being more frequent than previously realized. Herpesviruses (including cytomegalovirus) and rubella in particular should be considered in clinically suspicious cases, especially unexplained hypertensive uveitis and cases relatively unresponsive to topical steroids.
- **Conjunctival biopsy:** sampling of tissue such as a suspected granuloma or infiltrative lesion is occasionally indicated.



**Centurion**  
**UNIVERSITY**  
*Shaping Lives...  
Empowering Communities...*

# Topical steroids

- **Prednisolone 1% or dexamethasone 0.1%** is commonly utilized as a first choice.
- Treatment of AAU initially involves instillation at a frequency appropriate to the severity of inflammation.
- Treatment of CAU is generally targeted at complete suppression of inflammation, with no anterior chamber cellular activity or flare – the latter is now thought to be an indicator of active inflammation in most or all cases.
- Common complications of topical steroids include transient elevation of IOP in susceptible individuals.
- Cycloplegic agents. These are used in AAU and in exacerbations of CAU to prevent the formation of posterior synechiae (PS), to break down recently formed synechiae and to promote comfort by relieving spasm of the pupillary and ciliary muscle.



**Centurion**  
**UNIVERSITY**

*Shaping Lives...  
Empowering Communities...*

# Continue...

- Mydricine® No. 2. This is a preparation containing adrenaline and atropine that is used to try to break fresh PS when drops are ineffective; it also contains local anaesthetic to improve comfort.
- Tissue plasminogen activator (TPA). In severe fibrinous anterior uveitis 12.5–25 µg of TPA in 0.1 ml injected into the anterior chamber (intracamerally) with a 30-gauge needle under topical anaesthesia will dissolve dense fibrinous exudate and may break down recently formed PS.
- Subconjunctival steroid can be administered in severe cases or to patients in whom poor compliance is likely.



Centurion  
UNIVERSITY

Shaping Lives...  
Empowering Communities...

- **Regional steroid injection.** The use of an inferior approach ('orbital floor') or posterior sub-Tenon injection of depot steroid preparations (e.g. triamcinolone acetonide, methylprednisolone acetate) is common in the treatment of posterior segment inflammation, but is generally reserved in anterior uveitis patients for the treatment of cases complicated by cystoid macular oedema (CMO), and for patients noncompliant with topical administration.
- **Intraocular steroids.** Intravitreal triamcinolone acetonide (4 mg in 0.1 ml, i.e. one-tenth of the orbital dose) is occasionally used in anterior uveitis for CMO unresponsive to other forms of therapy (see Fig. 13.34E), and rarely may be considered at the time of intraocular surgery in high risk anterior uveitis patients.



**Centurion**  
**UNIVERSITY**

*Shaping Lives...  
Empowering Communities...*

- Systemic steroids are very rarely required for anterior uveitis but may be needed where the response to less aggressive treatment is inadequate.
- Non-steroidal anti-inflammatory drugs (NSAIDs) such as naproxen and tolmetin may be effective in CAU and can be used long-term under appropriate specialist physician supervision.
- Antimetabolites such as methotrexate are generally not required in the treatment of anterior uveitis, though may be necessary in exceptional patients such as juvenile idiopathic arthritis-associated CAU when other measures fail to control inflammation, or as a steroid-sparing measure.



Centurion  
UNIVERSITY

Shaping Lives...  
Empowering Communities...

# Intermediate uveitis

**Symptoms:** are initially floaters and later impairment of visual acuity due to cystoid macular oedema.

**Signs:** Cellular infiltration of the vitreous with fewer cells in the anterior chamber. Absence of focal inflammatory lesions in the posterior fundus.

**Complications:** include cystoid macular oedema. cyclitic membrane formation. cataract and tractional retinal detachment.



Centurion  
UNIVERSITY

Shaping Lives...  
Empowering Communities...

# Posterior uveitis

## Symptoms:

These are floaters and impaired vision. patient with inflammatory peripheral inflammatory lesion will complain of floaters and may have only minimal blurring of vision on the other hand. active choroiditis involving the fovea or papillomacular bundle. with primarily cause loss of central vision. and patient may not notice vitreous opacities.

## Signs

- **Vitreous** signs include cells. Flare, opacities and posterior vitreous detachment. The posterior hyaloic face may be covered by inflammatory precipitates comparable to KP.



**Centurion**  
**UNIVERSITY**

*Shaping Lives...  
Empowering Communities...*

# Continue...

- **Choroiditis** is characterized by deep, yellow or grayish patches with fairly well-demarcated borders. Inactive lesions appear as white, well-defined areas of chorioretinal atrophy with pigmented borders.







**Centurion**  
**UNIVERSITY**

*Shaping Lives...  
Empowering Communities...*

# Continue...

- Retinitis gives the retina white cloudy appearance. with formation of retinal. The outline of the inflammatory focus is indistinct. rendering exact demarcation between healthy and affected retina difficulties.
- Vasculitis most frequently involves retinal veins and less commonly arteries.
- 'Spill-over' anterior uveitis is common.



Centurion  
UNIVERSITY

*Shaping Lives,  
Empowering Communities.*

# Complications

- These include direct involvement of the macula by the inflammatory process. cystoid macular oedema. macular ischaemia. epiretinal membrane formation. vascular occlusions. choroidal neovascularization. retinal detachment and consecutive optic neuropathy.



Centurion  
UNIVERSITY

Shaping Lives...  
Empowering Communities...

# Morphological Classifications

**Focal** In which there is a solitary inflammatory focus e.g. toxoplasmosis.

**Multifocal** in which there are several separate foci e.g. birdshot retinochoroidopathy.

**Geographical** in which there is a large confluent area of inflammation e.g. cytomegalovirus retinitis.



Centurion  
UNIVERSITY

Shaping Lives...  
Empowering Communities...

# Treatment

- **Mydriatics**

## Preparations

### Short acting:

Tropicamide (0.5% and 1%,..) has a duration of 6 hours.

Cyclopentolate 0.5 and 1% has a duration of 24 hours.

Phenylephrine (2.5% and 10%) has a duration of 1 hours but no cycloplegic effects.

**Long-acting:** atropine 1% is the most powerful cycloplegic and mydriatic with a duration of action lasting up to 2 weeks.



Centurion  
UNIVERSITY

Shaping Lives...  
Empowering Communities...

Continue...

- **For specific infective etiology** 
  - Treatment for toxoplasmosis .
  - Treatment for toxocariasis.
  - AT drugs, etc. with systemic steroids if necessary.
- **Idiopathic posterior uveitis** 
  - **Systemic corticosteroids:** Oral prednisolone—1–1.5 mg/kg body weight/day, then in tapering doses.
  - Posterior sub-Tenon injections of depot steroid.
  - Rarely, immunosuppressive agents.

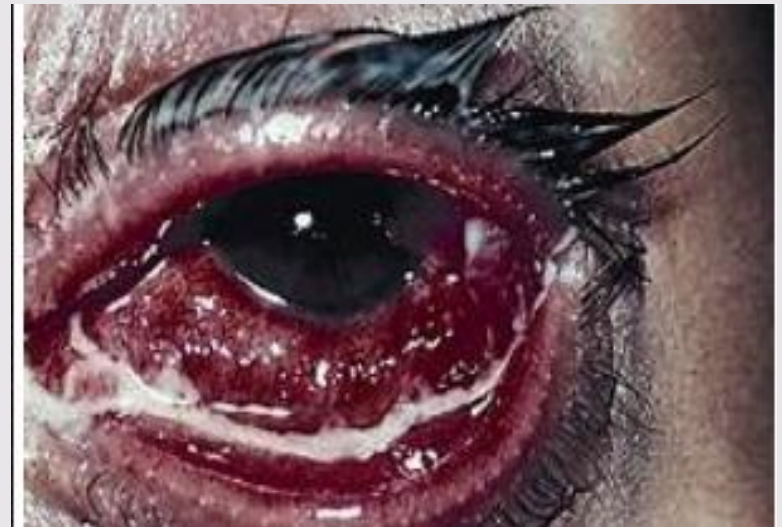

**Centurion**  
**UNIVERSITY**

*Shaping Lives...  
Empowering Communities...*

# Purulent uveitis

- It is the severe form of uveitis which involves the whole uveal tract.
- Common causes are as follows:
  - Sympathetic ophthalmitis
  - Vogt-Koyanagi-Harada syndrome
  - Sarcoidosis
  - Behcet's disease.





**Centurion**  
**UNIVERSITY**

*Shaping Lives...*  
*Empowering Communities...*

# **DISEASES OF THE CORNEA**

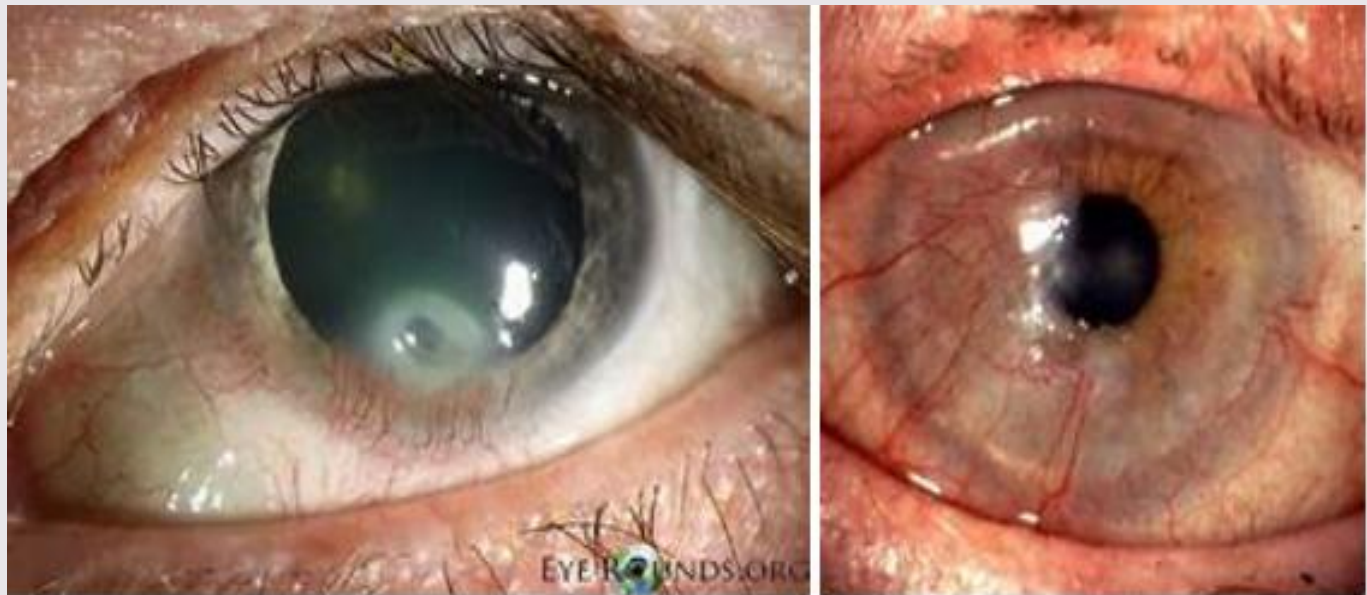


**Centurion**  
**UNIVERSITY**

*Shaping Lives...  
Empowering Communities...*

# ROSACEA KERATITIS

- Corneal ulceration is seen in about 10 percent cases of acne rosacea, which is primarily a disease of the sebaceous glands of the skin.







Centurion  
UNIVERSITY

Shaping Lives...  
Empowering Communities...

## Clinical features

1. The condition typically occurs in elderly women in the form of **facial eruptions** presenting as butterfly configuration, predominantly involving the malar and nasal area of face.
2. **Ocular lesions** include chronic blepharoconjunctivitis and keratitis. Rosacea keratitis occurs as yellowish white marginal infiltrates, and small ulcers that progressively advance across the cornea and almost always become heavily vascularised.



**Centurion**  
**UNIVERSITY**

*Shaping Lives...  
Empowering Communities...*

# Treatment

## **1. Local treatment.**

Rosacea keratitis responds to topical steroids, but recurrences are very common.

## **2. Systemic treatment.**

The essential and most effective treatment of rosacea keratitis is a long course of systemic tetracycline (250 mg QID × 3 weeks, TDS × 3 weeks, BID × 3 weeks, and once a day for 3 months).



**Centurion**  
**UNIVERSITY**

*Shaping Lives...  
Empowering Communities...*

- Clinical ophthalmology, Author: Jack J Kanski ;Publishers: Elsevier ,Edition no:4<sup>th</sup> and 8<sup>th</sup> edition.
- Essentials of ophthalmology. Author: Samar K Bosak. Publishers: Jaypee; Edition no:6<sup>th</sup> edition.



**Centurion**  
**UNIVERSITY**  
*Shaping Lives...*  
*Empowering Communities...*

# Thank you