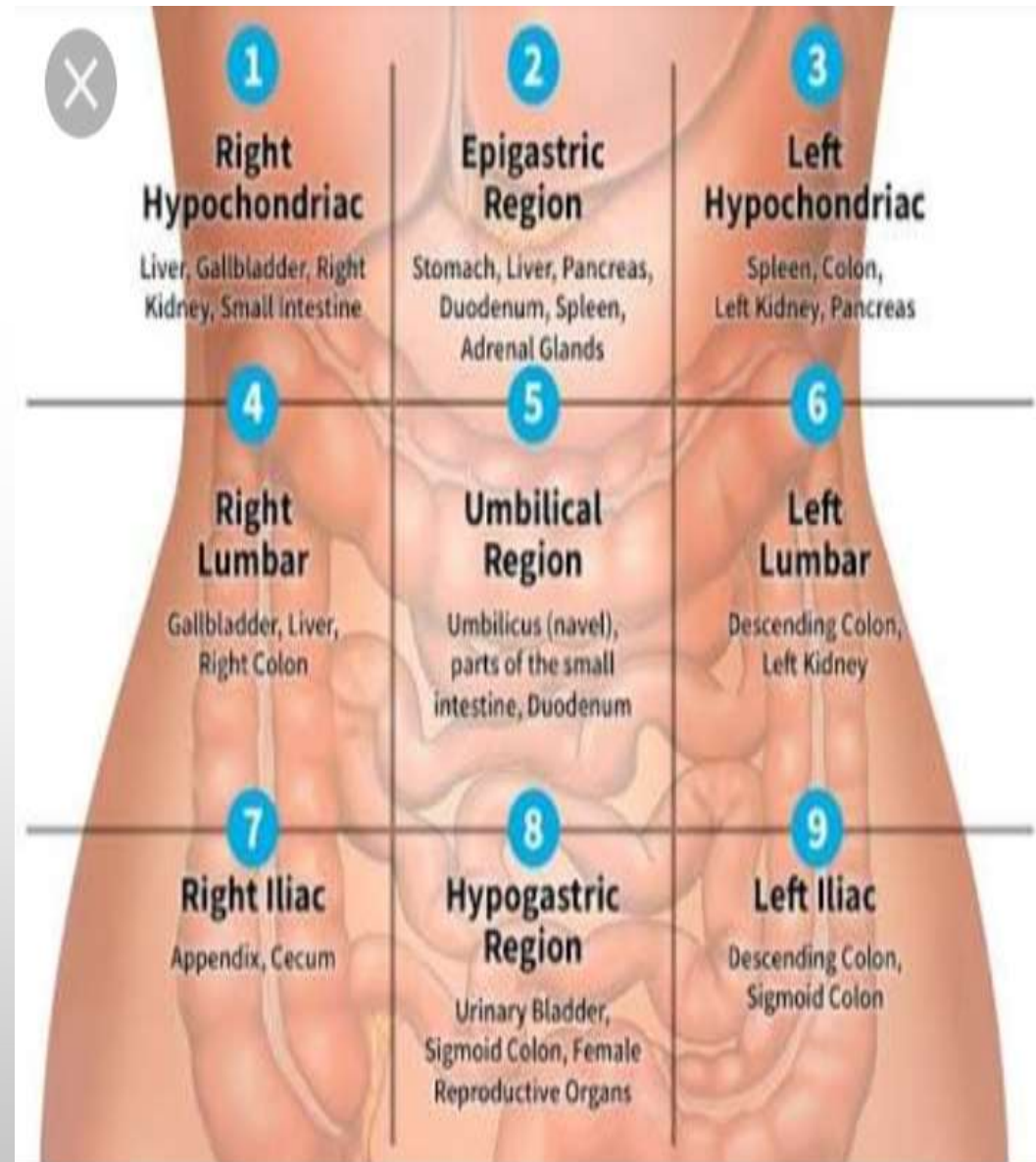


The background of the slide is a light gray gradient with several realistic water droplets of various sizes scattered across it. The droplets have highlights and shadows, giving them a three-dimensional appearance.

ABDOMEN X RAYS
BY
MR.S.S.SIVA SAGAR
TEACHING ASSISTANT
RADIOLOGY
CENTURIAN UNIVERSITY

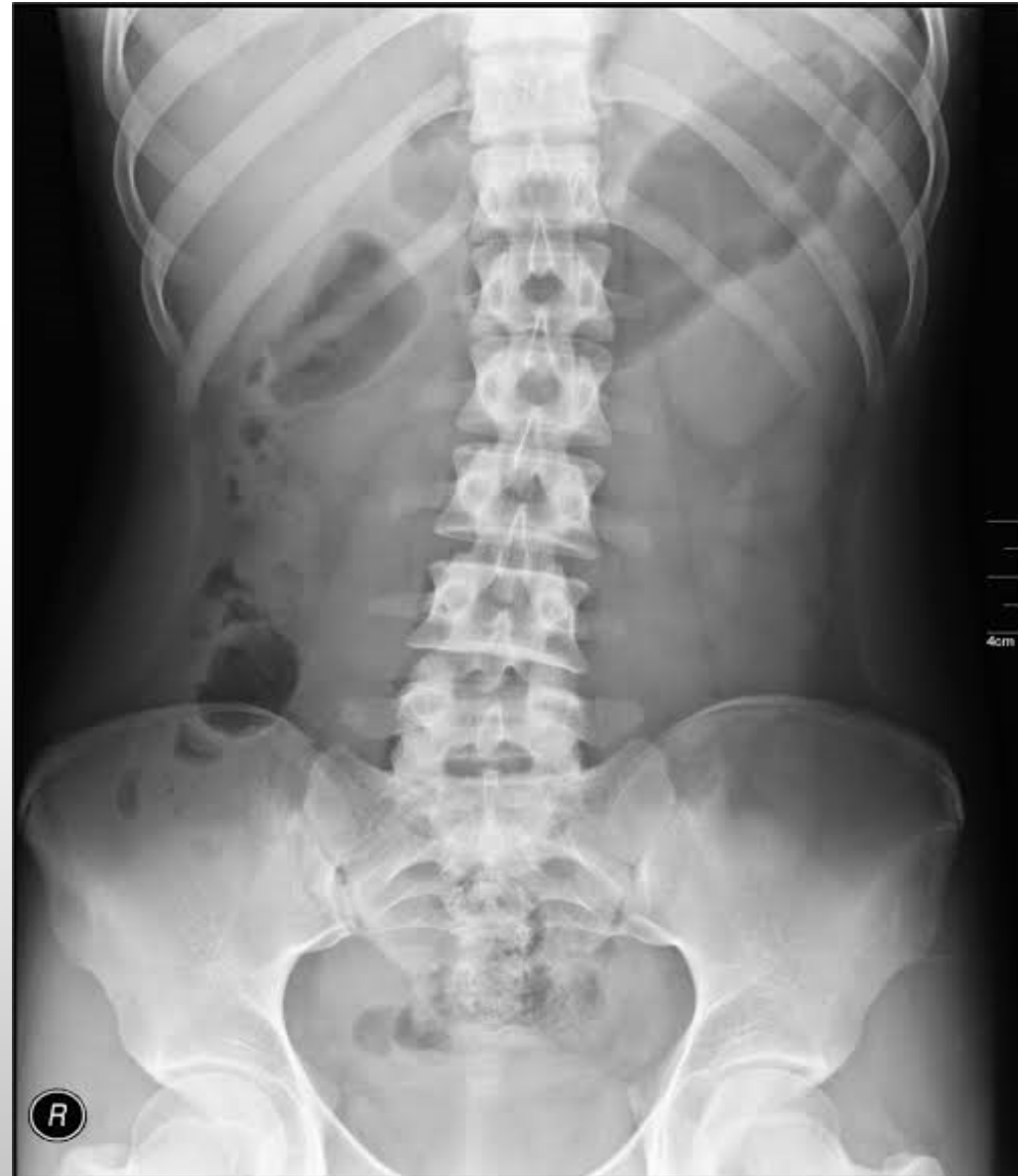VIEWS

- **KUB**
- **SUPINE ABDOMEN.**
- **LATERAL ABDOMEN.**
- **ERECT ABDOMEN.**
- **LATERAL DECUBITUS ABDOMEN.**
- **SUPINE DECUBITUS ABDOMEN.**




KUB INDICATIONS

- **ABDOMINAL PAIN.**
- **ABDOMINAL TENDERNESS.**
- **CLCIFICATIONS IN URINARY TRACT.**
- **POST OP CASES (DJ STENT INSITU)**




KUB PREPARATION

- **GIVE LAXATIVE DRUGS LIKE DISTILIN AND DULCOLAX.**
- **GIVE CASTOR OIL (40 TO 50 ML) TO PATIENT AND DRINK AT NIGHT BEFORE SLEEPING.**
- **ADIVCE SOFT DIET AT NIGHT LIKE DAL AND CHAPATHI.**
- **24 HRS PREPARATION IS REQUIRED FOR KUB.**
- **THE BOWEL HAS NO GASES , THE X RAY RESOLUTION INCREASES AND AVOID OVERLAPPING OF GAS OVER STRECTURES.**



ERECT ABDOMEN INDICATIONS

SHOULD INCLUDE THE DIAPHRAGMS AND THE SYMPHYSIS PUBIS.

- **SUSPECTED GASTROINTESTINAL PERFORATION.**
 - **POSITION OF ANY MEDICAL DEVICES LIKE PERITONEAL TUBE.**
 - **POST OP CASES.**
 - **LOOK FOR FLUID LEVELS AND FREE GAS**
 - **ASCITIS.**
 - **PNEUMOPERITONIUM.**
- 

SUPINE ABDOMEN INDICATIONS

THE ROUTINE X-RAY PROJECTION IS THE SUPINE ABDOMINAL FILM AND SHOULD INCLUDE THE DIAPHRAGMS AND THE SYMPHYSIS PUBIS.

- **PAIN AND TENDERNESS**
- **SUSPECTED BOWEL OBSTRUCTION.**
- **DILATED BOWEL.**
- **SUSPECTED ABDOMINAL MASS.**
- **FOREIGN BODIES LIKE EATING SHARP OBJECTS.**
- **SUSPECTED BILIARY STONES.**
- **POST OP CASES.**



ABDOMEN LATERAL VIEW INDICATIONS

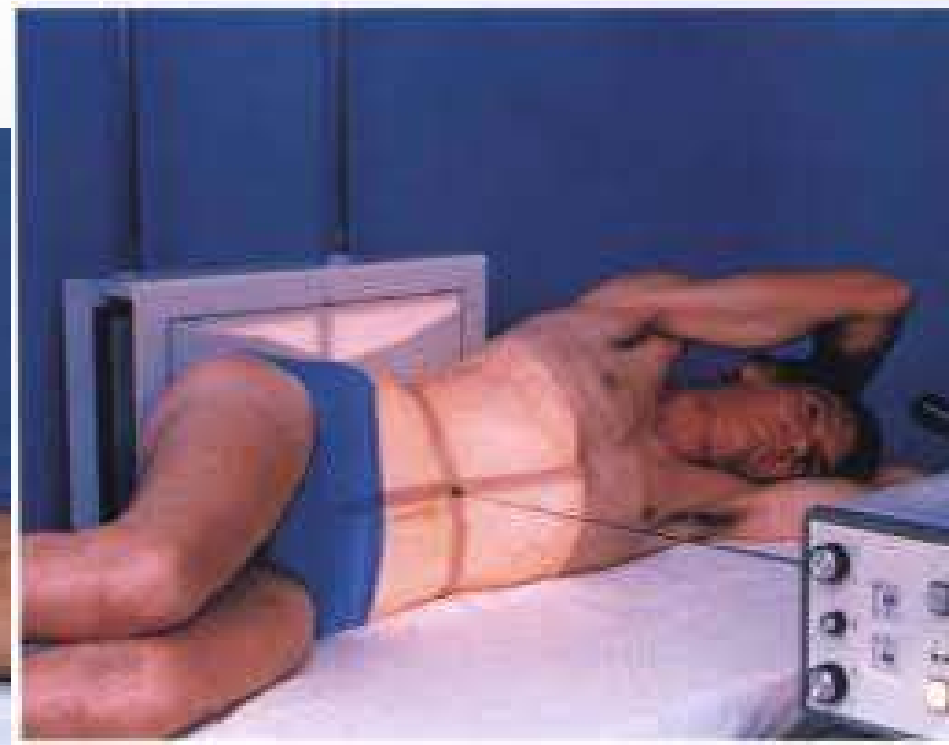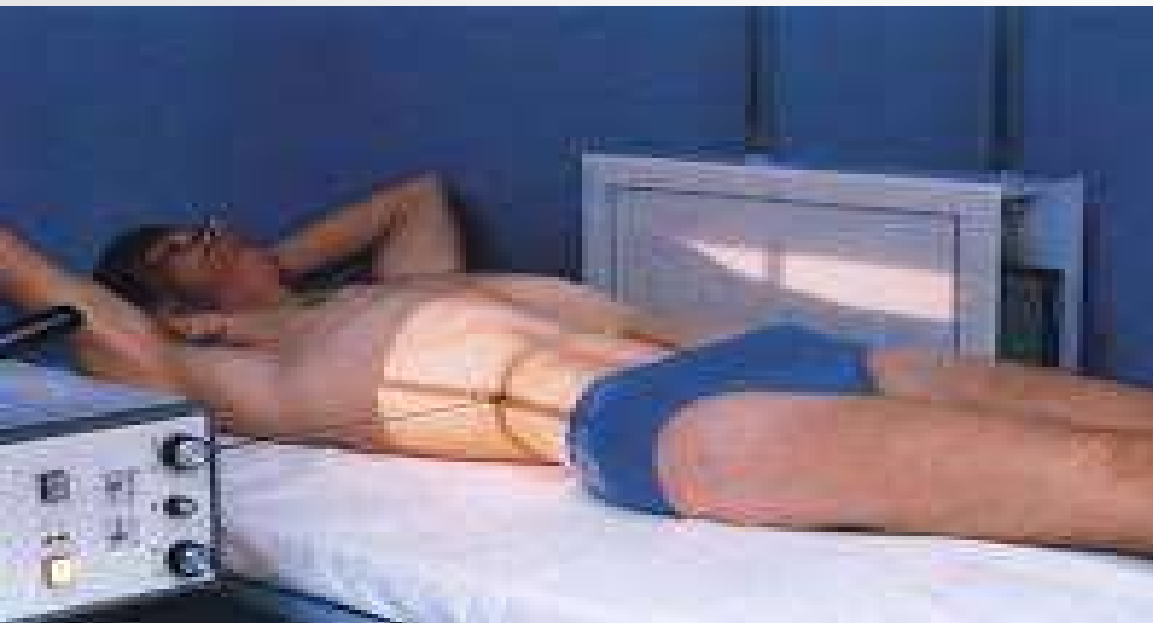- **TO DIFFERENTIATE THE BOWEL GAS AND PNEUMOPERITONEUM.**



SUPINE AND LATERAL DECUBITUS VIEW.

INDICATIONS

- UNCOOPERATIVE PATIENTS.
- IF PATIENT IS UNFIT TO STAND.





CONTRAINDICATIONS

- **PREGNANCY**

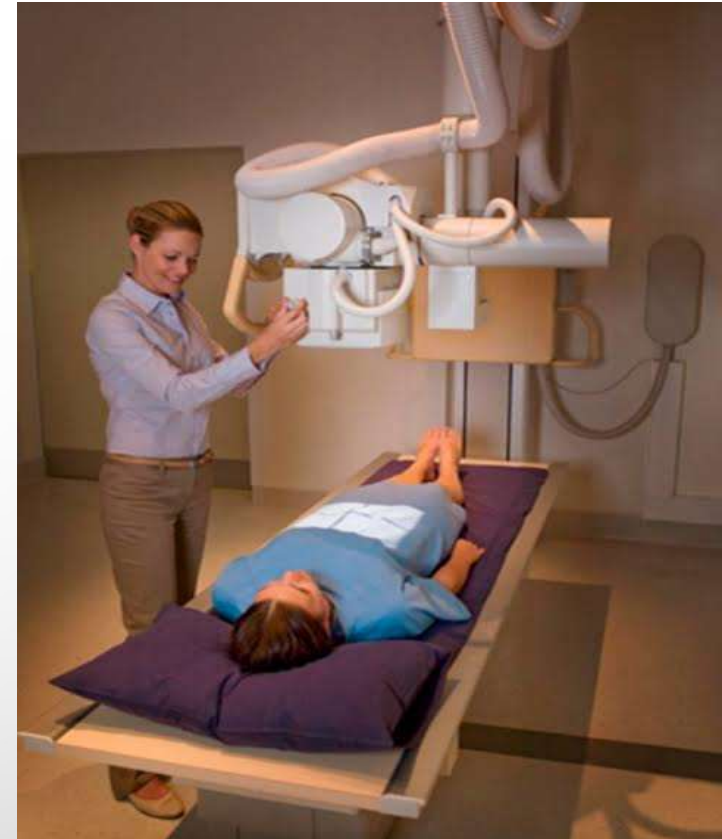

PREPARATION

- **COLLECT HISTORY FROM PATIENT.**
- **PATIENT IS ASKED TO REMOVE ALL RADIOPAQUE MATERIALS.**
- **WEAR HOSPITAL GOWN.**
- **SHIELDING IS PROVIDED TO PATIENT.**
- **AT THE TIME OF EXPOSURE , PATIENT IS ASKED TO TAKE BREATH.
EXPOSURE TAKE DURING ARRESTED INSPIRATION**
- **IF FEMALE PATIENT COME TO X RAY , CHAPERONE IS NECESSARY.**

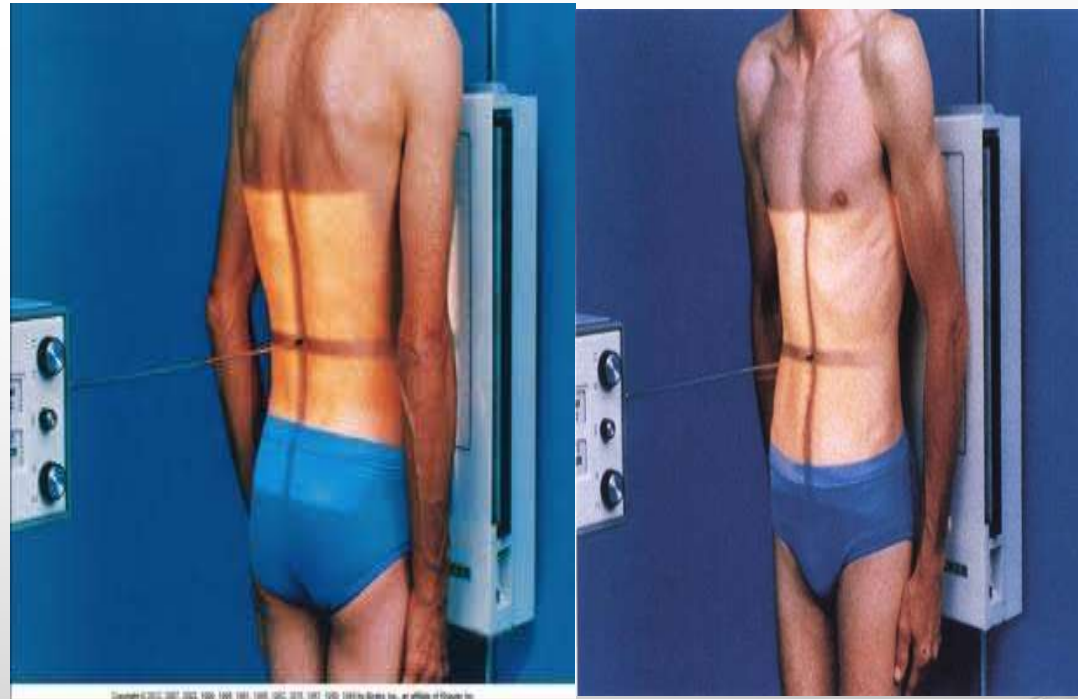
KUB POSITIONING

- **PATIENT IS SUPINE ON MIDLINE OF THE X RAY TABLE.**
- **HIS HAND AND ARMS ABOVE THE HEAD. IT IS ENSURED THAT BODY IS STRAIGHT.**
- **THE UPPER BORDER OF CASSETTE IS JUST ABOVE XIPHISTERNUM AND LOWER BORDER JUST BELOW SYMPHYSIS PUBIS.**
- **TO INCLUDE BLADDER.**
- **PATIENT IS IMMOBALISED, SIDE IS MARKED AND BEAM IS COLLIMATED.**



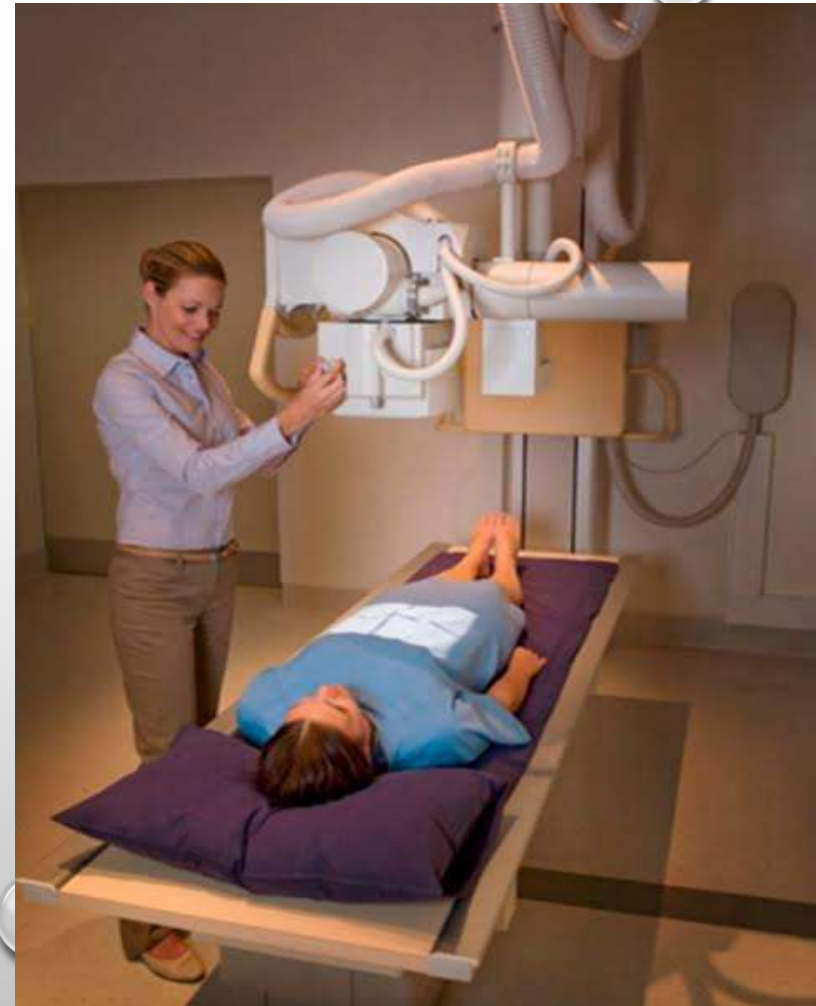POSITIONING OF ERECT X RAY

- PATIENT STANDS IN FRONT OF THE CHEST STAND.
 - UPPER BORDER OF THE CASSETTE IS AT THE LEVEL OF NIPPLES.
 - PATIENT IS IMMOBILISED, SIDE IS MARKED AND BEAM IS COLLIMATED.
1. **PA** : PATIENT STANDS FACING CHEST STAND.
 2. **AP** : PATIENT STANDS FACING TUBE SIDE.



POSITIONING OF SUPINE ABDOMEN

- **PATIENT IS SUPINE ON MIDLINE OF THE X RAY TABLE.**
- **HIS HAND AND ARMS ABOVE THE HEAD. IT IS ENSURED THAT BODY IS STRAIGHT.**
- **THE UPPER BORDER OF CASSETTE IS JUST ABOVE XIPHISTERNUM AND LOWER BORDER JUST BELOW SYMPHYSIS PUBIS.**
- **PATIENT IS IMMOBALISED, SIDE IS MARKED AND BEAM IS COLLIMTED.**



POSITIONING OF LATERAL VIEW OF ABDOMEN.

- **PATIENT LIES IN TRUE LATERAL POSITION ON MIDLINE OF X RAY TABLE.**
- **HIS ARMS ARE RAISED ABOVE THE HEAD.**
- **UPPER BORDER OF THE CASETTE IS AT THE LEVEL OF XIPHISTERNUM.**
- **PATIENT IS IMMOBILISED, SIDE IS MARKED AND BEAM IS COLLIMATED.**

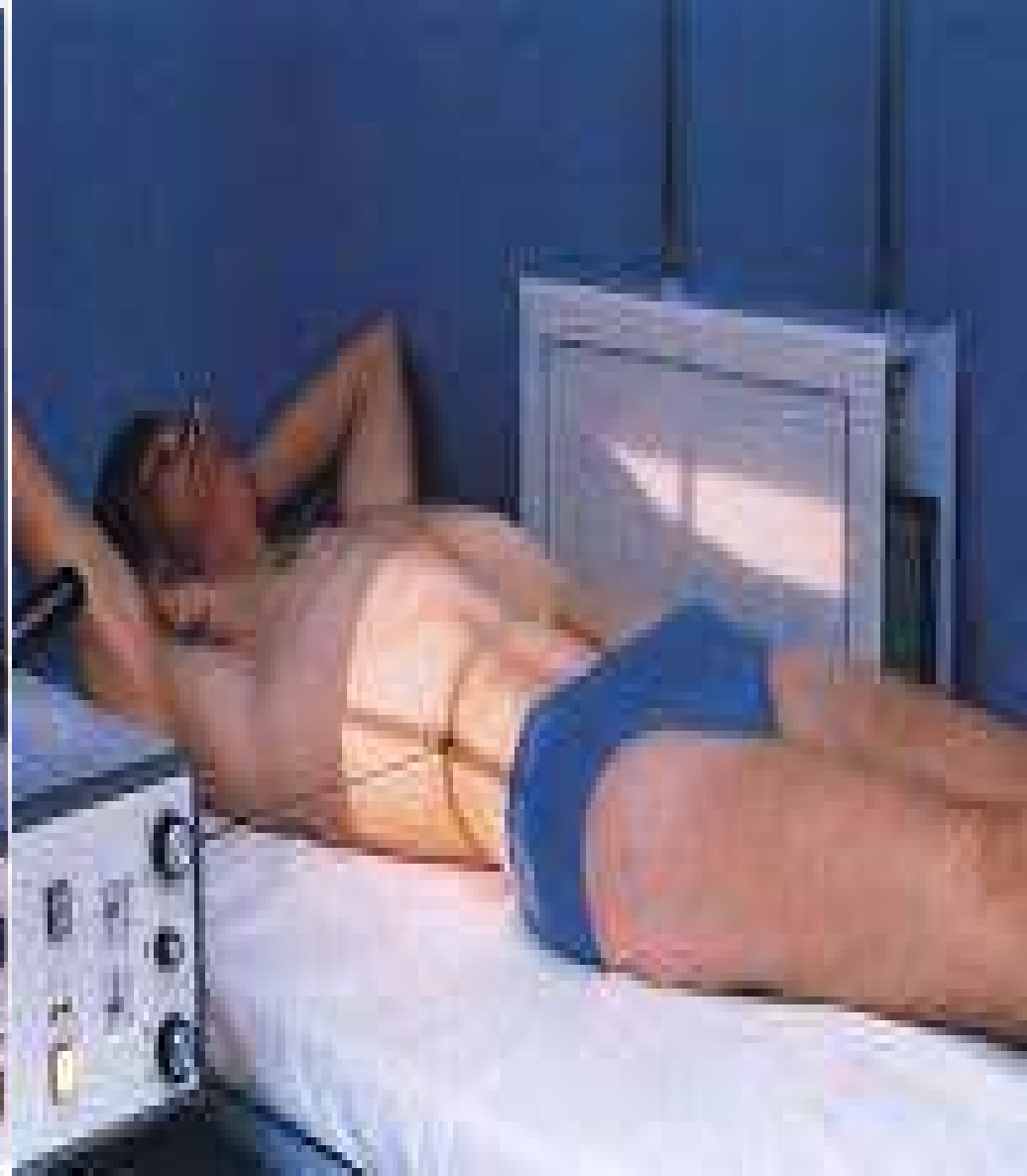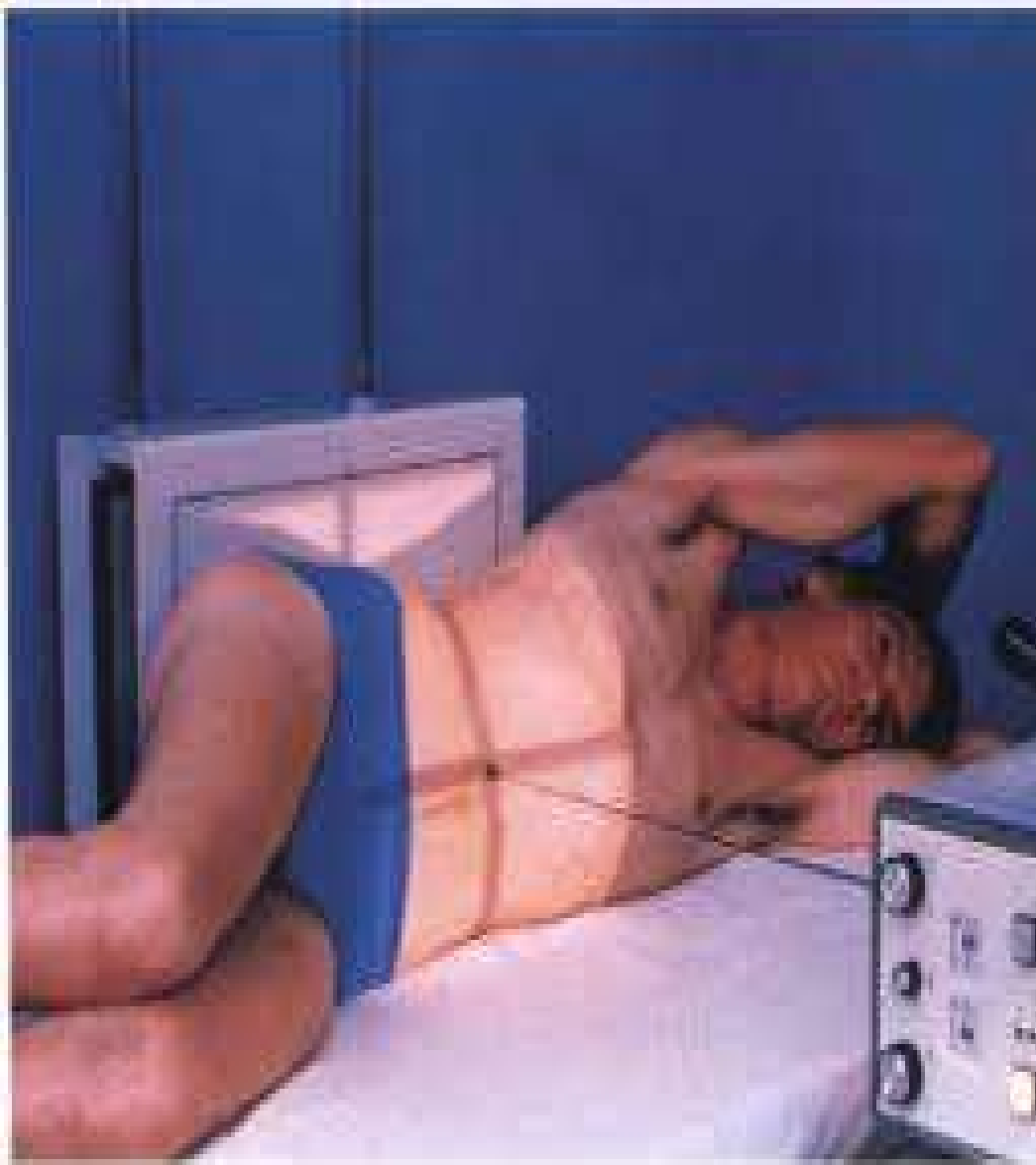POSITIONING OF DECUBITUS VIEW

1. **SUPINE DECUBITUS :**

- PATIENTT LIES SUPINE ON MIDLINE OF X RAY TABLE. IT IS ENSURED THAT TRUNK IS NOT ROTATED.
- CASSETTE IS VERTICALLY SUPPORTED IN CONTACT WITH ONE SIDE OF HIS ABDOMEN.
- UPPER BORDER OF CASSETTE IS AT THE LEVEL OF NIPPLE . BEAM IS COLLIMTED.

2. **LATERAL DECUBITUS :**

- PATIENT LIES ON X RAY TABLE IN TRUE LATERAL POSITION.
- ARMS ARE RAISED AND RESTED OVER THE HEAD.
- CASSETTE PLACED ON BACK SIDE OF THE BODY. UPPER BORDER AT THE LEVEL OF NIPPLES.
- PATIENT IS IMMOBALISED. BEAM IS COLLIMTED.

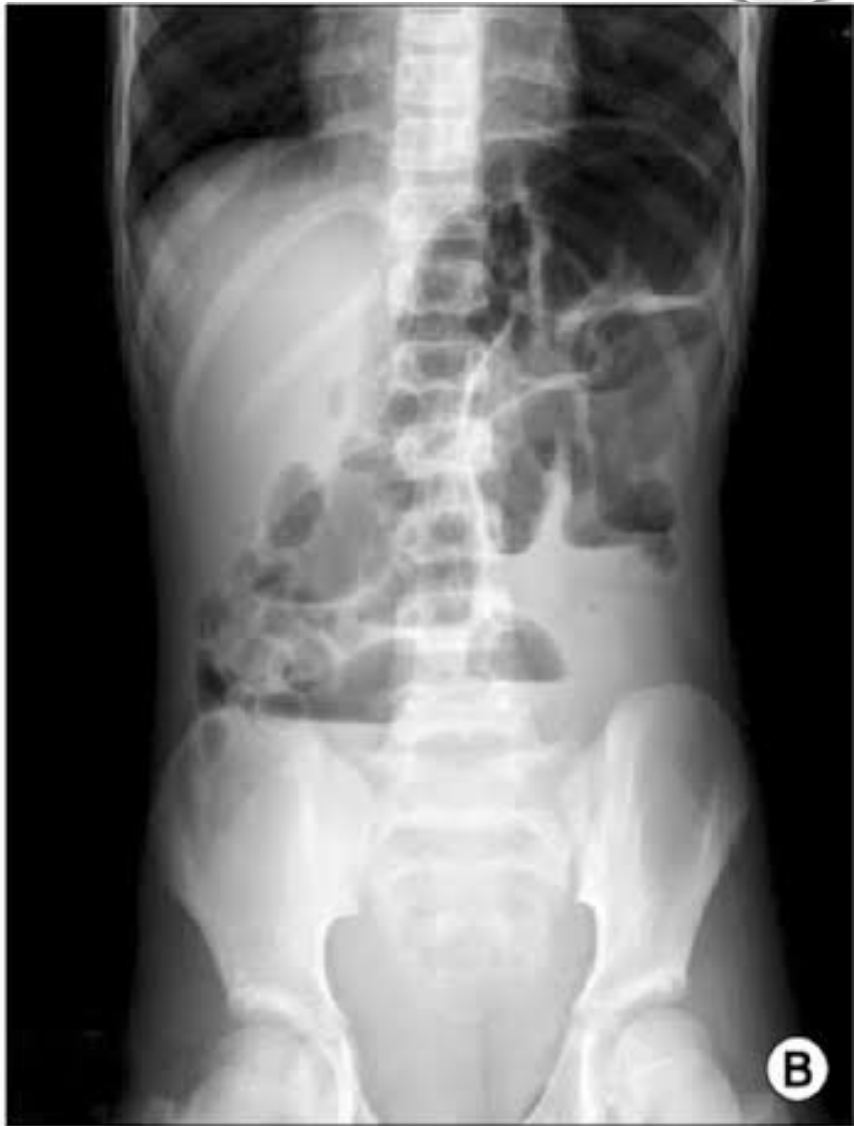
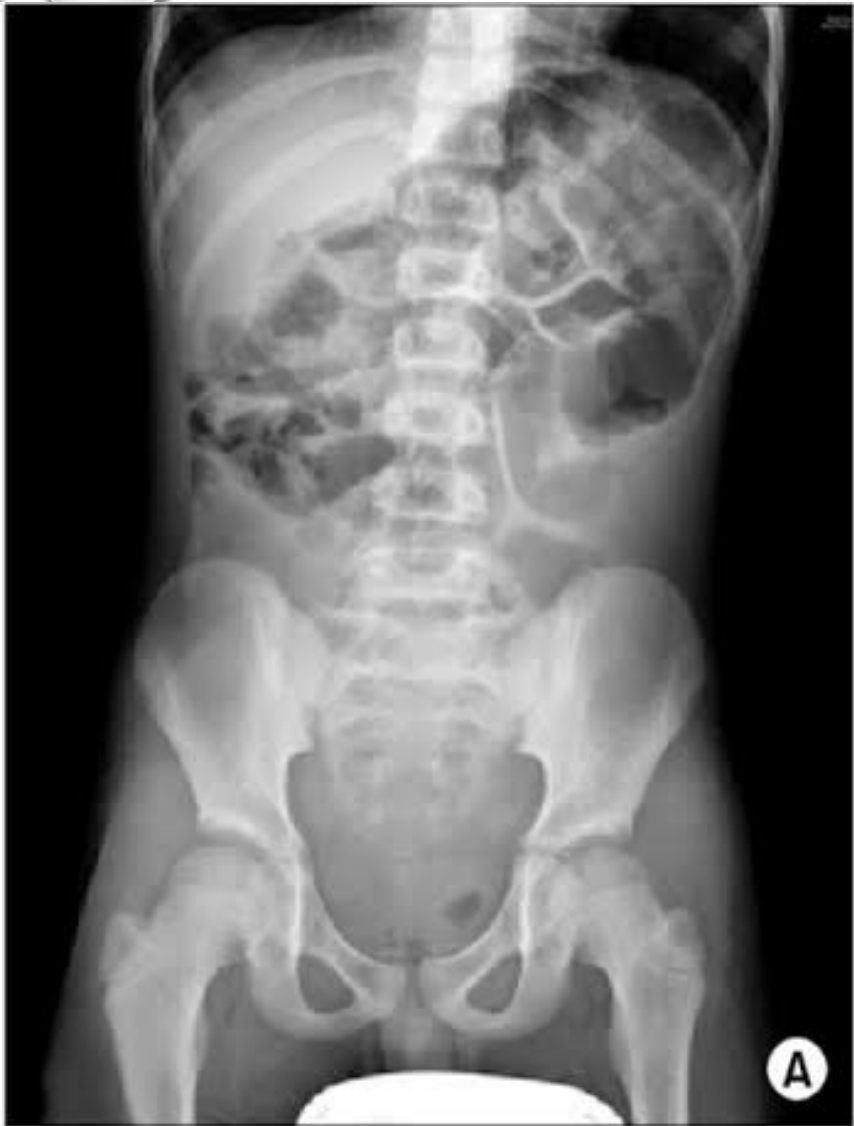
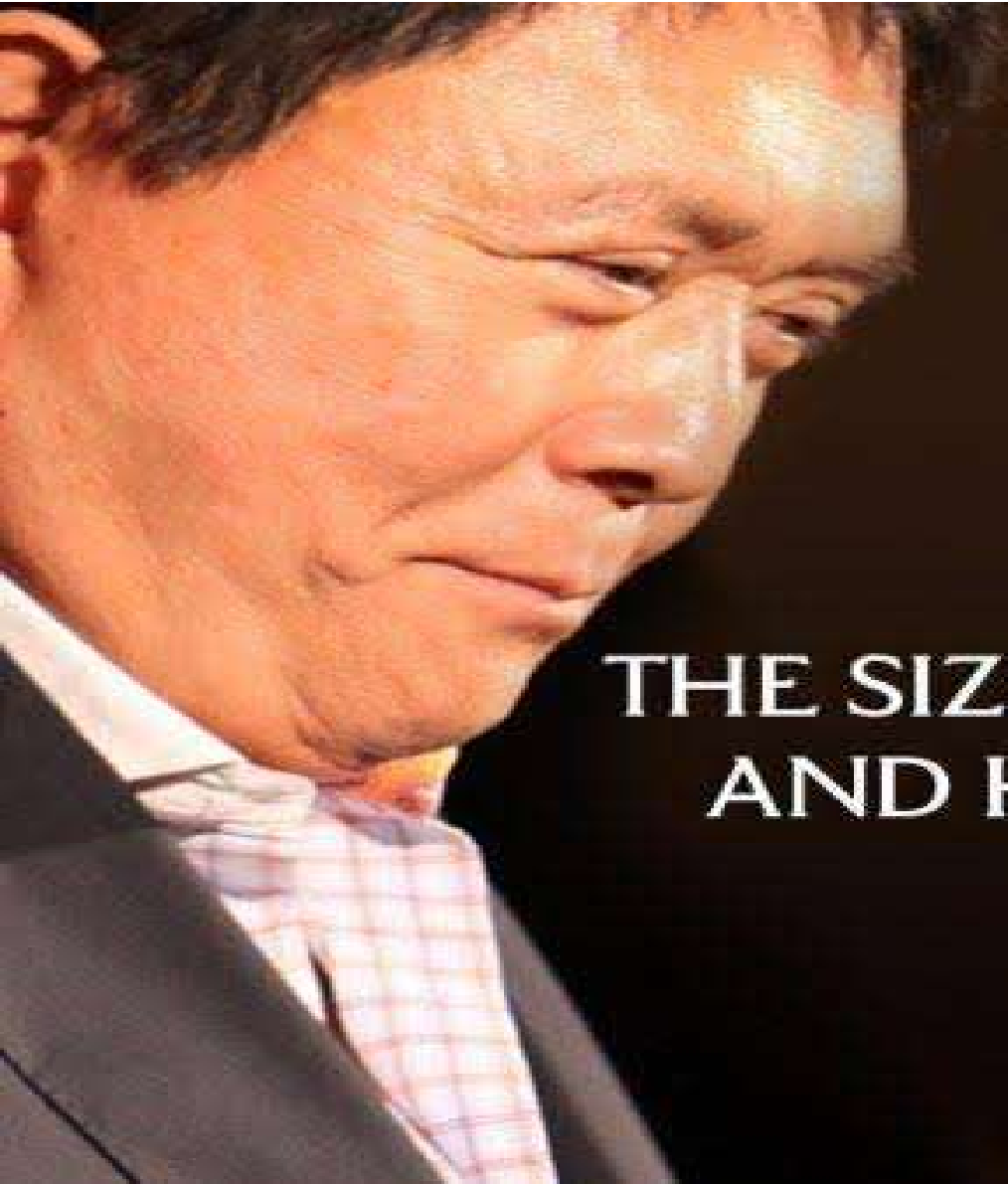
CENTERING

1. **KUB : MIDLINE TO MIDDLE OF CASSETTE OVER UMBILICUS.**
2. **LATERAL : MID AXILLARY LINE TO MIDLINE OF X RAY TABLE.**
3. **ERECT : IT IS DONE ON L3 VERTEBRA.**
4. **SUPINE DECUBITUS : IT IS DONE ON MID AXILLARY LINE TO CENTER OF CASEETTE.**
5. **LATERAL DECUBITUS : IT IS DONE OVER UMBILICUS.**

TECHNIQUE

- **KVP : 70**
 - **MAS : 30**
 - **FSS : LARGE**
 - **FFD : 100 CMS**
 - **WITH GRID.**
 - **CASEETTE SIZE : 17" X 14"**
- **KVP : 75**
 - **MAS : 40**
 - **FSS : LARGE**
 - **FFD : 100 CMS**
 - **WITH GRID.**
 - **CASEETTE SIZE : 17" X 14"**





**"THE SIZE OF
YOUR SUCCESS
IS MEASURED
BY THE STRENGTH
OF YOUR DESIRE;
THE SIZE OF YOUR DREAM;
AND HOW YOU HANDLE
DISAPPOINTMENT
ALONG THE WAY."**

– ROBERT KIYOSAKI