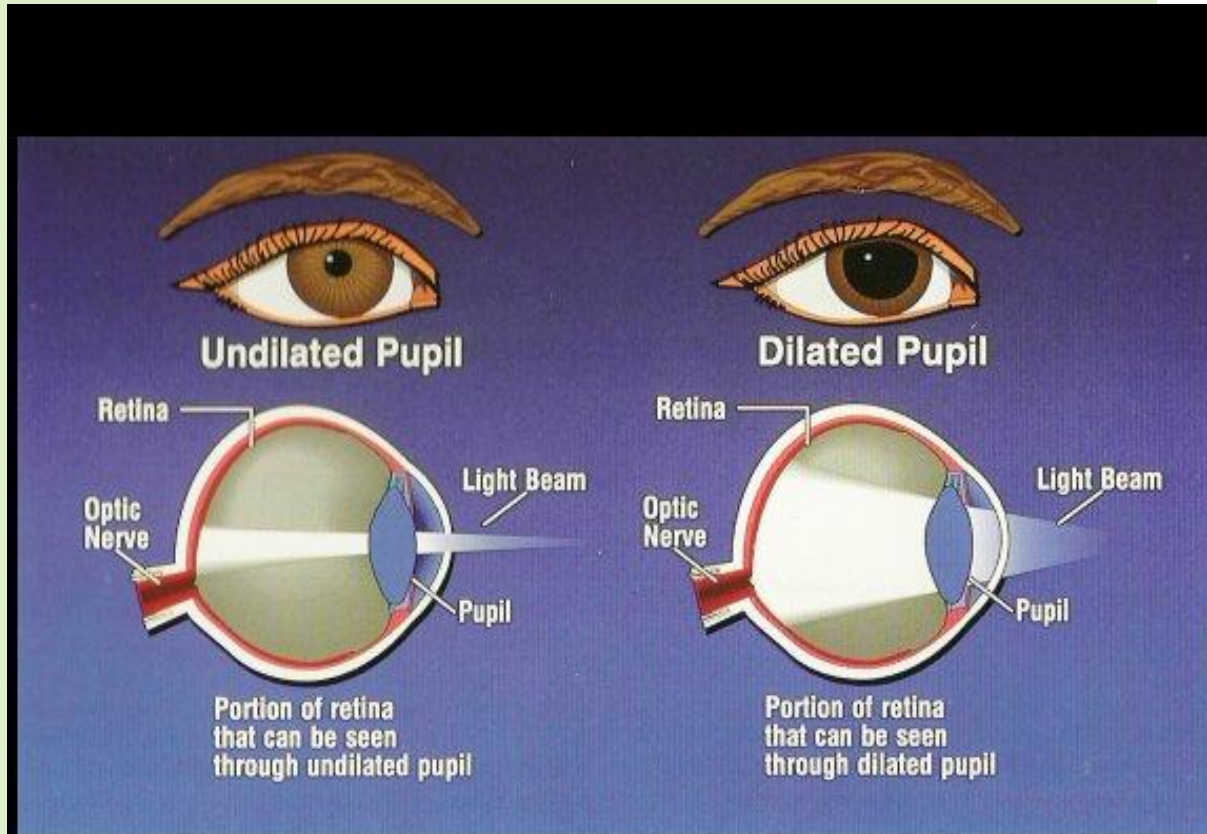


ANATOMY OF PUPILLARY PATHWAYS AND ABNORMAL PUPILS

Sourav
HOD

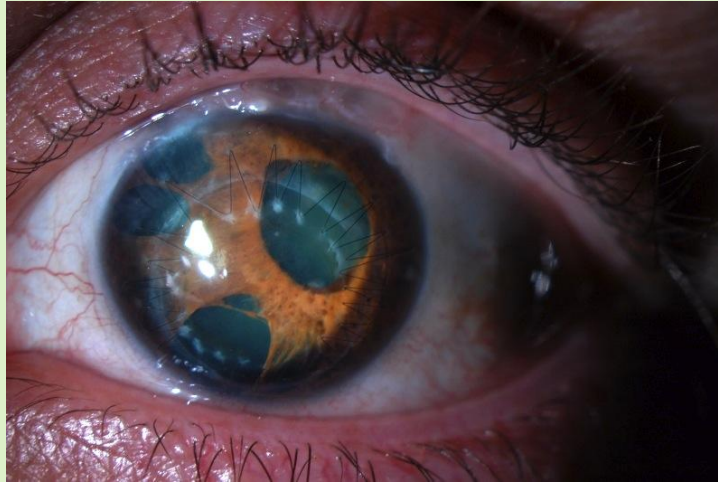NORMAL PUPIL

- An aperture present in the centre of the iris.
- The size of the pupil determines the amount of light that enters the eye.
- The pupil size is controlled by the dilator and sphincter muscles of the iris.



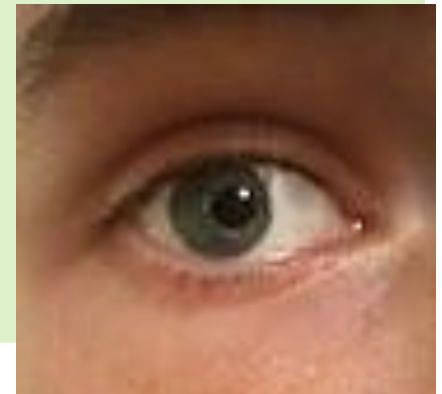■ NUMBER :

- Normally there is one pupil in each eye.
- Rarely, there may be more than one pupil. This congenital anomaly is called *POLYCORIA*.



■ LOCATION :

- Normally, pupil is placed almost in the centre (slightly nasal) of the iris.
- Rarely it may be congenitally eccentric (*CORECTOPIA*)

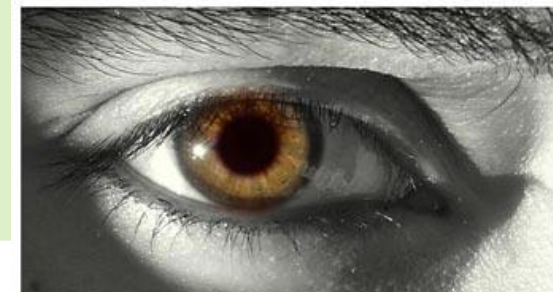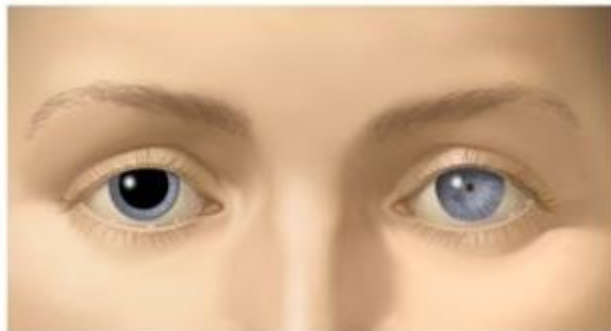


■ SIZE :

- Normal pupil size varies from 2.5-4mm depending upon the illumination.
 - Miotic pupils are less than 2mm
 - Mydriatic pupils are greater than 7mm
- Diameter of the pupil size should be estimated in light, using either a normal room light or a hand held transilluminator.
- It should then be assessed in darkness using the dimmest possible room light and then during near stimulation using an accommodative target to achieve maximum constriction of pupils.

Dilated pupil

Constricted pupil



- **Owing to the refraction of the corneal surface the image of the pupil is magnified by about $1/8$** (an actual diameter of 3.5mm appears clinically to be 4mm).
- If the eye is viewed through a box with glass sides filled with water so that the corneal refraction is eliminated, the pupil appears in its natural form and position.

■ The size depends on :

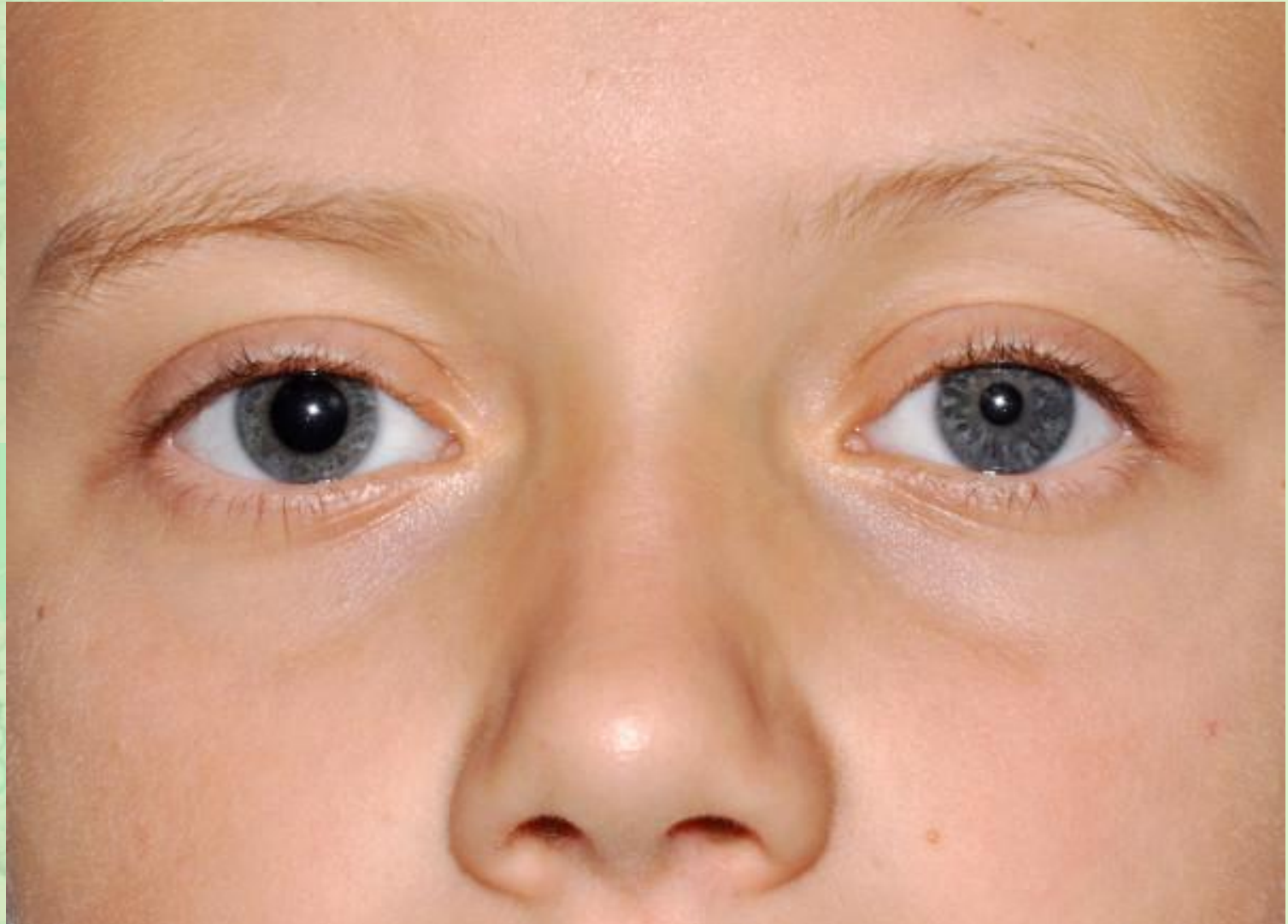- ✓ *Age* : Smaller in infants and elderly
- ✓ *Sleep* : Smaller due to parasympathetic dominance
- ✓ *Psychology of individual* – smaller in placid people
- ✓ *Refraction* : Hyperopes have smaller pupils
- ✓ *Colour* : Darker iris have smaller pupils

□ **Isocoria** : Normally the two pupils are equal in size. A slight (one-tenth of a millimeter) anisocoria is present in a significant percentage of normal pupil.

□ **Anisocoria** : Difference in pupillary diameter of 2 eyes of the same individual by 0.3mm or more.

- The most common cause of anisocoria is central anisocoria (occurs in 20% of normal individuals) and is due to asymmetric supranuclear inhibition of Edinger-Westphal nucleus.
- It can be easily distinguished from other abnormal pupils by normal reactions to bright light, near response and lesser degree of inequality

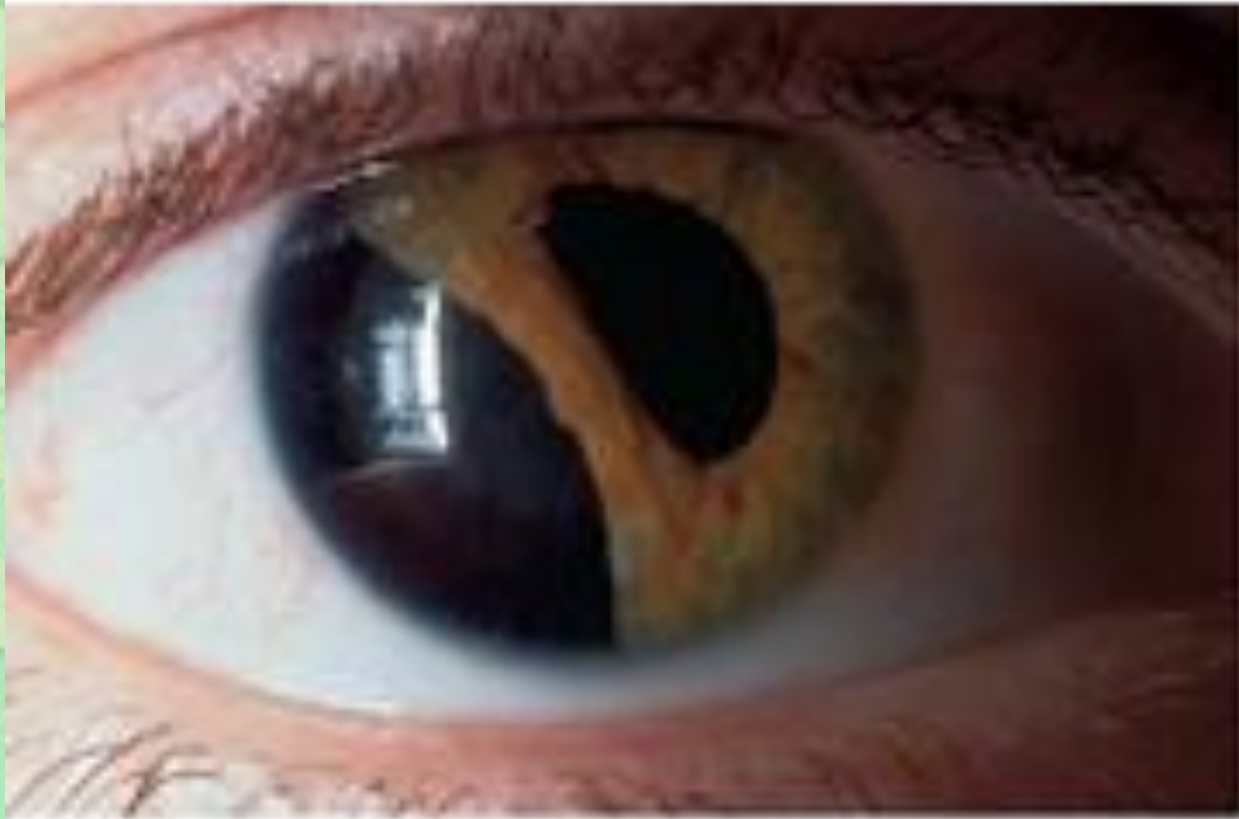ANISOCORIA



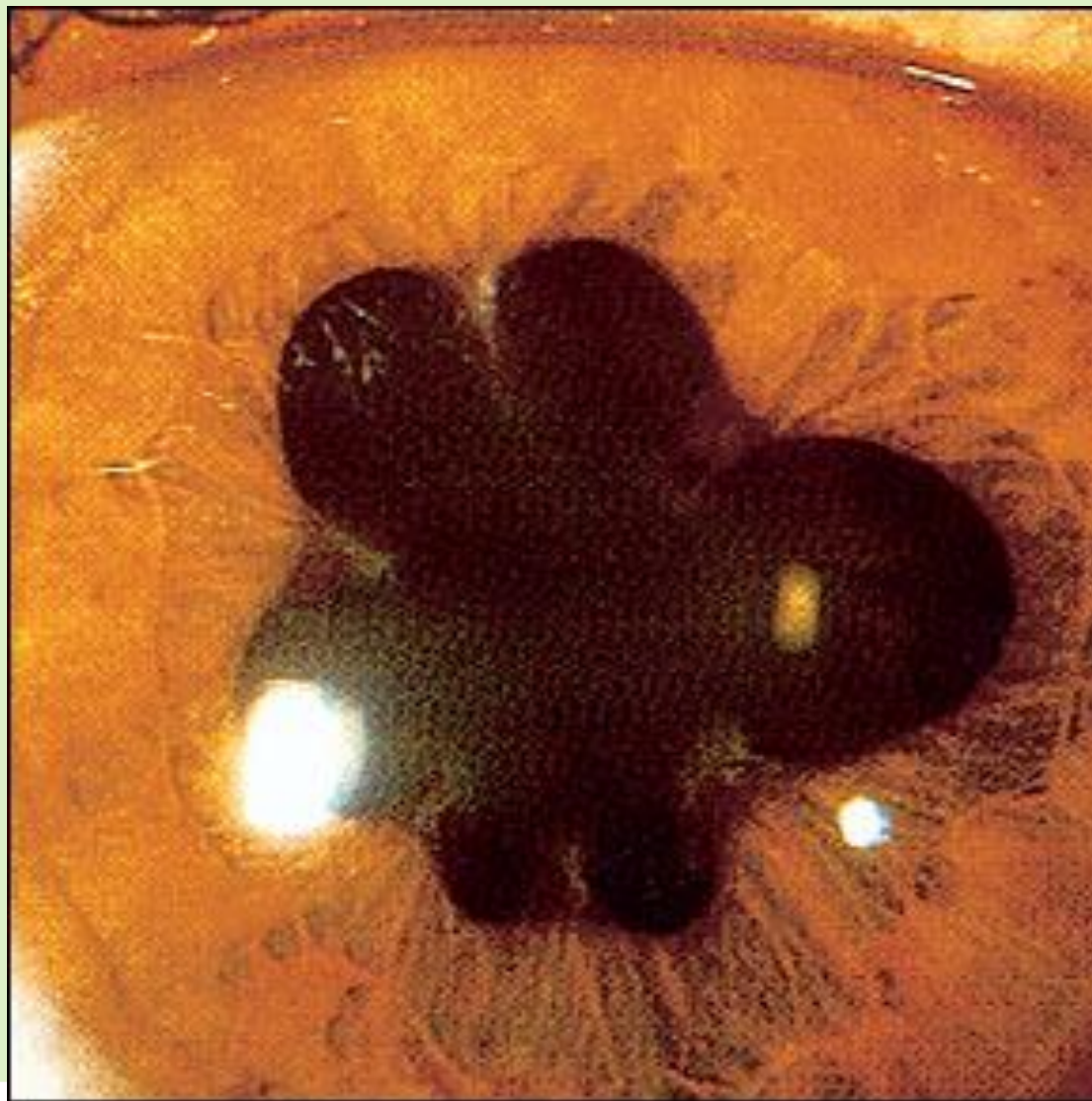
■ SHAPE :

- Normal pupil is almost circular in shape
- D - shaped in iridodialysis.
- Festooned on dilatation if there is posterior synechia.
- Pear shaped in cases of leukoma adherent.
- Key hole shaped in cases of sector iridectomy.
- Oval in cases of acute congestive glaucoma, severe brain disease.
- Tadpole shaped pupils results from sector dilatation observed sometimes in Horner's syndrome.
- Scallop shaped pupils due to sector atrophy of the iris are seen sometimes in amyloidosis and neuropathy of short ciliary nerves.

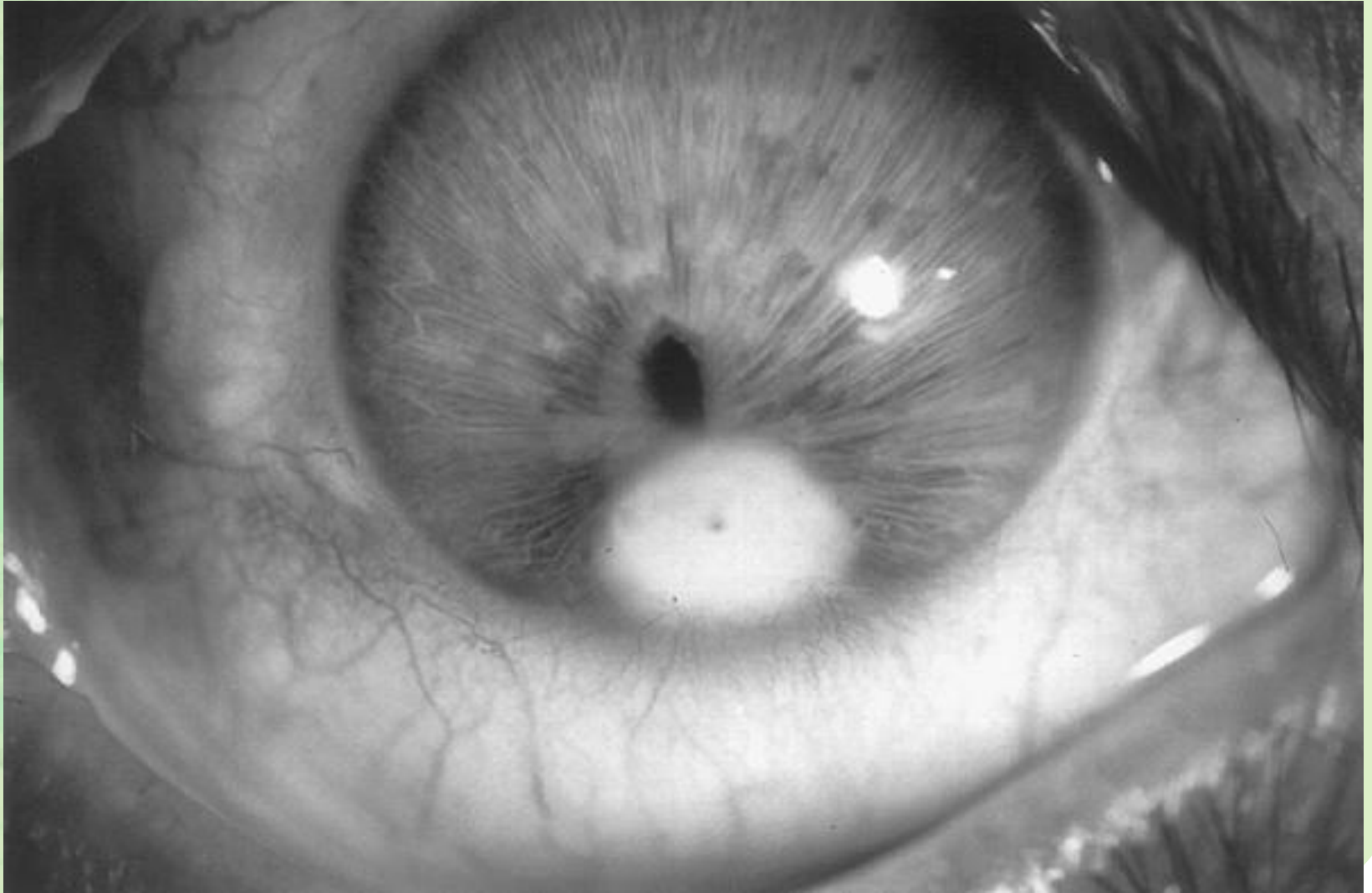
Iridodialysis



Posterior synechia



Adherent leukoma



■ COLOUR :

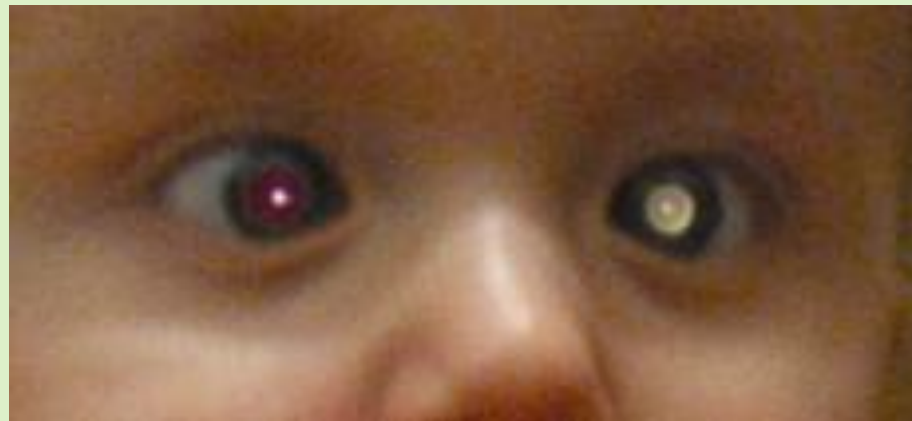- Normally, it is greyish black.
- It becomes jet black in aphakia
- Greyish white: - cataract.
- Brown in brown nuclear cataract.
- Whitish: - Retinoblastoma and pseudogliomas .
- Yellowish: - vitreous abscess (endo and panophthalmitis).
- Greenish: - Acute congestive glaucoma.
- Reddish in albinism.

❑ The term **leukocoria** means whitish pupil. Its cause are classified into:

A. Glioma (the old name of retinoblastoma).

B. Pseudoglioma (any other cause of leukocoria) as:

- Congenital cataract.
- Cyclitic membrane.
- Retinopathy of prematurity (retrolental fibroplasia): it occurs due to oxygen toxicity of premature infants.
- Retinal detachment.
- Endo and panophthalmitis.
- Toxocariasis
- Coat's disease
- PHPV
- Coloboma
- Retinal dysplasia
- Norrie's disease



■ Functions of the pupil :

1. It is the opening through which light enters the eye.
2. It regulates the amount of light entering the eye by miosis in light and mydriasis in darkness.
3. It improves the visual acuity because it prevents the irregular refraction by the periphery of the cornea and lens, and increases the depth of focus.
4. It allows passage of aqueous humour from the posterior chamber to the anterior chamber.

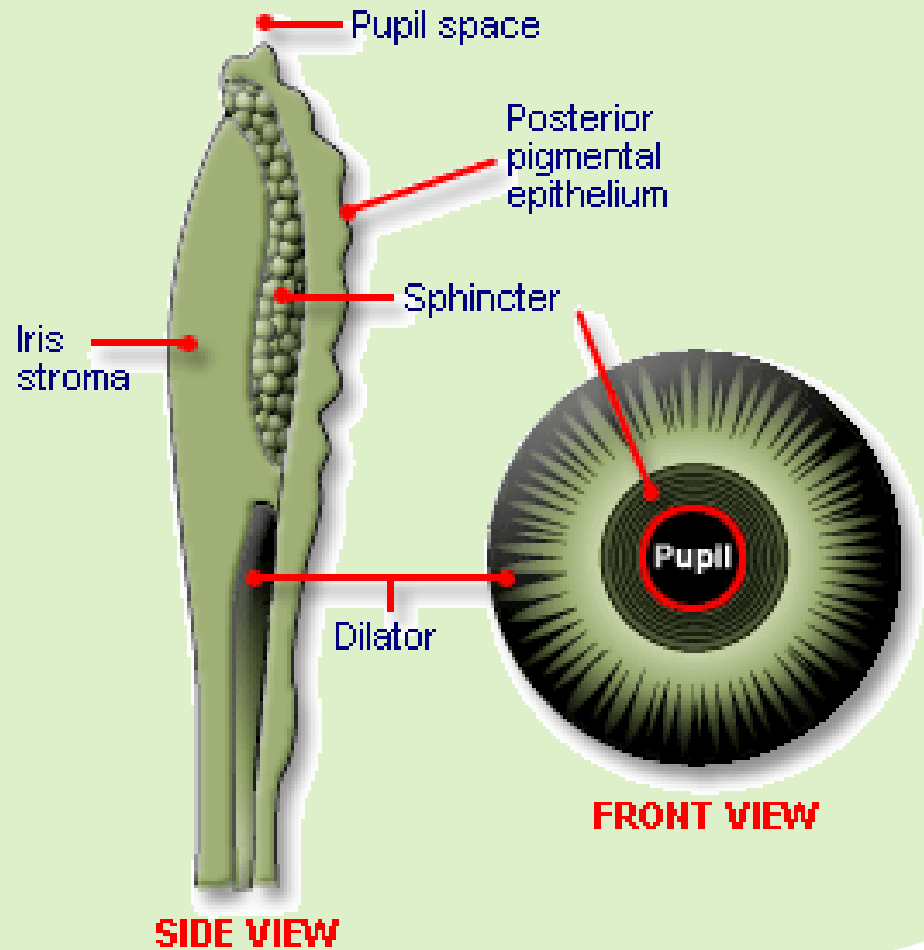


RELEVANT ANATOMICAL FACTS

SPHINCTER AND DILATOR PUPILLAE

Muscle tissue of the iris consists of

- A. Sphincter pupillae
- B. Dilator pupillae



A. SPHINCTER PUPILLAE

- It is a narrow circular band, 1 mm wide, situated close to the pupillary aperture, surrounding the pupil on the posterior aspect of iris.

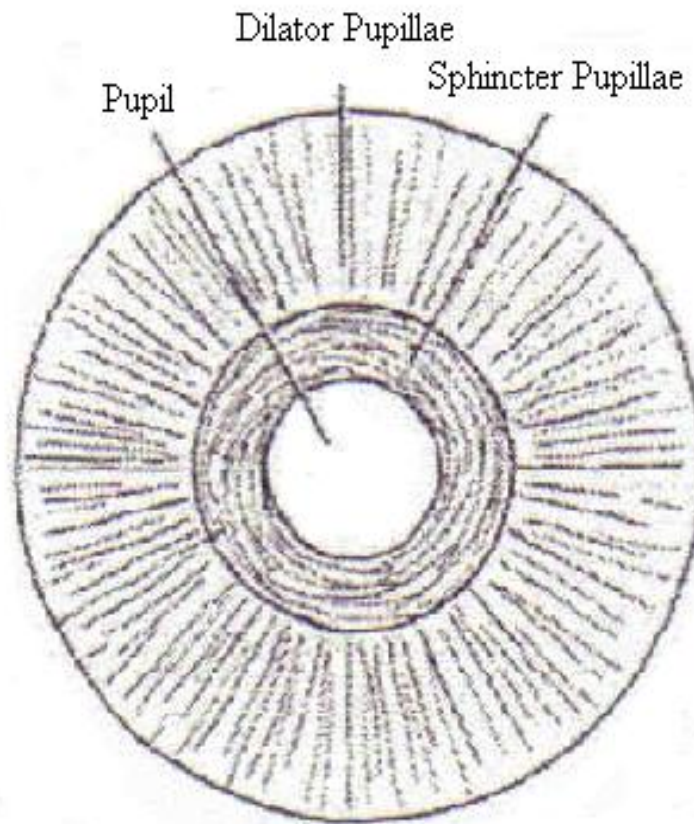
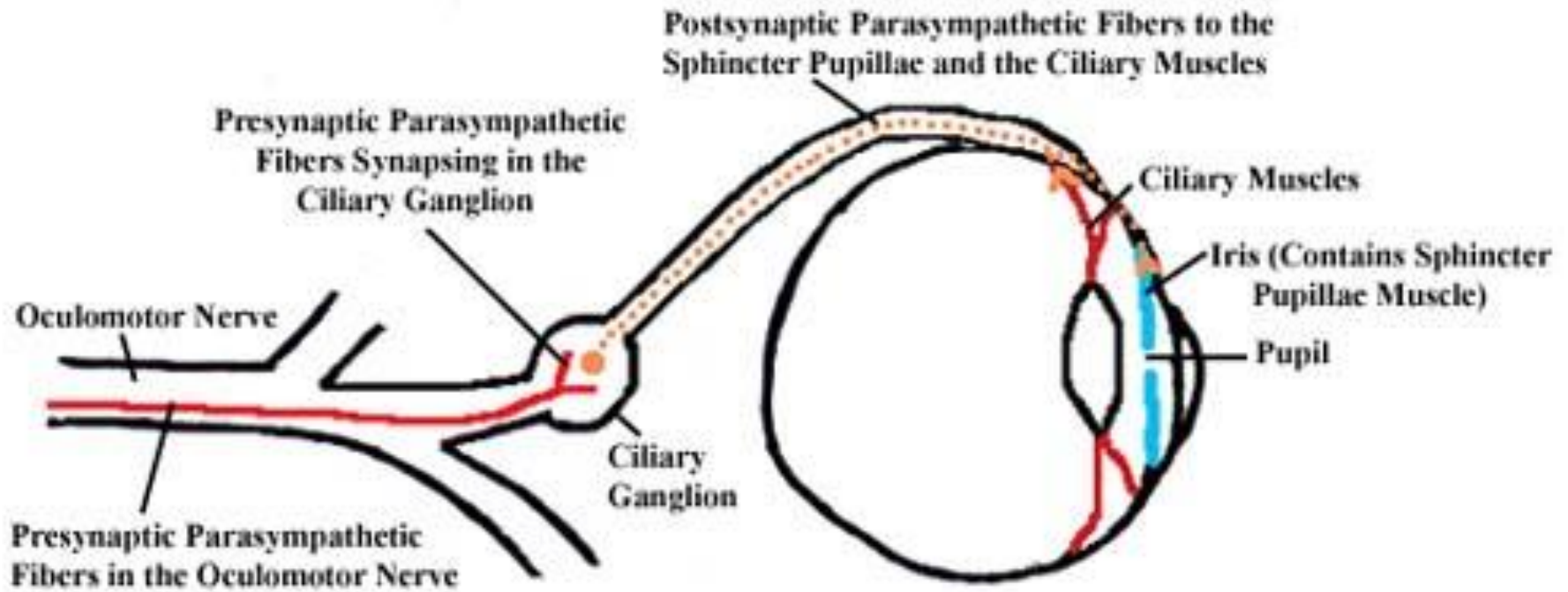
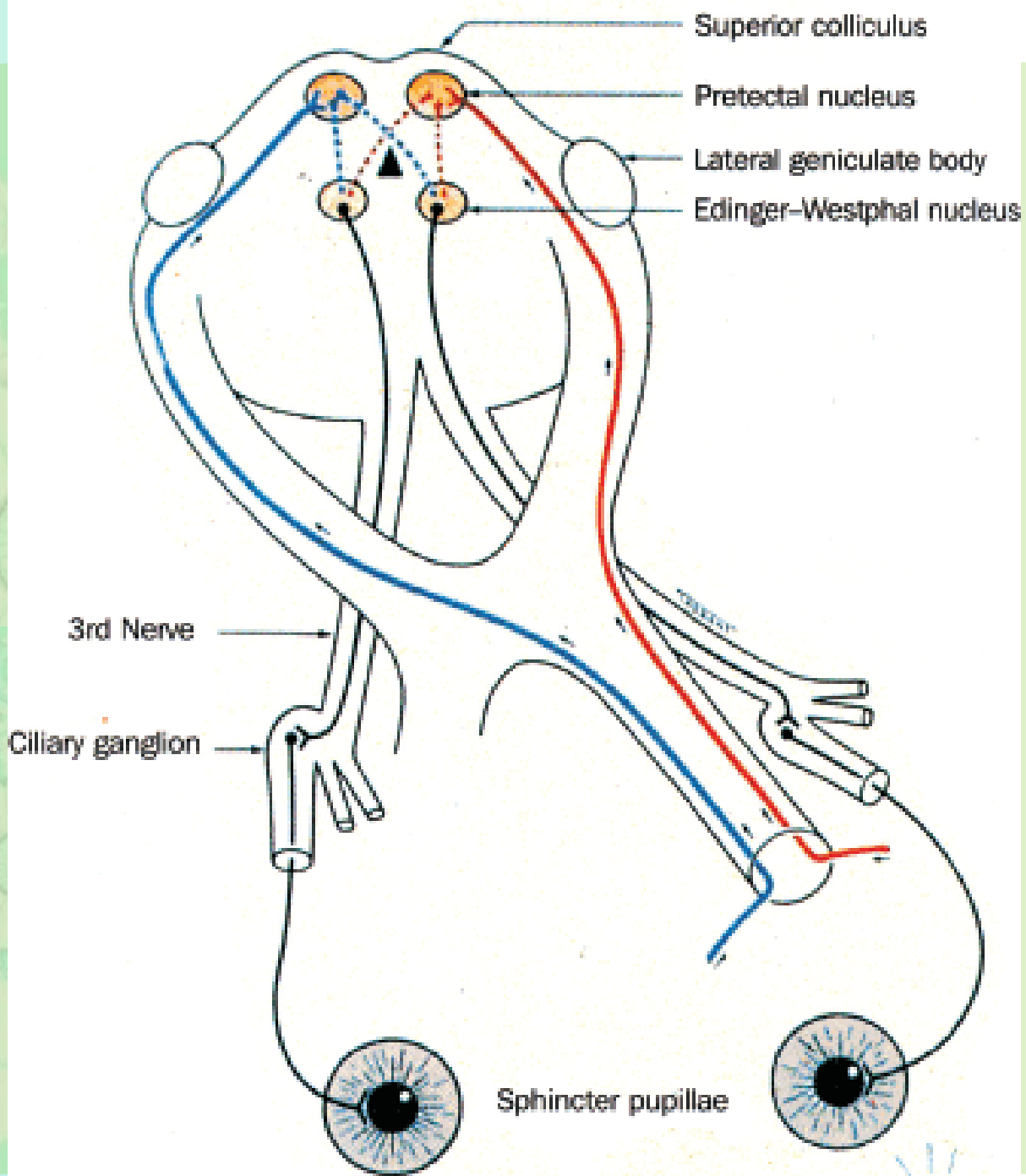


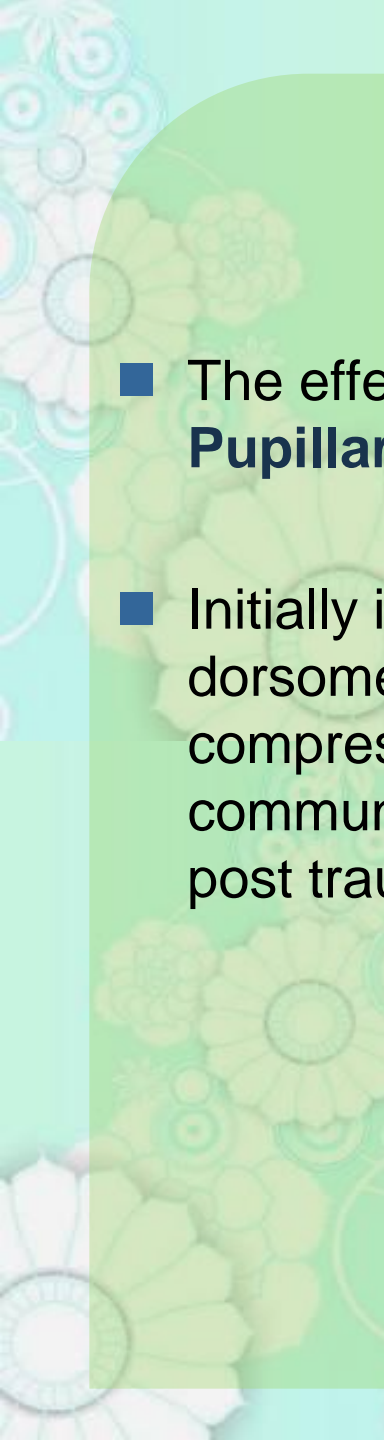
Diagram showing the arrangement of the fibers of the dilator pupillae and the sphincter pupillae of the iris

- It is supplied by the PARASYMPATHETIC PATHWAY as follows



1. From the Edinger Westphal nucleus, the preganglionic fibres for both the ciliary muscle and the pupil go through the oculomotor nerve.
2. At the anterior end of the cavernous sinus where the oculomotor nerve divides into superior and inferior divisions, the pupillomotor fibres go through the inferior division, then through the branch to the inferior oblique muscle and synapse at the *ciliary ganglion*, lying at the apex of the muscle cone between the optic nerve and the lateral rectus muscle
3. From here, about 6-10 small postganglionic short ciliary nerves originate and penetrate the posterior sclera and supply the ciliary muscle and the pupillary sphincter. The ratio of fibres innervating the ciliary body to those supplying the pupil is about 30:1.



- 
- The effect of parasympathetic innervation is to bring about **Pupillary Constriction.**
 - Initially in the third cranial nerve, these fibres are located on the dorsomedial surface of the nerve, where they are vulnerable to compression by aneurysms at the junction of posterior communicating artery and internal carotid artery, as well as by post traumatic uncal herniation.

B. DILATOR PUPILLAE

- This is contributed by radially disposed muscle fibres which extend from ciliary body to pupillary margin

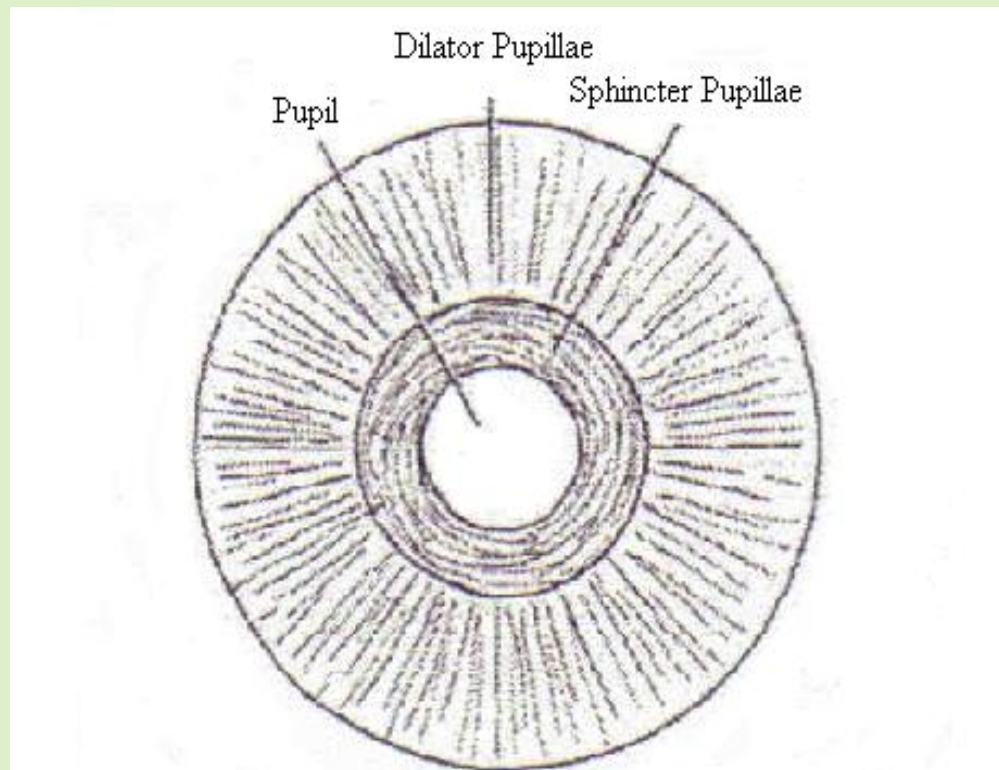
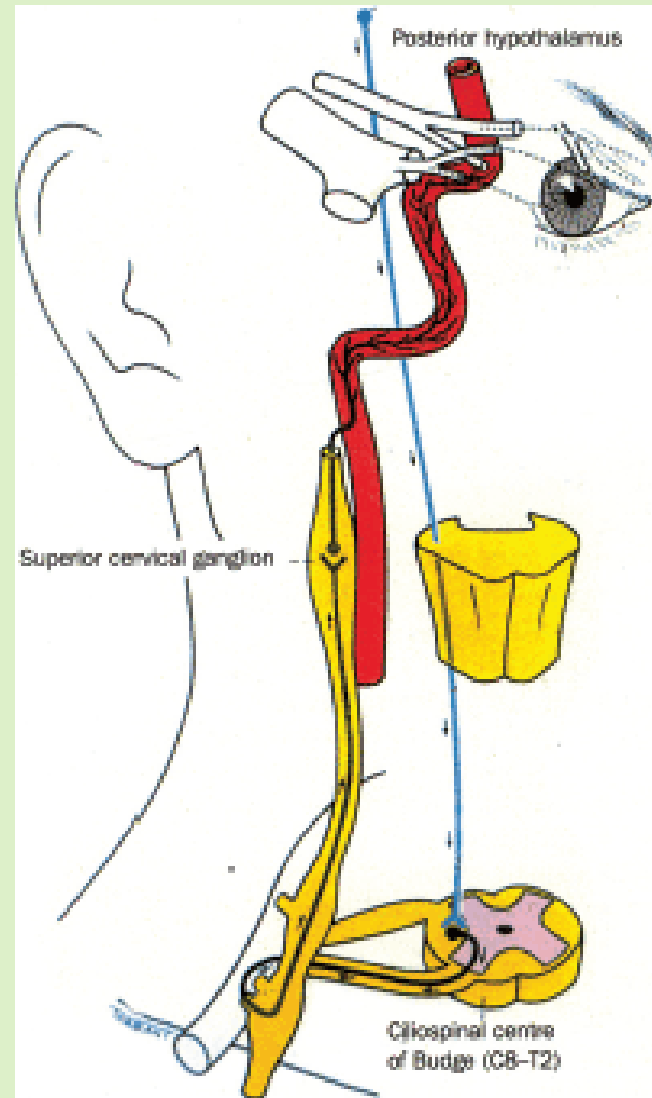


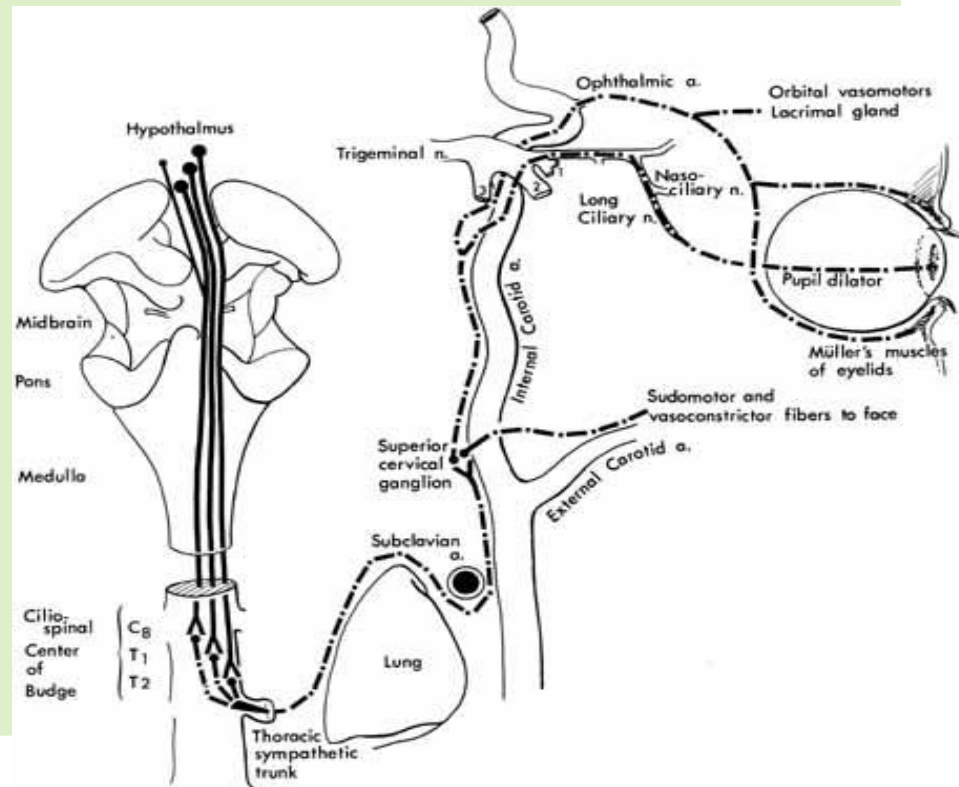
Diagram showing the arrangement of the fibers of the dilator pupillae and the sphincter pupillae of the iris

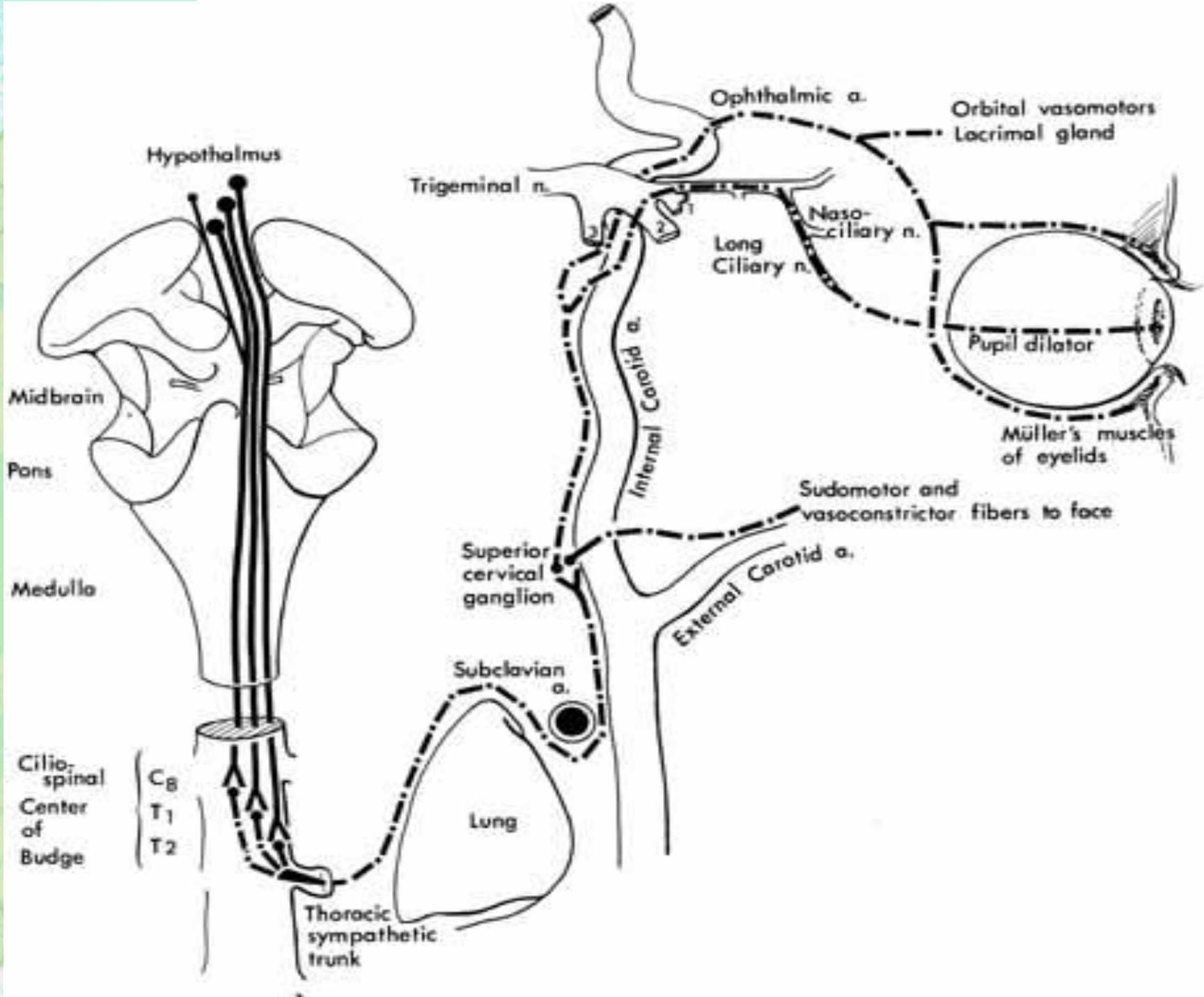
- They are supplied by SYMPATHETIC SYSTEM.

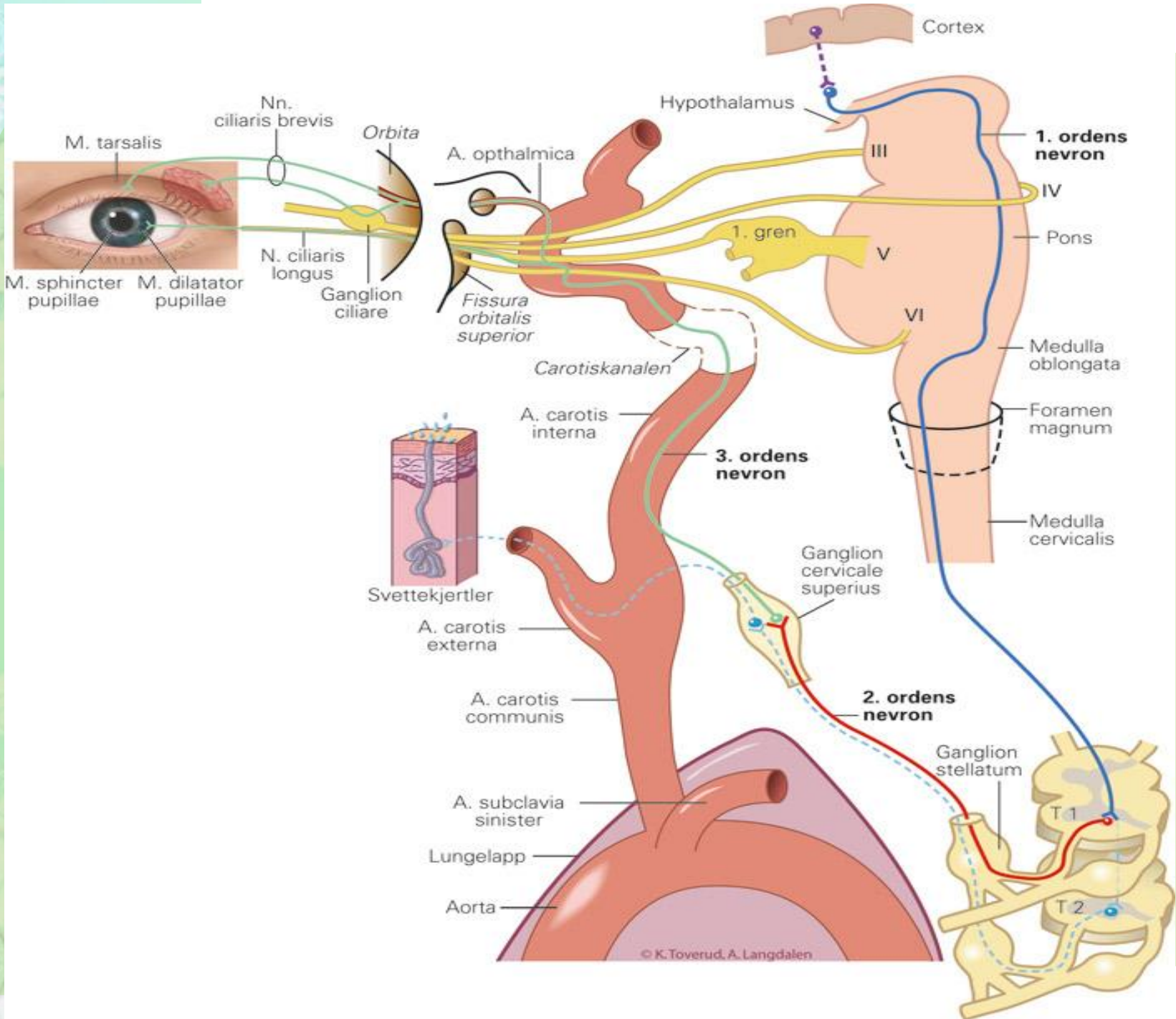


Efferent pathway for pupillary dilatation :

- The **First Order Neurons** start from the posterolateral hypothalamus and their axons run uncrossed through the reticular formations, lateral pons and medulla and finally synapse at the intermediolateral cell column of C8 to T2 (*cilio-spinal centre of budge*).
- The **Second Order Preganglionic Axons** travel along the ventral roots of C8 to T2 and depart as the white rami, ascend into the sympathetic chain, travel over the lung apex and synapse at the superior cervical ganglion at the carotid bifurcation.



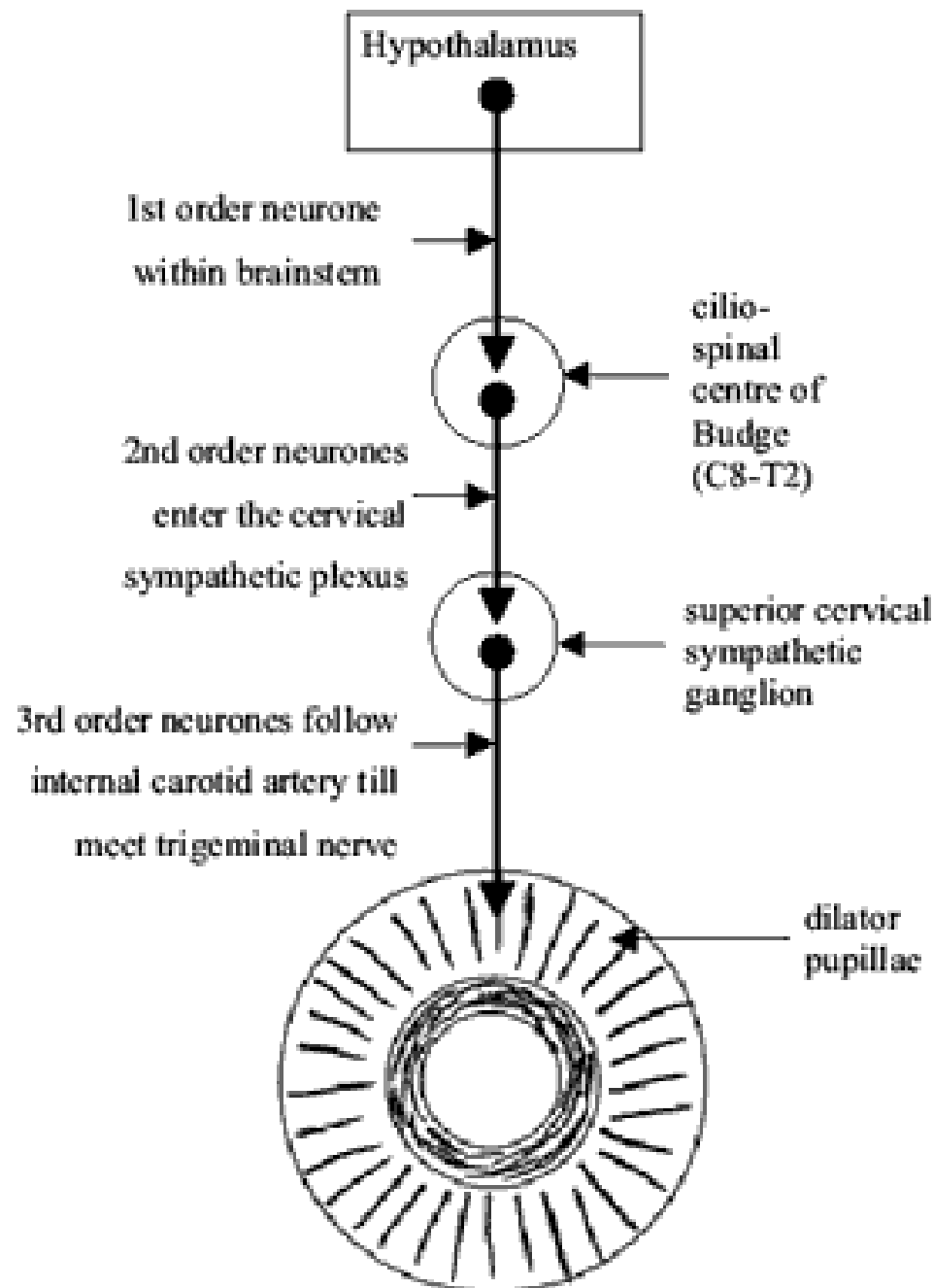




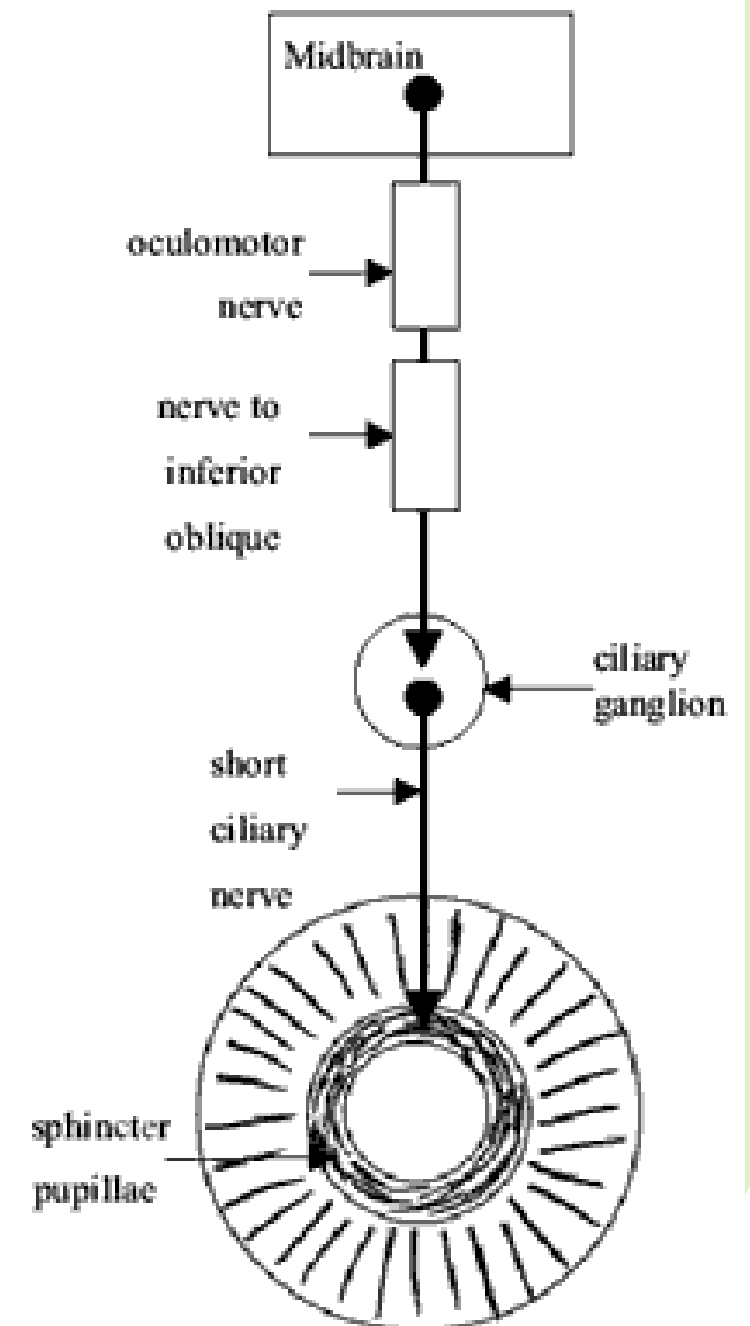
- The **Third Order Neurons** from here send their post ganglionic fibres.
- The sudomotor fibres course along with the external carotid to innervate the sweat glands of the face.
- Other fibers ascend in the cranium as a plexus around the sheath of the internal carotid artery. These fibers leave the carotid at its cavernous portion, join the ophthalmic division of the trigeminal and enter the ciliary ganglion but *without synapsing there*, they finally reach the dilator muscle as long ciliary nerves.
- Some of the oculosympathetic fibres innervate the Muller's muscle in the upper and lower lids.

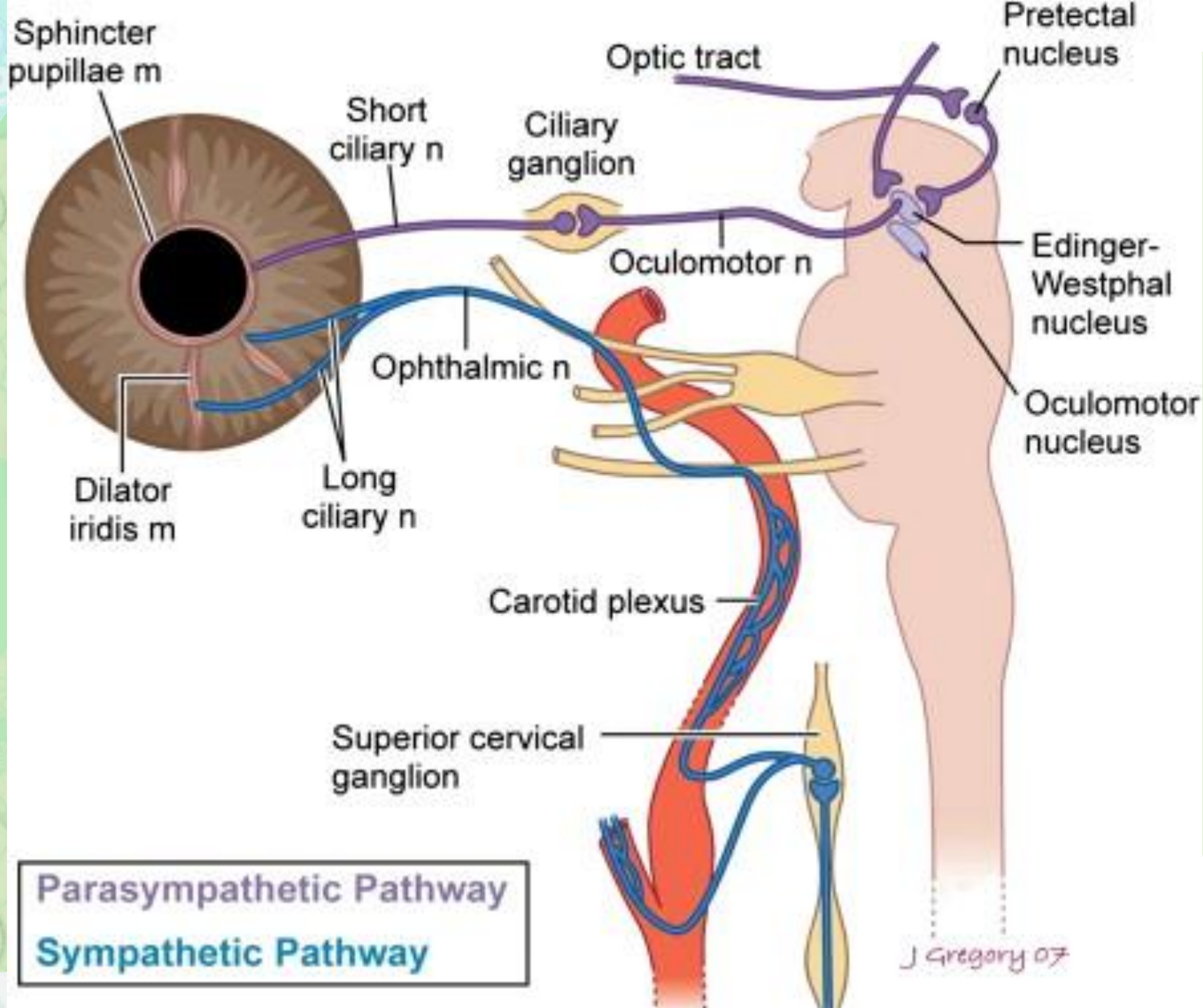
- The effect of sympathetic stimulation is **Pupillary Dilatation**.

Sympathetic



Parasympathetic



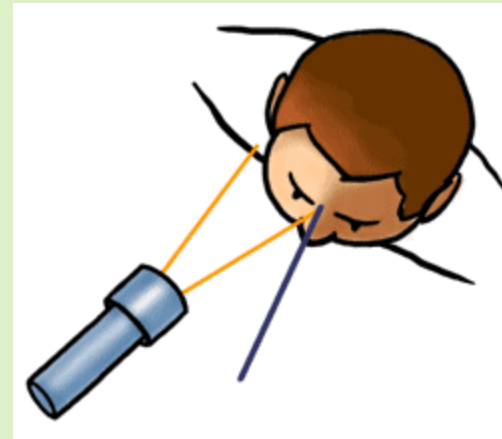


PUPILLARY REFLEXES

- LIGHT REFLEX
- NEAR REFLEX
- DARKNESS REFLEX
- PSYCHOSENSORY REFLEXES
- THE LID-CLOSURE REFLEX

1. LIGHT REFLEX

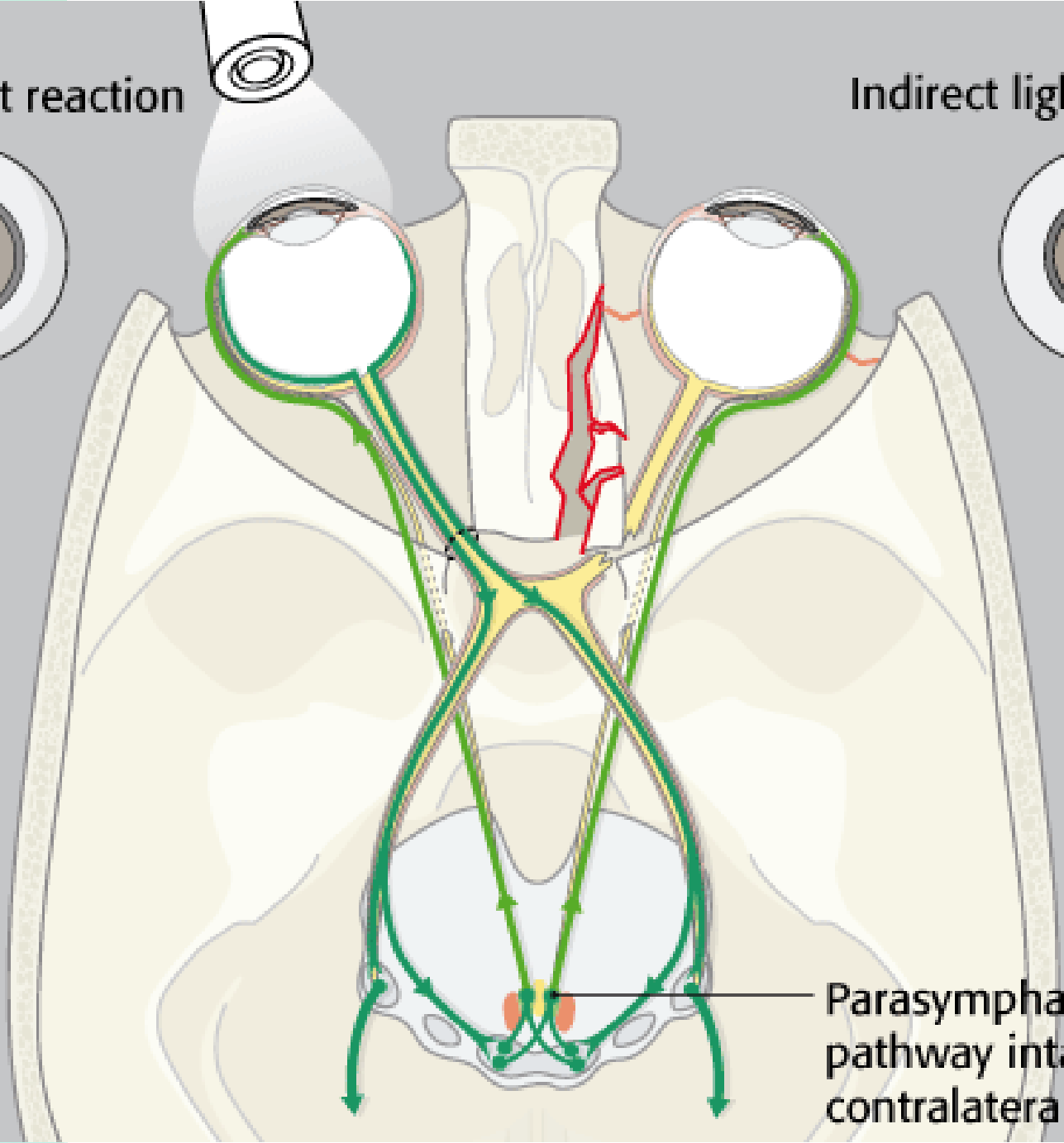
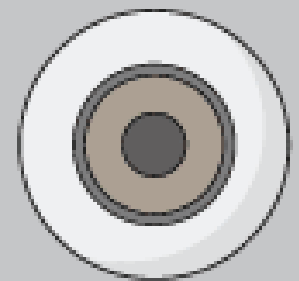
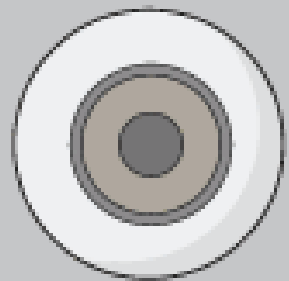
- When light is shone in one eye, both the pupils constrict.
- Direct light reflex : contraction of the ipsilateral pupil when the ipsilateral eye is stimulated by light
- Consensual light reflex : contraction of the contralateral pupil when the ipsilateral eye is stimulated by light.



- In normal subjects, the direct and consensual reactions are almost, always identical in time, course and magnitude.
- If both pupils are illuminated simultaneously, the response summates, i.e. the constriction of each pupil is greater than the constriction noted when only one pupil is illuminated.

Direct light reaction

Indirect light reaction

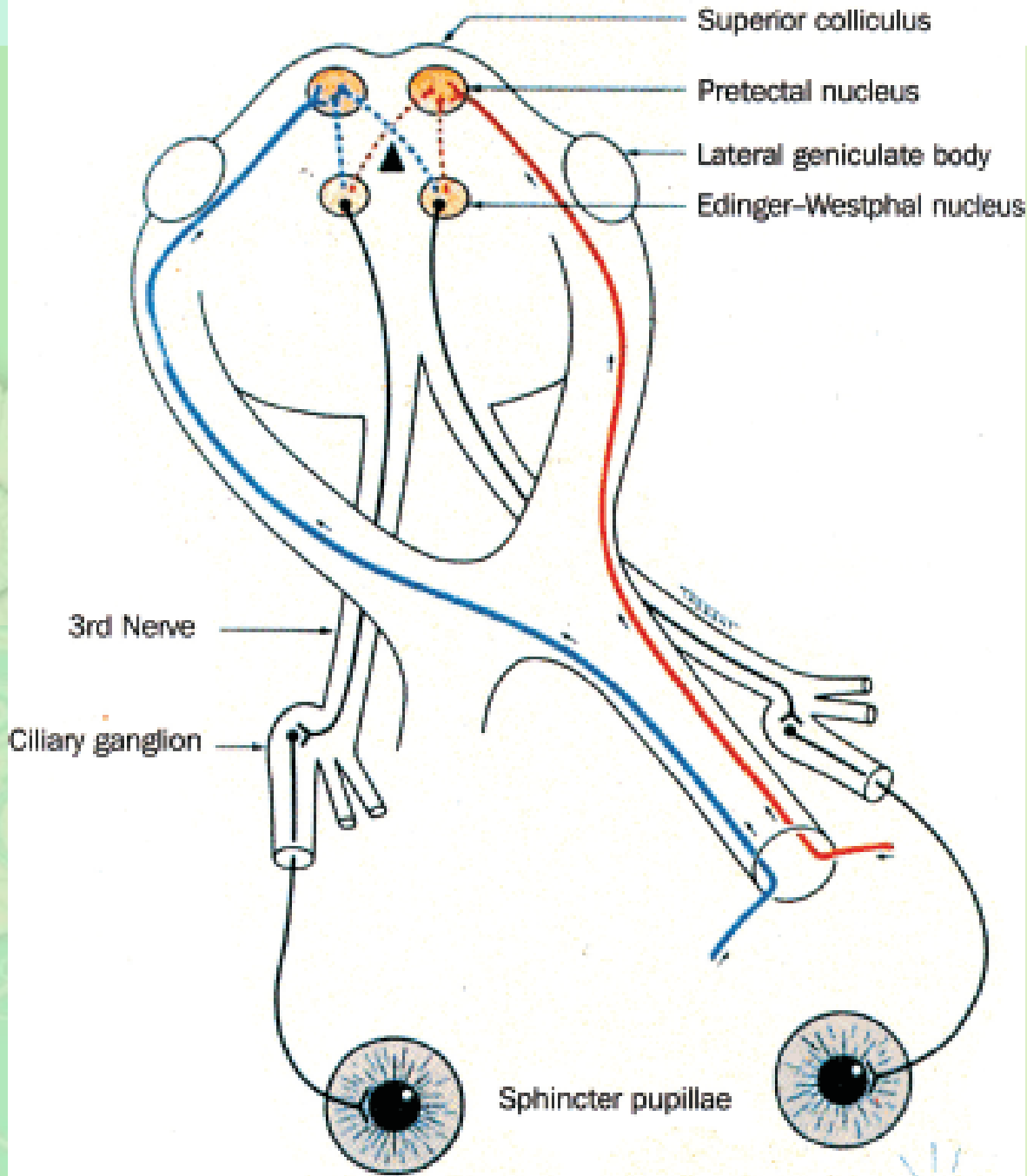


Parasympathetic pathway intact with contralateral stimulus



PATHWAY OF LIGHT REFLEX

- The light reflex is mediated by the retinal photoreceptors and subserved by four neurones
 - 1. First** (sensory) connects each retina with both pretectal nuclei in the midbrain at the level of the superior colliculi. Impulses originating from the nasal retina are conducted by fibres which decussate in the chiasm and pass up the opposite optic tract to terminate in the contralateral pretectal nucleus. Impulses originating in the temporal retina are conducted by uncrossed fibres (ipsilateral optic tract) which terminate in the ipsilateral pretectal nucleus.
 - 2. Second** (*internuncial*) connects each pretectal nucleus to both Edinger-Westphal nuclei. Thus a uniocular light stimulus evokes bilateral and symmetrical pupillary constriction. Damage to internuncial neurones is responsible for light-near dissociation in neurosyphilis and pinealomas.



Superior colliculus

Pretectal nucleus

Lateral geniculate body

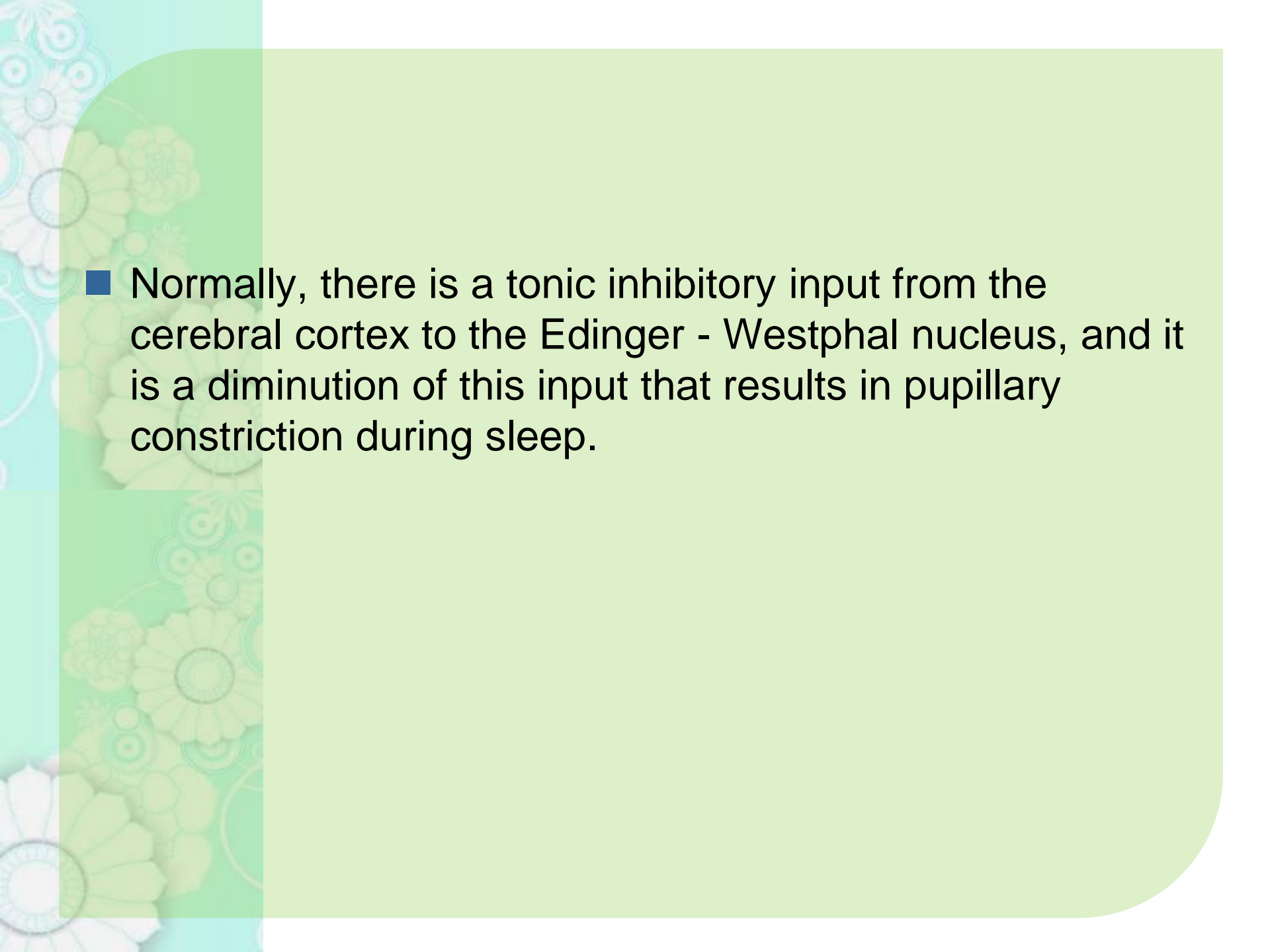
Edinger-Westphal nucleus

3rd Nerve

Ciliary ganglion

Sphincter pupillae

- 3. Third** (pre-ganglionic motor) connects the Edinger-Westphal nucleus to the ciliary ganglion. The parasympathetic fibres pass through the oculomotor nerve, enter its inferior division and reach the ciliary ganglion via the nerve to the inferior oblique muscle.
- 4. Fourth** (post-ganglionic motor) leaves the ciliary ganglion and passes in the short ciliary nerves to innervate the sphincter pupillae. The ciliary ganglion is located within the muscle cone, just behind the globe. It should be noted that, *although the ciliary ganglion serves as a conduit for other nerve fibers, only the parasympathetic fibers synapse there.*

- 
- Normally, there is a tonic inhibitory input from the cerebral cortex to the Edinger - Westphal nucleus, and it is a diminution of this input that results in pupillary constriction during sleep.

2. NEAR REFLEX

- The near reflex, a synkinesis rather than a true reflex, is activated when gaze is changed from a distant to a near target.
- It comprises **Accommodation, Convergence And Miosis.**
- Vision is not a prerequisite and there is no clinical condition in which the light reflex is present but the near response absent.
- Although the final pathways for the near and light reflexes are identical (i.e. 3rd nerve, ciliary ganglion, short ciliary nerves), the center for the near reflex is ill-defined

- There are probably two supranuclear influences: the frontal and occipital lobes.
- The midbrain centre for the **Near Reflex** is probably located **more ventrally** than the pretectal nucleus and this may explain *why compressive lesions such as pinealomas, preferentially involving the dorsal internuncial neurones involved in the light reflex, spare the near reflex fibres until later.*

3. DARKNESS REFLEX

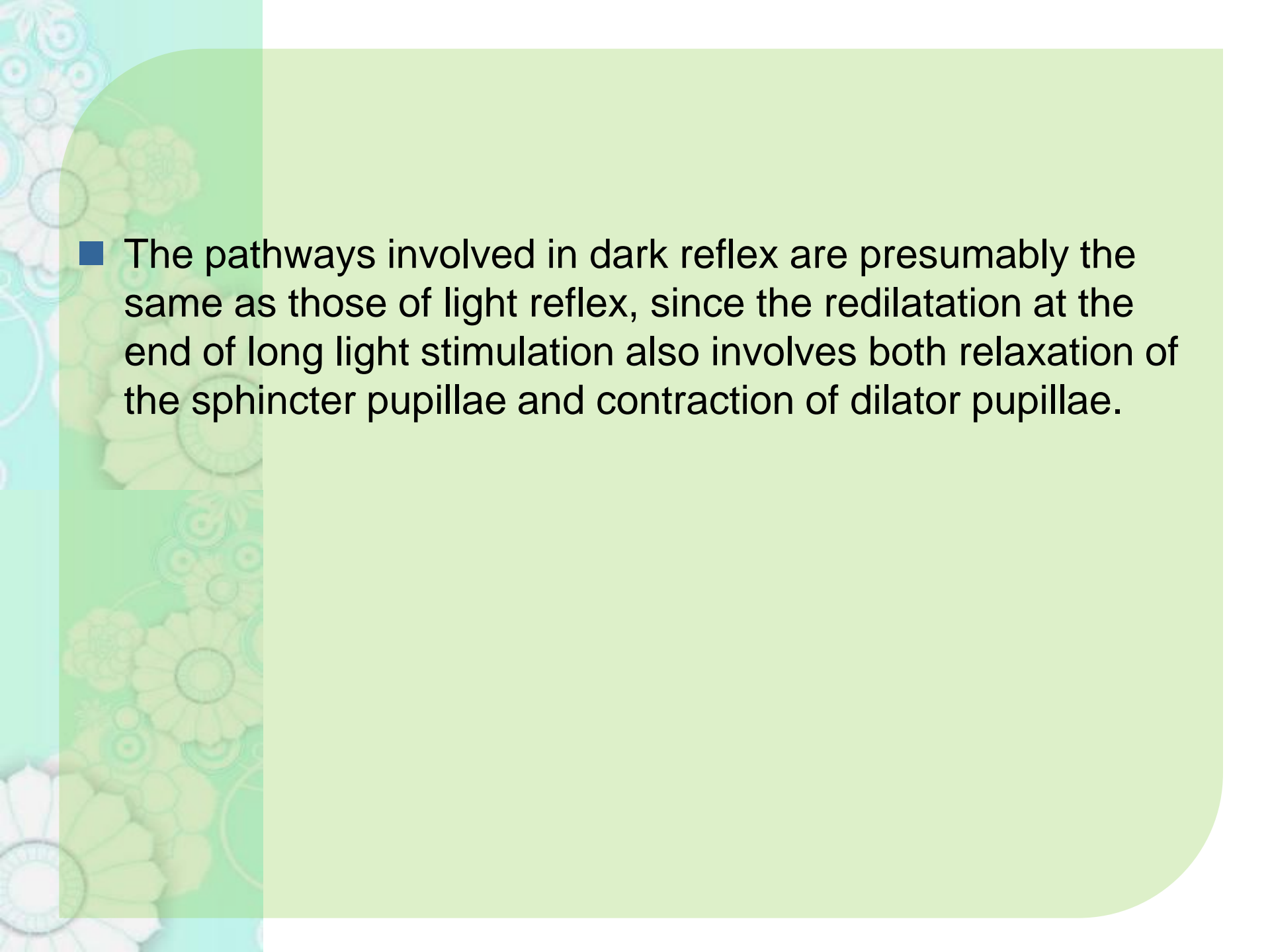
■ Lighted environment → Darkness



pupils dilate

✓ 2 causes for dilatation :

- First is simply abolition of light reflex with consequent relaxation of the sphincter pupillae.
- Second is contraction of dilator pupillae supplied by sympathetic nervous system.

- 
- The pathways involved in dark reflex are presumably the same as those of light reflex, since the redilatation at the end of long light stimulation also involves both relaxation of the sphincter pupillae and contraction of dilator pupillae.

4. PSYCHOSENSORY REFLEXES

- ❖ It refers to dilatation of pupil in response to sensory and psychic stimuli.
- The psychosensory reflexes are not seen in a newborn, but appear in the first few days of life, developing fully by the age of six months.
- Their mechanism is very complex and their pathways have still not been elucidated.
- In general, it is believed that the mechanism of psychosensory reflexes is a cortical one and apparently the pupillary dilatation in these results from two components - a sympathetic discharge to the dilator pupillae and an inhibition of the parasympathetic discharge to the sphincter pupillae.

Pathway Of Sympathetic Discharge

- It is believed that somehow sensations are conveyed to the hypothalamus, from where the impulses descend to intermediolateral cell column of the cervical and thoracic parts of the spinal cord.
- However, the *Ciliospinal Reflex* (dilatation of pupil in response to painful stimuli in the neck region) has been reported to be elicited from patients with damaged sympathetic pathways in brainstem and even from patients with cervical cord transections; indicating thereby that at least sympathetic discharge related to some of the psychosensory reflexes is mediated at the level of spinal cord.

THE LID – CLOSURE REFLEX

- It is a non-specific term, (since the lid-closure may be accompanied by either pupillary contraction or pupillary dilatation), and hence should be used sparingly.

1. *Constriction of pupil associated with blinking :*

- Following a blink, either voluntary or spontaneous, both pupils constrict transiently.
- It has been observed that such a reflex does not occur in darkness, so it has been assumed that perhaps this lid-closure reflex is nothing but simply a type of darkness reflex.

2. *Homolateral pupillary constriction associated with closure of the lid* which is evoked if the lid is held open whilst the effort of closure is made, is another entity which has also been referred to as lid-closure reflex.

- The effect is not large, however, if the subject is instructed to keep his gaze fixed on a distant object, while trying to close the eyes, this reaction does not occur.
- From this, it has been concluded that perhaps the pupillary contraction reported with this reflex is the result of an unconscious attempt at near gaze during the lid closure effect.

3. *Pupillary dilatation associated with lid-closure on touching the cornea (oculopupillary reflex):*

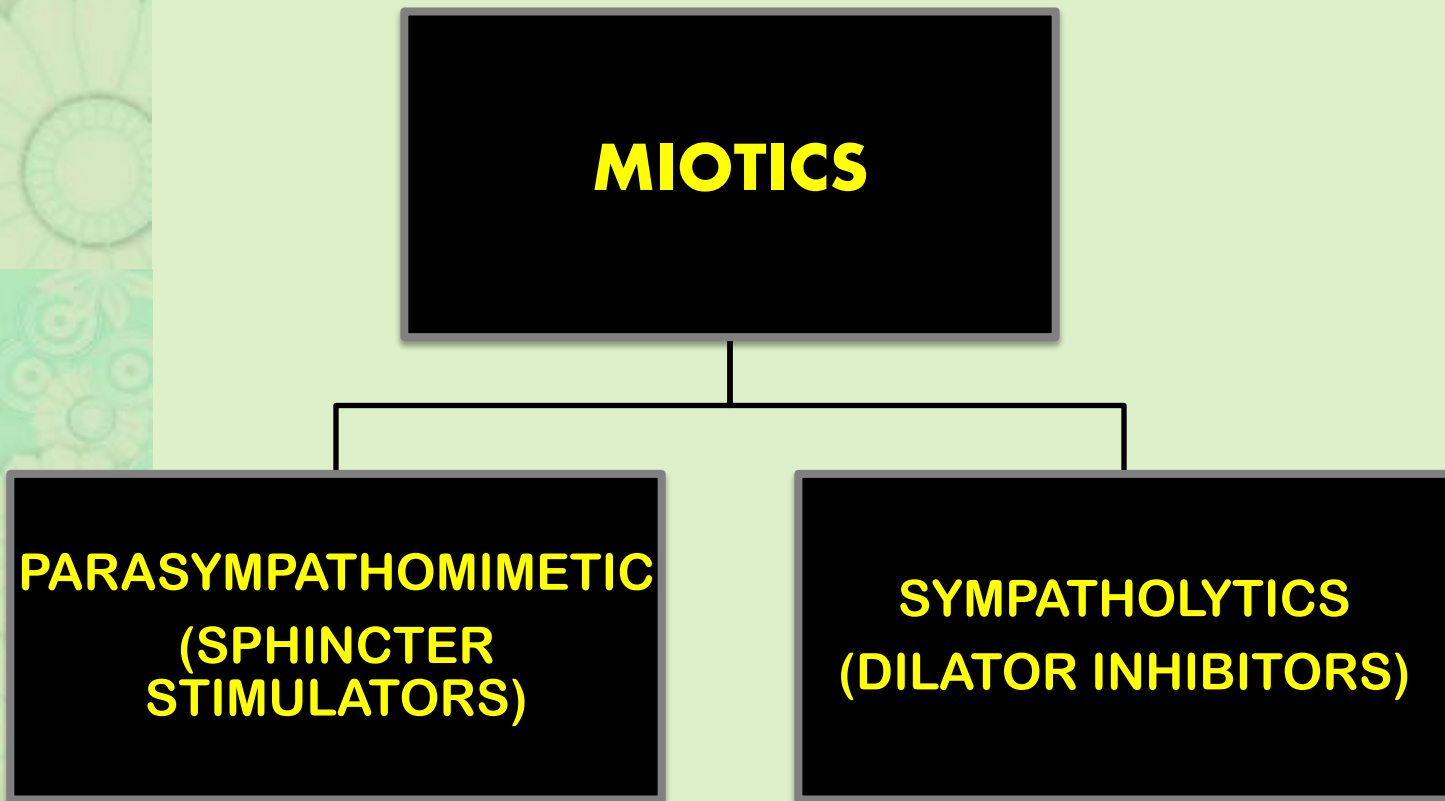
- It has been considered by some as lid-closure reflex.
- However, it has also been reported that it is simply a type of psychosensory reflex.

PHARMACOLOGY OF THE PUPIL

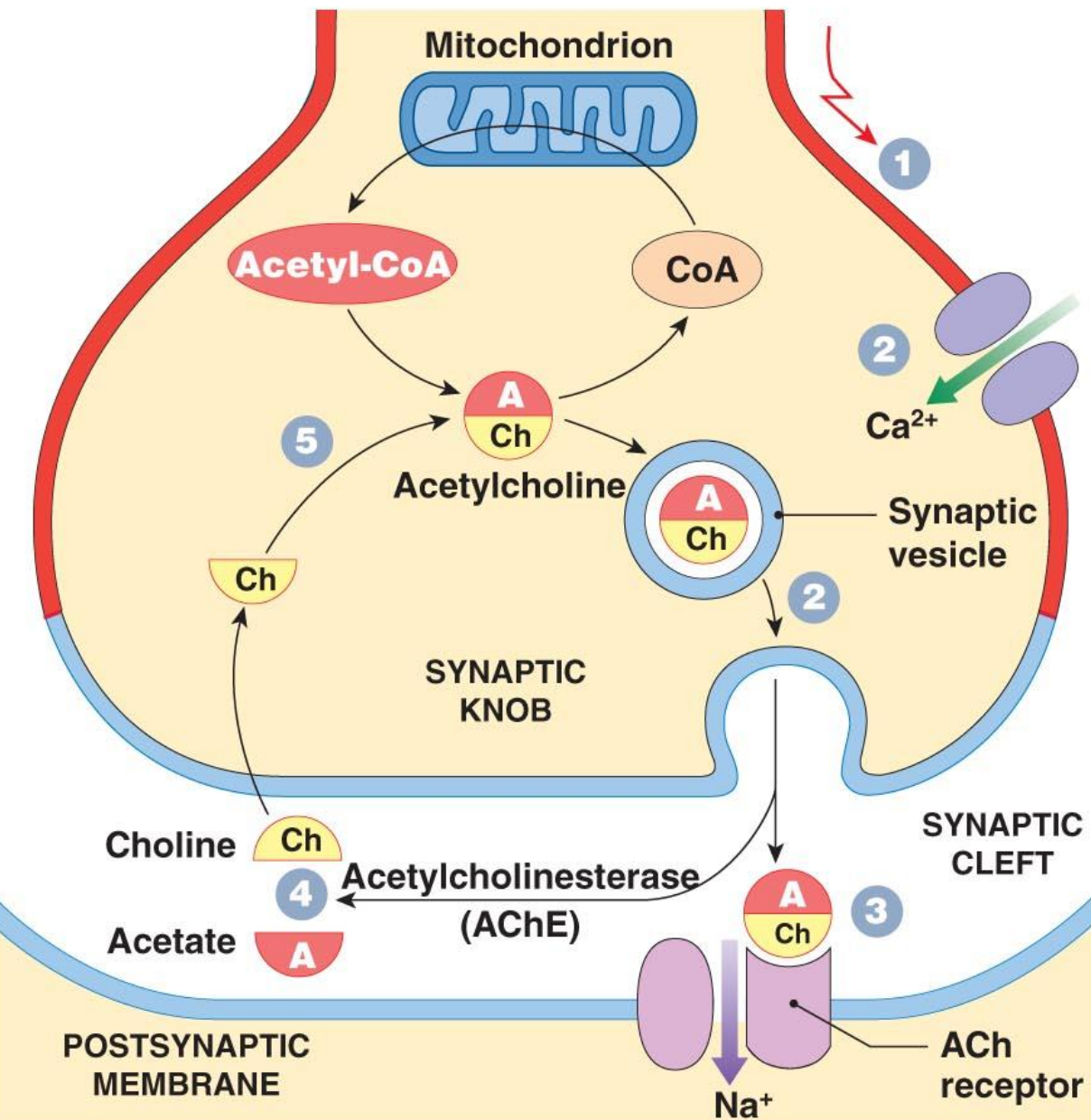
- MIOTICS
- MYDRIATICS

MIOTICS

- The drugs which constrict the pupil are known as miotics.



The events that occur at a cholinergic synapse



Events Occurring at Synapse

- 1 An arriving action potential depolarizes the synaptic knob
- 2 Calcium ions enter the cytoplasm, and after a brief delay, ACh is released through the exocytosis of synaptic vesicles.
- 3 ACh binds to sodium channel receptors on the postsynaptic membrane, producing a graded depolarization.
- 4 Depolarization ends as ACh is broken down into acetate and choline by AChE.
- 5 The synaptic knob reabsorbs choline from the synaptic cleft and uses it to synthesize new molecules of ACh.

1. PARASYMPATHOMIMETIC DRUGS

- Also called as cholinergic drugs – either imitate or potentiate the effects of acetylcholine.
- Depending upon the mode of action –
 - *Direct acting or agonists* : e.g: pilocarpine, structurally similar to Ach and act directly on muscarinic receptors on muscle membrane
 - *Indirect acting parasympathomimetics or cholinesterase inhibitors*: act indirectly by destroying the enzyme cholinesterase, thereby sparing the naturally acting Ach for its actions. 2 subgroups :
 - *reversible cholinesterase inhibitors (e.g physostigmine)*
 - *irreversible cholinesterase inhibitors (e.g ecothiophate iodide, demecarium, DFP)*
 - *Dual action parasympathomimetics* which acts as both

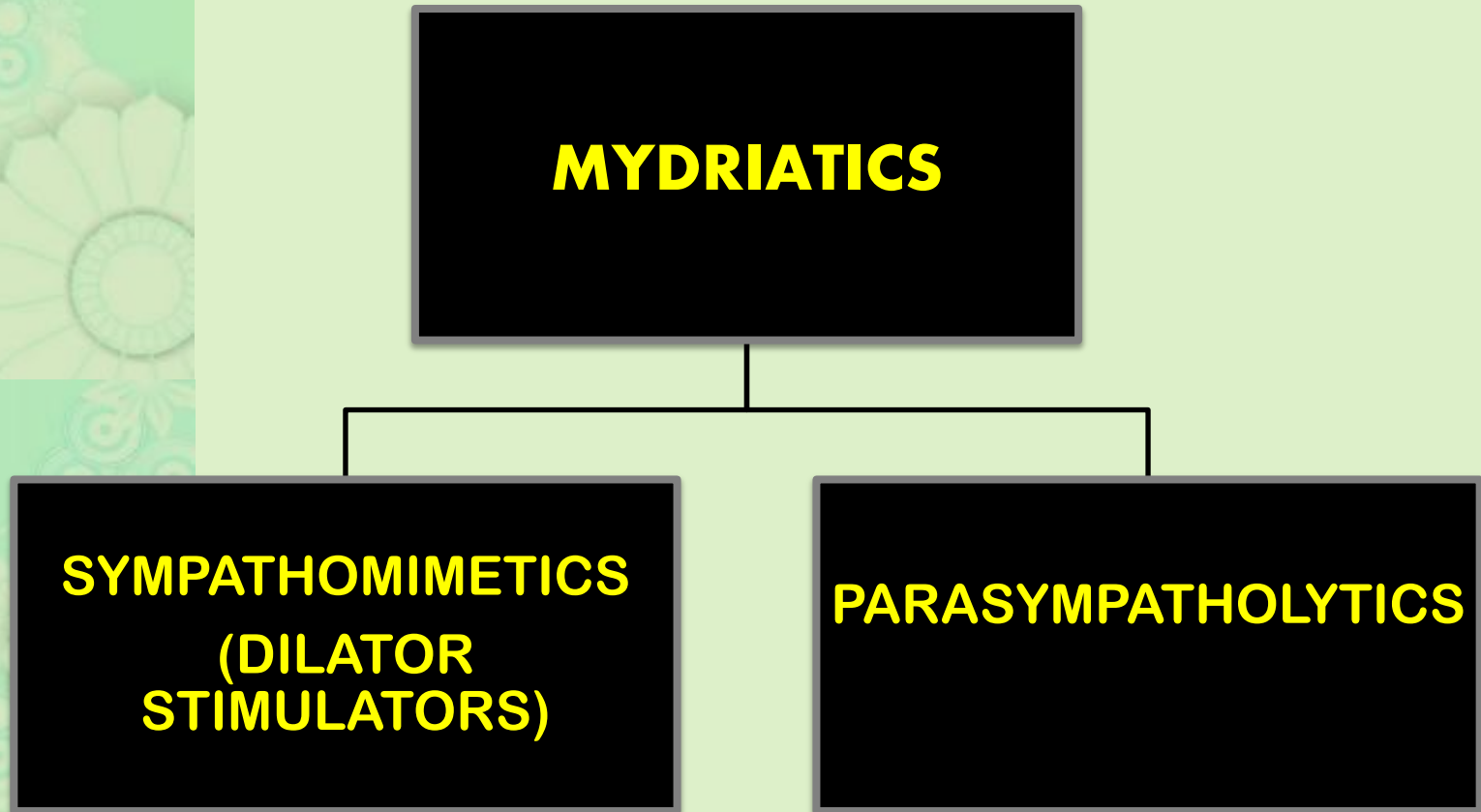
2. SYMPATHOLYTIC DRUGS

- Dilator pupillae can be inhibited either by preventing transmitter release at the NM Junction or by preventing the transmitter from affecting the dilator fibres.
- ***α- adrenergic blocker drugs*** such as thymoxamine, phenoxybenzamine, dibenamine & tolazoline produce miosis by preventing dilator contraction.
 - These drugs occupy α - receptor sites on the iris dilator muscle.
 - *Guane-thidine* is the commonly used sympatholytic drug.
 - It disrupts NE release from the nerve endings and depletes NE stores
 - Continued topical administration of this drug to the eye causes Horner's syndrome characterized by ptosis, miosis and supersensitivity to adrenergic drugs.

Other Miotics

- *Histamine* – acts as protoplasmic irritant and affects the sphincter fibres directly. It even constricts the pupil of a thoroughly atropinized eye.
- *Morphine* causes miosis by cutting off cortical inhibition of the Edinger-Westphal Nucleus

MYDRIATICS



1. SYMPATHOMIMETIC MYDRIATICS (DILATOR STIMULATORS)

- At the neuroeffector junction of the dilator pupillae, NE is stored in vesicles at the presynaptic terminal and is constantly released.
 - After the release, some of the NE is taken up into the presynaptic vesicle, some is metabolized & destroyed by monoamine oxidase, a small portion is washed away & the last portion may be degraded by the enzyme catechol-O-methyl transferase.
- Sympathomimetics increase the dilator activity by any of the three ways :
1. Increasing NE release
 2. Preventing its reuptake by presynaptic vesicle, or
 3. Directly stimulating the dilator fibres.

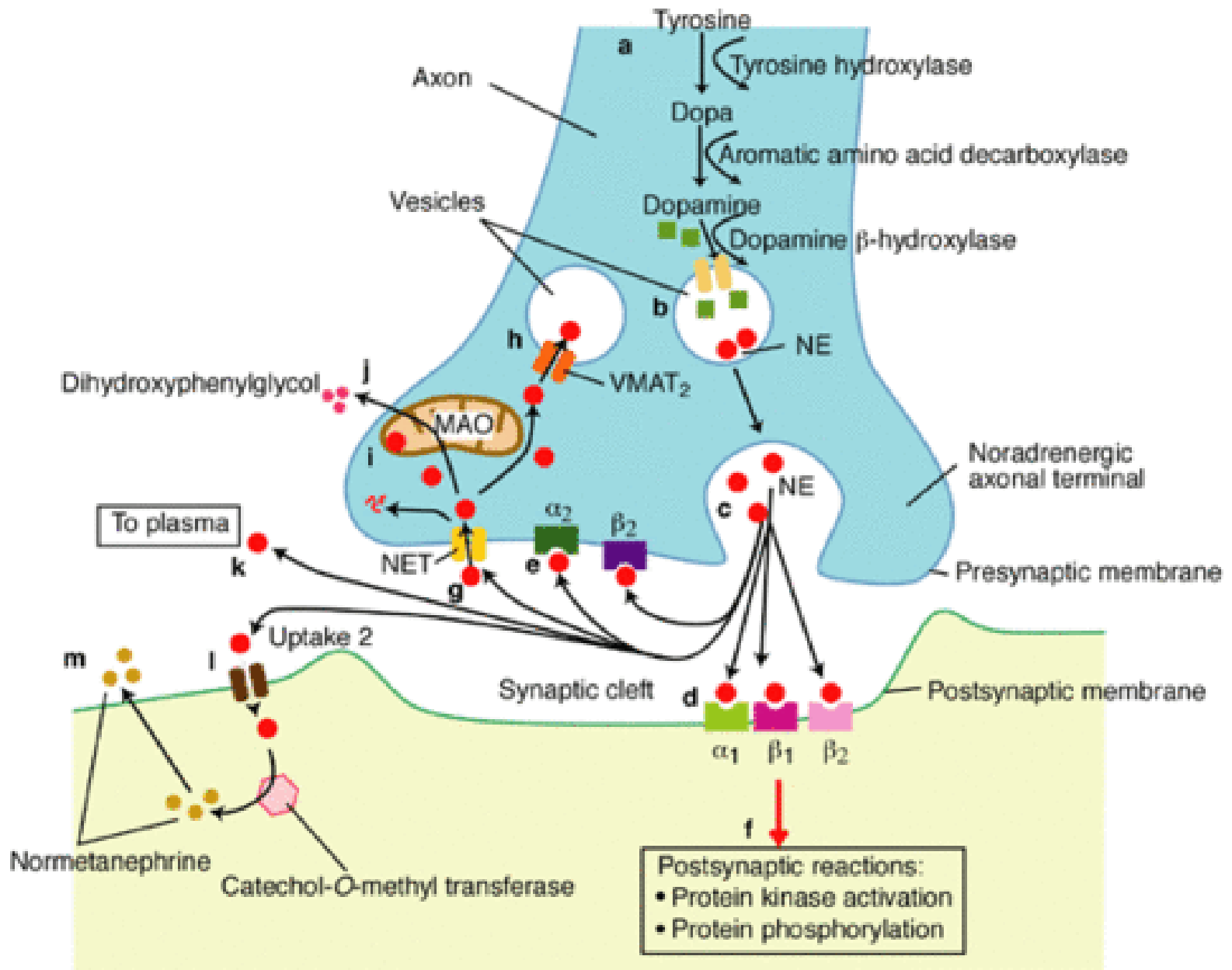



Diagram of a noradrenergic axonal terminal showing the release and re-uptake of norepinephrine

- **Adrenaline (epinephrine)** – acts directly on the α -receptors on the dilator pupillae, produces dilation after instillation of four drops of 1 in 1000 solution. Instillation is repeated every 5 min. However topically applied epinephrine is not very effective in normal eyes, because it is readily taken up or inactivated. This makes it useful in testing for certain denervation syndromes in which dilator becomes hypersensitive.
 - **Phenylephrine** – synthetic analog of epinephrine. It stimulates the normal dilator, when used in fairly high concentration (5%-10%).
 - **Hydroxyamphetamine and ephedrine** – cause NE to be rapidly released from peripheral nerve terminals – mydriasis of short duration.
 - **Cocaine** – Local anaesthetic – prevents the reuptake of NE at the presynaptic terminal. Thus NE released from the nerve remains in the synaptic cleft and activates the dilator fibres.
- **Cocaine and hydroxyamphetamine are, therefore, ineffective and adrenaline remains effective when the sympathetic nerve is paralyzed.**

2. PARASYMPATHOLYTIC MYDRIATICS

- These drugs compete with Ach at the myoneural junction and thus cause mydriasis by blocking sphincter activity.
- ❖ **Atropine** - strongest mydriatic which completely paralyses the sphincter pupillae and ciliary muscle. Used as 1% drops or oint. Causes complete dilatation in 30-40 mins and cycloplegia in about 2 hours. Its effect persists for a week or more.
- ❖ **Homatropine (2% drops)** – acts more quickly than atropine. Causes cycloplegia and mydriasis in about 45 mins to 1 hr. Its effect passes completely in about 48 hrs.
- ❖ **Cyclopentolate (1% drops)** – short acting cycloplegic. Causes mydriasis and cycloplegia in about 1 hr and effect lasts for 6-12 hrs.
- ❖ **Tropicamide (1%)** – quick and short acting.



ABNORMALITIES OF PUPILLARY REFLEXES

AFFERANT PATHWAY DEFECTS

TOTAL AFFERENT PATHWAY DEFECT (TAPD) OR AMAUROTIC PUPIL

- Caused by a complete optic nerve or retinal lesion leading to total blindness on the affected side.
- Characterized by the following :
 - ▣ The involved eye is completely blind (i.e no light perception)
 - ▣ Absence of direct light reflex on the affected side and absence of consensual light reflex on the normal side.
 - ▣ When the normal eye is stimulated, both pupils react normally.
 - ▣ In diffuse illumination, both pupils are equal in size.
 - ▣ The near reflex is normal in both eyes.

Amaurotic pupillary response

Normal eye



Contralateral pupil constricted

Blind eye



Contralateral pupil not constricted

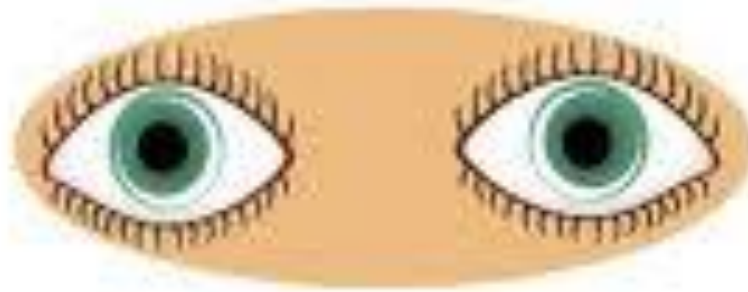
RELATIVE AFFERENT PATHWAY DEFECT (RAPD) OR MARCUS GUNN PUPIL

- It is the paradoxical response of a pupil to light in the presence of a relative afferent pathway defect (RAPD).
- Caused by an incomplete optic nerve lesion or a severe retinal disease.
- It is best tested by 'swinging flashlight test'


Swinging Flashlight Test

- To perform this test, a bright flashlight is shone on to one pupil and constriction is noted. Then the flashlight is quickly moved to the contralateral pupil and response is noted.
- This swinging to and fro of flashlight is repeated several times while observing the pupillary response.
- Normally, both pupils constrict equally and the pupil to which light is transferred remains tightly constricted.
- In the presence of RAPD in one eye, the affected pupil will dilate (paradoxical response) when the flashlight is moved from the normal eye to the abnormal eye.
- This response is called *Marcus Gunn Pupil*.
- It is the earliest indication of optic nerve disease even in the presence of a normal visual acuity.

No Light



**Normal
Response
to Light**



**Positive
RAPD of
Right Eye**



There are many different methods to measure an RAPD in clinic. A common method is using a qualitative 1-4+ grading scale.

Grading Scale: RAPD

Grade 1+: A weak initial pupillary constriction followed by greater redilation

Grade 2+: An initial pupillary stall followed by greater redilation

Grade 3+: An immediate pupillary dilation

Grade 4+: No reaction to light – Amaurotic pupil

EFFERANT PUPILLARY DEFECTS

- Characterized by absence of both direct and consensual light reflex on the affected side (say right eye) and presence of both direct and consensual light reflex on the normal side (i.e left eye).
- On the affected side, near reflex is also absent and pupils remains fixed and dilated.

EFFERENT PUPILLARY DEFECT ETIOLOGIES:

- Iris sphincter damage from trauma
- Tonic pupil (Adie's pupil)
- Third-nerve palsy
- Pharmacologic agents:
 - Unilateral use of dilating drops
 - Atropine, cyclopentolate, homatropine, scopolamine, tropicamide, phenylephrine.
 - Handling/administrating of sympathomimetic or anticholinergic agents :
 - Sympathomimetic agents:
 - OTC cold agents containing ephedrine
 - Illegal street drugs: cocaine, amphetamines, methamphetamine
 - Dietary supplements: ephedra alkaloids
 - Very popular illicit designer drugs: 3, 4-methylenedioxy methamphetamine [MDMA, "ecstasy"]

- Anticholinergic agents including scopolamine patch.
- Other drugs causing mydriasis:
 - LSD (lysergic acid diethylamide)
 - Alcohol
 - Marijuana
 - Mescaline
 - Jimson weed (*Datura stramonium*) containing belladonna alkaloids (active ingredients are atropine and scopolamine). Some brands of eye make-up contain belladonna alkaloids.
- Traumatic iritis, uveitis, angle-closure glaucoma, pseudoexfoliation syndrome and recent eye surgery
- Benign episodic unilateral mydriasis

COMMON CAUSES OF EFFERENT PUPILLARY DEFECTS ARE :

1. *Brainstem lesions* at the level of the superior colliculus and red nucleus. Lesions here are often accompanied by long tract signs.
2. *Fascicular third nerve lesions*. Compressive third nerve lesions classically have pupillary involvement, although an efferent defect is not pathognomonic of a compressive lesion, as 20% of microvascular palsies will affect the pupillary fibres. An efferent pupillary defect may be a false localizing sign when raised intracranial pressure causes uncal herniation and compression of third nerve.
3. *Lesions of the ciliary ganglion* or short ciliary nerves.
4. *Iris damage* 2° to previous surgery or grossly elevated IOP.
5. *Drugs*: inadvertent exposure to mydriatic agent such as atropine is a common cause of fixed dilated pupil. Pilocarpine 1% will constrict a dilated pupil 2° to a neurological lesion; it will have no effect on dilated pupil caused by a mydriatic agent.

TONIC PUPIL

- Damage to the ciliary ganglion or short ciliary nerves produces tonic pupil which is characterized by following :
 - Reaction to light is absent and to near reflex is very slow and tonic.
 - Accommodative paresis.
 - Cholinergic supersensitivity of the denervated muscle (i.e constricts with 0.125% pilocarpine, while normal pupil does not)
 - The affected pupil is larger.

Causes Of Tonic Pupil :

A. Local tonic pupil

- Viral ciliary ganglionitis (e.g Herpes zoster)
- Orbital or choroidal trauma or tumours
- Blunt trauma to the globe may injure branches of short ciliary nerves at the iris root.

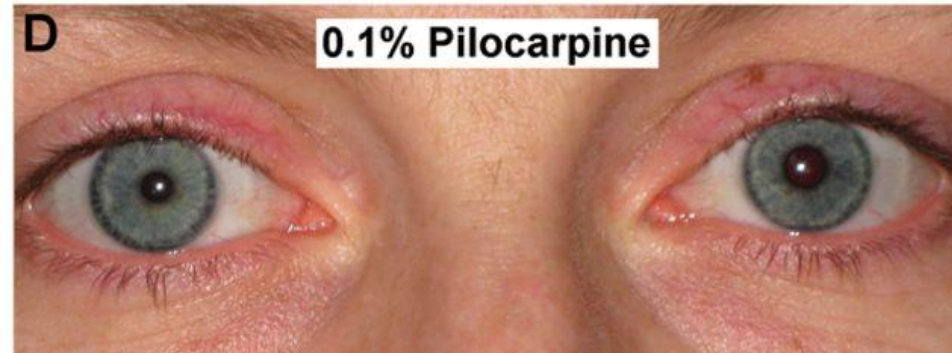
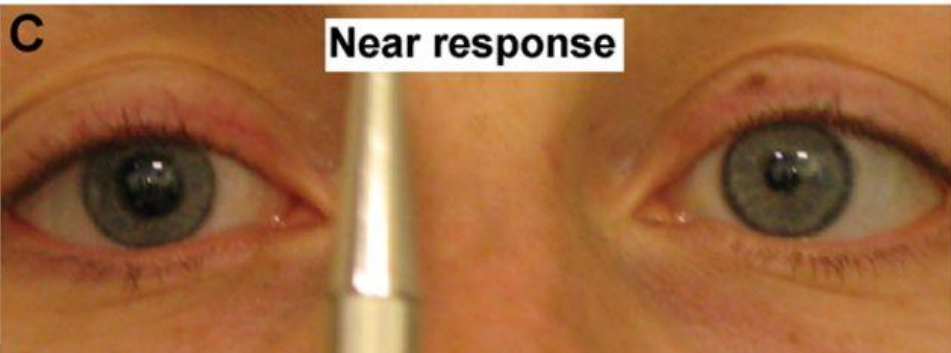
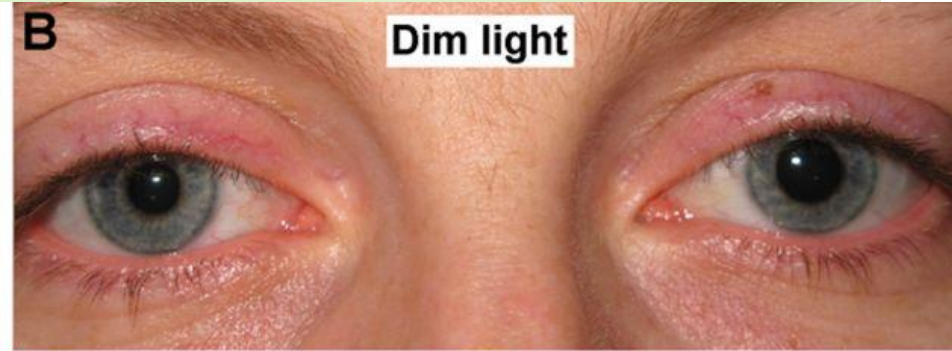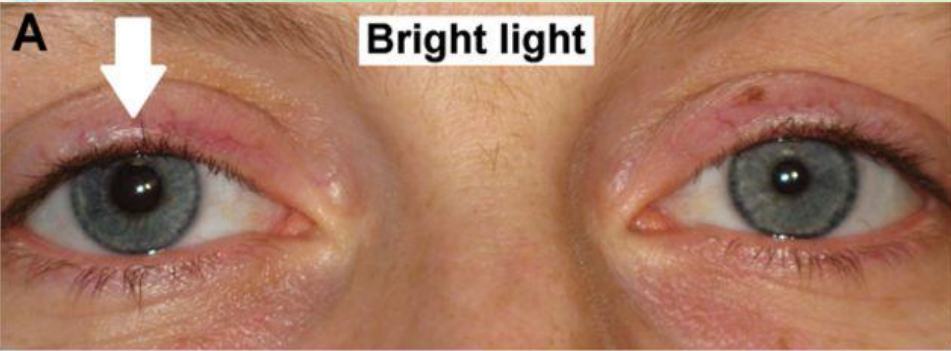B. Neuropathic tonic pupil

- Part of picture of peripheral neuropathy of diabetes, alcoholism.

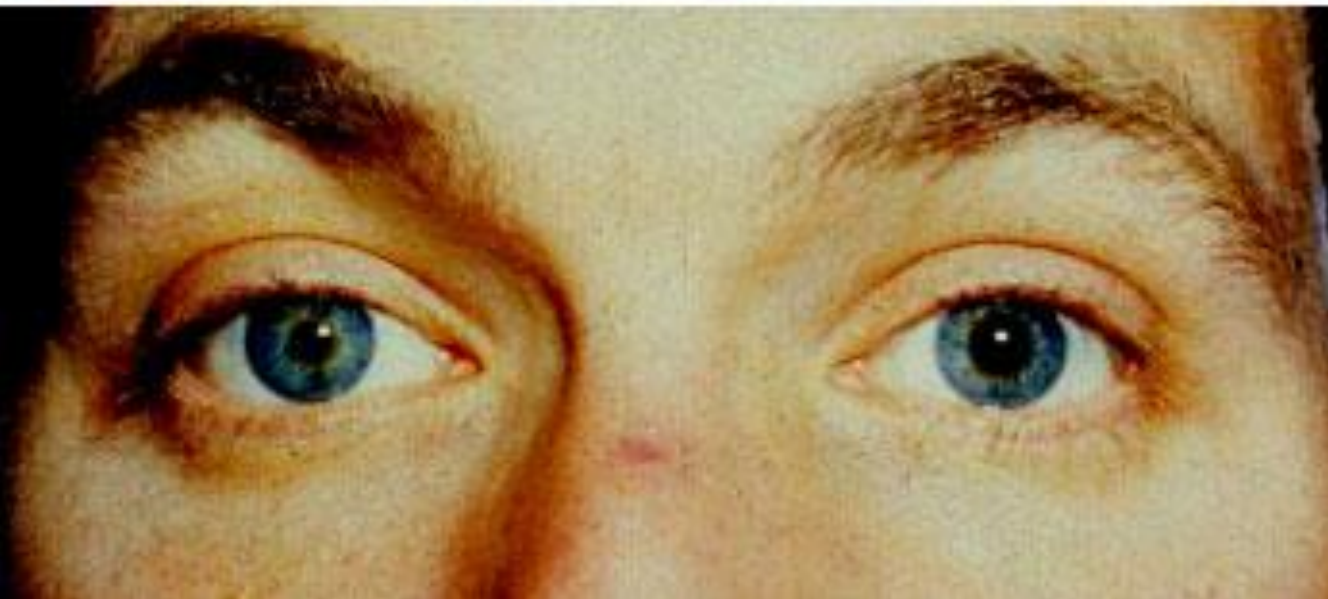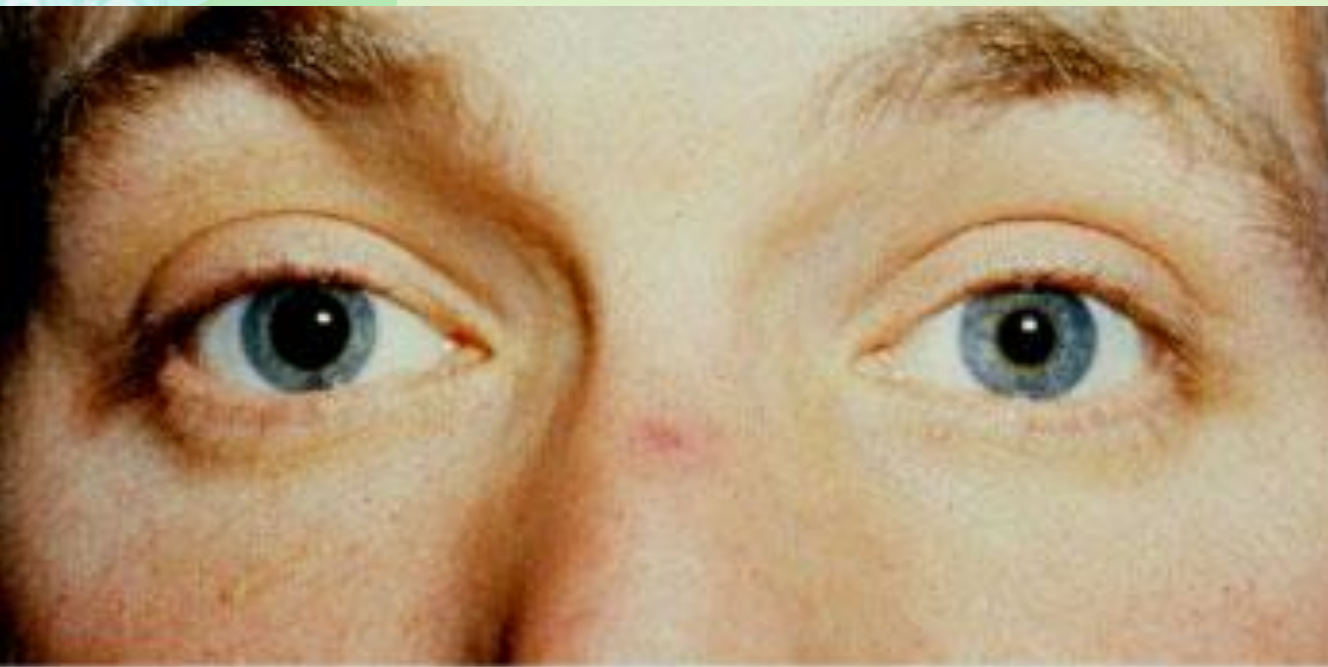C. Idiopathic tonic pupil with benign areflexia (Adie's tonic pupil)

The Adie's Tonic Pupil

- Adie's tonic pupil is caused by denervation of the postganglionic supply of the sphincter pupillae and ciliary muscle of unknown etiology.
- Its characteristic features are :
 - ⊙ It is usually unilateral (in 80%)
 - ⊙ It typically effects healthy young women more often than men.
 - ⊙ It may be assoc. with absent knee jerk.
 - ⊙ The affected pupil is large and irregular (anisocoria)
 - ⊙ The light reflex is absent or slow.
 - ⊙ Near reflex is slow and tonic.
 - ⊙ Accommodative paresis.
 - ⊙ There may be assoc. mild regional impairment of corneal sensations.



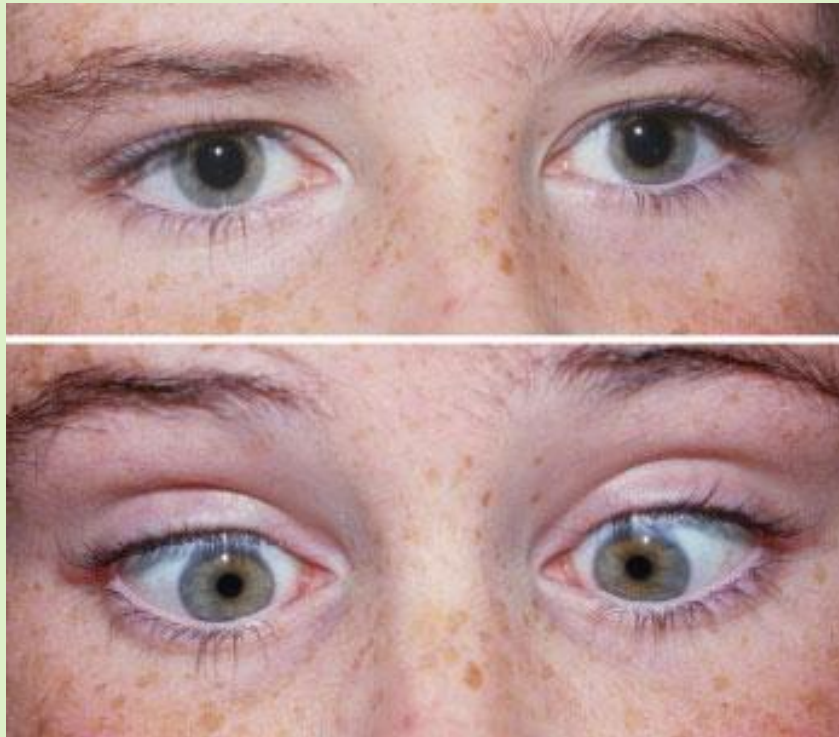- Pharmacological testing helps in the diagnosis of Adie's tonic pupil.
- **In 80-90% of patients with Adie's tonic pupil, 0.125% pilocarpine or 2.5% methacholine causes denervation supersensitivity.** The concentration is too weak to cause constriction of the normal pupil.
- Pharmacologic testing steps:
 - 0.125% pilocarpine (prepared by diluting one part 1% pilocarpine with 7 parts balanced salt solution)
 - Patient is fixating at a distance to prevent near accommodative reflex. Measure the pupil size of each eye.
 - Instill a drop of 0.125 pilocarpine ophthalmic solution in each eye, and recheck the pupils in 10-15 minutes.
 - A positive test result – The tonic pupil constricts significantly more than the contralateral pupil



Right tonic pupil: dilated pupil with minimal reaction to light (above); the right pupil constriction (denervation supersensitivity) and no left pupil constriction with 0.125 % pilocarpine.

PUPILLARY LIGHT - NEAR DISSOCIATION

- The term pupillary light-near dissociation refers to any situation in which the pupillary near reaction is present and the light reaction is absent.



Bilateral light-near dissociation caused by the dorsal midbrain syndrome: moderately dilated pupils (above) with brisk near reflex (below).

CAUSES OF LIGHT - NEAR DISSOCIATION

Of course Argyll Robertson pupil is one of the important causes of light-near dissociation; but it is not synonymous with the condition.

Causes Of Light Near Dissociation

- Bilateral complete afferent pathway defect, e.g. in B/L old total retinal detachment or B/L optic atrophy, the light reflex is absent but near reflex is present.
- Lesions in the midbrain : the light reflex path can be interrupted in the pretectal area without damaging the more ventrally located input for the near reflex. Causes incl. tumors (e.g. pinealomas manifesting as Parinaud's syndrome), vascular lesions, encephalitis and demyelination. Neurosyphilis causing ARP also causes damage in the area of pretectum to the intercalated neuron.
- Third nerve palsy with aberrant regeneration of medial rectus innervation into the sphincter innervation pathway : pseudo-Argyll Robertson's Pupil.
- Ciliary ganglion or short ciliary nerve lesions with aberrant regeneration of accommodation impulse fibres into sphincter pupillae.

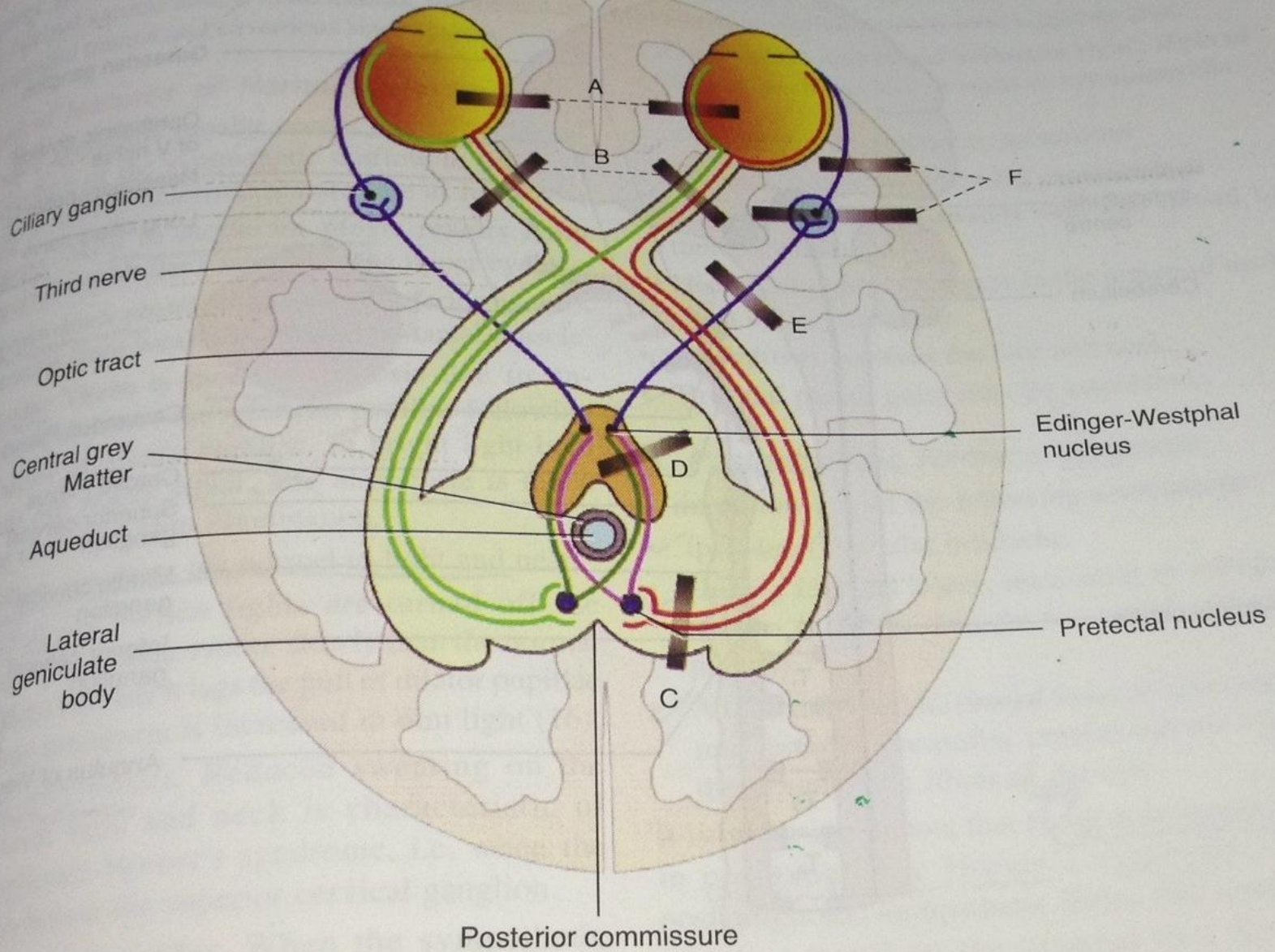


Fig. 7.7. Site of lesions producing light-near dissociation: A, Retinal lesions; B, Optic nerve lesions; C, Lesions in pretecal region; D, Lesions in the intercalated neurons (e.g. Argyll Robertson pupil); E, Third nerve lesions with aberrant regeneration of sphincter innervation; F, Ciliary ganglion or short ciliary nerve lesions with aberrant regeneration of sphincter innervation.

TABLE 9-19-2 CAUSES OF LIGHT-NEAR DISSOCIATION OF THE PUPIL

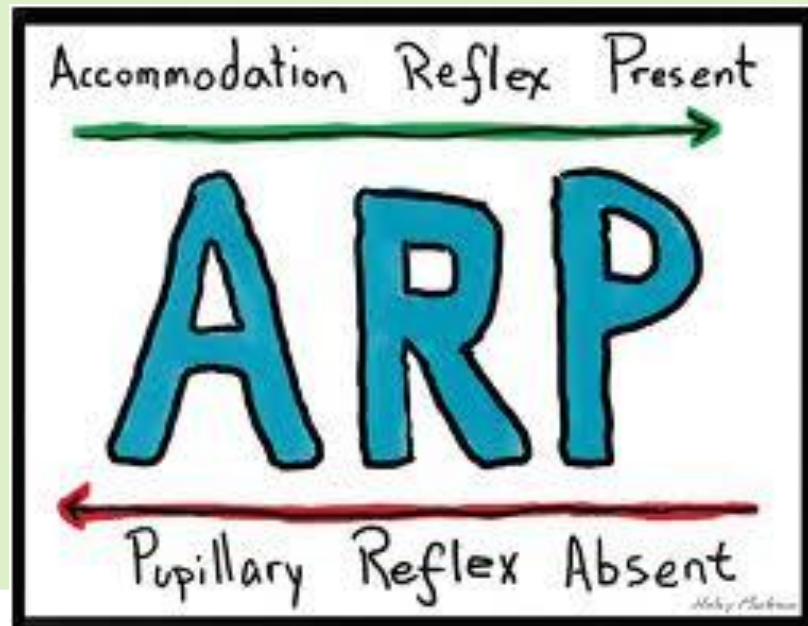
Cause	Location	Mechanism
Severe loss of afferent light input to both eyes	Anterior visual pathway (retina, optic nerves, chiasm)	Damage to the retina or optic nerve pathways
Loss of pretectal light input to Edinger-Westphal nucleus	Tectum of the midbrain	Infectious (Argyll Robertson pupils) or compression (pinealoma)
Adie's syndrome	Iris sphincter	Aberrant reinnervation of sphincter by accommodative neurons
Third cranial nerve aberrant reinnervation	Iris sphincter	Aberrant reinnervation of sphincter by accommodative neurons or medial rectus neurons

ARGYLL ROBERTSON PUPIL (ARP)

- Argyll Robertson Pupil (ARP) – 1869 –in pts with Tabes Dorsalis.
- Bilateral, miotic pupil with irregular margins and are asymmetrical.

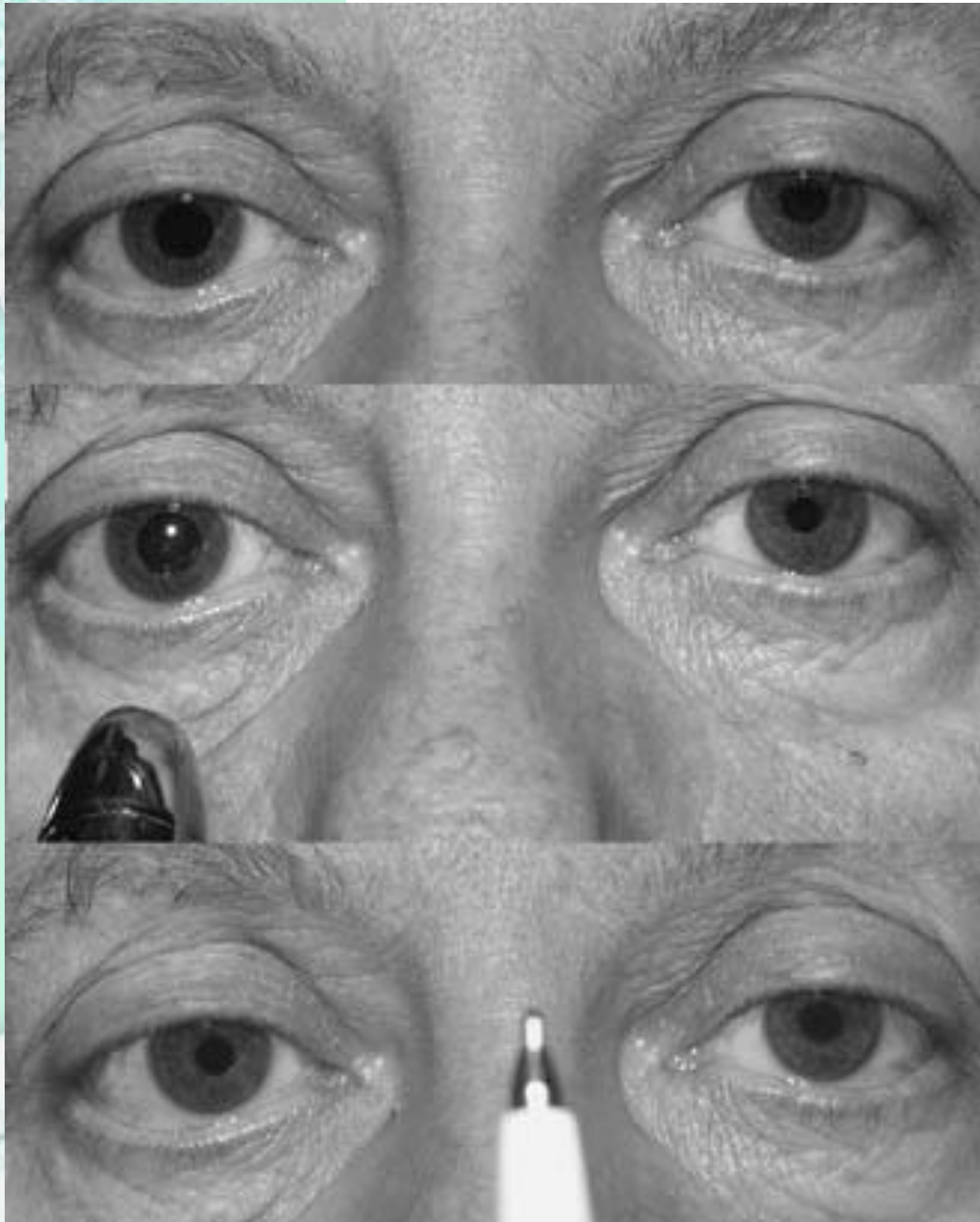Response to light and near reflex :

- Light reflex is absent & accommodation is retained. The lesion is at the pretectal area. Commonly seen in tertiary neurosyphilis especially in Tabes.
- Other causes include :
 - Diabetes
 - Wernicke's encephalopathy
 - Encephalitis,
 - Midbrain tumours
 - Hereditary neuropathies



The features of ARP are :

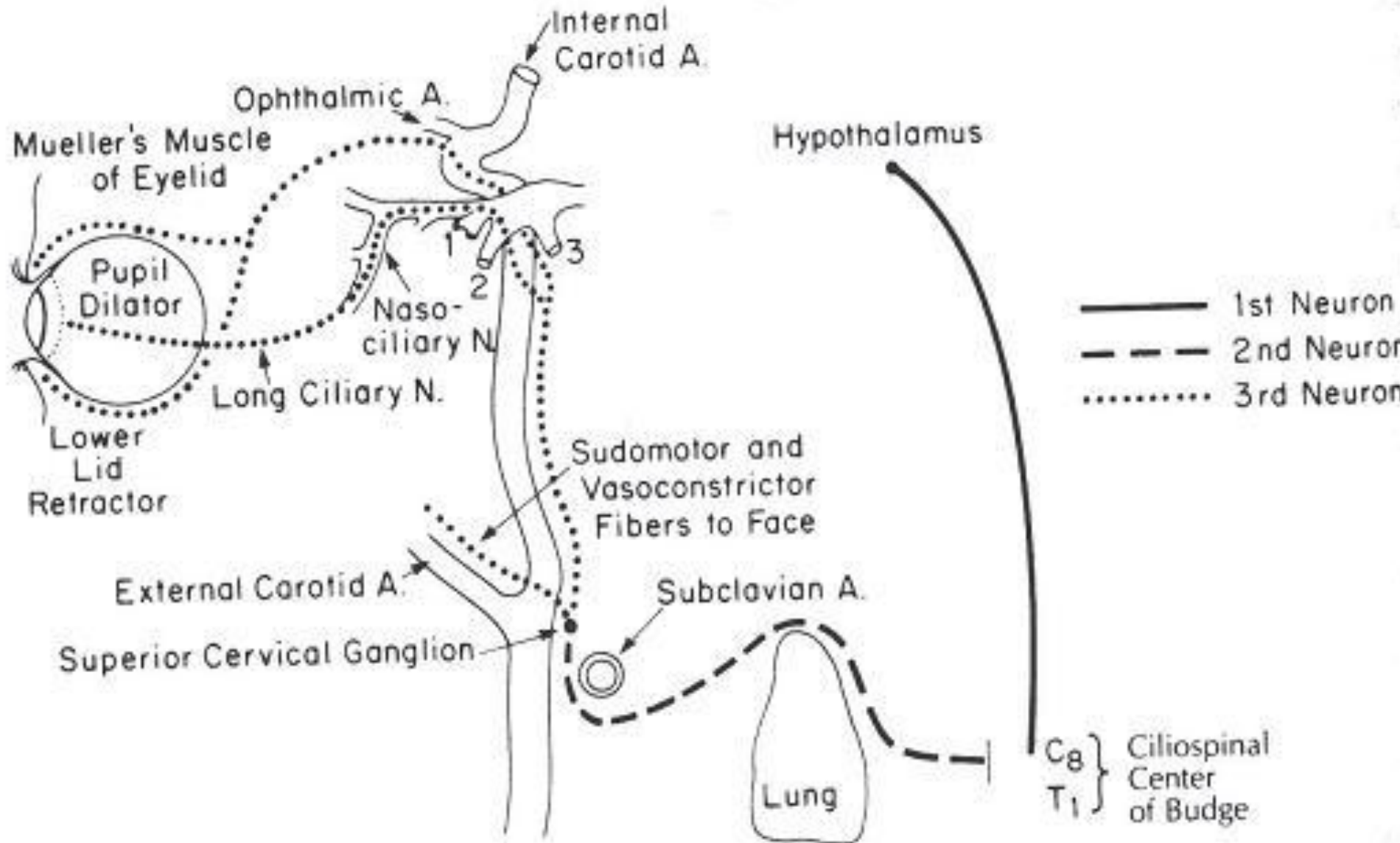
- ✿ Small pupils < 2 mm
- ✿ Often irregular
- ✿ Near response is brisk and normal
- ✿ Light reflex is absent
- ✿ Iris atrophy is frequent with iris showing transillumination defects and poor dilatation with mydriatics
- ✿ Visual acuity is usually normal



- Light reflex absent, accommodation reflex present

SYMPATHETIC PARESIS

SYMPATHETIC SUPPLY OF EYE :



HORNER'S SYNDROME

(OCULOSYMPATHETIC PARESIS)

It is of three types :

CENTRAL

LESION :
hypothalamus to C8-T2

CAUSES : brainstem &
spinal cord/
vascular/demyelinating/
tumors/syringomyelia

PREGANGLIONIC

LESION : C8-T2 to
superior cervical
ganglion

CAUSES: pancoast
tumour/carotid and
aortic aneurysm &
dissection/neck lesions-
glands,trauma & post
surgical

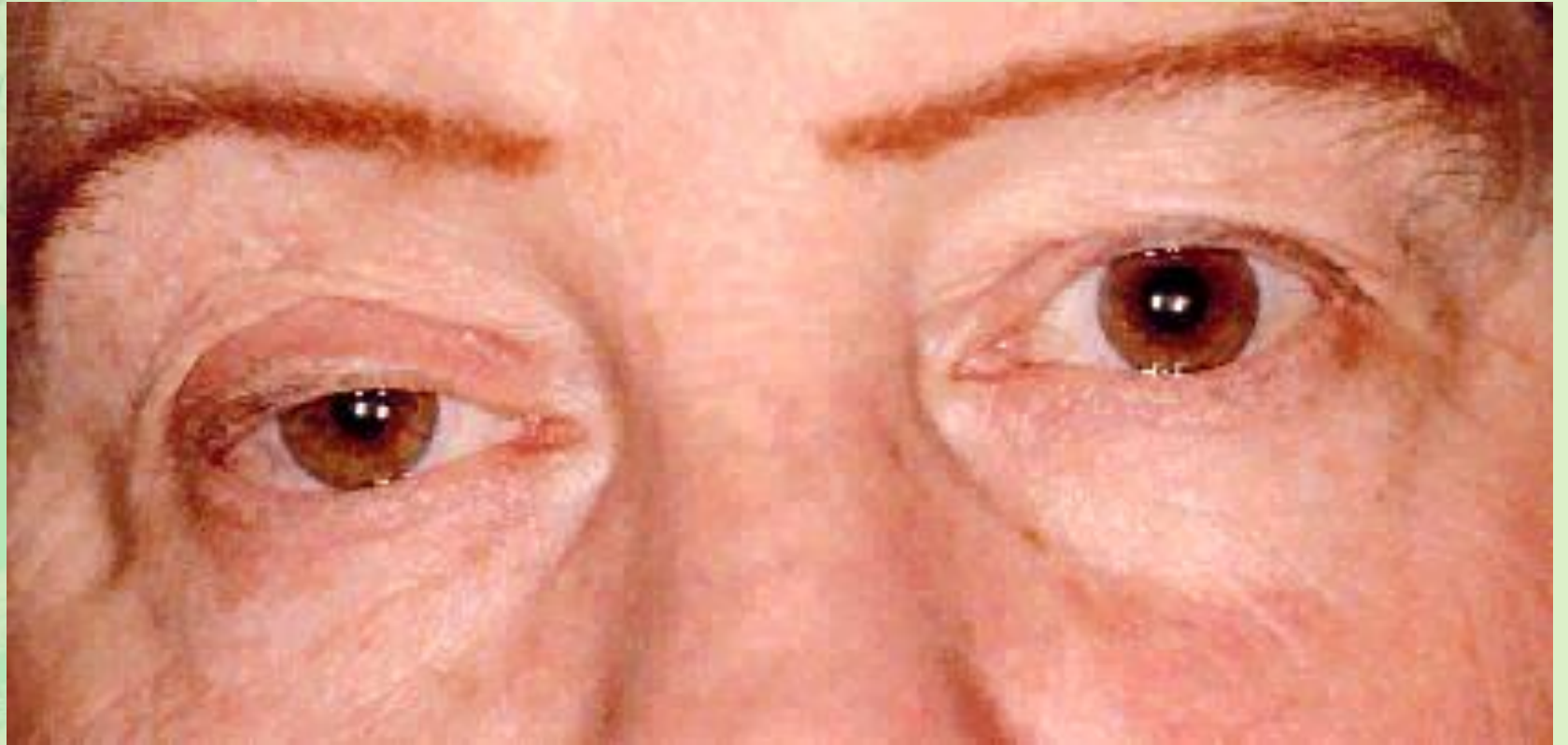POSTGANGLIONIC

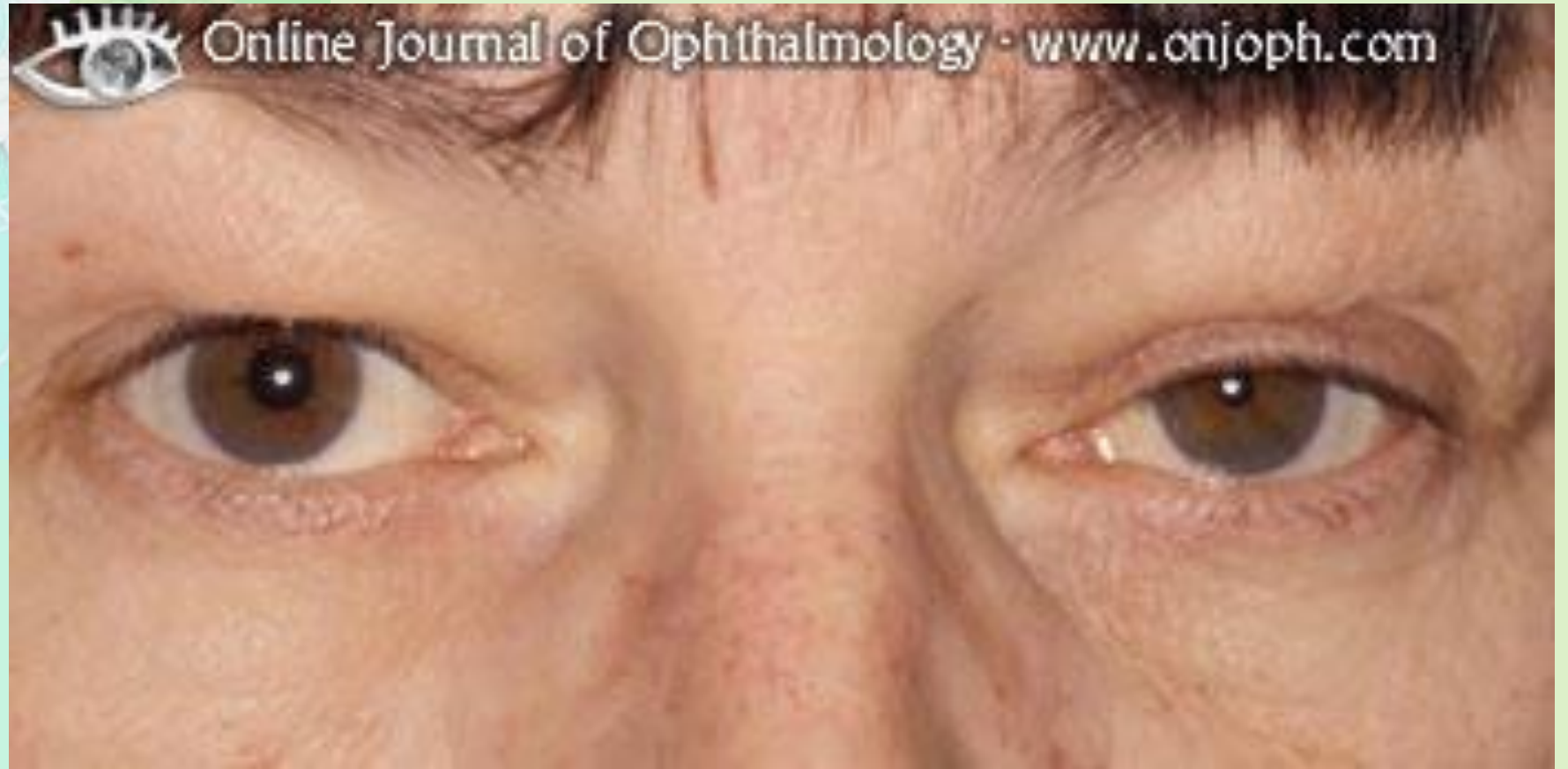LESION :superior
cervical ganglion to ICA
to cavernous sinus to
V1

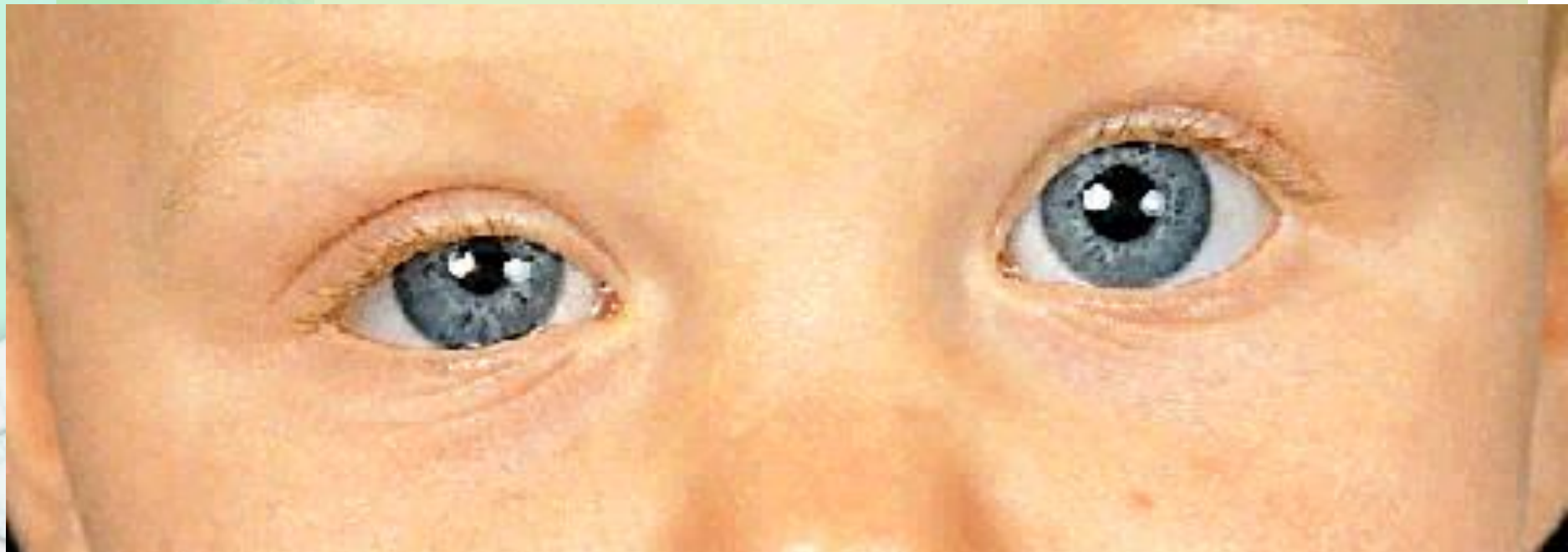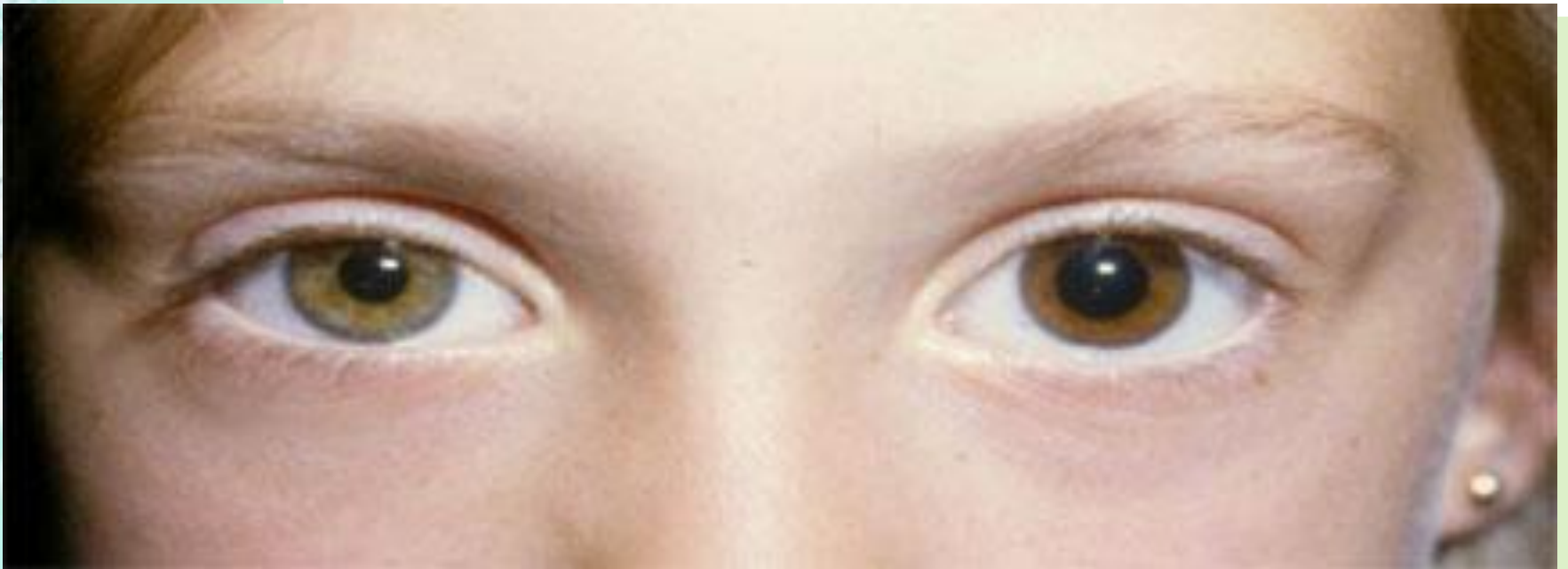CAUSES :ICA
dissection, cavernous
sinus mass,
nasopharyngeal tumor,
otitis media, cluster
headache

CLINICAL FEATURES OF HORNER'S SYNDROME

- ✿ Ptosis – paralysis of muller muscle of upper eyelid (usually 1-2mm)
- ✿ Upside down ptosis – weakness of the inferior tarsal muscle.
- ✿ Miosis – accentuated in dim light
- ✿ Pupillary reactions are normal to light and near
- ✿ Dilatation lag
- ✿ Facial anhydrosis – when the lesion is below the superior cervical ganglion
- ✿ Heterochromia irides – seen in congenital Horner's syndrome – the pigment of iris stroma fail to develop







LOCALIZATION OF HORNER'S SYNDROME

■ CENTRAL HORNER'S SYNDROME

- Assoc. with brain stem signs, signs of cervical cord disease or signs of syringomyelia

■ PREGANGLIONIC HORNER'S SYNDROME

- Lung or breast malignancies that has spread to thoracic outlet
- Facial anhidrosis
- Brachial plexus palsies may be present

■ POSTGANGLIONIC HORNER'S SYNDROME

- Ipsilateral vascular headache
- h/o head injury, intraaural or retroparotid trauma
- Tumor of middle cranial fossa or cavernous sinus

PHARMACOLOGICAL TESTS

1. COCAINE 4% :

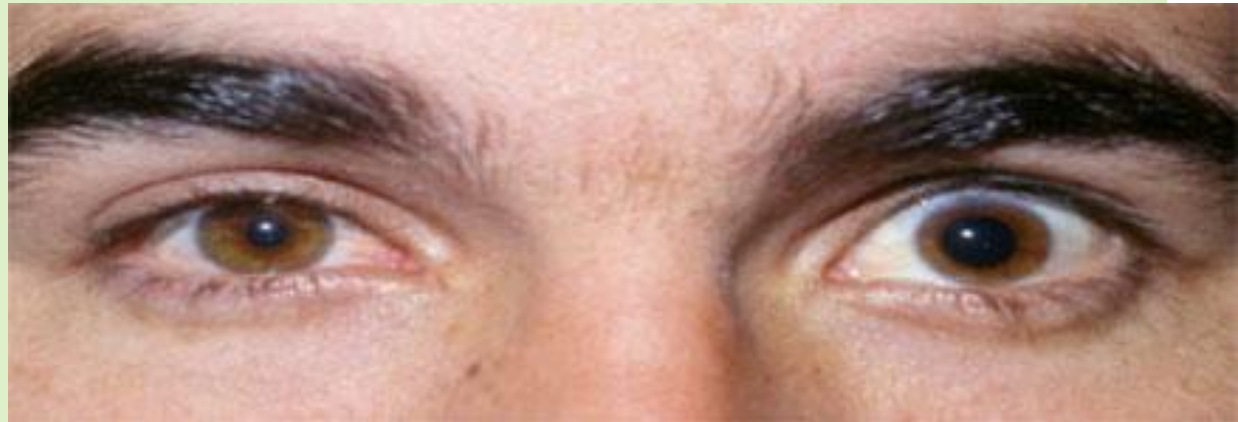- Rationale- cocaine blocks NE uptake at postganglionic sympathetic nerve endings
- Result – Normal pupil will dilate but Horner pupil will not because in Horner's syndrome there is no NE being secreted. Therefore, a post cocaine anisocoria of $>0.8\text{mm}$ in a dimly lit room is significant.

➤ Cocaine

➤ Continues

➤ Constriction

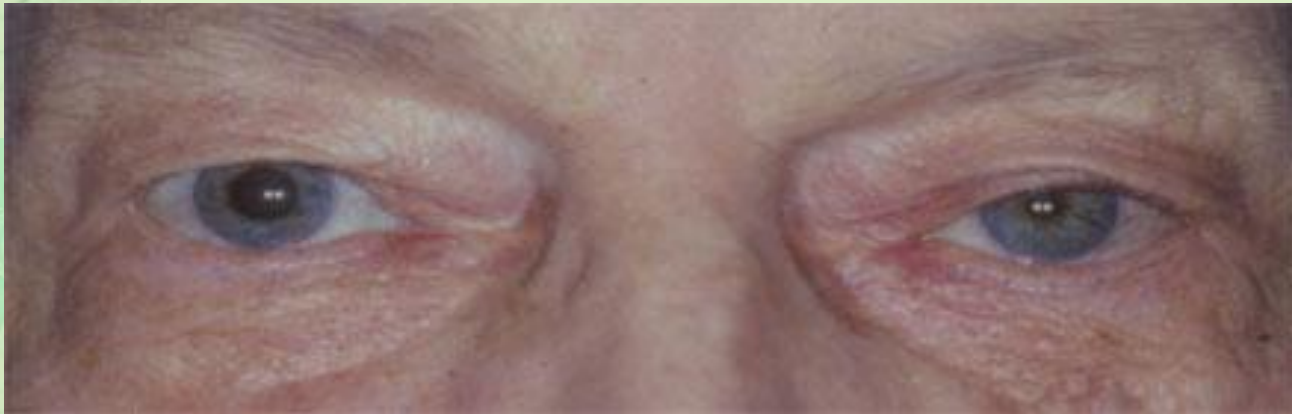in Horner's syndrome



Right Horner's syndrome: the right pupil failed to dilate while the left eye dilated to 7 mm with 10 % cocaine.

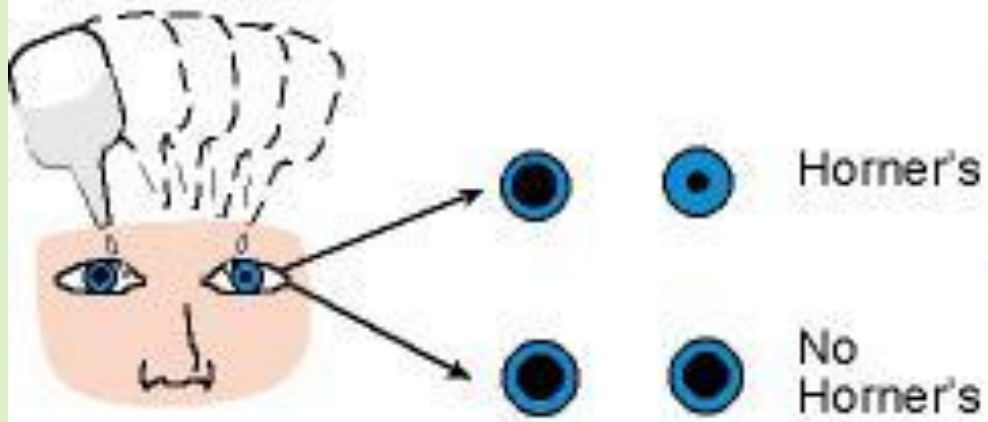
2. HYDROXYAMPHETAMINE 1% :

- Rationale : hydroxyamphetamine potentiates the release of NE from post ganglionic nerve endings
- Result : in the preganglionic lesion, both pupils will dilate. In postganglionic lesion, Horner's pupil continues to constrict.



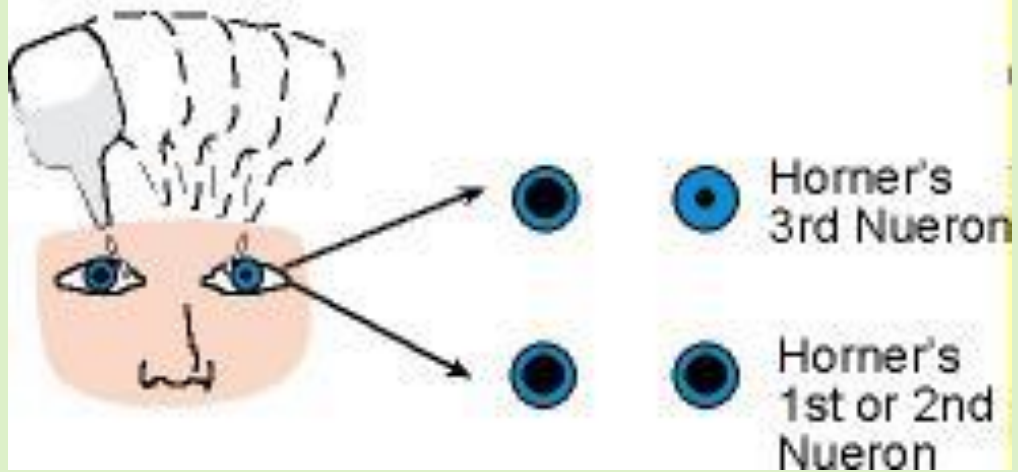
Left Horner's syndrome with a postganglionic (third-neuron order) lesion: the left pupil failed to dilate while the right eye dilated with 1% hydroxyamphetamine.

4% Cocaine



24 Hours Later

Hydroxyamphetamine paradine



3. ADRENALINE 0.1% :

- Rationale : the principle is based on denervation hypersensitivity to adrenergic neurotransmitters
- Result : in preganglionic lesion, neither pupil will dilate because adrenaline is rapidly destroyed by MAO. In postganglionic lesion, Horner's syndrome will dilate and ptosis will be relieved because adrenaline is not broken down due to absence of MAO.

4. APRACLONIDINE 0.5% OR 1% :

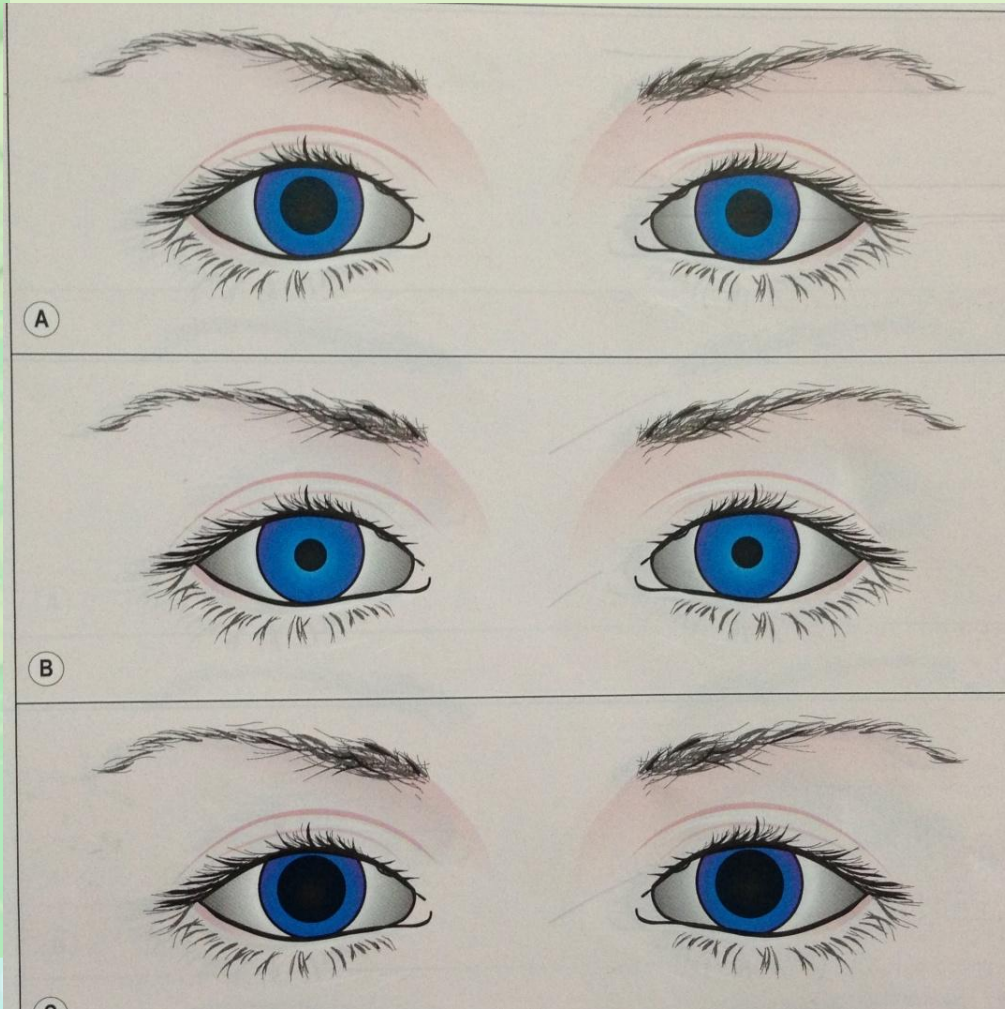
- Rationale – α_1 receptors are upregulated in the denervated dilator pupillae
- Result - Horner pupil will dilate but the normal pupil is unaffected.



OTHER ABNORMAL REACTIONS

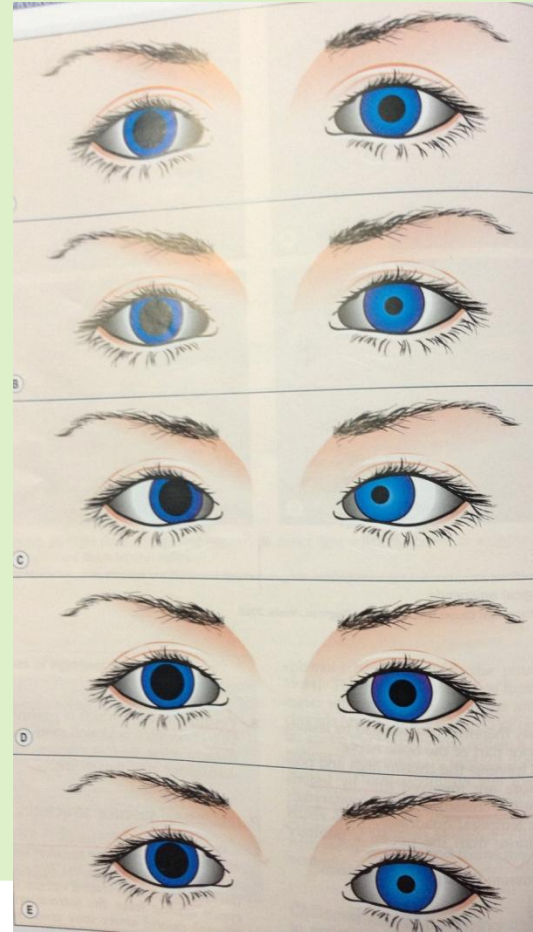
Right physiological anisocoria :

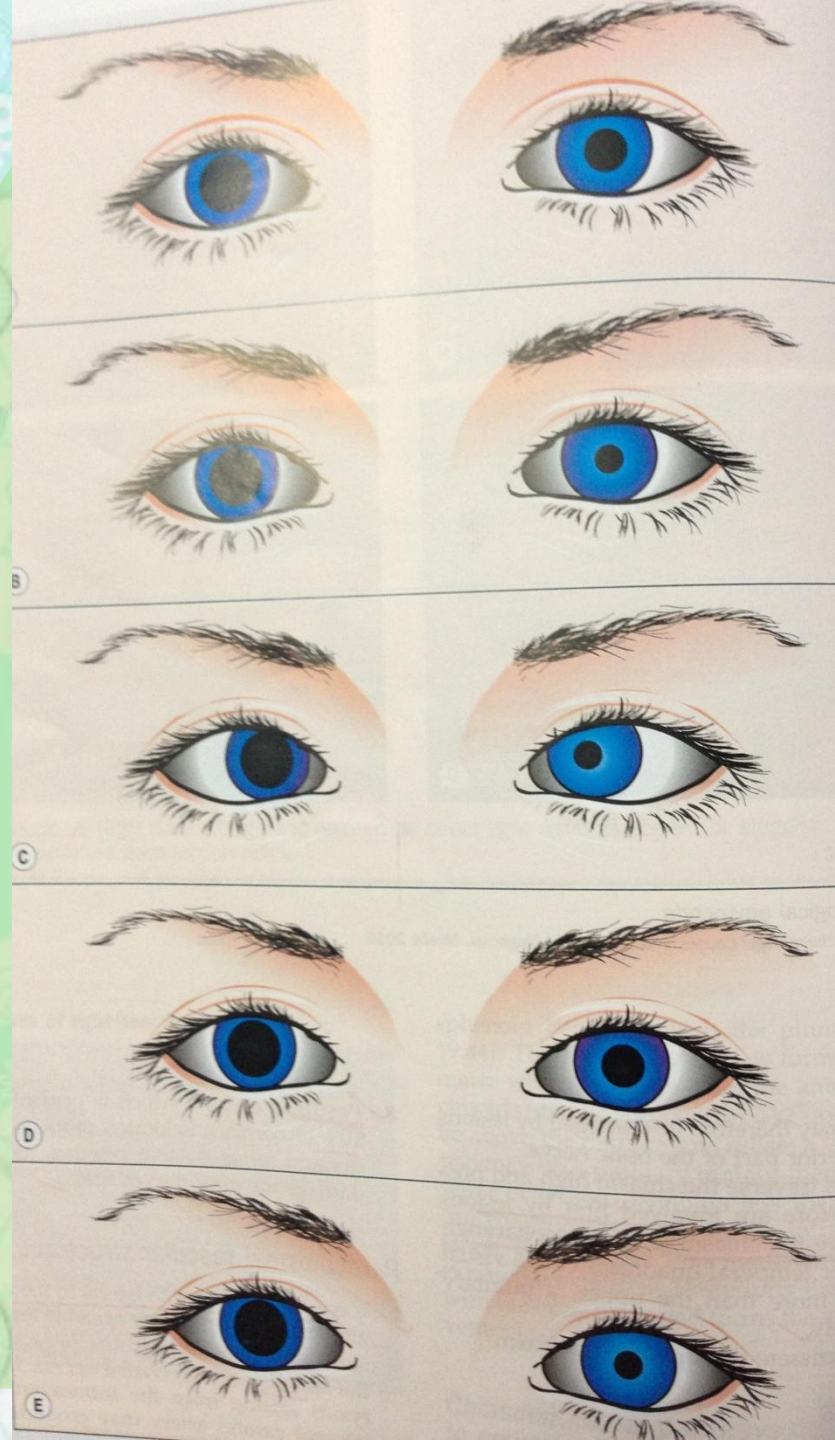
- In dim light, right pupil is larger than the left.
- In bright light, both pupils constrict normally.
- After instillation of 4%cocaine to both eyes, both pupils dilate.



Right pharmacological mydriasis :

- Right mydriasis in dim illumination.
- In bright light the right pupil does not constrict.
- On accommodation, the right pupil does not constrict.
- After instillation of pilocarpine 0.1% into BE neither pupil constricts.
- After instillation of pilocarpine 1% into BE, Rt pupil does not constrict, but the left does.





In dim light

In bright light

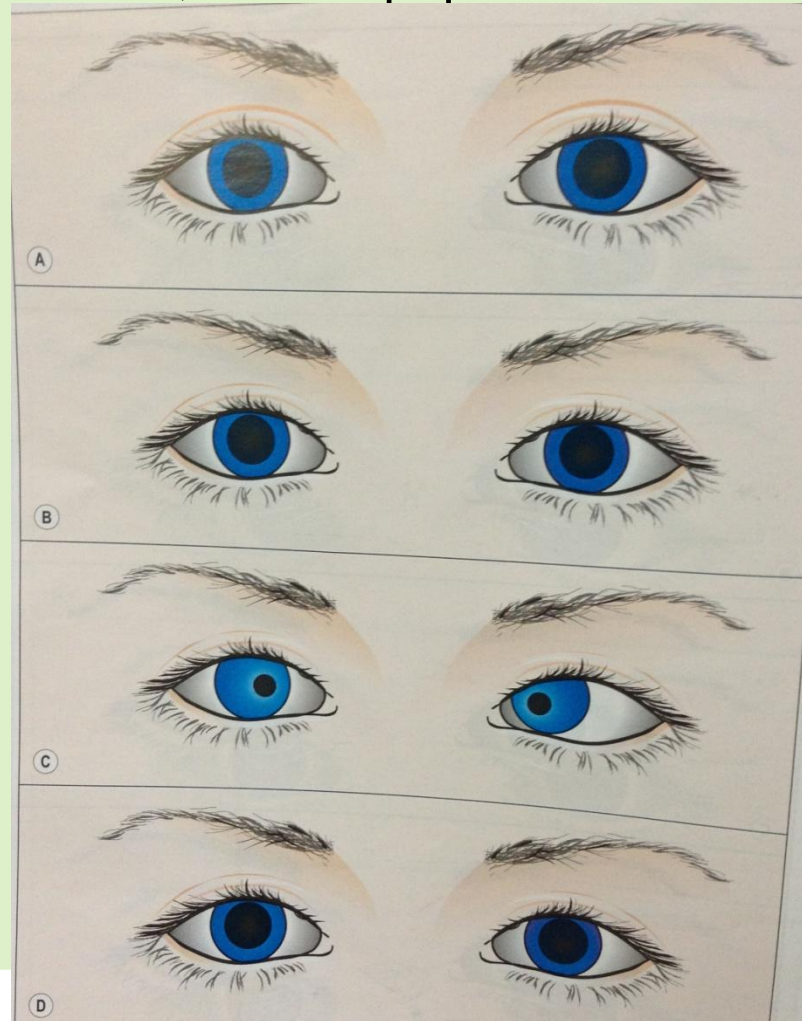
On accommodation

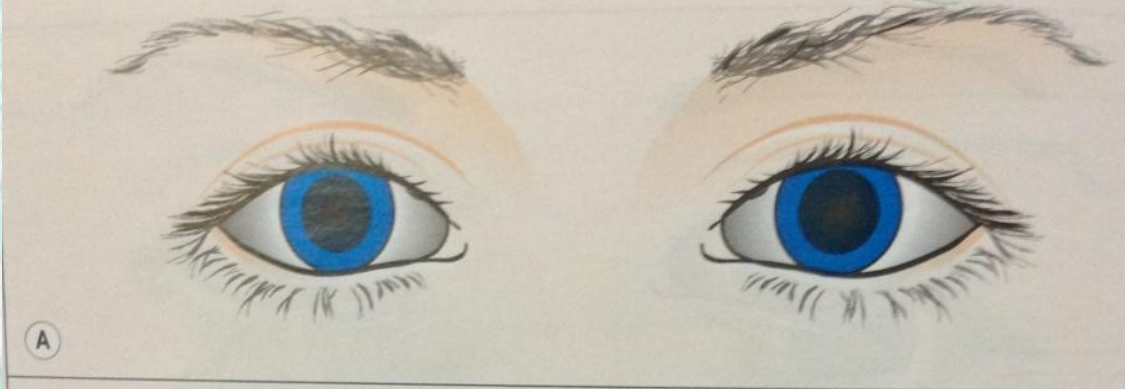
Pilocarpine 0.1%

Pilocarpine 1%


Tectal (dorsal midbrain) pupils :

- In dim light there is B/L mydriasis which may be asymmetrical.
- In bright light, neither pupil constricts.
- On accommodation, both pupils constrict normally.
- After instillation of pilocarpine 0.1% to BE, neither pupil constrict.

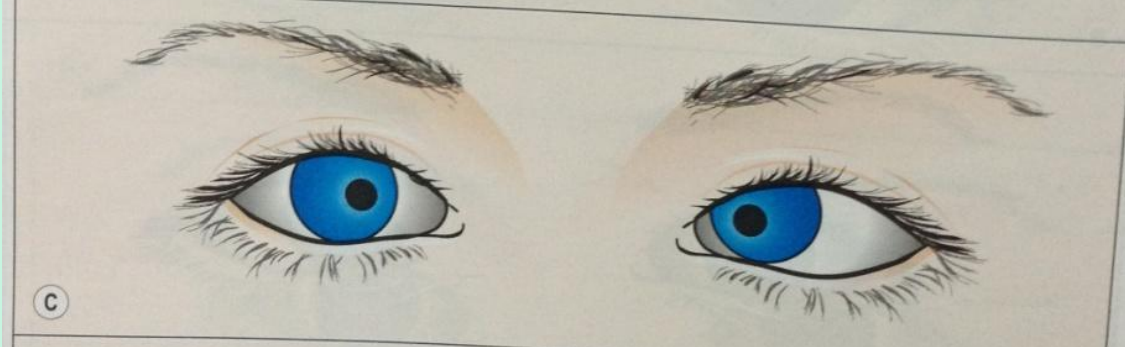




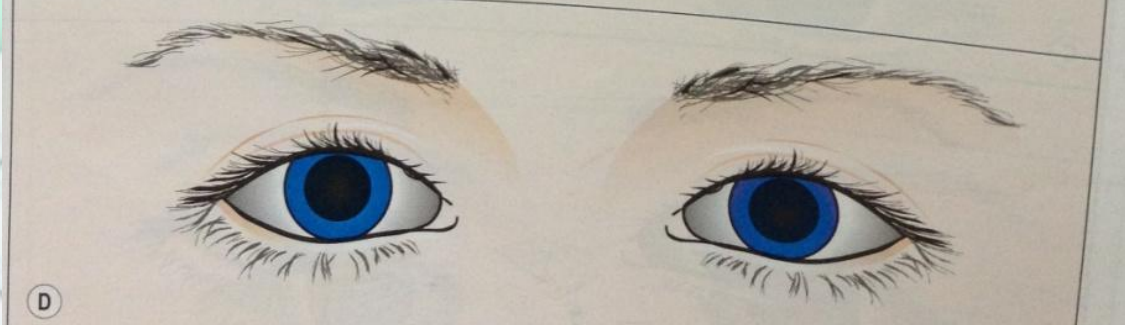
In dim light



In bright light



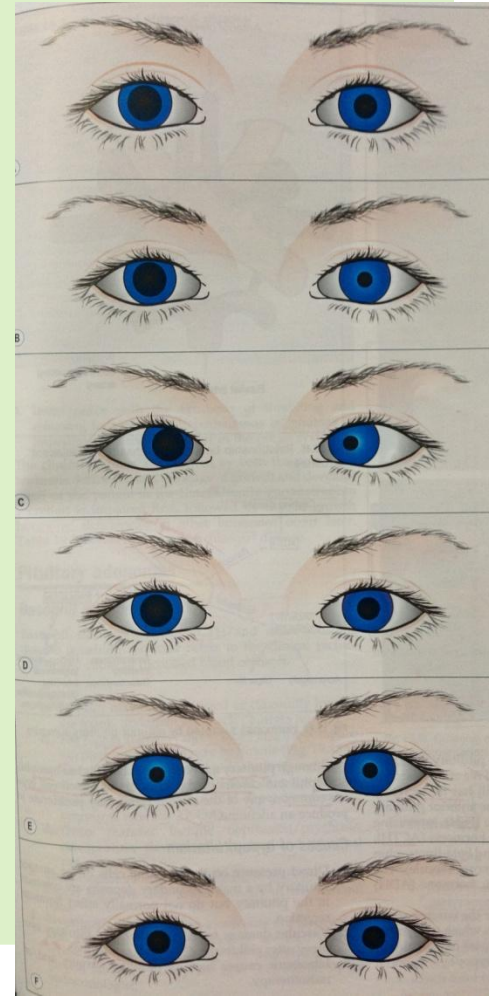
On accommodation



Pilocarpine 0.1%

Right episodic mydriasis :

- In dim light the right pupil is larger than the left.
- In bright light the right pupil does not constrict.
- On accommodation, the right pupil does not constrict.
- Instillation of 0.1% pilocarpine to BE fails to constrict either pupil.
- Instillation of 1% pilocarpine to BE induces B/L miosis.
- After 24 hrs, both pupils are equal.



In dim light

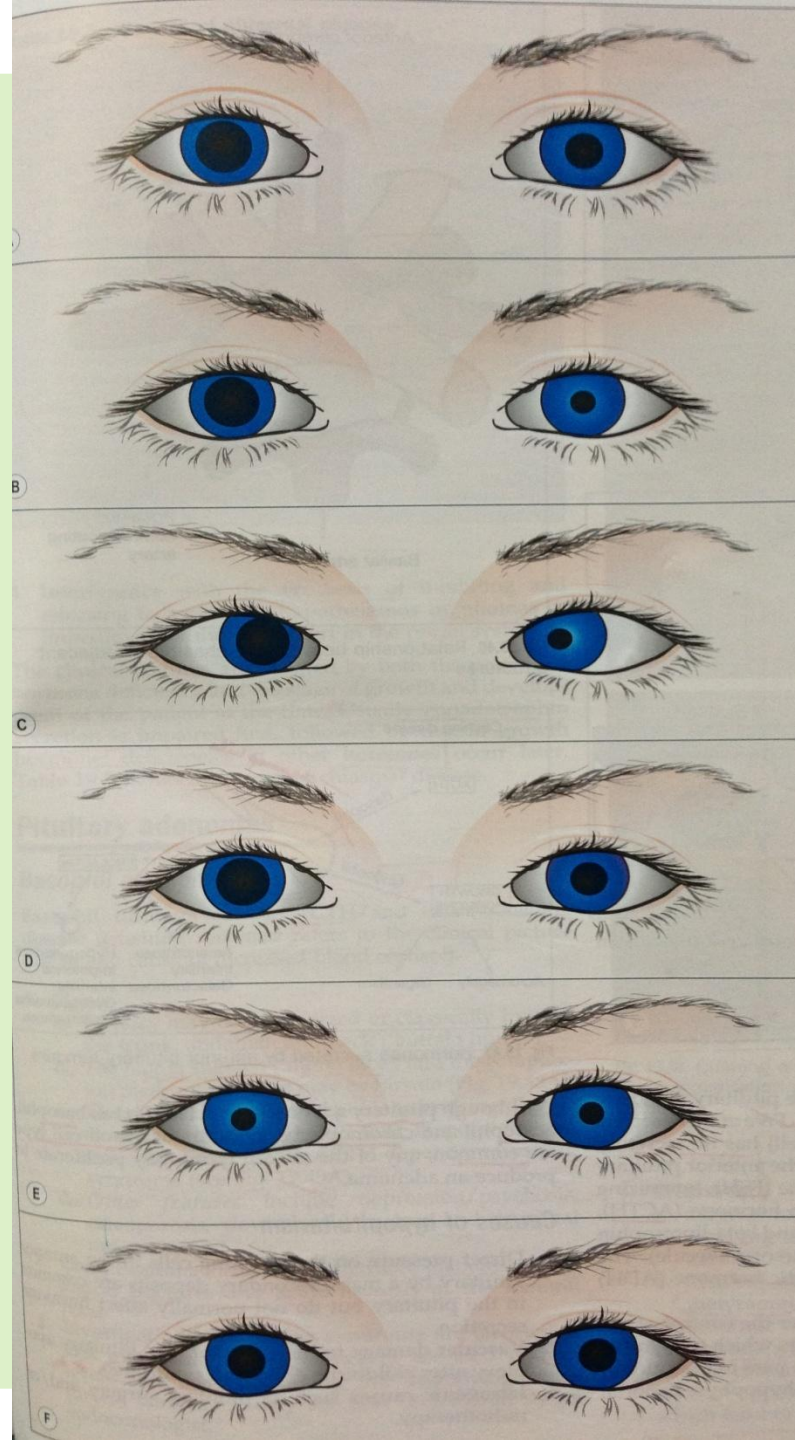
In bright light


On accommodation

Pilocarpine 0.1%

Pilocarpine 1%

After 24 hrs





Thank you ..