

VITREOUS

Sourav

HOD

General features

- Vitreous humour is an inert, transparent, colorless, jelly-like, hydrophilic gel that serves the optical function and act as a supporting Struthers of the eye ball.
- It weighs 4 g and occupied a volume of almost 4 cc which approximately $\frac{2}{3}$ the volume of the entire globe.
- It is an extracellular material composed of approximately 99% of water.

Continue...

- It is bounded on the front by the posterior surface of the lens and the retrozonular portion of the posterior chamber.
- Peripherally and posteriorly, it is bounded by the pars plana of the ciliary body, the retina, and the optic disc.
- All surfaces that interface with the vitreous are basement membranes.

Stretchers

- It divided into 3 parts
 1. Hyaloid layer or membrane
 2. Cortical membrane
 3. Medullary vitreous

Hyaloid layer or membrane

- It is not true membrane but the outermost surface layer or condensation of vitreous body
- It has a Structures of connective tissue and shows striations due to its fibrils which run parallel with the surface.

(A)Anterior hyaloid membrane

- The hyaloideocapsular ligament (of Weiger), or retrolental ligament, forms an annular attachment 1 to 2 mm wide and 8 to 9 mm in diameter between the posterior surface of the lens and the anterior face of the vitreous.
- This is a firm attachment site in young persons, but the strength of the bond diminishes after age 35.
- Within the ring formed by this ligament is a potential space, the retrolental space (of Berger), which is present because the lens and vitreous are juxtaposed but not joined.

Continue...

- The peripapillary adhesion around the edge of the optic disc also diminishes with age. The annular ring of attachment at the macula is 3 to 4 mm in diameter.
- The attachment of the vitreous to retinal blood vessels consists of fine strands that extend through the internal limiting membrane to branch and surround the larger retinal vessels

Continue...

- Hyalocillary zonules: these fibers extend from the anterior hyaloid membrane to the valley between the ciliary processes.
- Retroretinal ligament (ligamentum hyaloidocapsulare) attaches the anterior hyaloid membrane to the lens
- Coronary ligament: its fibers extend from the anterior hyaloid membrane to the inner face of the posterior third of the ciliary process circumferentially.

Continue...

- Median ligament: it is also runs circumferentially from the anterior hyaloid membrane at the level of the mid-zone of pars plana.

(B) Posterior hyaloid membrane

- It extends back from the vitreous base up to the optic disc.
- It lies in contact with the internal limiting membrane of the retina.

VITREOUS ZONES

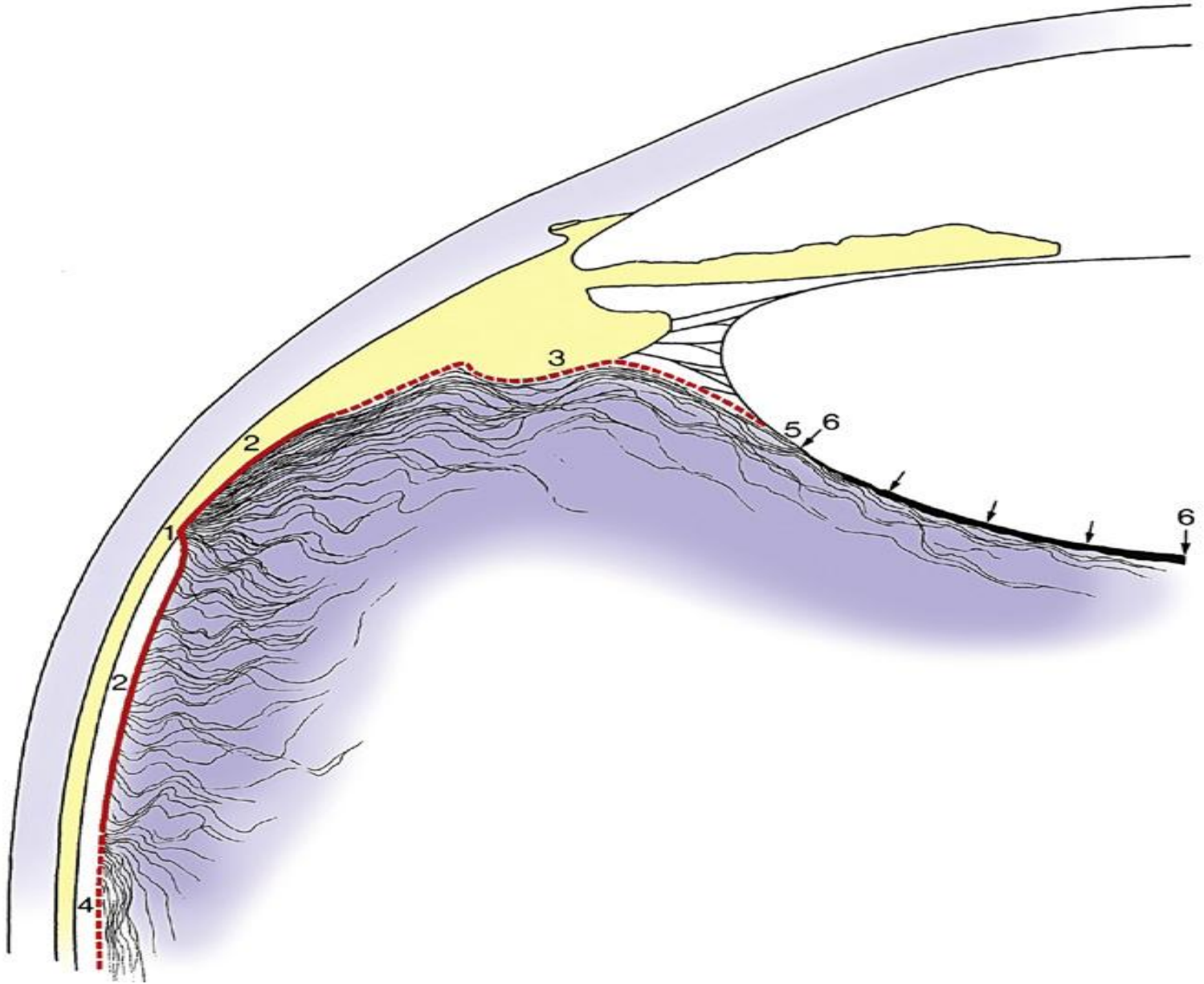
- The vitreous can be divided into zones that differ in relative density.
- The outermost zone is the vitreous cortex, the center zone is occupied by Cloquet's canal, and the intermediate zone is inner to the cortex and surrounds the center canal.

(1) Vitreous Cortex

- The vitreous cortex, also called the hyaloid surface, is the outer zone.
- It is 100 μm wide, and it is composed of tightly packed collagen fibrils, some of which run parallel and some perpendicular to the retinal surface.
- **The anterior cortex** lies anterior to the base and is adjacent to the ciliary body, posterior chamber, and lens.

Continue...

- **The posterior cortex** extends posterior to the base and is in contact with the retina.
- It contains transvitreal channels that appear as holes—the *prepapillary hole*, the *premacular hole*, and *prevascular fissures*.
- The **prepapillary hole** can sometimes be seen clinically when the posterior vitreous detaches from the retina.



Continue...

- The **premacular hole**, a weak area, may be a region of decreased density rather than an actual hole.
- The **prevascular fissures** provide the avenue by which fine fibers enter the retina and encircle retinal vessels

(2) Intermediate Zone

- The intermediate zone contains fine fibers that are continuous and unbranched and that run anteroposteriorly.
- These fibers arise at the region of the vitreous base and insert into the posterior cortex.
- The peripheral fibers parallel the cortex, whereas the more central fibers parallel Cloquet's canal.
- Membranelike condensations, called vitreous tracts, may be differentiated as areas that have differing fiber densities

(3) Cloquet's Canal

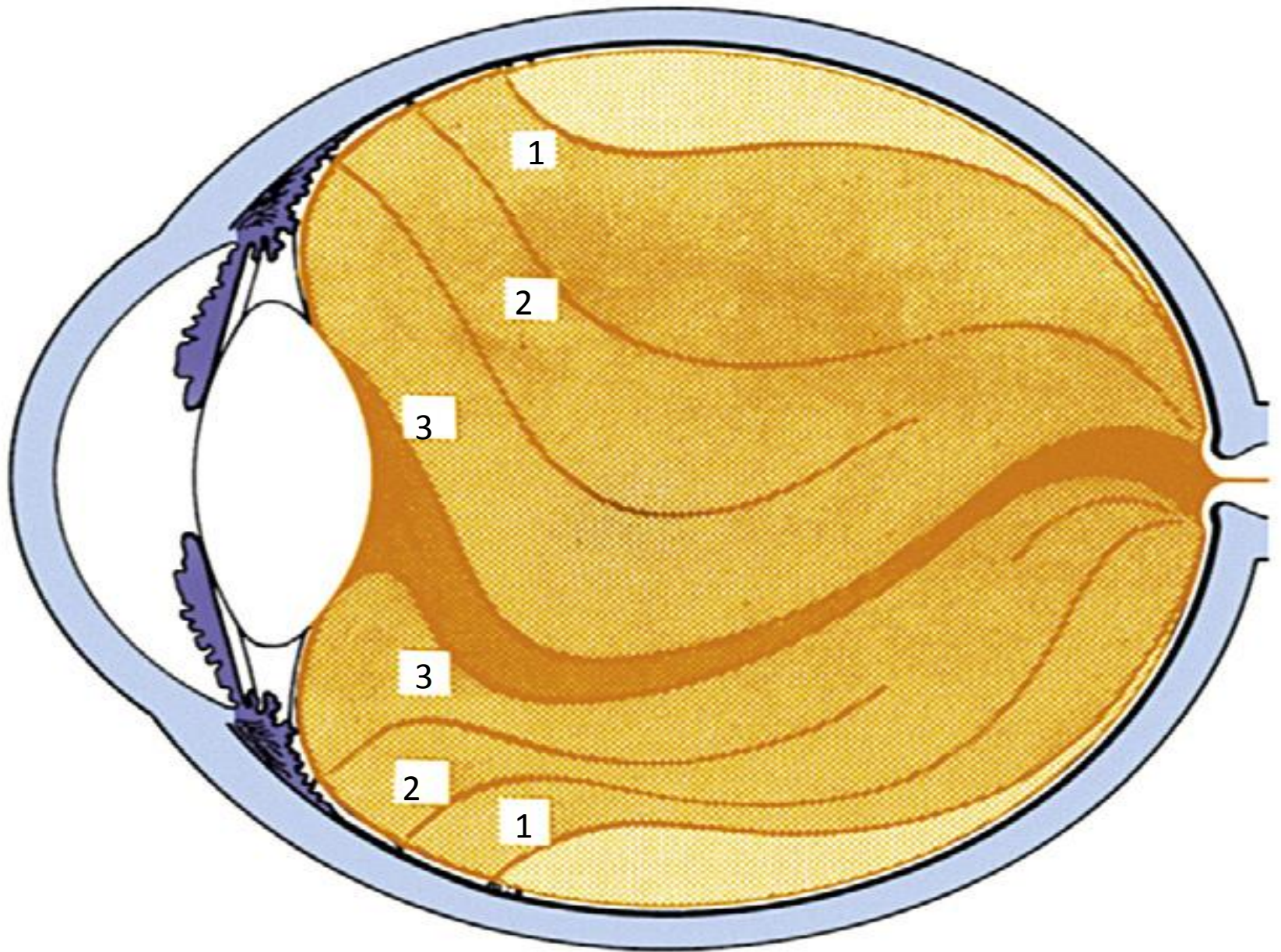
- **Cloquet's canal**, also called the **hyaloid channel** or the **retrolental tract**, is located in the center of the vitreous body.
- It has an S shape, rotated 90 degrees with the center dip downward, and is the former site of the hyaloid artery system, which was formed during embryologic development.

Continue...

- Cloquet's canal arises at the retrolental space. Its anterior face is approximately 4 to 5 mm in diameter.
- It terminates at the area of Martegiani, a funnel-shaped space at the optic nerve head that extends forward into the vitreous to become continuous with the canal.

Vitreous tracts

- Fine sheet-like condensations of vitreous tissue which radiate into the vitreous space from the ciliary body and anterior retina.
- These track gives rise to the concentric 'onion-skin' arrangement of the adult vitreous.
- Vitreous tracts seen in the adult vitreous tracts seen in the adult vitreous space are follows.
- 1)Retrolental tract 2)coronary tract 3)median tract 4) preretinal tract



1) Retrolental tract

- It is the innermost vitreous tract which is attached anteriorly to the lens capsule just near to hyaloidocapsular ligament at the boundary of pateller fossa.
- It runs backwards and terminates in front of the optic disc. It forms a reflecting membrane also called membrana plicata of vogt.

2) coronary tract

- It attached anteriorly to the coronary ligament which is a circumferential band binding the inner face of the posterior third of ciliary process to the anterior hyaloid membrane.
- It runs backward in the central vitreous around the tractus retrolentalis.

3) Median tract

- It is inserted anteriorly on the median ligament which is a circumferential band binding anteriorly hyaloid membrane to the mid zone of pats plana.
- It extends backwards as faint veil, around the tractus coronaries, into the central vitreous.

4) preretinal tract

- It is the outermost vitreous tract which is attached anteriorly at the ora serrata circumferentially.
- It is comparatively more reflecting membrane and extends backwards around the tractus medianus.

VITREAL ATTACHMENTS

- It is firmly attached to the surrounding structures around the ora serrata, optic disc, back of the lens and fovea region. The strongest attachment of the vitreous is to the pars plana and retina in the region of the ora serrata.
- It is called vitreous base

VITREOUS BASE

- Origin of the vitreous refers to approximately 4 mm wide zone of the vitreous which is most firmly attached to the region of ora serrata, 1.5 to 2 mm adjoining pars plana anteriorly and about 2mm adjoining region of the peripheral retina posterior to the ora serrata nasally.

Continue...

- In the region of vitreous base, collagen fibres from the cortical vitreous get inserted into the internal limiting membrane of the retina and pars plana part of ciliary body at right angle to their surface.
- It right angle attachment of collagen fibres, which makes the vitreous base a three dimensional zone, which in the posterior part the collagen fibres are nearly parallel to the internal limiting membrane of the retina.

Continue...

- Microscopically firm attachment of the vitreous base are different anterior to the ora serrata when compared with the attachment posterior to the ora.
- Anteriorly the attachments consist of complex interdigitations of vitreal collagen fibres with the reticular fibrillar material of the basement membrane of the non-pigmented ciliary epithelium

Continue...

- Microscopically posterior ora serrata vitreous base firm attachment to the retina is characterized by a process called as ***degenerative remodelling of the retina.***
- The vitreous base attachments remain all through the life and are so strong that in traumatic detachment of the vitreous base

Continue...

- Vitreous base is detached along with the underlying ciliary epithelium and retina.