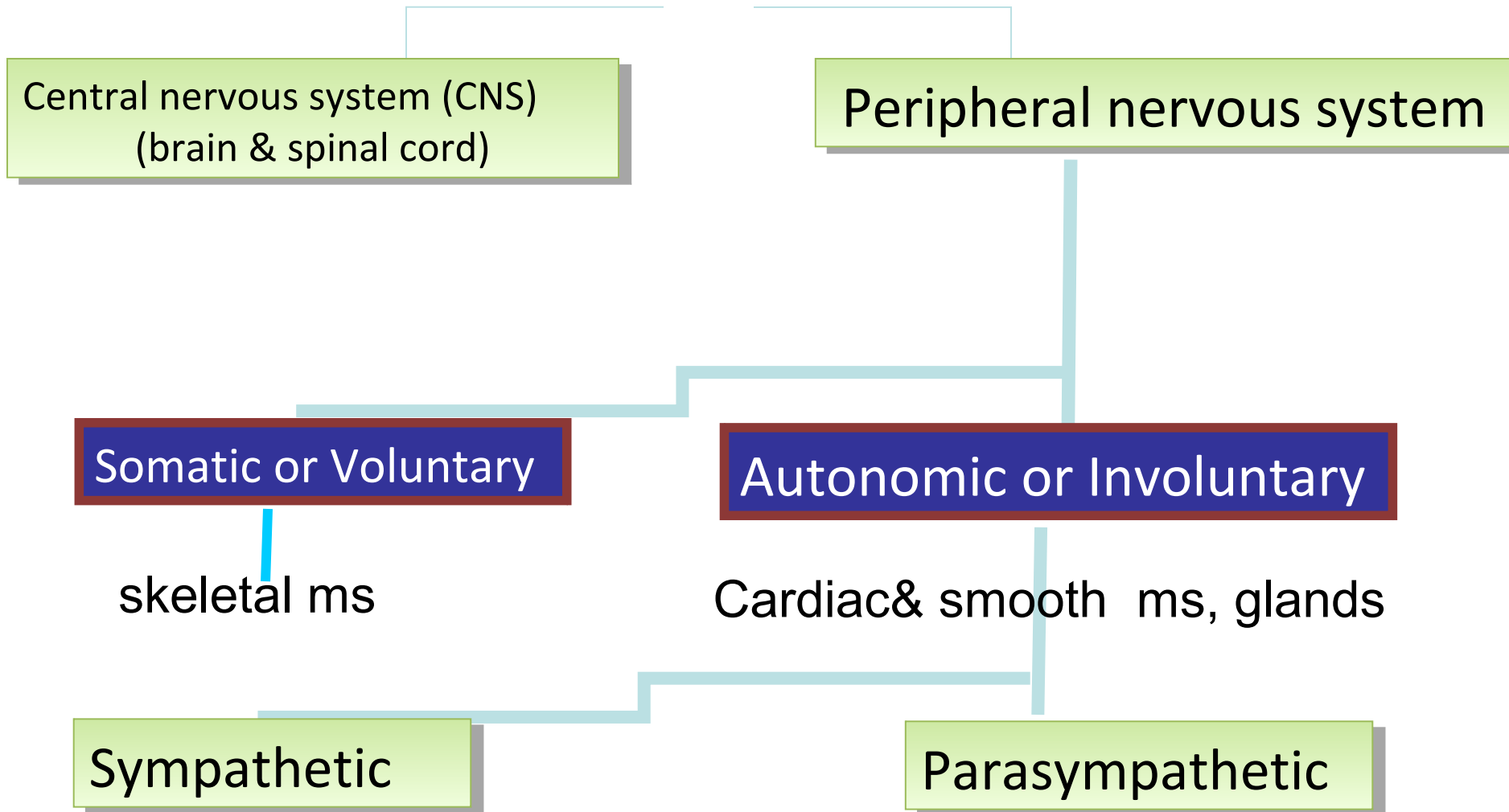


Autonomic Nervous System

Nermeen Bastawy
Physiology Department
Faculty of Medicine
Cairo University

Nervous system



CNS Consists of:

1-Brain

2 cerebral hemispheres, Brain stem & Cerebellum

2- Spinal cord : 31 segments

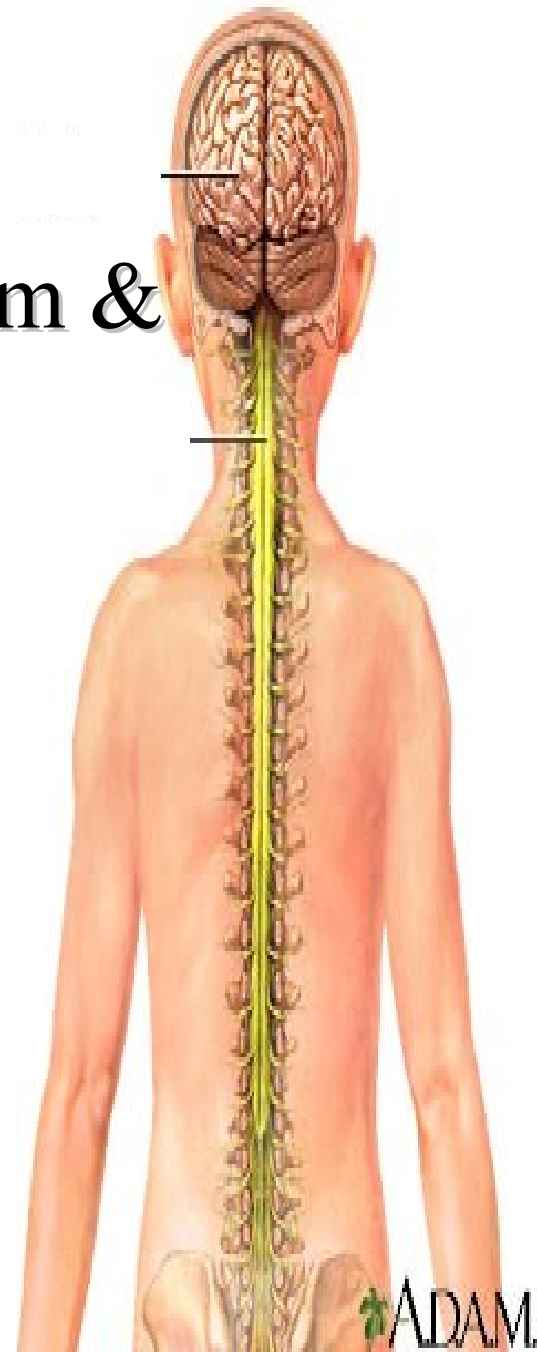
Cervical region (8 segments)

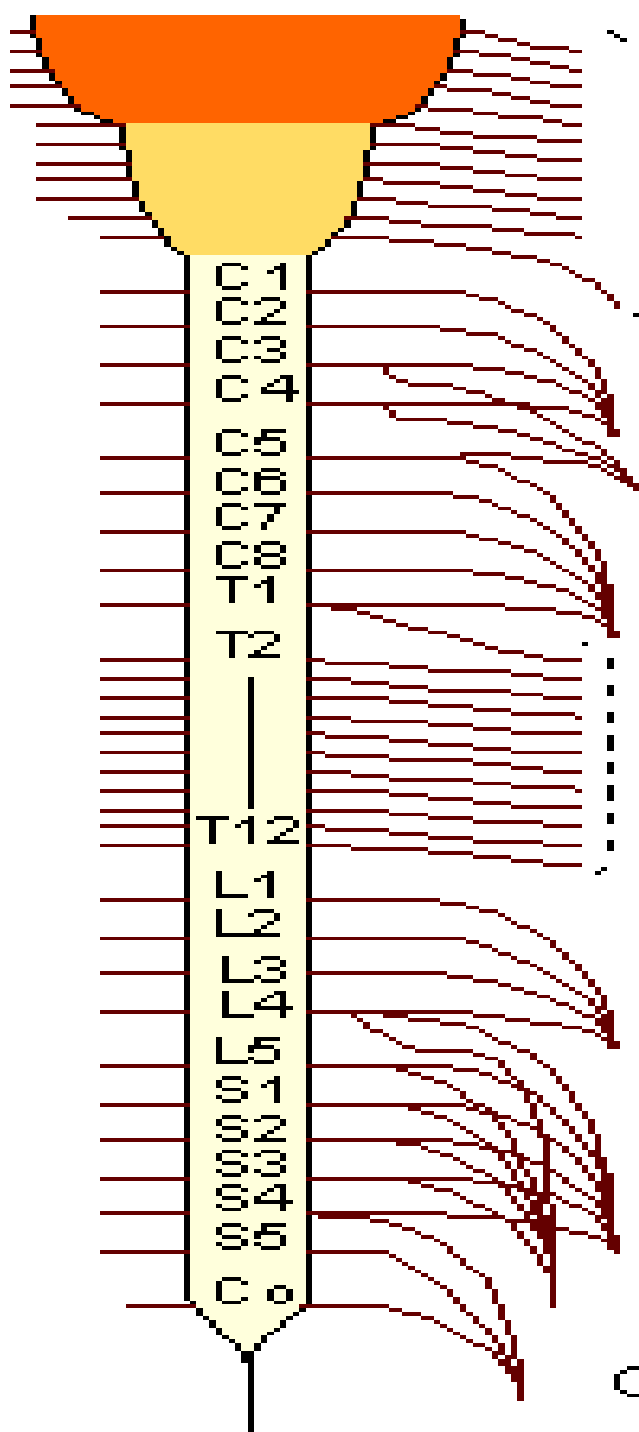
Thoracic region (12 segments)

Lumbar region (5 segments)

Sacral region (5 segments)

Coccygeal region (1 segment)






Nerve

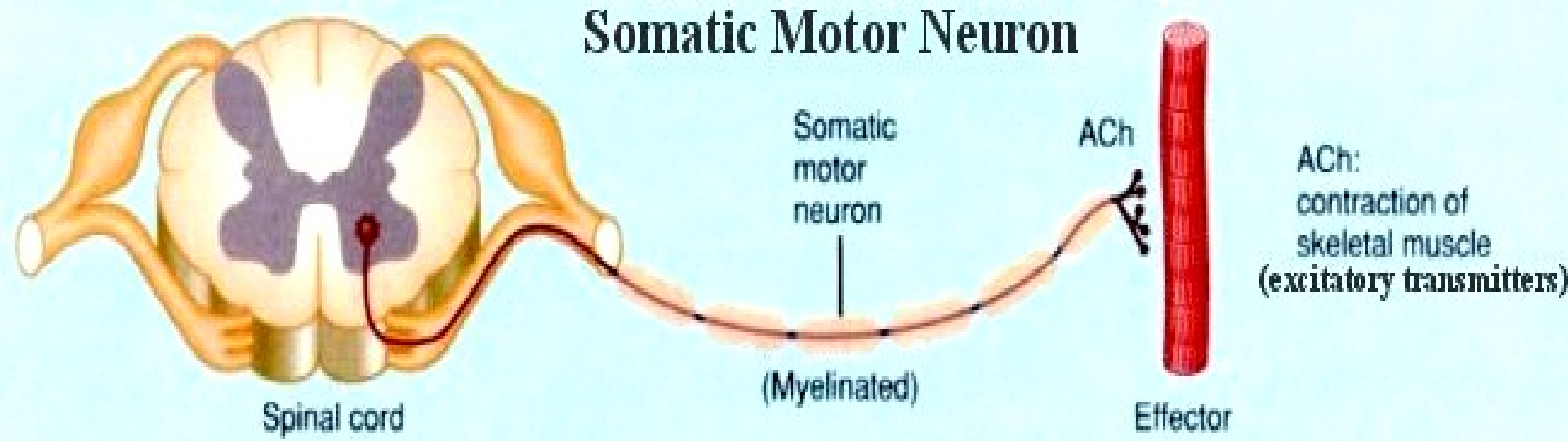
**Cranial
nerves**

**Spinal
nerves**

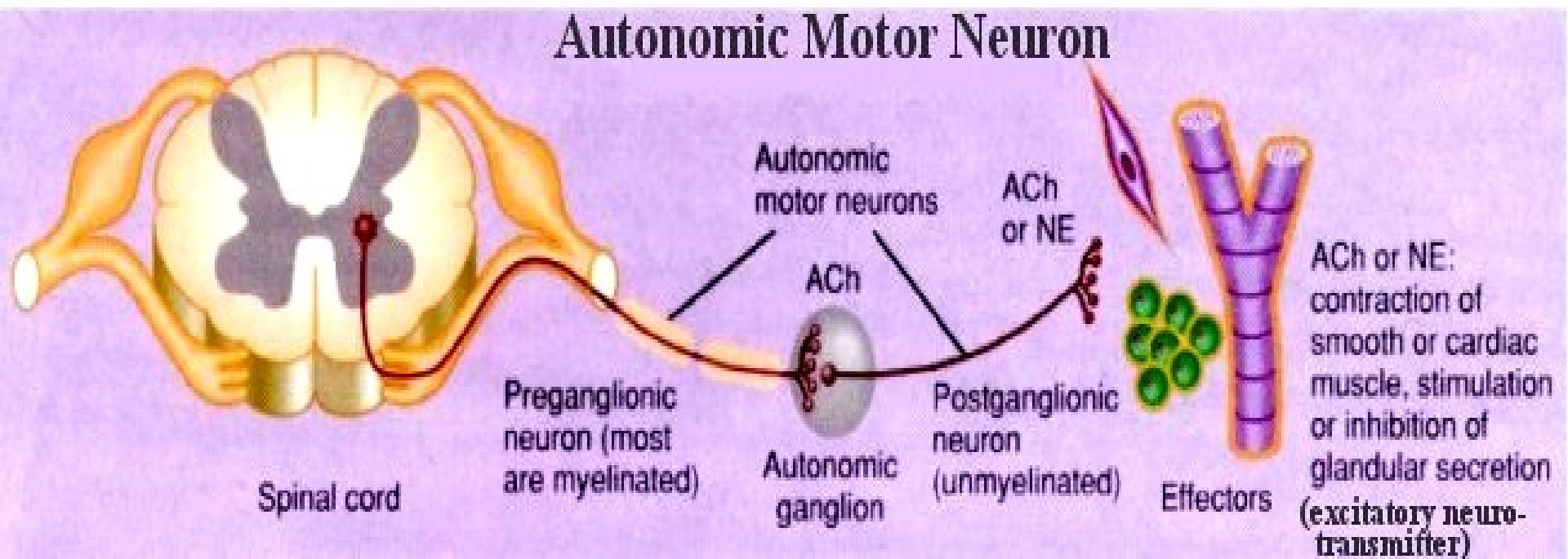
PNS



Somatic Motor Neuron



Autonomic Motor Neuron



Autonomic pathway

Brain
sp.cd

Origin

Preganglionic
neuron

Postganglionic
neurons

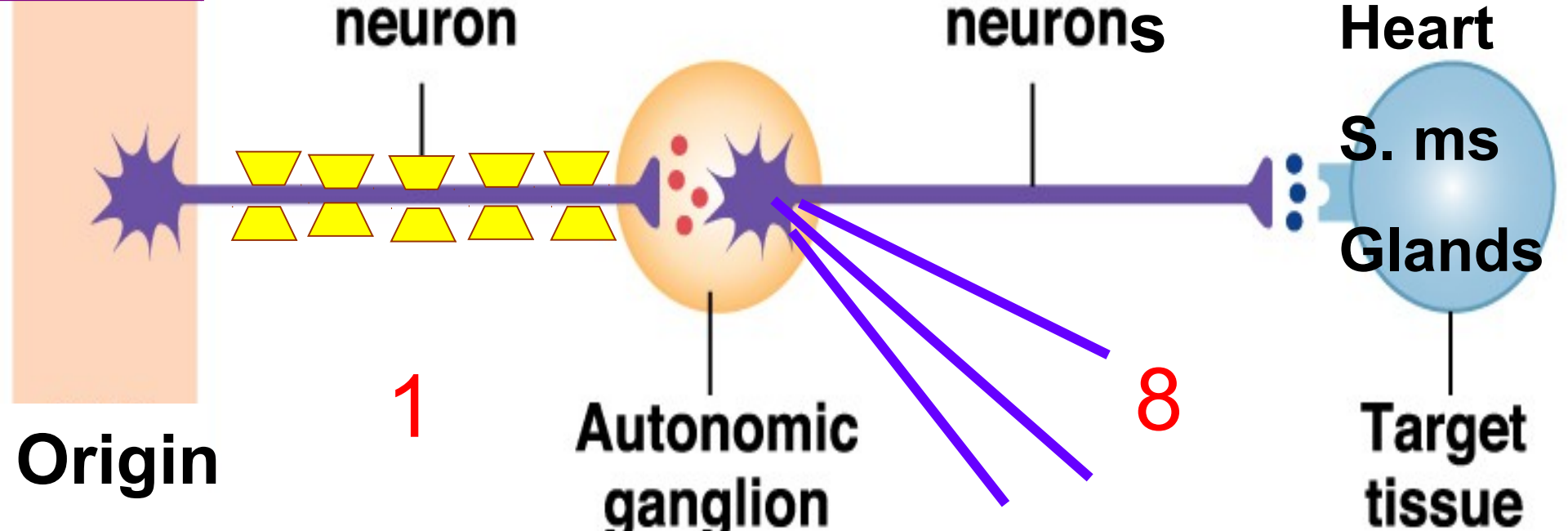
Autonomic
ganglion

Heart
S. ms
Glands

Target
tissue

1

8



Autonomic Ganglia

Definition:

Collection of neurons **outside** CNS

Functions:

Distribution centers

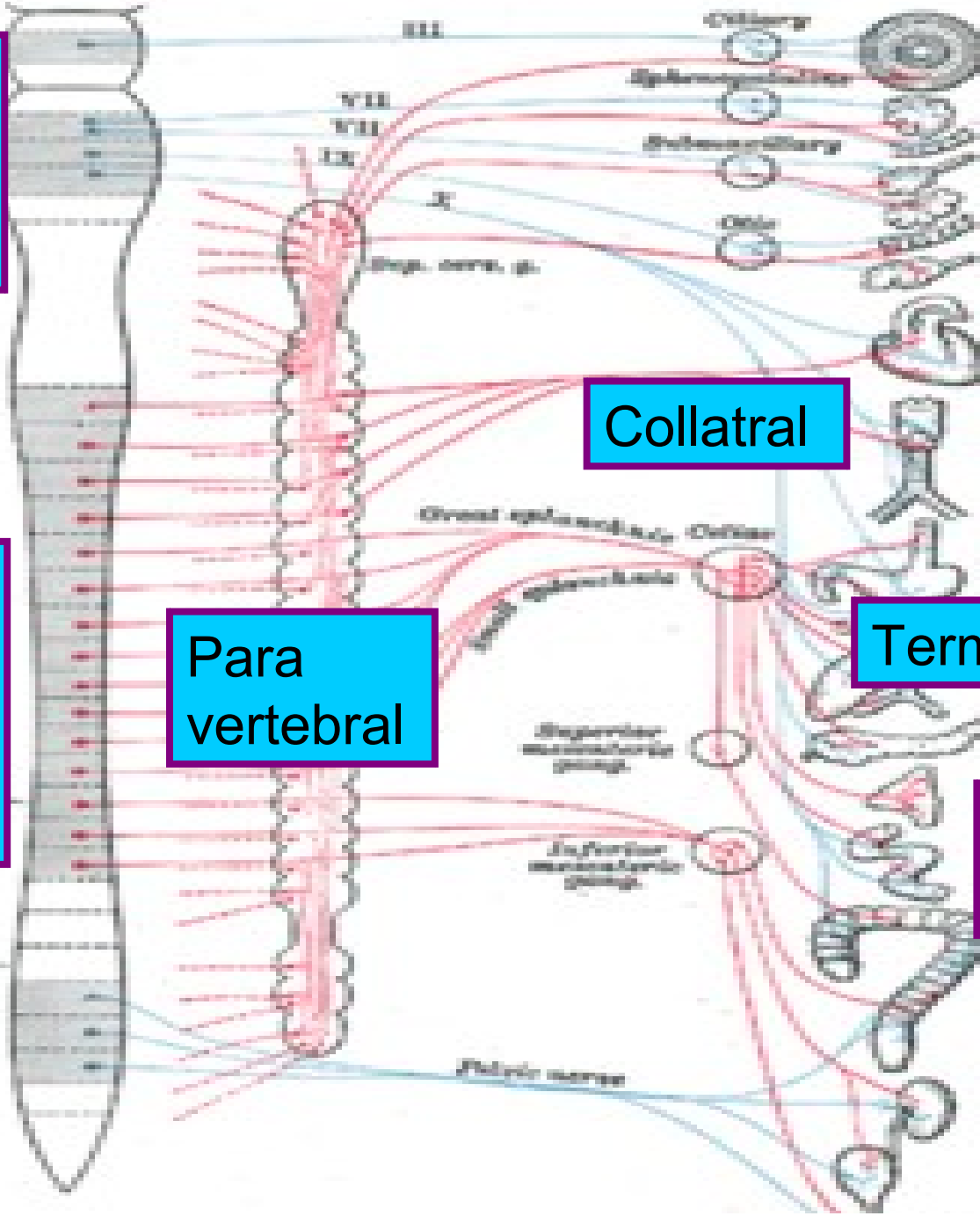
Brain stem

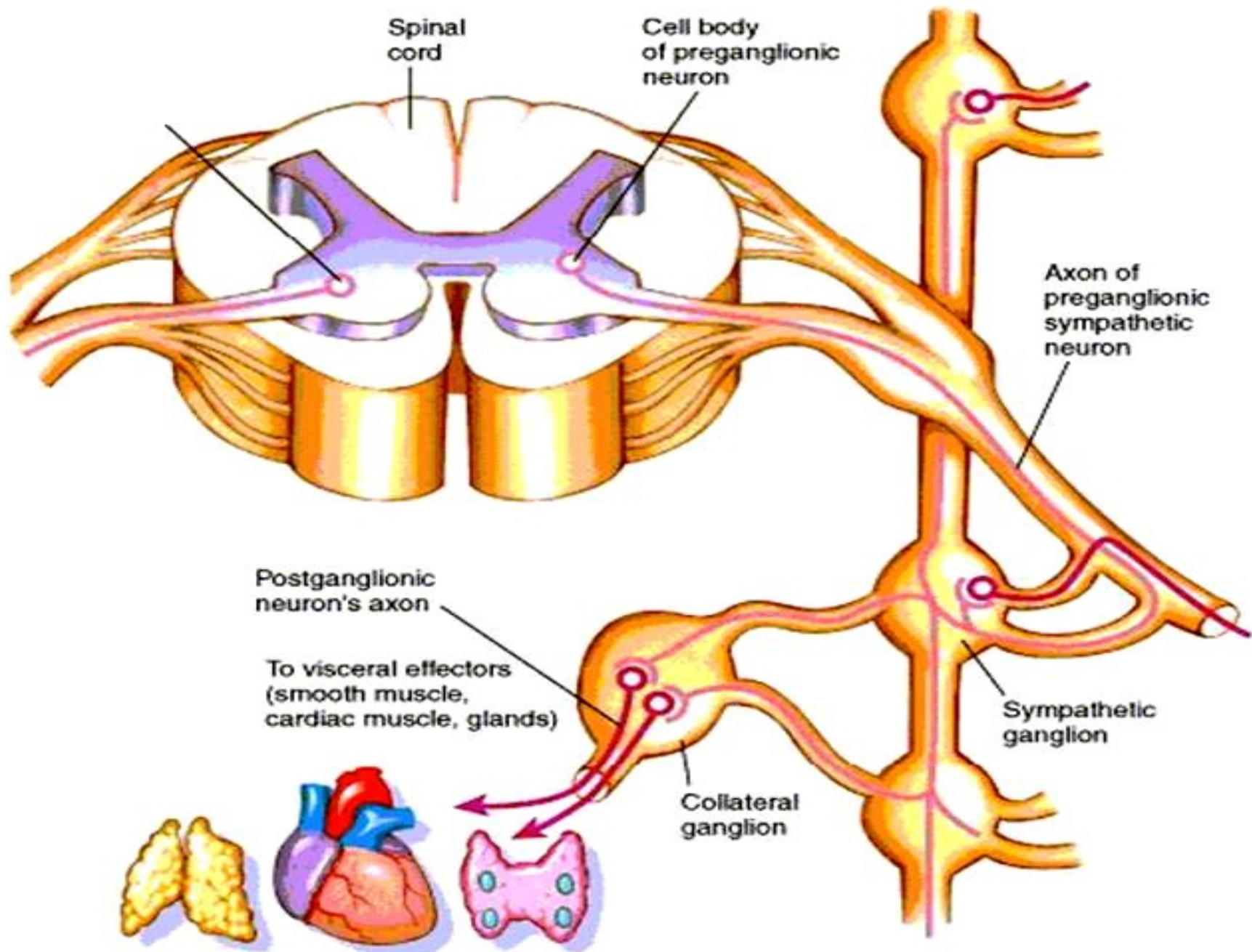
جذع المخ

Spinal cord

الحبل الشوكي


Types of ganglia





ANS

- **Sympathetic NS** → stress :
 - “Fight or flight”
 - “E” division: exercise, emergency.

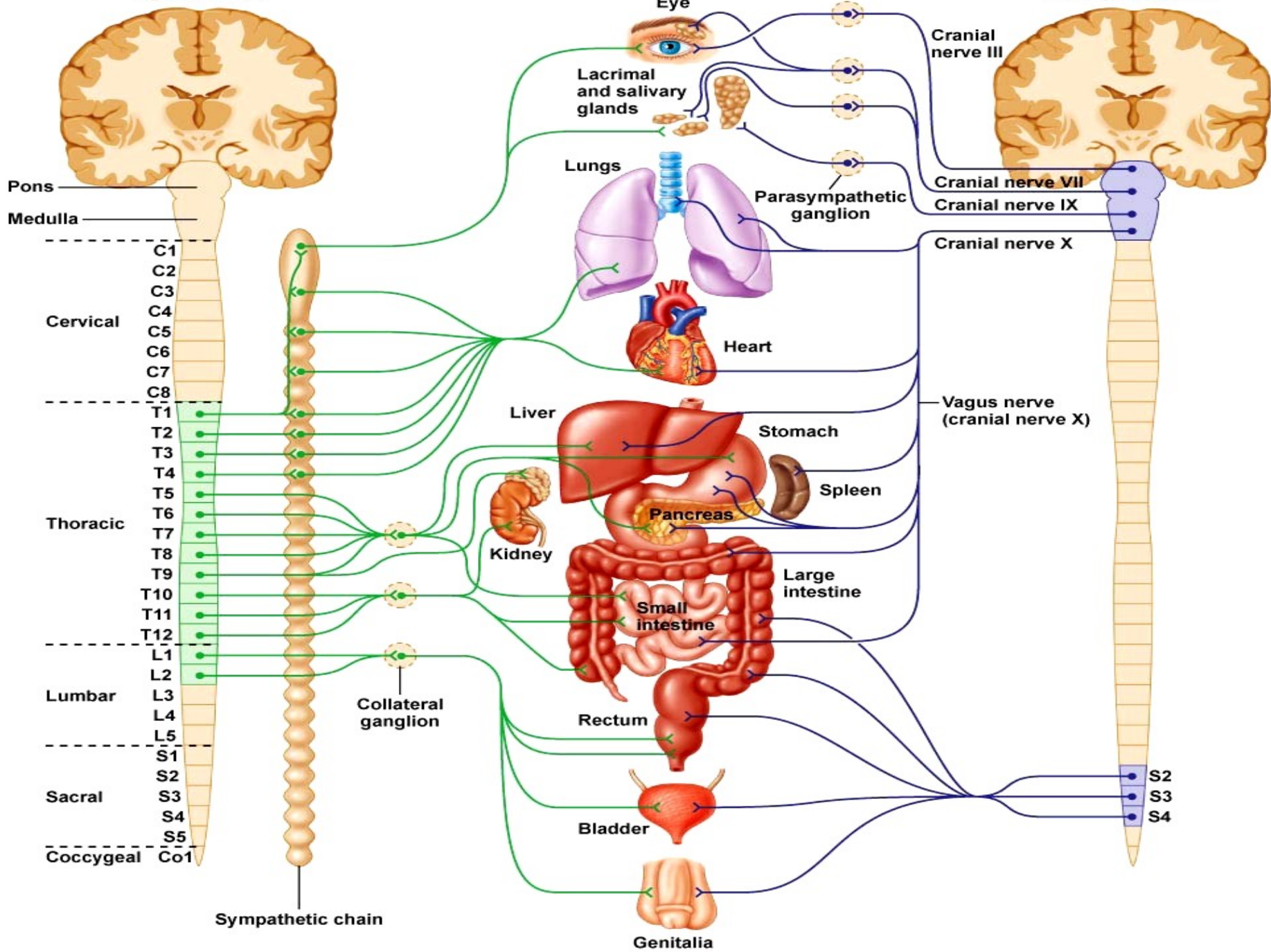


- **Parasympathetic** → Digest & rest:
 - Maintain normal functions
 - “D” division: digestion, defecation, and diuresis.

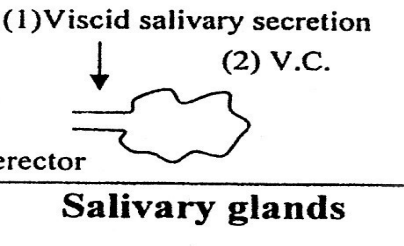
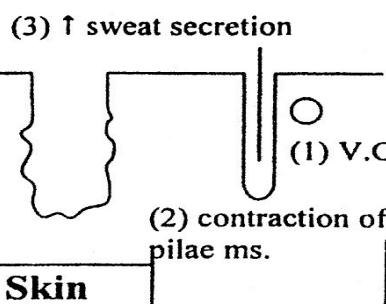
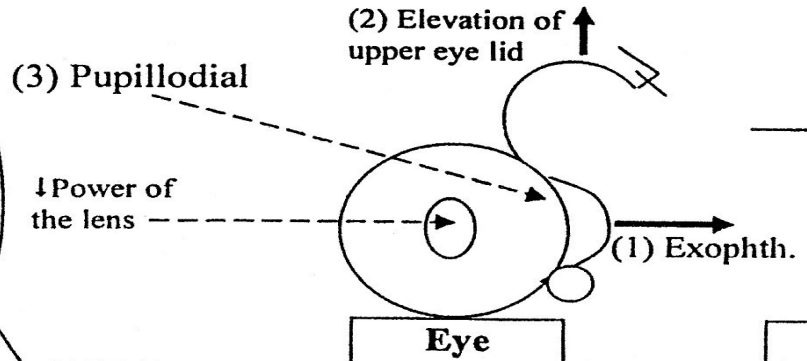


Sympathetic

Parasympathetic



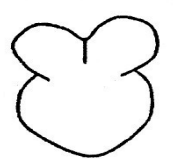
Head and neck
Upper 2 thoracic



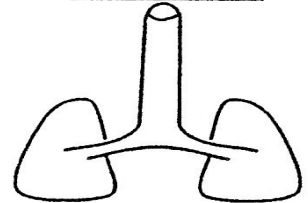
Upper 4 Thoracic

(1) Coronary V.D.
(2) stimulate the heart.
- Increase heart rate.
- Increase contraction.

Heart



Lung



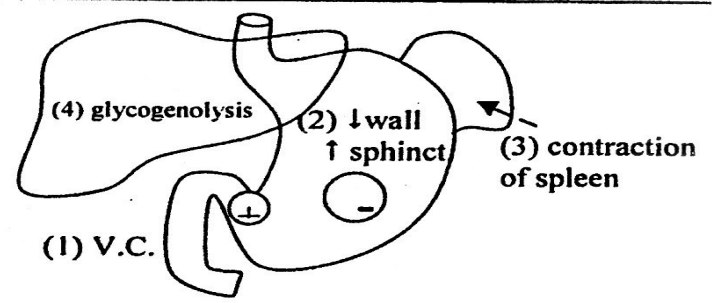
(1) V.C. of pulm. BL.V.
(2) Bronchodilatation

Lower 6 thoracic

G. splanchnic nerve



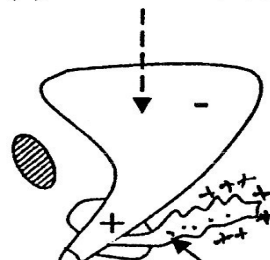
Suprarenal gland
Secrete 80% adrenal
20% noradrenal



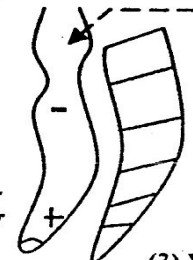
L. splanchnic nerve

Upper 3 lumber

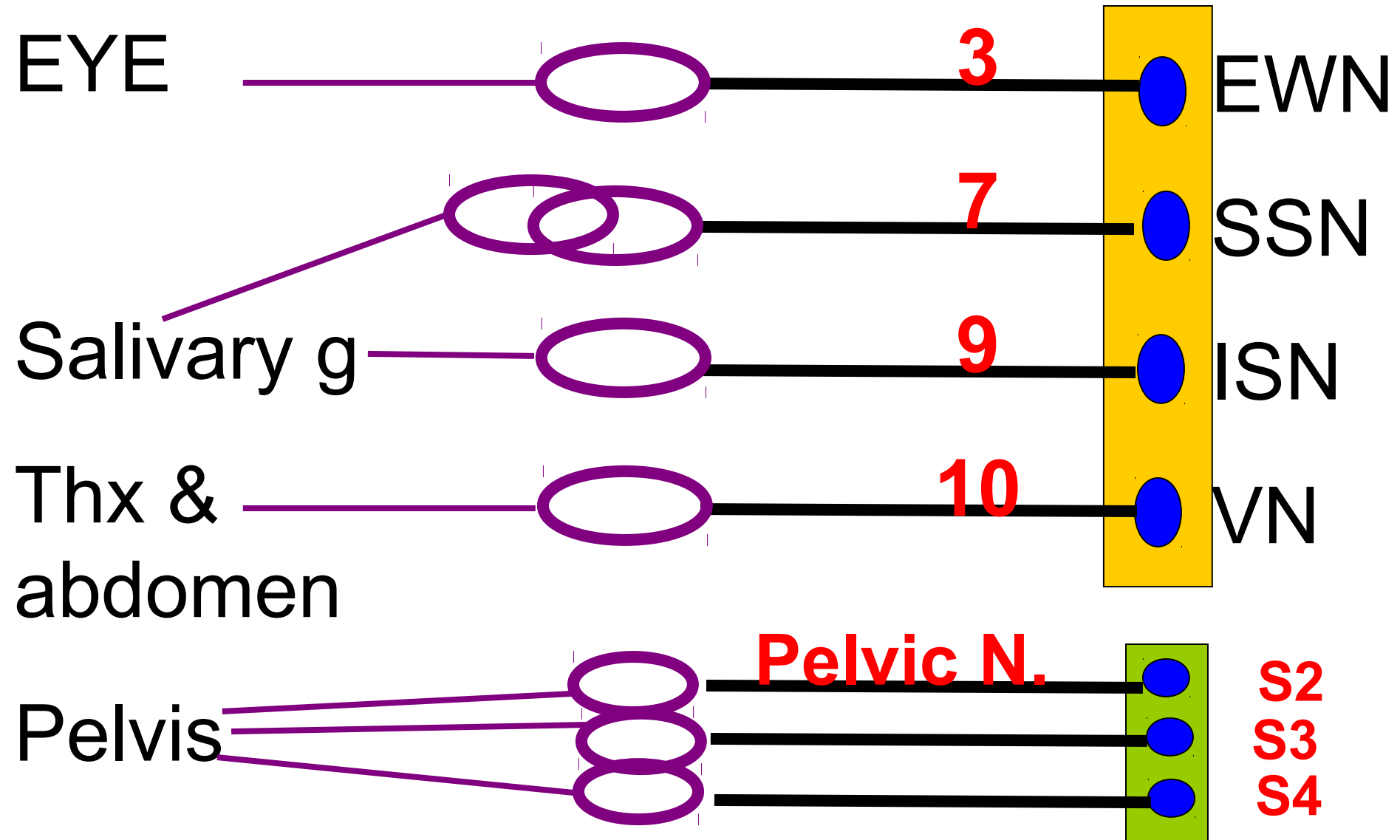
(1) retention of urine



(2) retention of faces



Parasympathetic origin



الانتصاب

Erection Physiology

Penis

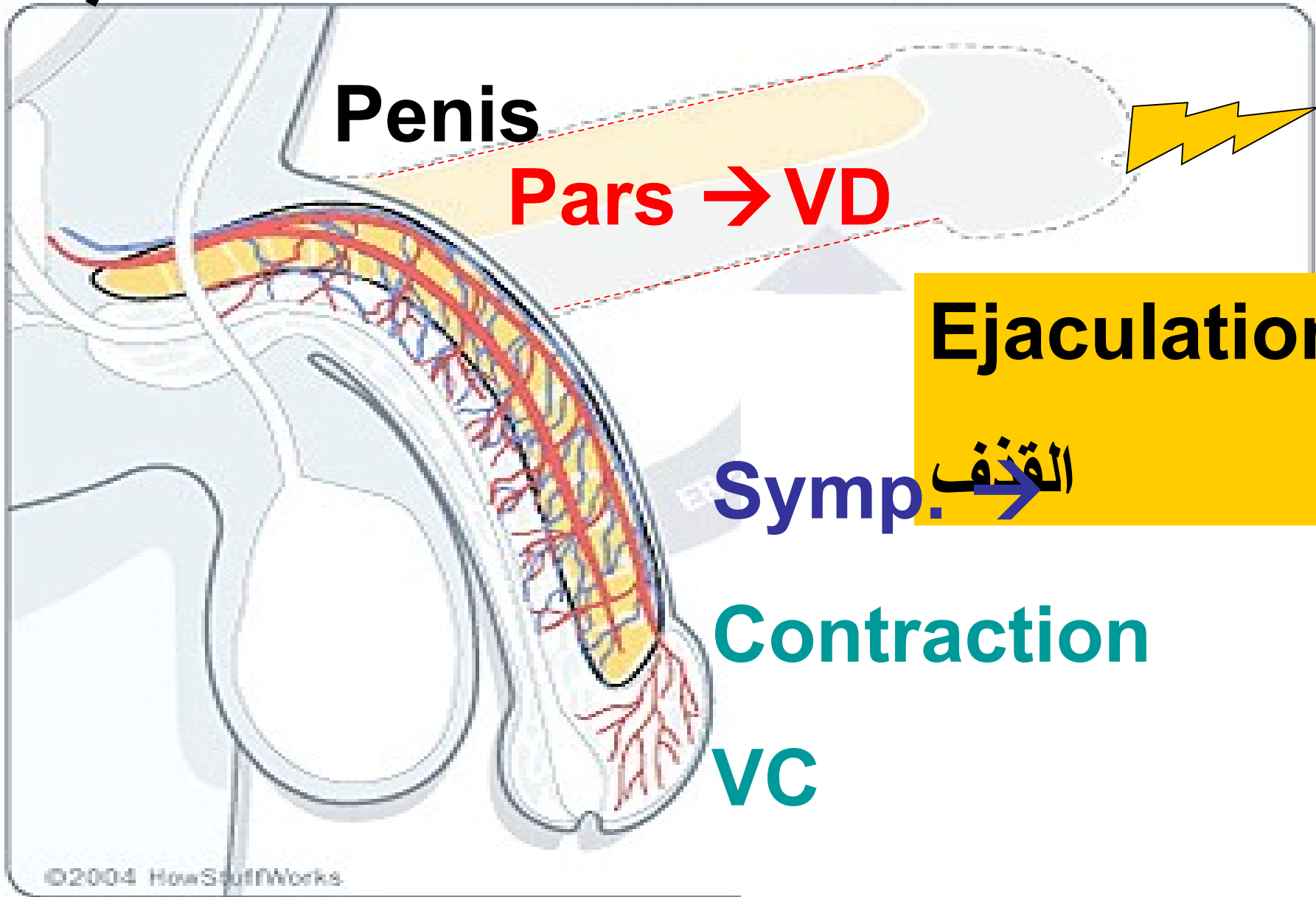
Pars → VD

Ejaculation

Symp. → القذف

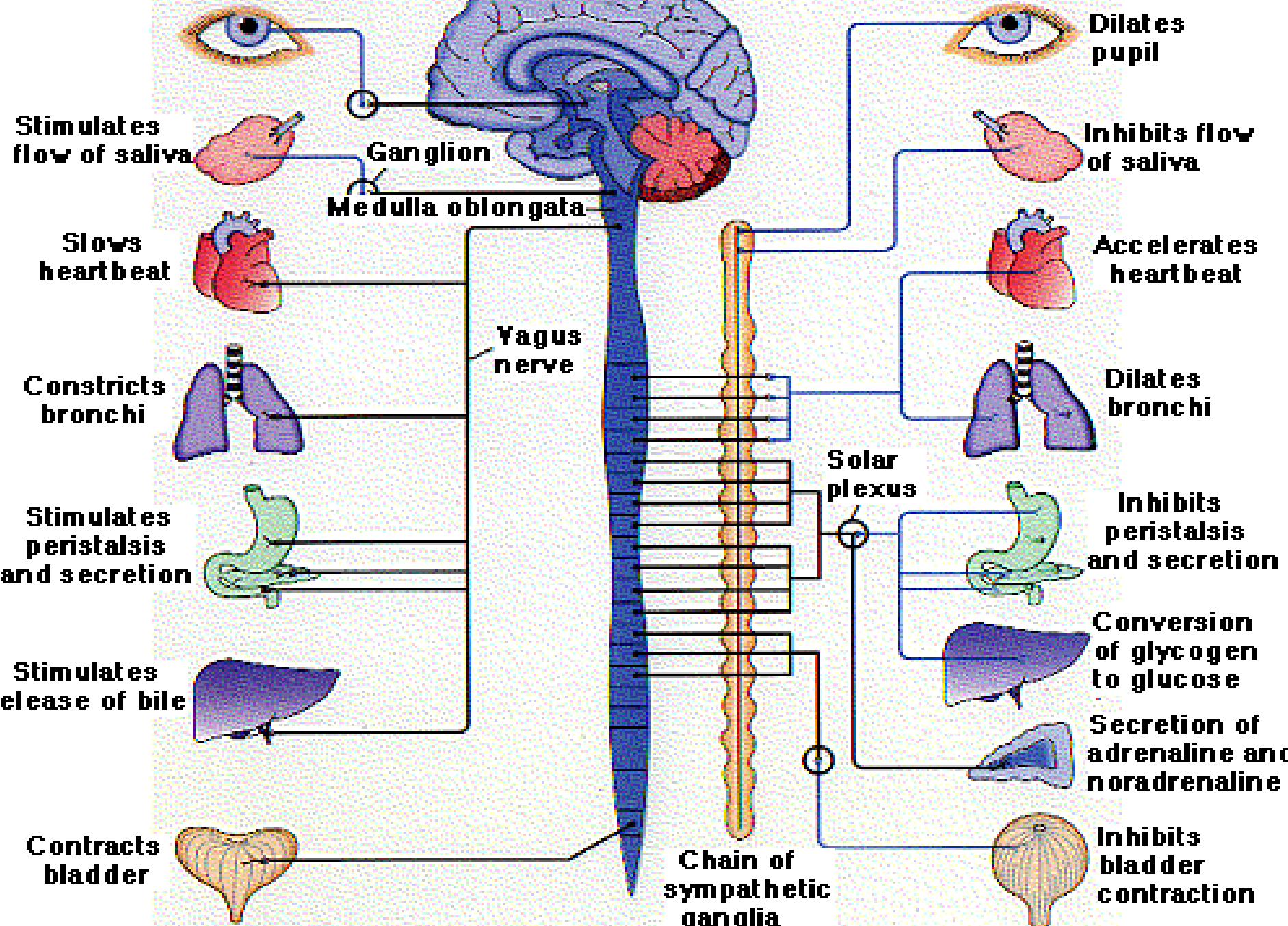
Contraction

VC



Parasympathetic

Sympathetic



Symp.

Thoracolumbar

T1 → L3

Ganglia away
from organs

Long postgang.

NA, Ach

Parasym.

Craniosacral

1973, S2,3,4

Ganglia near
to organs

Short postgang.

Ach

Functions of ANS

Sympathetic

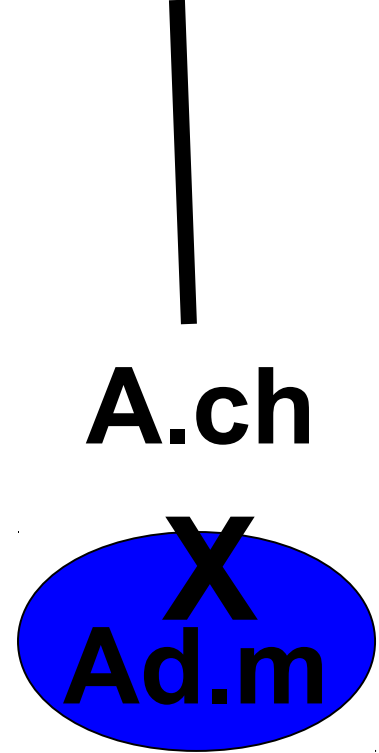
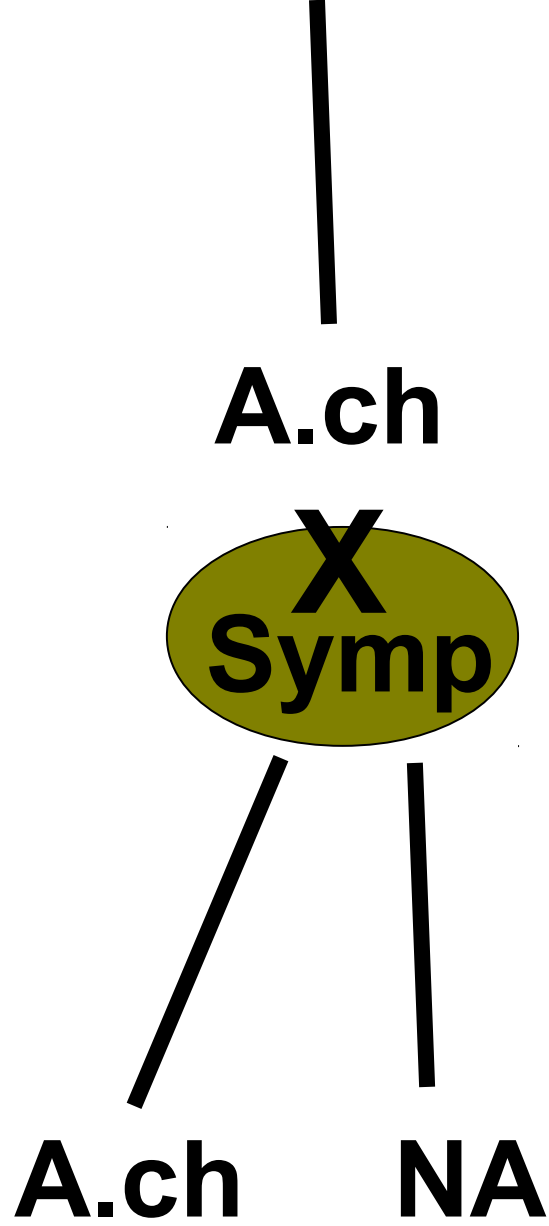
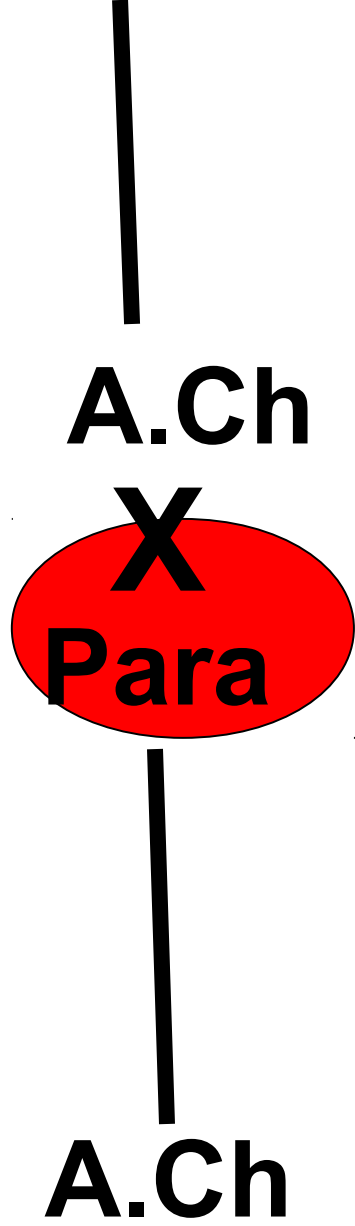
- ▶ Heart
 - ▶ ↑ heart rate + *VD*
 - ▶ ↑ force of contraction
- ▶ Blood vessels
 - ▶ *Constriction*
- ▶ Lungs
 - ▶ Bronchodilation
- ▶ GIT
 - ▶ ↓ motility
 - ▶ Sphincter contraction
 - ▶ Decreased secretions

Parasympathetic

- ▶ Heart
 - ▶ ↓ heart rate + *VC*
 - ▶ ↓ force of contraction
- ▶ Blood vessels
 - ▶ *Dilation*
- ▶ Lungs
 - ▶ Bronchoconstriction
- ▶ GIT
 - ▶ ↑ motility
 - ▶ Sphincter relaxation
 - ▶ Increased secretions

- Ach :
Fibers → cholinergic F
Receptors → cholinergic R
- NA :
Fibers → adrenergic F
Receptors → adrenergic R





Neurotransmitters of the Autonomic Nervous System

Sympathetic

Parasympathetic

~~XXX~~
ACh

~~XXX~~
ACh

~~XXX~~
ACh

Ch R

Ch R

Pre G

Post G

ACh

NE

ACh

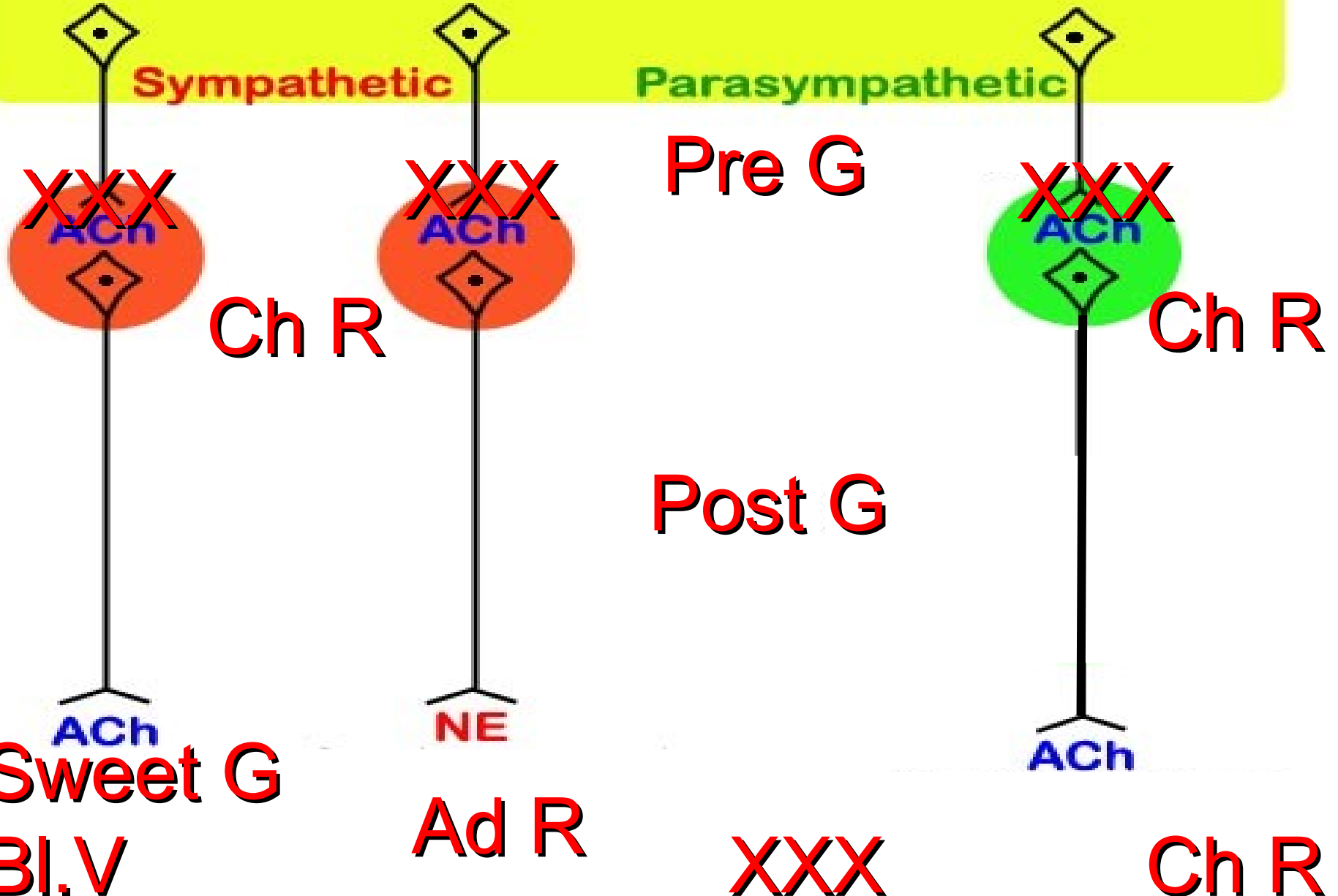
Sweet G

Ad R

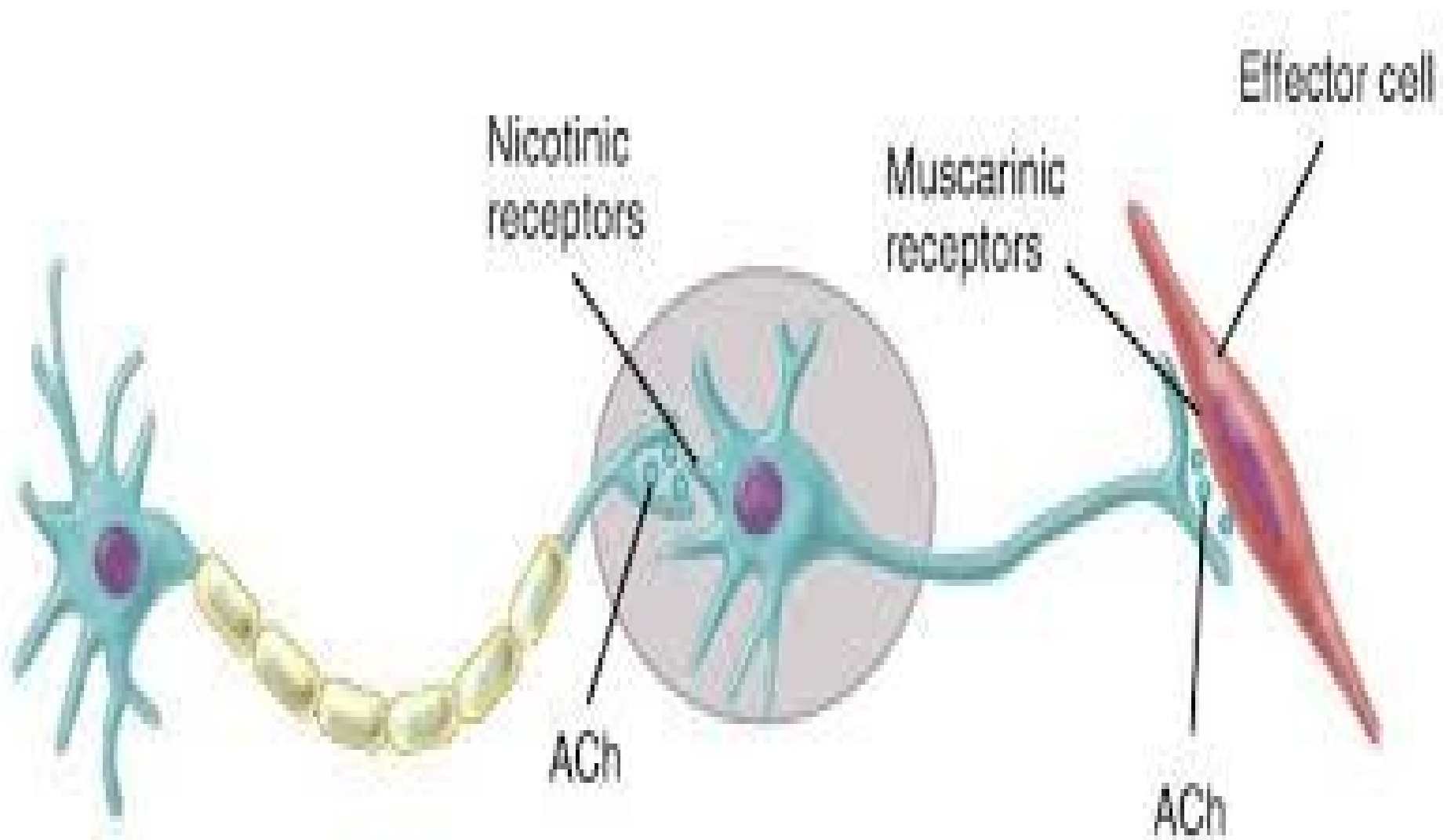
~~XXX~~

Ch R

Bl.V



Cholinergic receptors



ACh

NA

Sites

Nerve Knobs

Nerve knobs
Adrenal G

Source

Choline+Acetyl
e-COA

Dopamine

Storage

Clear vesicle

Dark vesicle

Release

AP → Ca⁺⁺ → Exocytosis

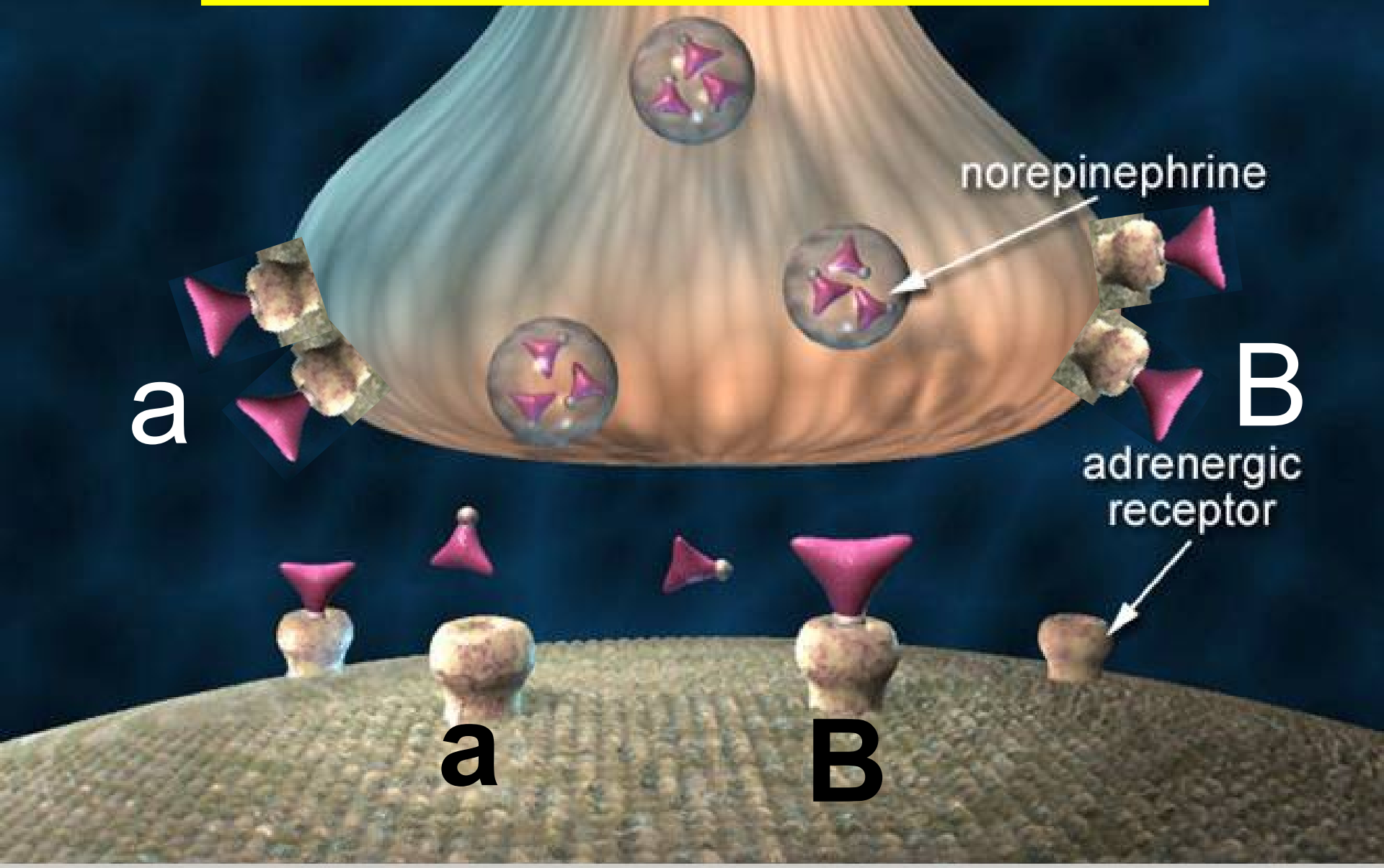
Remove

Ach esterase

Reuptake

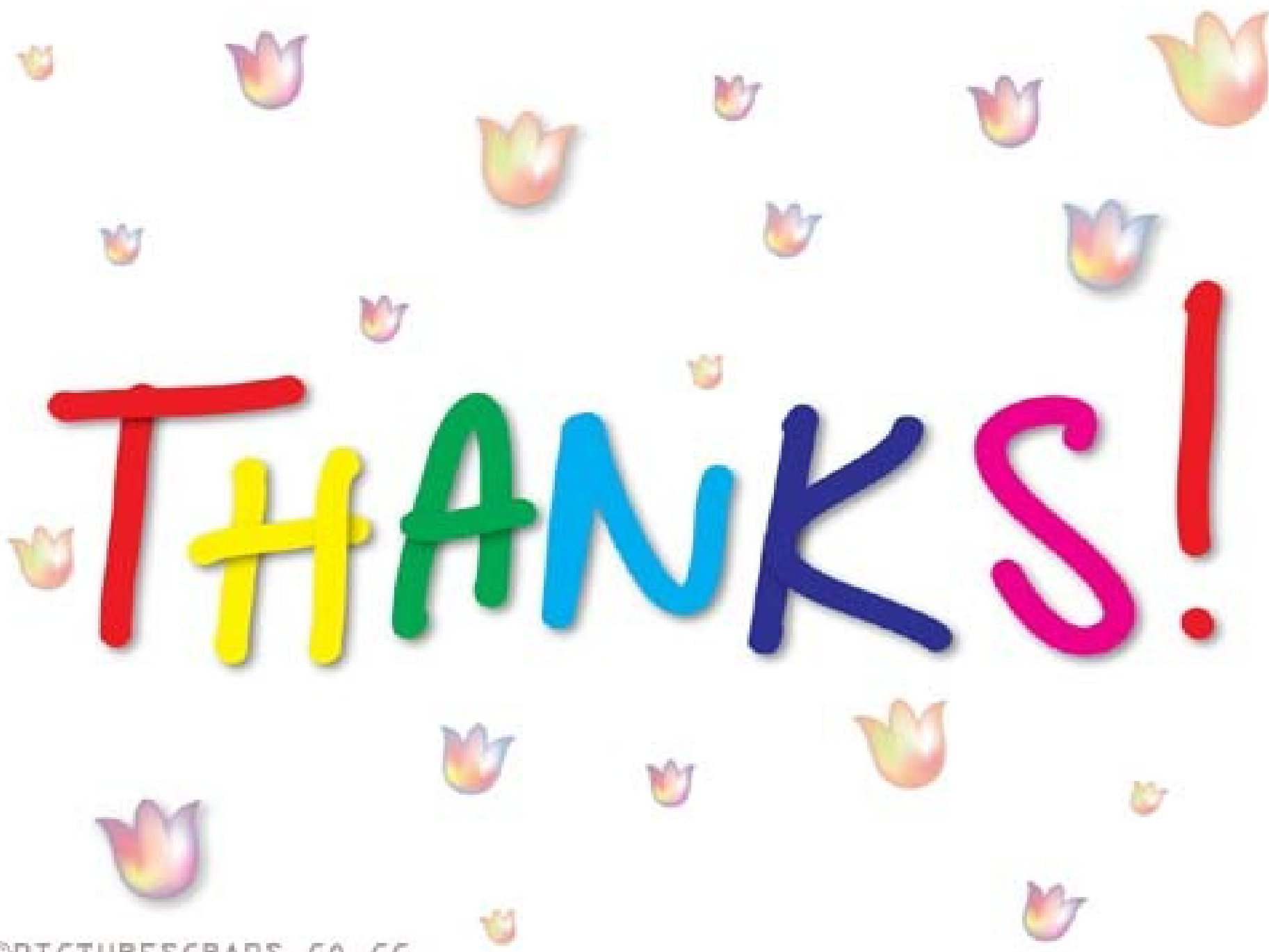MAO/COMT

Adrenergic receptors



Alarm or "Stress" response

- **Sympathetic discharges as one unit**
→ preparation for flight or fight.
- Dilates pupils → more light
- ++ HR & ABP → ++perfusion
- VC in skin → --- bleeding.
- -- Threshold in reticular formation
→ ++ arouse
- ++ Lipolysis and glycogenolysis → E



THANKS!