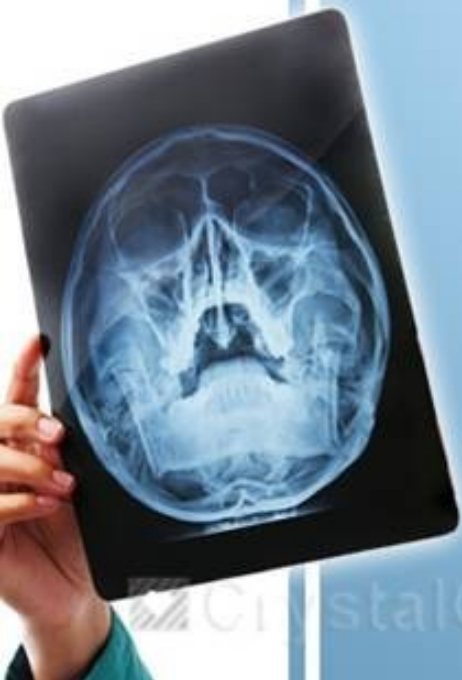
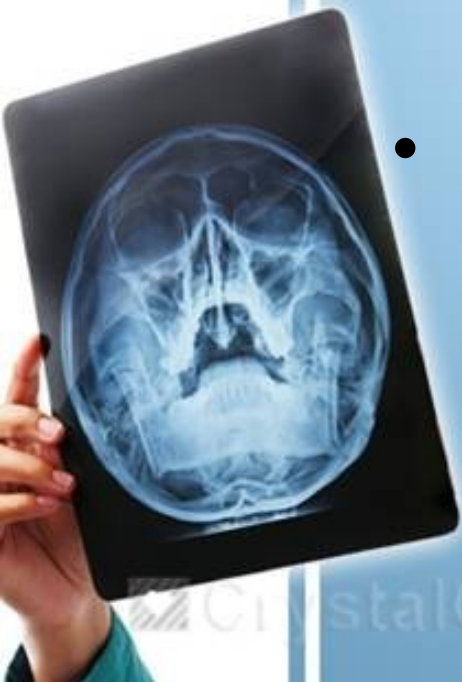
# CONTENTS-

- Introduction
- Adjuncts in extraoral radiography
  - Intensifying screens
  - Grids
  - Digital radiography
- Extraoral radiographic techniques
  - Panoramic radiograph
  - Skull views
    - PA Skull      PA Cephalogram
    - AP Skull      Towne's view
    - Submentovertex view (base of the skull)
    - Lateral skull    Lateral cephalogram

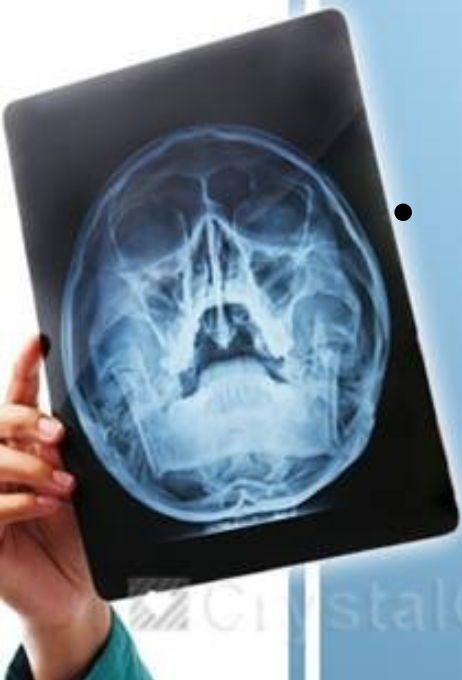

- Maxillary sinus-
  - PA Water's view
  - Modifications- Grenger's view
  - Caldwell's projection
- Mandible-
  - PA Mandible
  - Lateral oblique views
    - Body
    - Ramus
- TMJ views-
  - Transcranial
  - Transpharyngeal
  - Transorbital
  - Reverse Towne's view

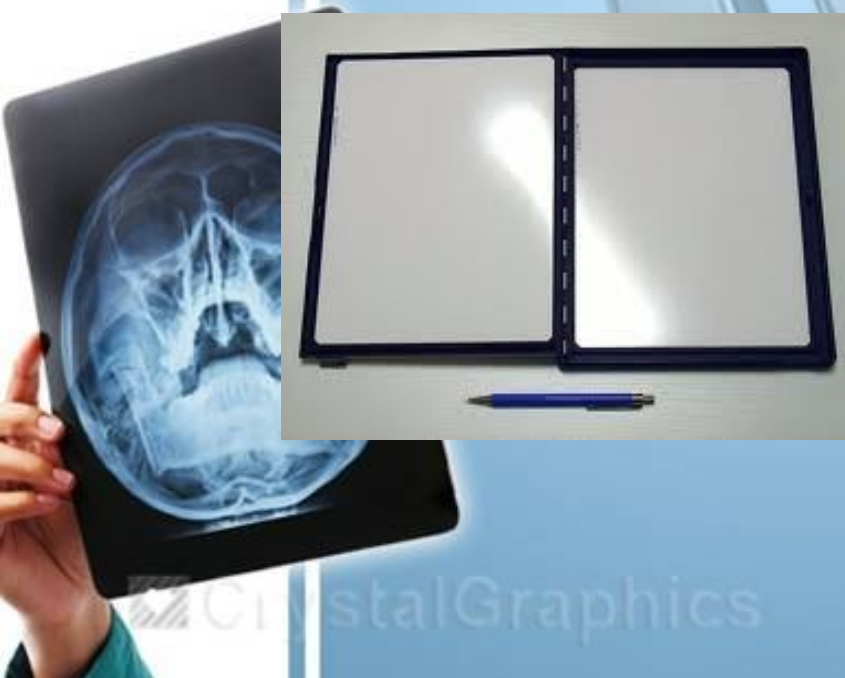

# INTRODUCTION-

- Extraoral radiographs (outside the mouth) are taken when large areas of the skull or jaw must be examined or when patients are unable to open their mouths for film placement.
- Extraoral radiographs do not show the details as well as intraoral films.
- Extraoral radiographs are very useful for evaluating large areas of the skull and jaws but are not adequate for detection of subtle changes such as the early stages of dental caries or periodontal disease.
- There are many type of extraoral radiographs. Some types are used to view the entire skull, whereas other types focus on the **maxilla and mandible**.

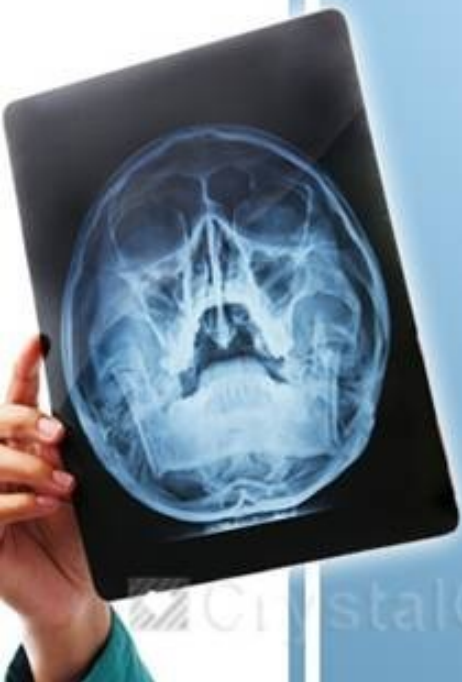

- It makes use of intensifying screens.
- Cephalometric and skull views require at least a 8X10 inch image receptor, whereas oblique lateral projections of the mandible can be obtained with 5X7 inch.



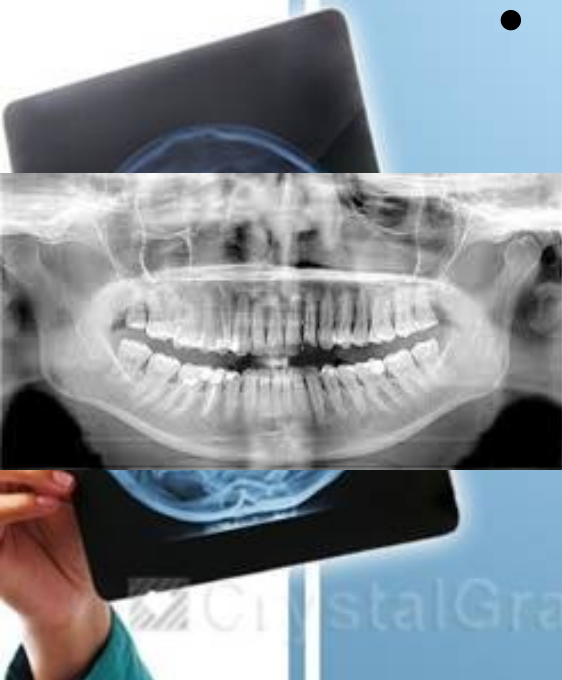

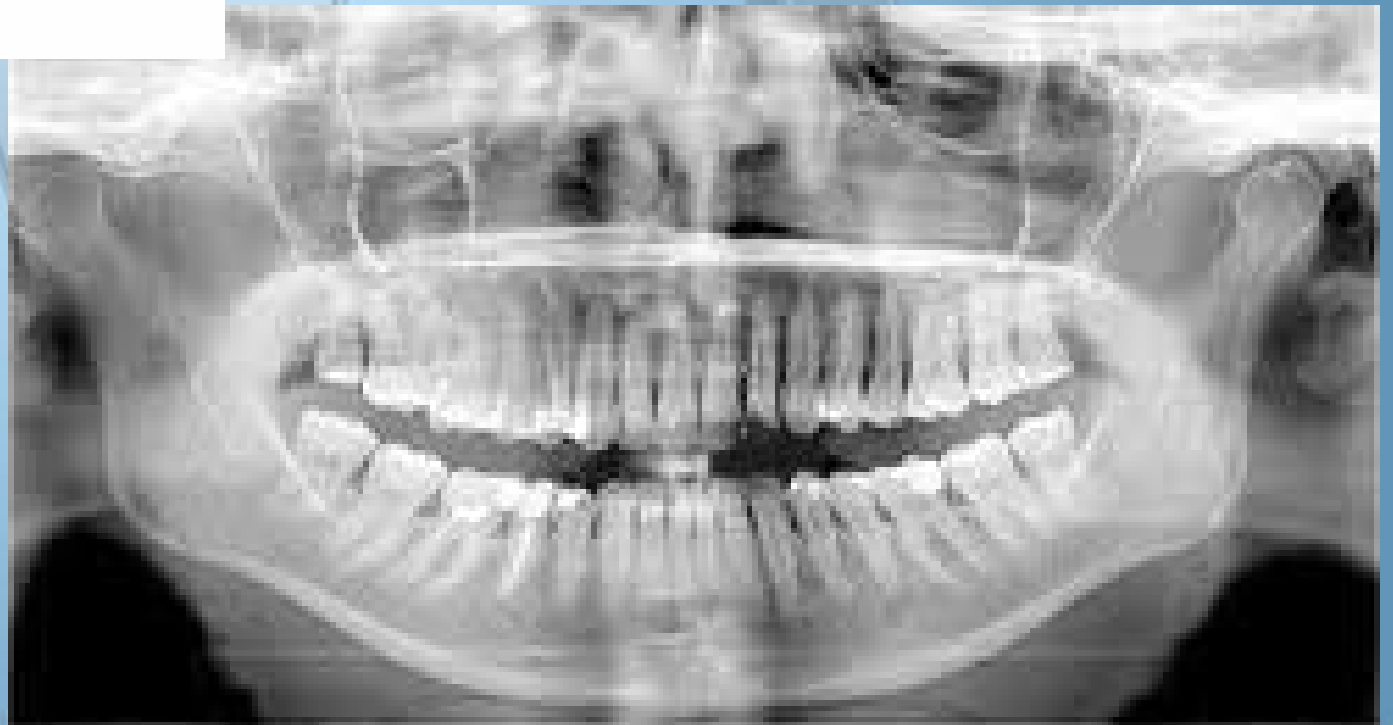
# EXTRAORAL RADIOGRAPHIC TECHNIQUES-



# Panoramic radiographs

- Most common.
- It is a technique for producing a single tomographic image of facial structures that includes both maxillary and mandibular arches and their supporting structures.
- This is curvilinear variant of conventional tomography and is also used on the principle of the reciprocal movement of an x-ray source and an image receptor around a central point or plane called the image layer in which the object of interest is located.





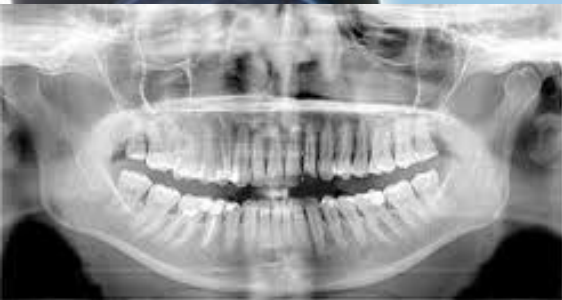## Indications-

Evaluation of-

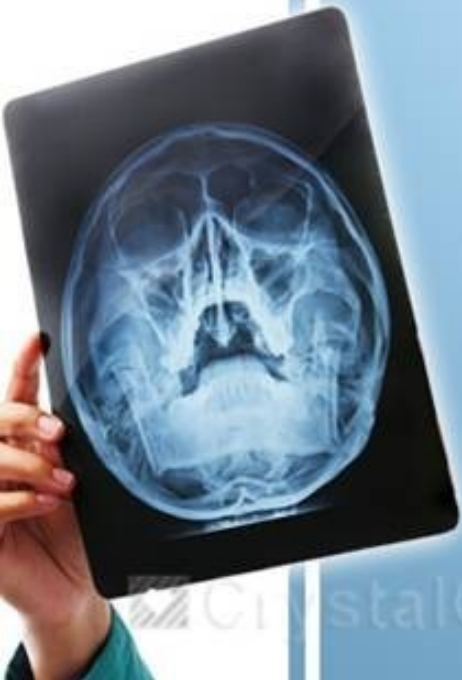- Trauma
- Location of third molars
- Extensive dental or osseous disease
- Known or suspected large lesions
- Tooth development
- Retained teeth or root tips

TMJ pain

Dental anomalies etc.



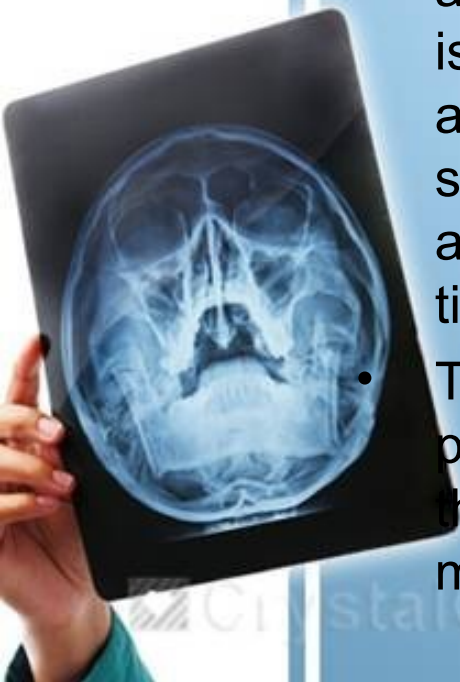
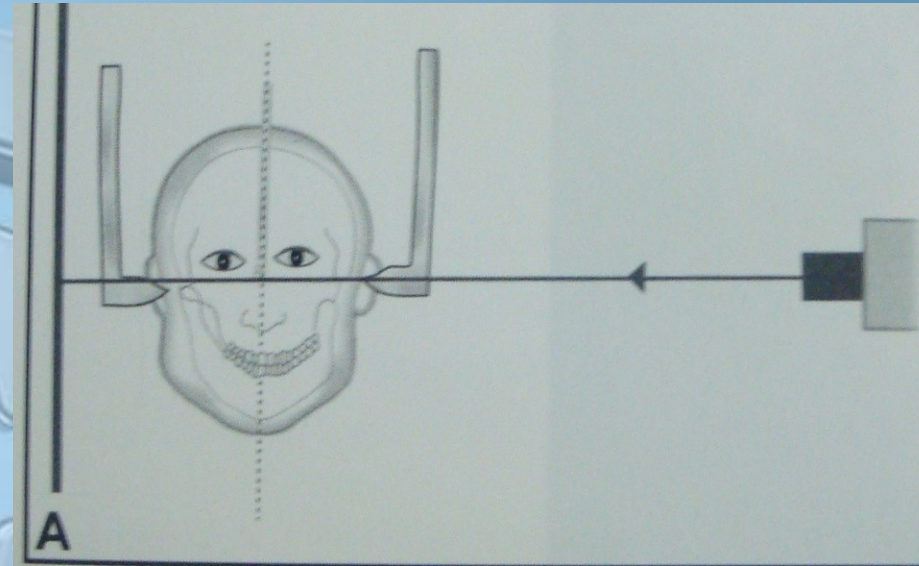


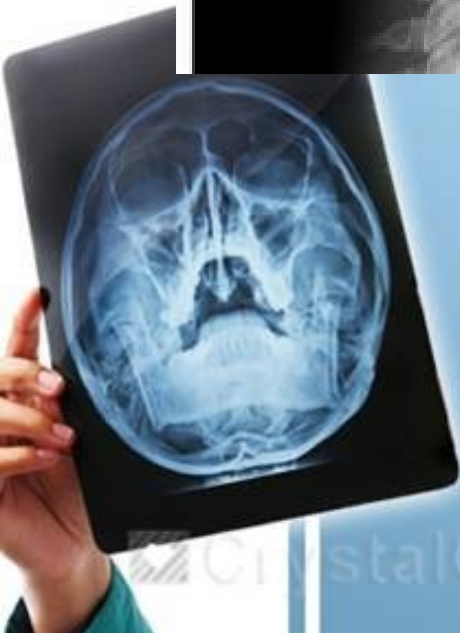
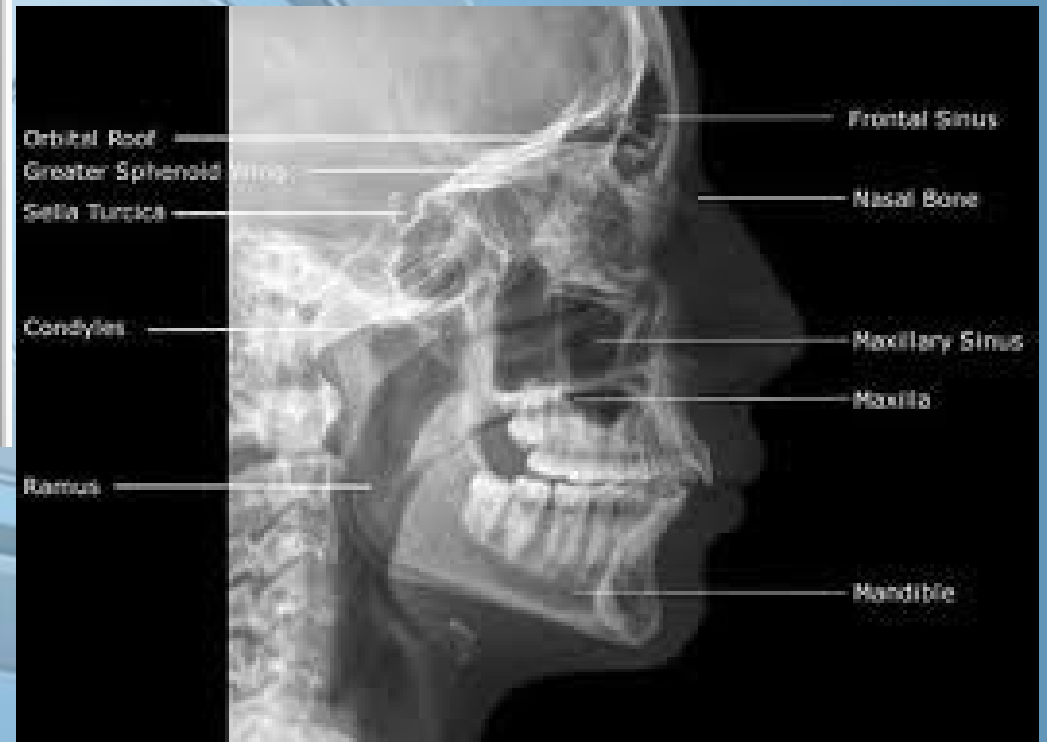
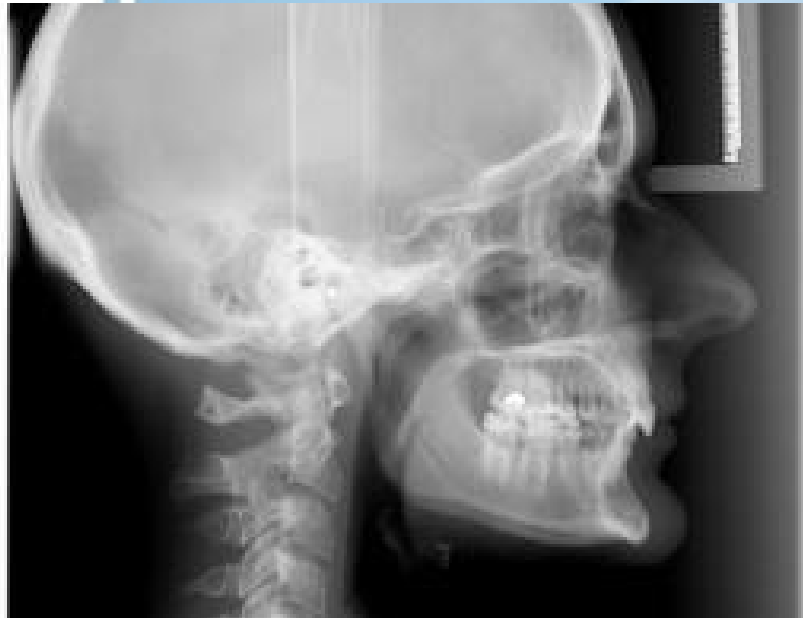# Lateral cephalometric projection-

## Image Receptor and Patient Placement

- The image receptor is positioned parallel to the patient's midsagittal plane. The site of interest is placed toward the image receptor to minimize distortion.
- In cephalometric radiography, a wedge filter at the tube head is positioned over the anterior aspect of the beam to absorb some of the radiation and to allow visualization of soft tissues of the face.
- The central ray is directed perpendicular to the cassette through the external auditory meatus.







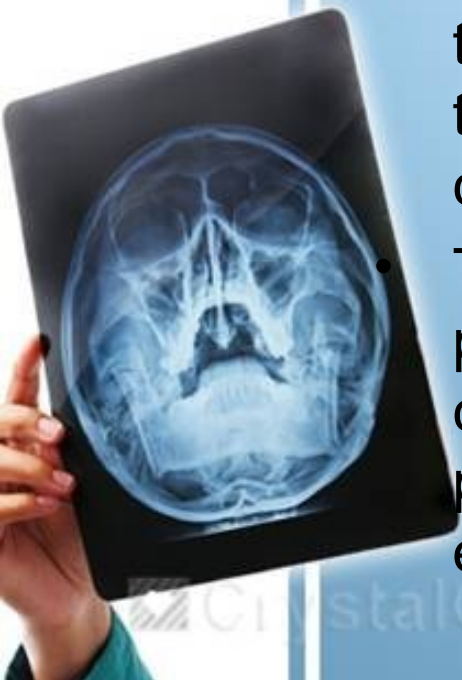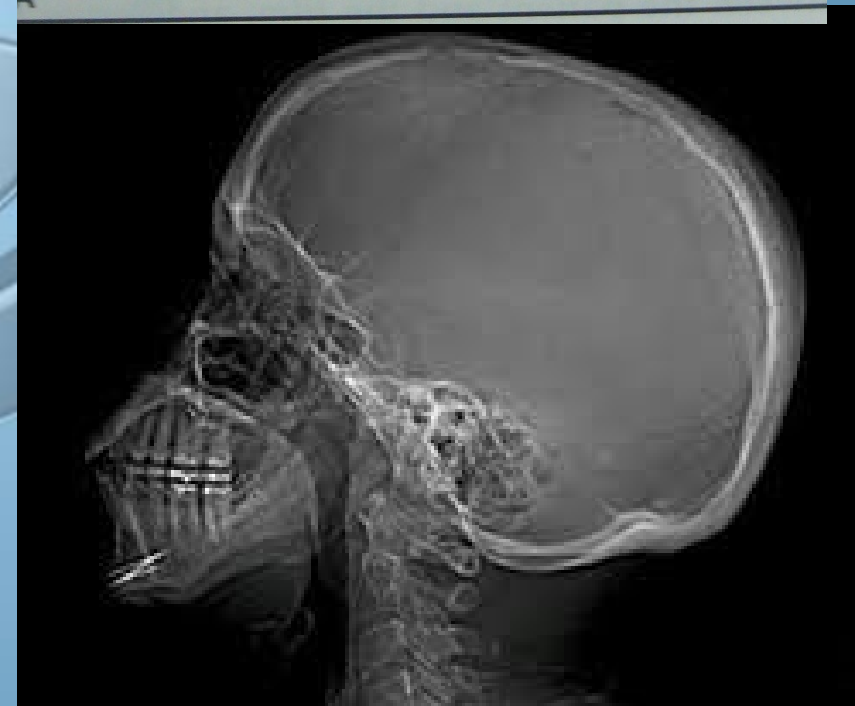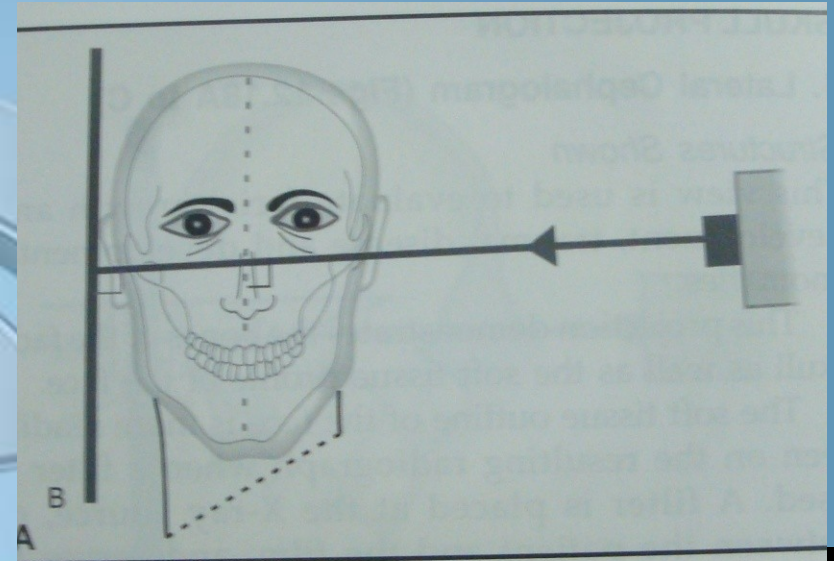
- This view is used to evaluate facial growth and development, trauma, disease and developmental anomalies.
- This projection demonstrates the bones of the face, skull as well as the soft tissue profile of the face.





# True lateral skull

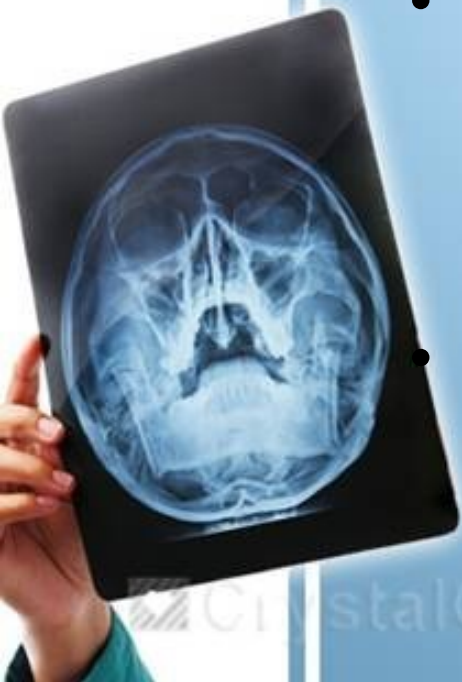- The image receptor is positioned parallel to the patient's midsagittal plane. The site of interest is placed toward the image receptor to minimize distortion.
- The film is adjusted so that the upper circumference of the skull is half inch below the upper border of the cassette.
- The central ray is directed perpendicular to the cassette and the midsagittal plane and towards the external auditory meatus.





# INDICATIONS

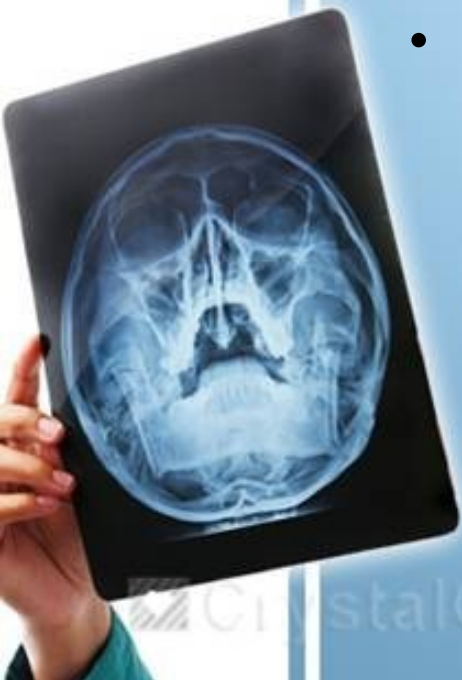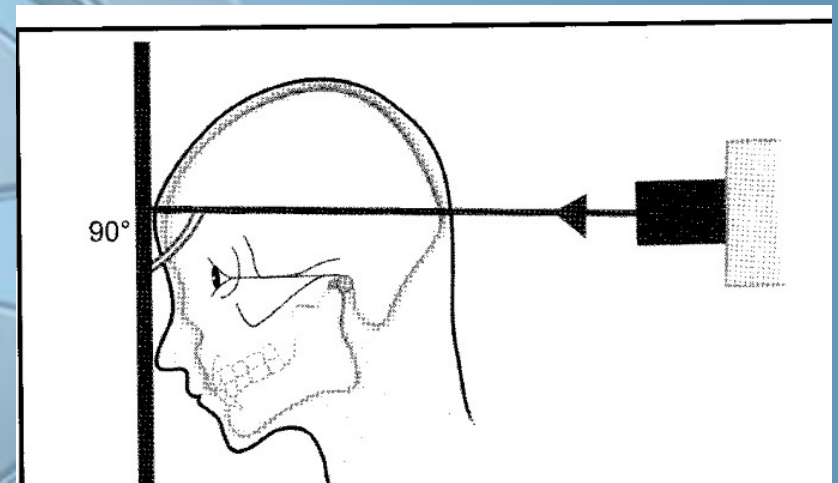
- Fractures of the cranium and the cranial base
- Middle third facial fractures, to show possible downward and backward displacement of the maxilla
- Investigation of the frontal, sphenoidal and maxillary sinuses
- Conditions affecting the skull vault,
  - Paget's disease
  - Multiple myeloma
  - Hyperparathyroidism
- Conditions affecting the sella turcica,
  - Tumor of pituitary gland in acromegaly





# PA skull projection

- The image receptor is placed in front of the patient, perpendicular to the mid sagittal plane and parallel to coronal plane, so that the canthomeatal line is perpendicular to the image receptor.
- Central Ray is directed at right angles to the film through the midsagittal plane through the occiput.

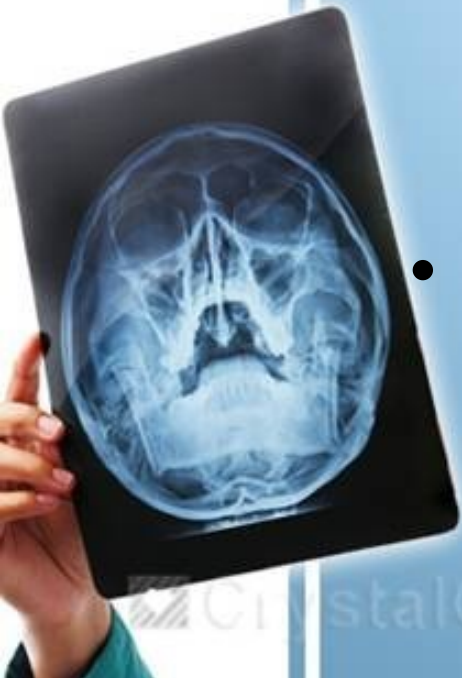





## INDICATIONS

- Fractures of the skull vault
- Investigation of the frontal sinuses
- Conditions affecting the cranium
  - Paget's disease
  - Multiple myeloma
  - Hyperparathyroidism
- Intracranial calcifications



# PA cephalogram



# Towne's view

- The cassette is placed perpendicular to the floor.
- The long-axis of the cassette is positioned vertically.
- This is an anteroposterior view, with the back of the patient's head touching the film. The canthomeatal line is perpendicular to the film.
- The central ray is directed at 30 degrees to the canthomeatal line and passes through it at a point between the external auditory meatus.

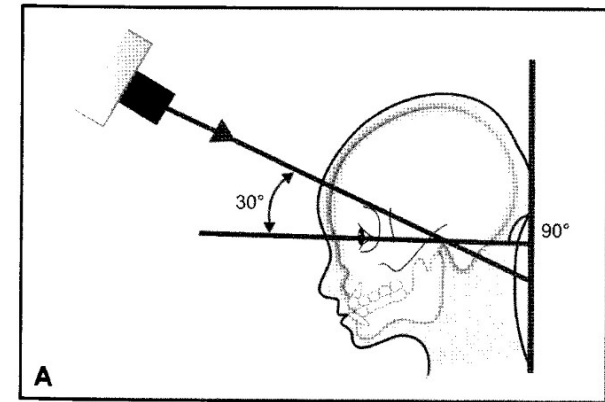
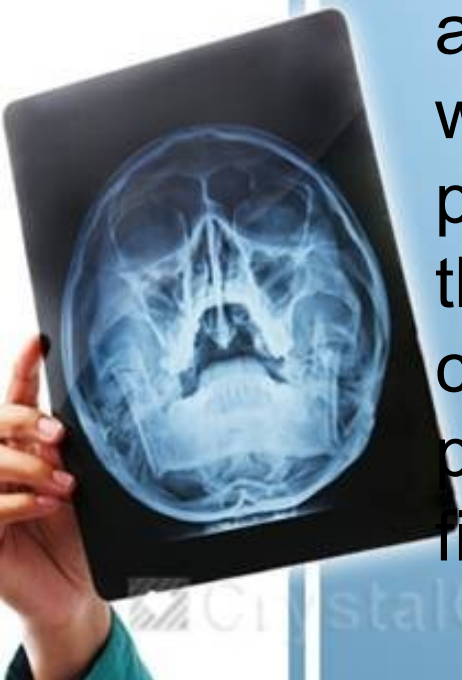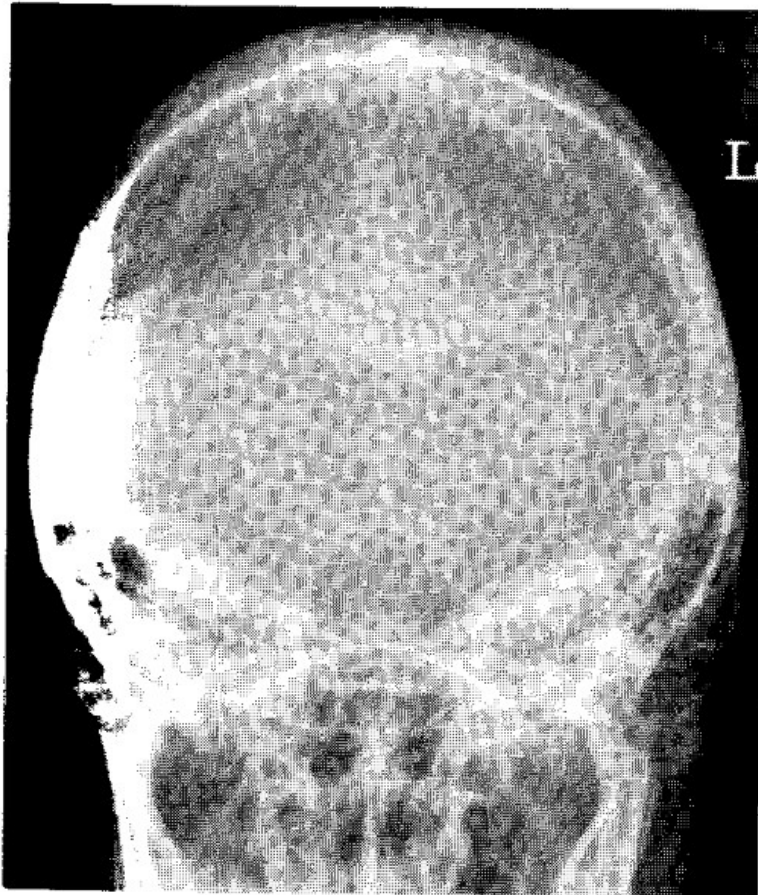


Fig. 12.22A: Diagram for the positioning for Towne's projection, showing back of head of the patient touching the cassette and the central ray at an angle of 30° to the canthomeatal line

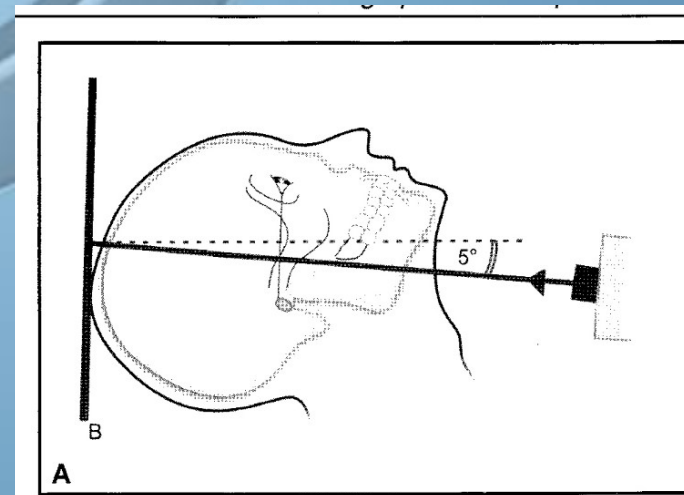
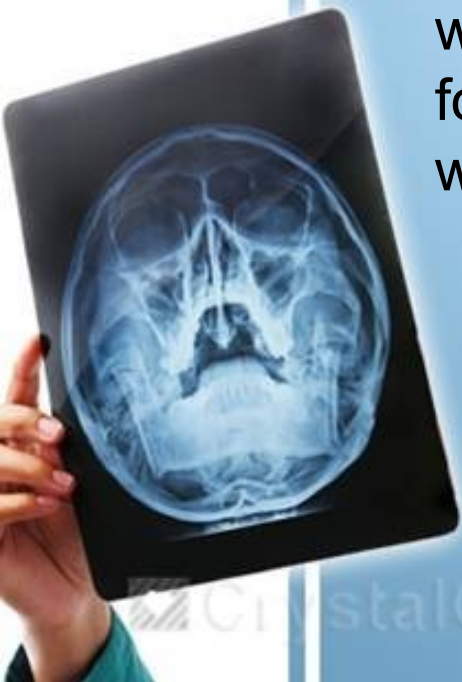


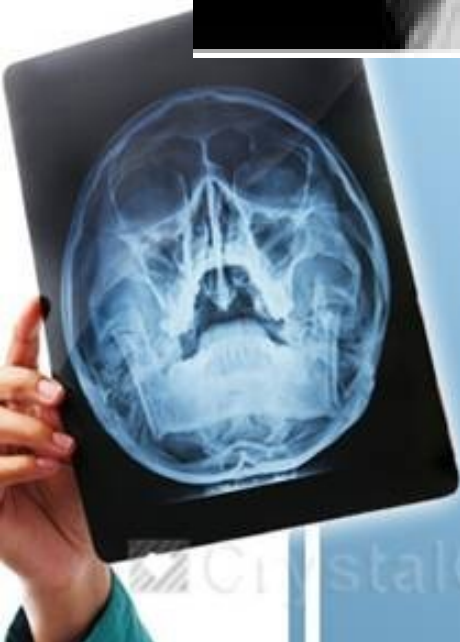
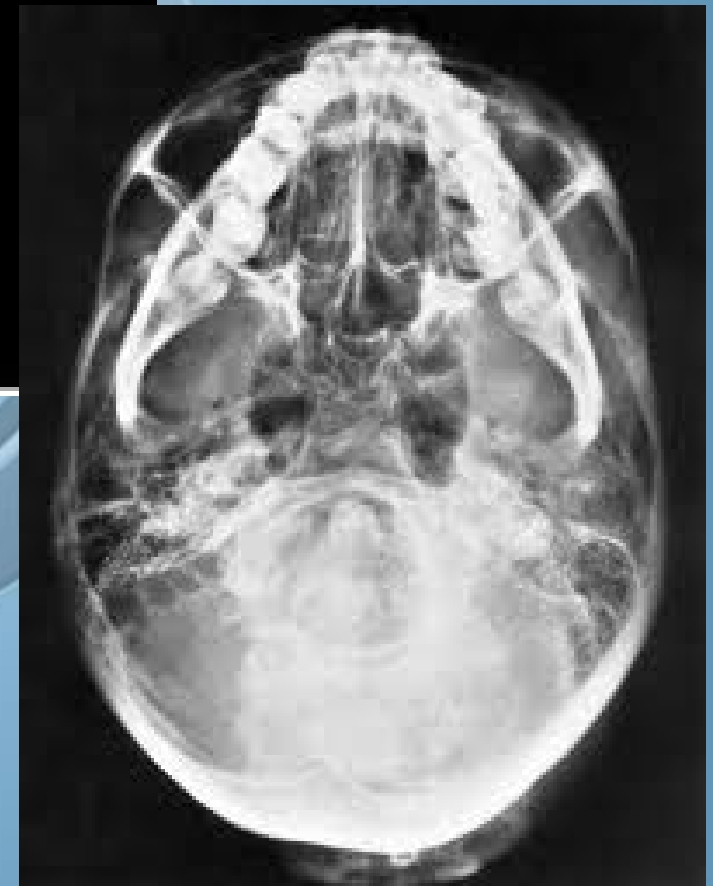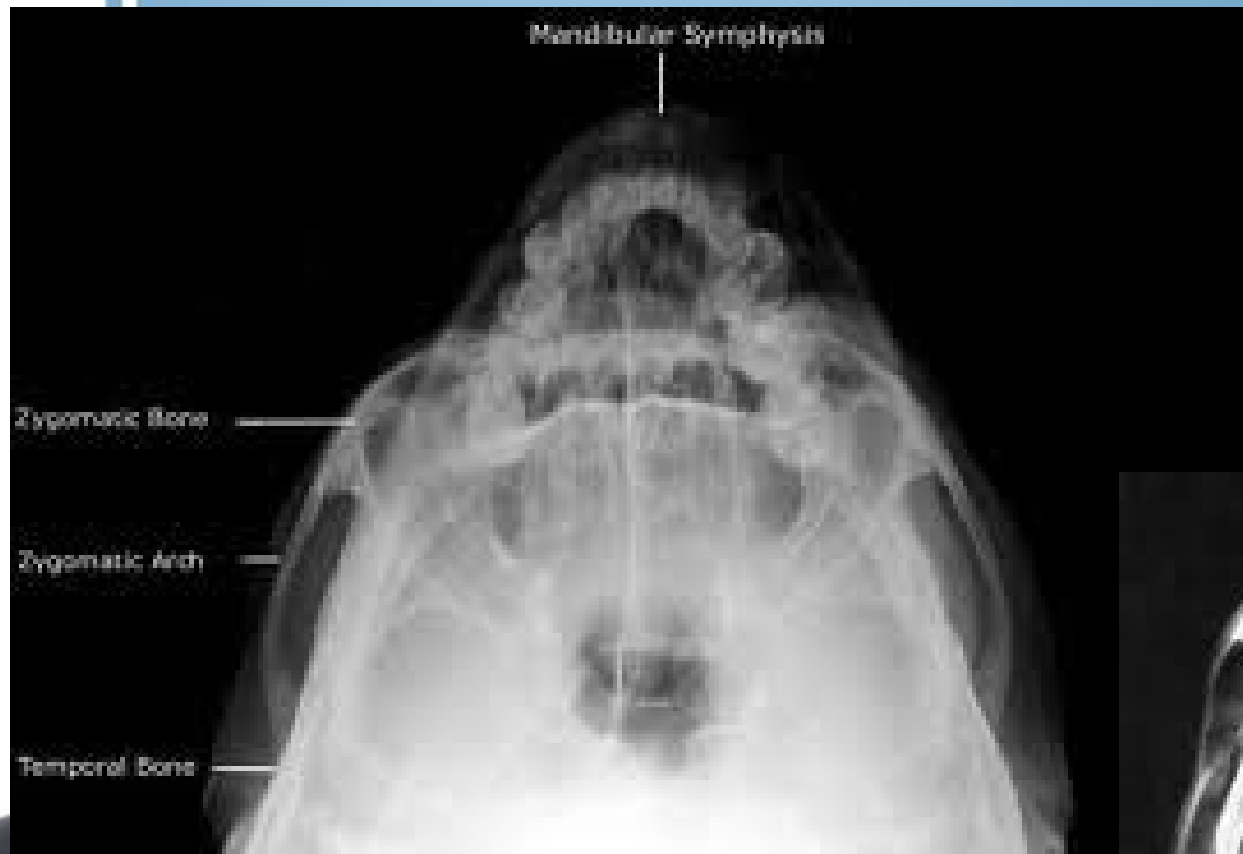- It is primarily used to observe the occipital area of the skull.
- The necks of the condyloid process can also be viewed.

# Submentoververtex (base of the skull)

- The image receptor is positioned parallel to patient's transverse plane and perpendicular to the midsagittal and coronal planes. To achieve this, the patient's neck is extended as far backward as possible, with the canthomeatal line forming a 10 degree angle with the receptor.
- The central beam is perpendicular to the image receptor, directed from below the mandible toward the vertex of the skull (hence the name submentoververtex, or SMV), and centered about 2 cms anterior to a line connecting the right and left condyles.

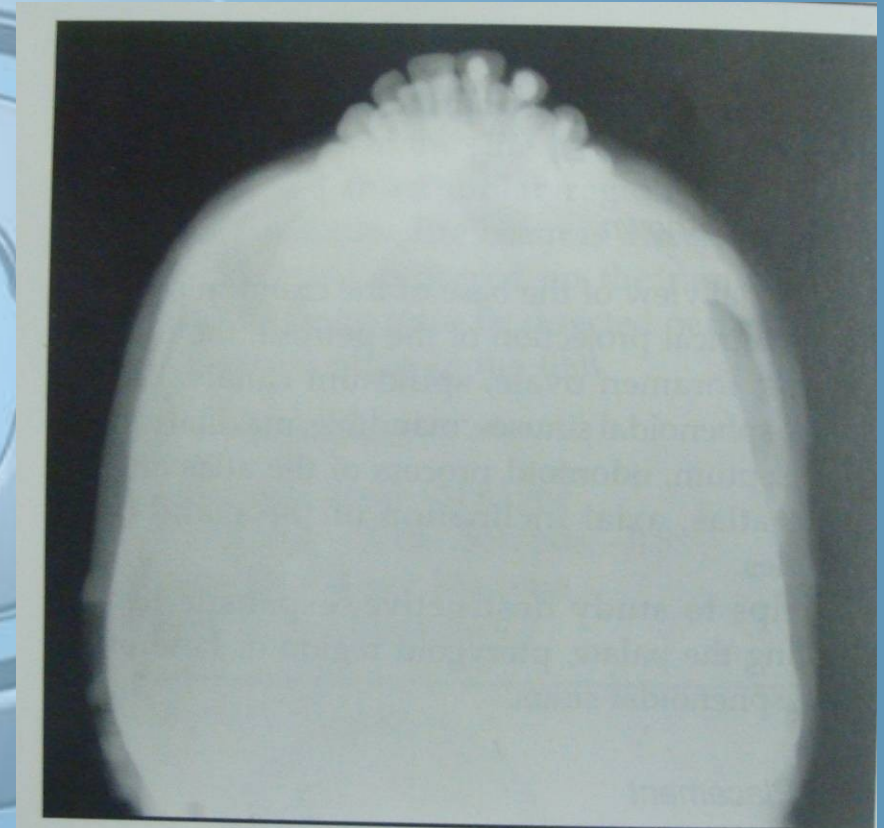






# Jug handle view

- Same as that in submentovertex.
- The exposure time for the zygomatic arch is reduced to approximately one-third the normal exposure time for a submentovertex projection.




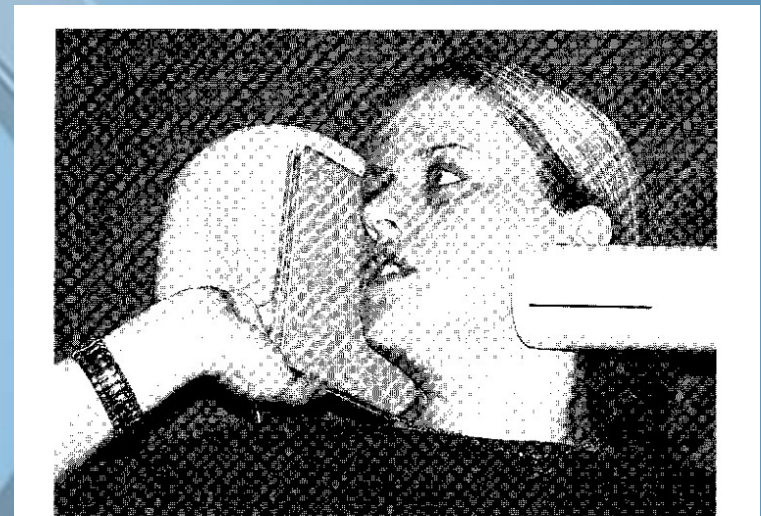
# PROJECTIONS FOR MANDIBLE

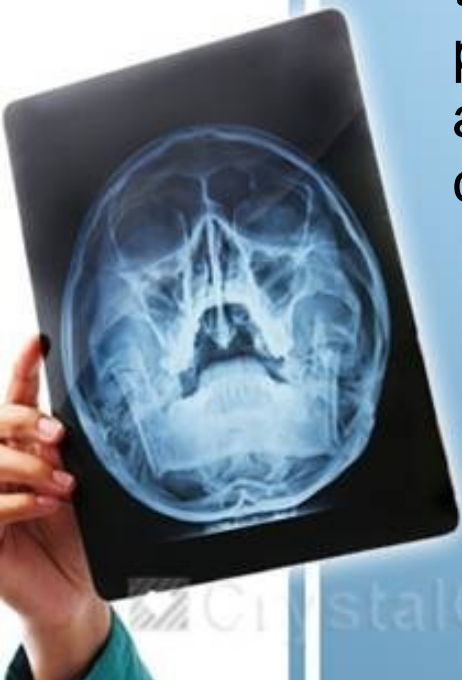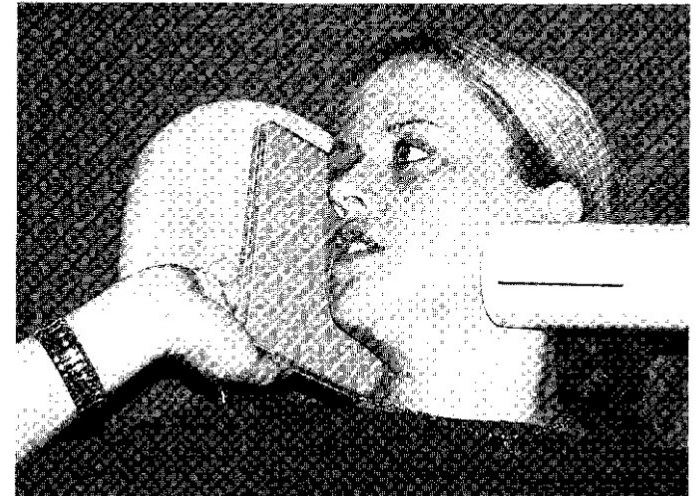


# Lateral oblique(body of mandible)

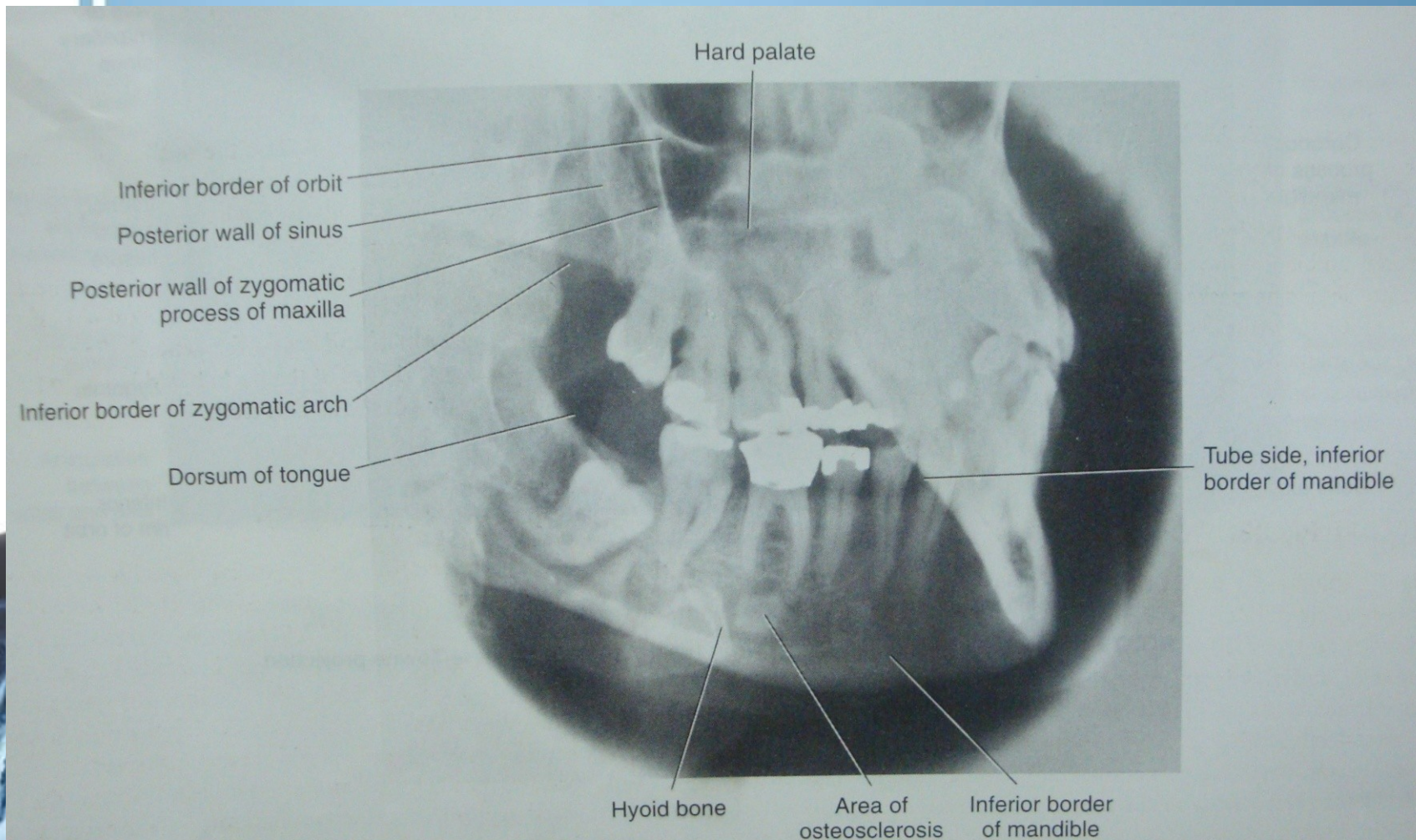
- The cassette is positioned against the patient's cheek overlying the ascending ramus and the posterior aspect of the condyle of the mandible under investigation.
- The cassette is positioned so that its lower border is parallel with the inferior border of the mandible but lies at least 2 cm below it



- The positioning achieves a 10-degree angle of separation between the median sagittal plane and the film.
- The mandible is extended as far as possible.
- The centring position of the tube is the contralateral side of the mandible at a point 2 cm below the inferior border in the region of the first/second permanent molar with angulation of 10 degrees cephalad or caudal



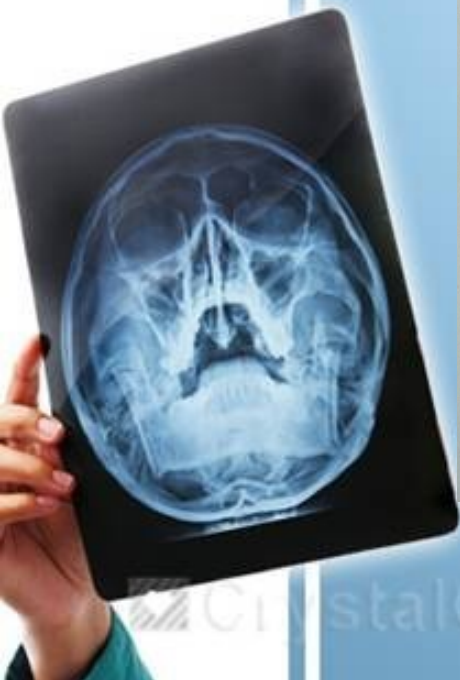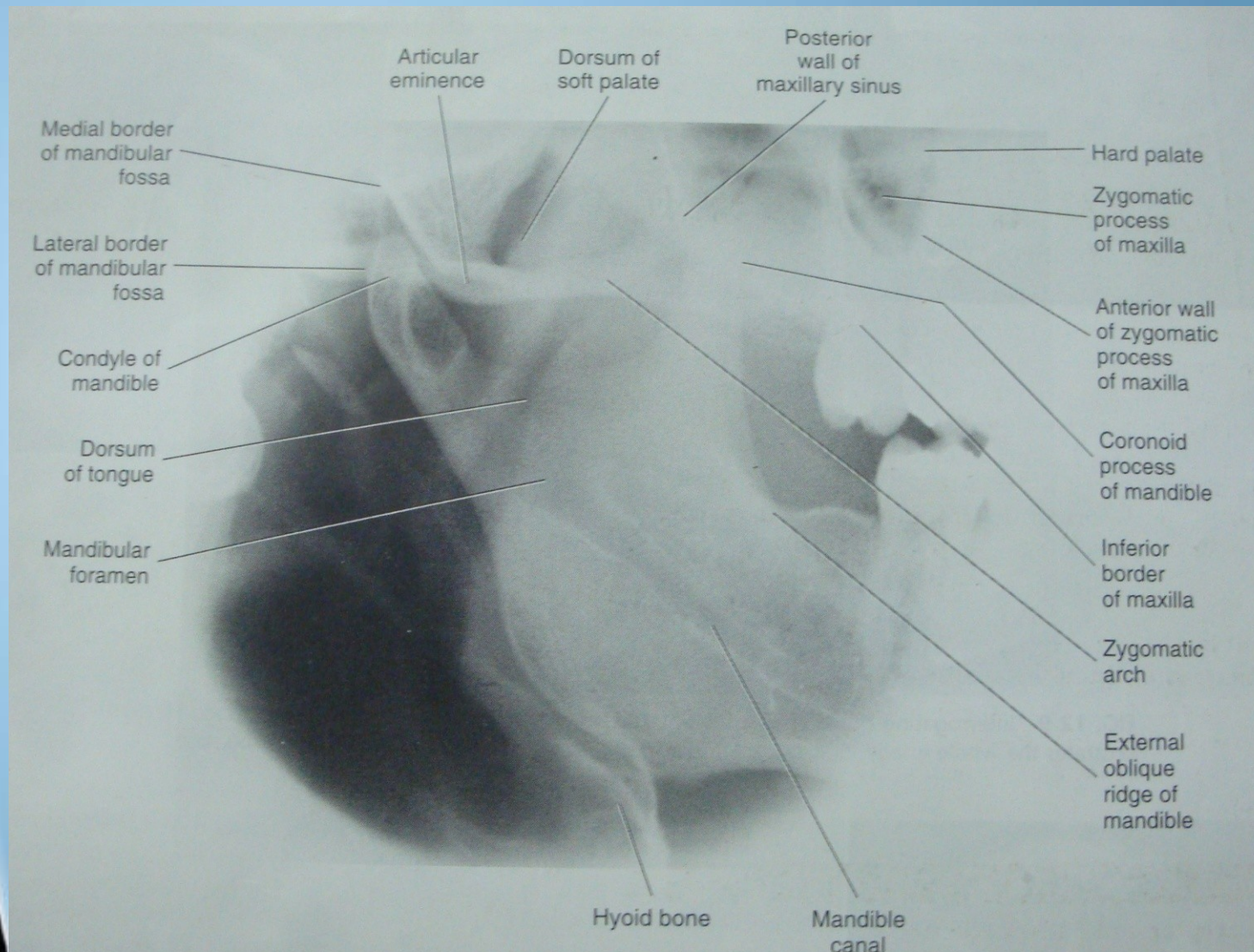






# Lateral oblique (ramus of mandible)







# PA mandible

- The cassette is placed in front of the patient, so that the median sagittal plane should be perpendicular to the cassette. The head is then adjusted to bring the orbito-meatal baseline perpendicular to the cassette
- The cassette should be positioned such that the middle of cassette, is centred at the level of the angles of the mandible.
- The central ray is directed perpendicular to the cassette and centred in the midline at the levels of the angles of the mandible.

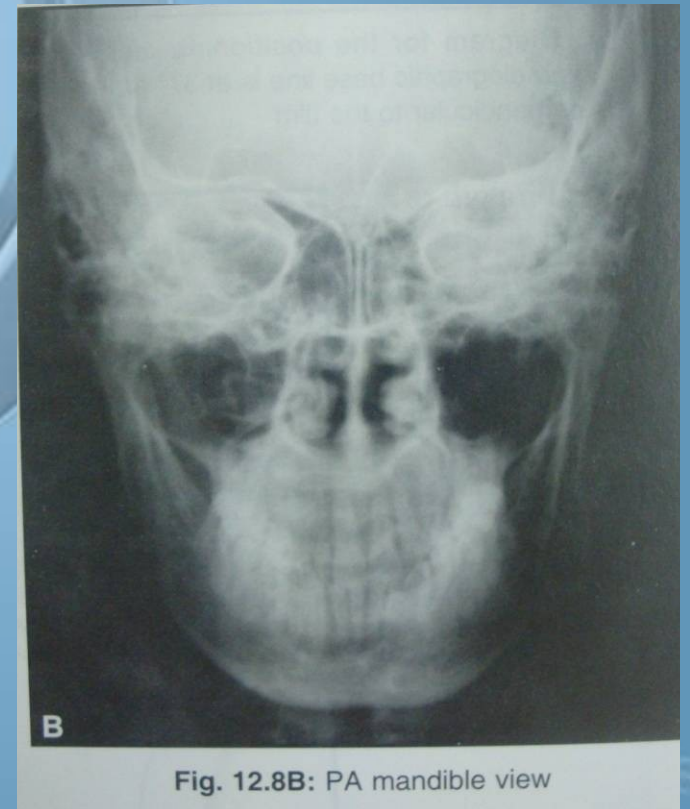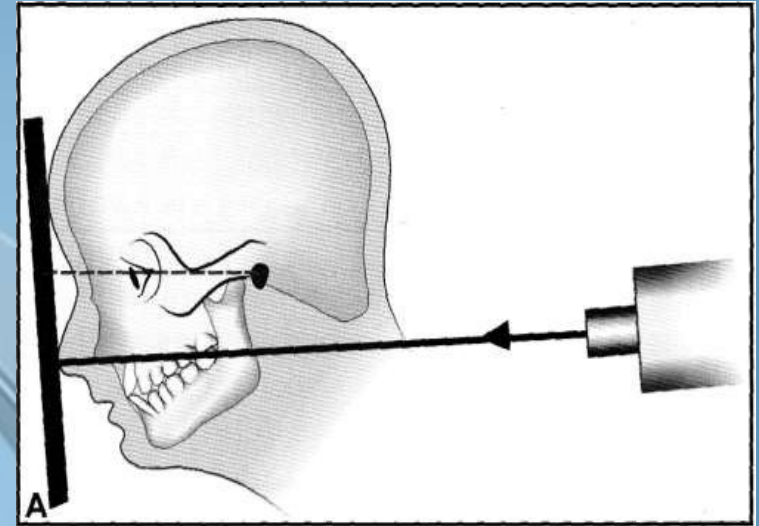


Fig. 12.8B: PA mandible view

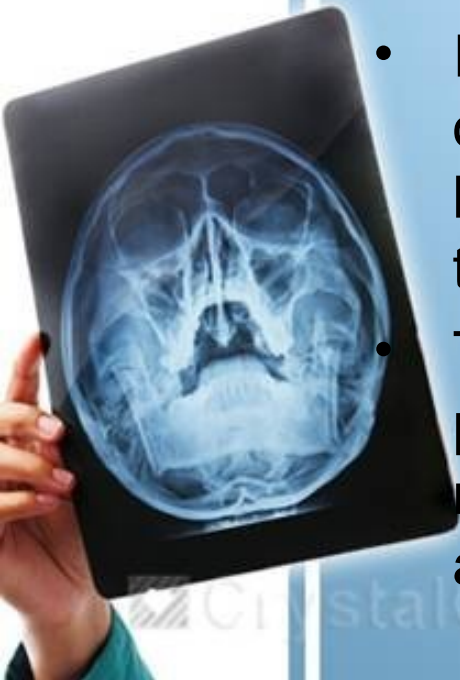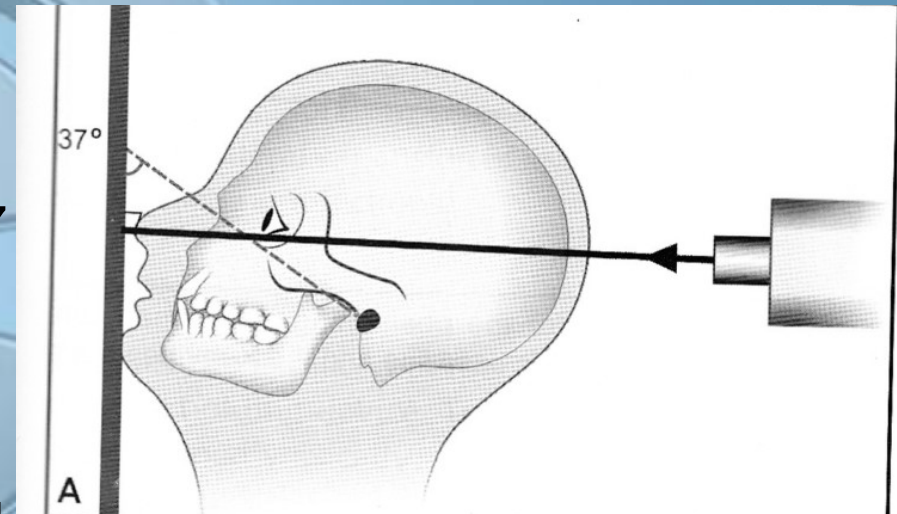
# PROJECTIONS FOR MAXILLARY SINUS-

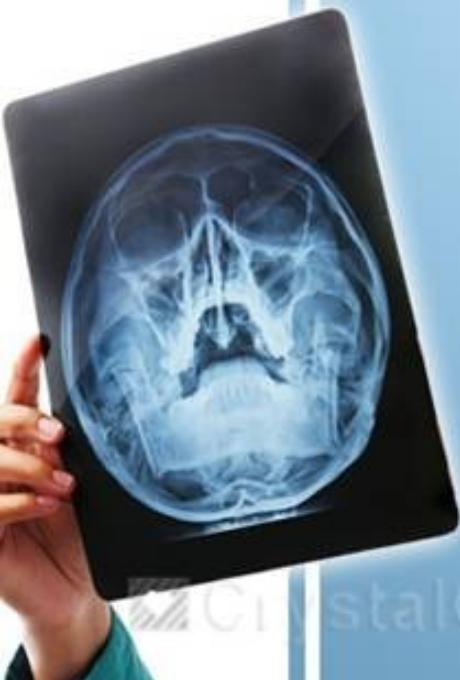
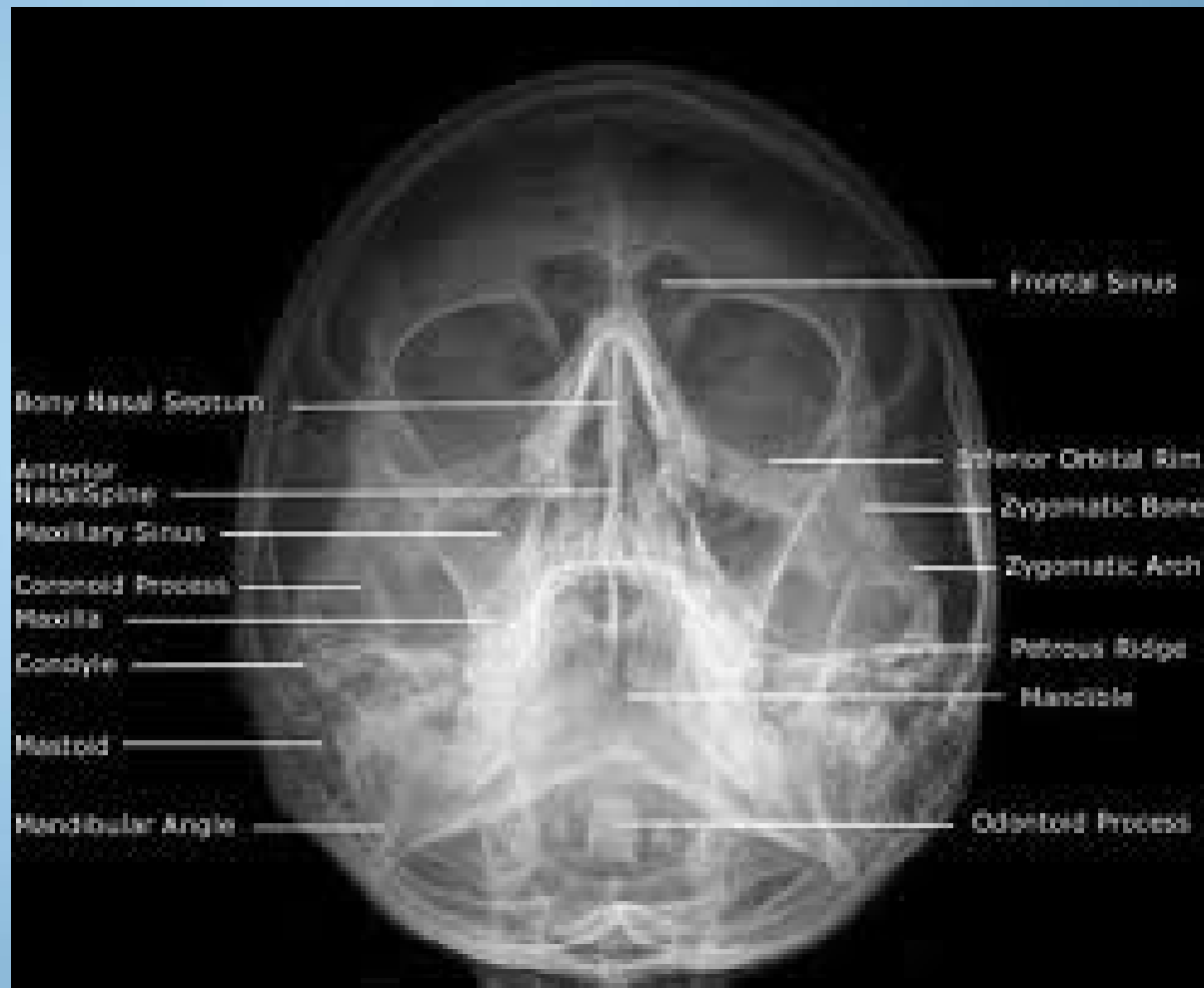


# PA Water's view (PNS)

- The image receptor is placed in front of the patient and perpendicular to the midsagittal plane.
- The patient's head is tilted upward so that the canthomeatal line forms a 37 degrees angle with the image receptor.
- If the patient's mouth is open, the sphenoid sinus will be seen superimposed over the palate.
- The central beam is perpendicular to the image receptor and centered in the area of maxillary sinuses.





# Granger's Modification-



# Caldwell's Modification-

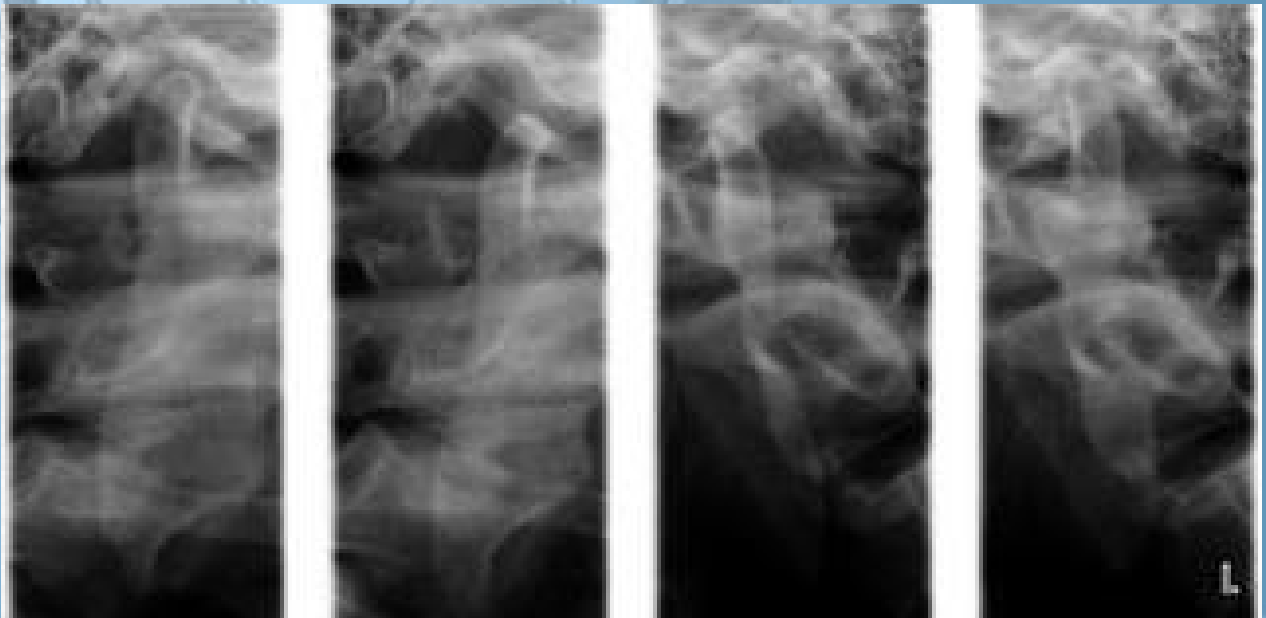
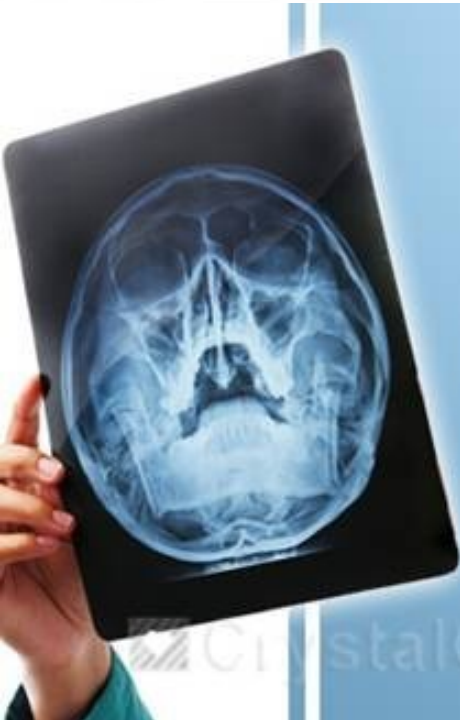
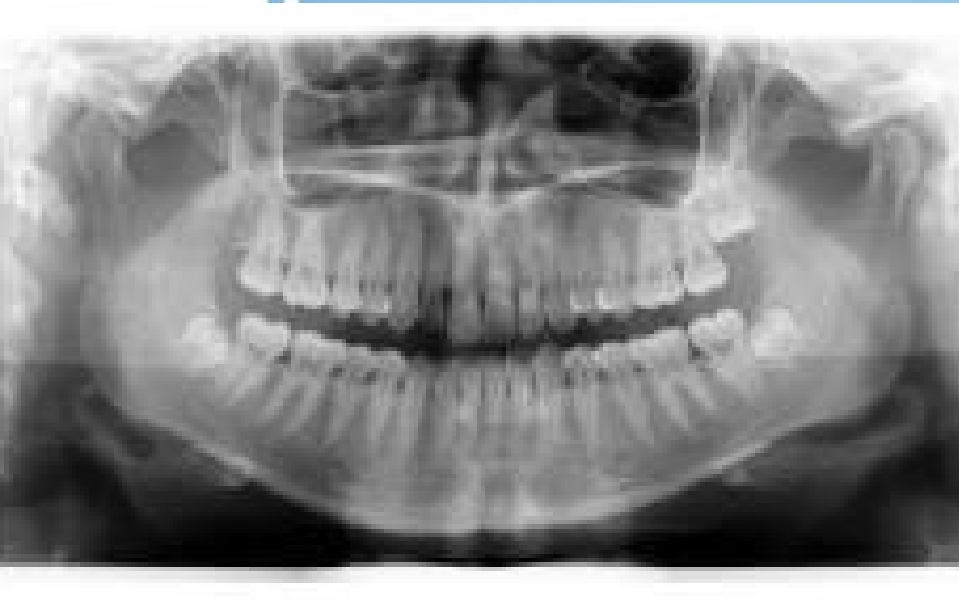


# TEMPOROMANDIBULAR JOINT VIEWS

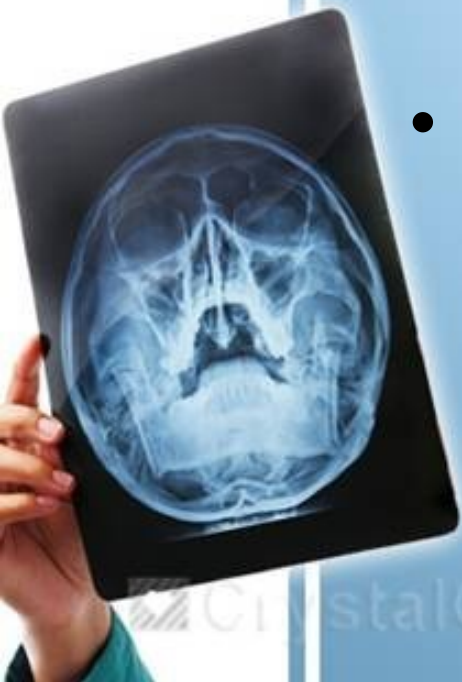

# TMJ panoramic view



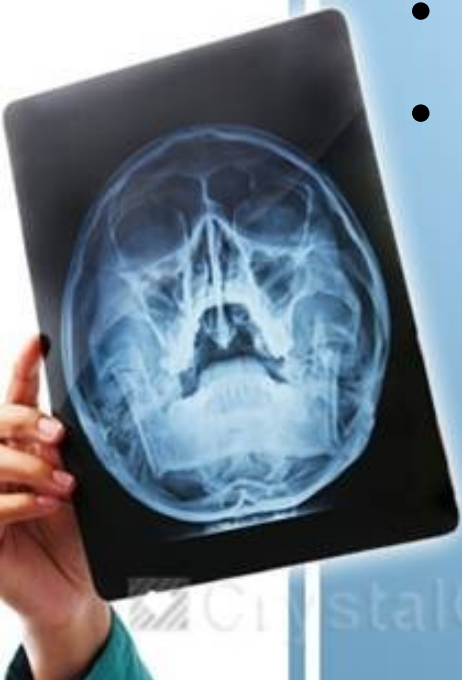## Indications-

- The panoramic projection serves as the screening projection to identify odontogenic disorders and other disorders that may be the source of TMJ symptoms
- Gross osseous changes in the condyles may be identified such as asymmetries, extensive erosions, large osteophytes, tumors or fractures.

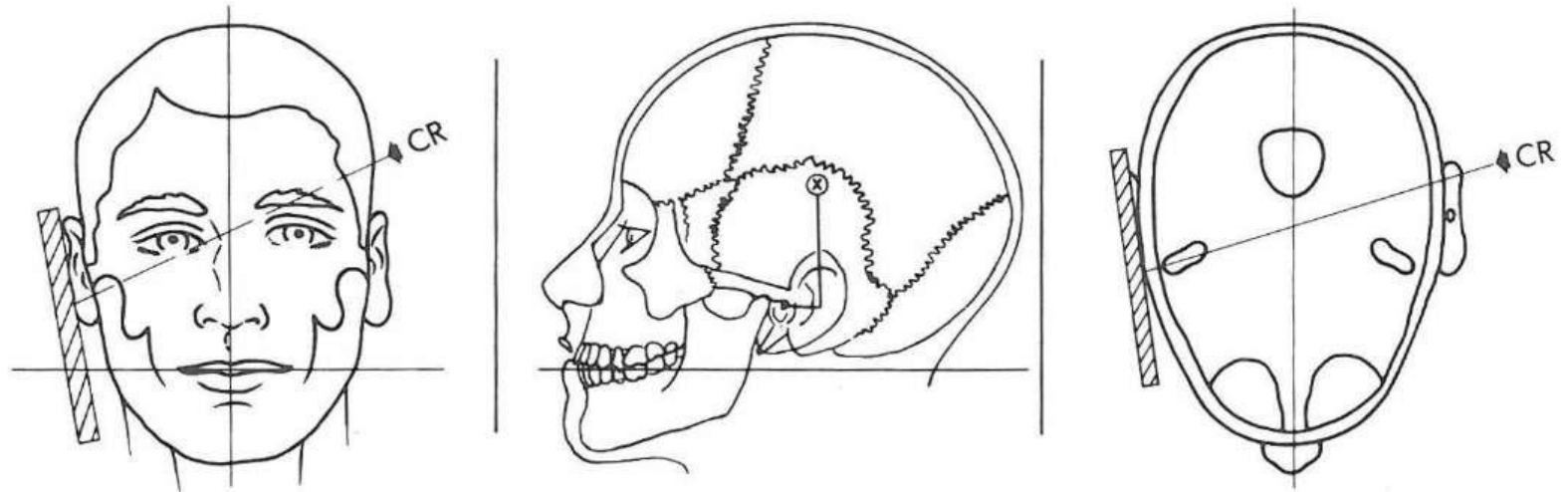


# TMJ- transcranial view

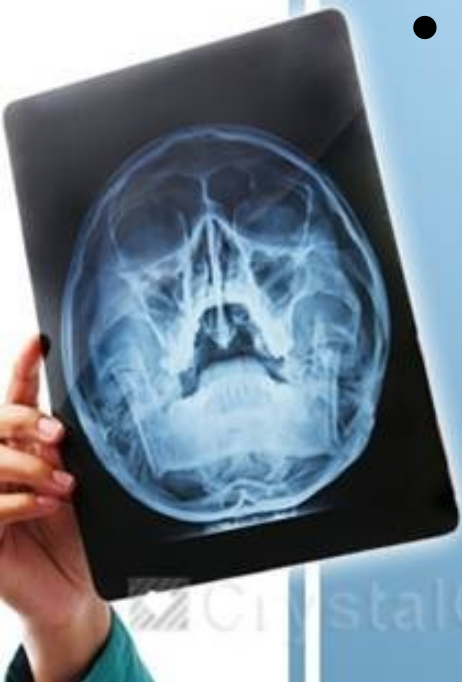- The cassette is placed flat against the patient's ear and centered over the TM- joint of interest, against the facial skin parallel to the sagittal plane.
- The patient's head is adjusted so that the sagittal plane is vertical.
- The ala-tragus line is parallel to the floor.
- This view is taken with both open and closed position.

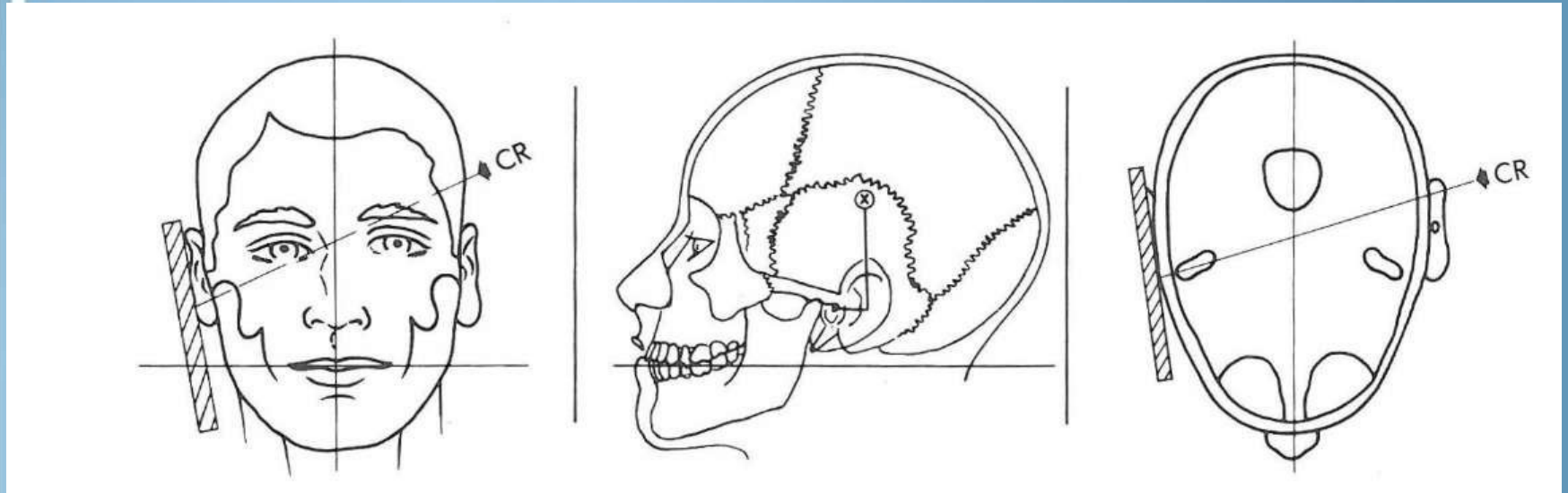






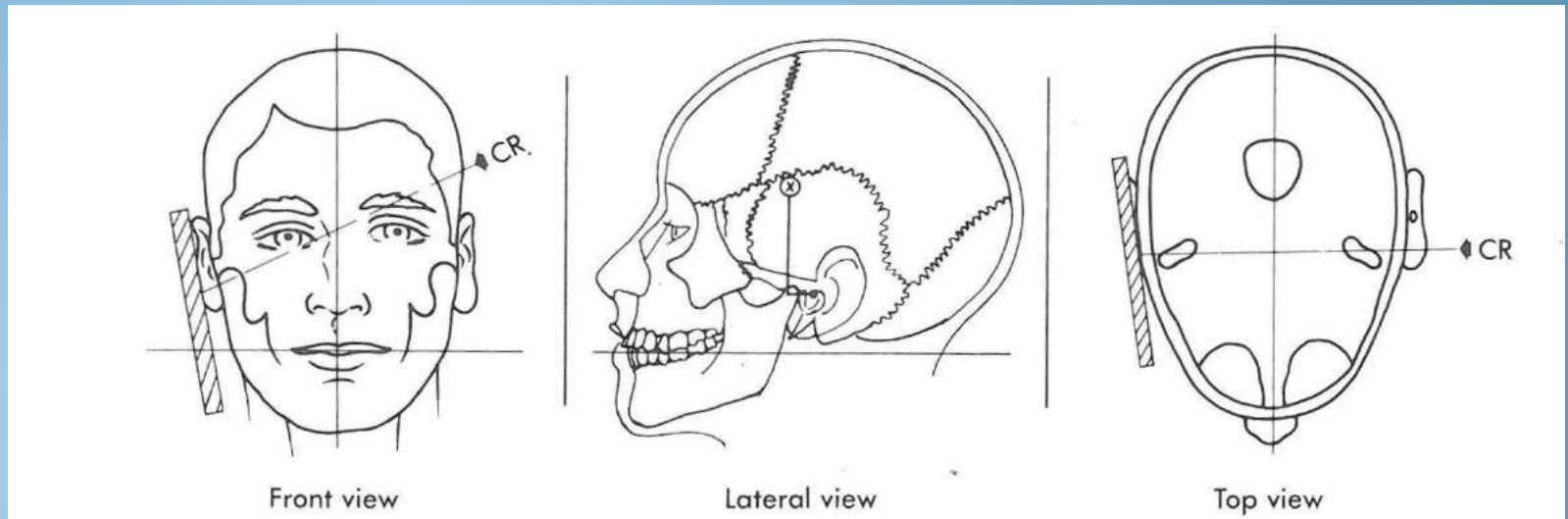
- In Lindblom technic (1936), central ray entered half inch behind and 2 inches above external auditory meatus.





- In Grewcock technic (1953), central ray entry point is 2 inches above external auditory meatus perpendicular to occlusal plane





- In Gillis technic (1939), central ray entry point is 1/2 inch in front and 2 inches above external auditory meatus parallel and perpendicular to occlusal plane.





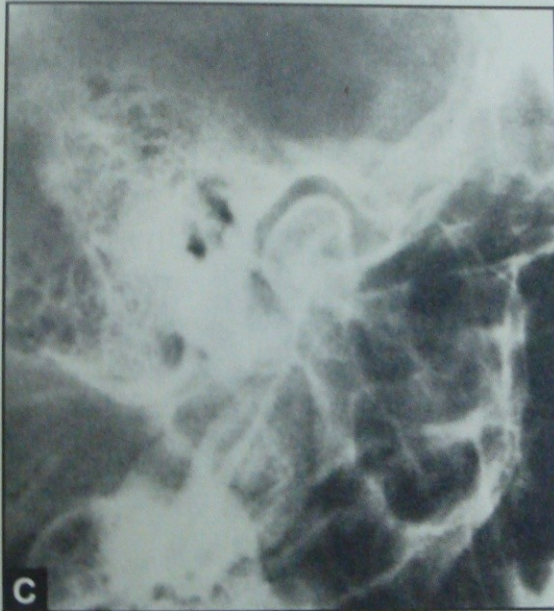

Fig. 12.14C: Transcranial view mouth closed position

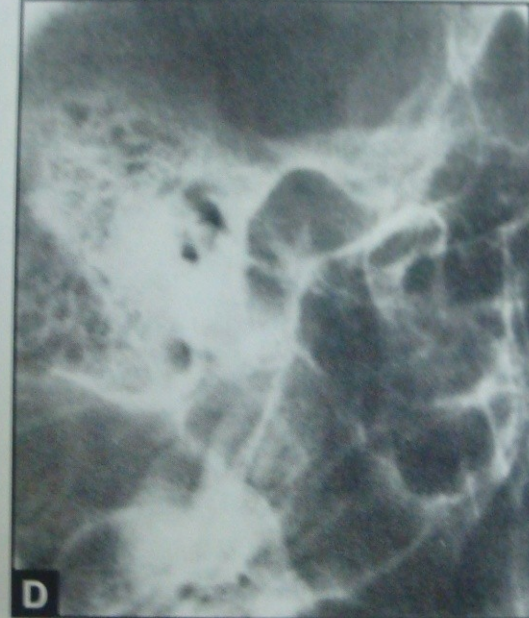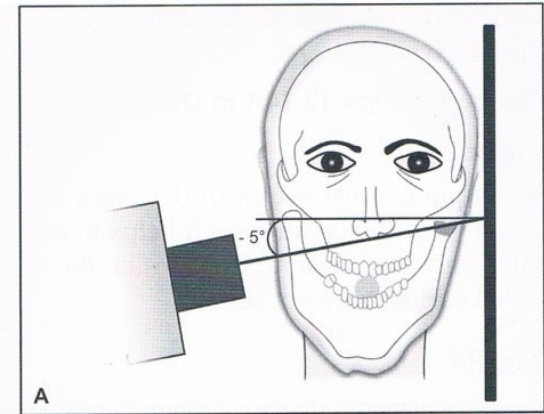


Fig. 12.14D: Transcranial view mouth open position

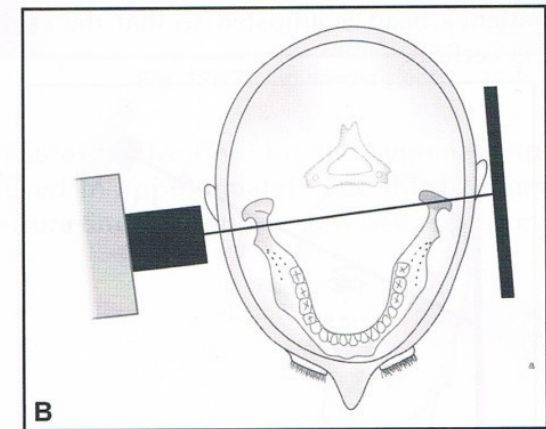
It depicts the lateral aspect of the TMJ.  
It helps to evaluate the joint's bony relationship.  
Detecting arthritic changes on the articular surfaces.

# TMJ- transpharyngeal view

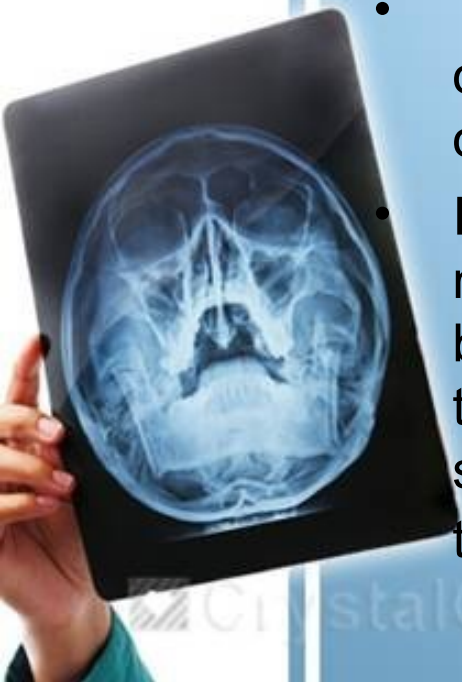- The cassette is placed flat against the patient's ear, over the TM joint of interest, against the facial skin parallel to the sagittal plane.
- The patient is positioned so that the sagittal plane is vertical and parallel to the film. The patient is instructed to slowly inhale through the nose during exposure.
- The patient should open mouth
- The central ray is directed from the opposite side cranially, at an angle of -5 to -10 degrees posteriorly.
- It is directed through the mandibular notch, that is a window between the coronoid, condyle and the zygomatic arch, of opposite side below the base of the skull to the TM joint of interest.



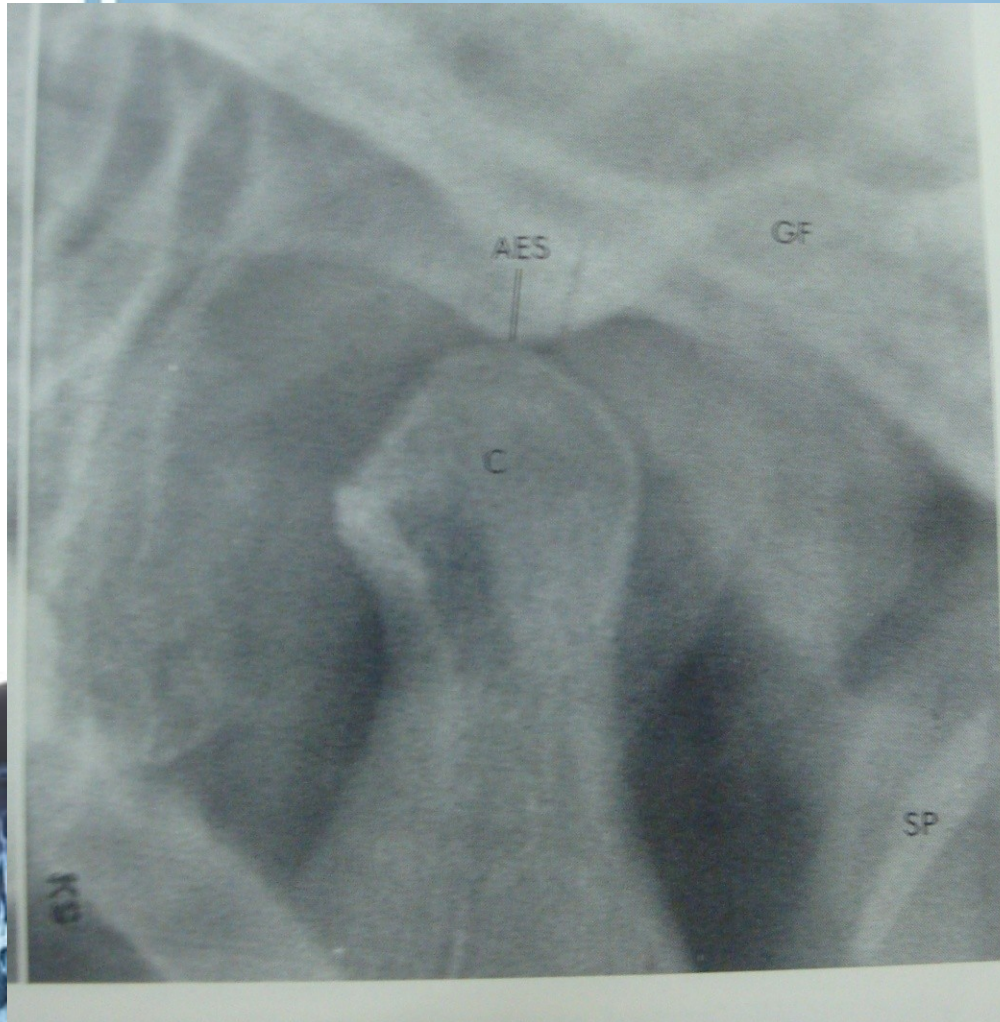
**Fig. 12.15A:** Transpharyngeal projection. The central ray is oriented superiorly 5° to 10° and posteriorly approximately 10°, centered over the TMJ of interest. The mandible is positioned at maximal opening



**Fig. 12.15B:** Transpharyngeal projection, showing positioning from above, showing the X-ray beam aimed slightly posteriorly across the pharynx





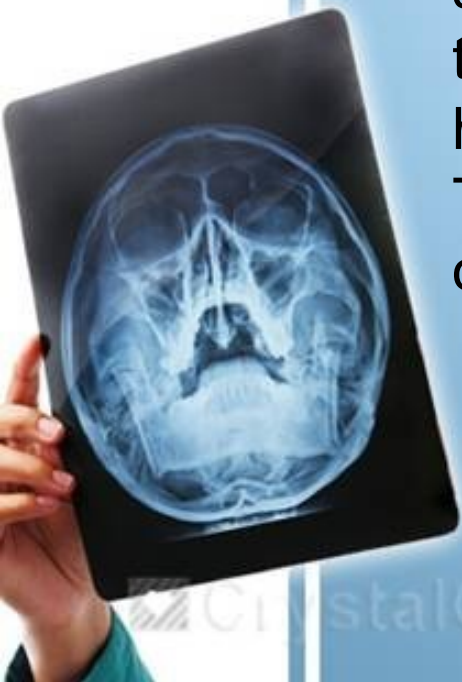

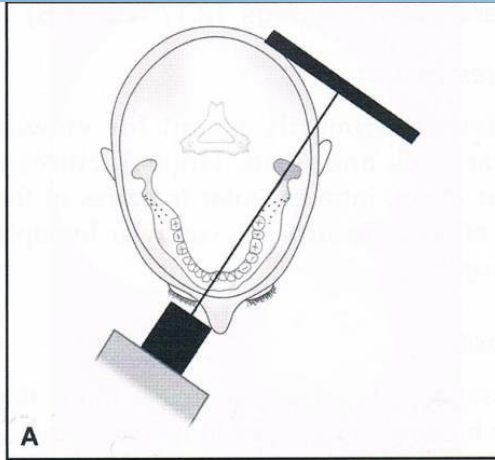
- It is a lateral projection showing medial aspect of condylar head and neck.



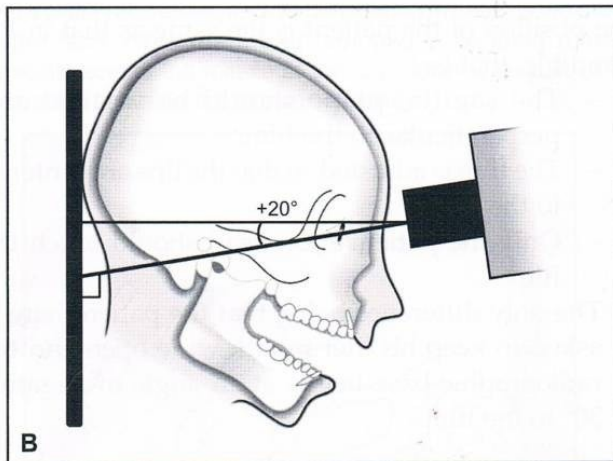
# TMJ- transorbital view

- The film behind the patient's head at an angle of 45 degrees to the sagittal plane.
- The patient is positioned so that the sagittal plane is vertical.
- The canthomeatal line should be 10 degrees to the horizontal, with the head tipped downwards. The mouth should be wide open.
- The tube head is placed in front of patient's face.
- The central ray is directed to the joint of interest, at an angle of +20 degrees, to strike the cassette at right angles.
- The point of entry may be taken at:
  - Pupil of the same eye, asking the patient to look straight ahead.
  - Medial canthus of the same eye
  - Medial canthus of the opposite eye

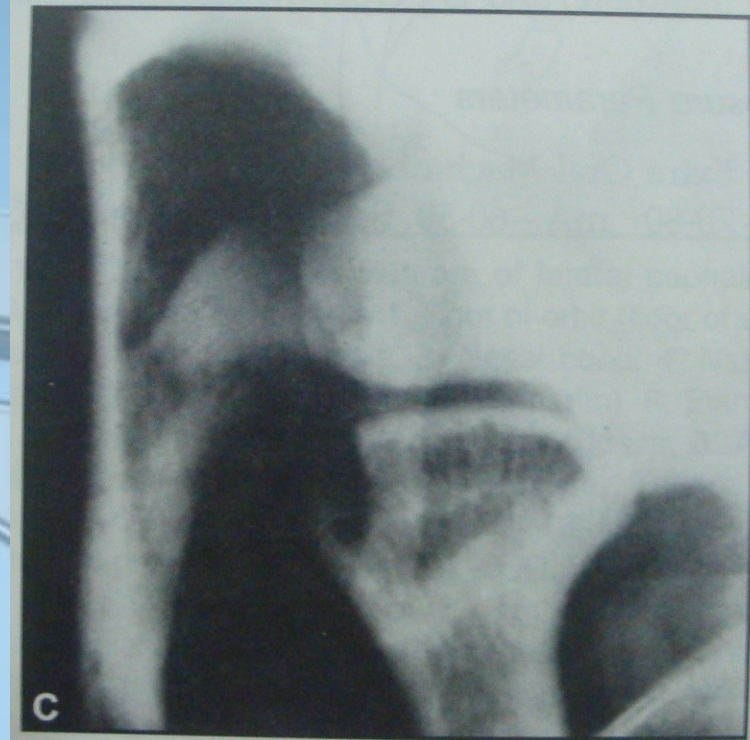




**Fig. 12.16A:** Transorbital projection, the central ray is oriented downward approximately  $20^\circ$  and laterally approximately  $30^\circ$  through the contralateral orbit, centered over the TMJ of interest



**Fig. 12.16B:** Transorbital projection, positioning from above, showing the cassette behind the condyle and X-ray beam aimed across the orbit



**Fig. 12.16C:** Transorbital view

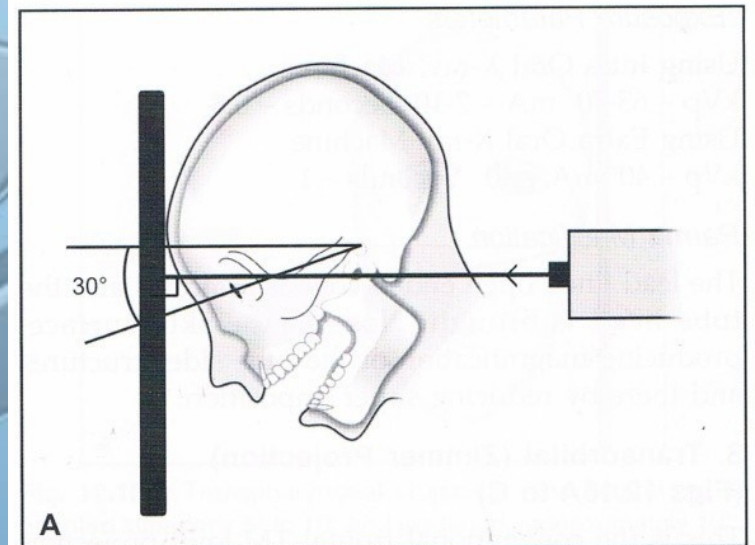
The anterior view of the temporomandibular joint  
 Medial displacement of fractured condyle  
 Fracture of neck of condyle



# Reverse Towne's view

- The image receptor is placed in front of the patient, perpendicular to the midsagittal and parallel to the coronal plane.
- The patient's head is tilted downward so that the canthomeatal line forms a 25 to 30 degree angle with the image receptor.
- To improve visualization of the condyles, the patient's mouth is opened so that the condylar heads are located inferior to the articular eminence.

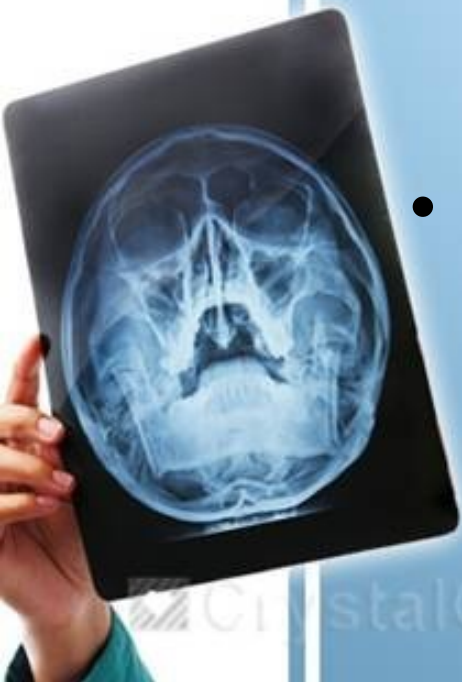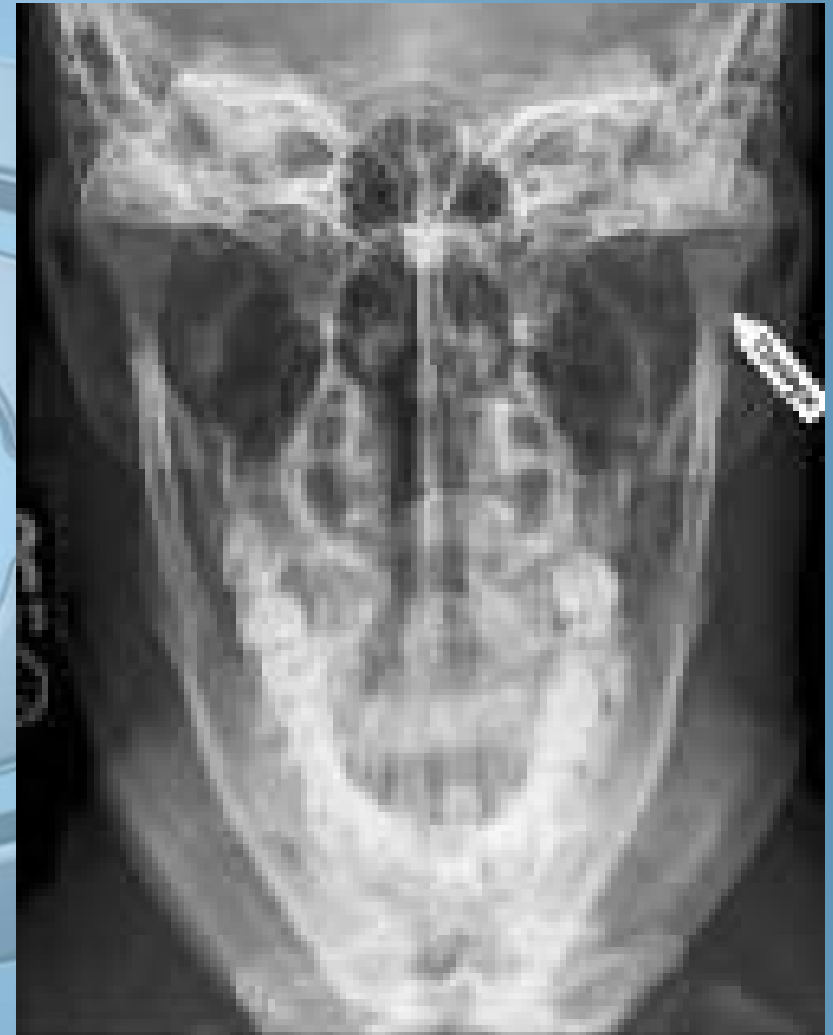The central beam is perpendicular to the image receptor and parallel to patient's midsagittal plane and it is centered at the level of the condyles.



**Fig. 12.17A:** Diagram for the positioning of Reverse Towne's projection, the radiographic base line is 30° to the film and the X-ray is directed at perpendicular to the film



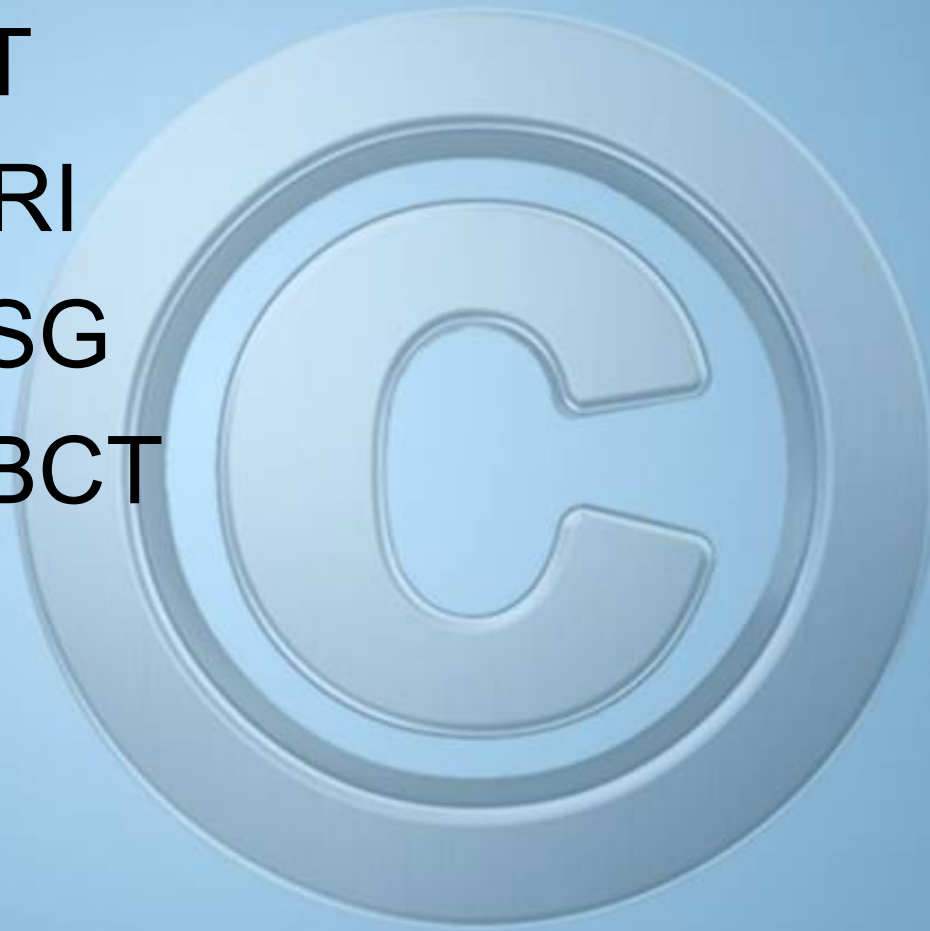- Condylar neck and head
- High fractures of condylar neck, intracapsular fractures of the TMJ
- Condylar hypoplasia or hypertrophy



- **OTHER IMAGING MODALITIES**



- CT
- MRI
- USG
- CBCT



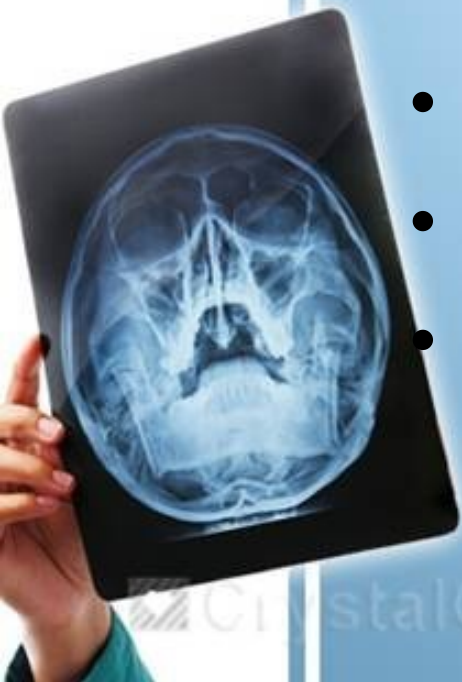

# COMPUTED TOMOGRAPHY

## Indications-

The diagnosis and extent of

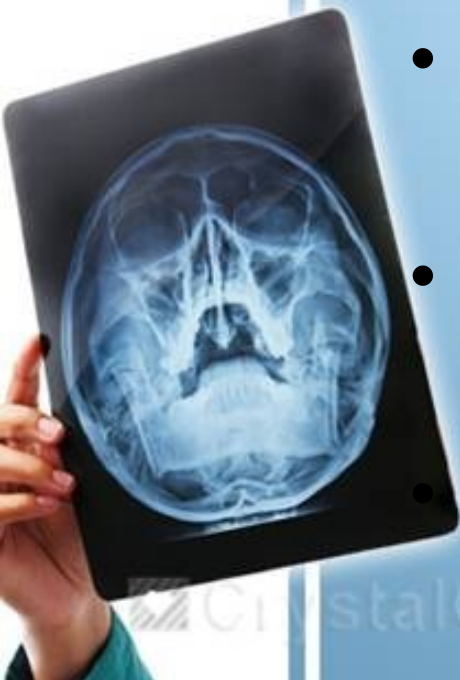- Variety of infections
- Osteomyelitis
- Cysts
- Benign and malignant tumors
- Trauma in the maxillofacial region
- Lesions involving the bone
- 3D CT has been applied to trauma and craniofacial reconstructive surgery and used for treatment of congenital and acquired deformities.



# MRI

## Indications-

- To evaluate the position and integrity of the disk in the TMJ.
- Neoplasia involving the soft tissues, such as tongue, cheek, salivary glands, and neck.
- Determining malignant involvement of lymphnodes.
- Determining perineural invasion by malignant neoplasms.
- With contrast, enhances the image resolution of neoplasia.

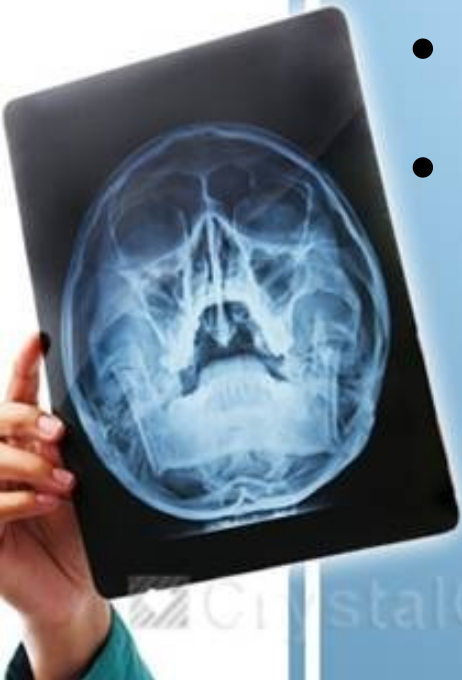

# ULTRASONOGRAPHY

## Indications-

For the evaluation of

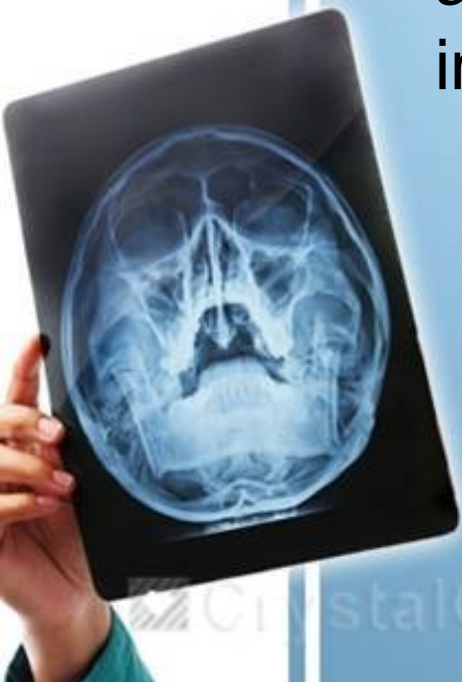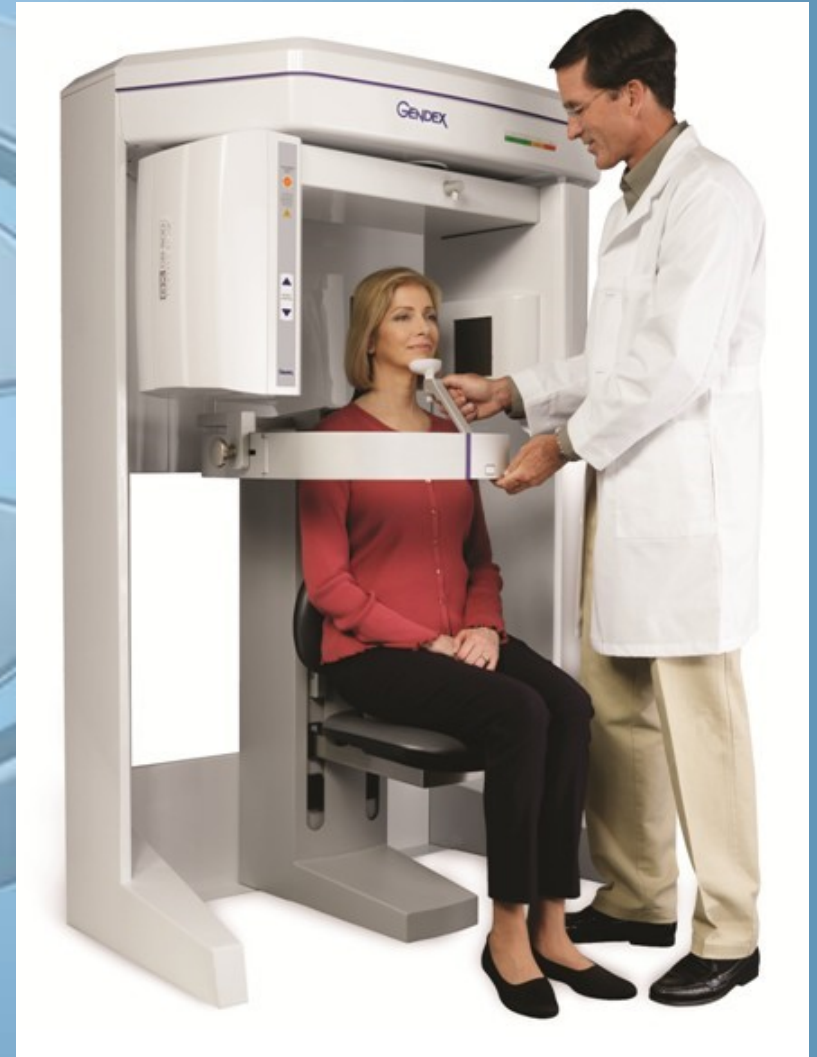- Neoplasms in the thyroid, parathyroid or salivary glands or lymph nodes.
- Stones in salivary glands or ducts
- Vessels of neck
- To guide fine-needle aspiration in the neck





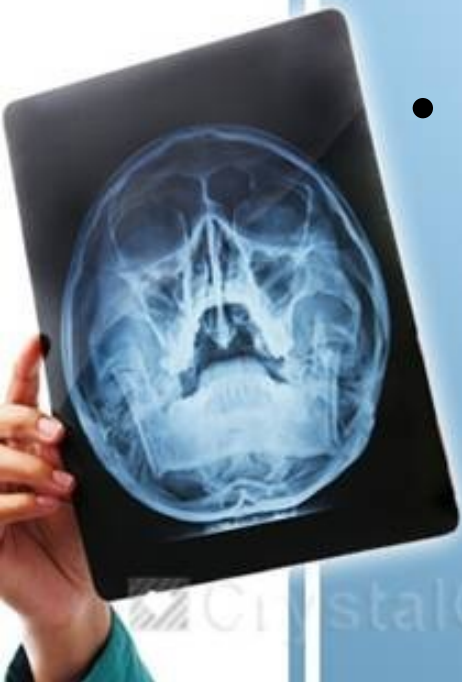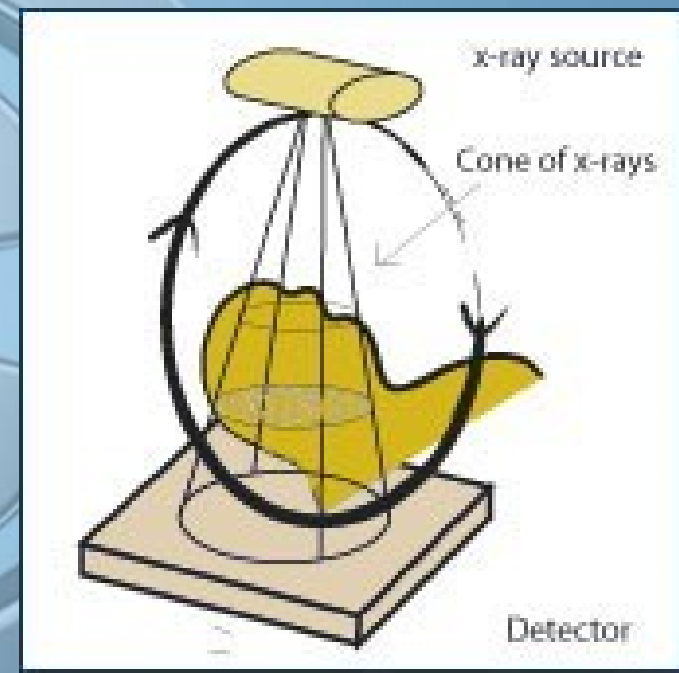
# CONE-BEAM COMPUTED TOMOGRAPHY

- Cone-beam computed tomography (CBCT) is a recent technology initially developed for angiography in 1982 and subsequently applied to maxillofacial imaging.



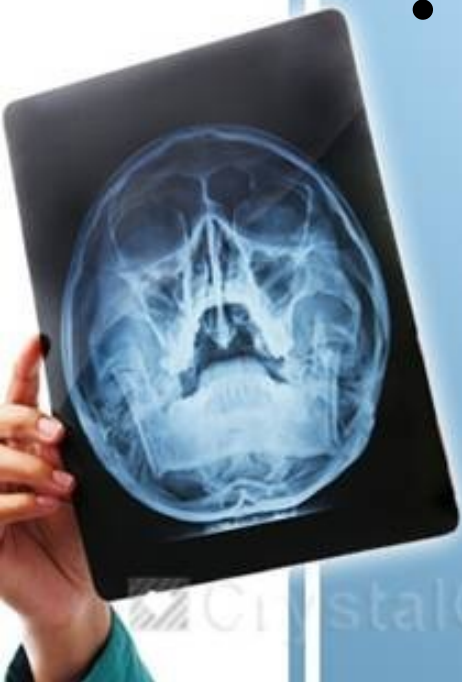It constitutes of

- Two-dimensional digital array providing an area detector fixed on a rotating gantry
- A three-dimensional (3D) cone shaped x-ray beam



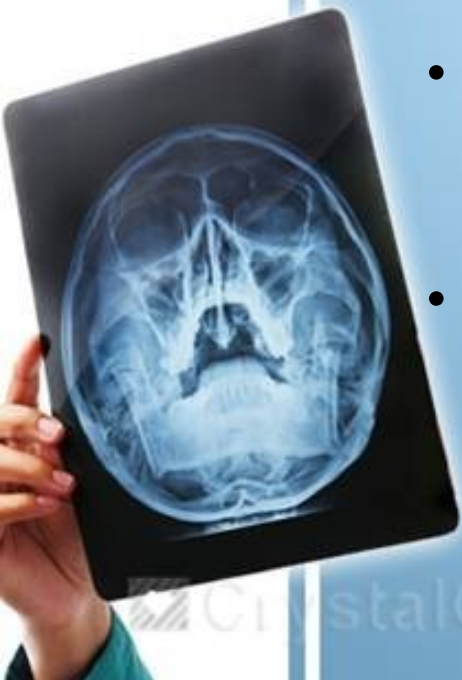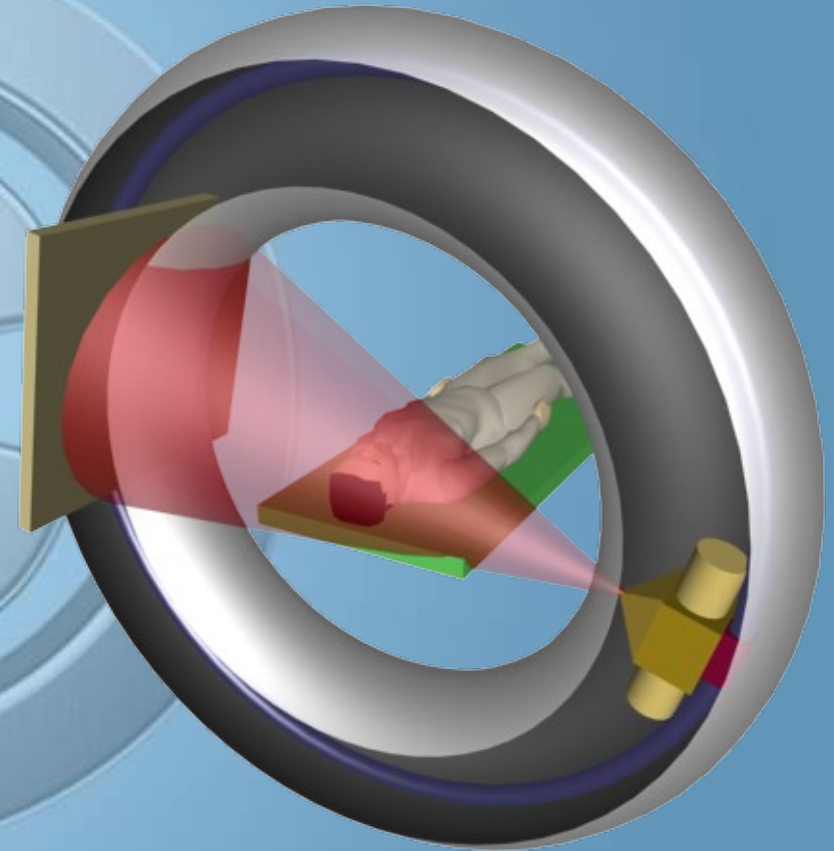
## PRINCIPLE-

- Cone-beam scanners use a two-dimensional digital array providing an area detector rather than a linear detector as CT does.
- This is combined with a three-dimensional (3D) x-ray beam with circular collimation so that the resultant beam is in the shape of a cone, hence the name "cone beam."



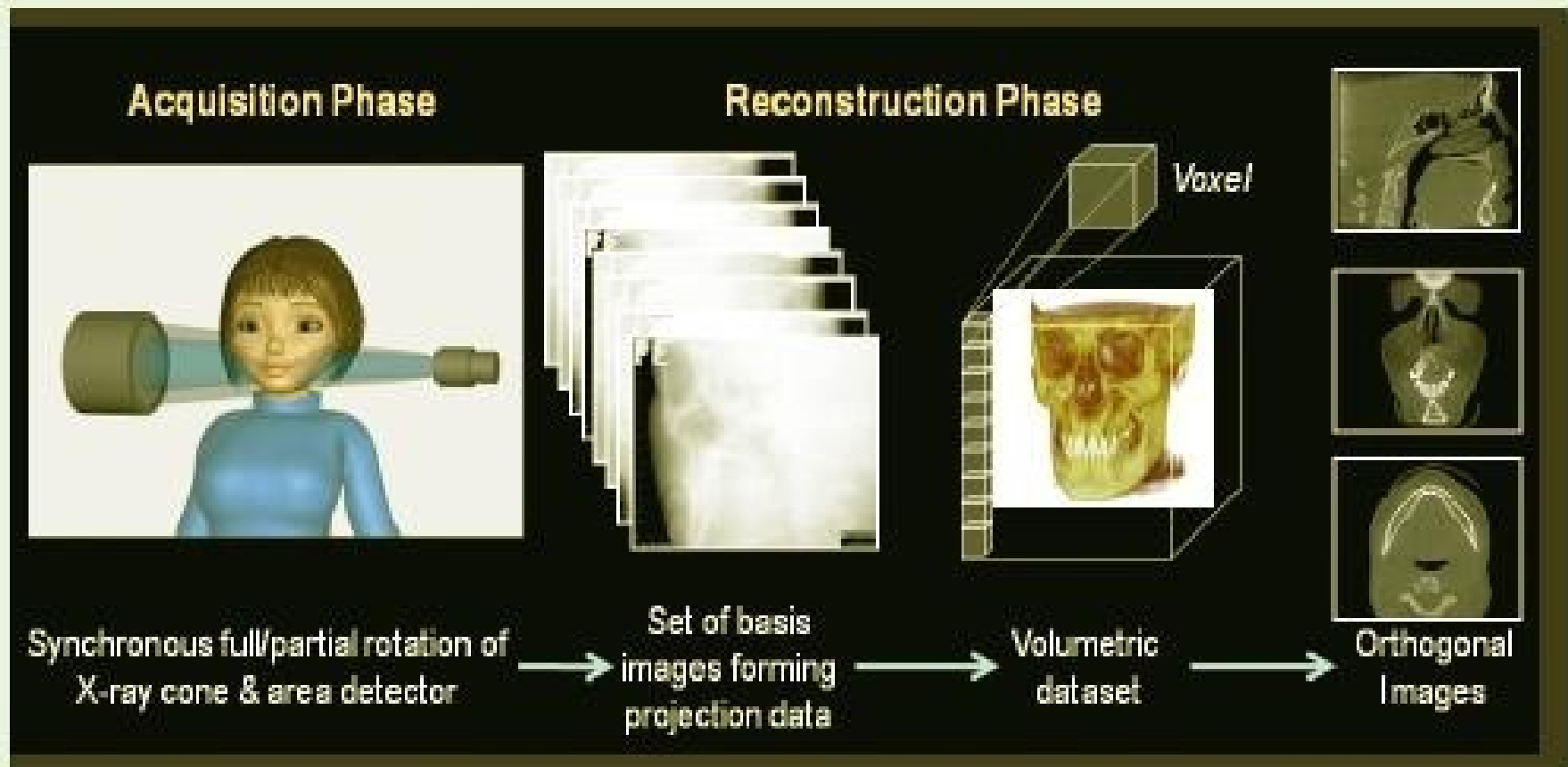


- Because the exposure incorporates the entire region of interest (ROI), only one rotational scan of the gantry is necessary to acquire enough data for image reconstruction.
- CBCT produces an entire volumetric dataset from which the voxels are extracted.
- Voxel dimensions are dependent on the pixel size on the area detector.
- Therefore CBCT units in general provide voxel resolutions that are isotropic-equal in all three dimensions.



# How the image acquisition occurs?

FIGURE 1: THE MECHANICS OF CBCT ACQUISITION



Multiple basis projections form the projection data from which orthogonal planar images are secondarily reconstructed in cone beam geometry.

- **End Result**

- 3-D visualization of the oral and maxillofacial complex from any plane
- A stack of 360 images or exposures compiled into a volumetric dataset through a computer process known as primary reconstruction
- This data volume is then converted into a patient-study by accompanying software
- Can be visualized as
  - 2D trans-axial, multi-planar reformatted
  - 3D techniques such as surface reconstruction and volume rendering
  - A combination of 2D and 3D techniques





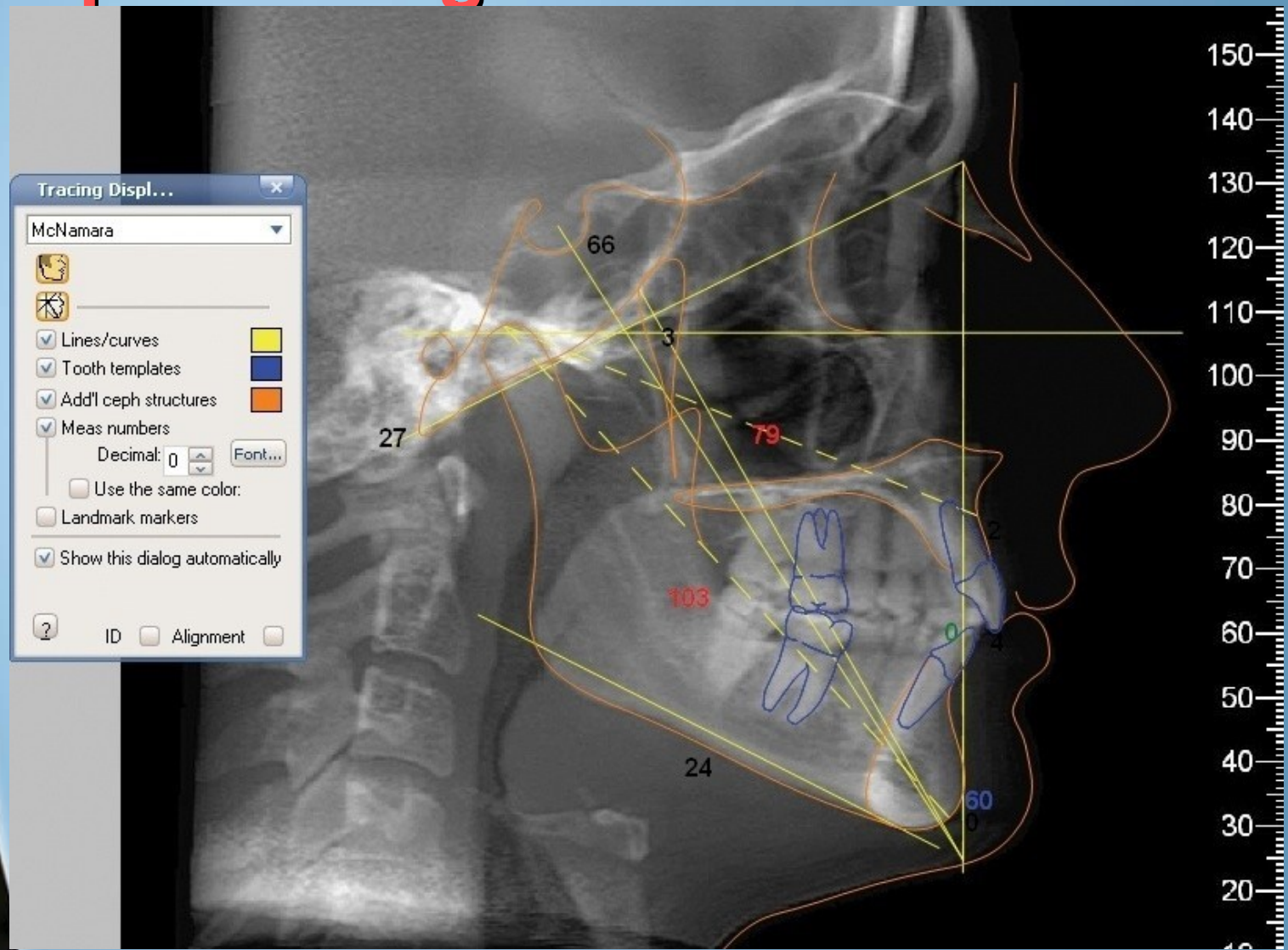
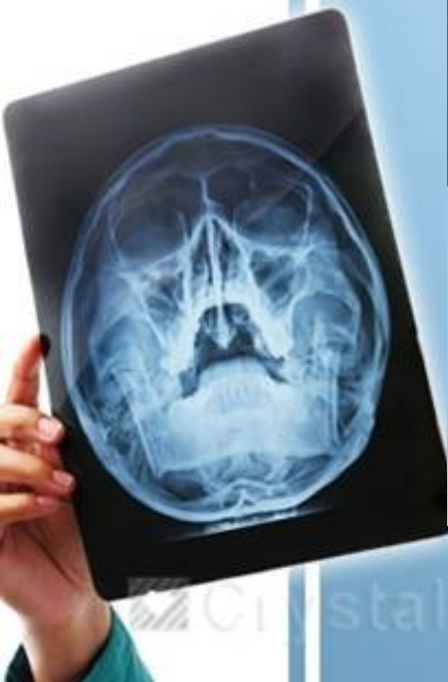# APPLICATIONS

- Orthodontic treatment planning
- Dental implants
- Temporomandibular joints for osseous degenerative changes
- Evaluation of wisdom teeth vs. mandibular nerve
- Endodontic assessment
- Assessment of impacted teeth, fractured teeth and jaws, periapical infections and periodontal diseases.
- Benign calcifications (tonsilloliths, lymph nodes, salivary gland stones) can also be identified)



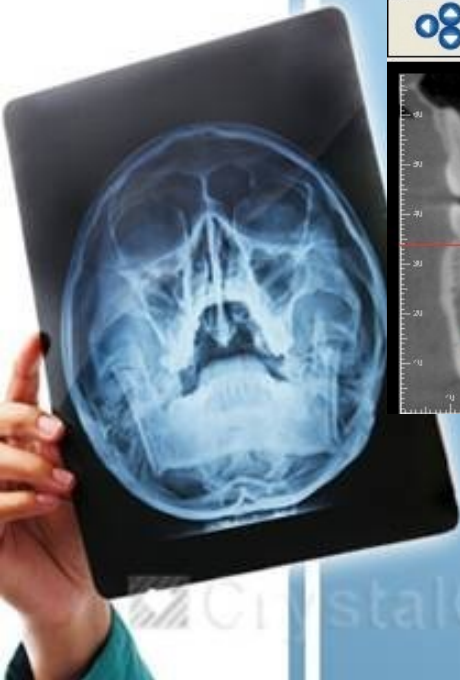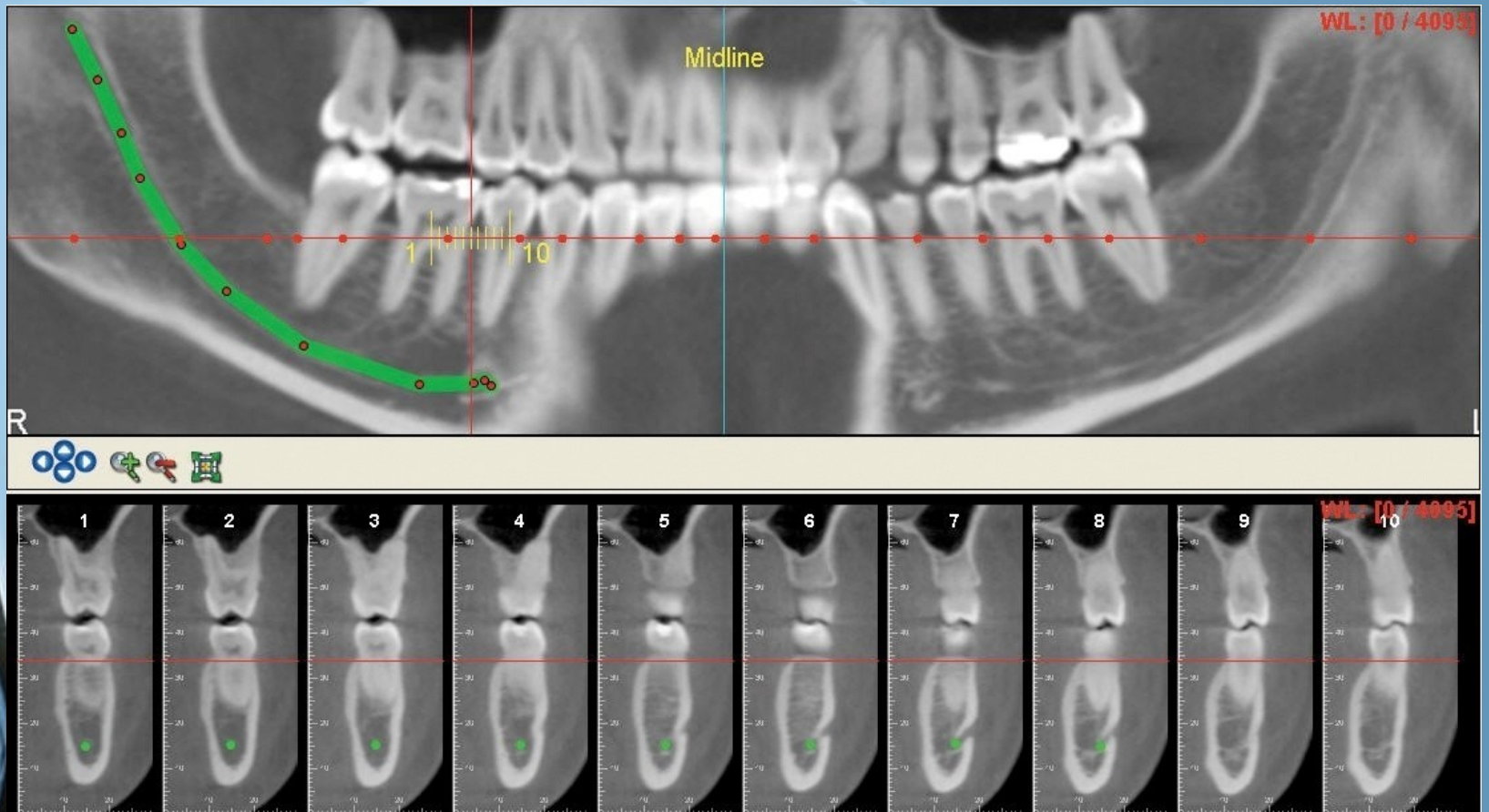
# C B C T - ORTHO

## Ceph Tracing



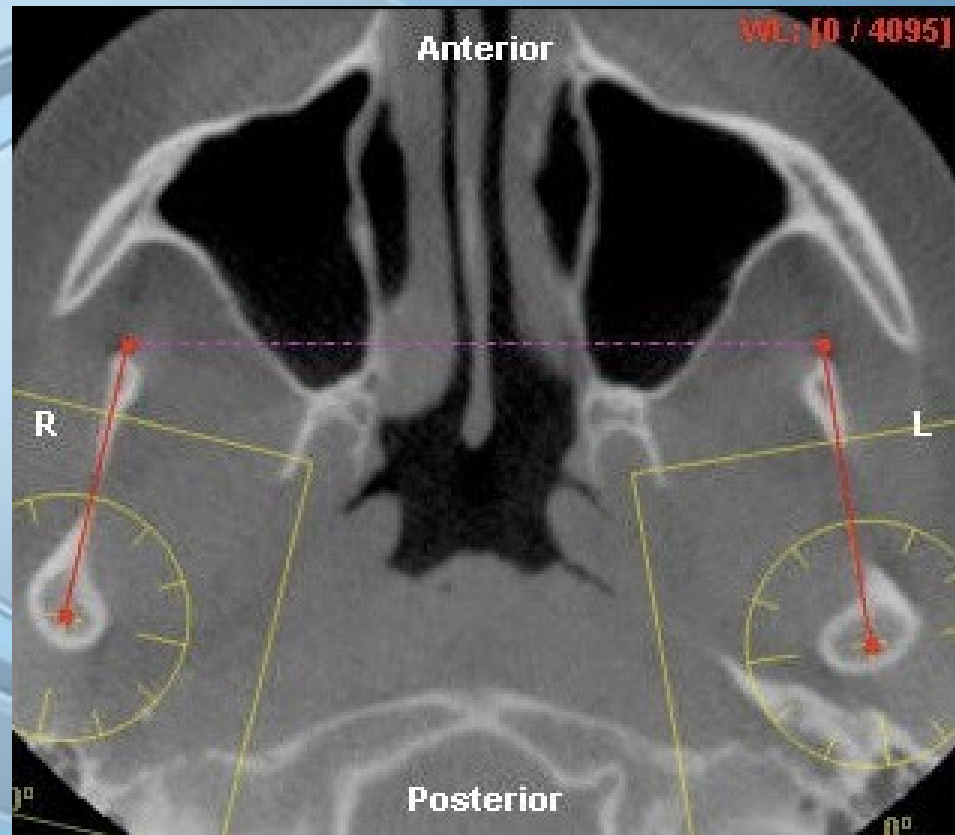
# C B C T

## Nerve Mapping



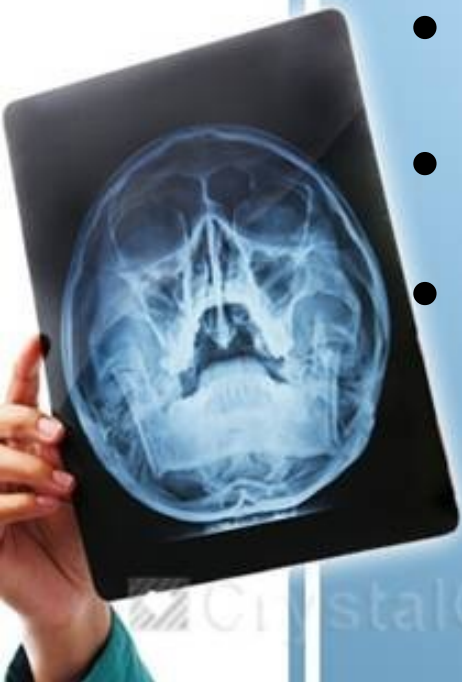

# CBCT TMJ view



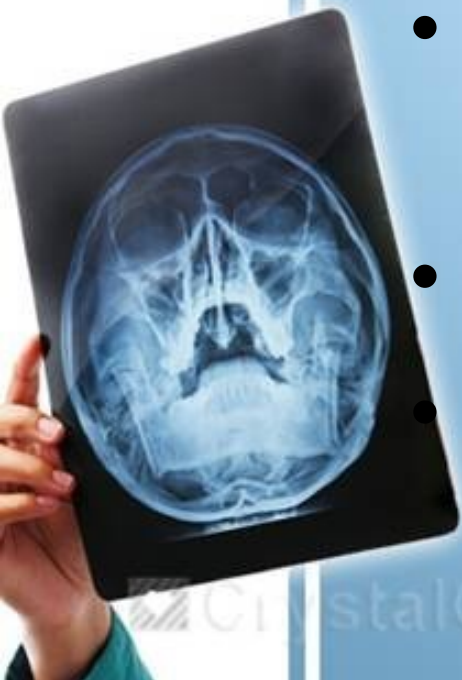## ADVANTAGES-

- Lower dose than helical
- Compact design
- Superior images to Panoramic
- Low cost
- Low heat load
- High speed scanning (less than 30 secs)



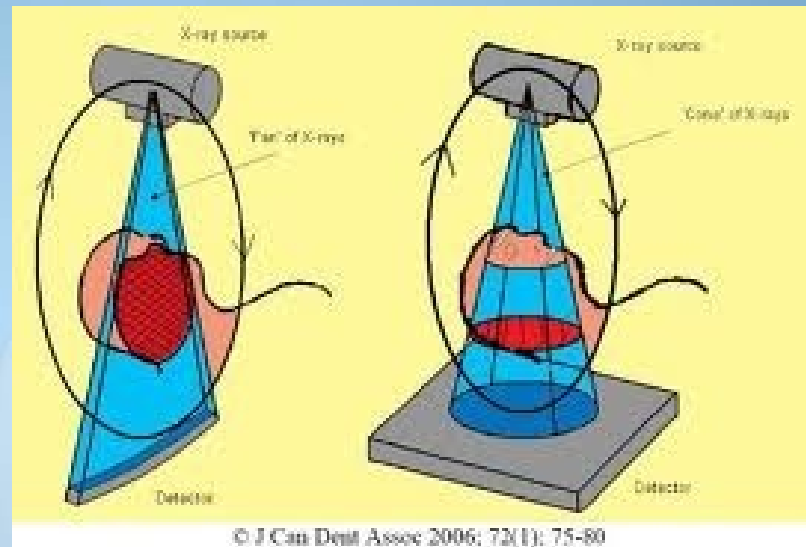
## DISADVANTAGES-

- Worse low contrast detectability
- Poor soft tissue contrast
- Long scan times = motion artifacts
- Slightly Inferior quality to conventional CT
- Image noise
- Metal artifacts





# C B C T versus Medical C T

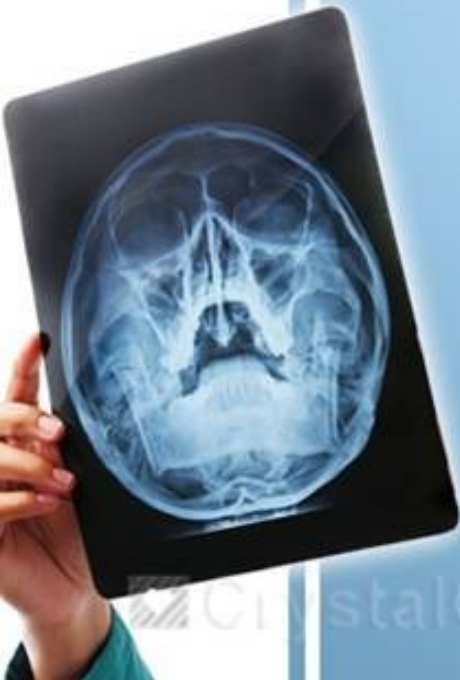

- Med CT
  - Conventional linear fan beam
  - Single row or a series (4, 8, 12, 32, 64) of solid state detectors
  - Provides a set of consecutive slices of the patient
- CBCT
  - Cone beam
  - Square 2 dimensional array of detectors
  - Provides a volume of data

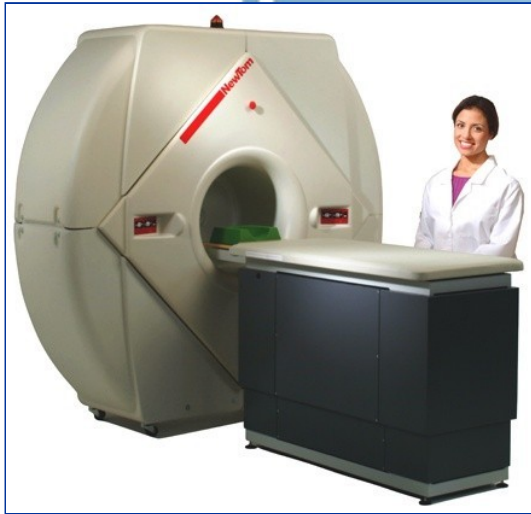

# C B C T versus Medical C T

- Med CT
  - Greater contrast resolution
    - More discrimination between different tissue types (i.e. bone, teeth, and soft tissue)
- CBCT
  - Equipment
    - Cost 3-5x less than MDCT
    - Lighter & Smaller
    - No special electrical
    - No floor strengthening
    - No special cooling
  - Ease of operation
  - Dedicated to dental
  - Patient sits or stands
  - Both jaws can be imaged at the same time
  - Lower radiation burden



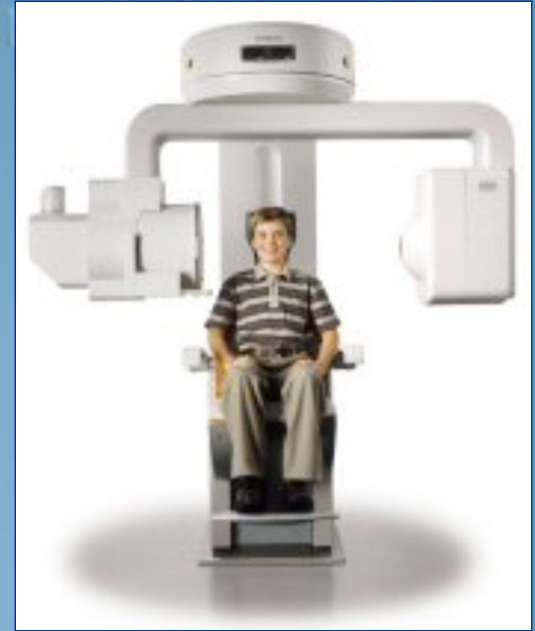## VARIOUS CBCT UNITS



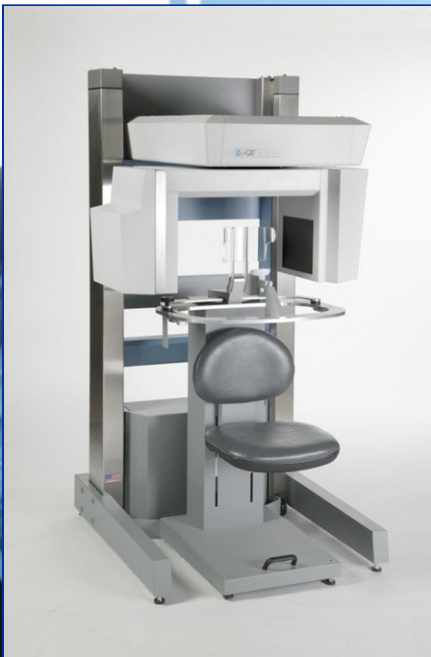
NewTom 3G by AFP



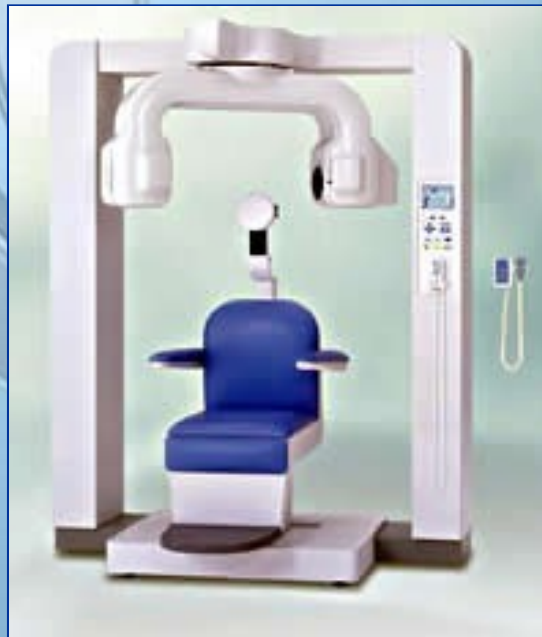Galileos by Sirona



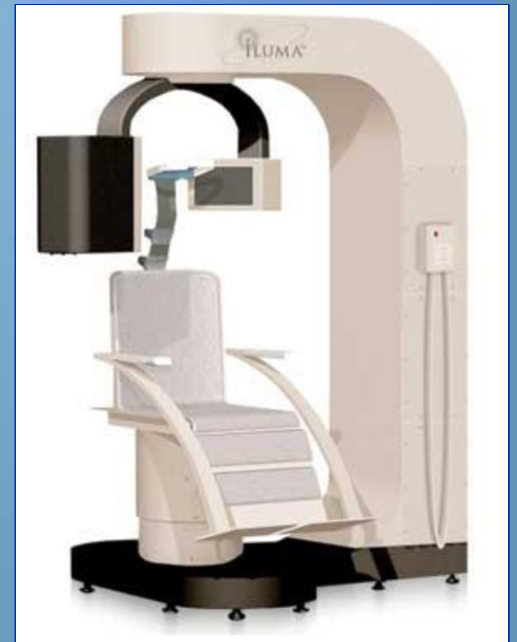MercuryRay by Hitachi



I-CAT by ISI



3D Accuitomo  
by J. Morita



Iluma by IMTEC



**THANK YOU**

