

Eyelids and lacrimal system

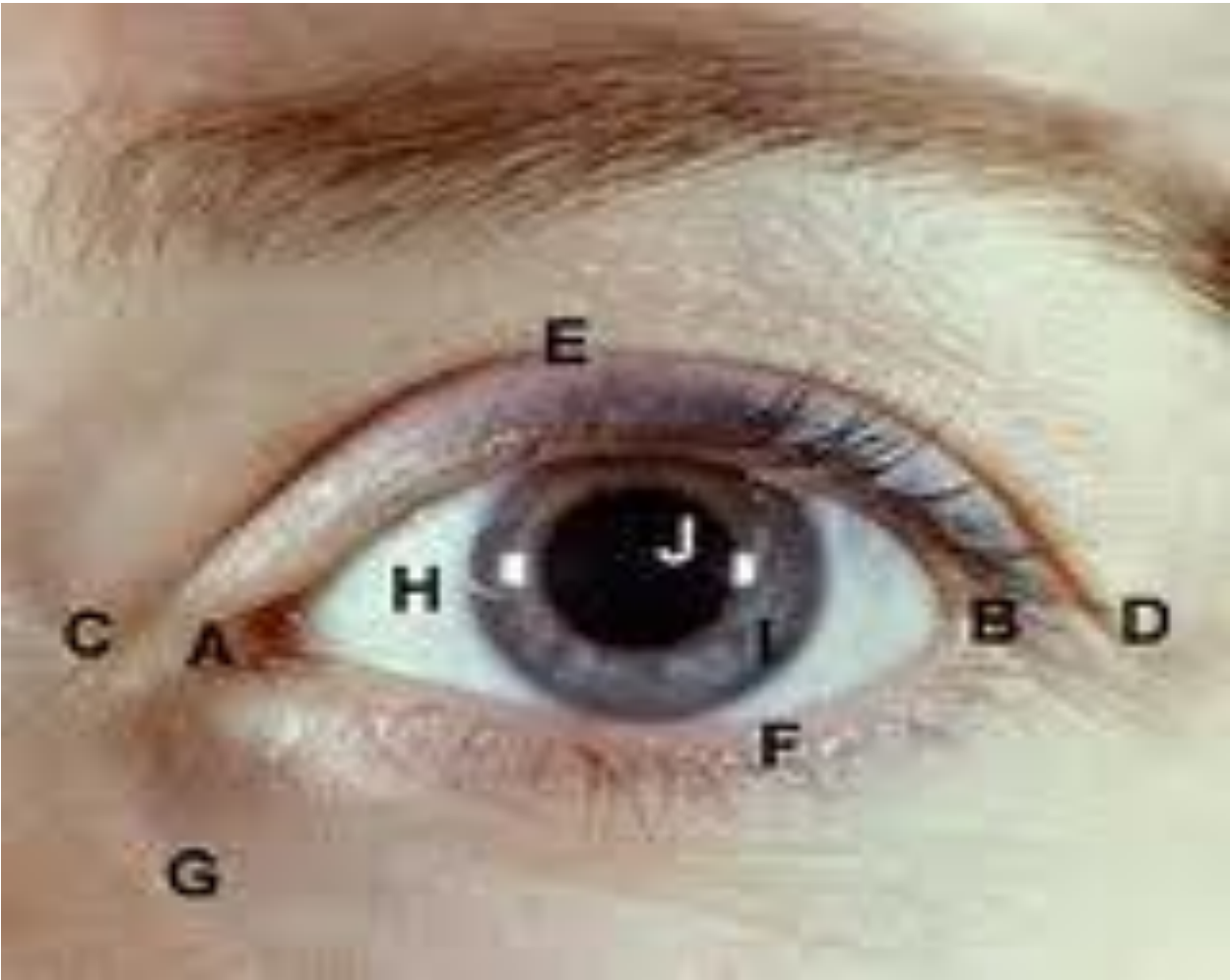Sourav

Eyelids-functions

- Lid, lashes and eyebrow (with bony orbit)
—————> primary protection mechanism for the globe from the external environment.

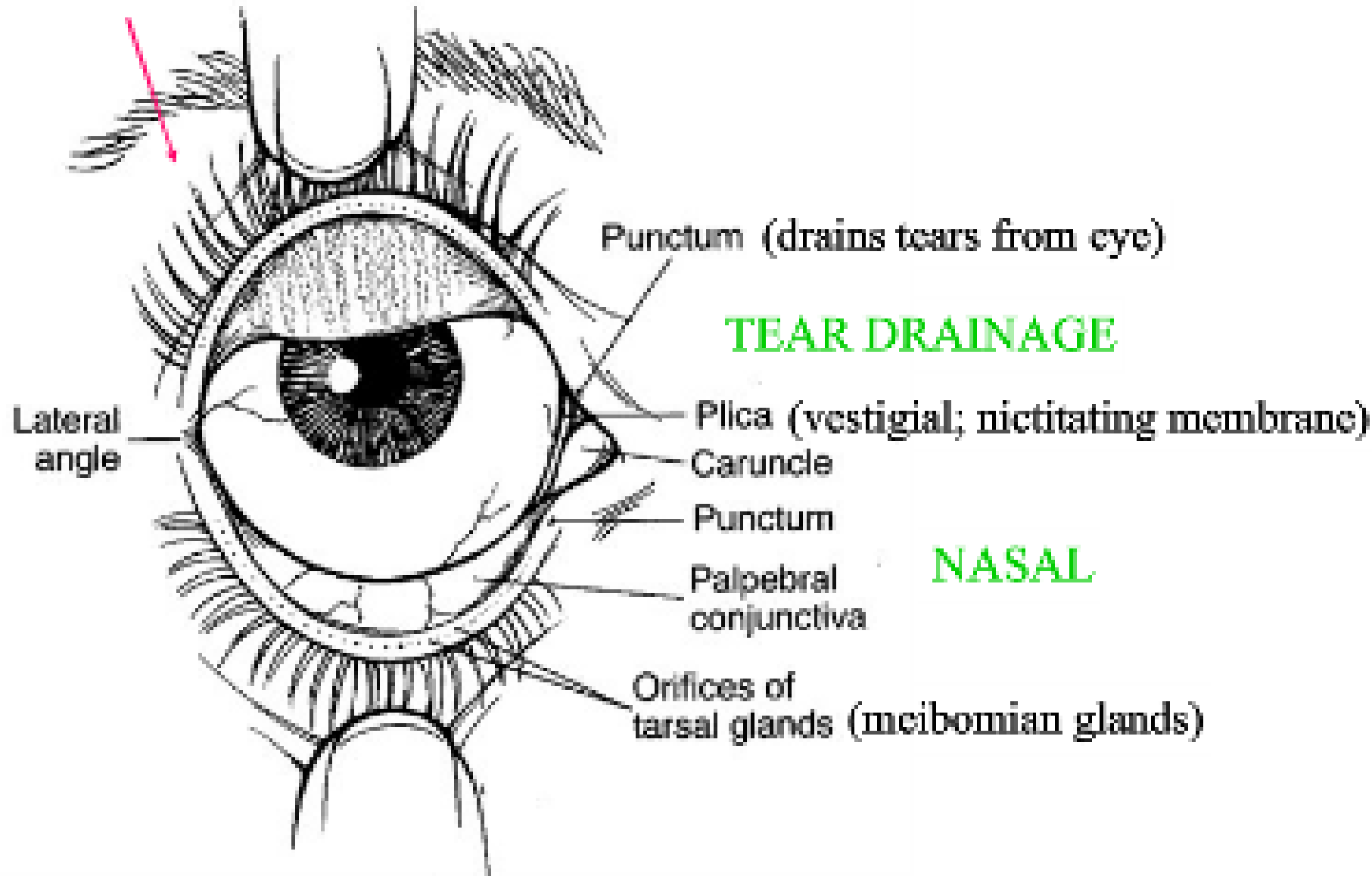
Eyelids-functions

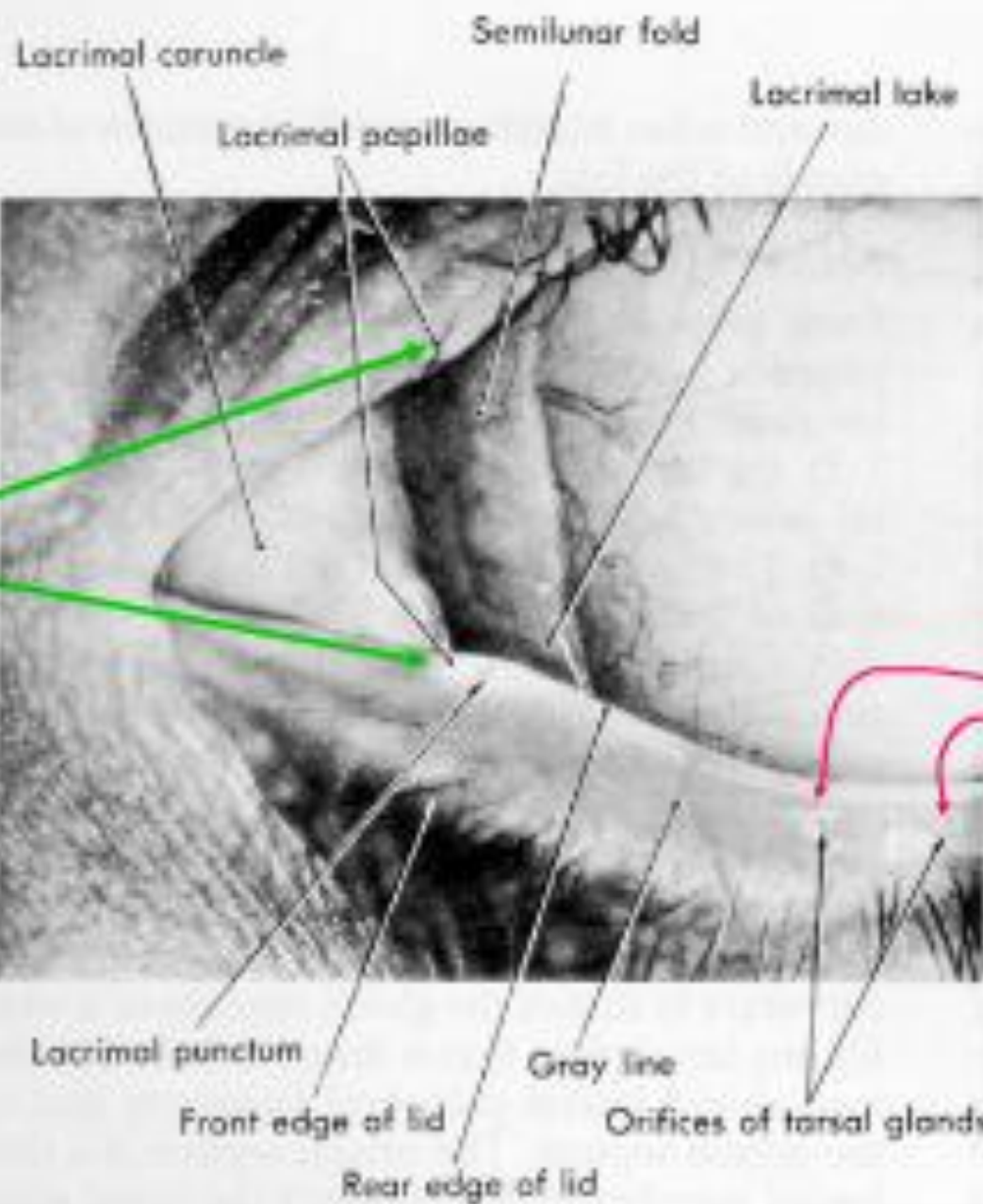
- Eyelids provides both physical and physiological protection of the eye
- Several tear film components are provided by glands in the eyelids
- Blinking resurfaces and replenishes the precorneal tear film
- Eyelids actively excrete the tears via the lacrimal pump



Eyelid Gross Anatomy

**TEAR
SECRETION**

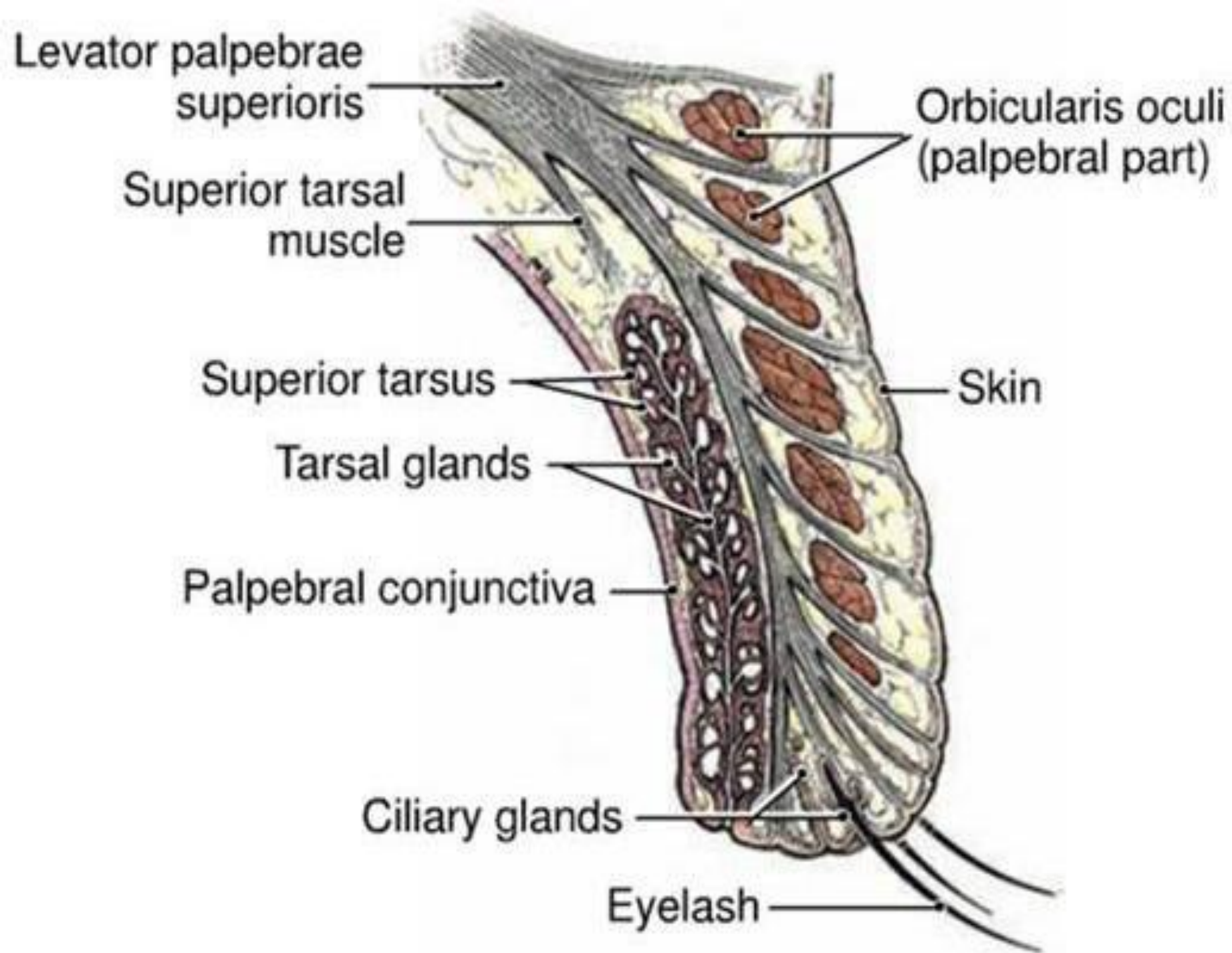




**TEAR
DRAINAGE
PUNCTA**

NASAL

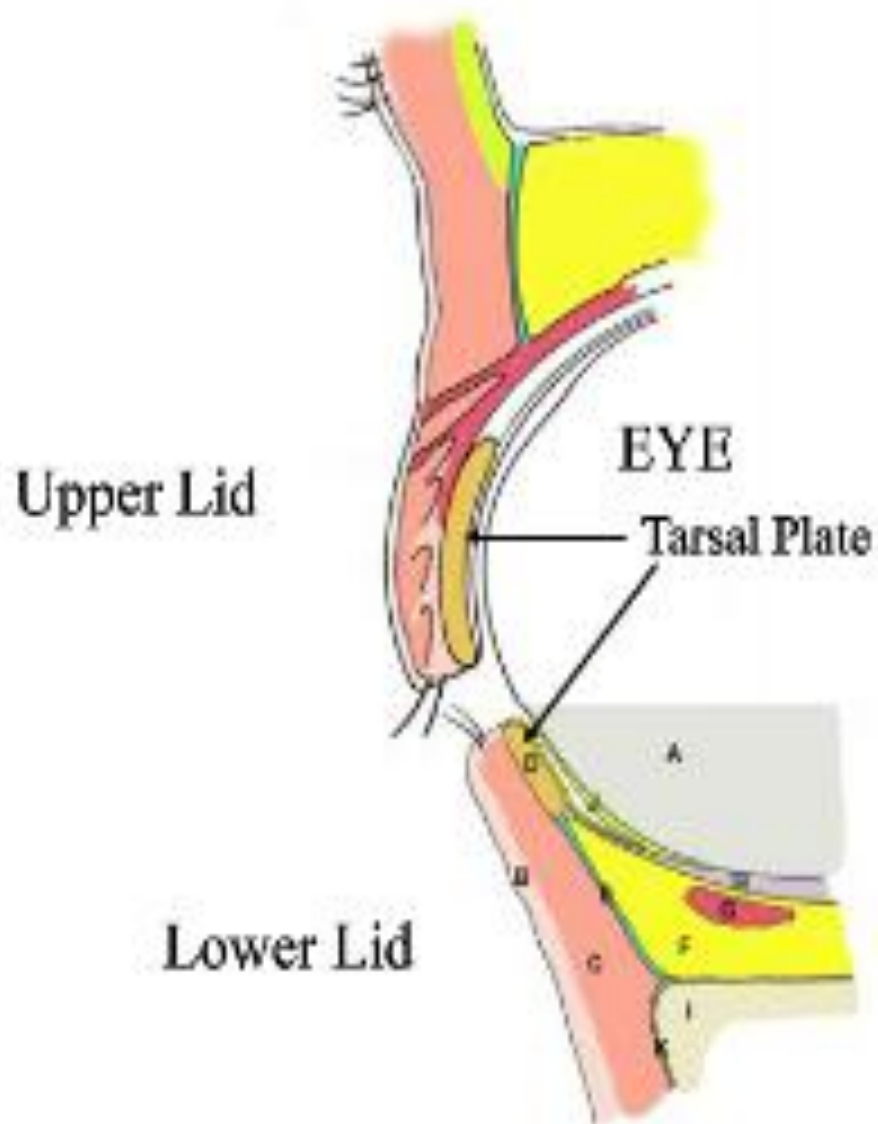
**MEIBOMIAN
SECRETION**



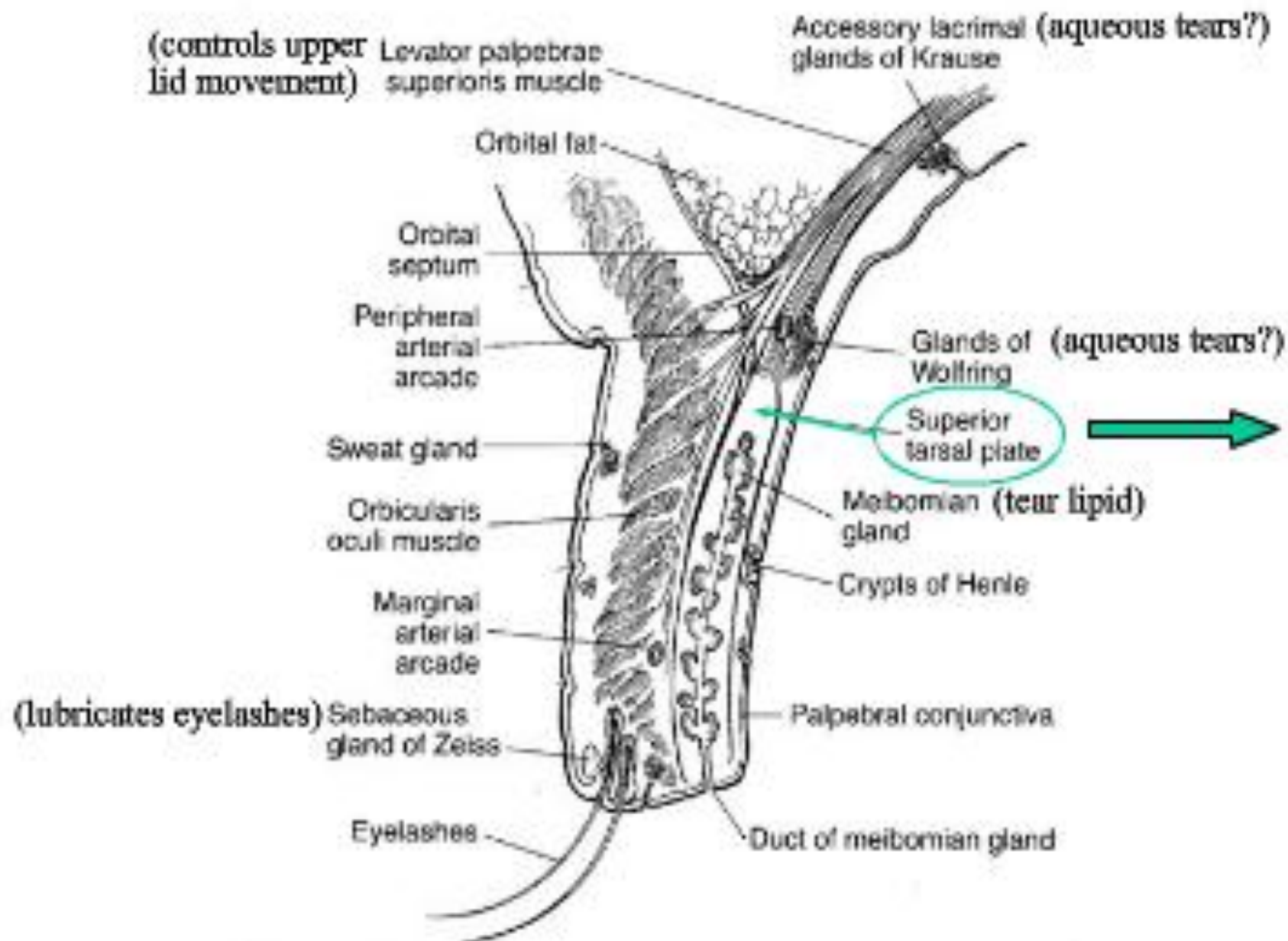
MUSCLES OF THE EYELID

- *Levator palpebrae superioris*
- Muller's muscle
- *Orbicularis oculi*

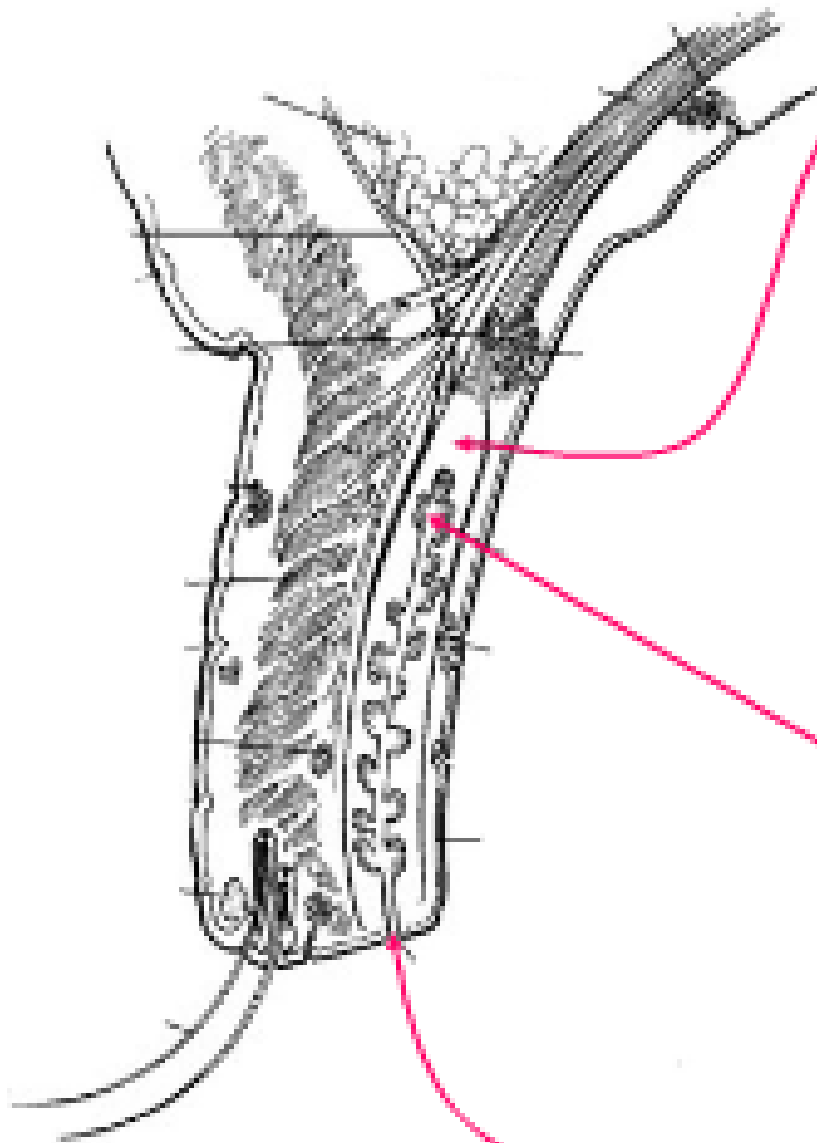
Tarsal Plates



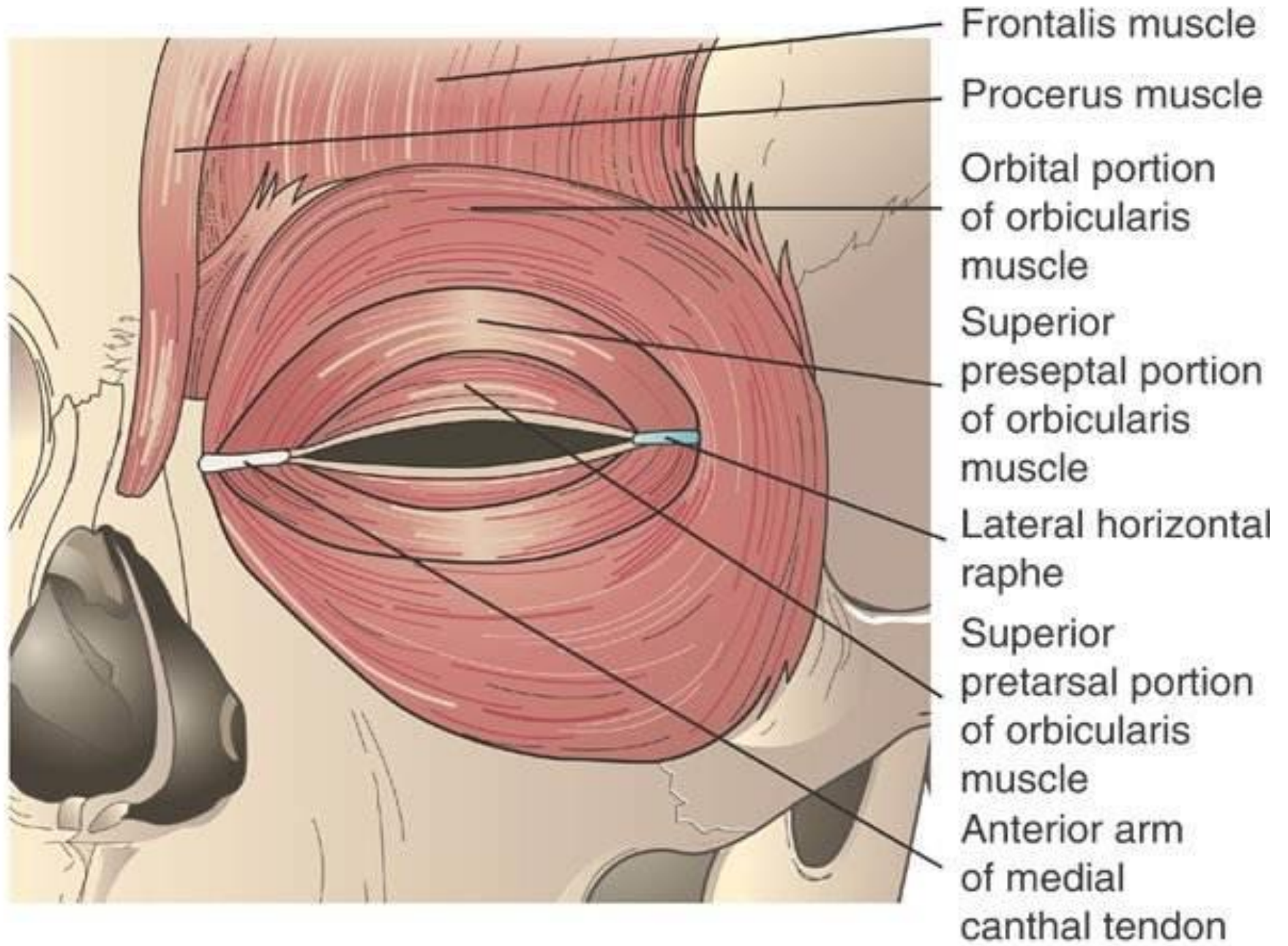
Tarsal Plate (in upper eyelid)



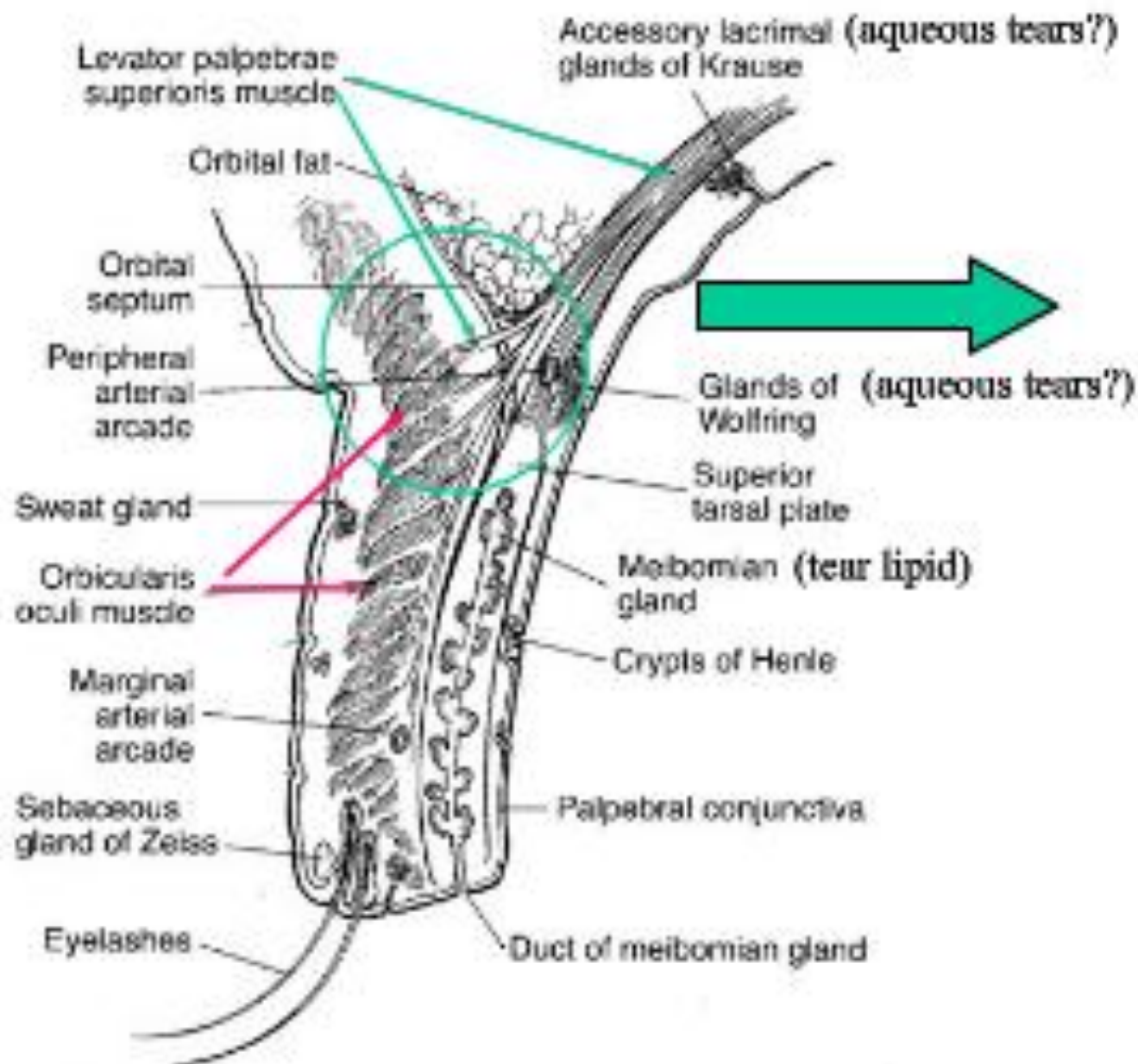
Tarsal Plate



- Made of dense fibrous tissue
- Gives rigidity to the eyelids
- ~ 1 mm thick; 25 mm in length (mediolateral)
- Vertically upper tarsus 10 mm; lower 5 mm
- Each tarsus contains ~ 30 meibomian glands that open onto the lid margin



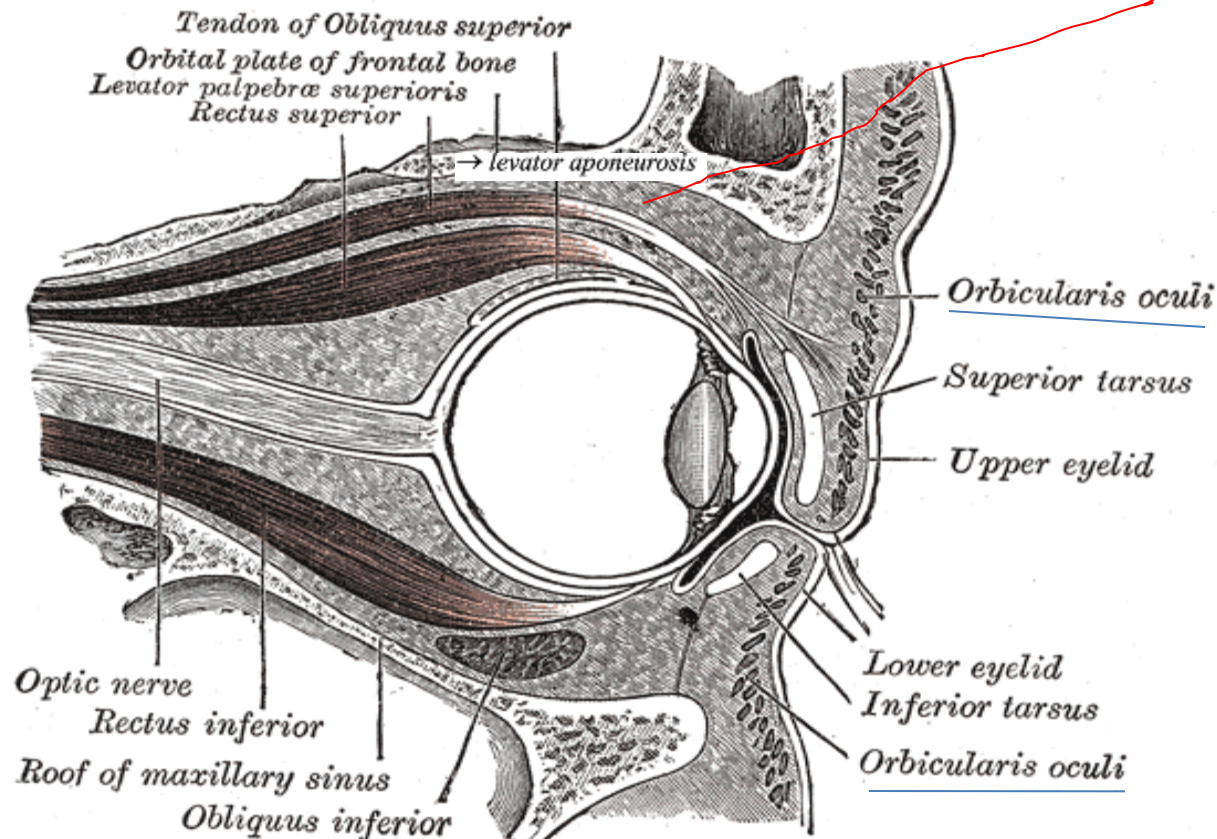
Primary Muscles of the Upper Eyelid



Levator - Orbicularis Interaction

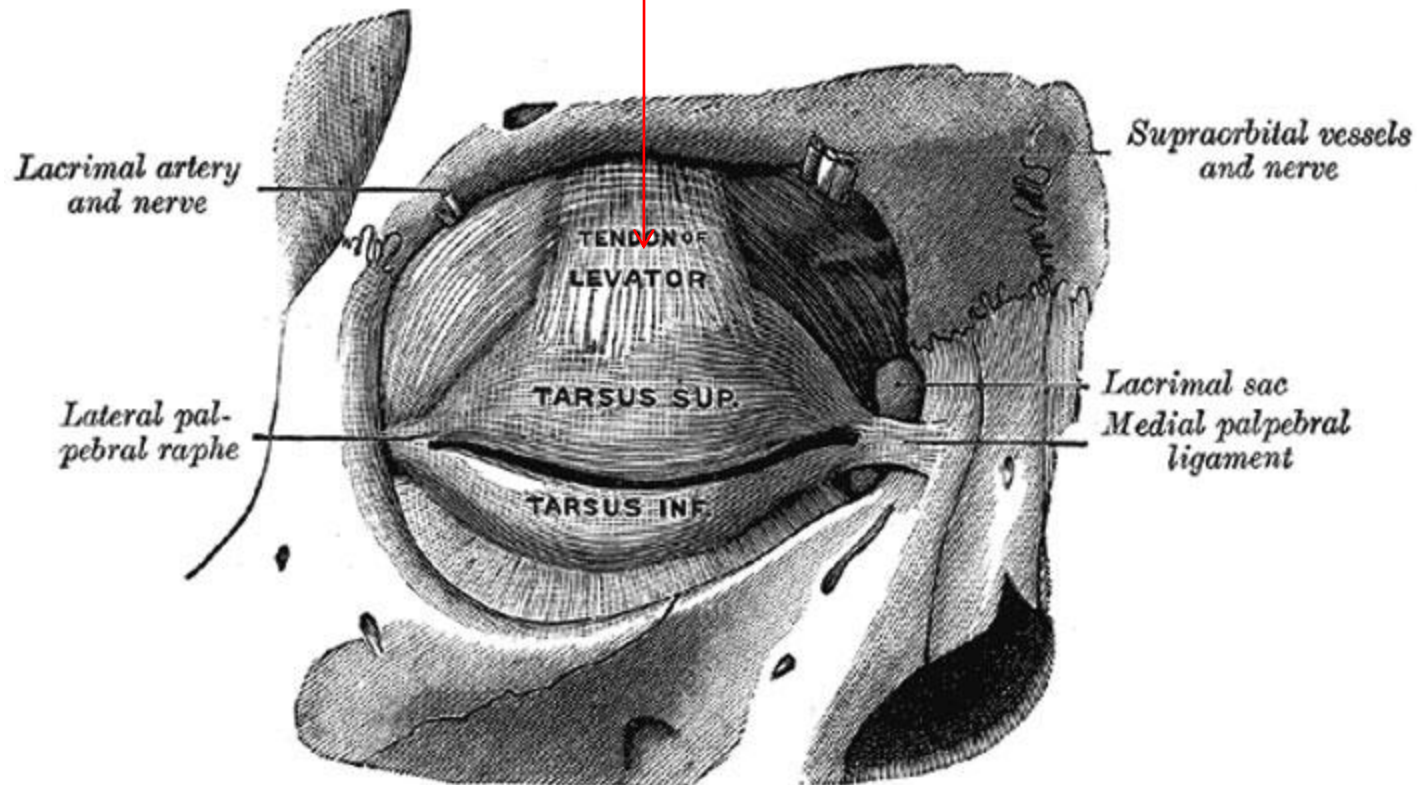
- Levator becomes tendinous ~ 15 mm above superior tarsal plate → *levator aponeurosis*
- Aponeurosis originates from periorbita of posterior orbit

Obliquus inferior.

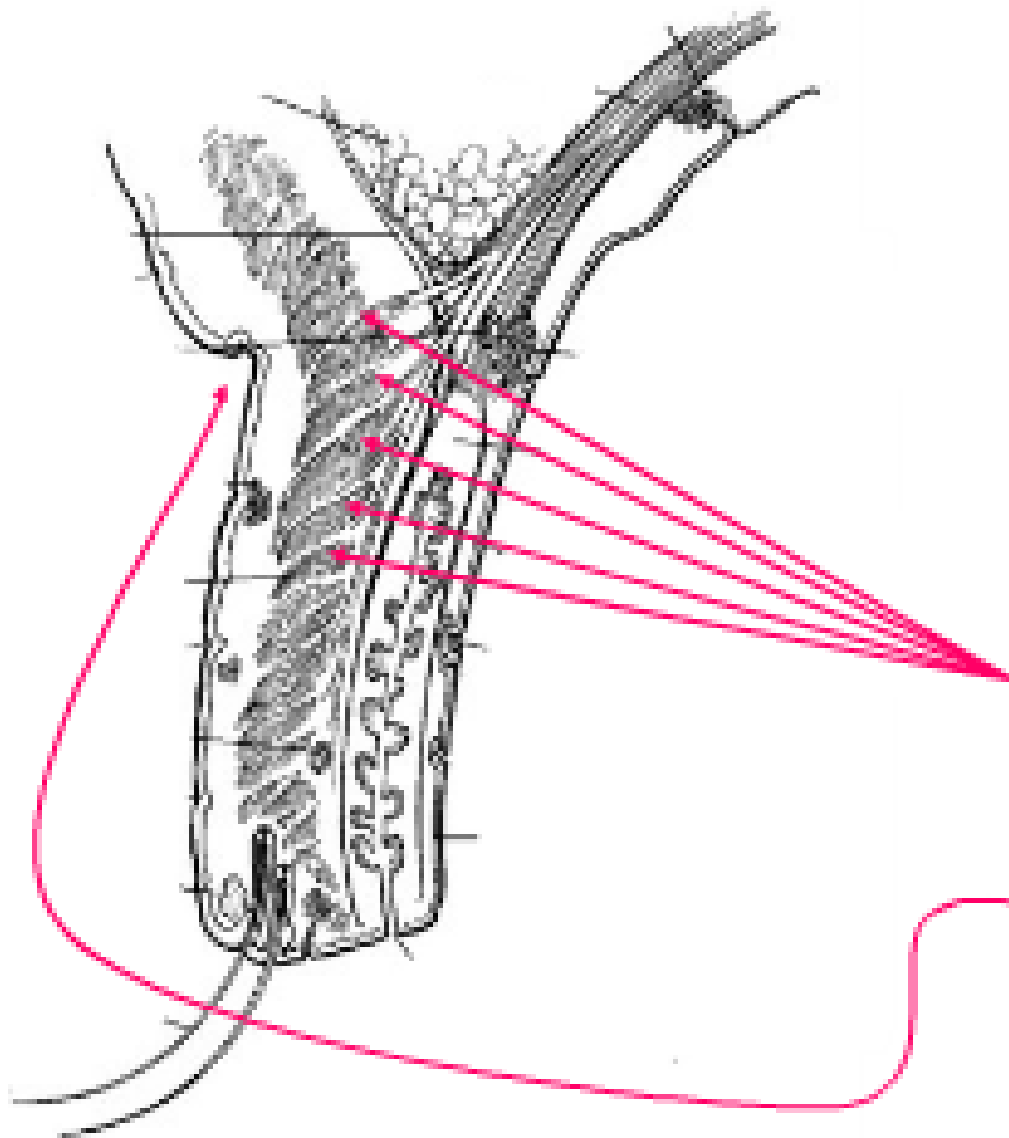


Levator - Orbicularis Interaction

Levator aponeurosis



Levator - Orbicularis Interaction



Aponeurosis fibers interdigitate with orbicularis (forms upper eyelid crease; a.k.a. superior palpebral furrow)

Eyelids: Landmarks

Orbital portion of lid

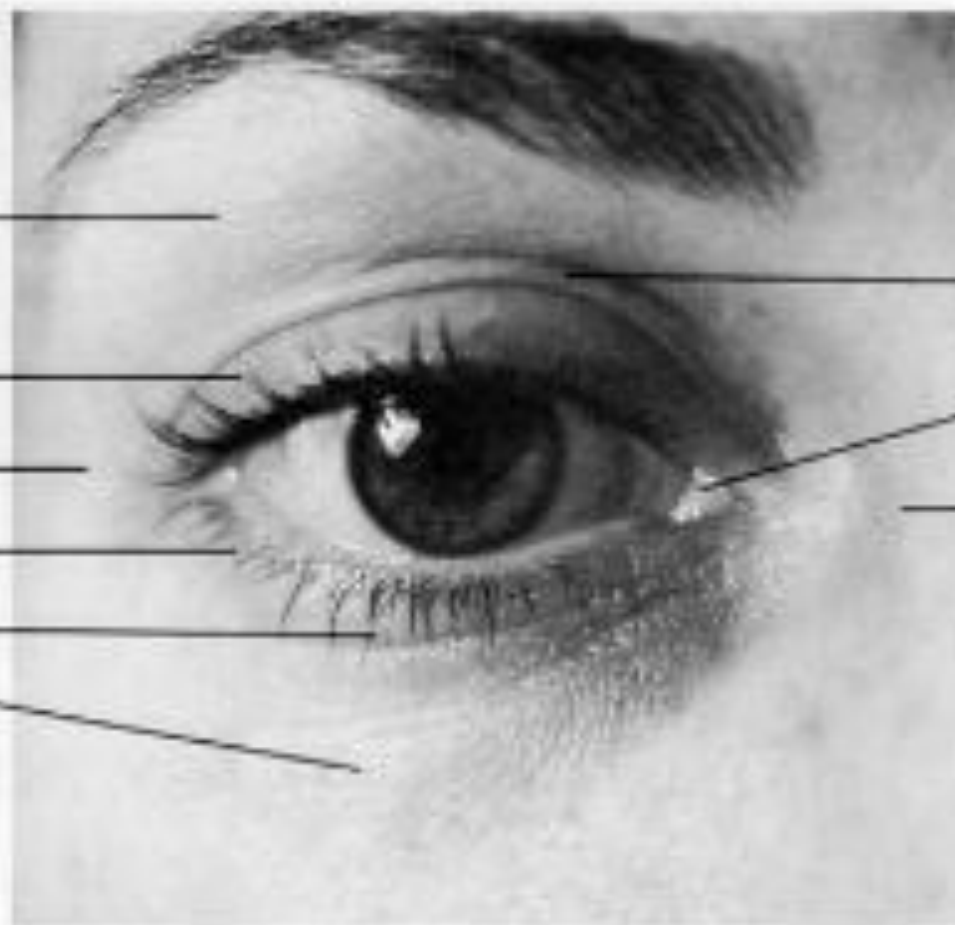
Tarsal portion of lid

Lateral canthus

Tarsal portion of lid

Inferior palpebral furrow

Orbital portion of lid



Superior palpebral furrow

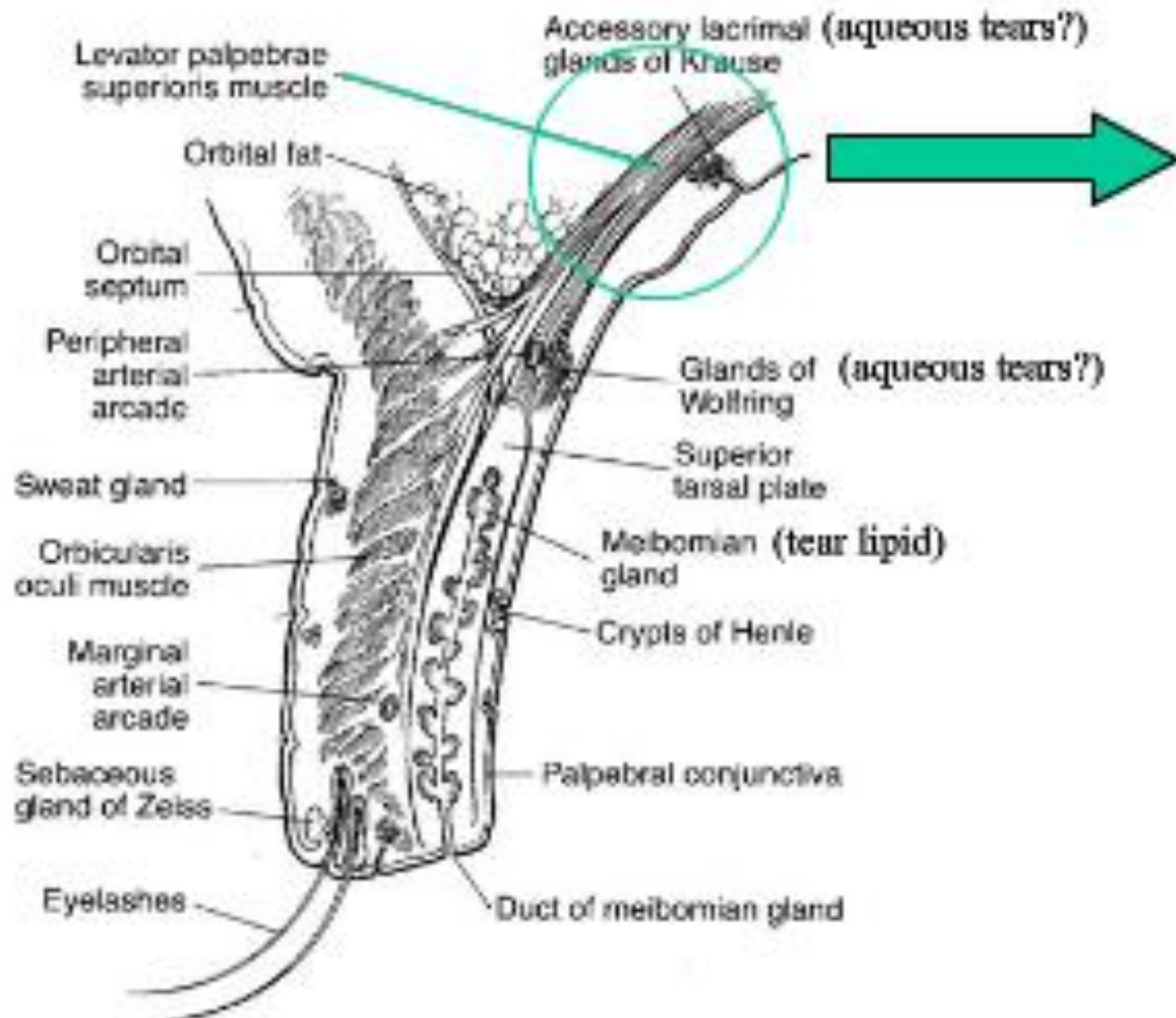
Caruncle

Medial canthus

MUSCLES OF THE EYELID

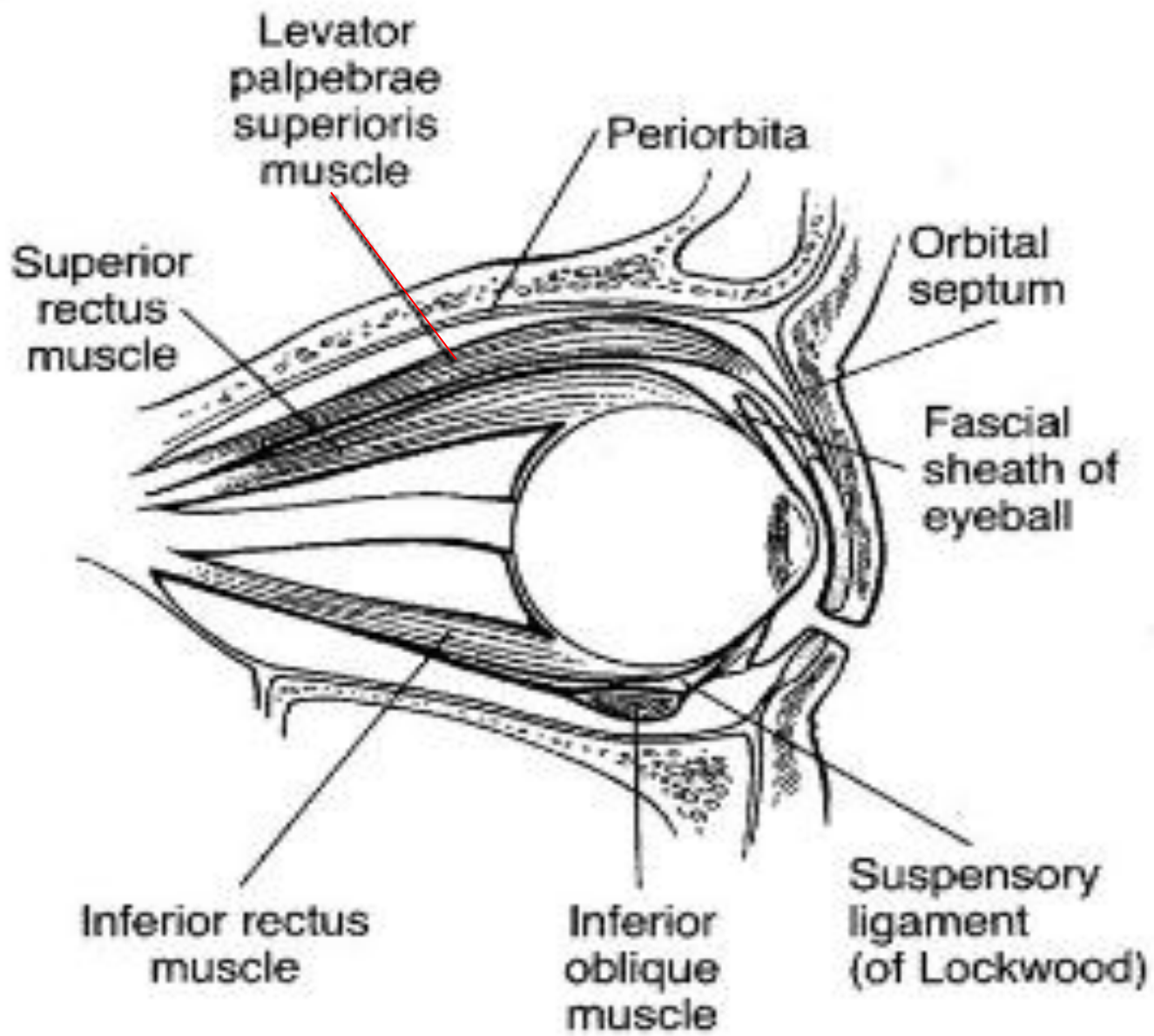
- *Levator palpebrae superioris*
- Muller's muscle
- *Orbicularis oculi*

Levator Palpebrae Superioris: (in upper eyelid)



Levator Palpebrae Superioris

- Striated muscle in upper lid (no counterpart in lower lid).
- Innervated by NIII (oculomotor nerve - superior branch.)
- Main eyelid retractor

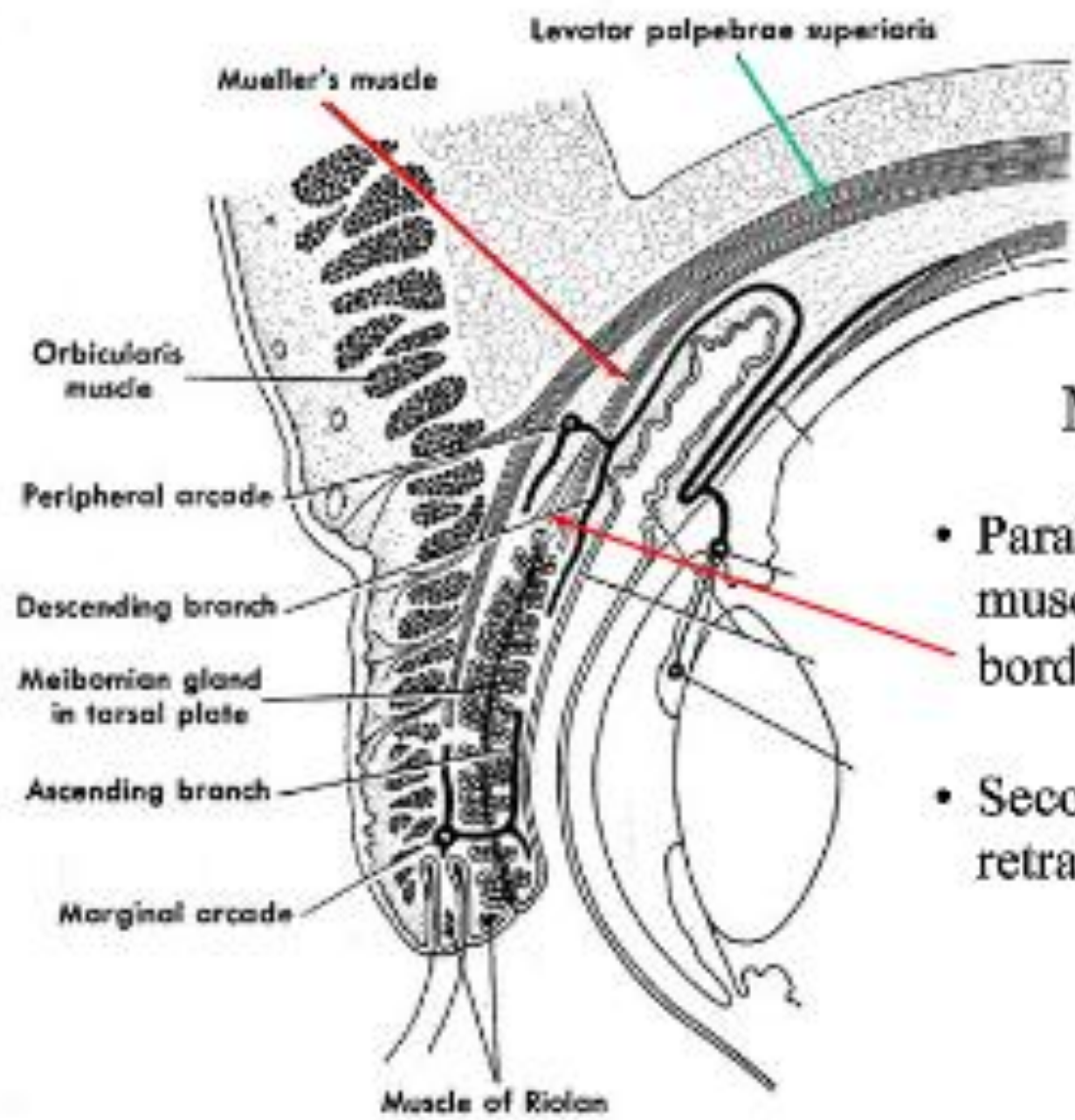


MUSCLES OF THE EYELID

- *Levator palpebrae superioris*
- **Muller's muscle**
- *Orbicularis oculi*

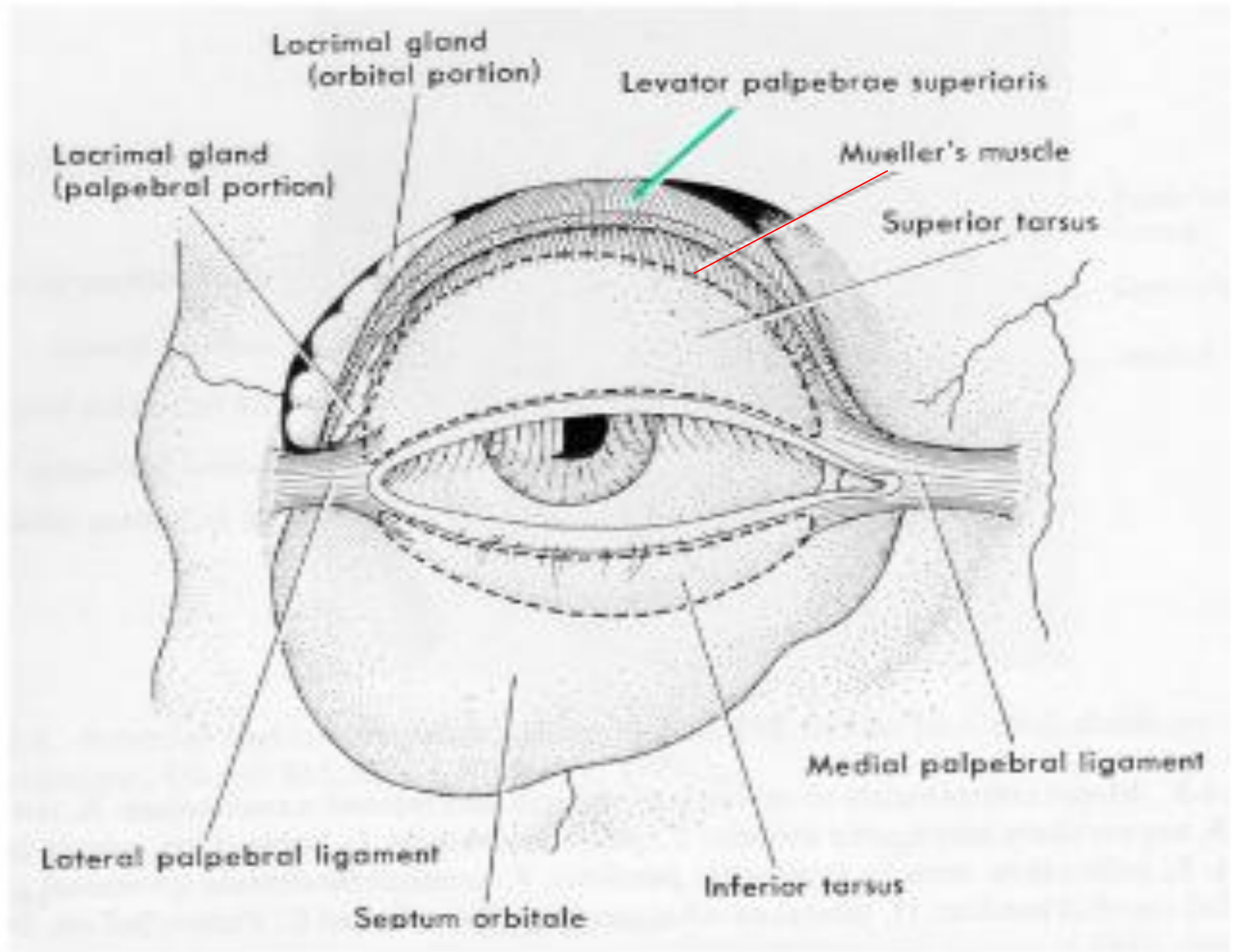
Müller's Muscle

- Smooth *superior tarsal muscle of Müller* (sympathetic) originates at levator aponeurosis



Müller's Muscle

- Parallels course of levator muscle to insert at upper border of tarsal plate.
- Secondary upper eyelid retractor. Also in lower lid.



MUSCLES OF THE EYELID

- *Levator palpebrae superioris*
- Muller's muscle
- *Orbicularis oculi*

Orbicularis Oculi

Forced lid closure and "expression"

Orbicularis oculi muscle:

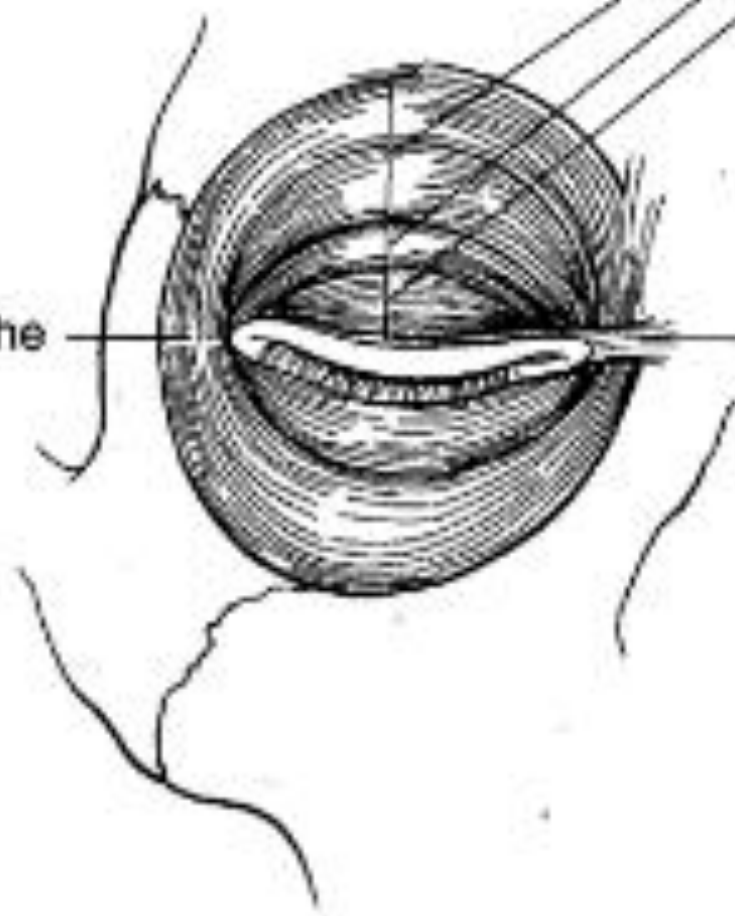
Orbital portion
Preseptal portion
Pretarsal portion

Lateral canthal raphe

Medial canthal tendon

Forms canthal tendons

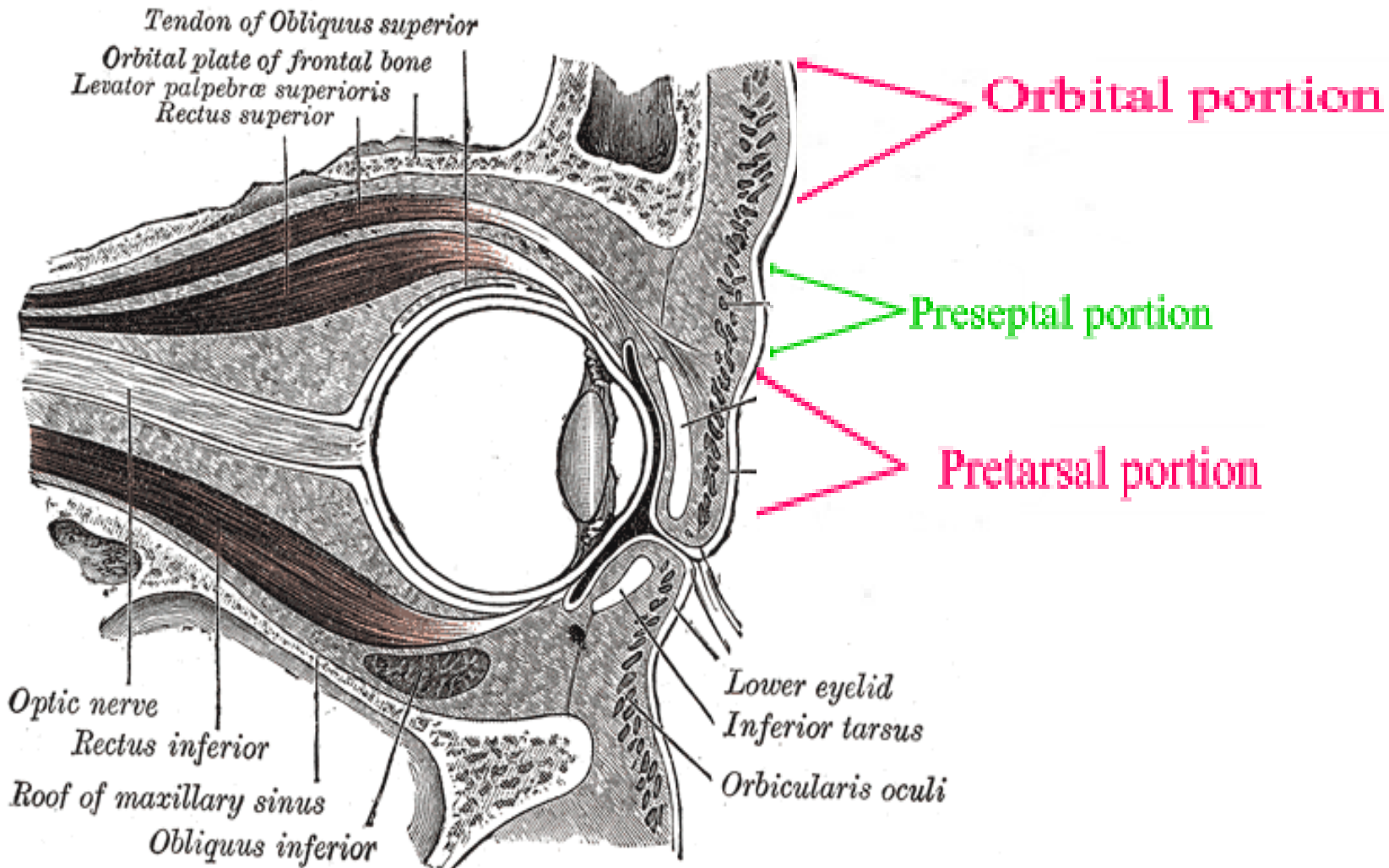
Aids in blinking and lid closure



Orbicularis Oculi

- Sphincter muscle of eyelid → direct antagonist of *levator palpebrae superioris*
- Innervation: temporal and zygomatic branches of facial nerve
- Divided into three parts:
 - pretarsal:
 - preseptal
 - orbital

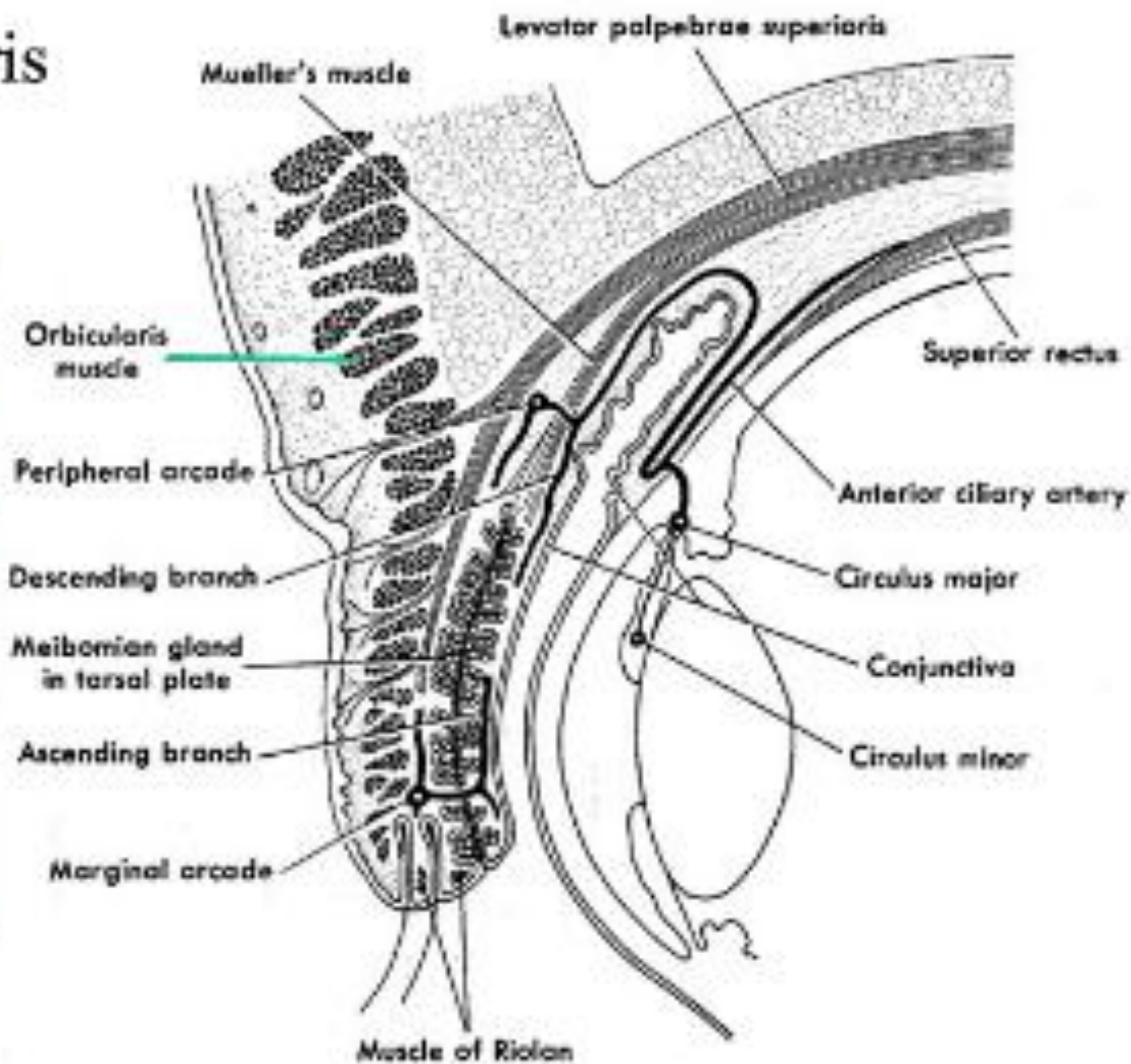
Orbicularis Oculi



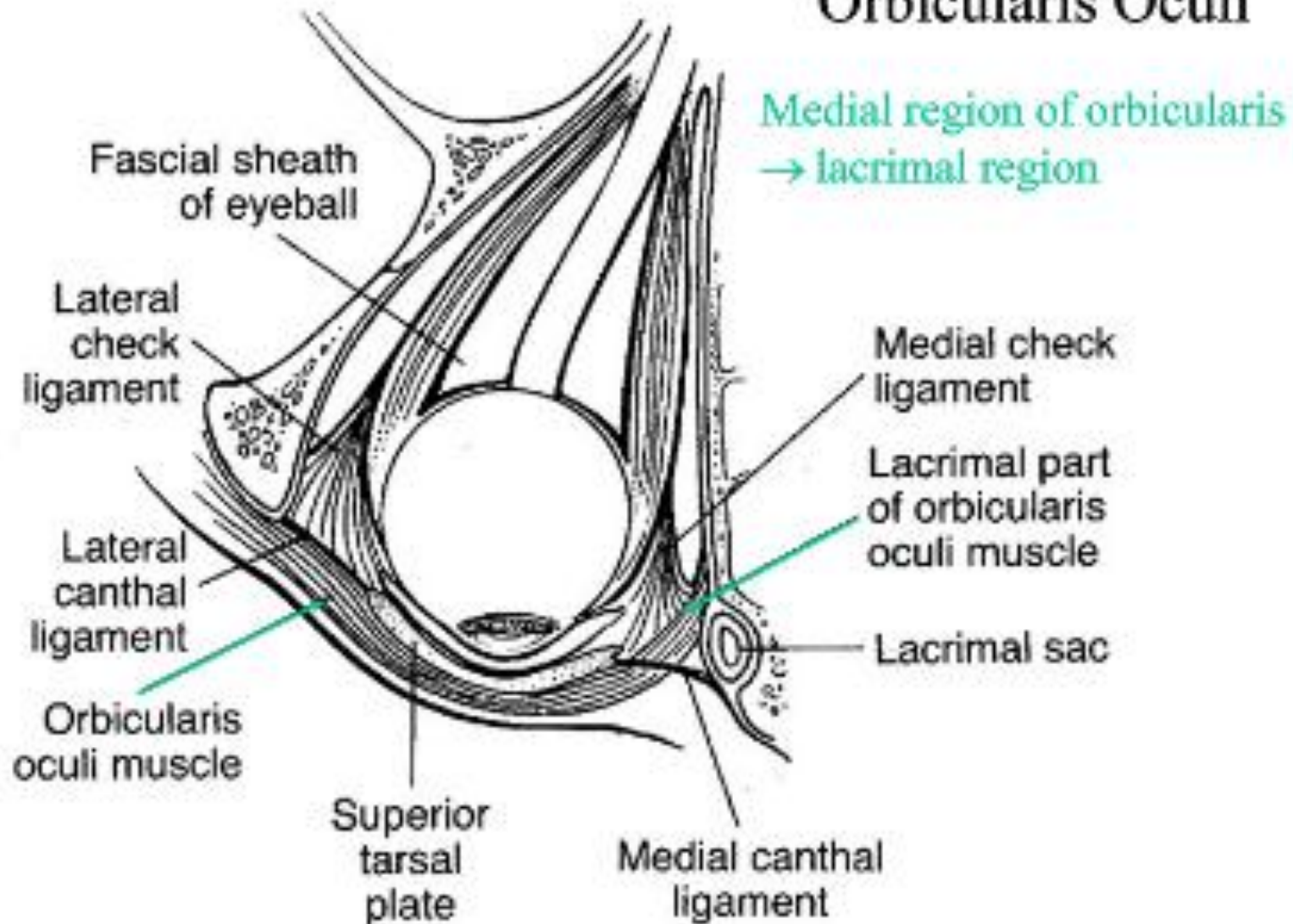
Orbicularis Oculi

Preseptal

Pretarsal



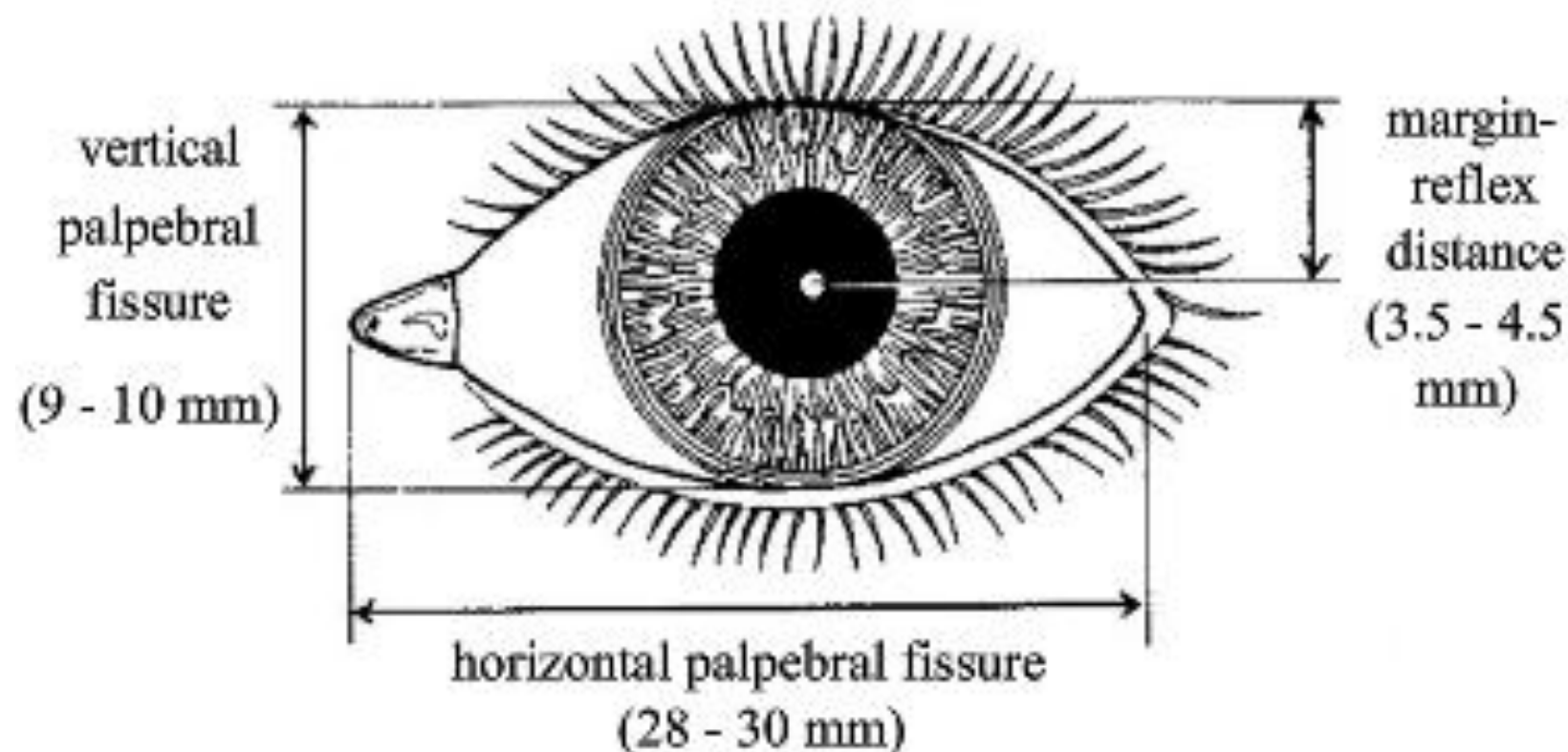
Orbicularis Oculi



The Palpebral Fissure

- Visible region between the upper and lower eyelids

PALPEBRAL FISSURE MEASUREMENTS



- Thank you