

# CONTENT

- Introduction
- Bitewing projection
- Occlusal radiography
- Intraoral localization techniques

# introduction

- Intraoral radiographic techniques are used in routine dental practice.
- It is divided into three categories;
- Periapical projections
- Bitewing projections
- Occlusal projections

- Periapical projections shows all teeth and surrounding bone.
- Bitewing projections shows crowns of maxillary and mandibular teeth and adjacent alveolar crest.
- Occlusal projections shows an area of teeth and bone larger than periapical film.

Second part includes....

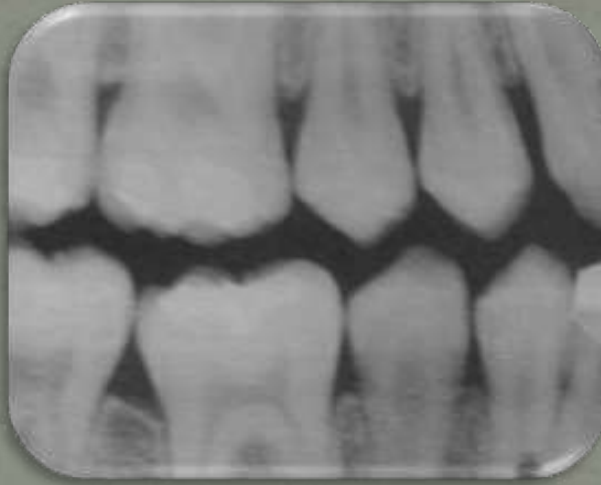
Bitewing projections and Occlusal projections



Bitewing projection




# Bitewing projection



- It is also called as interproximal radiographs.
- This includes the crowns of the maxillary and mandibular teeth and alveolar crest on the same film.

# Indications

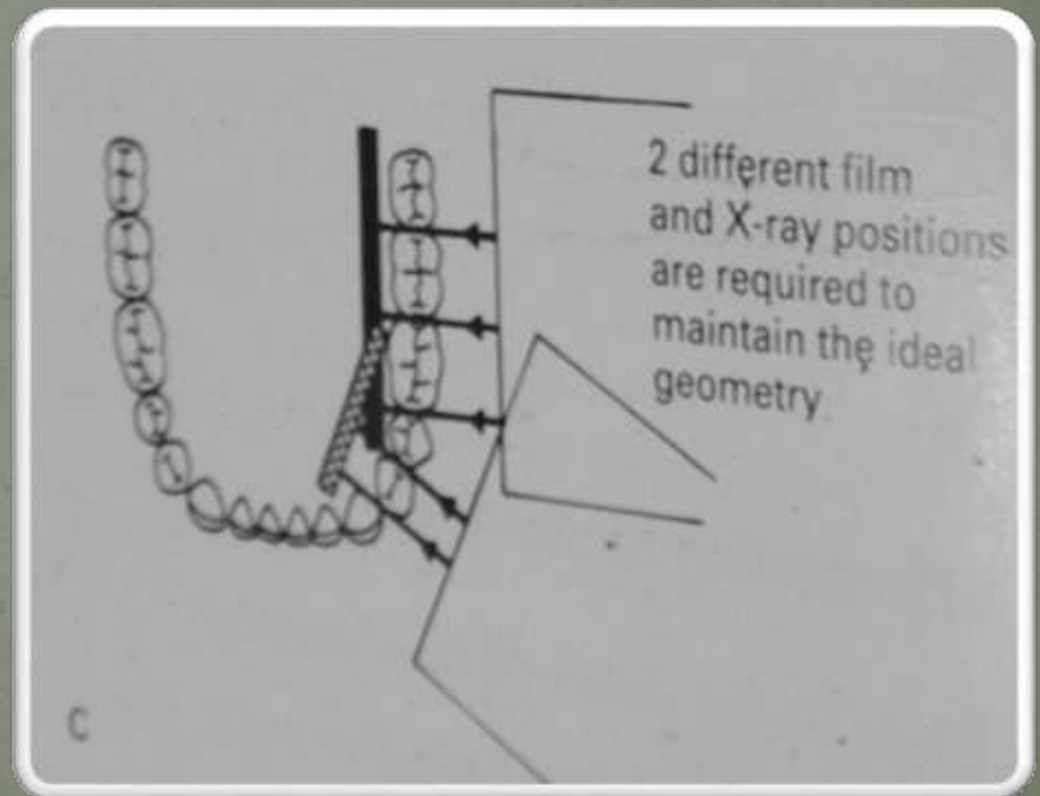
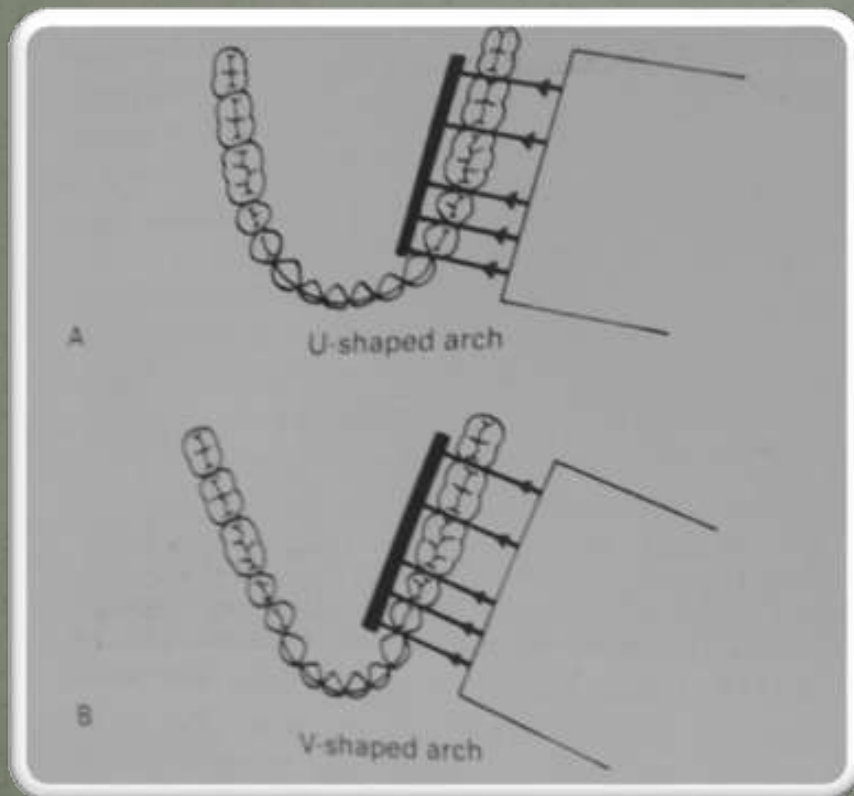
- Detection of interproximal caries.
- Monitoring progression of dental caries.
- Detection of secondary caries below restorations.
- Evaluating periodontal conditions.
- Useful for evaluating alveolar bone crest and changes in bone height can be assessed by comparison with the adjacent teeth.
- To detect interproximal calculus.(for better visualization exposure should be reduced as calculus has relatively low density)



# Exposure sequence ~

number of films depends on;

- curvature of arch
- number of teeth present





# Principles

- ❑ The film is placed in mouth parallel to the crowns of both the upper and lower teeth.
- ❑ The film is stabilized when the patient bites on the bitewing tab of bitewing holder.
- ❑ The central ray of the x-ray beam is directed through the contacts of the teeth, using a +10 vertical angulation.

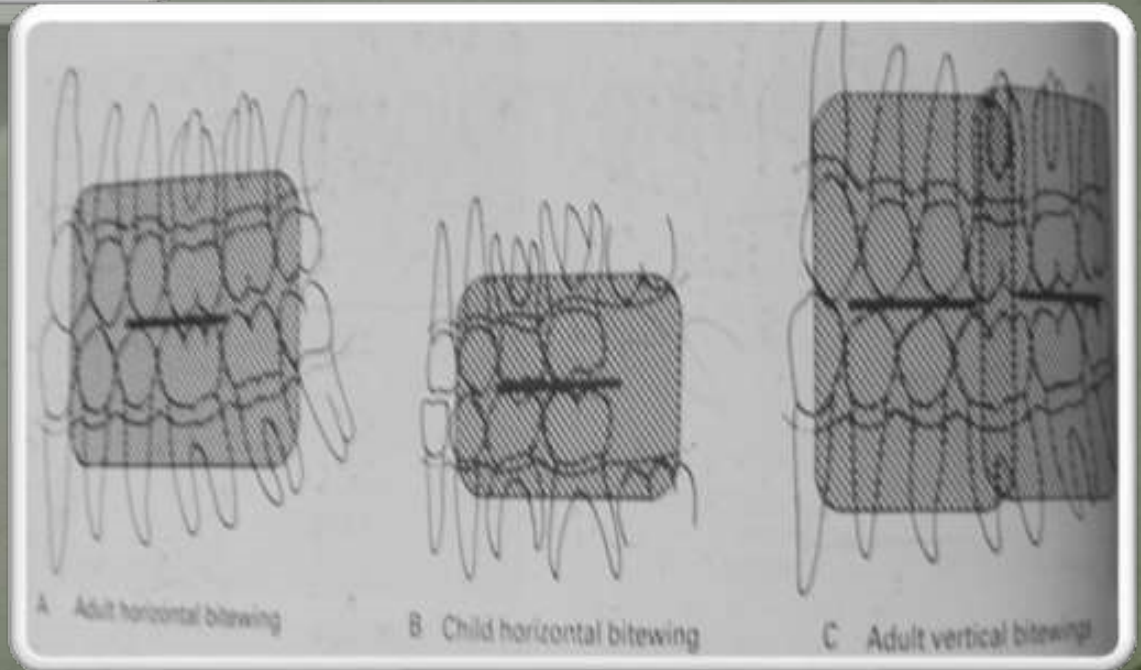
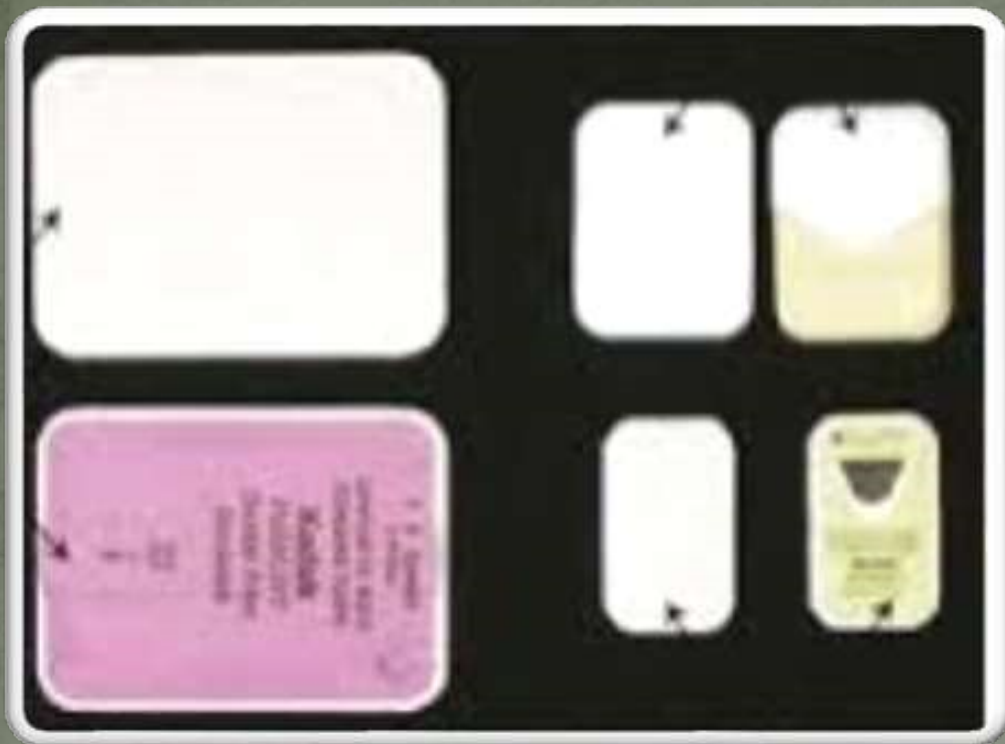
# films

- Four types of bitewing films are available.
- Size 0-used to study posterior teeth of children, always placed horizontally.
- Size 1-used to examine posterior teeth in mixed dentitions or anterior teeth of adults.

It is placed horizontally for the former and vertically to the latter.

- Size 2-used to examine posterior teeth of adults and is always kept horizontally.
- Size 3-it is a longer and narrower film used only for bitewing radiographs and spares horizontally from premolar to molar areas results in overlapping of the contacts.

# Film and placement



A Adult horizontal bitewing

B Child horizontal bitewing

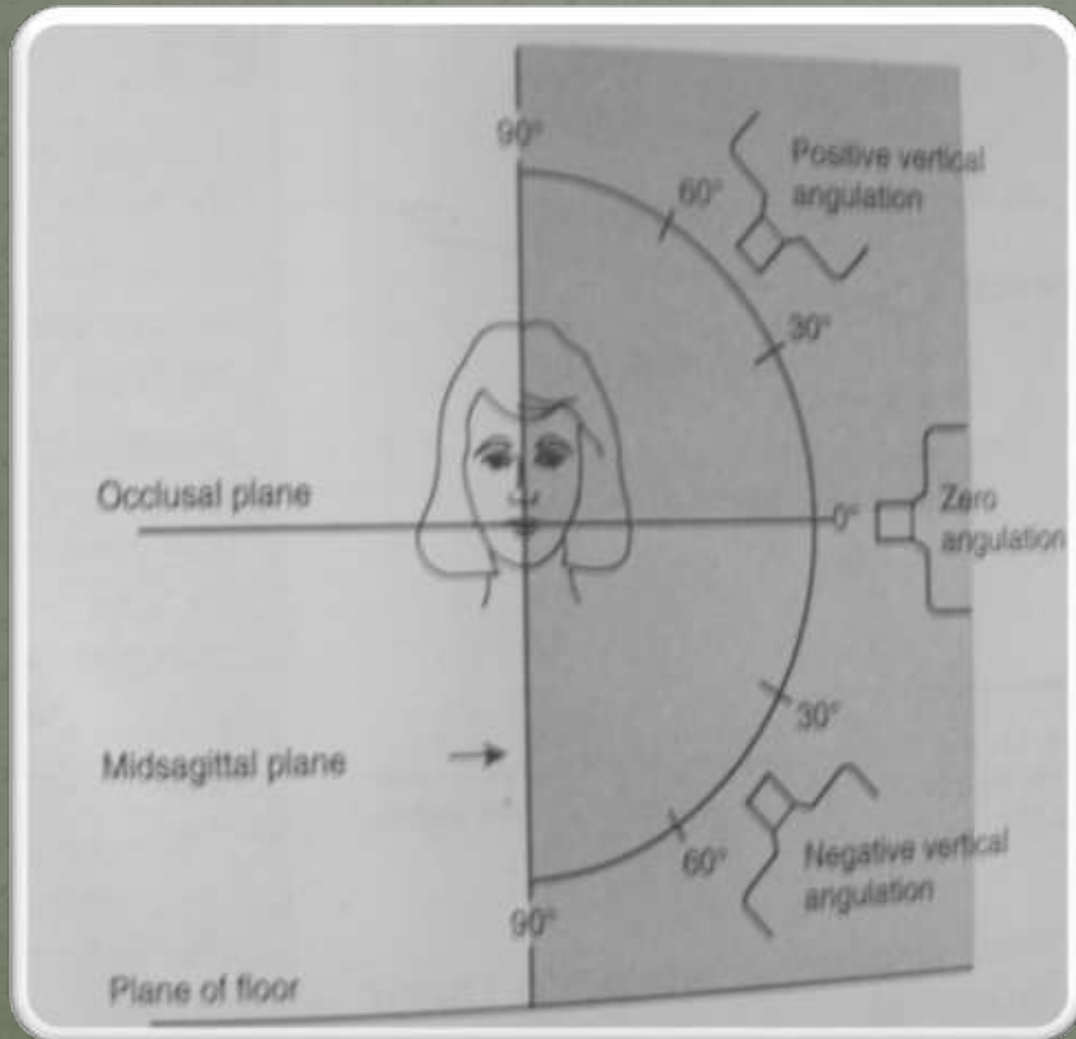
C Adult vertical bitewing



# Position indicating device and angulations

- If the bitewing holder is used, the aiming ring indicates the proper PID angulations.
- If the bitewing tab is used, then both the horizontal and vertical angulations must be precisely determined.
- Horizontal angulations –the central ray is perpendicular to the curvature of the arch and through the contact areas of teeth.
- Vertical angulations~the central ray is perpendicular to the long axis of tooth, a +10 vertical angulation is recommended for the bitewing radiograph, to compensate for the slight bend of the upper portion of the film and the slight tilt of the maxillary teeth.

# Position indicating device and angulations



# Patient positioning

- Patient is seated upright and the chair adjusted to a comfortable working position.
- Adjust the headrest to support and position the patient's head so that the upper arch is parallel to the floor and mid sagittal plane is perpendicular to the floor.
- Secure the lead apron and thyroid collar .
- Remove all foreign objects from the face and mouth.



# Basic rules of bitewing techniques

## Film placement~

- the film must be placed to cover the prescribed area.

## Film position~

- the film must be positioned parallel to the crowns of both the upper and lower teeth and stabilized by biting on the film holder or tab.

## Vertical angulation~

- the central ray must be directed at +10

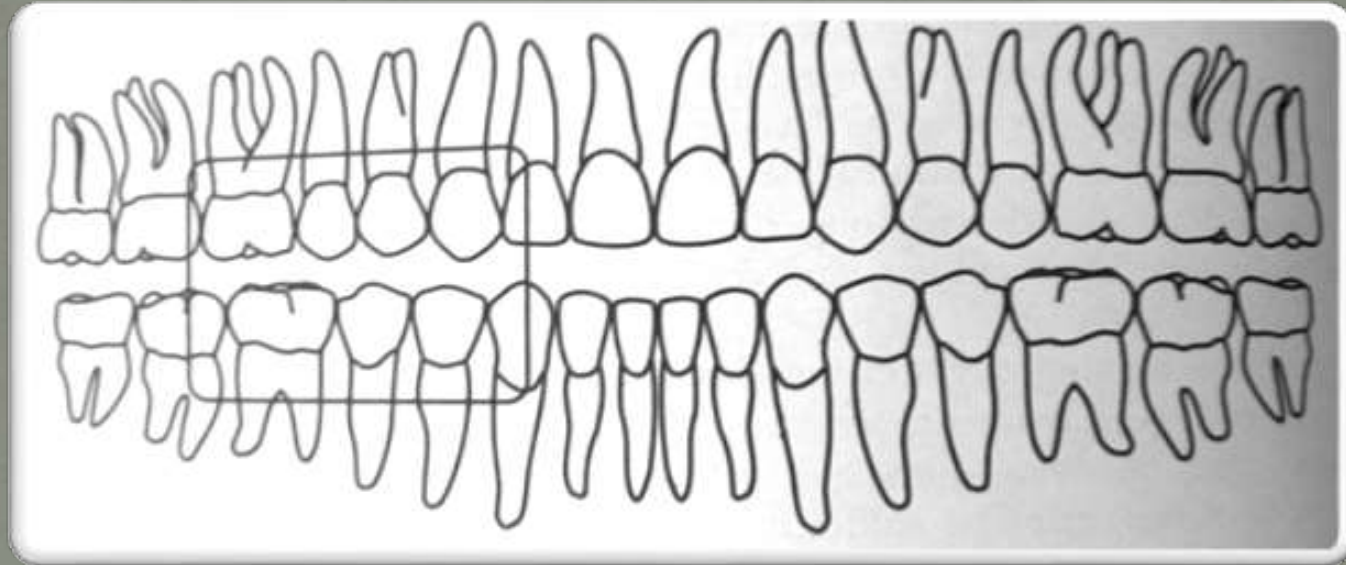
## Horizontal angulation~

- the central ray must be directed through the contact areas between the teeth.

## Film exposure~

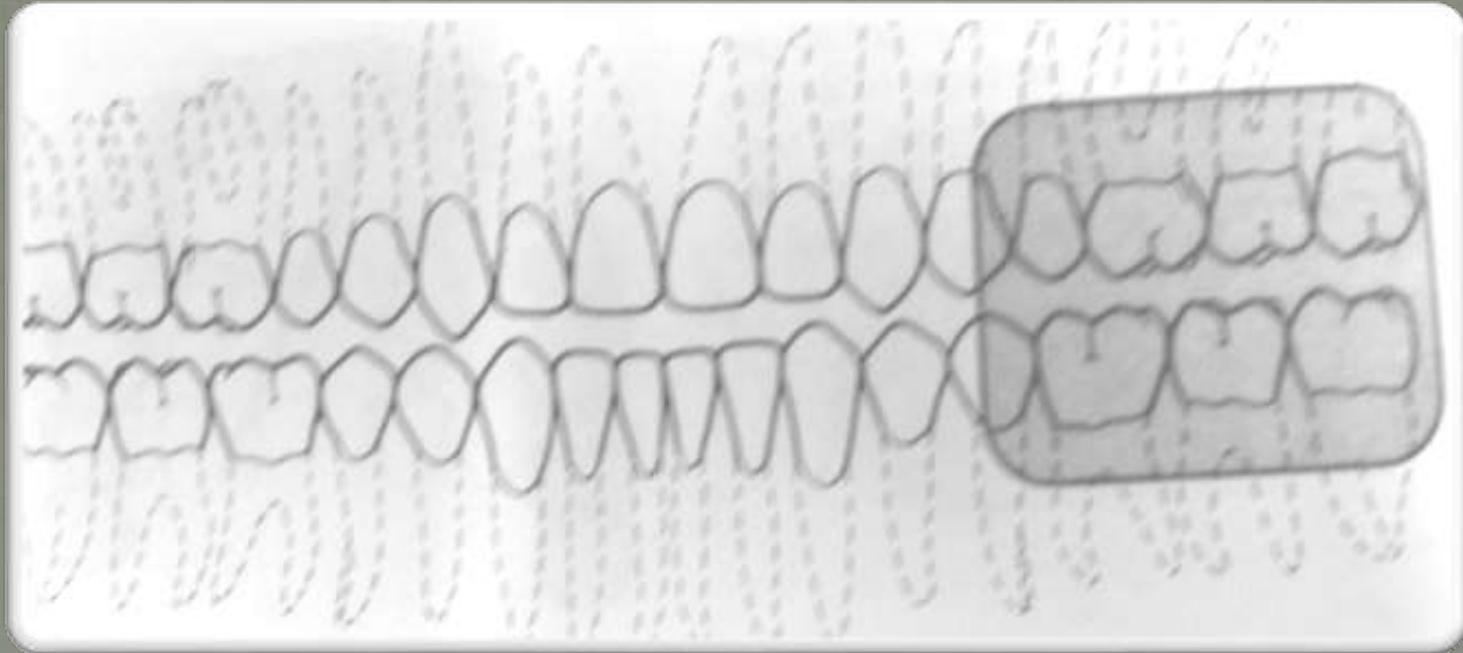
- the x-ray beam must be centered on the film to ensure that all the areas of the film are exposed and thus partial image or cone cut is avoided.

# Premolar exposure sequence





# Molar exposure sequence



# Advantages of film holder-

- Film packet can be held firmly and cannot be displaced by the tongue.
- Position of the holder relative to the teeth is recordable and reproducible.
- Position of the x-ray tube head determined by the holder ensuring that the x-ray beam is always at right angles to the film packet.
- Avoids coming of the anterior part of the film.
- All parts of the holder are autoclavable.

# Modifications in technique

Used in cases where..

- Edentulous spaces~a cotton roll is placed in the area of missing teeth to support the film holder or tab.
- Bony outgrowths~in case of mandibular tori, film should be placed in between tori and tongue.
- In case of large tori bitewing film holder is used to place film far away from teeth.



# Film holders

- The film holder is used to stabilize the film.
- Those used for bitewing radiographs are Benn Reproducible film packet holder and bite tab.
- A snap ring collimator may be added to reduce the exposure to the patient.
- Readymade bitewing films with attached tabs are also available.

# Benn Reproducible film packet holder



It is a modification of Rinn-XCP film holder used in periapical radiography.

In bitewing technique, the development of a holder incorporating two localized scales.

It allows the position of a holder relative to the teeth on both sides of the jaw to be recorded, ensuring a reproducible position for subsequent radiographs.

## Disadvantages

- Positioning of the holder can be uncomfortable for the patient.
- To be able to use localization scale on both sides of the arch, the film may have to be placed some distance from the teeth towards midline. This can increase the discomfort for the patient.
- Positioning the film holder and recording this position can be awkward for the un experienced operator.
- Not suitable for children and adult bitewing.
- Expensive.

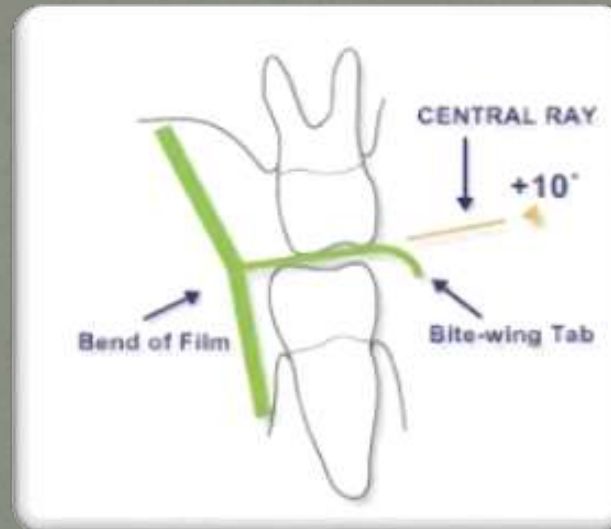


# Bite tab

It is made up of paper loop.

## Advantages

- Simple.
- Not expensive.
- Disposable.
- Can be used easily in children.

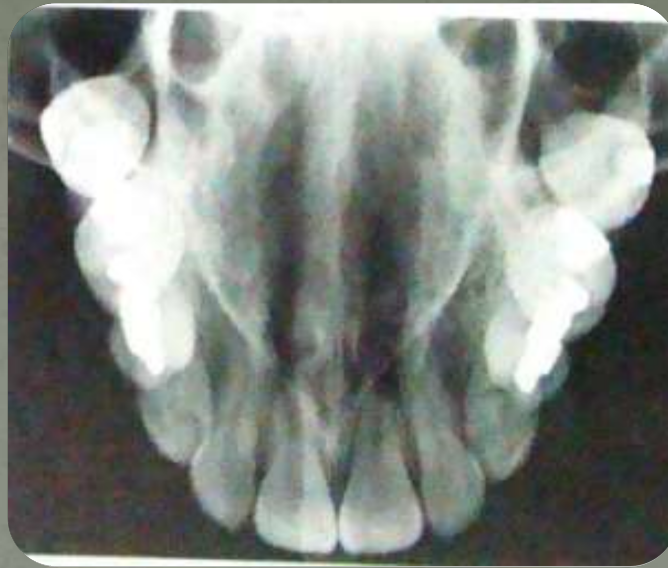

## Disadvantages

- Arbitrary, operator dependant assessment of horizontal and vertical angulations of the x-ray tube head.
- Radiographs are not accurately reproducible for progression of caries.
- Coming off the anterior part of film.
- The tongue can be easily displace the film packet.

# OCCLUSAL RADIOGRAPHY





- This technique is used to examine large areas of upper and lower jaw, palate and floor of mouth
- This is a supplementary radiographic technique that is usually used in conjunction with periapical or bitewing radiographs.

# Indications

- To locate retained roots of extracted teeth.
- To locate supernumerary, unerupted or impacted (canine/third molar) teeth.
- To locate foreign bodies in either jaws.
- To locate salivary stones in Wharton's duct at the floor of mouth.
- To locate and evaluate the extent of lesions (e.g.. cyst, tumor, tori etc)in the maxilla and mandible.

- To evaluate boundaries of the maxillary sinus.
- To evaluate fractures of maxilla and mandible.(location, extent and displacement)
- To aid in the examination of patient who is unable to open mouth fully or in adults and children who are unable to tolerate periapical films.
- To examine area of cleft palate.
- To measure changes in the size and shape of the maxilla and mandible.
- As a middle view, when using the parallex method for determining the buccal/palatal position of unerupted/impacted canines.



# classification

- Maxillary
- Topographic/anterior
- Cross sectional
- Lateral

## Mandibular

- Topographic/anterior
- Cross sectional
- Lateral

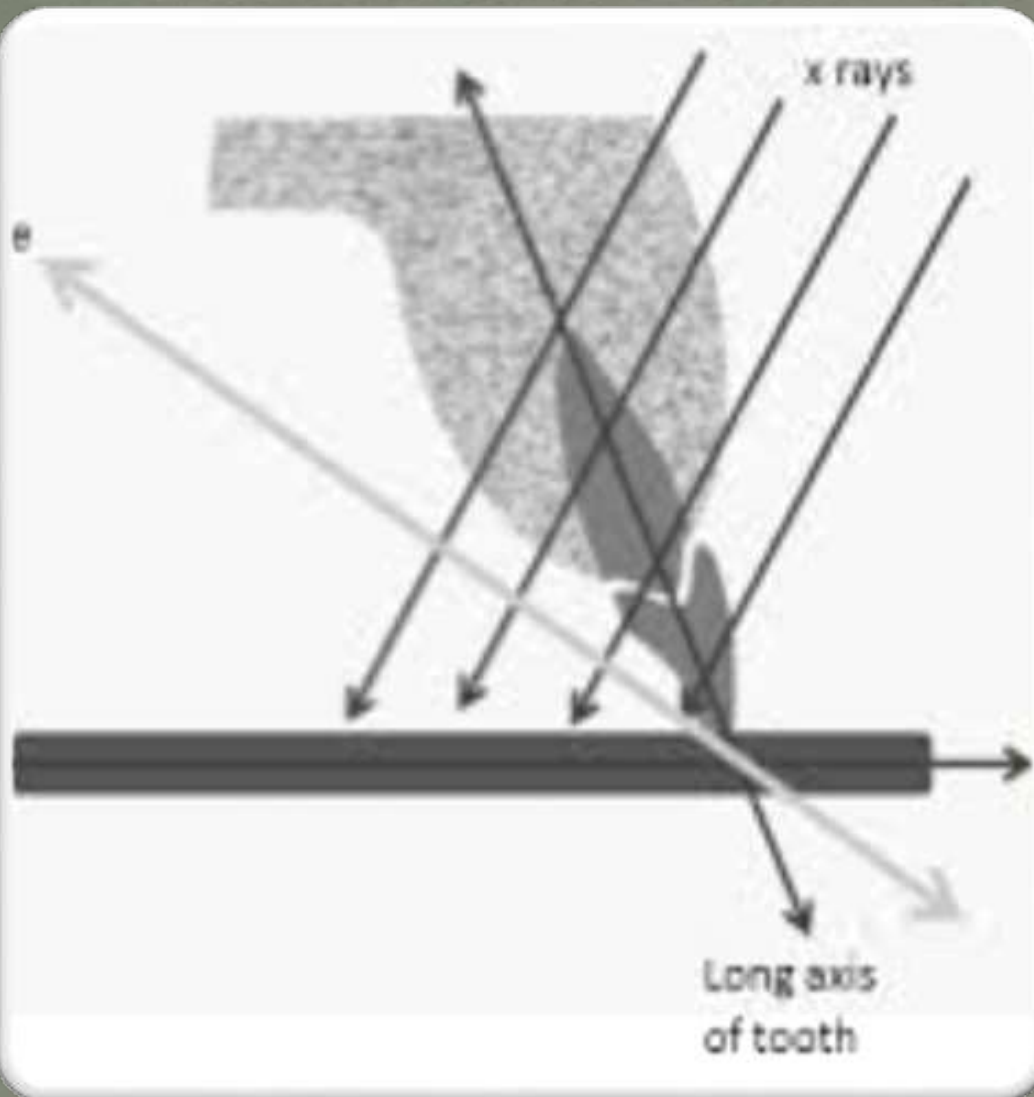
# Basic principle

- Film is positioned with white side facing the arch i.e. being exposed.
- Film is placed between the occlusal surfaces of the maxillary and mandibular teeth.
- Film is stabilized when patient bites on surface of film.
- For maxillary occlusal films the patient's head must be positioned so that the upper arch is parallel to the floor and mid-sagittal plane is perpendicular to the floor.
- For mandibular occlusal films the patient's head must be reclined and positioned so that the occlusal plane is perpendicular to the floor.

# Angulation

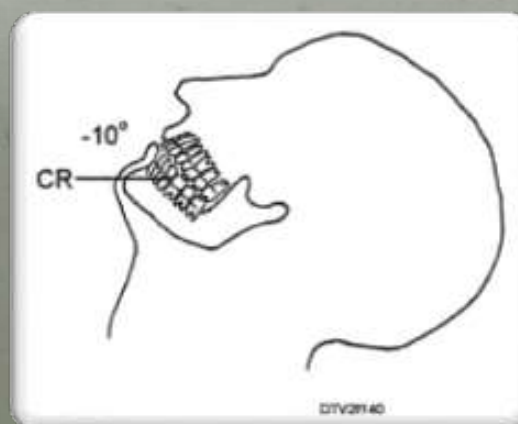
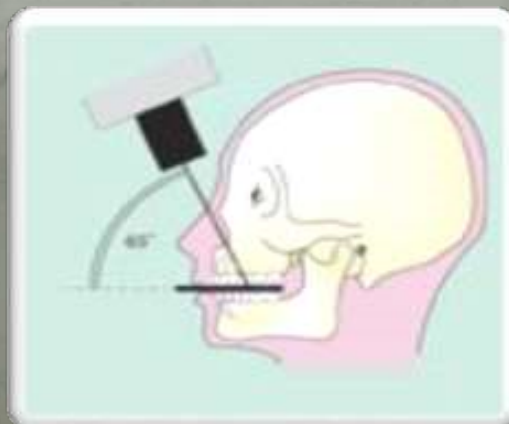
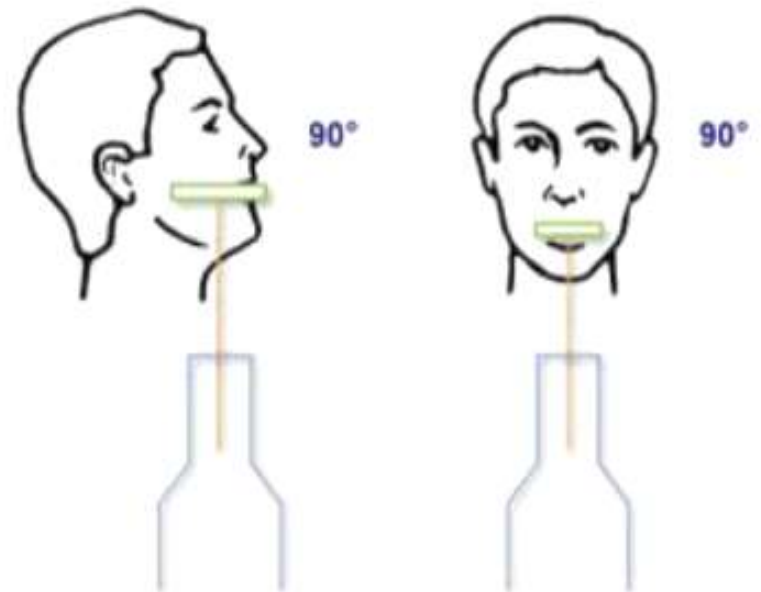
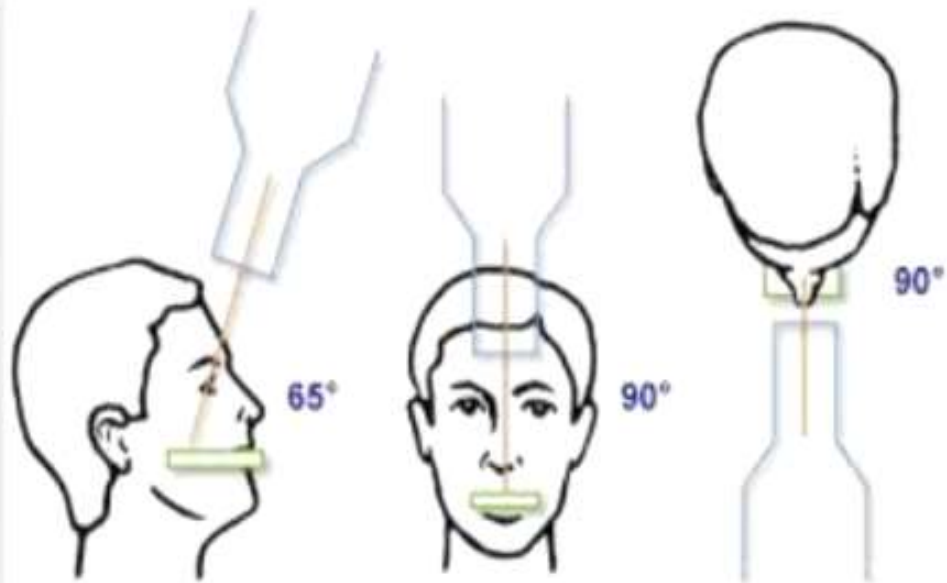
View\$	maxillary	mandibular
Cross sectional	+65	90
Topographic	+45	-10
lateral	+60	-55





## Maxillary view

Bisecting angle technique-the bisector of the angle formed by the film and the long axes of the teeth is first determined and then the central ray is directed perpendicular to the bisector.



Film~

Special occlusal films are marketed which are bigger than the intraoral films

Occlusal film is 3 times larger than Size-2 films(57x76mm)



# Maxillary cross-sectional view

## Image field

- This projection shows the palate, zygomatic process of maxilla, anteroinferior aspects of each antrum, nasolacrimal canals, nasal septum and teeth from right 2<sup>nd</sup> molar to left 2<sup>nd</sup> molar.

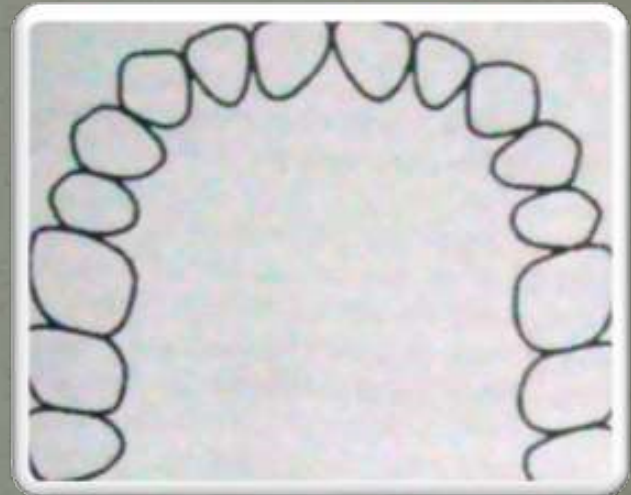
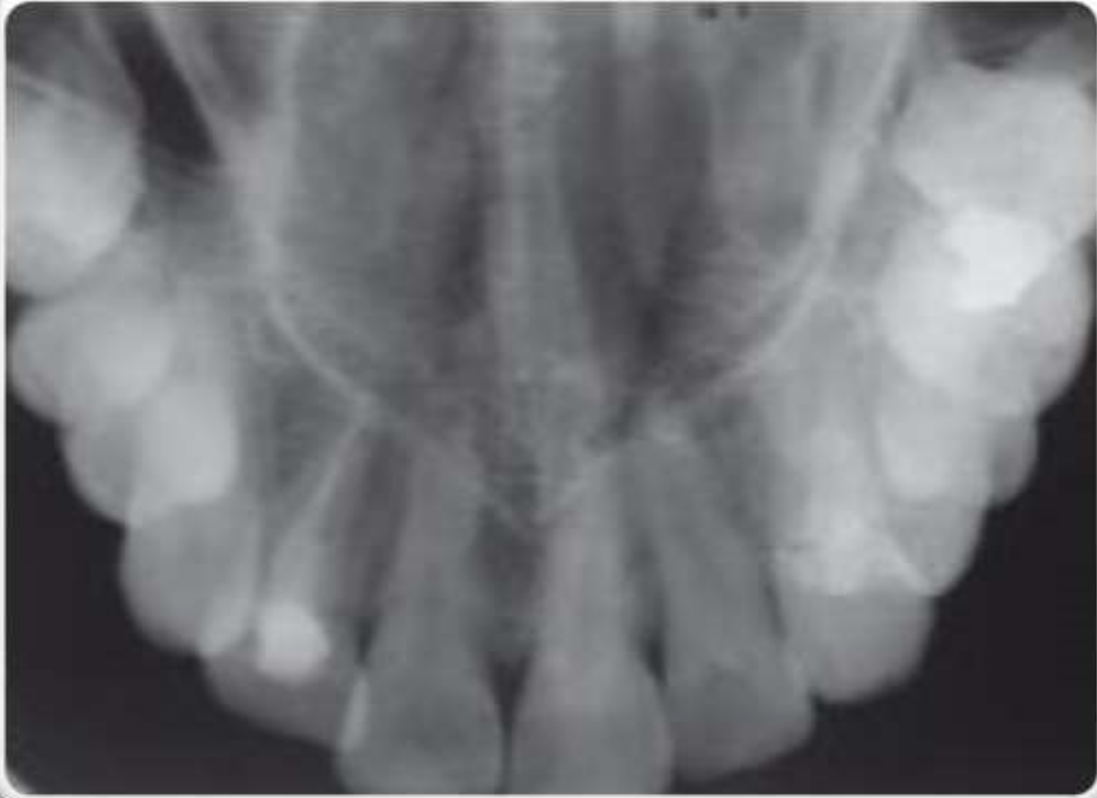## Film placement

- The film is placed crosswise into the mouth and gently pushed back until it contacts the anterior border of rami.

## Projections of the central ray

- The central ray is directed at a vertical angulation of +65 and a horizontal angulation of 0 towards the middle of the film.
- Generally central ray enters the patient's face through the bridge of the nose.

# Maxillary cross-sectional view

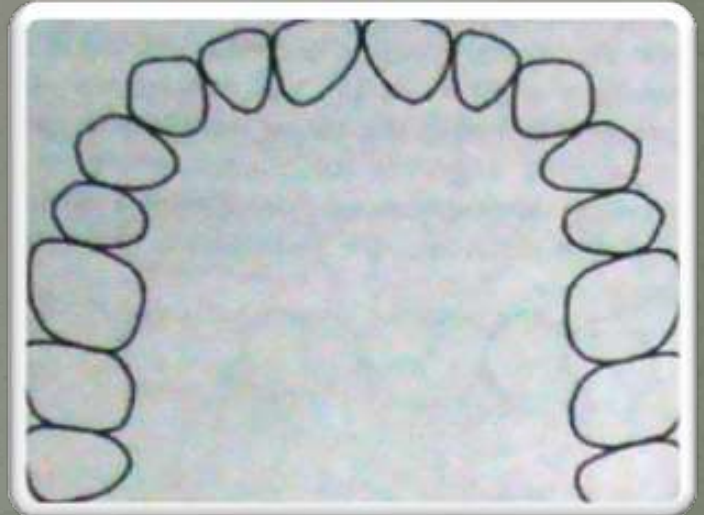
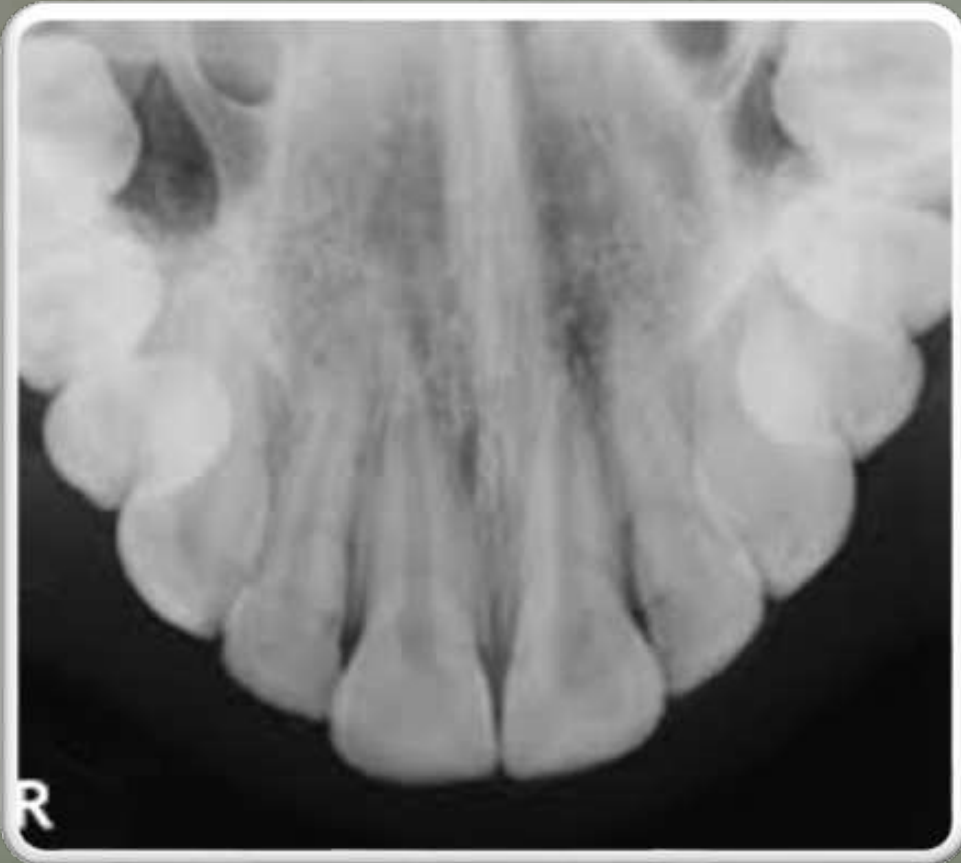

# Maxillary topographic view/ anterior

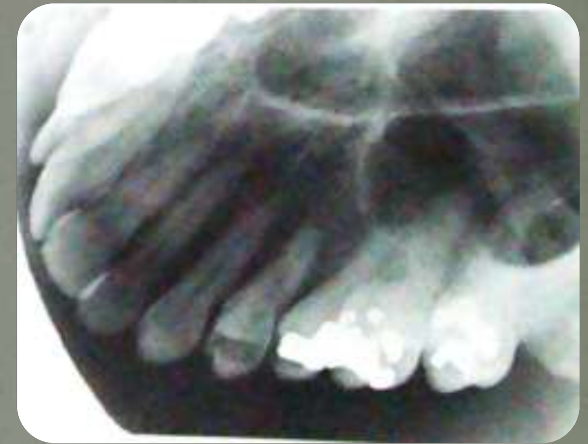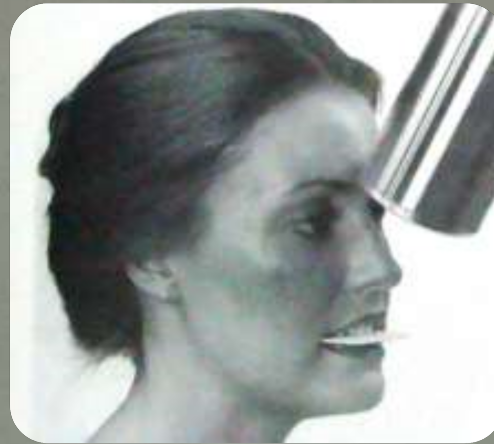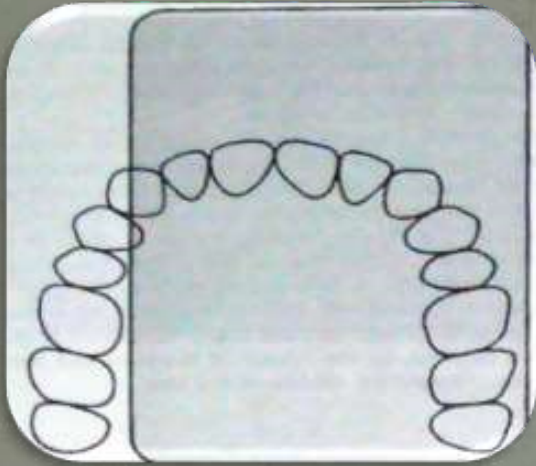
- Image field
- This projection shows the anterior maxilla and its dentition.
- It also includes anterior floor of nasal fossa and the teeth from canine to canine.
- Film placement
- The film is placed with the exposure side towards the maxilla and long dimension crosswise in the mouth.
- Projections of the central ray
- The central ray is directed towards the middle of the film. the vertical angulation is +65 and horizontal angulation is 0.
- Generally central ray enters the patient's face through the tip of nose.



## Maxillary topographic view



# Maxillary lateral view



## Image field~

- This projection shows half of the alveolar ridge of the maxilla, infero-lateral aspect of antrum, the tuberosity and the teeth from the lateral incisor to the third molar.
- It also shows zygomatic process of maxilla superimposed with the roots of molars.



## Film placement~

- The film is placed with its long axis parallel to the sagittal plane and on the side of interest with the pebbled side towards the maxilla in question.
- The lateral border should be positioned parallel to the buccal surface of the posterior teeth and extending lateral approximately  $1/4^{\text{th}}$  inch posterior to the buccal cusp.

## Projections of the central ray~

- the central ray is projected to a point below the lateral canthus of the eye and directed towards the centre of the film with a vertical angulation of  $+60$ .



# Anatomical landmarks in maxillary occlusal radiography

- Nasopalatine foramen
- Midpalatine suture
- Incisive foramina
- Hard palate
- nasal septum,
- the superior foramina of nasopalatine canal.
- Border of maxillary sinus
- Zygomatic process of maxilla
- Soft tissue shadow of nose

# Mandibular cross sectional view

## Image field~

- It includes soft tissues of the floor of mouth and lingual and buccal plates of mandible and teeth from 2<sup>nd</sup> m to 2<sup>nd</sup> m.

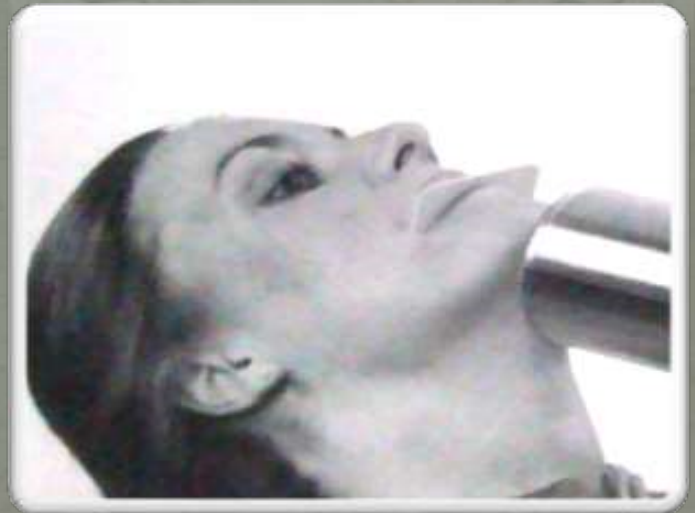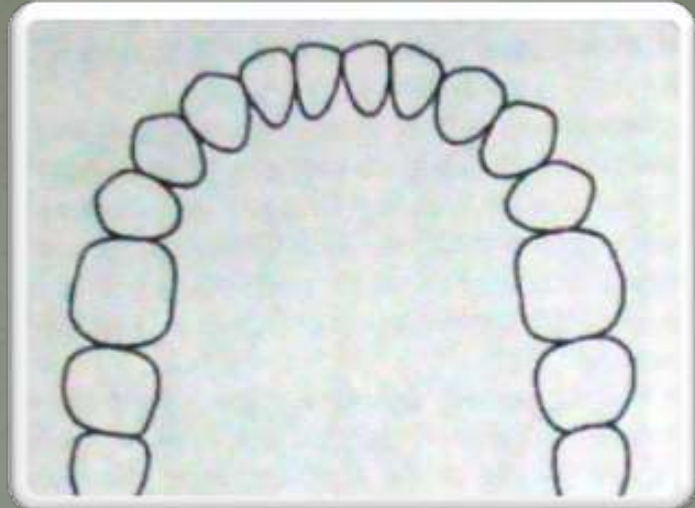
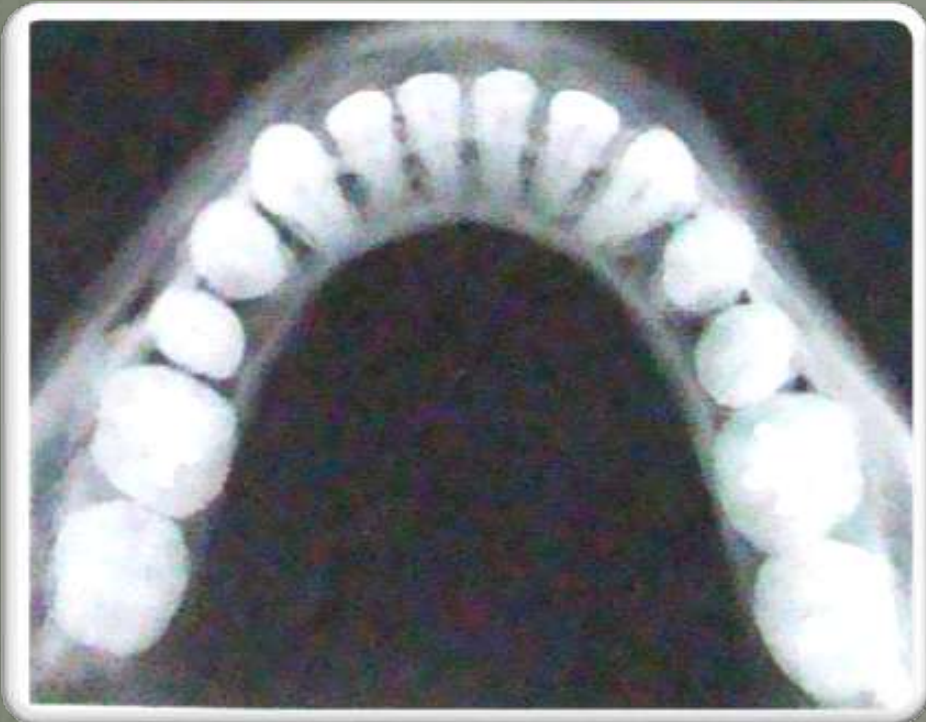## Film placement~

- The film is placed with its long axis perpendicular to the sagittal plane and the pebbled surface towards mandible.
- The anterior border of the film should be approximately 1/2 inch approximately anterior to the mandibular central incisor.

## Projection of the central ray~

- It is directed at right angles to the centre of the film. The point of entry is in the middle through the floor of the mouth approximately 3 cm below the chin.

# Mandibular cross sectional view





# Mandibular topographic/anterior view

## Image field~

- it shows anterior portion of mandible.

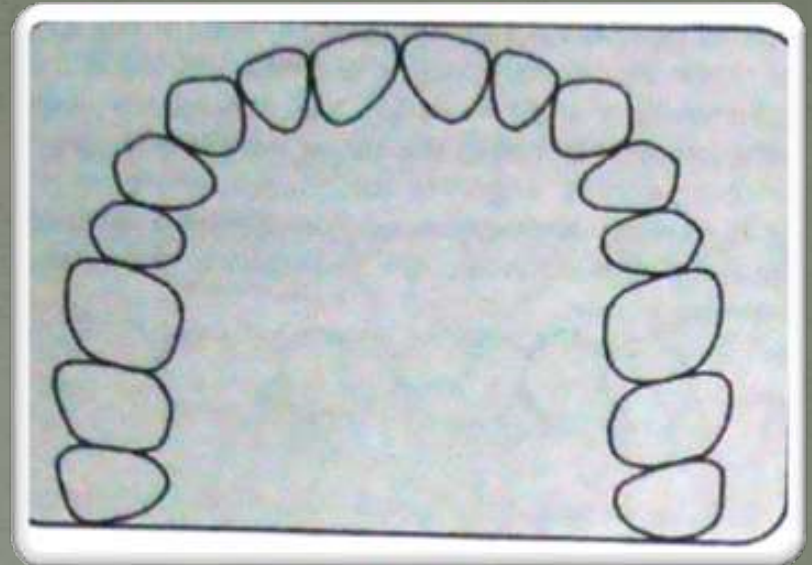
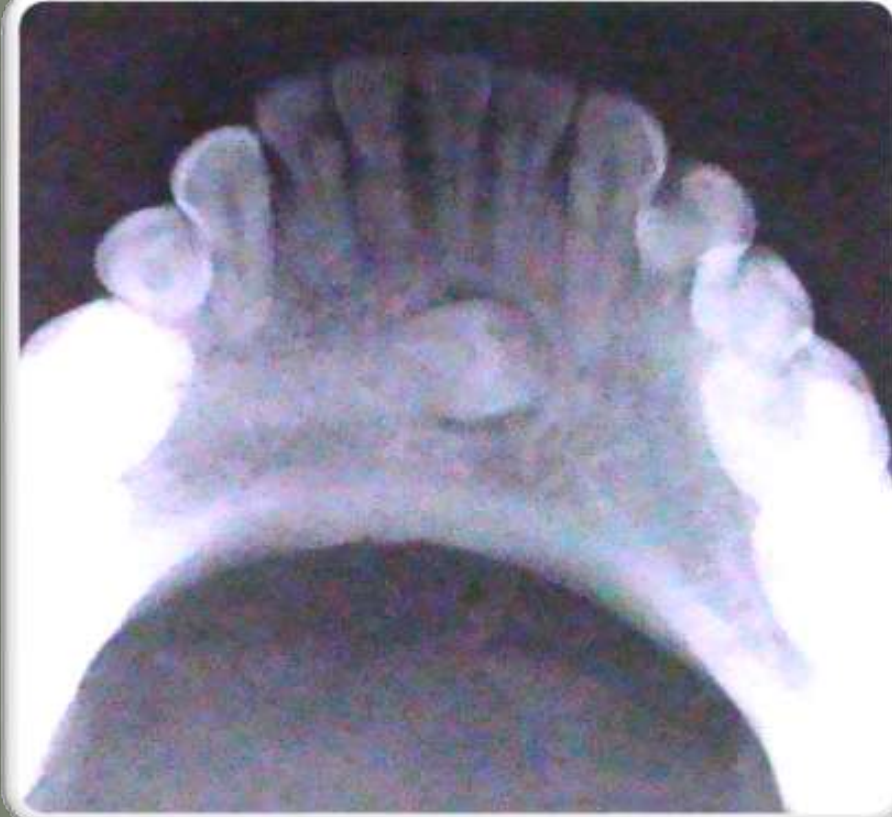## Film placement~

- the film is placed with long axis parallel with the sagittal plane and as far posteriorly as possible with the pebbled side down.

## Projection of the central ray~

- directed towards the middle of the film with  $-55^\circ$  angulation in respect to the plane of the film. The point of entry of the central ray in the midline and through the tip of chin.

# Mandibular topographic view





# Mandibular lateral view

## Image field~

It includes soft tissues of half of the mandible and teeth from lateral incisor to the 3<sup>rd</sup> m.

## Film placement~

The film is placed lengthwise in the mouth with its long axis directed dorso-ventrally and the pebbled side towards the mandible.

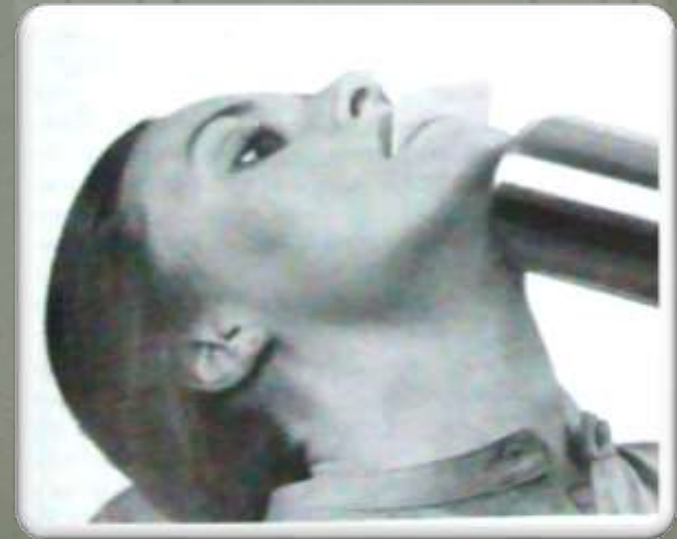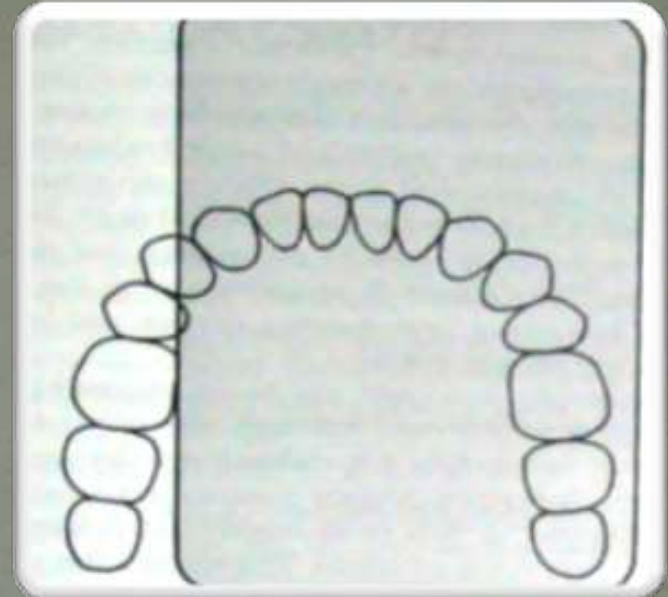
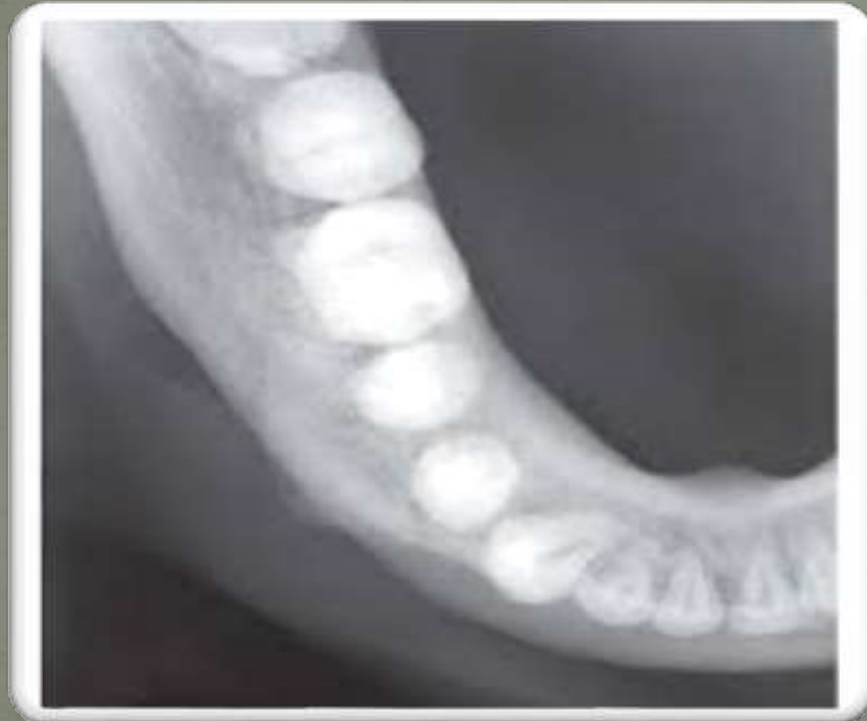The film is placed as far back as possible, so that the lateral border is parallel to the buccal surfaces of the posterior teeth and extending laterally approximately 1cm.

## Projection of the central ray~

Directed perpendicular to the centre of the film. The point of entry of central ray is beneath the chin and approximately 3cm lateral to the midline.



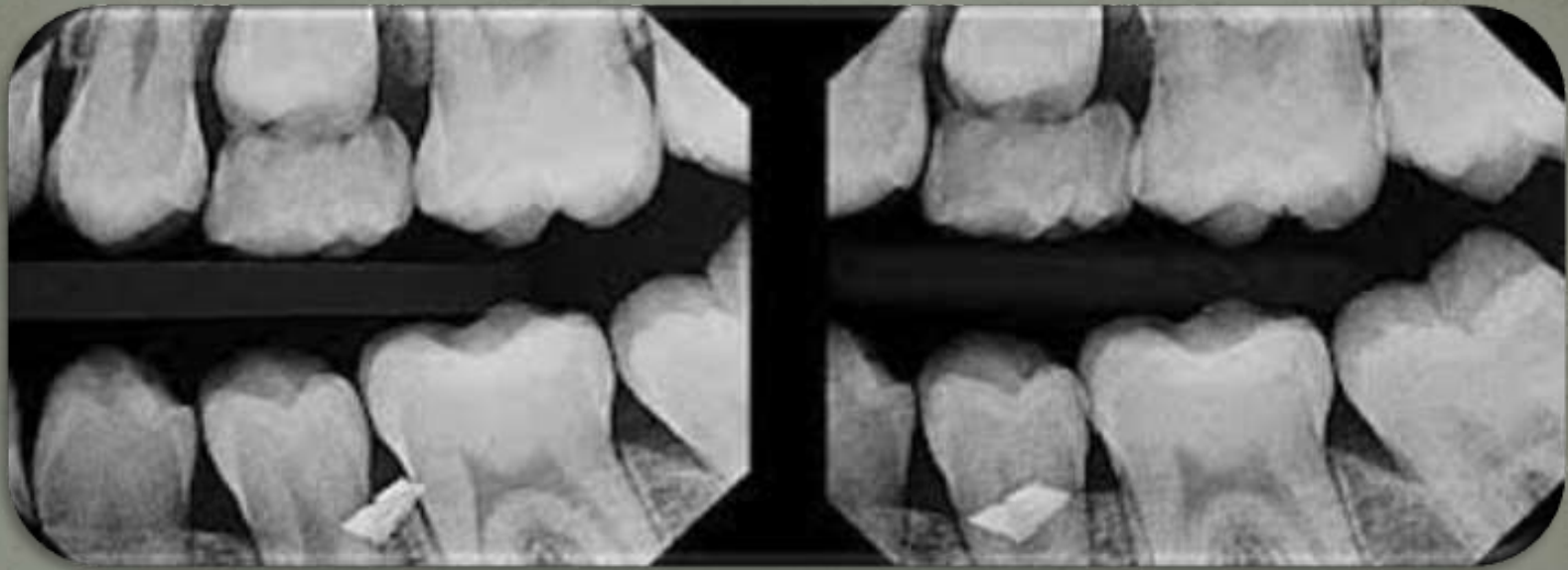
# Mandibular lateral view



# Anatomical landmarks of mandibula occlusal radiography

- Mental ridge
- Lingual Foramina
- Mental fossa
- Genial tubercle
- Soft tissue shadow of floor of mouth

# Object localization





# Intraoral localization techniques

- These are methods used to locate the position of a tooth or an object in the jaw.
- The dental radiograph is a 2D picture of a 3D object.
- It depicts the object in the superio-inferior and antero-posterior relationship or depth of the object.

# Indications

- Foreign bodies
- Impacted teeth
- Unerupted teeth
- Retained roots
- Salivary stones
- Jaw fractures
- Broken needles and instruments
- Root positions
- Filling materials

# Buccal object rule

(Tube shift technique or Clark's rule)

- The basic principal is that the relative position of the radiographic images of two separate objects changes when the projection mode is changed.
- A different horizontal angle is used when trying to locate vertically aligned images .e.g. root canals.
- A different vertical angulation is used when trying to locate a horizontally aligned images. e.g.. mandibular canal.



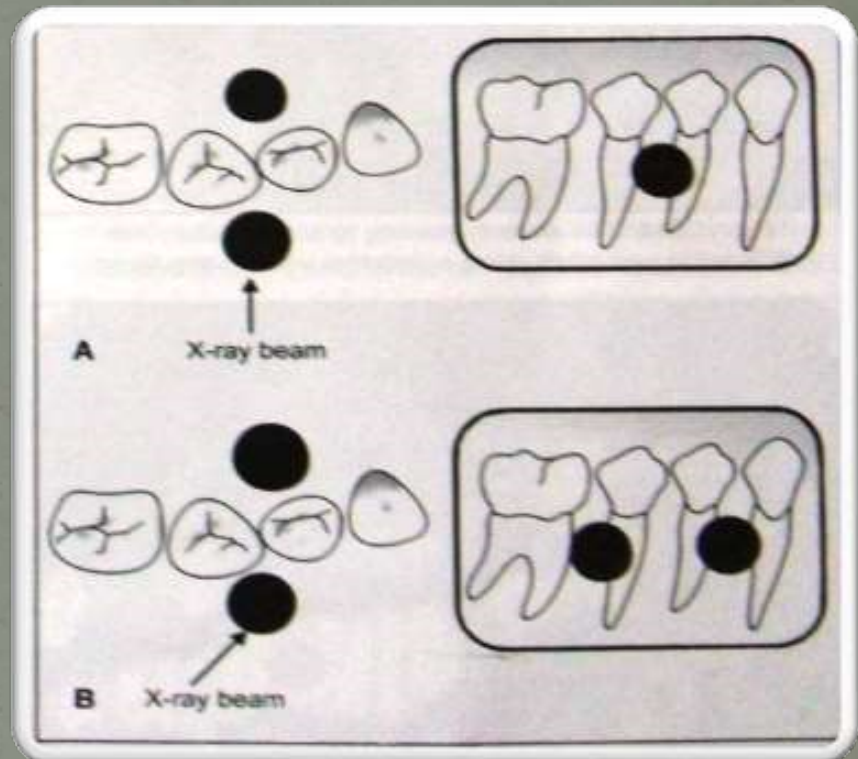
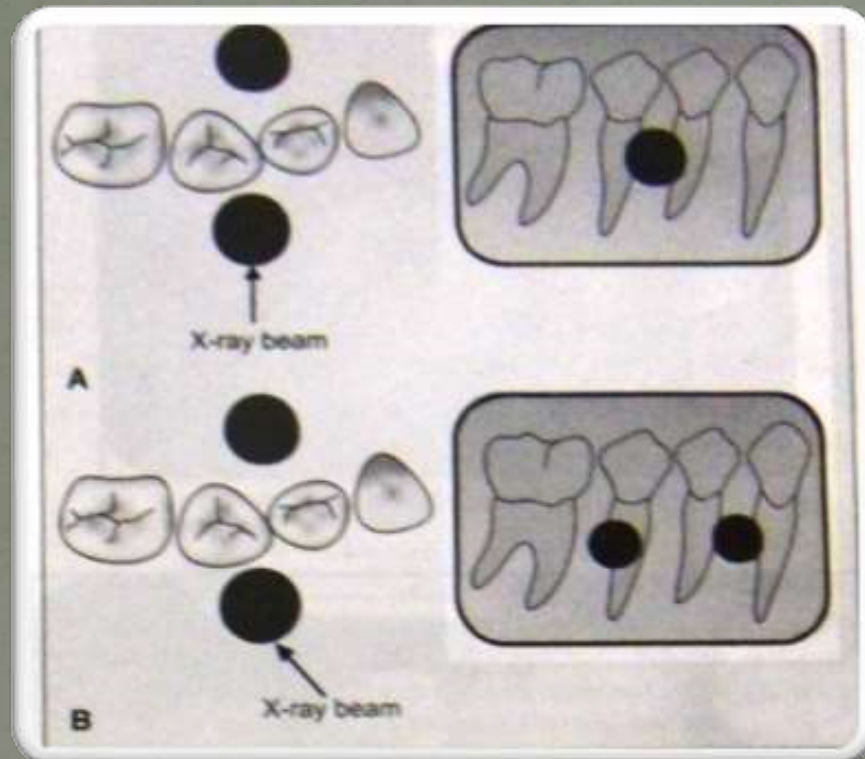
## Method:

- Two radiographs of the object are taken first using the proper technique and angulations as prescribed and the second radiograph is taken keeping all other parameters constant and equivalent of those of the central ray either with different horizontal or vertical angulation is used.

## Interpretation

- When the dental structure or object seen in the second radiograph appears to have moved in the same direction as the shift of the position indicating device(PID), the structures or object in question is said to be positioned lingually.
- If object appears to have in a direction opposite to the shift of the PID, then the object is positioned buccally.
- SLOB Rule- Same side Lingual Opposite side Buccal

# SLOB





## 2. Right angle technique

Here two projections are taken at right angles to each other, which helps to localize an object in the maxilla or mandible.

### Method

- A periapical radiograph is taken to show the position of the object superior-inferiorly and anterior-posteriorly.
- An occlusal radiograph is taken which will show the object's bucco-lingual and anterior-posterior relationship.
- The two radiographs when studied together help to localize the object in all three dimensions.

# stereoscopy

- It is used to determine the location of small intracranial calcification and multiple foreign bodies in dense or thick sections
- In cases where the interpretation of images produced at right angle may be difficult and to evaluate the relationship at margins of bony fractures.
- It requires the exposure of two films, one for each eye, thus raises the amount of radiation to the patient.
- Between exposures the patient is maintained in position, the film is changed, and tube is shifted from right to left eye.
- Although the magnitude of the tube shift which is empiric, it is sufficient to form slightly different images.
- A tube shift which is equal to 10% of the focal film distance has been found to produce satisfactory results.

- After processing ,the films are viewed with a stereoscope.
- Use of mirrors or prisms to coordinate the accommodation and convergence of the viewer's eyes so that the brain can fuse the two images.

This technique is popular for the evaluation of...

- Bony pocket in patients with periodontal diseases
- Morphology of TMJ area.
- Determination of root configuration of teeth that require endodontic therapy.
- Assessment of relationship of mandibular canal to the roots of unerupted mandibular 3<sup>rd</sup> molar.
- Assessment of bone shape when the placement of dental implants is considered.





**Thank  
You**