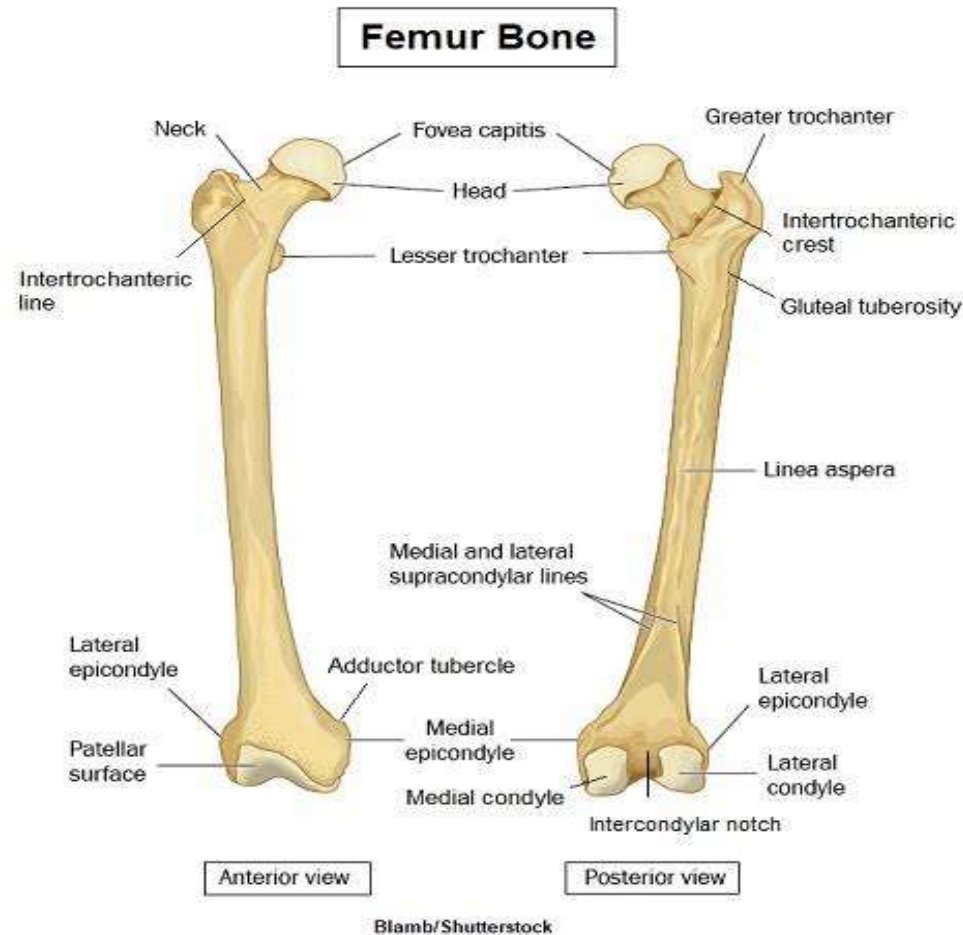


Thigh x ray views  
By  
S.S.SIVA SAGAR  
TEACHING ASSISTANT  
RADIOLOGY  
CENTURIAN UNIVERSITY

# Views

1. Thigh AP view( lower 2/3 rd).
2. Thigh lateral view( lower 2/3 rd).



# Thigh x ray indications

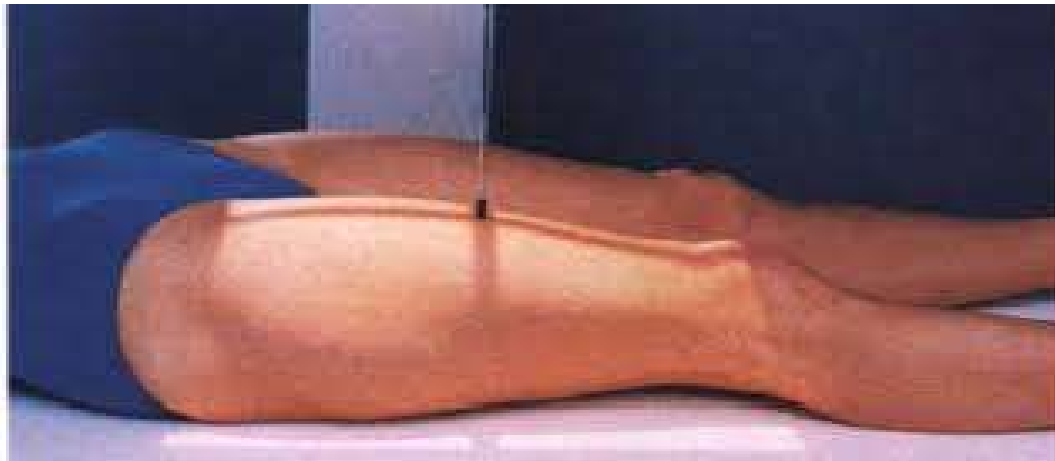- ◆ trauma
- ◆ obvious deformities
- ◆ suspected foreign body
- ◆ inability to weight bear
- ◆ osteomyeliti.
- ◆ Swelling of thigh.

# Contraindications

**Pregnancy**

# Thigh x ray AP view Positioning

- Patient lies supine on x ray table with both legs extended.
- Unaffected leg is abducted and held in comfortable position.
- Knee joint of affected side is included in cassette.
- Lower leg is immobilised with sand bags , side is marked and beam is collimated.



# Preparation

- ① **Collect History from patient.**
- ② **Patient is asked to remove all radiopaque materials.**
- ③ **Wear hospital gown.**
- ④ **If female patient come to x ray , chaperone is necessary.**
- ⑤ **Shielding is provided to patient.**

# Thigh x ray lateral view positioning

- Patient lies laterally on x ray table with affected side, hip and knee slightly flexed.
- The lateral aspect of affected thigh is placed on cassette.
- Limb is immobilised with sand bags under the ankle.
- Knee joint included in cassette. Side is marked and beam is collimated



# Centering

**Thigh AP : It is done on anterior aspect of thigh to center of cassette.**

**Thigh lateral : it is done on medial aspect of thigh.**



# Technique

**KVp : 65**

**mAs:20**

**FSS : large.**

**FFD :100 cms.**

**With grid**

**Cassette size: 14"x 14"**

**SUCCESS IS  
DEPENDENT ON  
EFFORT.**

*QuoteHD.com*

**Sophocles**  
Ancient Greek Playwright  
496 BC - 406 BC