

# WHAT IS 'THE SHOULDER'?

## 1. **glenohumeral** joint

synovial (hyaline cartilage), ball-and-socket —  
mobile

## 2. **acromioclavicular** joint

synovial — limited movement; passive; no muscles  
act on joint

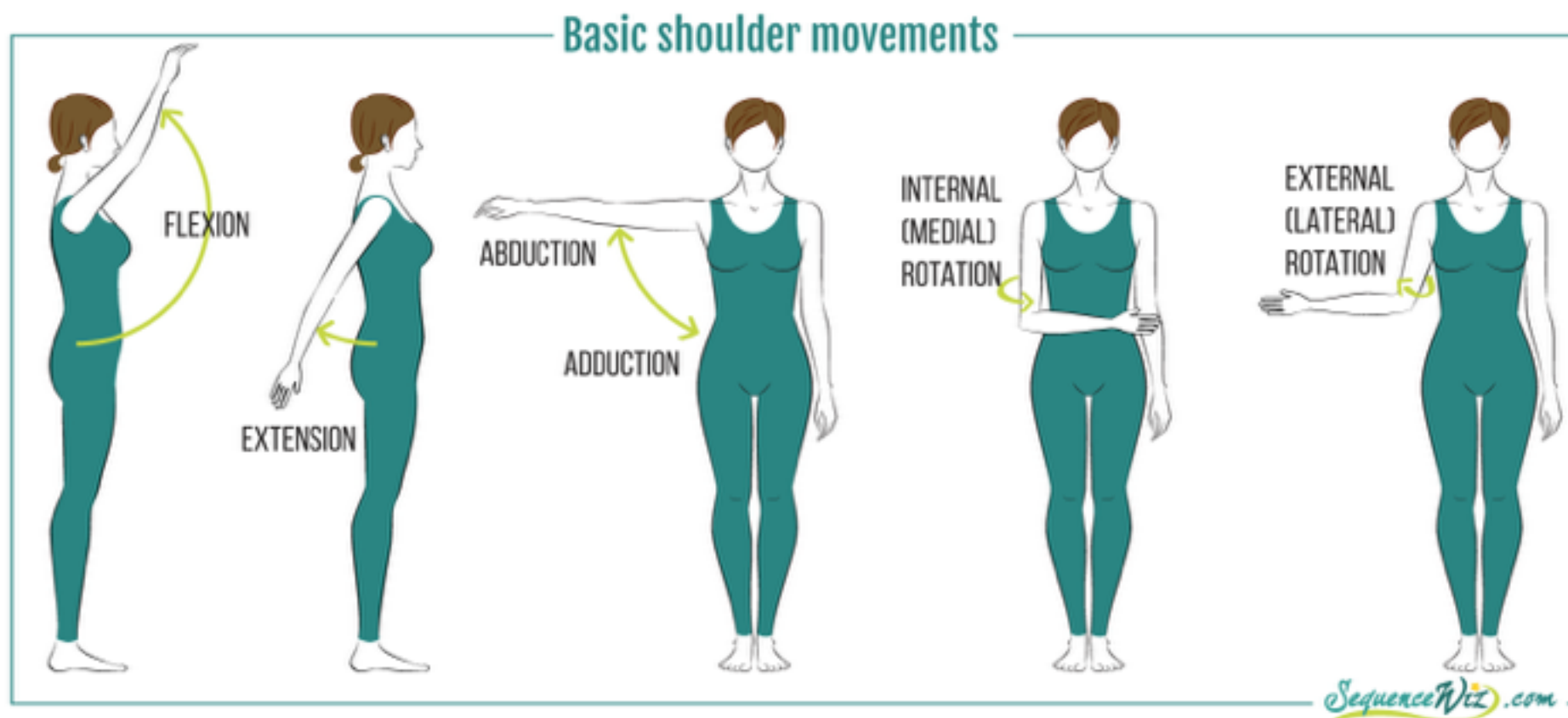
## 3. **sternoclavicular** joint

synovial, saddle (double-planed) — mobile

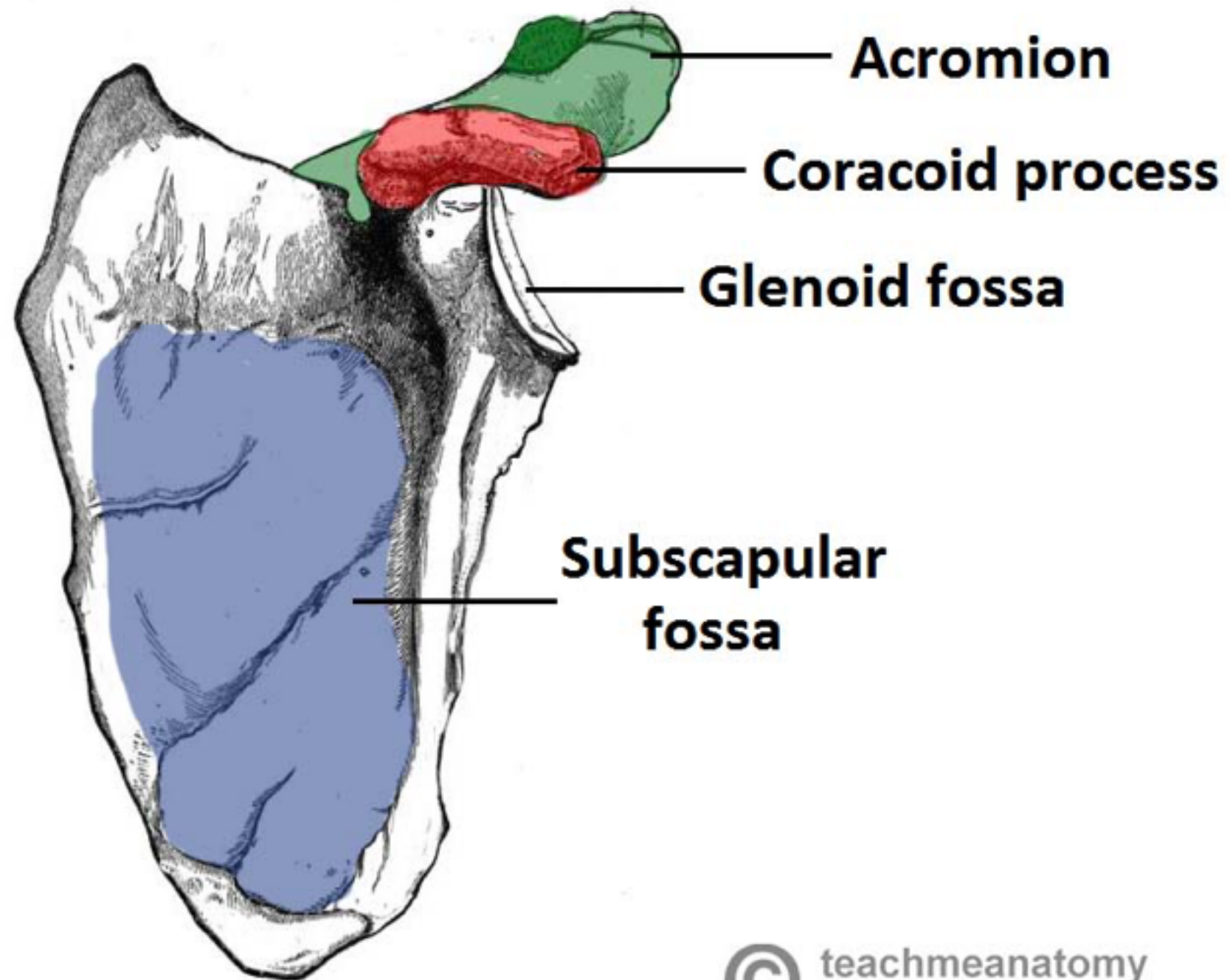
# Movements possible:

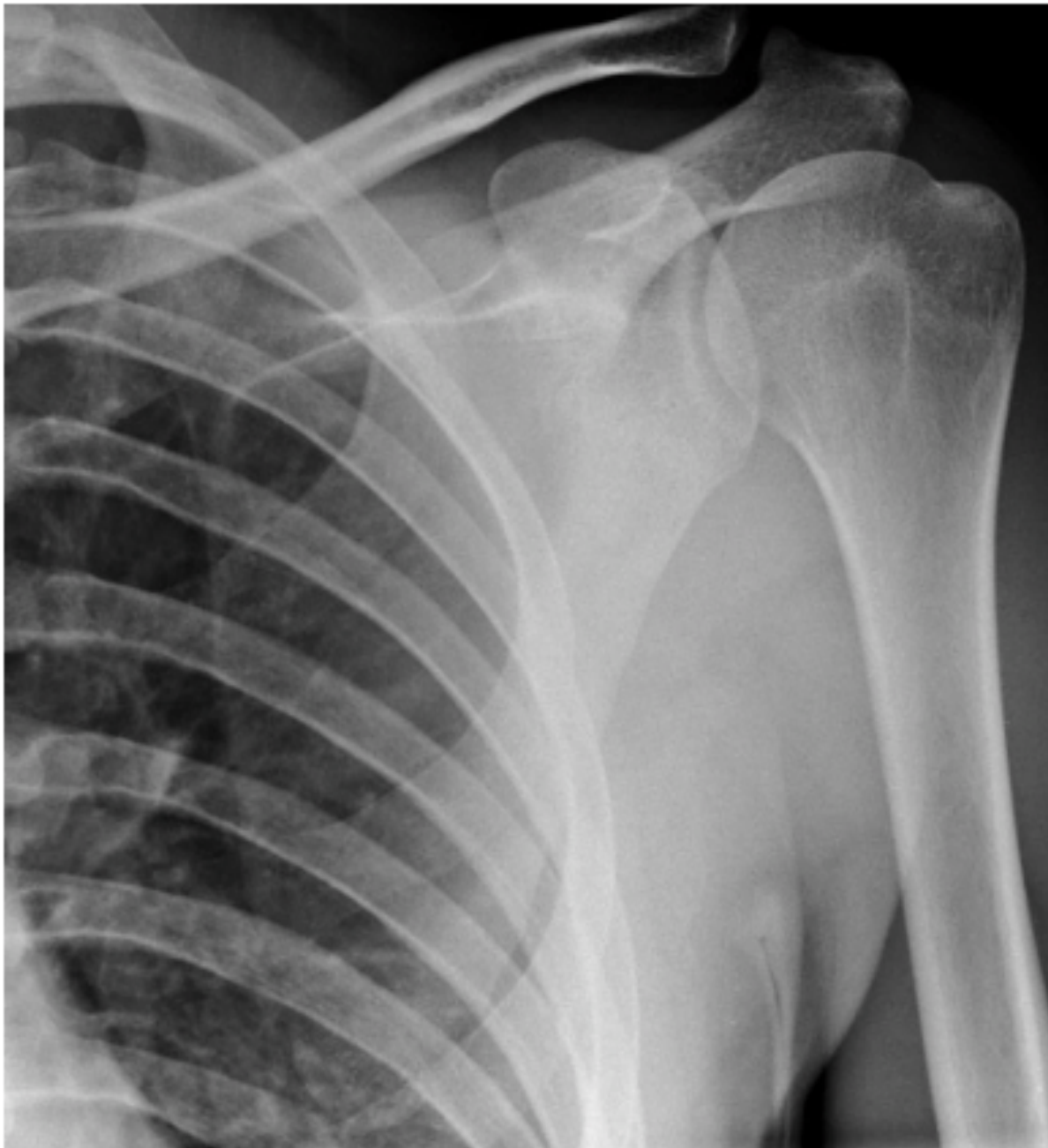- *flexion and extension of humerus*
- *abduction and adduction of humerus*
- *medial and lateral rotation of humerus*
- *scapulathoracic movement*

These movements in fact encompass **3** joints

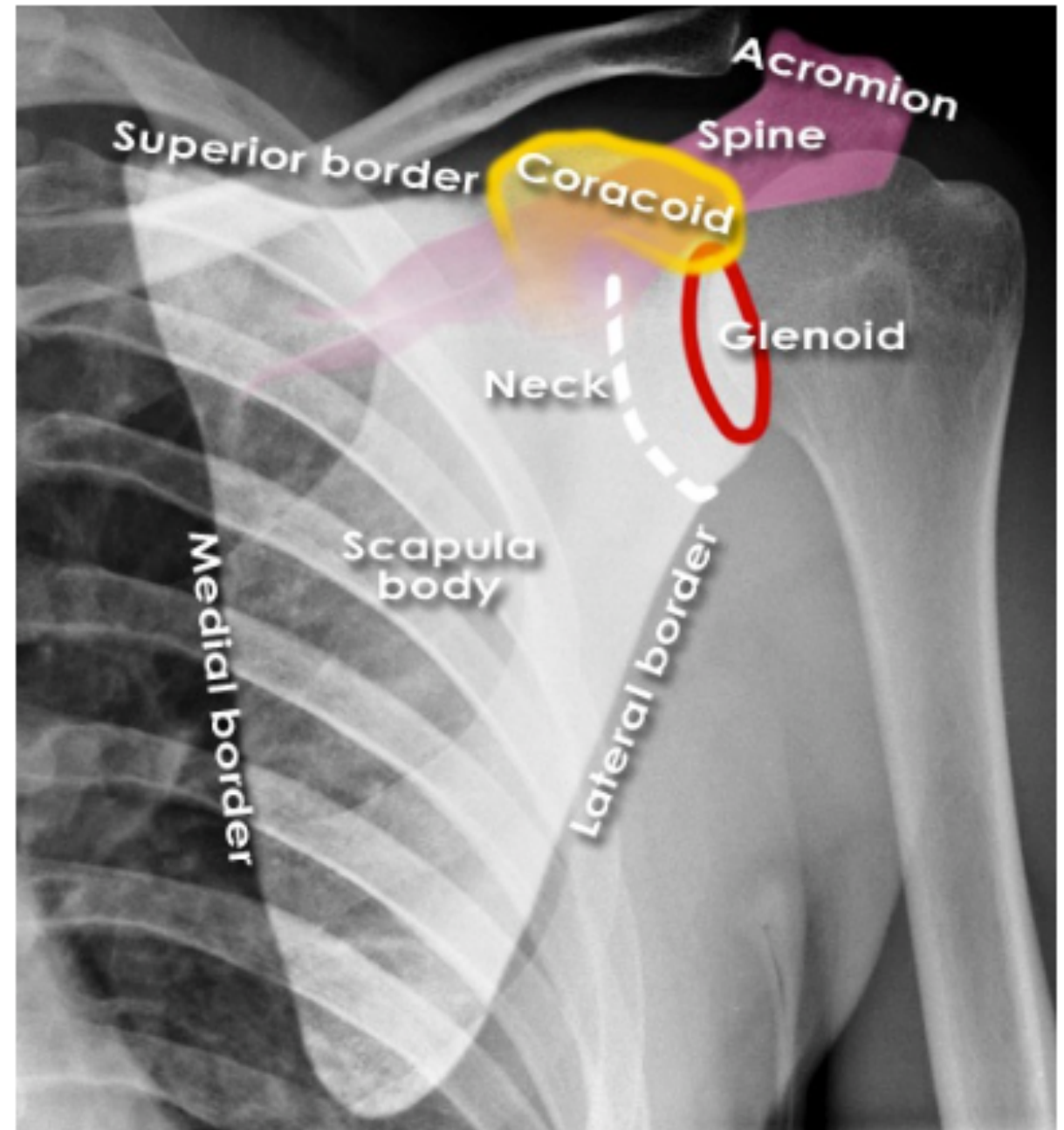


# Scapula — bony anatomy





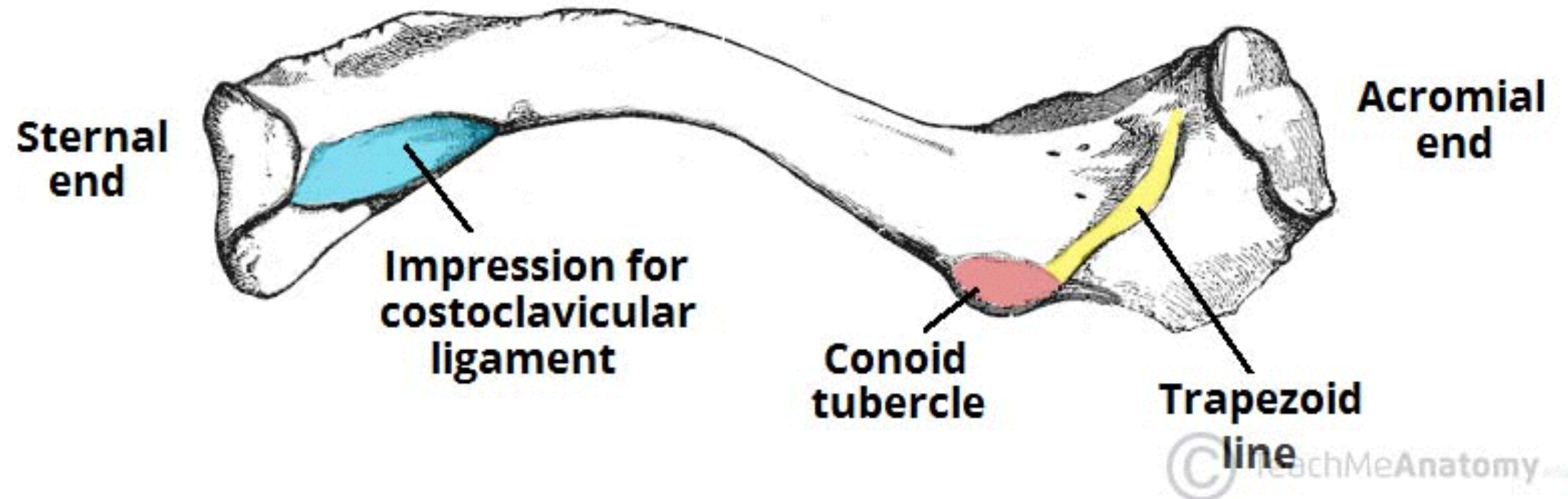
[Click image to align with top of page](#)

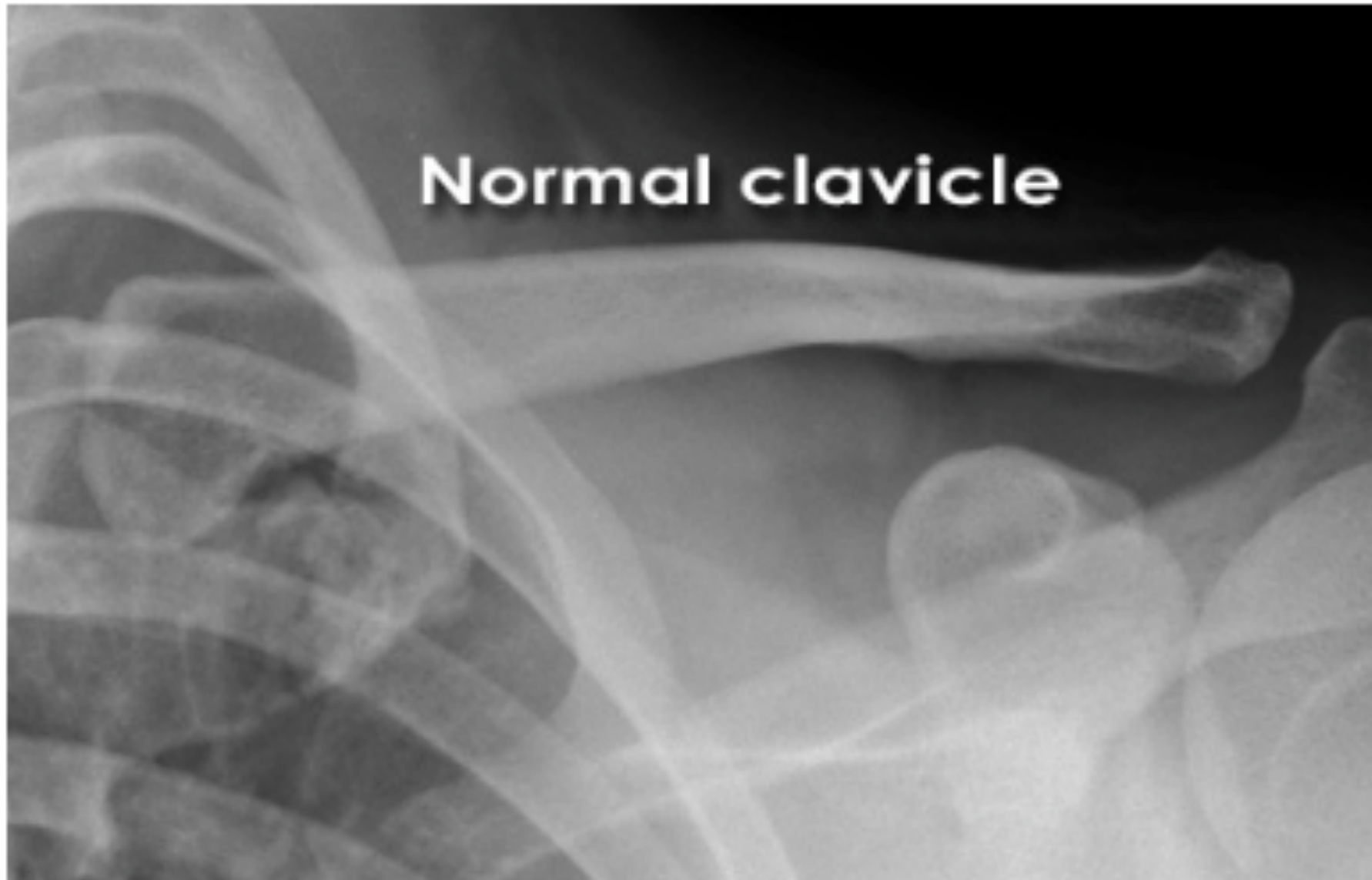

Source: Radiology MasterClass



# Clavicle — bony anatomy



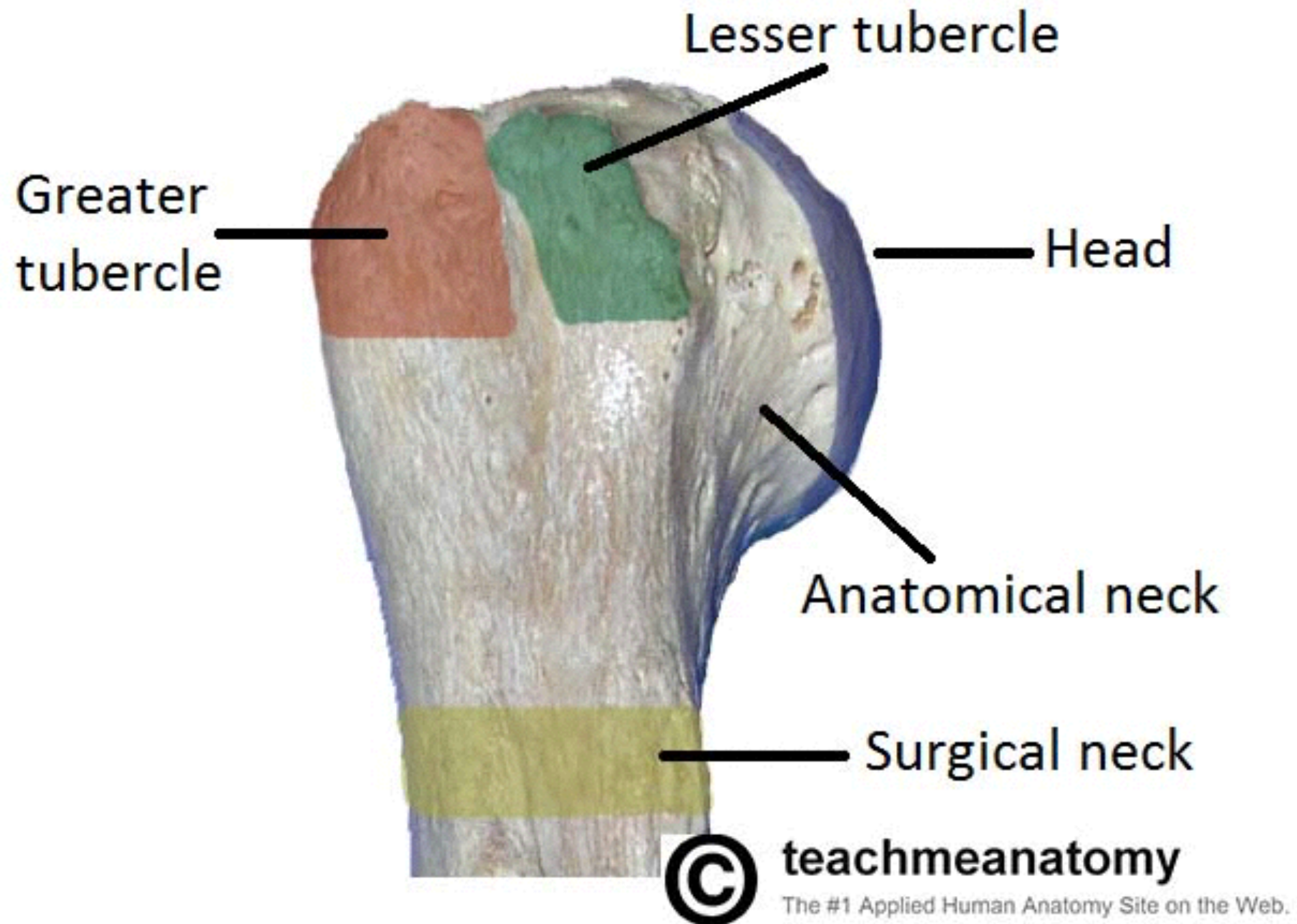


**Normal clavicle**

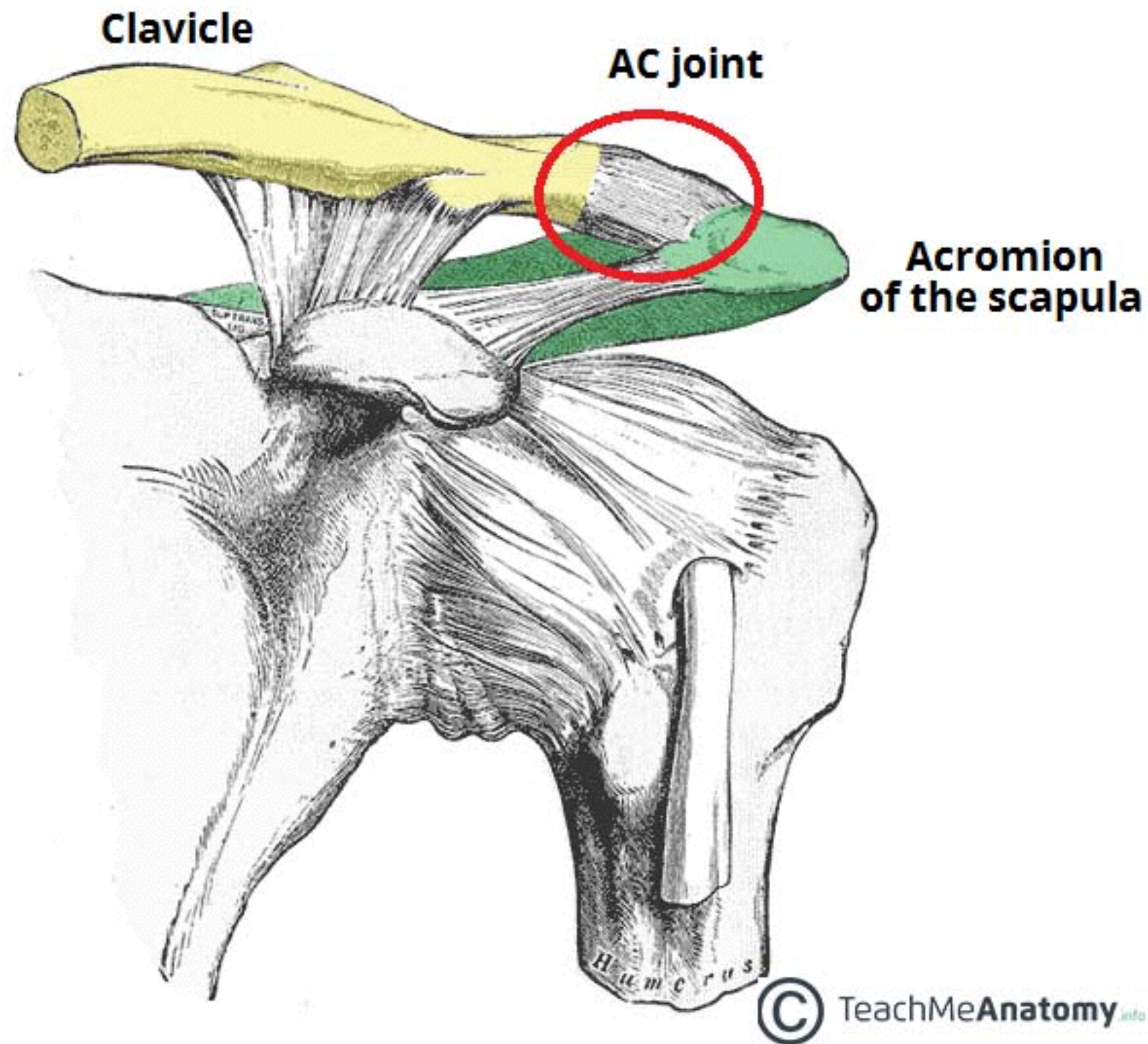
[Click image to slide with top of page](#)

Source: Radiology MasterClass

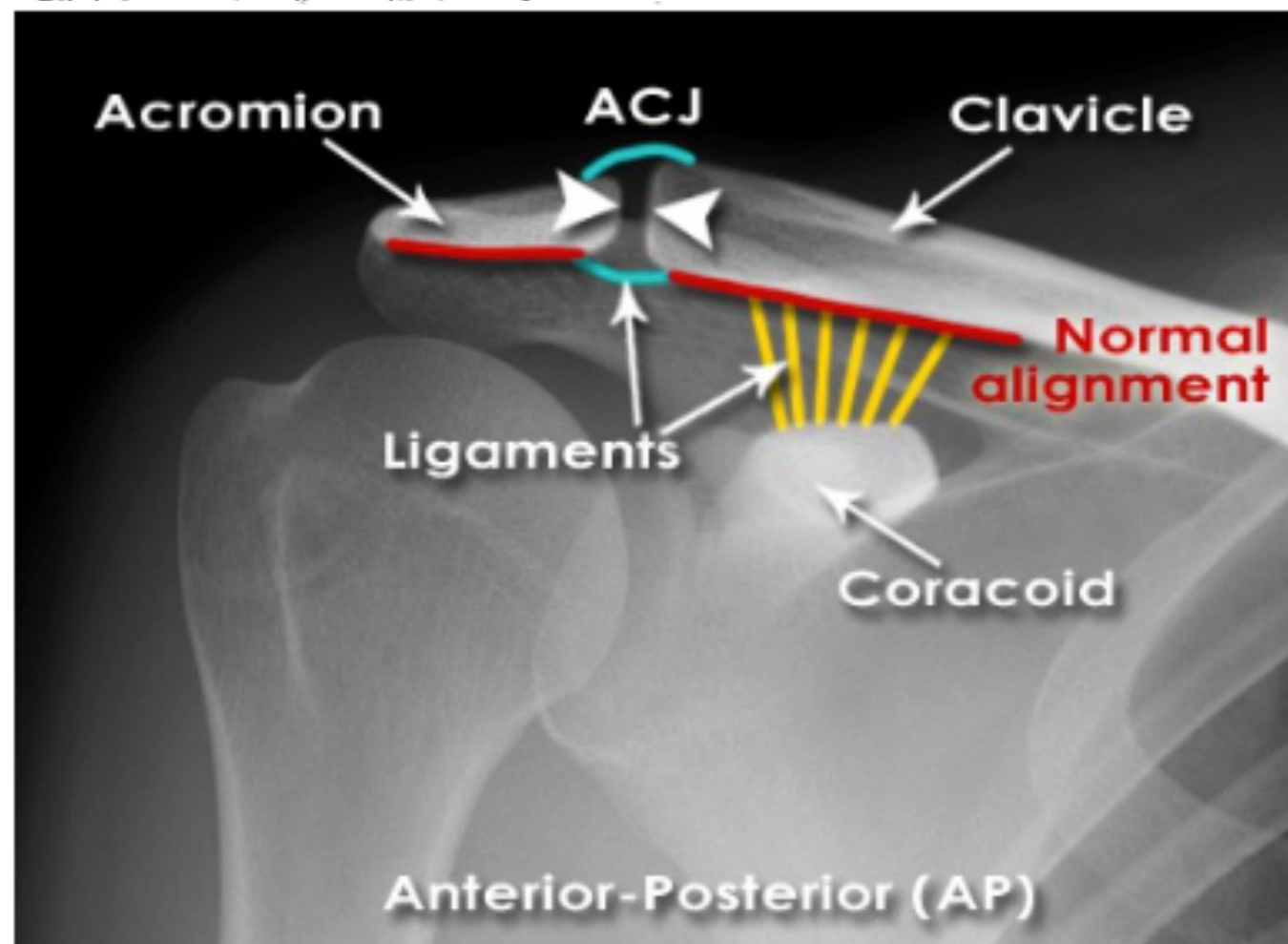
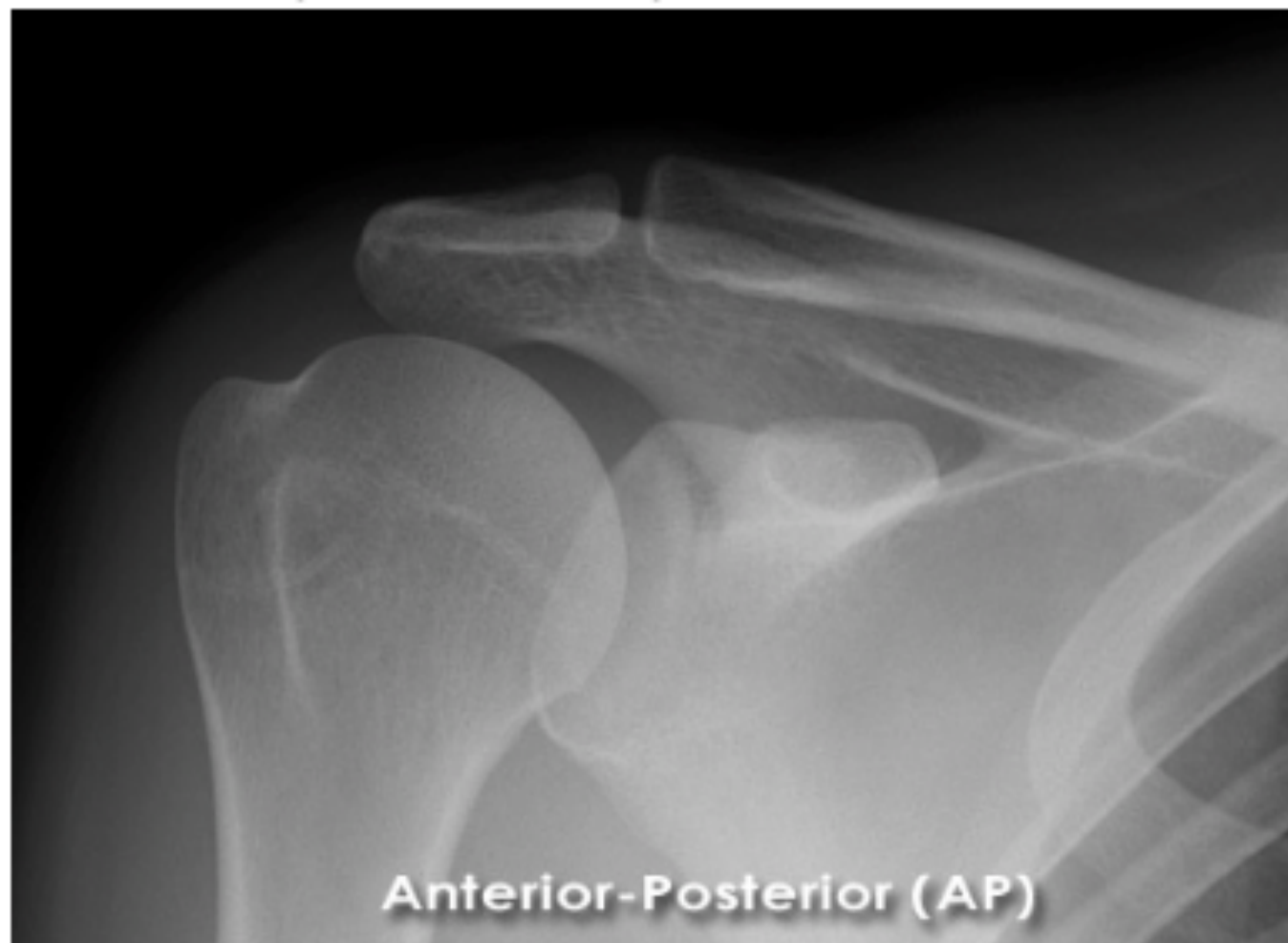# Humerus — bony anatomy



# Acromioclavicular joint

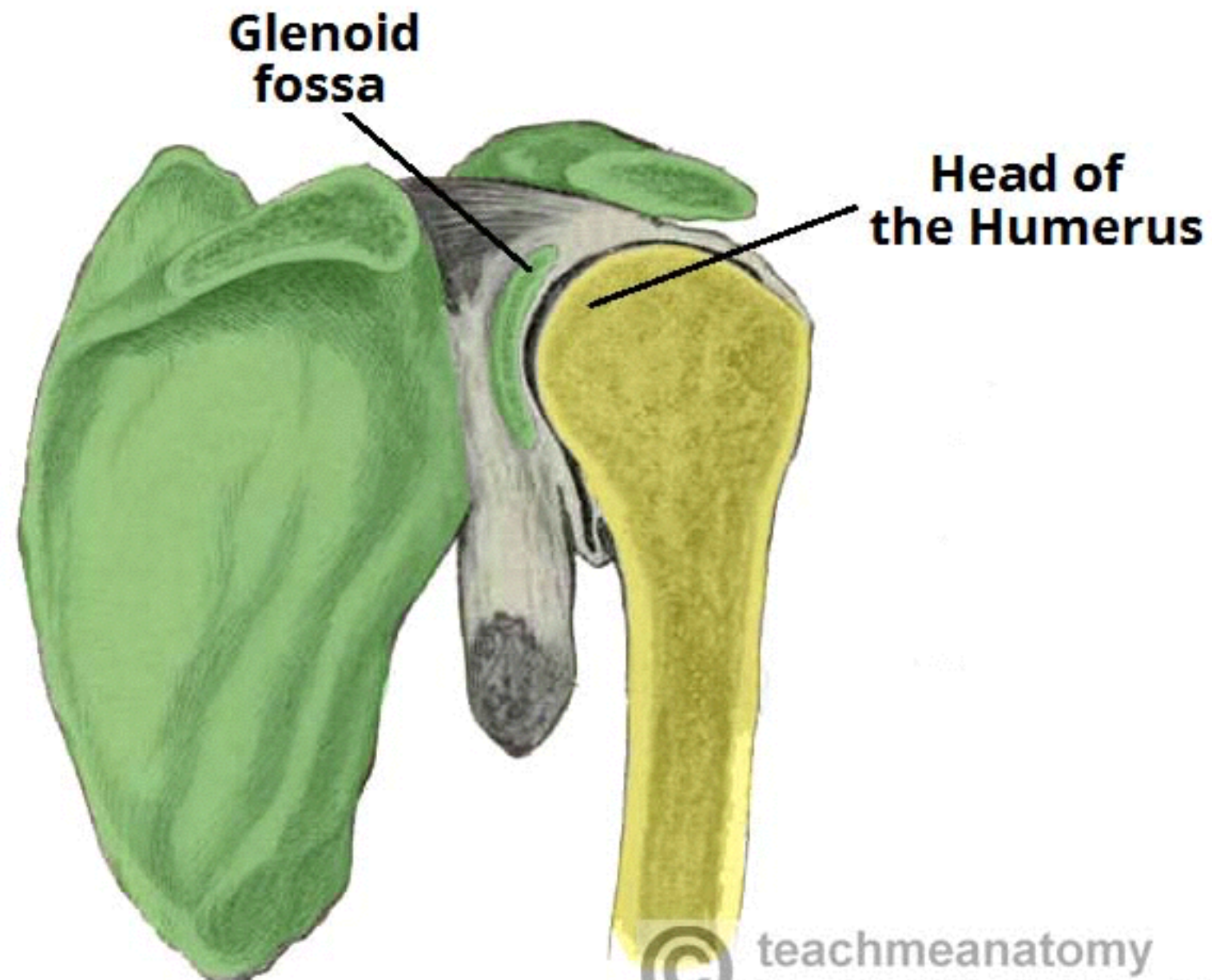






Source: Radiology MasterClass

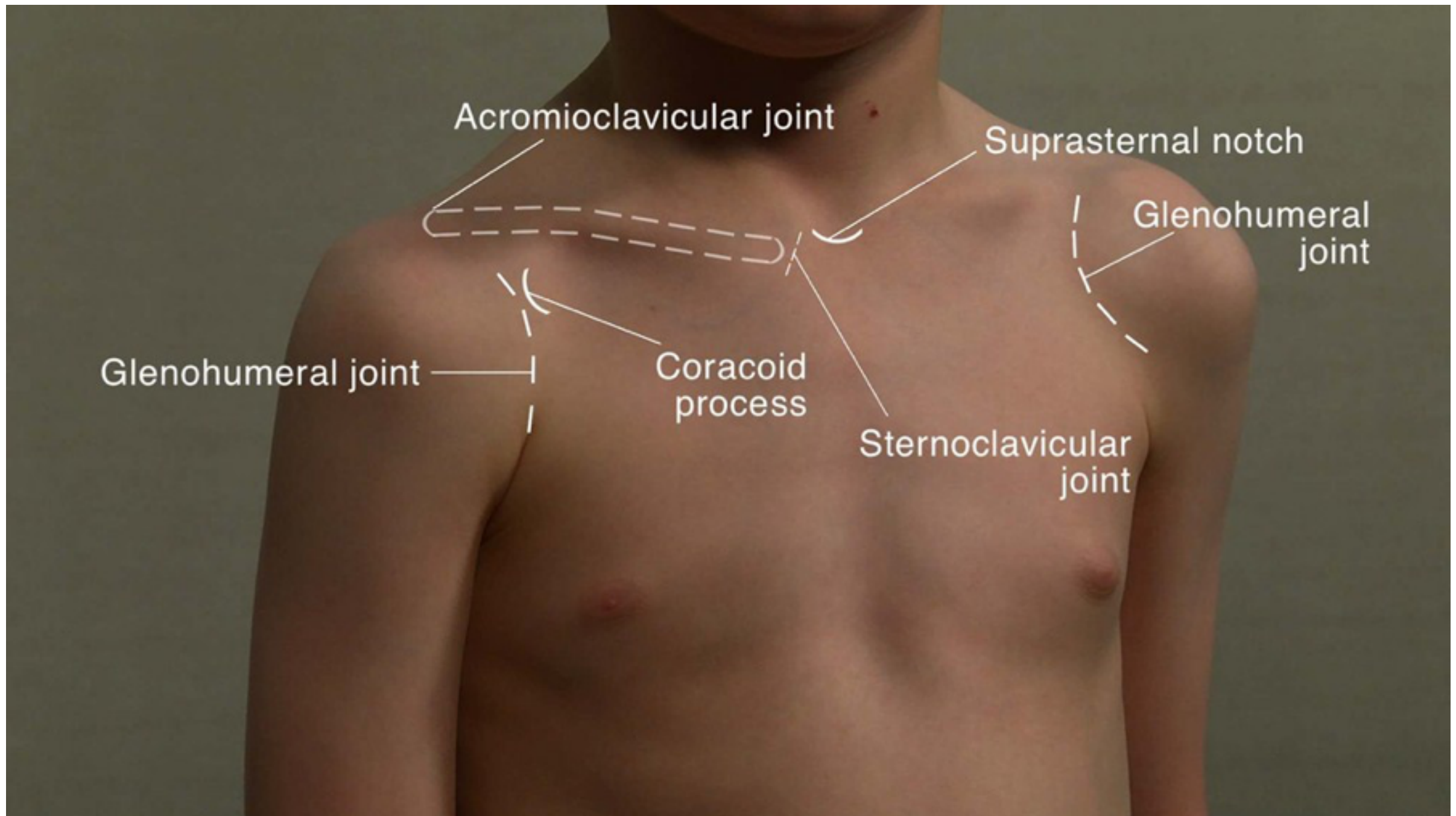
# Glenohumeral joint



**teachmeanatomy**

The #1 Applied Human Anatomy Site on the Web.

# Surface anatomy



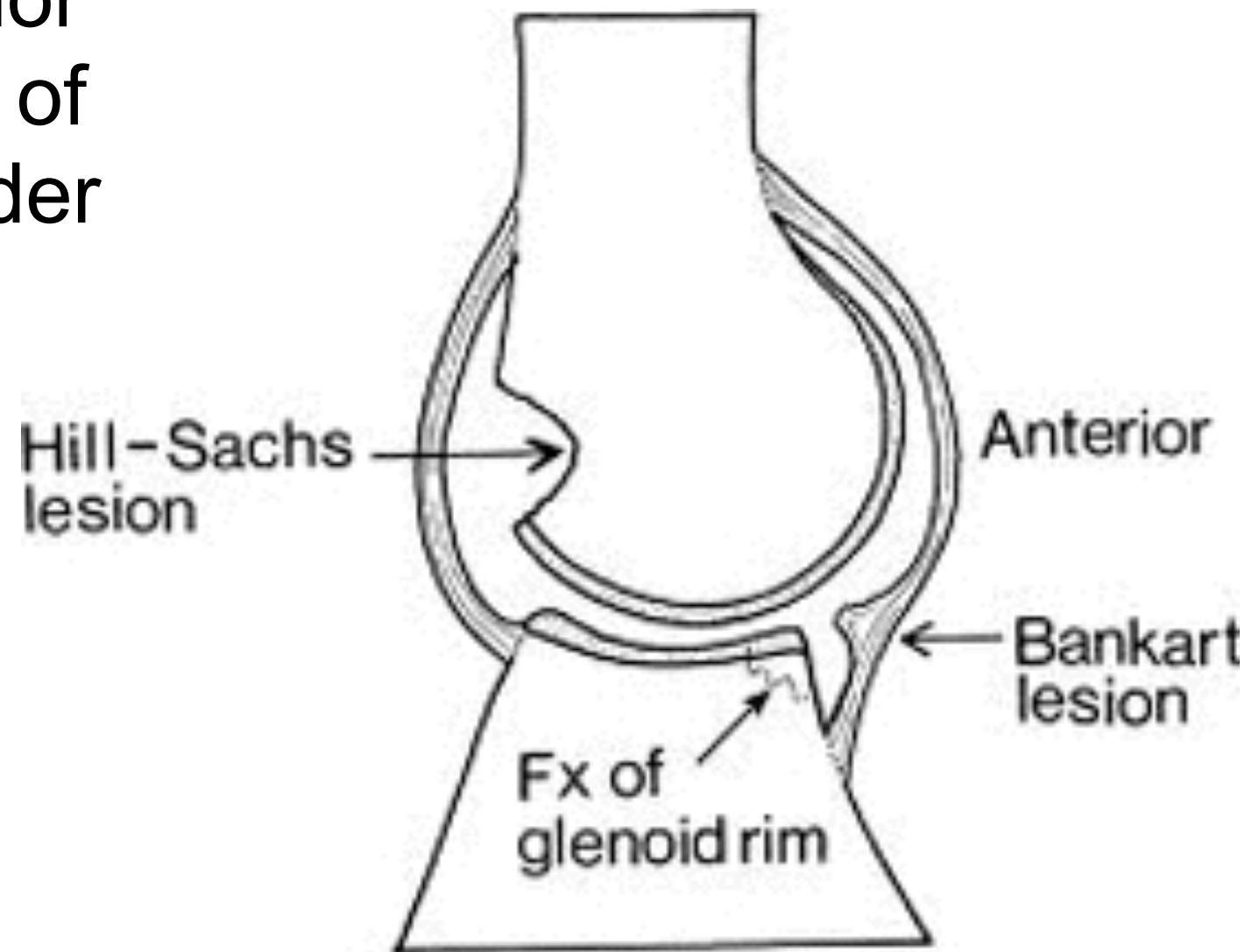
# Traumatic anterior shoulder instability

a.k.a. 'anterior dislocation'

- **loss of articulation between head of humerus and glenoid cavity of scapula**
- common; 80-90% in teenagers; high recurrence rate
- **mechanism:** anteriorly directed force on arm during shoulder abduction and external rotation
- **associated injury:** labral and cartilage injuries, #s and bone defects (e.g. Hill Sachs defect of posterosuperior humeral head, #s of greater & lesser tuberosity,), axillary nerve injury, rotator cuff tears



# Complications of anterior dislocation of shoulder



# Grading during follow-up to assess joint stability

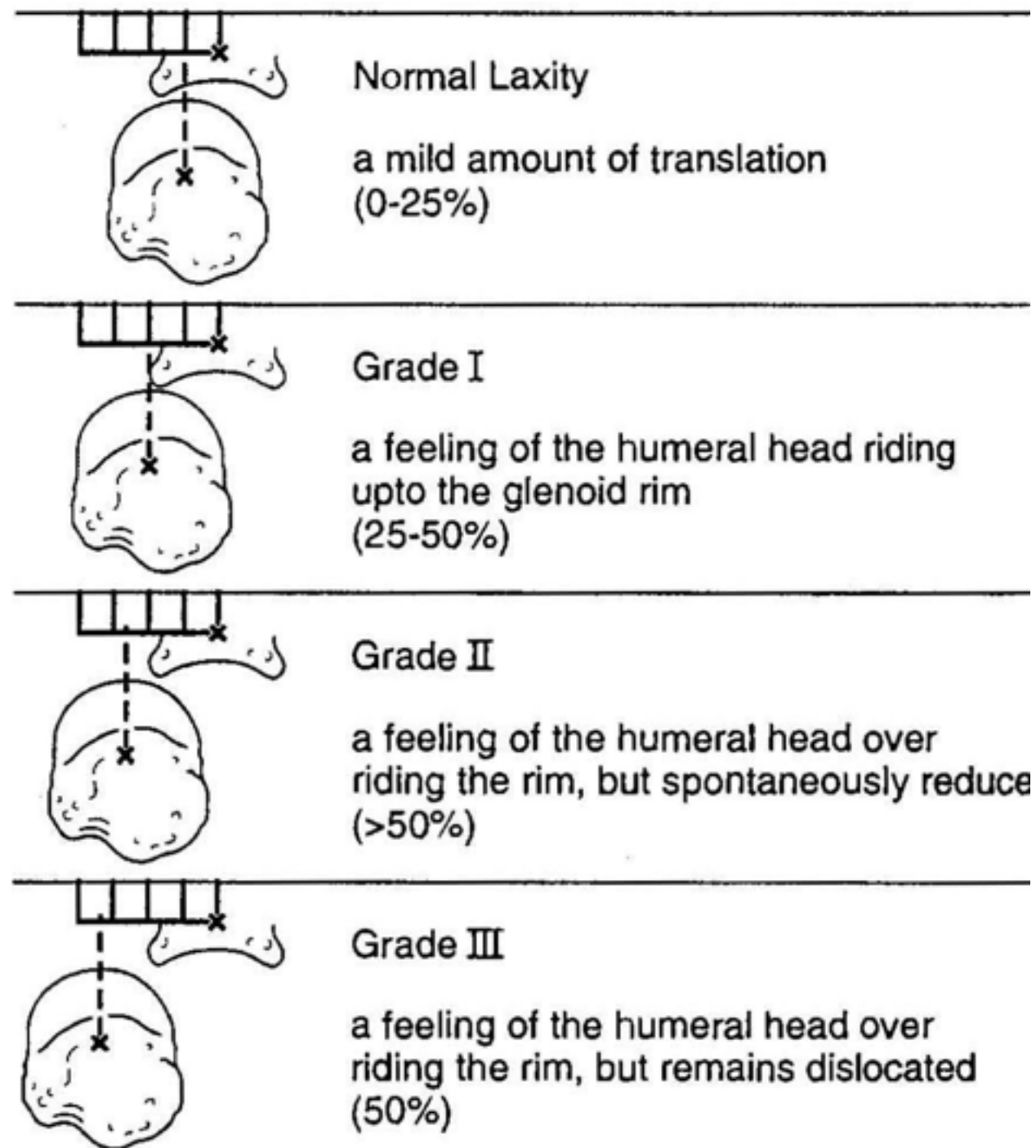
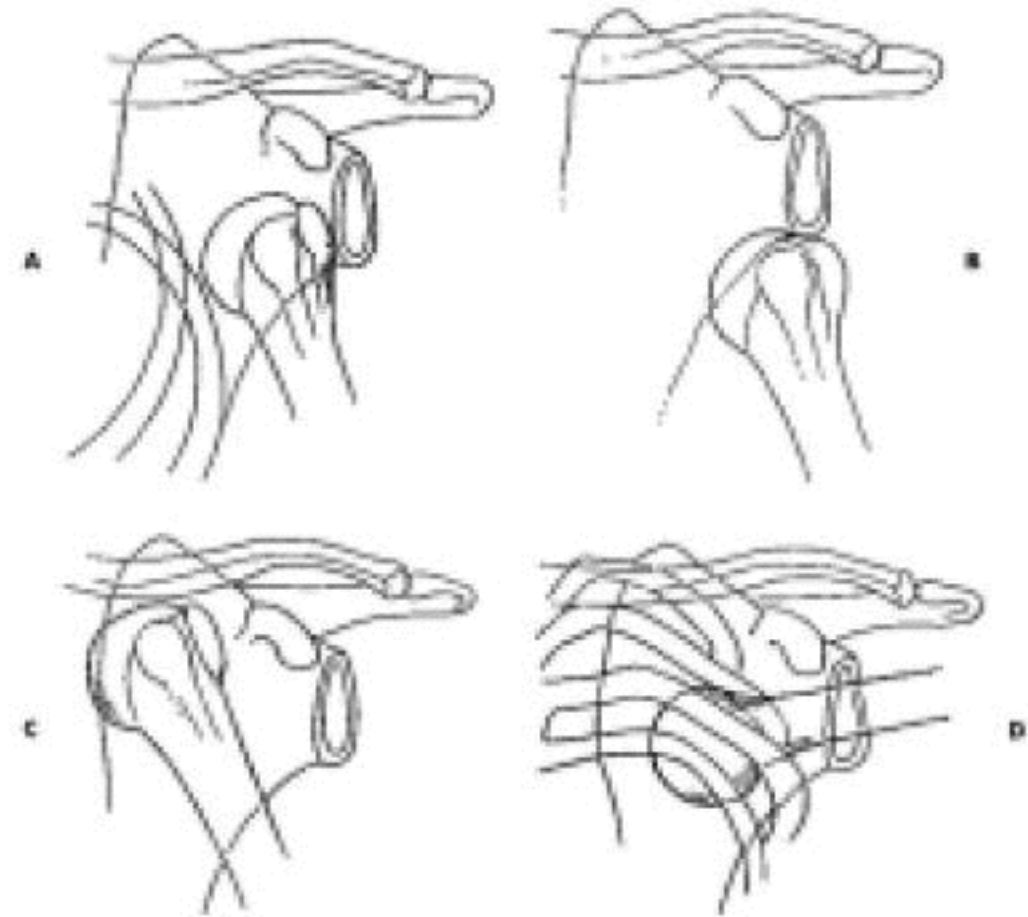


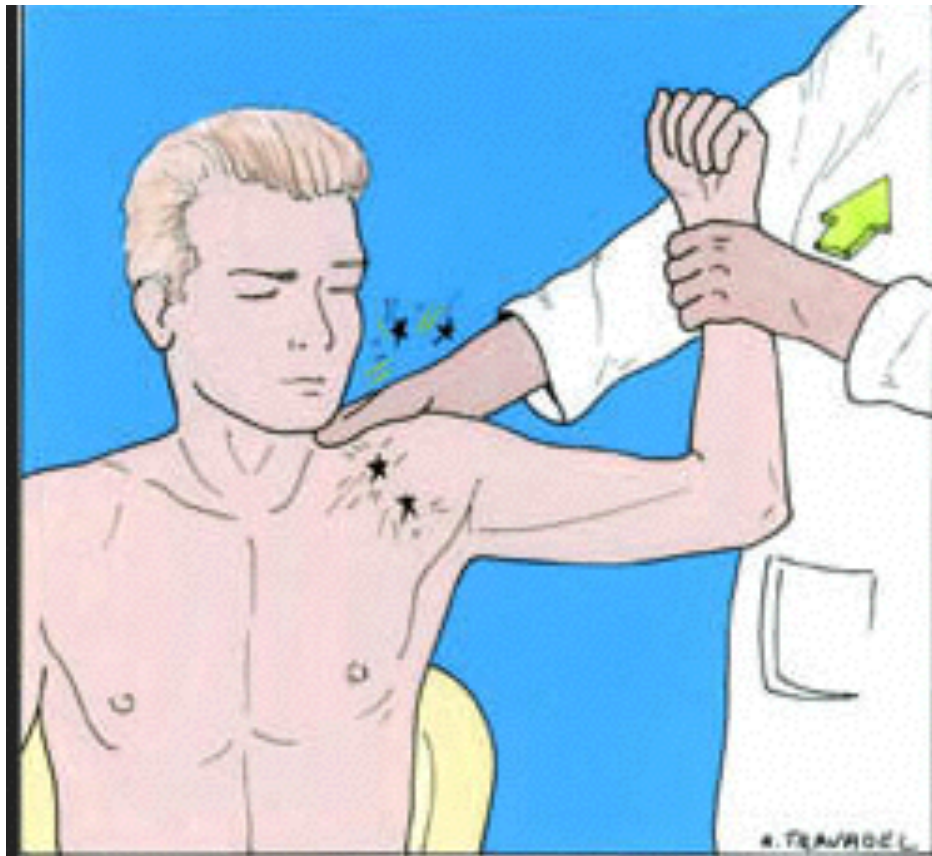
Figure 3. Types of anterior glenohumeral dislocations.



A: subarachnoid; B: subglenoid; C: subclavicular; D: intrathoracic.

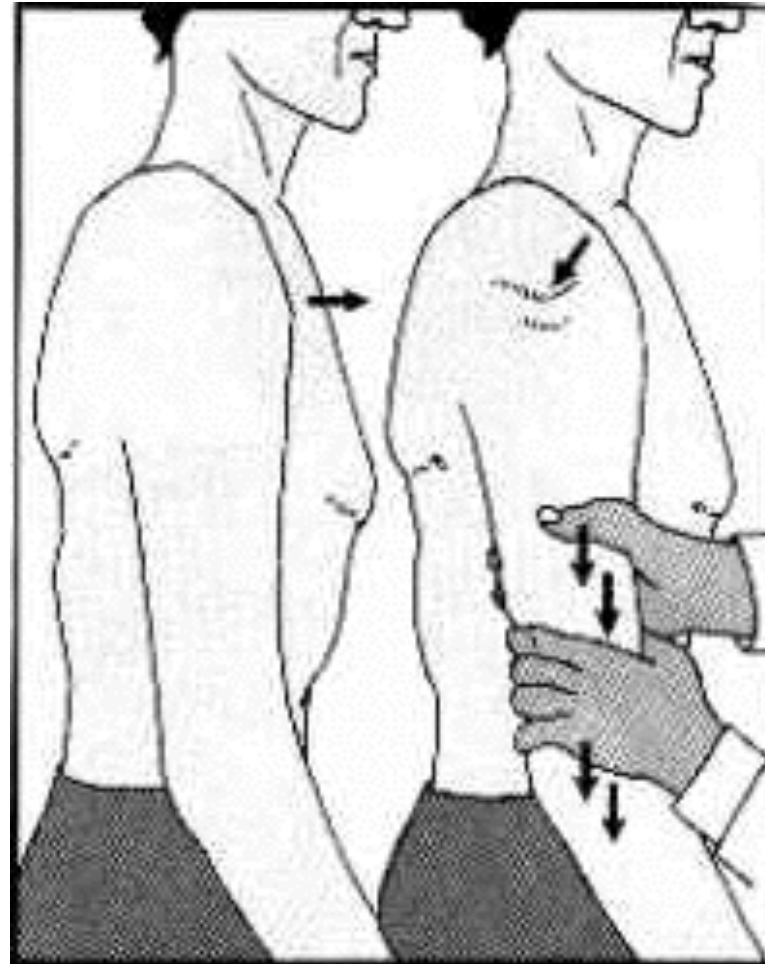
Reproduced with permission from: Marx JA, Hockberger RS, Walls RH, et al. eds. *Rosen's Emergency Medicine*. 5th ed. St. Louis: Mosby; 2002:593. Figure 46-26. With permission from Elsevier Science.

## Clinical picture



**‘Apprehension sign’**

**‘Relocation sign’** — relief  
of symptoms when  
applying anterior force to  
90-90 position



**‘Sulcus sign’** — *can  
grade by sulcus length*

- *Shoulder pain*
- *Instability*

# Management

- **Investigations**

- Trauma series — true AP, scapular Y, axillary  
CT for bony injuries  
MRI for labral tears

- **Conservative treatment**

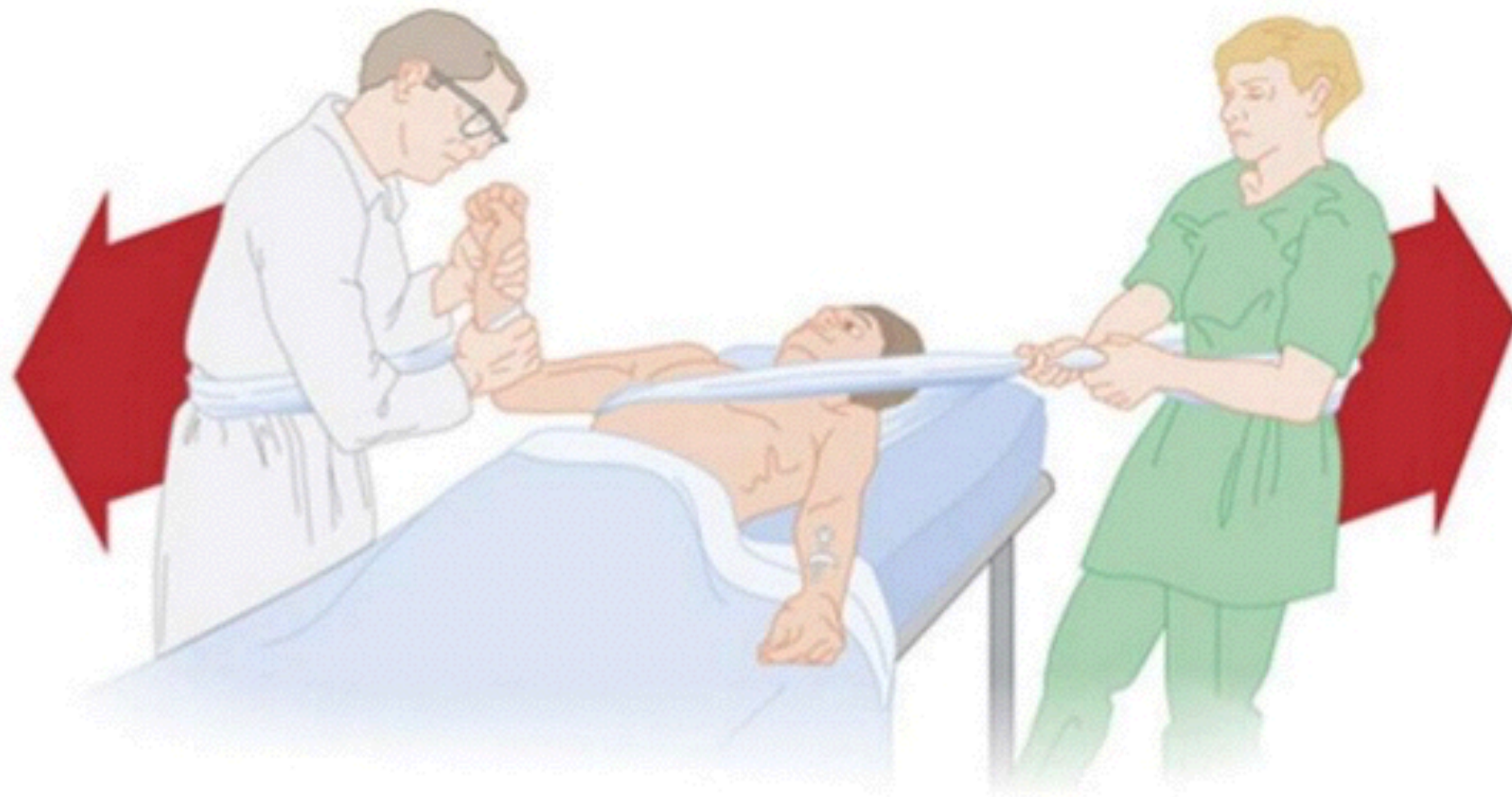
Acute reduction under analgesia, immobilisation,  
physiotherapy

- **Operative**

May include open or arthroscopic repairs of lesions

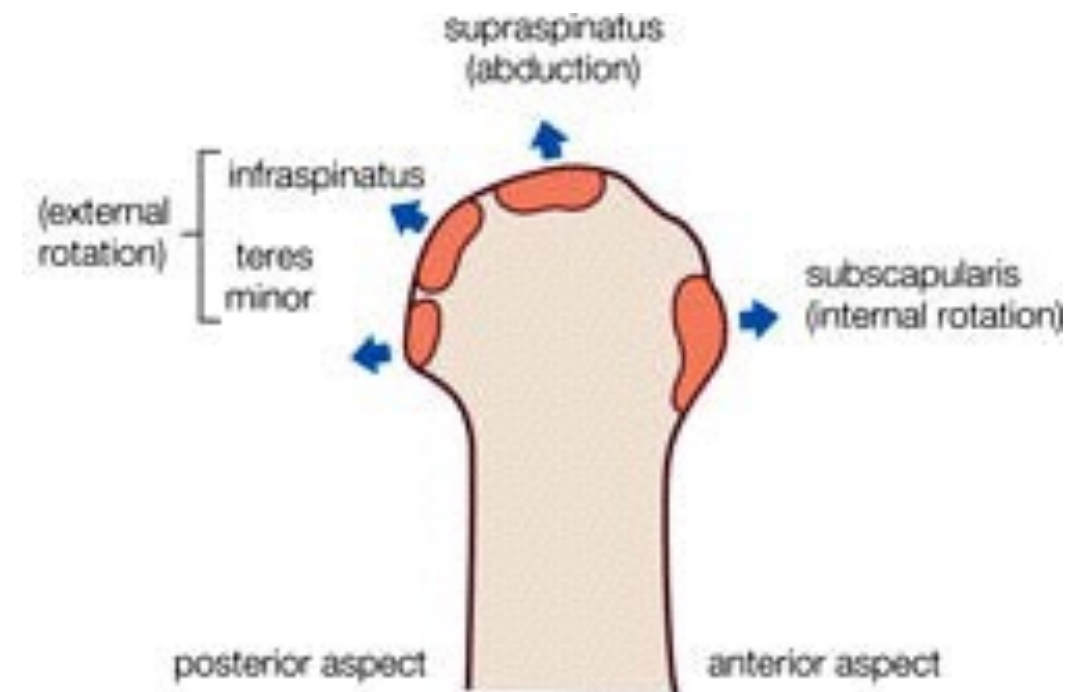

## Traction-countertraction



# Rotator cuff tears

- Part of a 'continuum' of **rotator cuff disease** and **impingement**
- **Tears of rotator cuff muscles that maintain stability of glenohumeral joint** (*supraspinatus, infraspinatus, teres minor, subscapularis*; at least 1 tendon involved)
- **Mechanism:**
  - **chronic degenerative**
  - **acute avulsion injury** (falls, shoulder dislocations)
  - **iatrogenic** (surgical failure)
- Common in athletes who **throw**



- Clinically — patient complains of **pain** and **weakness**
- Pain comes on **insidiously** and is exacerbated by **overhead activities**
- Test movements against resistance:
  - Abduction
  - External rotation
  - Internal rotation (subscapularis)

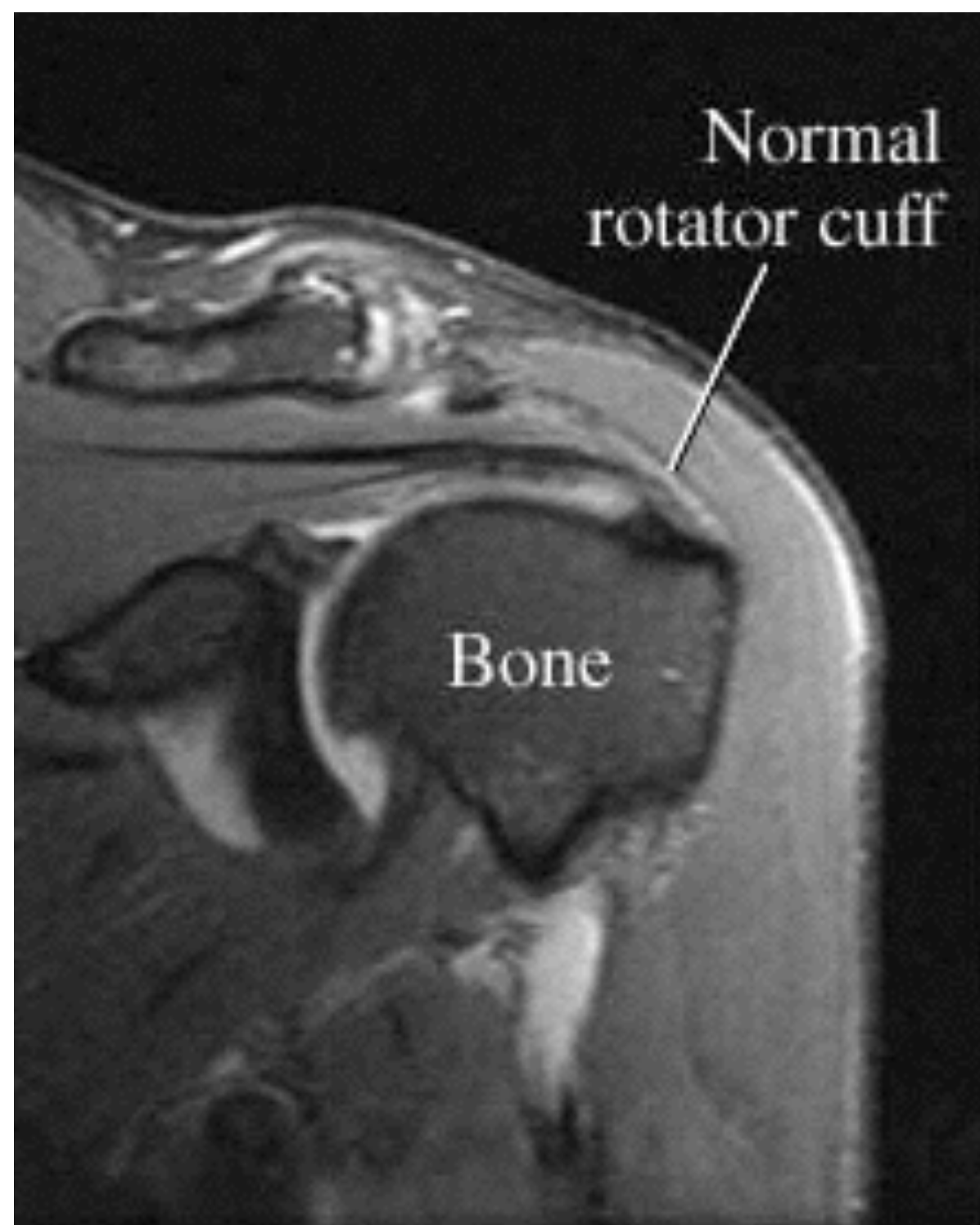


Figure 1

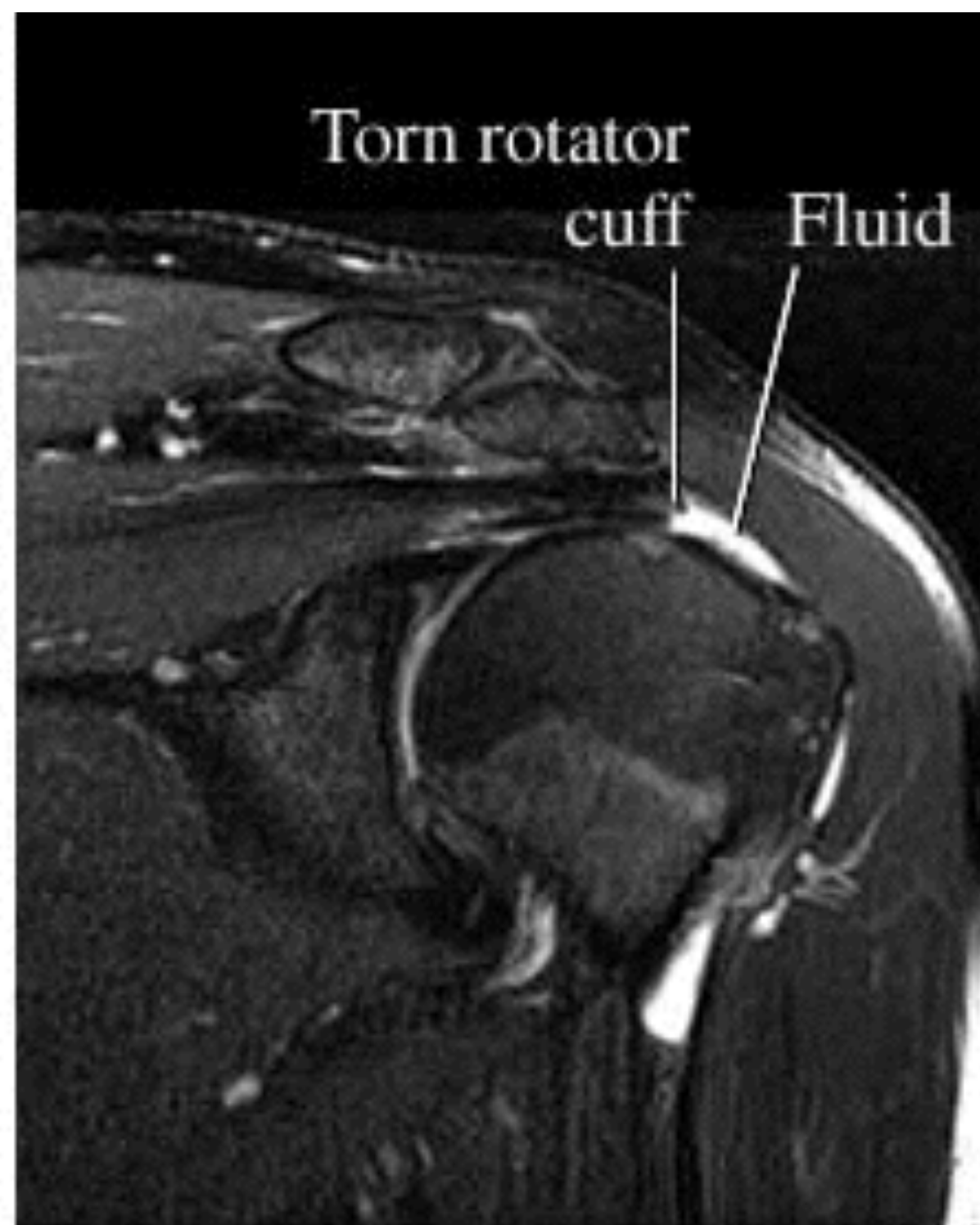


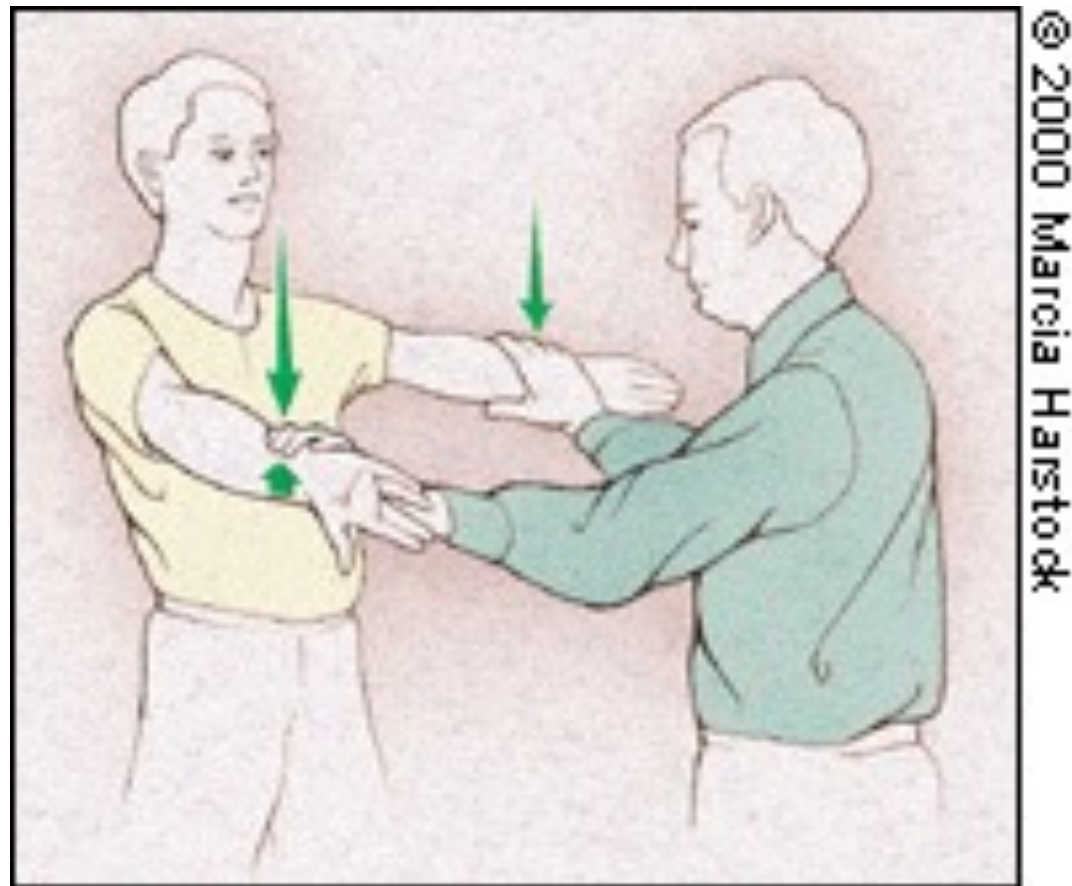
Figure 2



# Supraspinatus — special tests

(action: *abduction*)

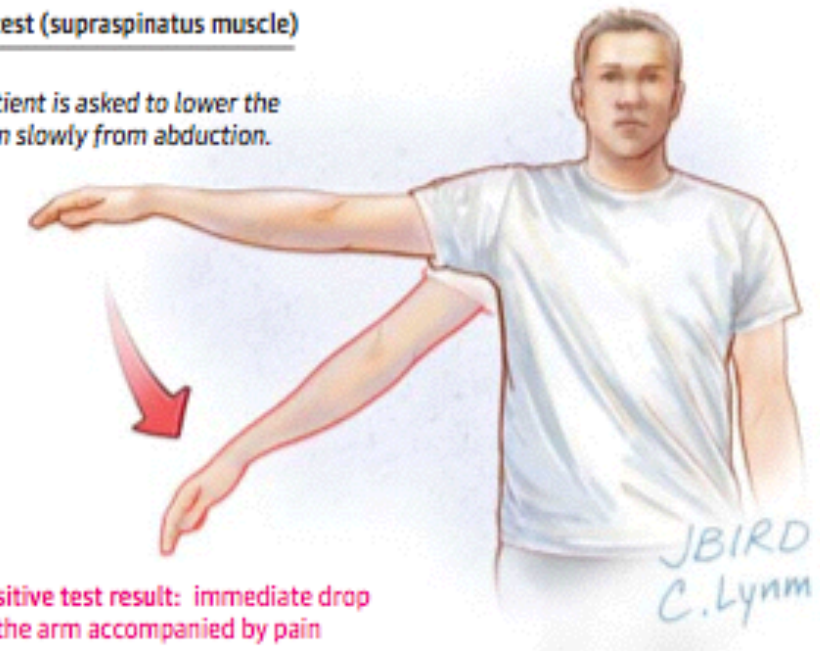
## Drop arm



Drop arm test (supraspinatus muscle)

Patient is asked to lower the arm slowly from abduction.

Positive test result: immediate drop of the arm accompanied by pain

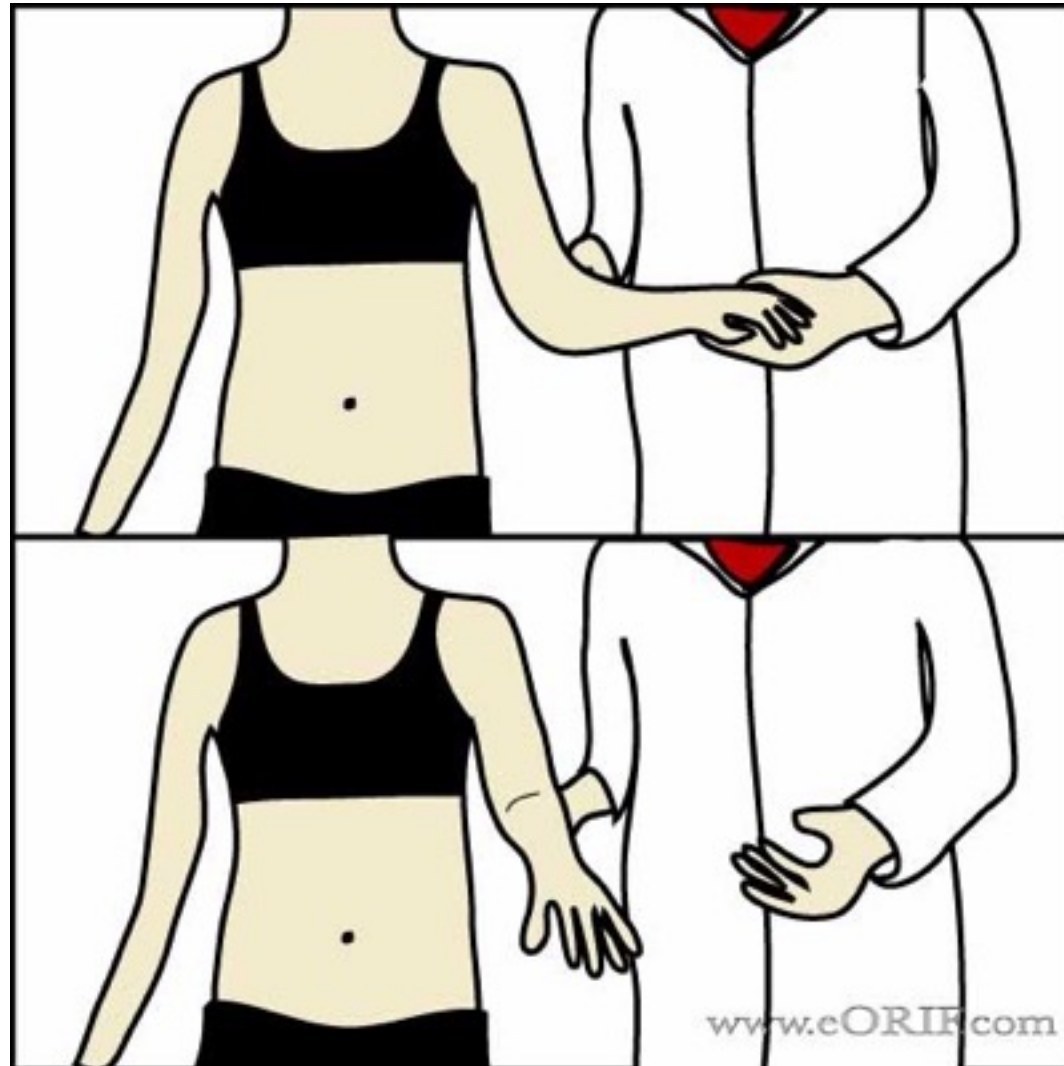


## Empty can test:

90° abduction of humerus;  
30° flexion; full internal rotation  
+ — **pain**

also: can ask patient to abduct with hands by side  
+ difficulty until 45° abduction, where deltoid takes over

# Infraspinatus (action: *external rotation*)

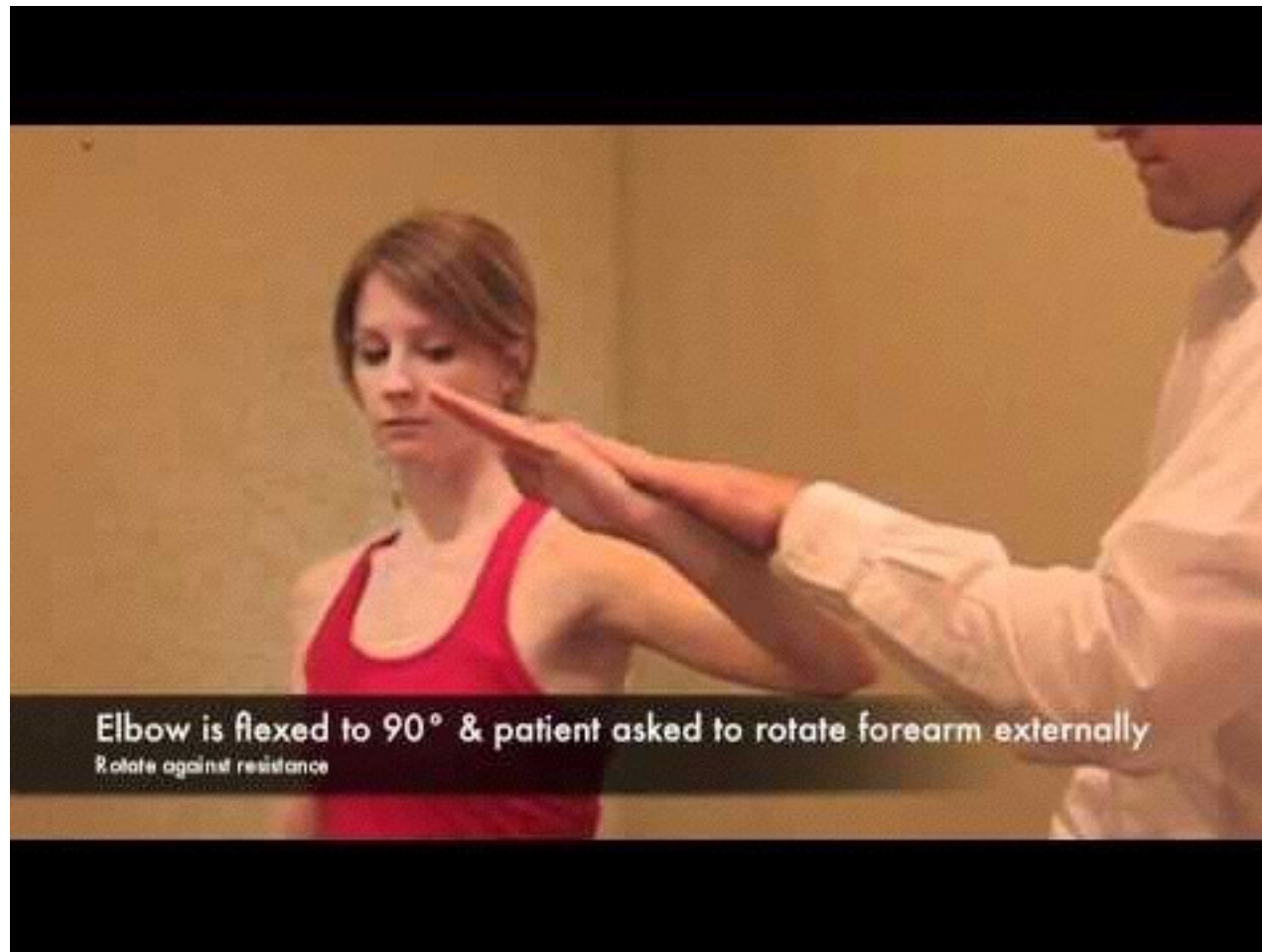

## **ER lag test:**

patient unable to maintain  
arm in external rotation

# **Teres minor**

(action: *external rotation*)



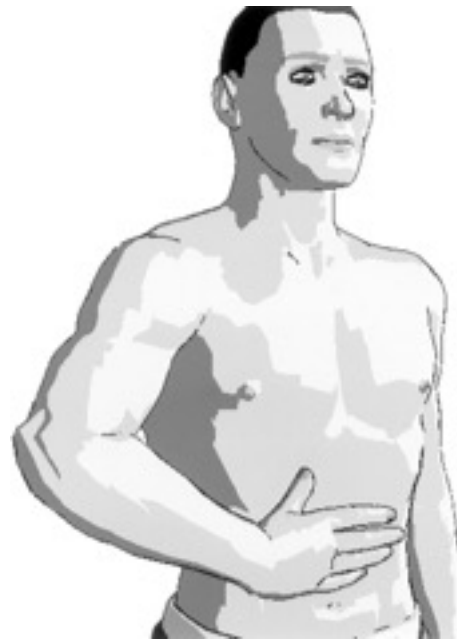## **Hornblower's test**

Elbow flexed  
90° in 'scapular  
plane';  
apply resistance  
against external  
rotation

+ — pain /  
weakness

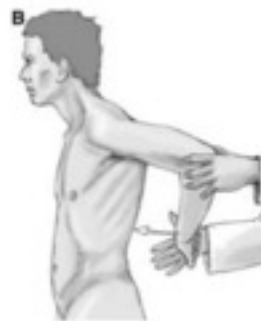# Subscapularis

(action: *internal rotation*)

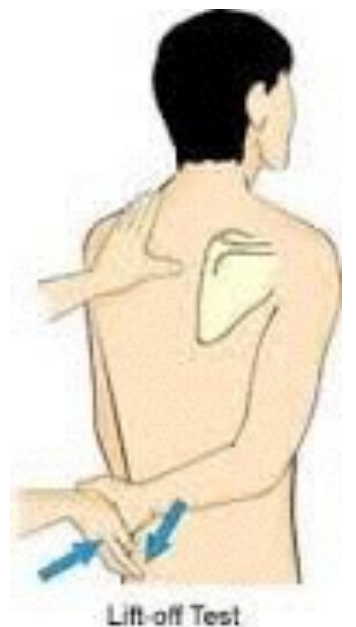

## Internal Rotation Lag Sign

Inability to hold hand away from the lumbar region in maximal internal rotation



- **Excessive passive ER**
- **Belly press** test — press against belly; + if wrist flexion or extension of elbow (moves posteriorly)
- **Lift off** test — dorsum of hand on back; push against resistance; + weakness
- **Internal rotation lag** sign — hold patient's arm in maximal internal rotation; + patient unable to maintain position





# Management

- **Investigations**

- MRI, ultrasound  
AP radiograph may show calcifications

- **Conservative treatment**

Physiotherapy, NSAIDs, subacromial corticosteroid injection

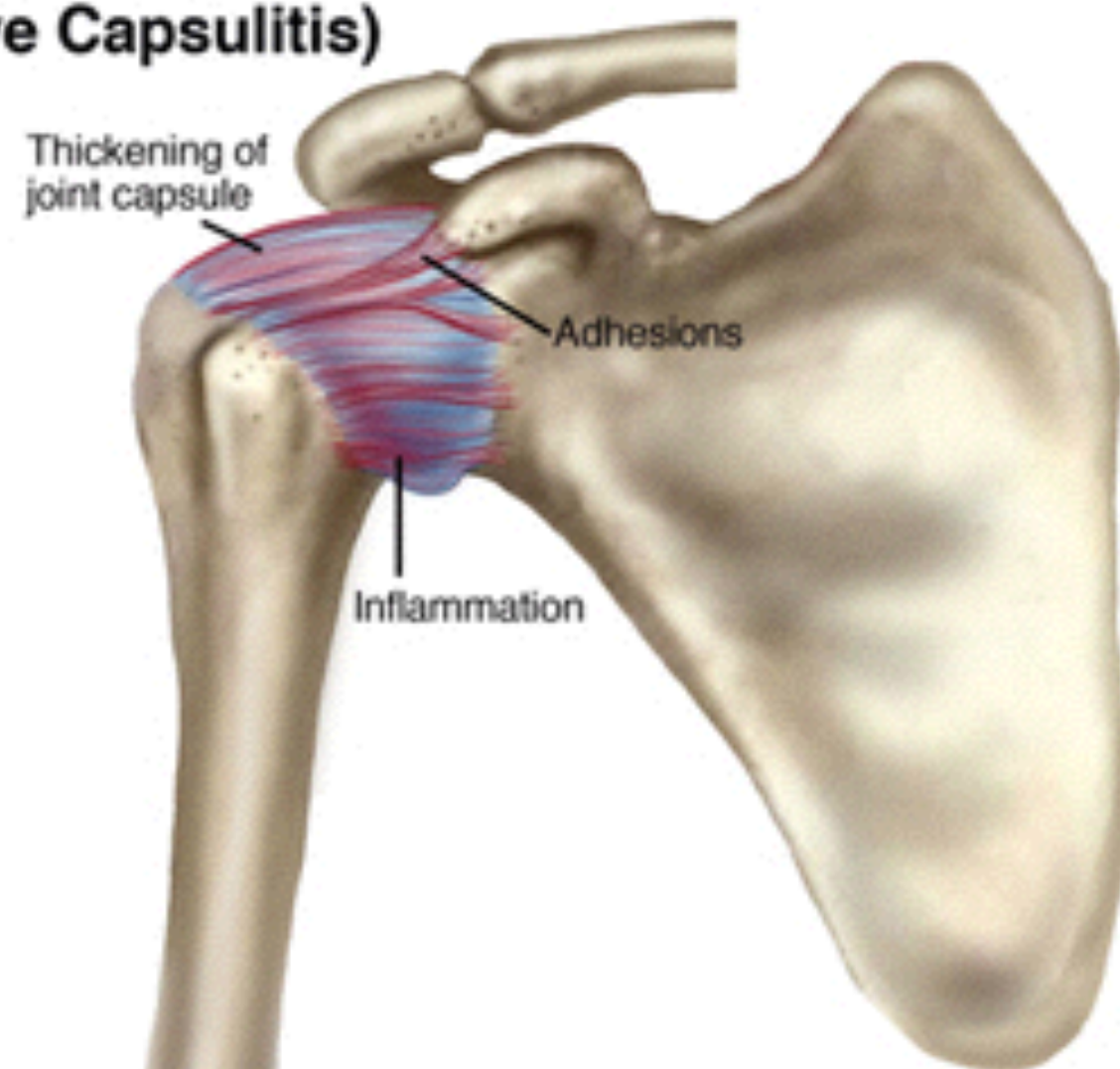
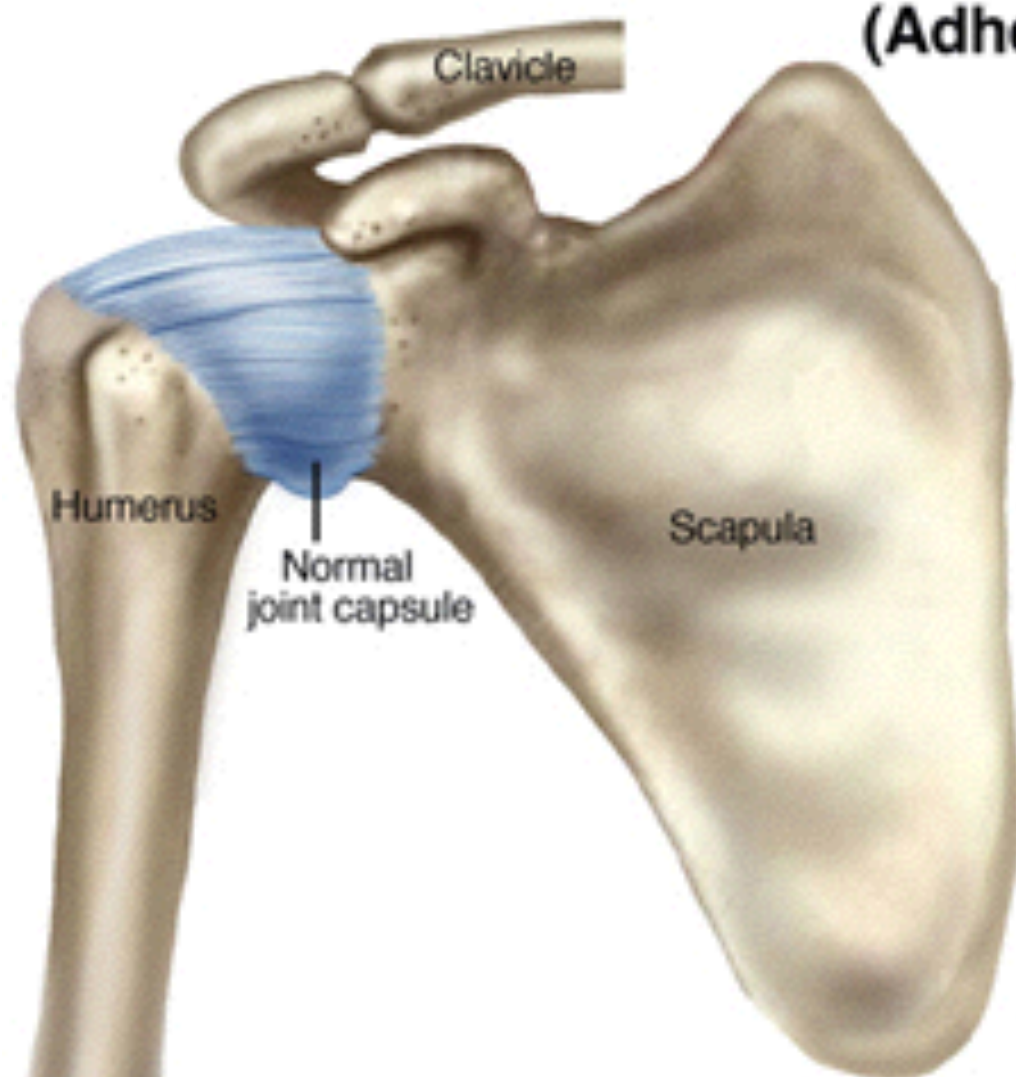
- **Operative**

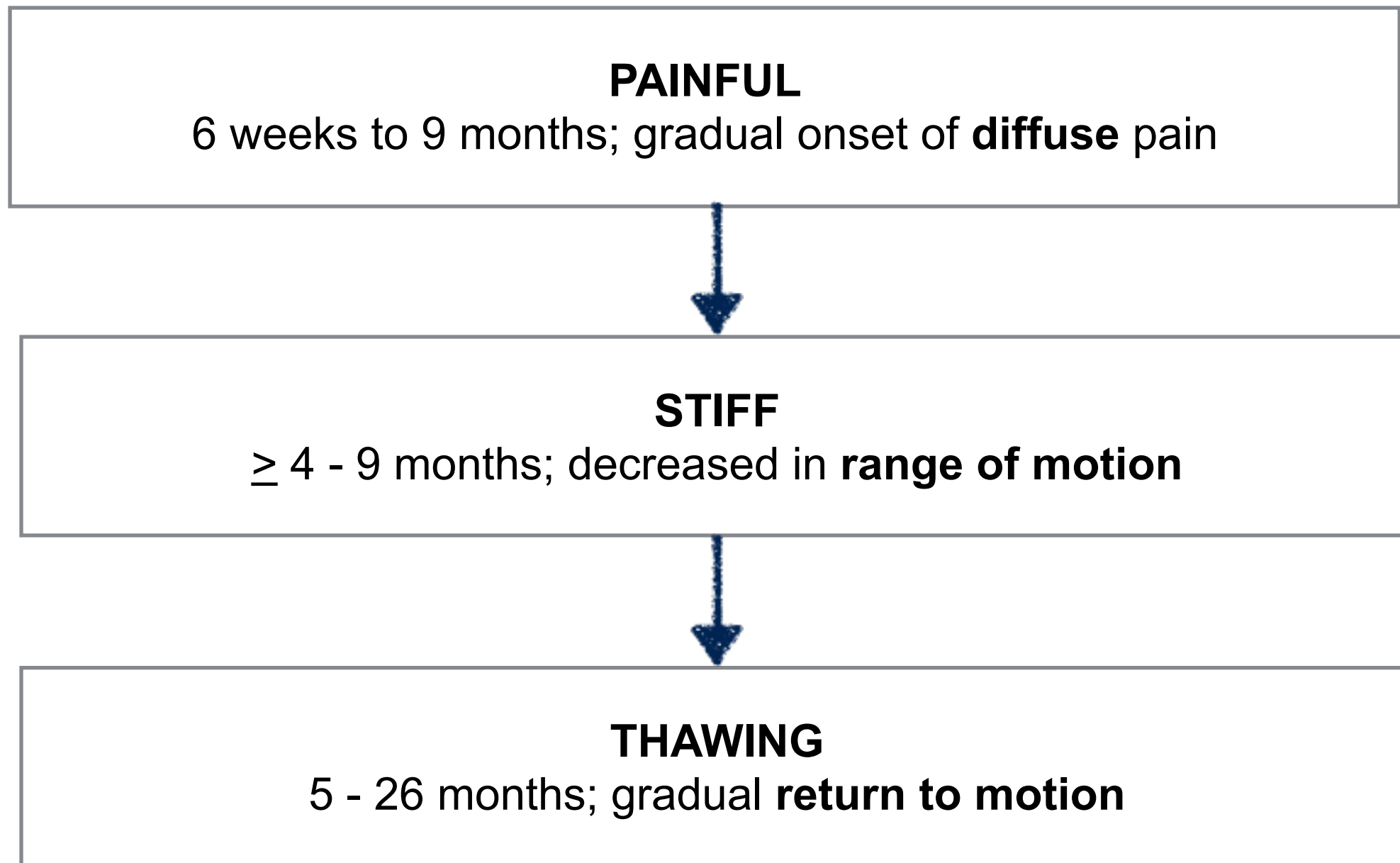
arthroscopic repair  
tendon transfer

# Adhesive capsulitis or 'frozen shoulder'

- **Pain and loss of motion in shoulder** with no other apparent cause
- **XR is normal**
- Fibrosis of joint capsule; soft tissue scarring and contracture
- Biopsy reveals **fibroblastic proliferation**
- Associated with **diabetes** (Type I, II), thyroid disorders, previous surgery, immobilisation and hospitalisation
- O/E. Painful arc of motion, decreased ROM.

## Frozen Shoulder (Adhesive Capsulitis)





## **Clinical stages of the frozen shoulder**

# Management

- **Investigations**
  - Radiographs
- **Conservative treatment — successful in majority**  
Physiotherapy, NSAIDs, intra-articular corticosteroid injection
- **Operative — only if conservative unsuccessful**  
manipulation under anaesthesia  
arthroscopic surgical release