



HAND & WRIST JOINT X RAY VIEWS

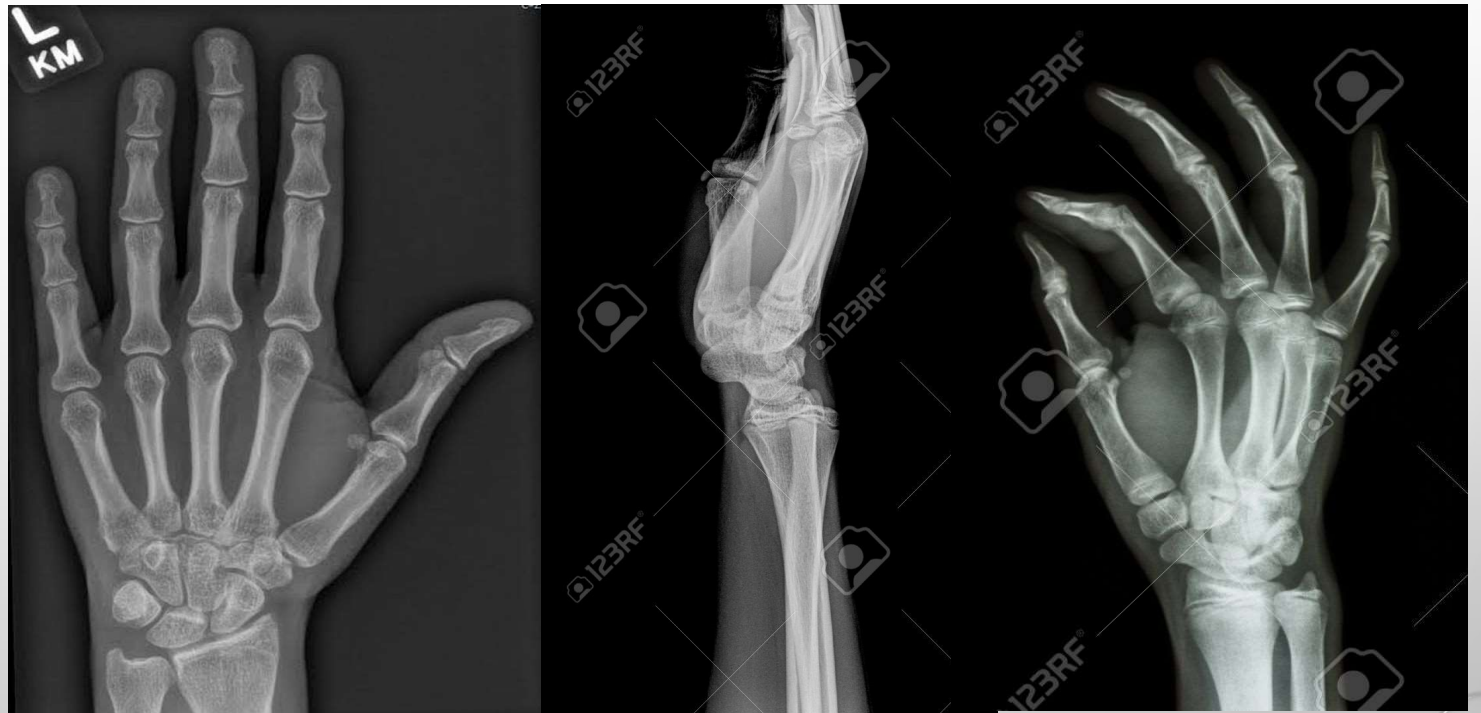BY

**S.S.SIVA SAGAR
TUTOR IN RADIOLOGY
CENTURIAN UNIVERSITY**



VIEWS

1. **HAND PA.**
2. **HAND OBLIQUE.**
3. **WRIST AP.**
4. **WRIST LATERAL.**



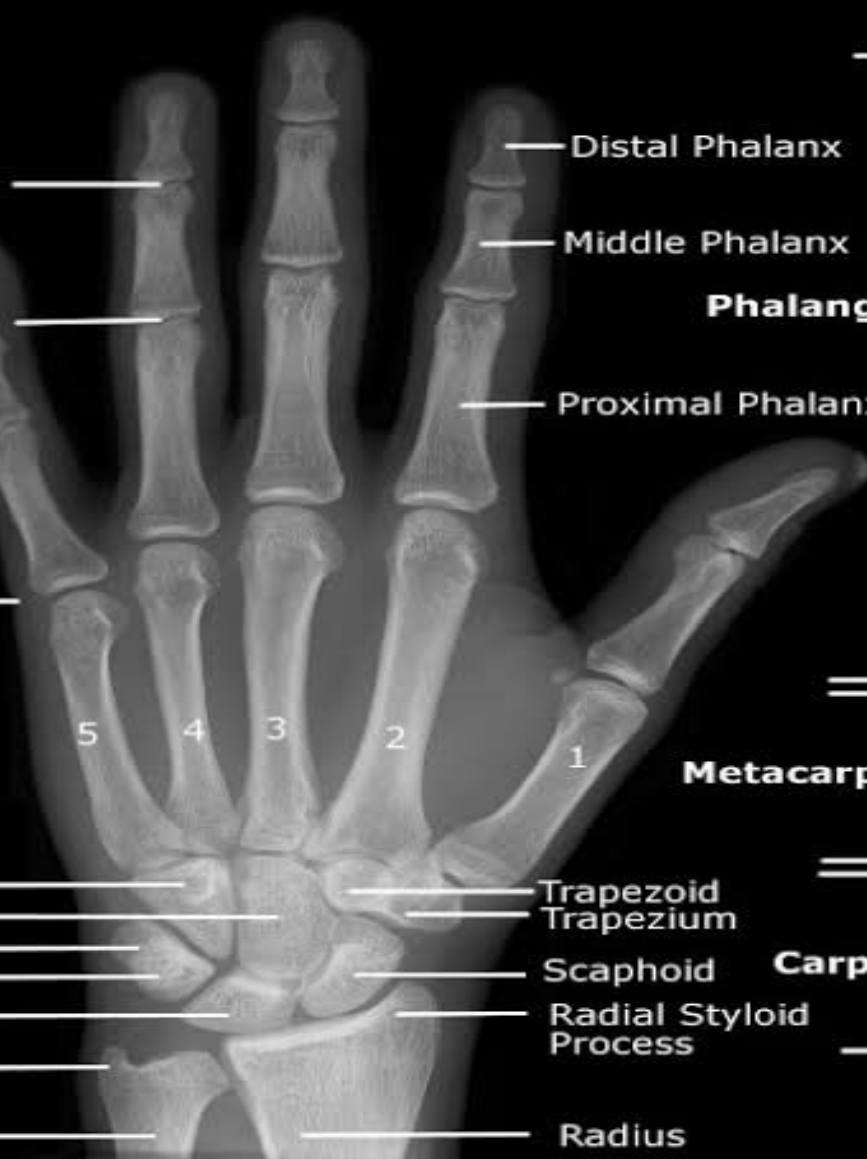

Distal Interphalangeal Joint

Proximal Interphalangeal Joint

Metacarpophalangeal Joint

Hamate
Capitate
Triquetrium
Pisiform
Lunate
Ulna Styloid Process
Ulna



Distal Phalanx

Middle Phalanx

Proximal Phalanx

Phalanges

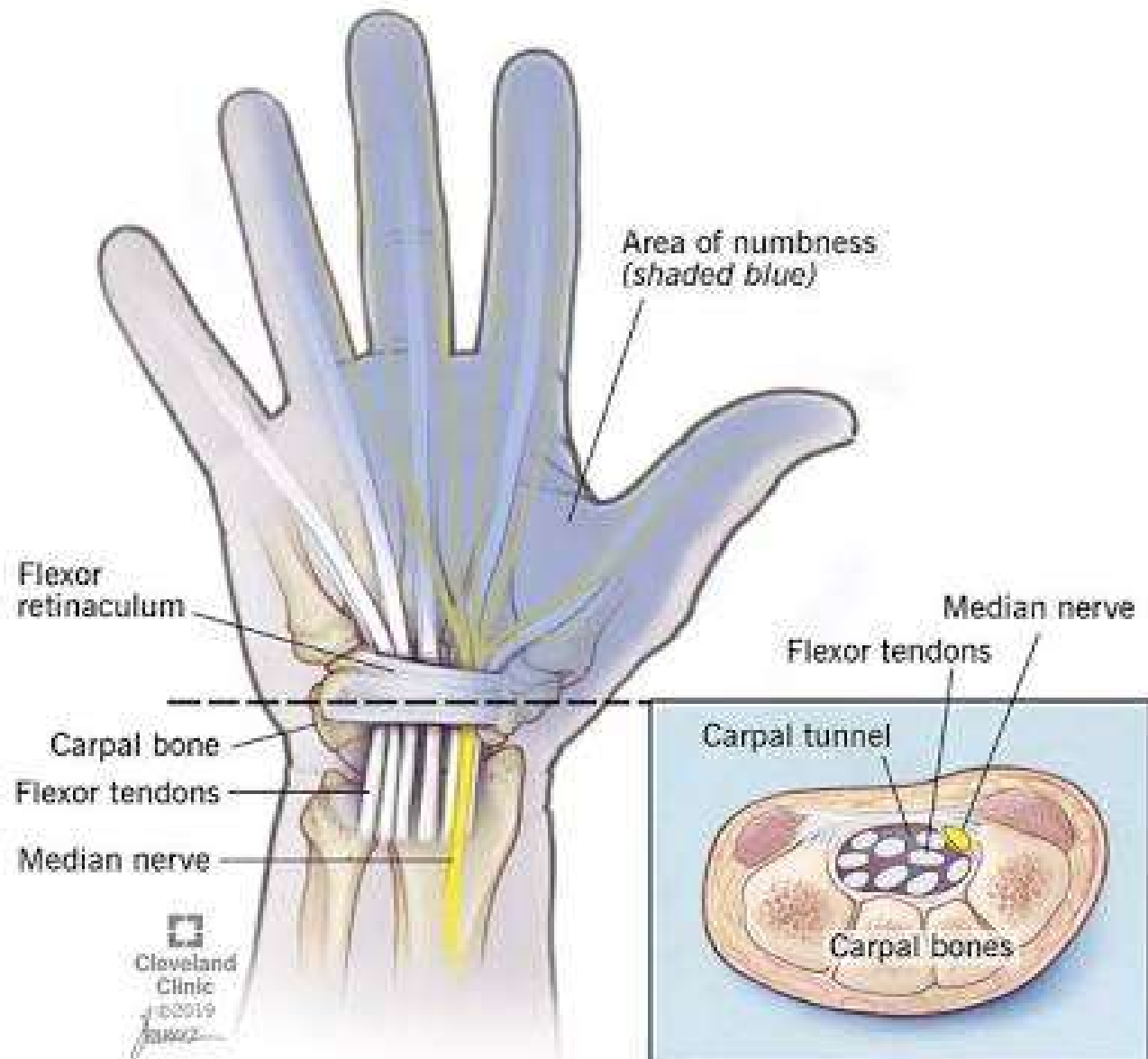
Metacarpals

Trapezoid
Trapezium

Scaphoid
Radial Styloid Process

Carpals

Radius



INDICATIONS OF HAND X RAY

- **PAIN AND BONY TENDERNESS**
- **TRAUMA CASES**
- **SWELLING OF HAND**
- **DEFORMITY OF BONES**
- **IMPROPER GROWTH OF HAND BONES.**
- **FRACTURES**
- **DISLOCATION OF JOINTS.**
- **ARTHRITIS**
- **POST OP CASES.**
- **BONE AGE STUDY.**

INDICATIONS OF WRIST X RAY

- **PAIN.**
- **TRAUMA CASES.**
- **BONY TENDERNESS.**
- **SWELLING OF WRIST JOINT**
- **DEFORMITY OF WRIST JOINT.**
- **DISLOCATION OF JOINTS**
- **FRACTURES**
- **POST OP CASES**
- **CARPLE TUNNEL SYNDROME.**



CONTRAINDICATIONS

- **PREGNANCY.**

SHIELDING IS PROVIDED TO PATIENT

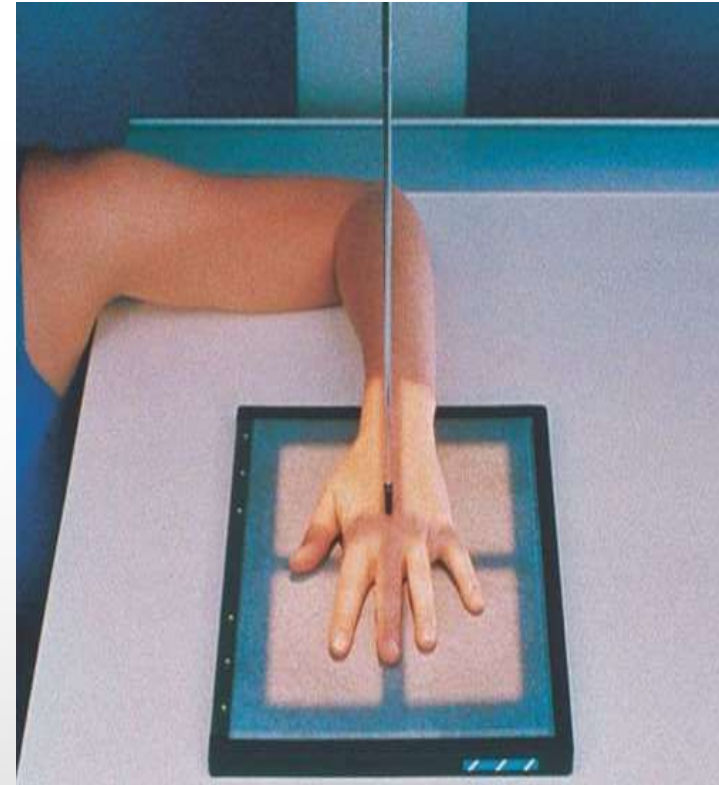


PREPARATION

- **COLLECT HISTORY FROM PATIENT.**
- **PATIENT IS ASKED TO REMOVE ALL RADIOPAQUE MATERIALS.**
- **WEAR HOSPITAL GOWN.**
- **IF FEMALE PATIENT COME TO X RAY , CHAPERONE IS NECESSARY.**
- **SHIELDING IS PROVIDED TO PATIENT.**

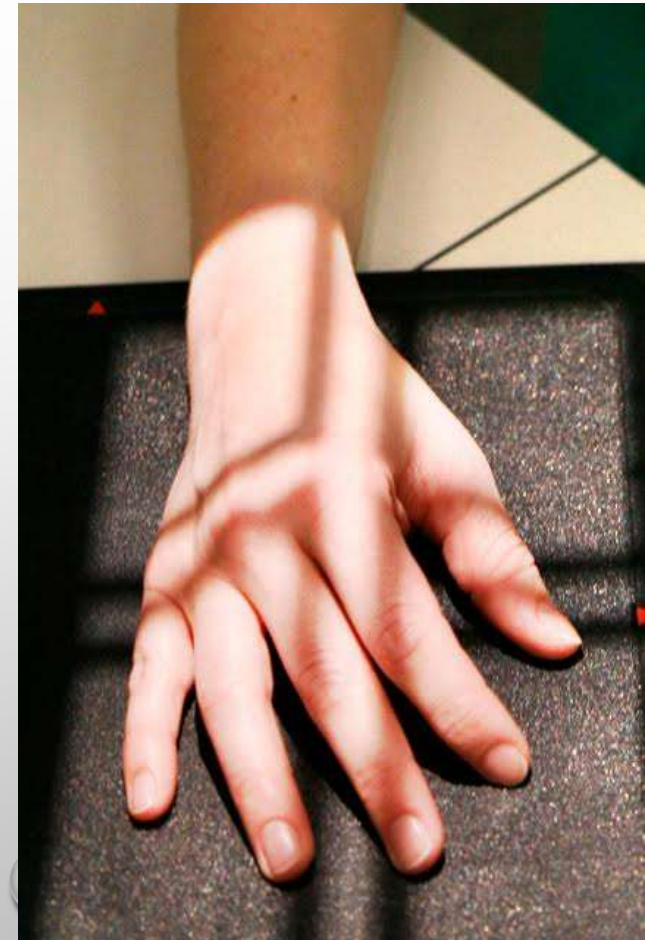
HAND & WRIST PA POSITIONING

- **PATIENT IS SEATED ON A STOOL ON THE SIDE OF X RAY TABLE.**
- **THE HAND, WRIST AND FOREARM ARE KEPT EXTENDED IN A STRAIGHT LINE.**
- **THE PALMER ASPECT OF HAND INCLUDING WRIST JOINT IS PLACED ON THE CASSETTE.**
- **THE FINGERS ARE EXTENDED AND SPACED EVENLY.**
- **THE LOWER PART OF FOREARM AND WRIST ARE IMMOBILISED WITH SANDBAGS.**
- **SIDE IS MARKED AND BEAM IS COLLIMATED.**



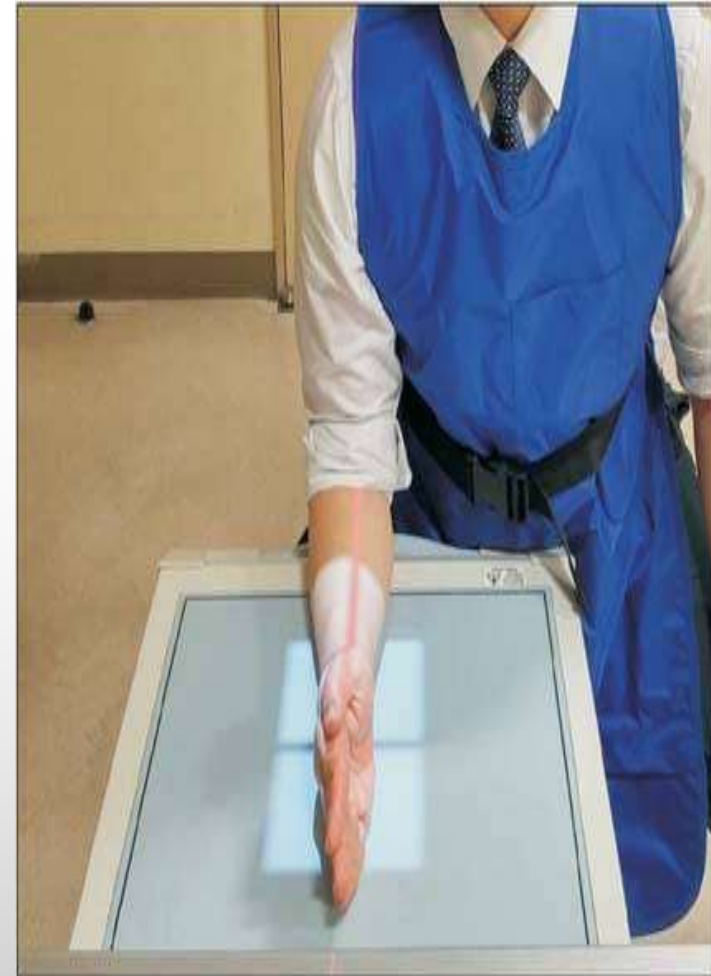HAND OBLIQUE POSITIONING

- **PATIENT IS SEATED ON A STOOL ON THE SIDE OF THE X RAY TABLE.**
- **HAND, WRIST AND FOREARM ARE EXTENDED IN A STRAIGHT LINE.**
- **THE PALMER ASPECT OF THE HAND IS PLACED ON THE CASSETTE.**
- **THE FINGERS ARE SLIGHTLY FLEXED AND SEPARATE EACH OTHER.**
- **FOREARM IS IMMOBALISED WITH A SANDBAG.**
- **SIDE IS MARKED AND BEAM IS COLLIMATED.**



WRIST LATERAL POSITIONING

- 1. THE PATIENT IS SEATED ON THE SIDE OF X RAY TABLE.**
- 2. THE HAND, WRIST AND FOREARM ARE EXTENDED.**
- 3. FOREARM IS ROTATED AND LITTLE FINGER SIDE IS RESTED ON CASSETTE.**
- 4. BEAM IS COLLIMATED.**



CENTERING

- **HAND PA** : ON THE HEAD OF THIRDED METACARPAL.
- **HAND OBLIQUE** : ON THE HEAD OF FIFTH METACARPAL.
- **WRIST AP** : IT IS DONE ON MIDWAY BETWEEN THE RADIAL AND ULNAR STYLOID PROCESSES.
- **WRIST LATERAL** : IT IS DONE ON RADIAL STYLOID PROCESS.

TECHNIQUE

- **KVP : 60**
- **MAS : 10**
- **FSS : SMALL**
- **FFD : 100 CMS.**
- **WITH OUT GRID.**
- **CASEETTE SIZE :10 "X 8"**

*If you born poor
it's not your mistake,
but if you die poor
it's your mistake.*

-BILL GATES

