

# **HUMAN ANATOMY AND PHYSIOLOGY-II**

## **Central nervous system (functions of afferent and efferent nerve tracts, reflex activit)**



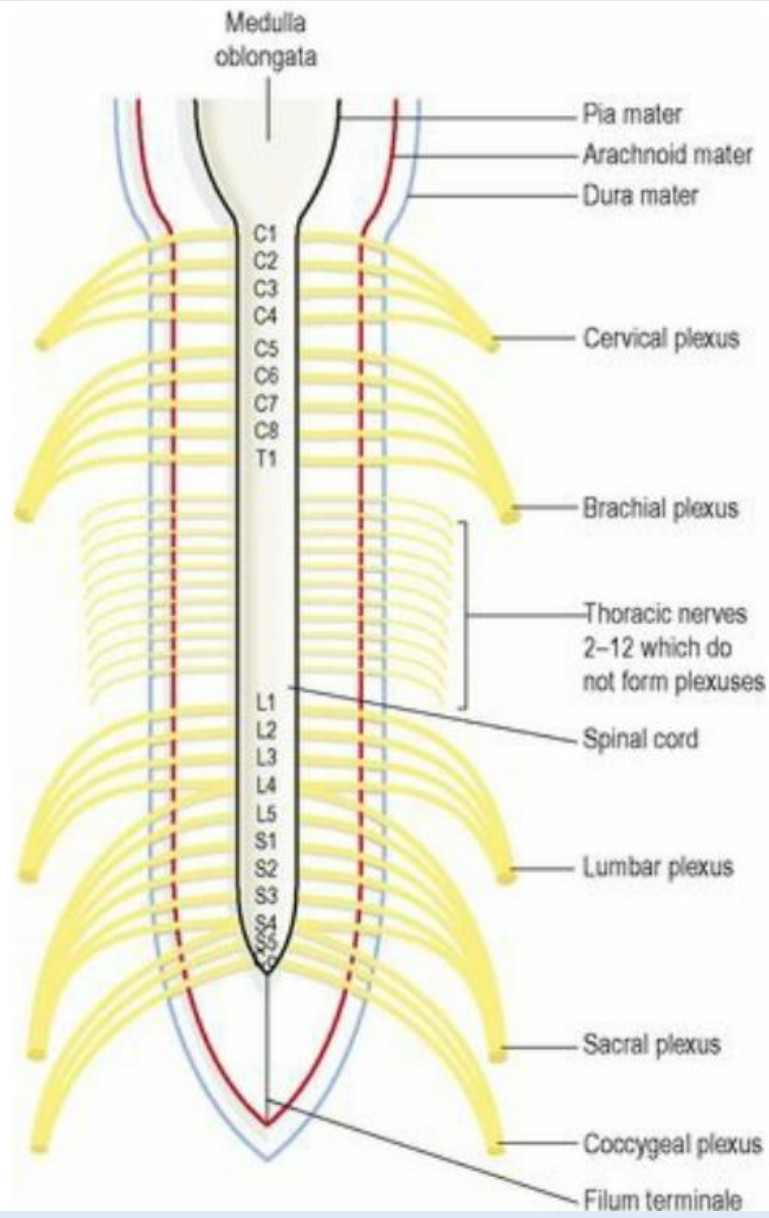
**Centurion**  
**UNIVERSITY**

*Shaping Lives...*  
*Empowering Communities...*

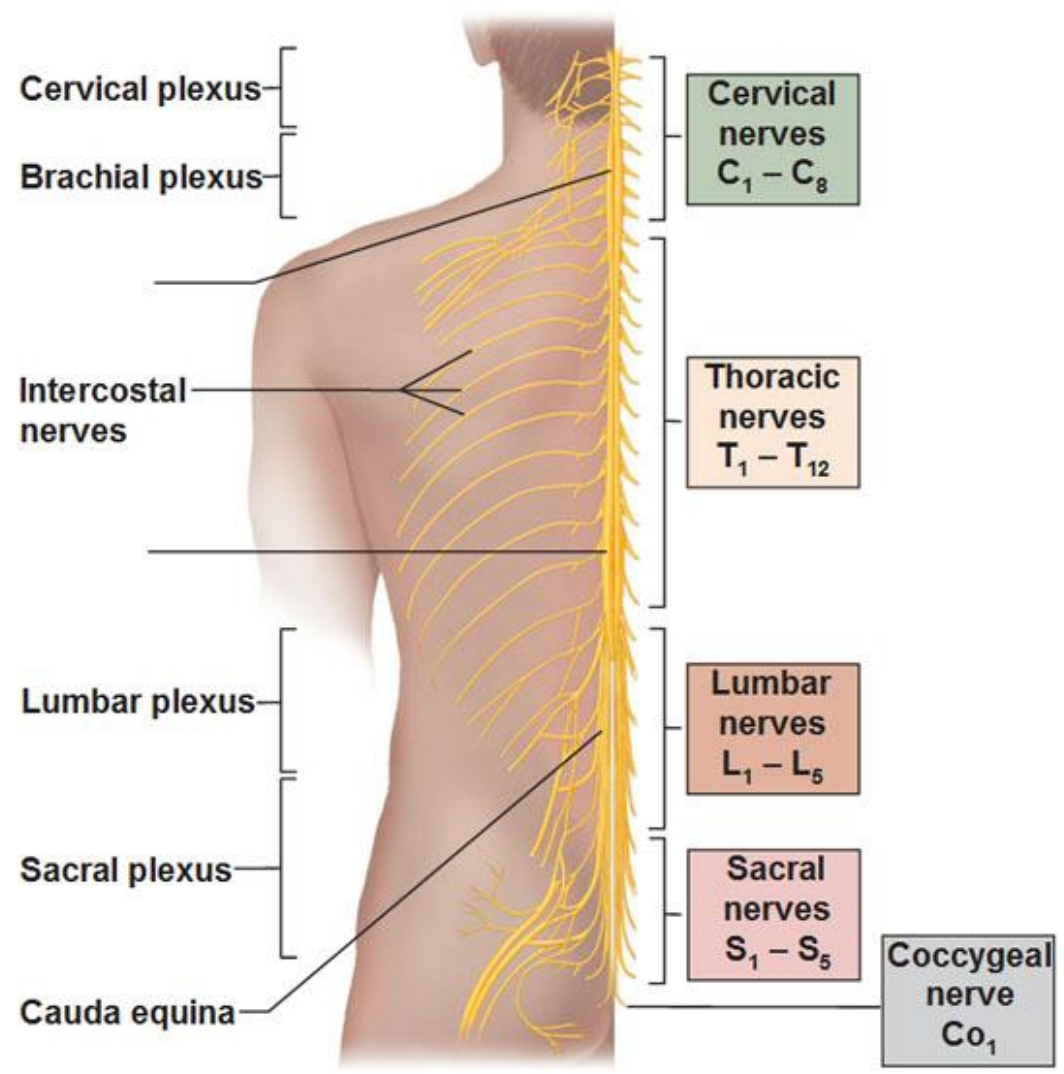
**Prepared by**  
**Sucharita Babu**  
**Assistant Professor**  
**School of Pharmacy and Life Sciences**

# Plexuses

- In the cervical, lumbar and sacral regions the anterior rami unite near their origins to form large masses of nerves, or plexuses, where nerve fibres are regrouped and rearranged before proceeding to supply skin, bones, muscles and joints of a particular area.
- These structures have a nerve supply from more than one spinal nerve and therefore damage to one spinal nerve does not cause loss of function of a region.



# Spinal Nerves Posterior View



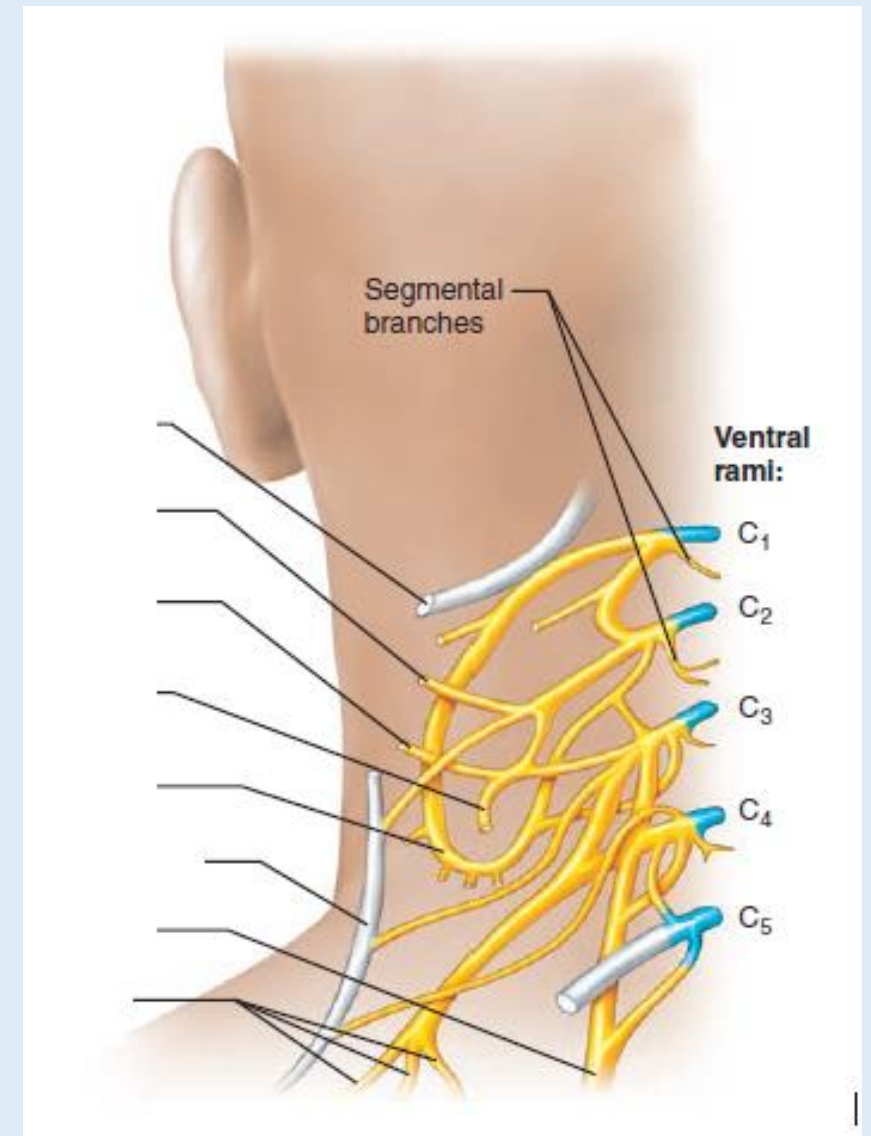
- In the thoracic region the anterior rami do not form plexuses. There are five large plexuses of mixed nerves formed on each side of the vertebral column.

They are the:

- cervical plexuses
- brachial plexuses
- lumbar plexuses
- sacral plexuses
- coccygeal plexuses.

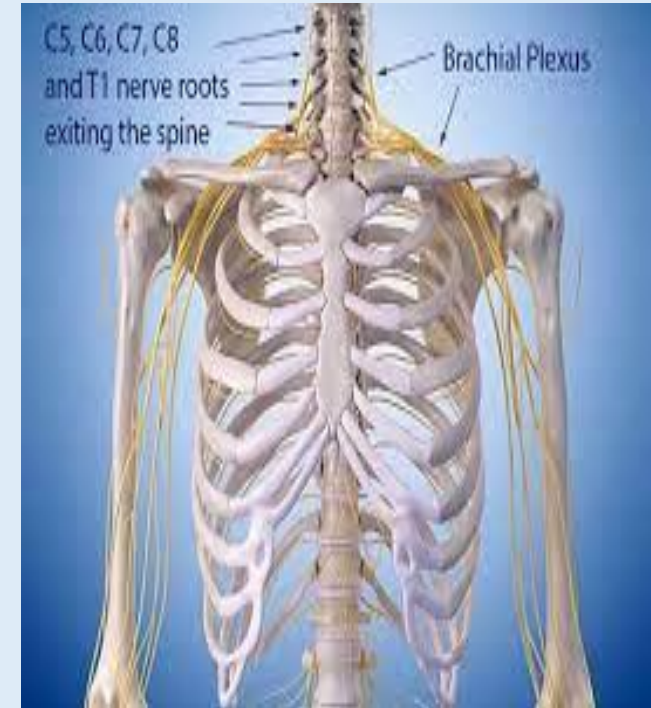
## Cervical plexus

- This is formed by the anterior rami of the first four cervical nerves. It lies deep within the neck opposite the 1st, 2nd, 3rd and 4th cervical vertebrae under the protection of the sternocleidomastoid muscle.
- The superficial branches supply the structures at the back and side of the head and the skin of the front of the neck to the level of the sternum.
- The deep branches supply muscles of the neck, e.g. the sternocleidomastoid and the trapezius.
- The phrenic nerve originates from cervical roots 3, 4 and 5 and passes downwards through the thoracic cavity in front of the root of the lung to supply the diaphragm, initiating inspiration.
- Disease or spinal cord injury at this level will result in death due to apnoea without assisted ventilation.



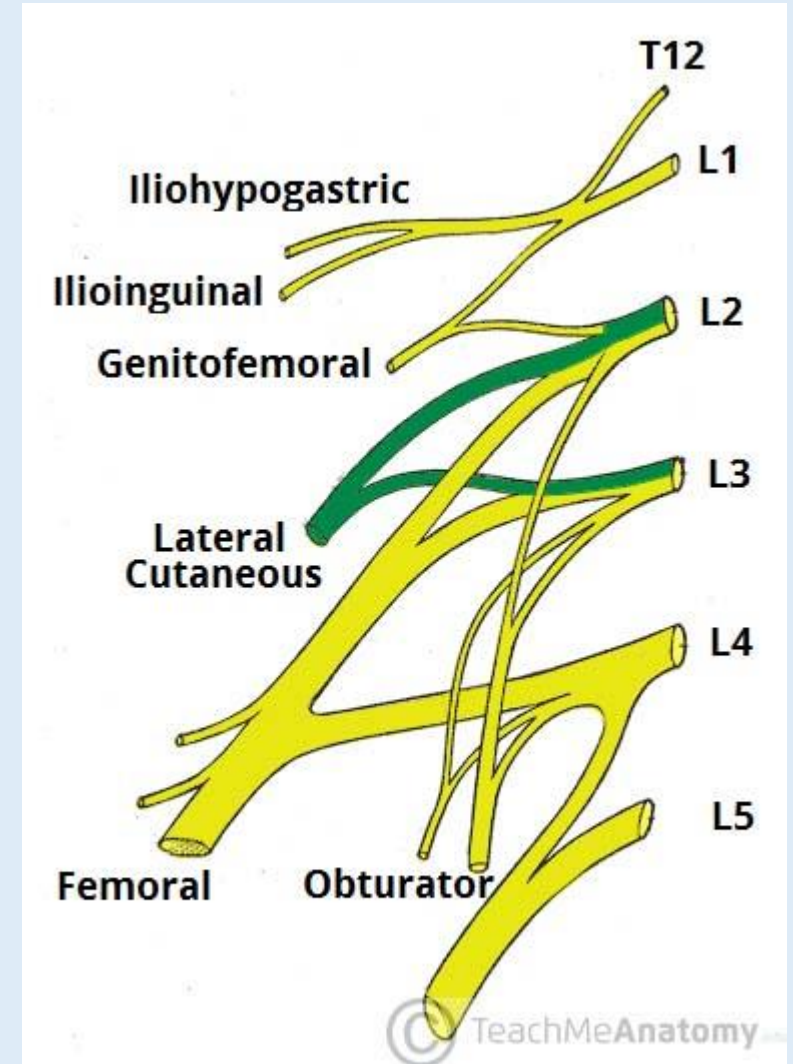
# Brachial plexus

- The anterior rami of the lower four cervical nerves and a large part of the 1st thoracic nerve form the brachial plexus.
- The plexus is situated deeply within the neck and shoulder above and behind the subclavian vessels and in the axilla.
- The branches of the brachial plexus supply the skin and muscles of the upper limbs and some of the chest muscles.
- Five large nerves and a number of smaller ones emerge from this plexus, each with a contribution from more than one nerve root, containing sensory, motor and autonomic fibres



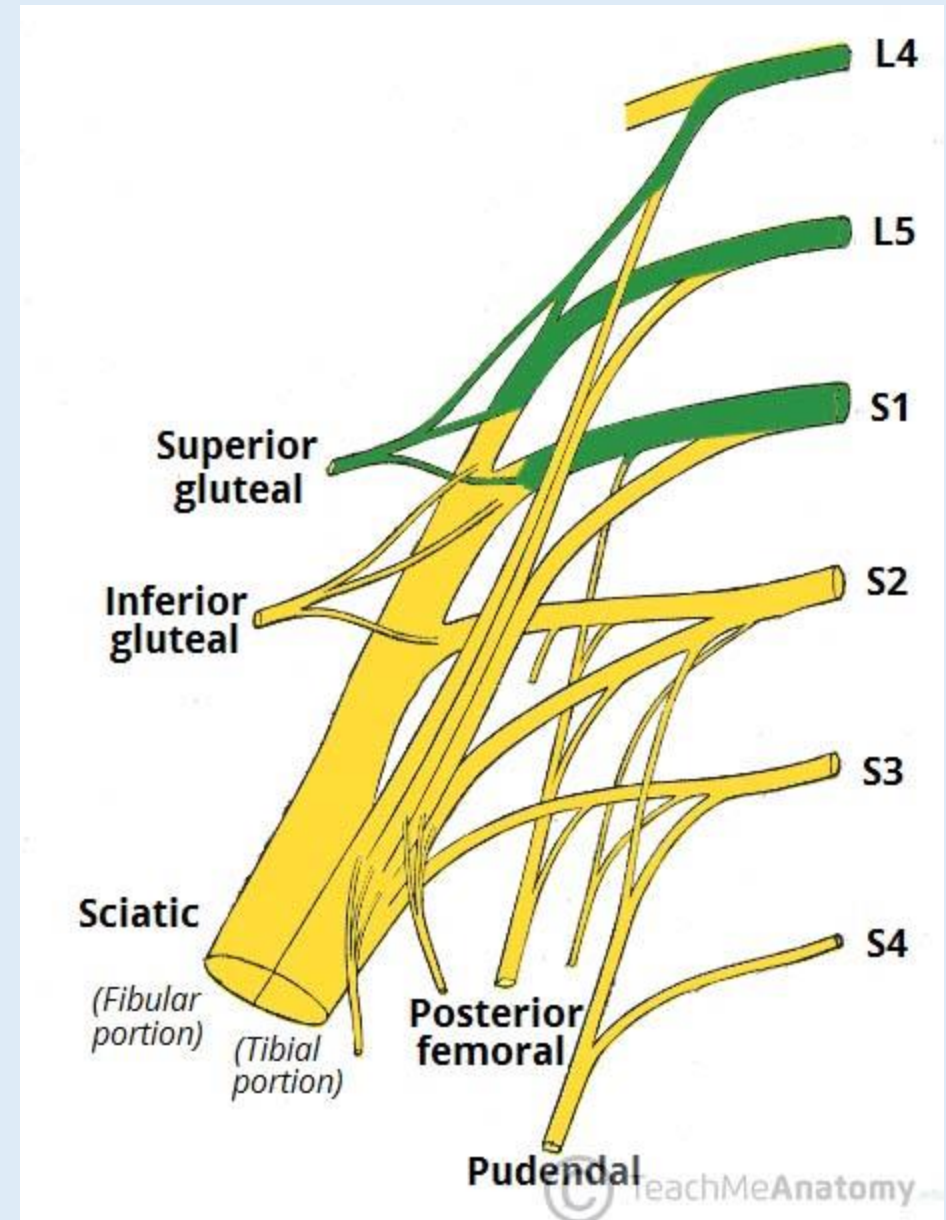
# Lumbar plexus

- The lumbar plexus is formed by the anterior rami of the first three and part of the 4th lumbar nerves.
- The plexus is situated in front of the transverse processes of the lumbar vertebrae and behind the psoas muscle.
- The main branches, and their nerve roots are:
  - iliohypogastric nerve: L1
  - ilioinguinal nerve: L1
  - genitofemoral: L1, 2
  - lateral cutaneous nerve of thigh: L2,
  - femoral nerve: L2, 3, 4
  - obturator nerve: L2, 3, 4
  - lumbosacral trunk: L4, (5).



# Sacral plexus

- The sacral plexus is formed by the anterior rami of the lumbosacral trunk and the 1st, 2nd and 3rd sacral nerves.
- The lumbosacral trunk is formed by the 5th and part of the 4th lumbar nerves. It lies in the posterior wall of the pelvic cavity
- The sacral plexus divides into a number of branches, supplying the muscles and skin of the pelvic floor, muscles around the hip joint and the pelvic organs.





## **Coccygeal plexus**

- The coccygeal plexus is a very small plexus formed by part of the 4th and 5th sacral and the coccygeal nerves. The nerves from this plexus supply the skin around the coccyx and anal area.

# Thoracic nerves

- The thoracic nerves do not intermingle to form plexuses.
- There are 12 pairs and the first 11 are the intercostal nerves.
- They pass between the ribs supplying them, the intercostal muscles and overlying skin.
- The 12th pair are the subcostal nerves.
- The 7th to the 12th thoracic nerves also supply the muscles and the skin of the posterior and anterior abdominal walls

- **TRACTS:**

- The white matter of the spinal cord is arranged in three columns or tracts; anterior, posterior and lateral.
- These tracts are formed by sensory nerve fibres ascending to the brain, motor nerve fibres descending from the brain and fibres of connector neurones.

- ❖ Sensory nerve tracts in the spinal cord

- ❖ Motor nerve tracts in the spinal cord

# Sensory nerve tracts in the spinal cord

- The skin.:
- Sensory receptors (nerve endings) in the skin, called cutaneous receptors, are stimulated by pain, heat, cold and touch, including pressure
- Nerve impulses generated are conducted by three neurones to the sensory area in the opposite hemisphere of the cerebrum where the sensation and its location are perceived

# Sensory nerve tracts in the spinal cord

- The tendons, muscles and joints: Sensory receptors are specialized nerve endings in these structures, called proprioceptors, and they are stimulated by stretch.
- Together with impulses from the eyes and the ears they are associated with the maintenance of balance and posture and with perception of the position of the body in space.
- These nerve impulses have two destinations:
- by a three-neurone system, the impulses reach the sensory area of the opposite hemisphere of the cerebrum
- by a two-neurone system, the nerve impulses reach the cerebellar hemisphere on the same side.

# Motor nerve tracts in the spinal cord

- Neurones that transmit nerve impulses away from the brain are motor (efferent or descending) neurones.
- Motor neurone stimulation results in:
  - contraction of skeletal (voluntary) muscle
  - contraction of smooth (involuntary) muscle, cardiac muscle and the secretion by glands controlled by nerves of the autonomic nervous system

# Spinal reflexes

These consist of three elements:

- i. sensory neurones
- ii. connector neurones (or interneurones) in the spinal cord
- iii. lower motor neurones

- A reflex action is an involuntary and immediate motor response to a sensory stimulus.
- Many connector and motor neurones may be stimulated by afferent impulses from a small area of skin, e.g. the pain impulses initiated by touching a very hot surface with the finger are transmitted to the spinal cord by sensory fibres in mixed nerves.
- These stimulate many connector and lower motor neurones in the spinal cord, which results in the contraction of many skeletal muscles of the hand, arm and shoulder, and the removal of the finger.
- Reflex action happens very quickly, in fact, the motor response may occur simultaneously with the perception of the pain in the cerebrum.
- Reflexes of this type are invariably protective but they can occasionally be inhibited.
- For example, if it is a precious plate that is very hot when lifted every effort will be made to overcome the pain to prevent dropping it!



# Stretch reflexes

- Only two neurones are involved.
- The cell body of the lower motor neurone is stimulated directly by the sensory neurone, with no connector neurone in between
- The knee jerk is one example, but this type of reflex can be demonstrated at any point where a stretched tendon crosses a joint.
- By tapping the tendon just below the knee when it is bent, the sensory nerve endings in the tendon and in the thigh muscles are stretched.
- This initiates a nerve impulse that passes into the spinal cord to the cell body of the lower motor neurone in the anterior column of grey matter on the same side.
- As a result the thigh muscles suddenly contract and the foot kicks forward. This is used as a test of the integrity of the reflex arc.
- This type of reflex has a protective function – it prevents excessive joint movement that may damage tendons, ligaments and muscles.

# Autonomic reflexes

- These include the pupillary light reflex when the pupil immediately constricts, in response to bright light, preventing retinal damage.