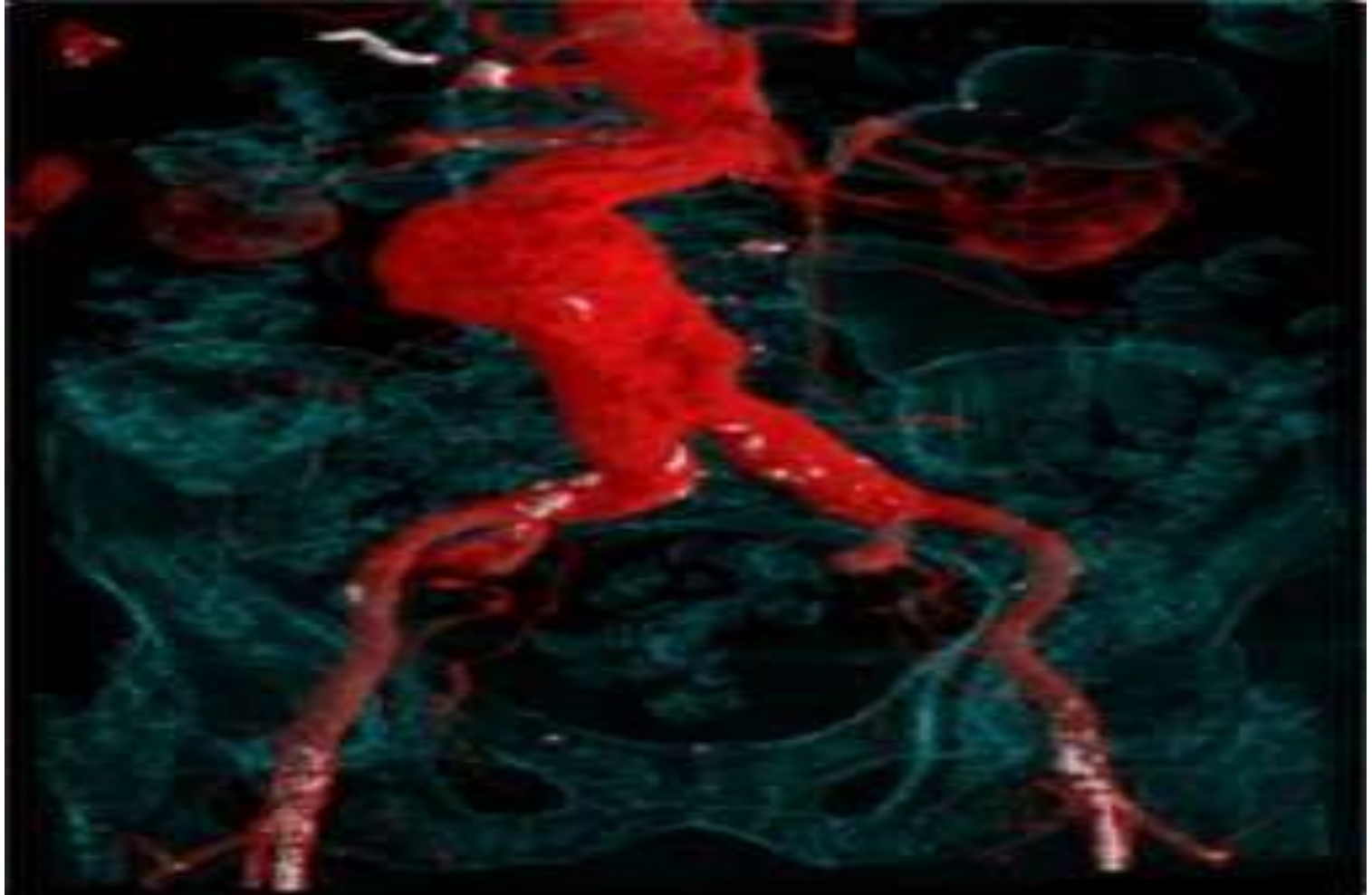


CT ANGIOGRAPHY



Outlines:


- What is CTA?
- Indications
- Contraindication
- Preparation
- Protocol
 - Cerebral to lower limb
 - Subclavian
- Pediatric patient
- Patient after care

What is CTA?

Computerized tomographic angiography is used to visualize blood vessels that have been opacified by CM.

This include:

- Circle of Willis.
- Carotid arteries
- Subclavian arteries
- Thoracic & abdominal aorta
- Renal vasculature
- Abdominal viscera vasculature
- Lower limb arteries



Indication

Contraindication

- Aneurysm
- Stenosis
- Dissection of aorta
- Atherosclerosis
- A-V fistula
- A-V malformation
- Thrombosis
- Pulmonary embolism
- Guide to implanting or evaluating stents.
- Thoracic Outlet Syndrom

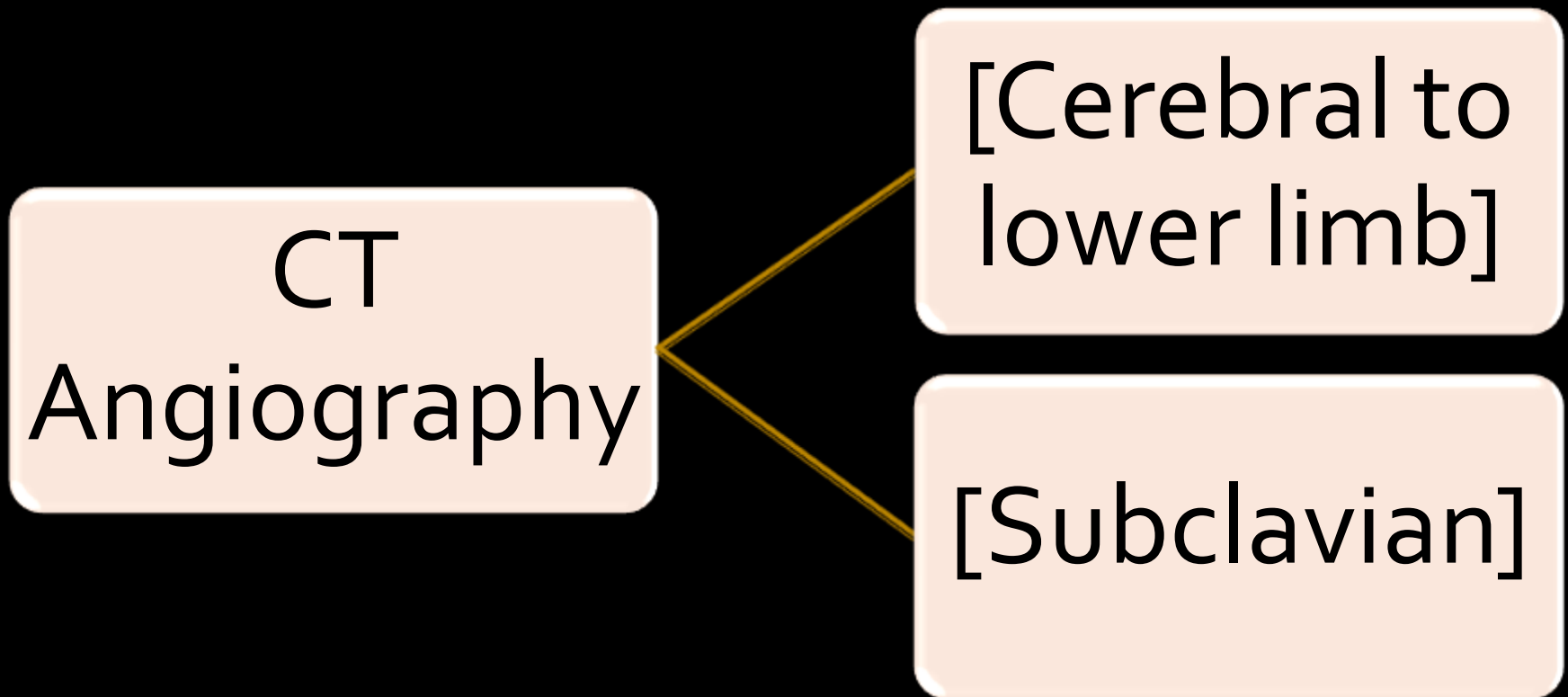
- Pregnancy
- unstable vital signs

- Allergic patient
- Kidney problems
- Severe diabetes

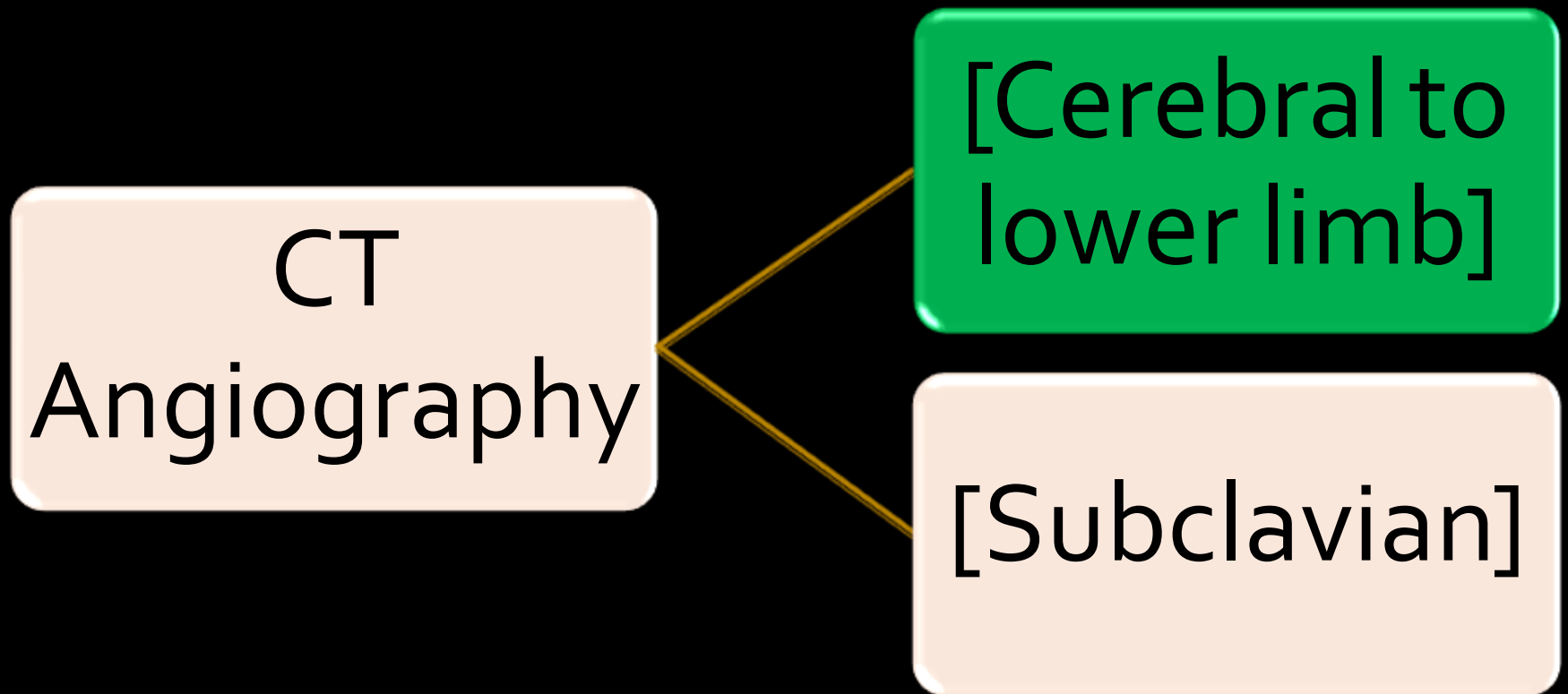
Preparation:

- NPO 3-4 hrs before the exam.
- Not severely allergic or asthmatic
- Recent Renal function test(RFT) must be normal;
 - 1 week inpatient.
 - 3 month diabetic patient
 - 6 month non diabetic patient.
- Explain procedure
- Signed consent form
- Sedation if needed

We will present:



We will present:



Pt position:

[Cerebral to
lower limb]

- Supine, in the center of the table.
- Head first in the gantry.
- The arms are raised above the head.
- Scanning from head to lower limb, as ordered.

Protocol:

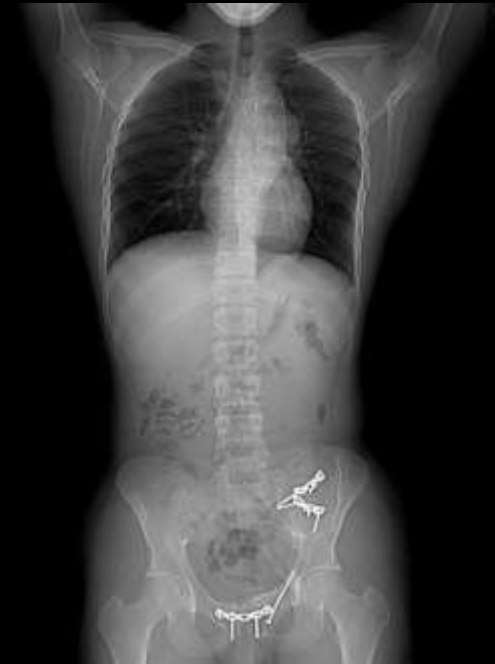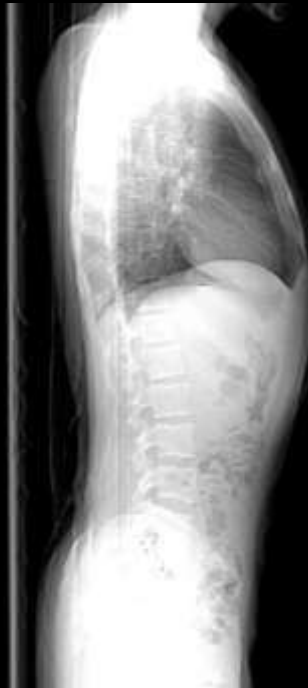64 detector arrays
KKUH



• Scout/topogram Images:

PA: plane 180°

Lat: plane 90°



Contrast media:

- Injection in the arm vein

CM Type: Omnipaque or Xenetix 300; injector machine.

Volume: 120 ml.

Flow rate: 4ml/sec.

Cannula size: 18 gauge

Smart prep technique:

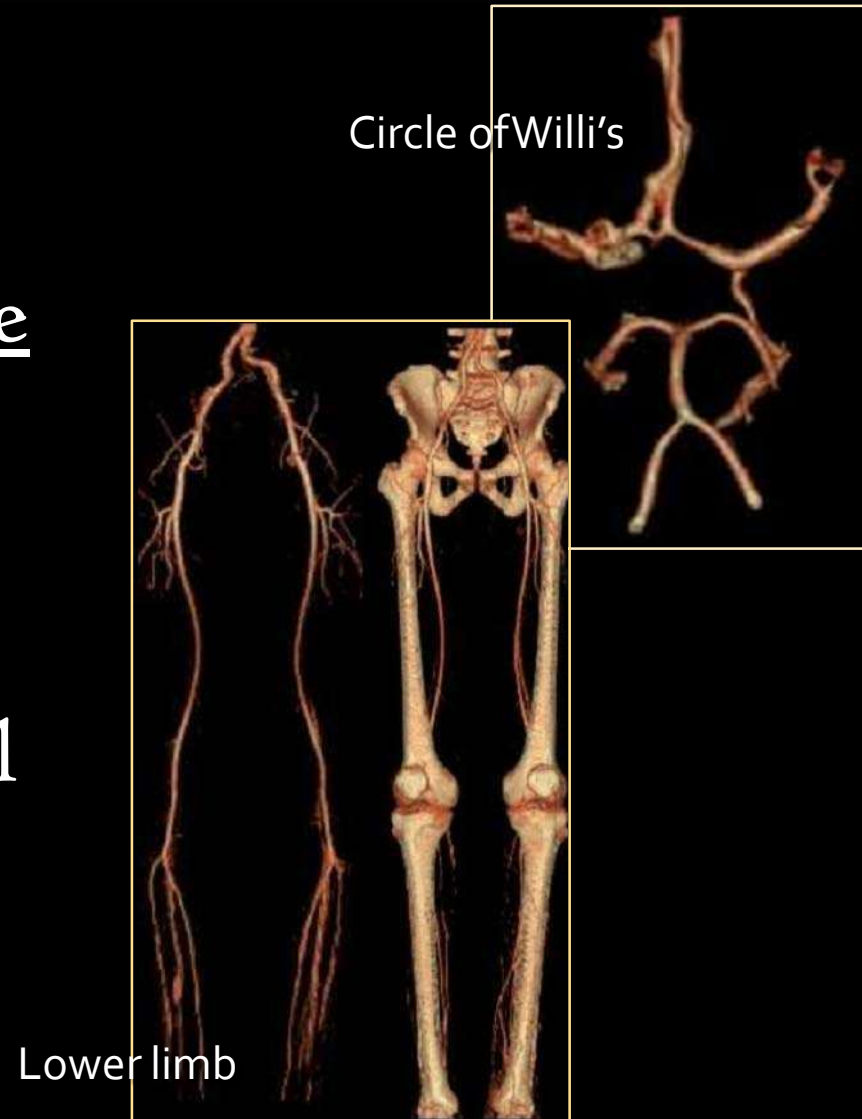
➤ With 64 detector arrays, the scan start when the CM is seen in the thoracic **aorta**.

➤ With 16, CM in the thoracic **pulmonary artery** .

Axial slices

Start location: the head
End location: down to the
ordered lower limb limit.

FOV is adjusted to as
small as possible; but still
include all parts needed.



Scan parameters:

Type of scan	KV	mA	Scan delay	Sec.	Slice thickness	Pitch	FOV	Recon. Algorithm
spiral	120	Auto min 150 Max 500	15sec-thorasic a. 20sec-abdom. a.	.7sec	1.25x0.625mm (old) .6x.6mm(new)	0.9 (new) 1.375 (old)	30\40cm	Standard Or Soft tissue

2nd reconstruction
2.5x2.5 mm

Note: scan delay time is used if we don't have smart prep.

Cont.

Filming:

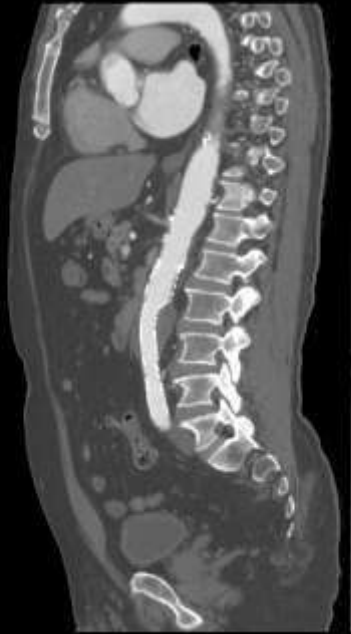No print out; PAC system is used.

Windowing:

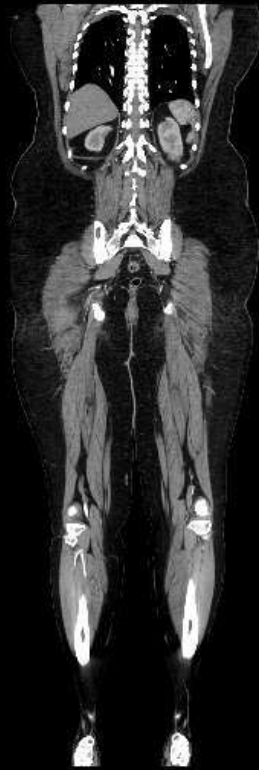window	WW	WL
Soft tissue	500	35

Reformatting: 2D\3D **must be done**

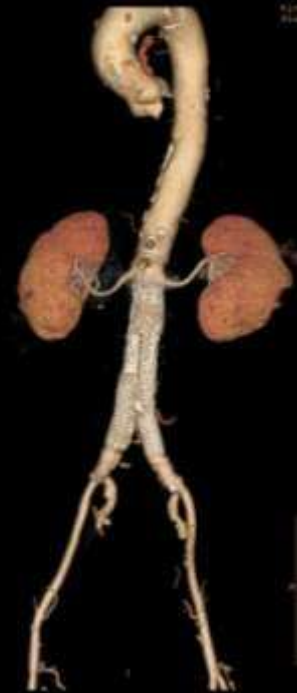Reformatting: 2D\3D



2D
sagittal



2D
coronal

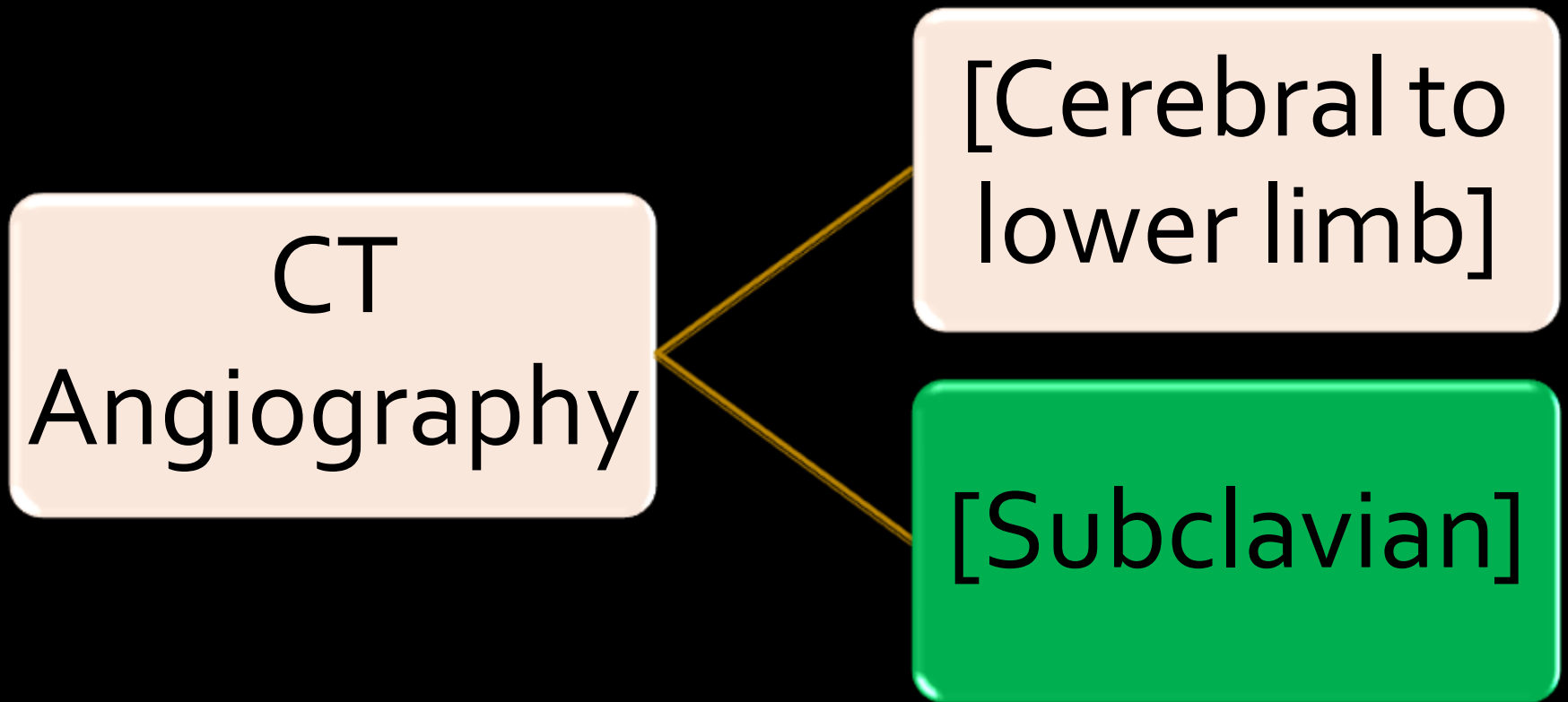


3D

Patient after care:

- Bandage over the injection site
- Watch the patient for possible adverse contrast reactions.
- Pt. can eat and drink as normal.
- He/she should drink plenty of fluids (CM flush out).

We will present:



Indication

Contraindication

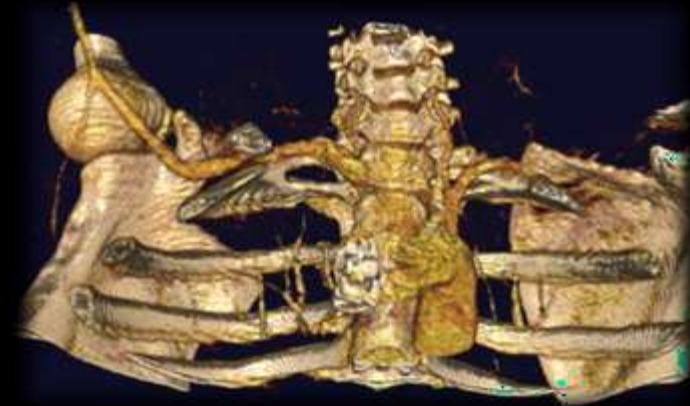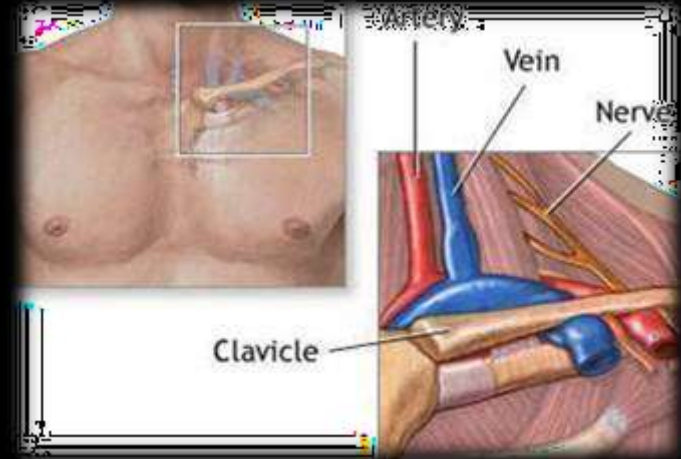
- Aneurysm
- Stenosis
- Dissection of aorta
- Atherosclerosis
- A-V fistula
- Thrombosis
- Pulmonary embolism
- Guide to implanting or evaluating stents

• **Thoracic Outlet Syndrome**

- Pregnancy
- unstable vital signs
- Allergic patient
- Kidney problems
- Severe diabetes

Thoracic Outlet Syndrome:

- The thoracic outlet is the area connecting the neck to the chest.
- TOS symptoms: pain in the arms, shoulder and neck, can turn blue.
- Caused by nerve or BV compression.



3D reconstructed image of RT subclavian artery compressed at costo-clavicular level.

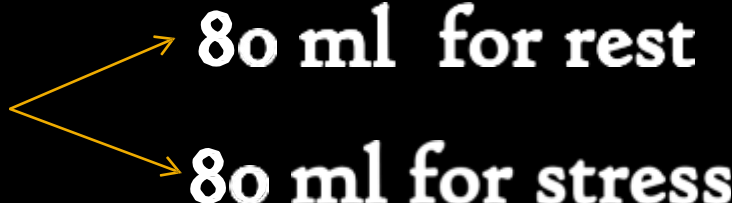
Differ than the previous
technique in the following...

Pt position:

[Subclavian]

- Exam is done twice, in two arm positions;
 1. Stress(elevated) &
 2. Rest (beside the Patient)
- Each has its own scout(pa/lat) image.

Contrast media:

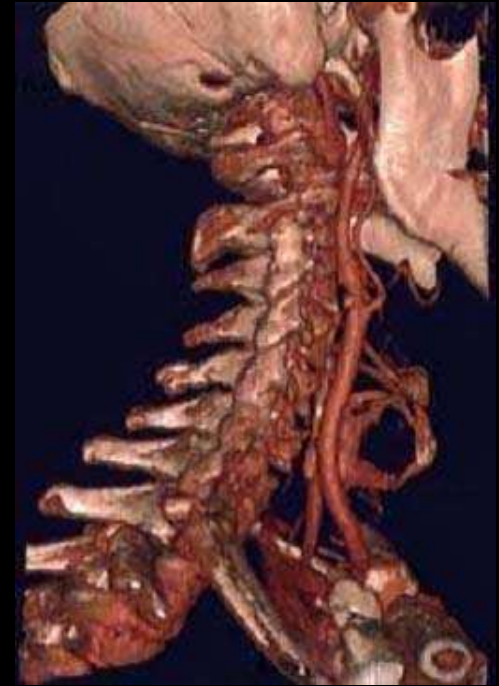
- Injection in *foot vein*. Why?
- ✓ To avoid the artifact caused by the thick CM in the subclavian artery of the injected arm.
- **Volume:** 160 ml 
 - 80 ml for rest
 - 80 ml for stress

Axial slices

Start location: half of carotid a.
or neck.

End location: down to mid chest
(bifurcation).

FOV is adjusted to as small as
possible; but include shoulder.



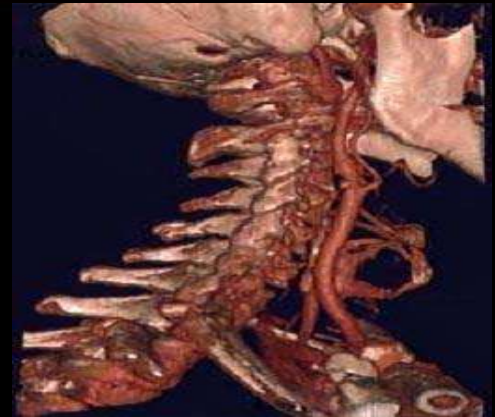Carotid arteries

Axial slices

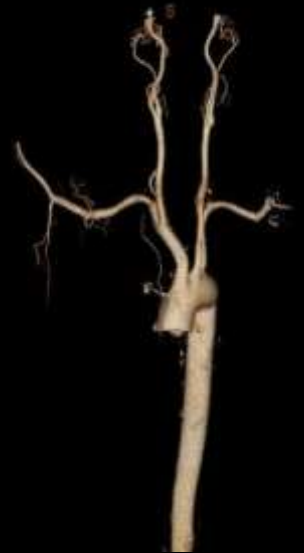Start location: half of carotid artery or neck.

End location: down to mid chest (bifurcation).

FOV is adjusted to as small as possible; but include shoulder.



Carotid arteries



ADVANTAGES

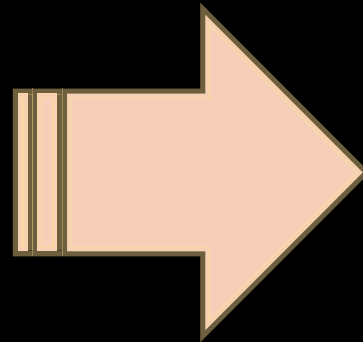
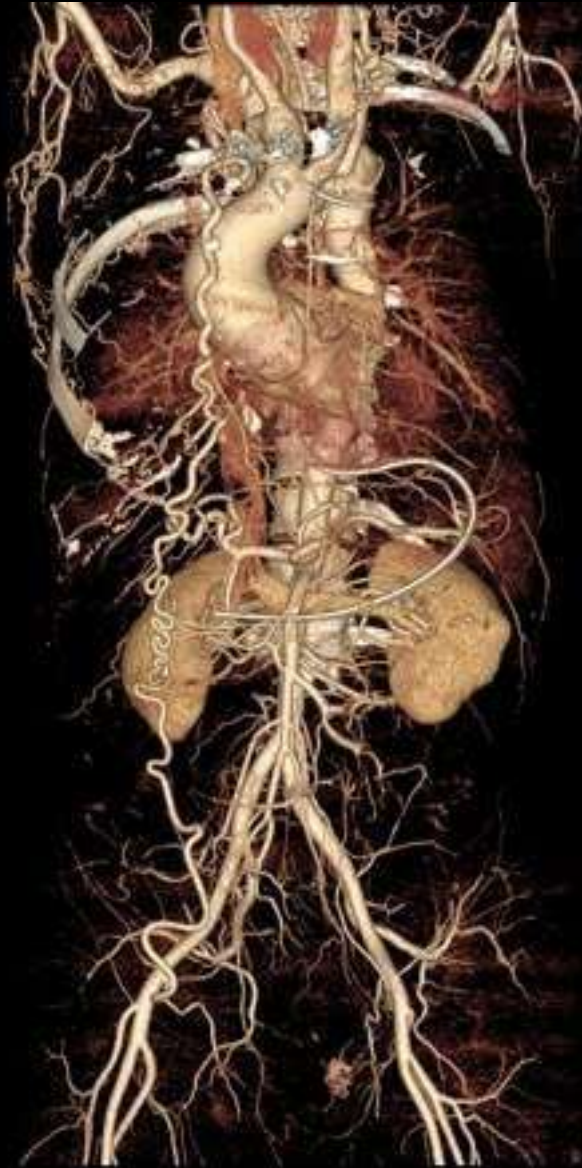
- CT angiography may give more precise anatomical detail than MRI, particularly in small blood vessels.
- Many patients can undergo CT angiography instead of a conventional catheter angiography (catheterization) to diagnose blood vessel problems.
- Lower cost examination compared to catheter angiography.

DISADVANTAGES

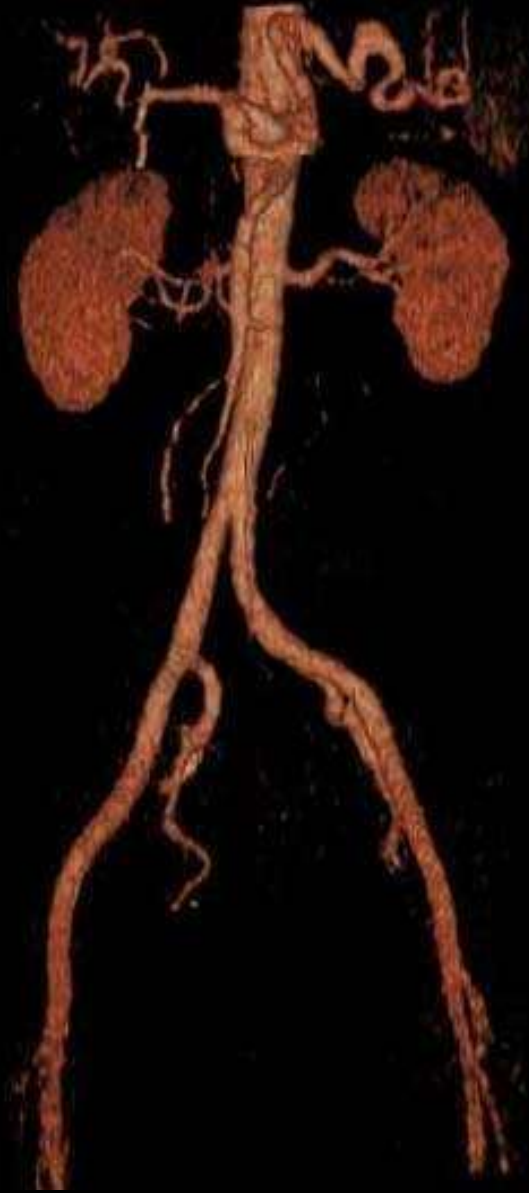
- There is always a slight chance of cancer from excessive exposure to radiation.
- However, the benefit of an accurate diagnosis far outweighs the risk.
- If a large amount of x-ray contrast material leaks out from the vein being injected and spreads under the skin where the IV is placed, it may damage the skin, blood vessels and nerves.
- There might be a risk of serious allergic reaction to contrast materials that contain iodine

To conclude..

- In CT angiography, 3D reconstruction is a must.
- Thin slices are needed or overlapped slices are needed.
- Auto Bone subtraction, or any other unwanted soft tissue structure is subtracted.
- Ct angio is not likely repeated.



Subtraction
or
Cleaning



Thank U



No thing is impossible, the word itself says "I'm possible"