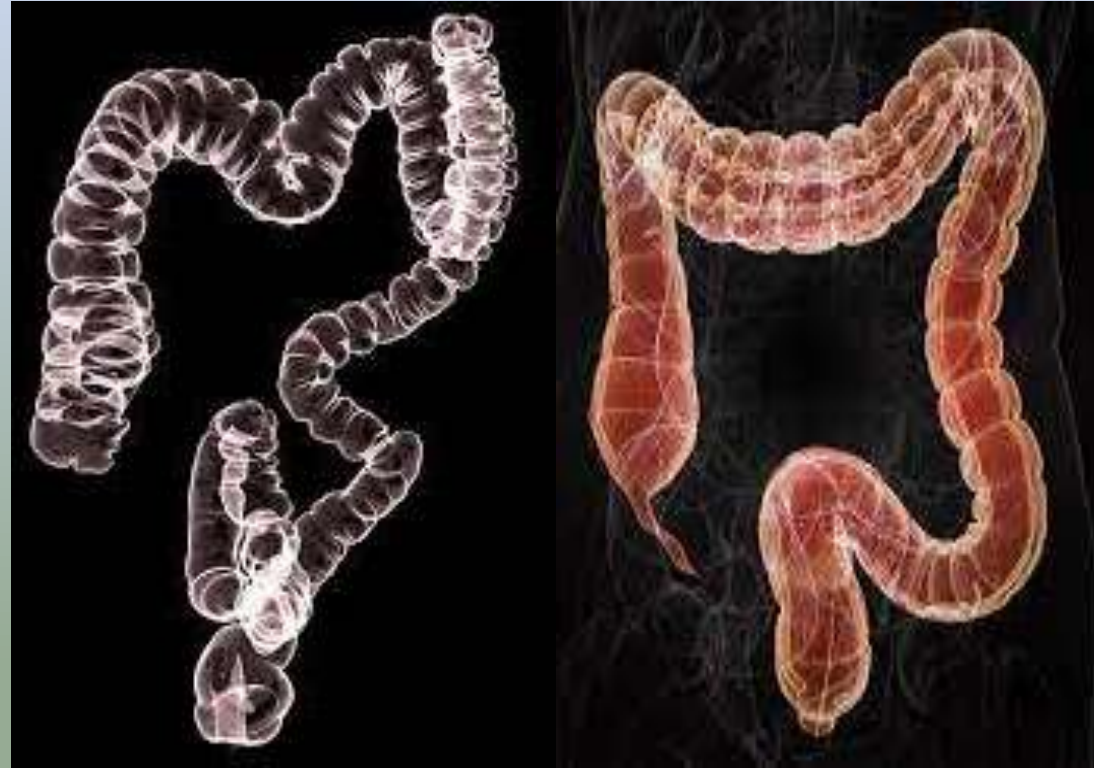


COLONOSCOPY & BRONCHOSCOPY



COLONOSCOPY

- Anatomy
- Indication
- Contraindication
- Patient preparation
- Procedure
- Post processing

BRONCHOSCOPY

- Anatomy
- Indication
- Contraindication
- Patient preparation
- Procedure
- Post processing

INTRODUCTION

Computed tomography (CT) colonography or virtual colonoscopy uses special x-ray equipment to examine the large intestine for cancer and growths called polyps.

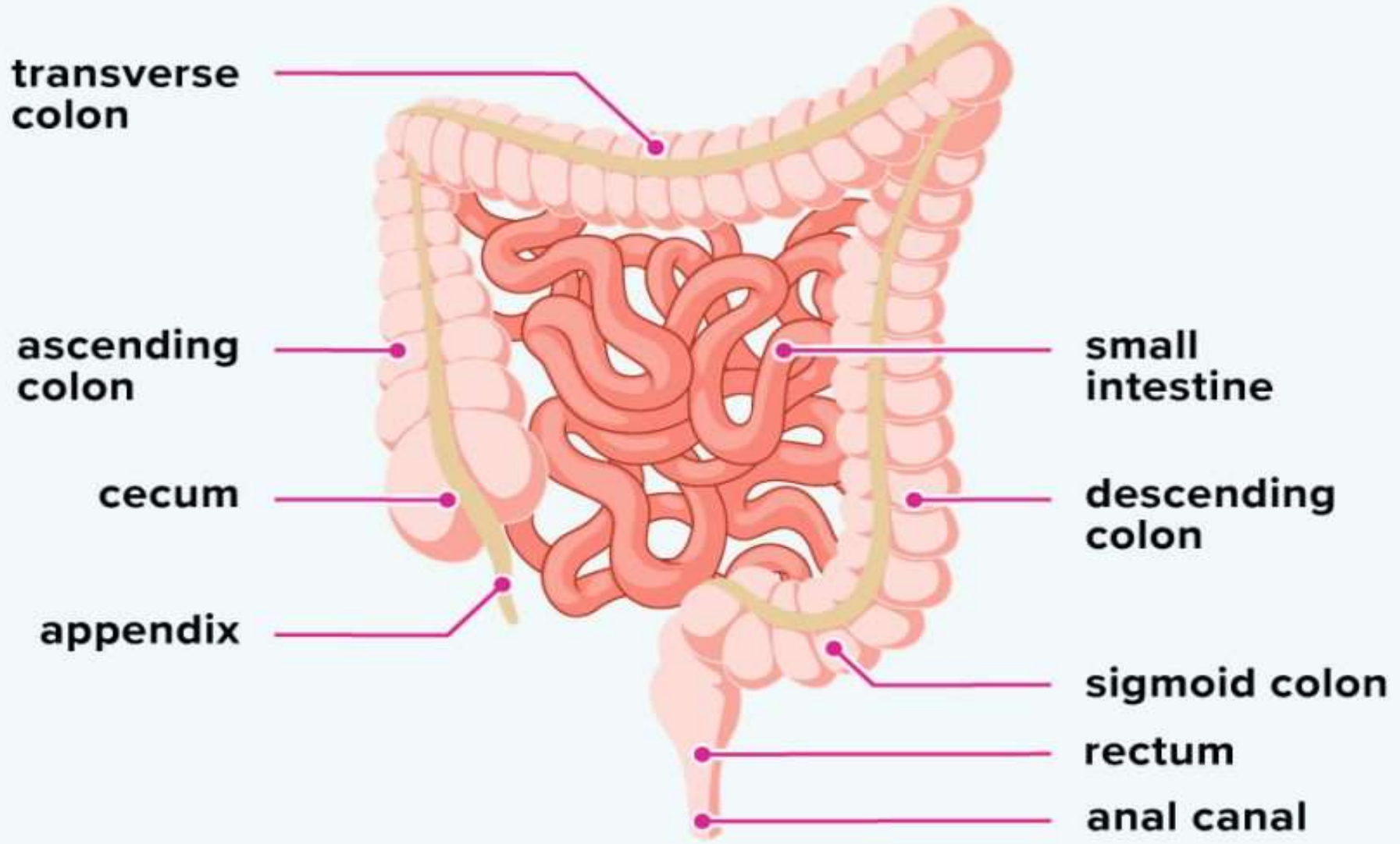
During the exam, a small tube is inserted a short distance into the rectum to allow for inflation with gas while CT images of the colon and the rectum are taken.

Colonoscopy is the standard practice for colorectal cancer screening, but it has a chance of failing cecal intubation and carries a risk of horrific adverse events by colonic perforation.

Computed tomographic colonography (CTC) was first introduced by Vining in 1994 as an alternative imaging method for evaluation of the colon.

In this technique, helical computed tomography (CT) data is used to produce three dimensional images and hence simulates a virtual endoluminal view; hence, also called virtual colonoscopy.

Small and large intestines



INDICATION

- Screening test for [colorectal carcinoma](#) (early detection)
- Colon evaluation after incomplete or unsuccessful conventional colonoscopy
- Assessment of strictures to better evaluate the colon proximal to obstructing neoplasms detected by conventional colonoscopy
- Patients with contraindications or refusing conventional colonoscopy

CONTRAINDICATION

- Acute inflammatory condition of the bowel
- Acute inflammatory bowel disease or diverticulitis,
- Due to the increased risk of perforation following insufflation of colon

PATIENT PREPERATION

PRECAUTIONS: Pregnant

CLOTHING: Patient gown

EAT/DRINK: NPO

MEDICATION: All patients can take their prescribed medications as usual.

Give Laxative (magnesium citrate, sodium phosphate, picolax & polyethylene glycol).

Advice to hold breathe at the time of examination

PROCEDURE

- Patient is asked to lie on his/her left side on a narrow table that is connected to a CT scan machine. knees will be up towards the chest.
- A small, flexible tube will be inserted into rectum.
- Air is pumped through the tube to make the colon bigger and easier to see. After this is done, patient will be asked to lie in supine position.
- The table moves through the scanner to produce a series of two-dimensional cross-sections along the length of the colon.
- A computer program puts these images together to create a three-dimensional picture that can be viewed on the video screen .
- Patient is asked to hold his/her breath during the scan to avoid distortion on the images.
- The scan is then repeated with the patient lying in a prone position .

FLY THROUGH AND FLY AROUND

“Fly through” function has been shown to be effective in clinical application such as virtual endoscopy and the evaluation of stent placement

“Fly around” is useful for the evaluation of complex local anatomy such as carotid artery stenosis and vascular anomalies

These tools are used to showing the inside hollow structures , correlating 3D endoscopic and MPR images , and a number of fly modes

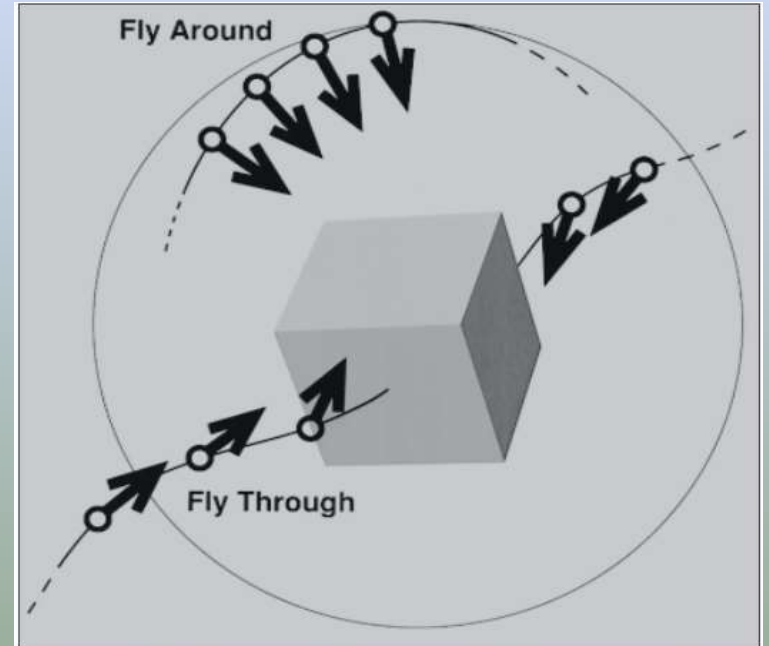

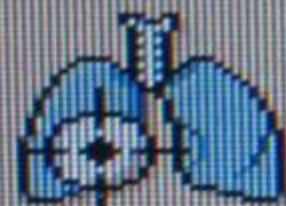


Figure 7. Diagram illustrates fly-through and fly-around display functions. A fly-through reconstructs an image sequence with rotation and dolly similar to what is used for a complex camera shot. A fly-around projects a sequence of views from the surface of a sphere that has the region of interest at its center.



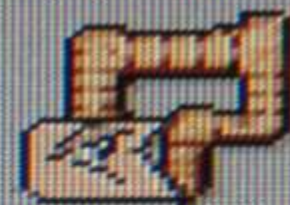
AVA




Lung Nodule
Assessment




Lung Density



Virtual
Colonoscopy



Comp.
Cardiac




Heart Beat-
CS



Brain
Perfusion




Functional
CT



Bone Mineral
Density



Dental
Planning



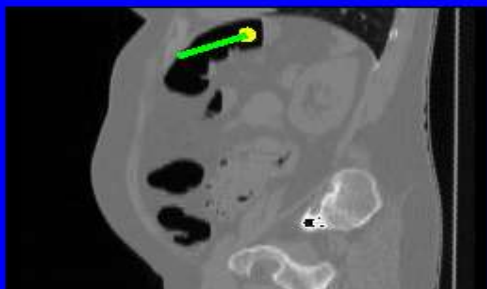
Liver



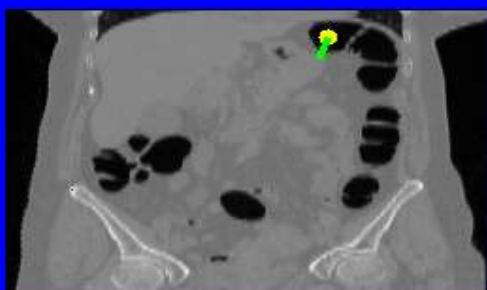
Fat
Assessment

Current Slices

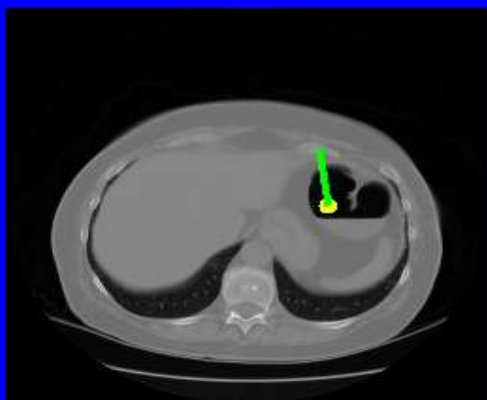Sagittal slice: 343



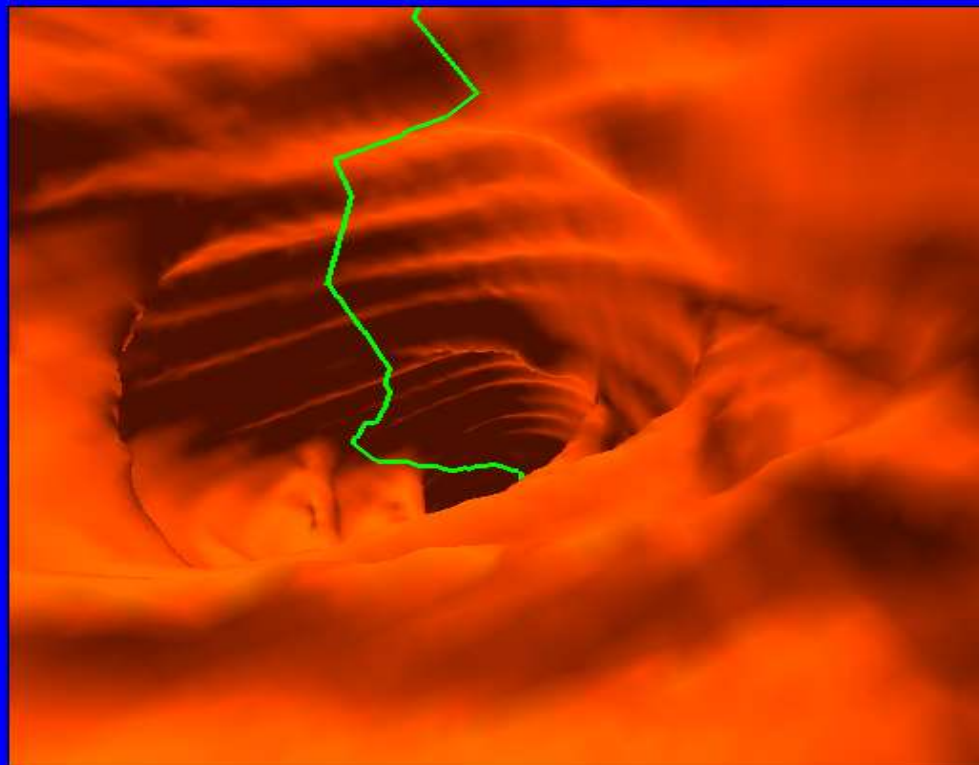
Coronal slice: 257



Transverse slice: 37



Patient: XXXXXX Date of Birth: XXXXXX Hospital ID: XXXXXX



Navigation:

to rectum to appendix skeleton volume render

Camera control:

still leveling compass

Potential field:

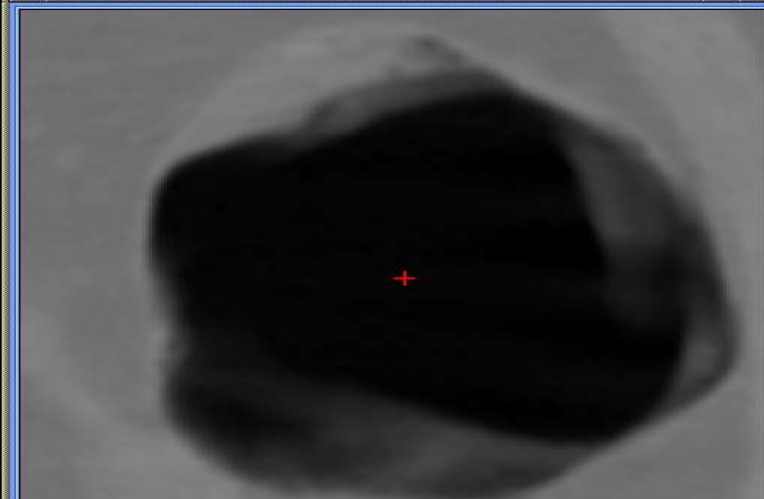
force speed

bounce influence

Others:

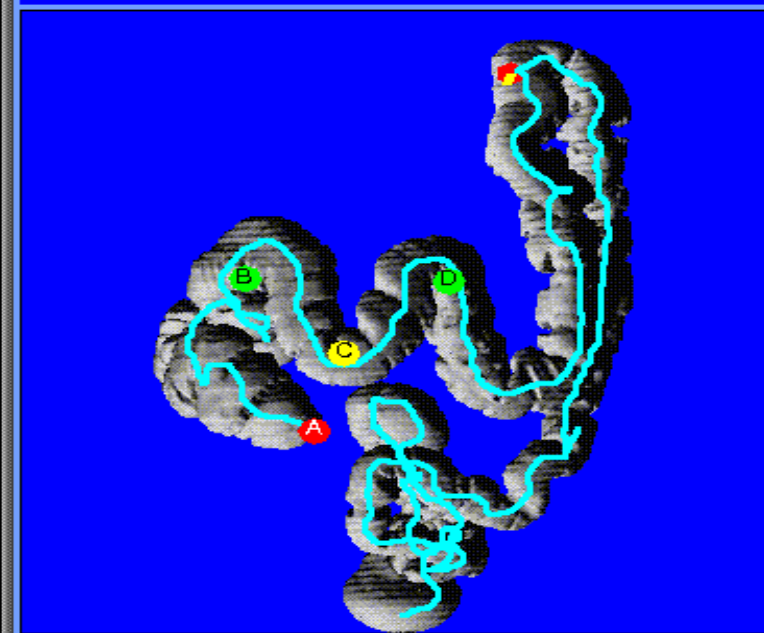
light field-of-view

Colon Cross Section

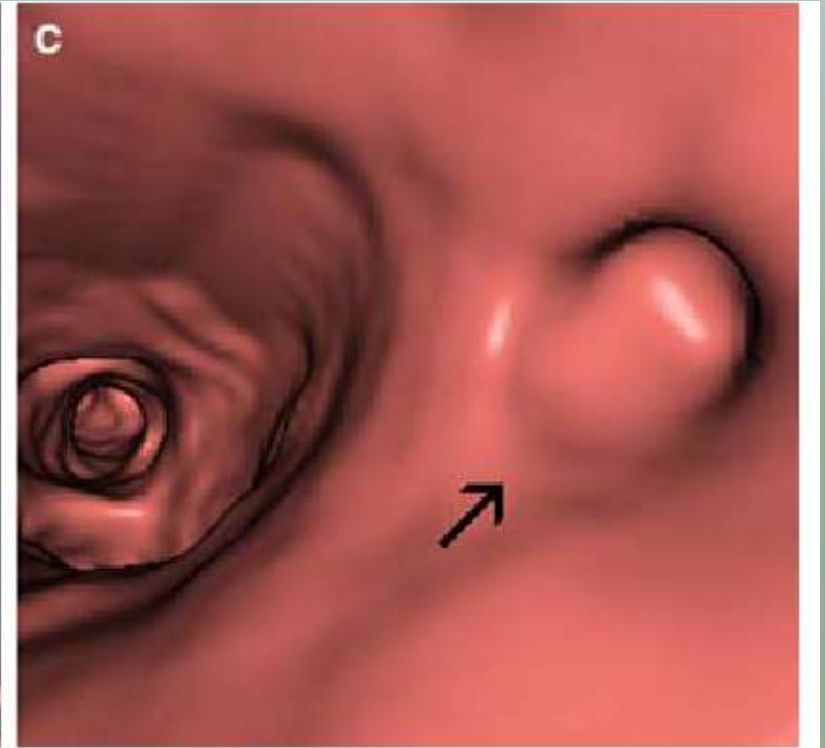
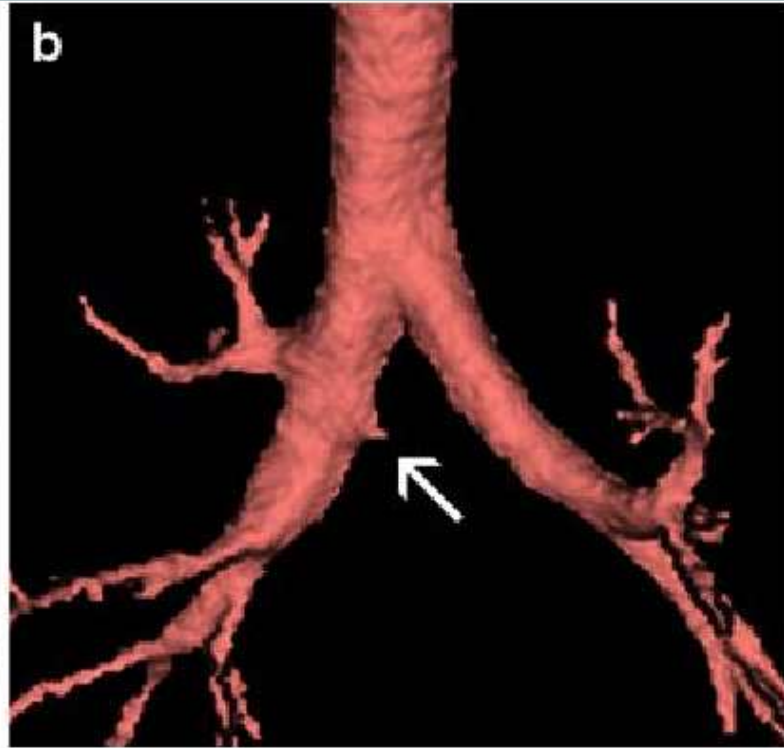
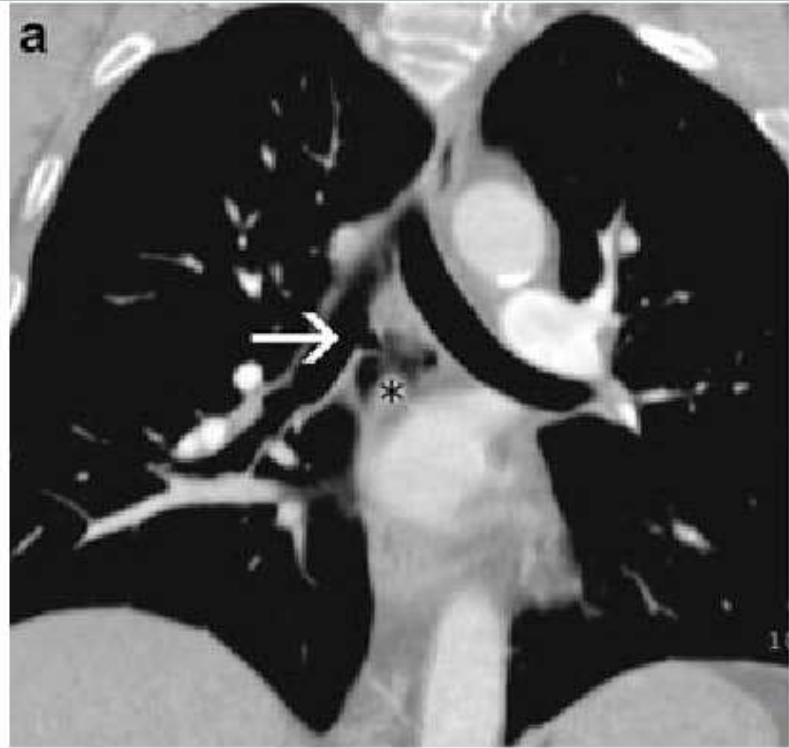


Coronal Projection

Distance from rectum is 91 cm.



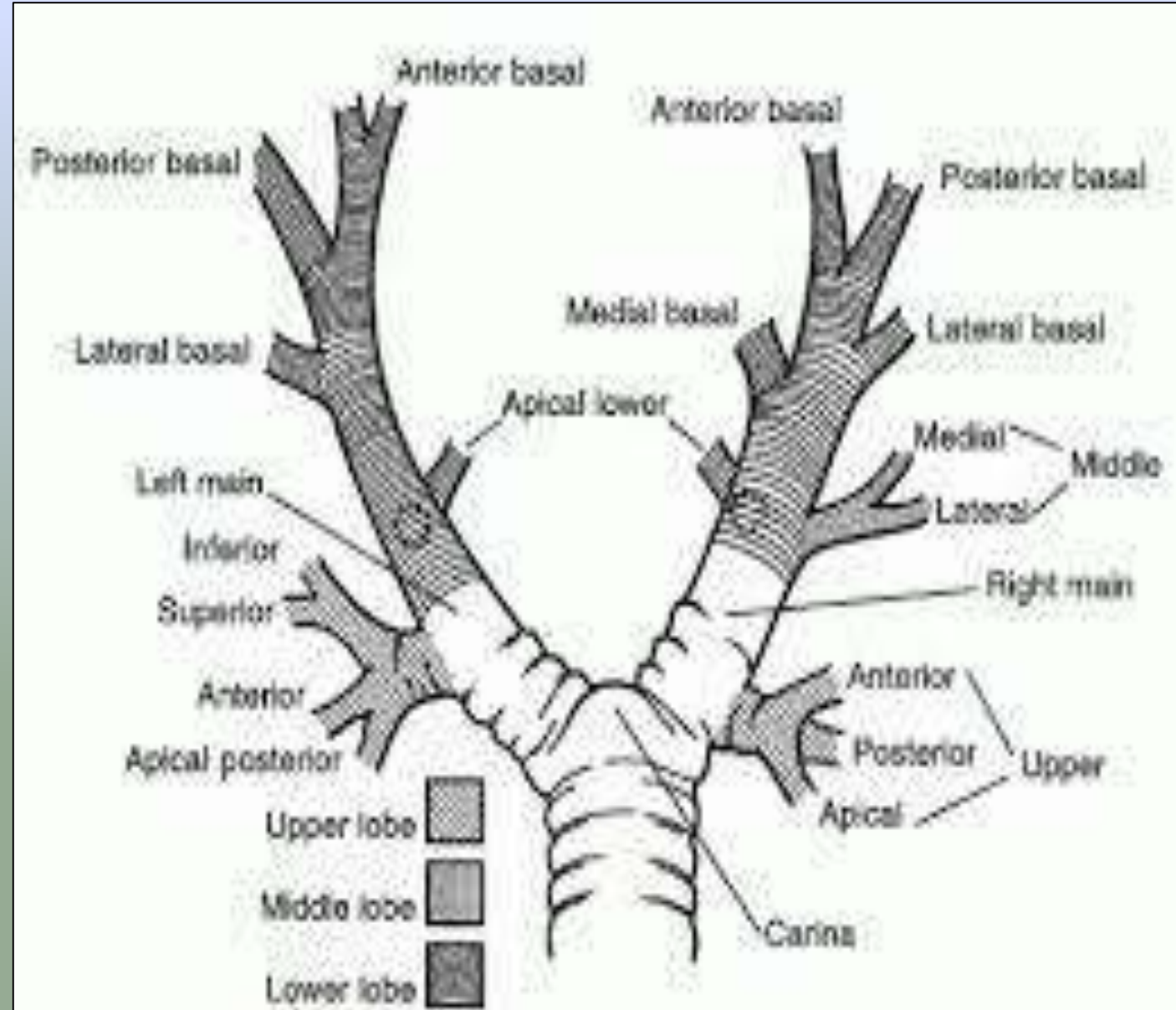
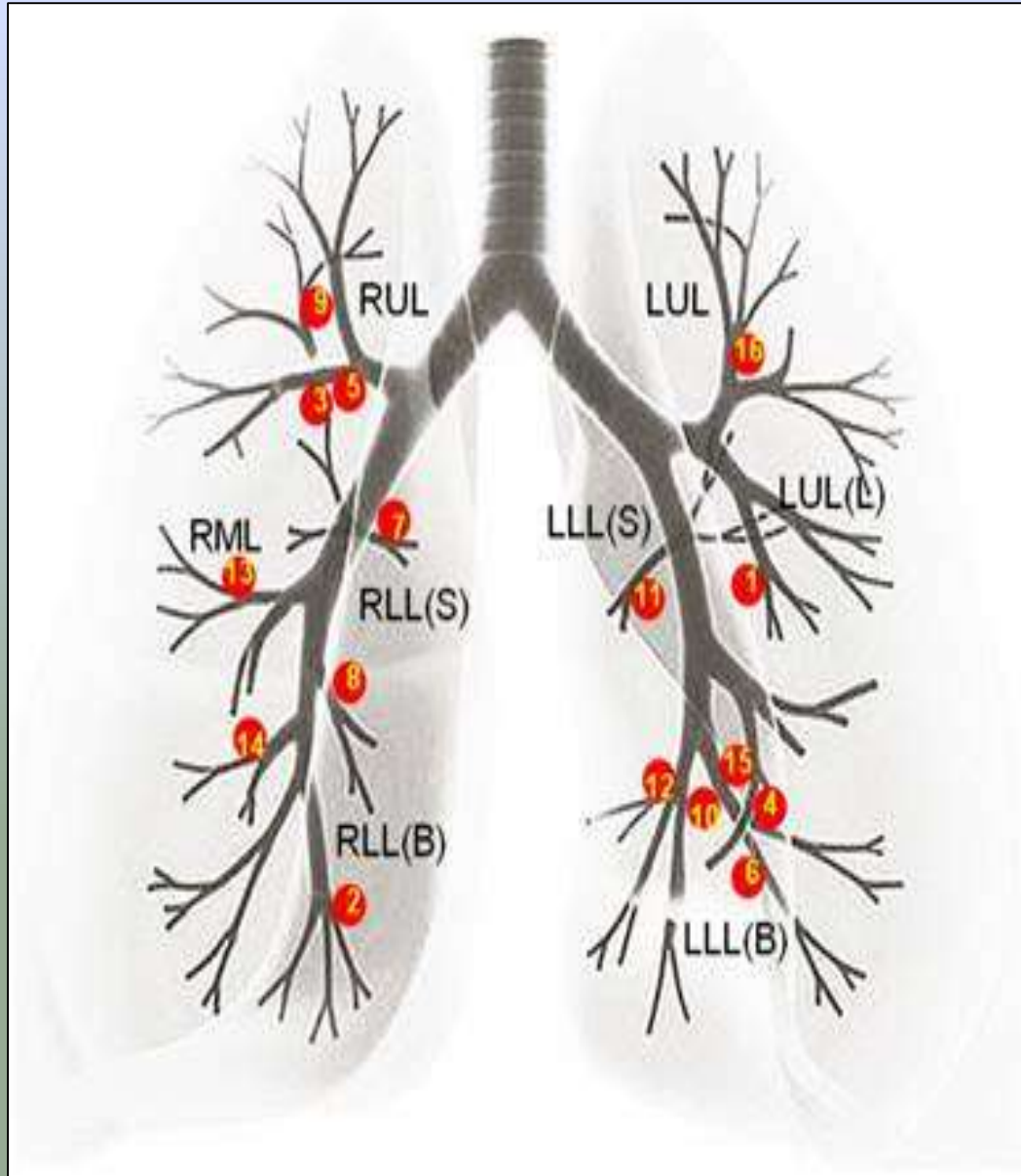
BRONCHOSCOPY



INTRODUCTION

- Virtual bronchoscopy (VB) is a novel computed tomography (ct)-based imaging technique that allows a noninvasive intraluminal evaluation of the tracheobronchial tree.
- Applications normal anatomic features & variants tracheobronchial stenosis bronchogenic carcinoma endoluminal lesions foreign body aspiration imaging guidance tracheoesophageal fistula burn injuries stent planning and follow-up trauma

ANATOMY



INDICATIONS

- Evaluation of bronchial stenosis
- Bronchogenic carcinoma
- External compression on the bronchial wall
- Tracheal or bronchial diverticula
- Evaluation of trachea and bronchi in children
- Guidance of trans bronchial biopsy
- Pre and post operative analysis

CONTRAINDICATIONS

- Recent myocardial infarction
- Unstable angina
- Serious dysarrhythmias
- CO₂ retention

PATIENT PREPARATION

PRECAUTIONS: Pregnant

CLOTHING: Patient gown

MEDICATION: All patients can take their prescribed medications as usual.

Sign a consent form

PROCEDURE

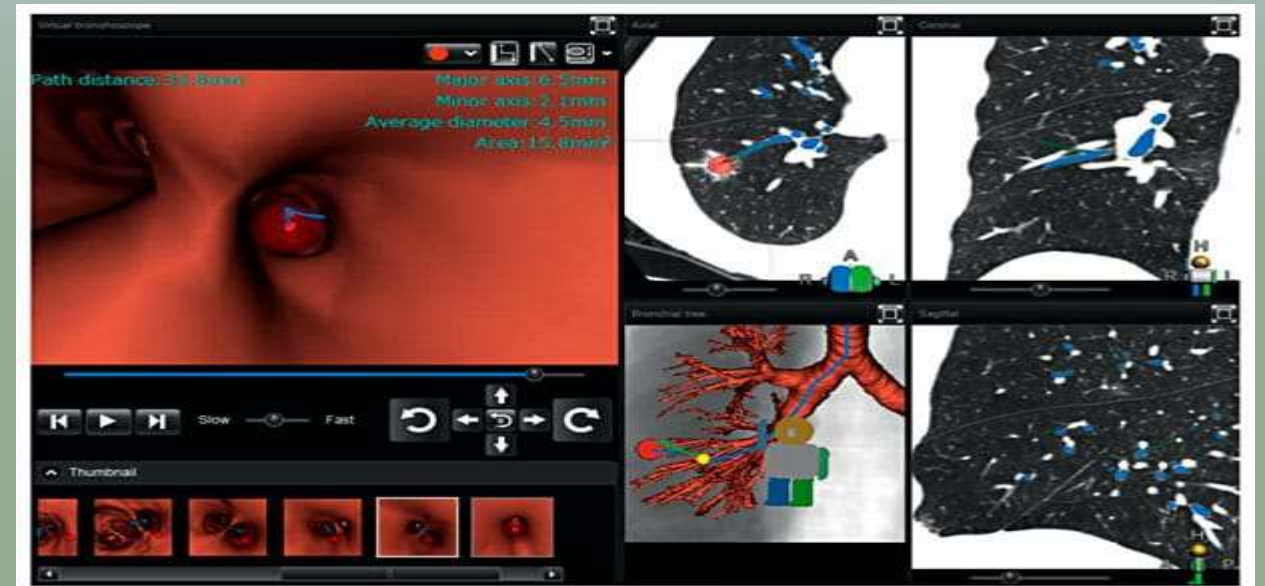- Thorax first scanned post 100mls iv contrast at 5mm collimation
- For VB chest then scanned at 2-3mm collimation with reconstruction interval of 1-1.5mm
- All VBN systems are composed of 2 phases: planning and guidance
- **Planning is a pre-bronchoscopy process to prepare for the production of VB images of a bronchial route to the target lesion.**
- **Guidance is the procedure to navigate a bronchoscope to the target lesion using VBN systems during bronchoscopy.**

PLANNING

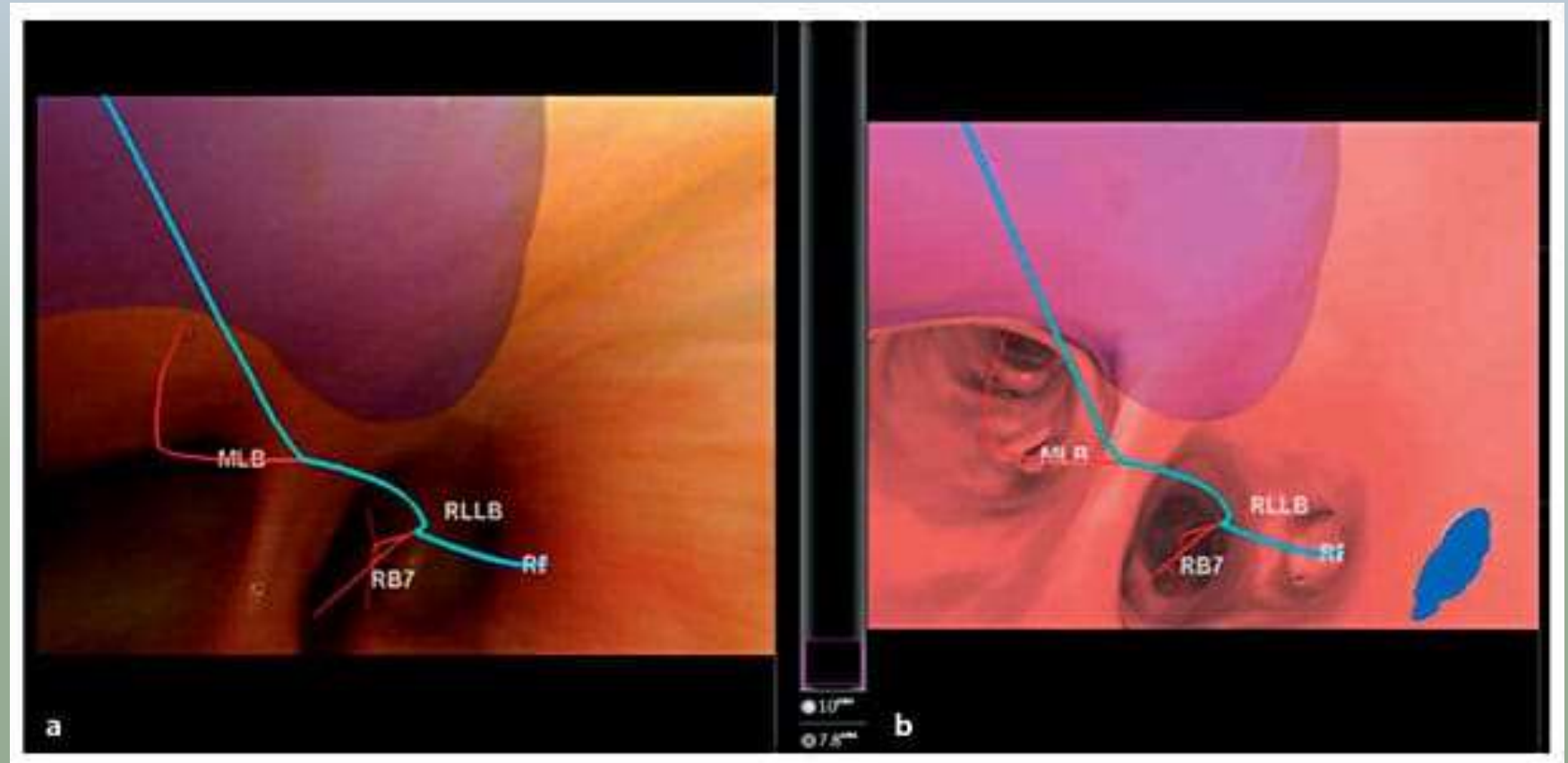
- Firstly, CT scan and image reconstruction are performed under conditions recommended for each VBN system.
- The recommended slice thickness (and reconstruction interval) is ≤ 1 mm. With thinner slices, VB images to more peripheral areas can be produced.
- When poor images are produced owing to respiratory artifacts, accurate VB images cannot be expected.
- With Lung Point, automatic processing is initiated upon input of CT information in a DICOM (Digital Imaging and Communications in Medicine) format into the system, after which the airway is extracted
- Axial, sagittal and coronal cross-sectional CT images are then displayed

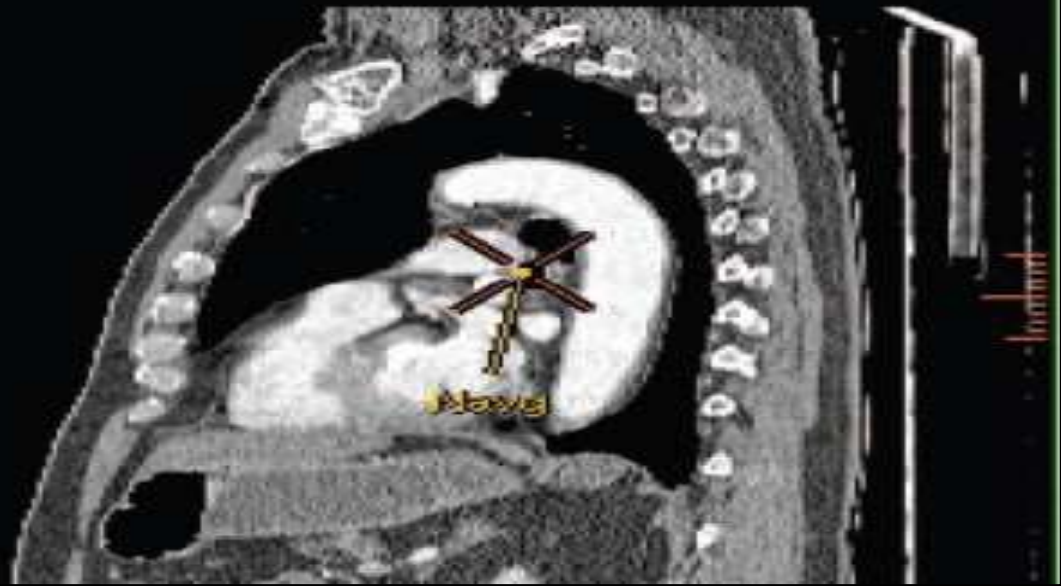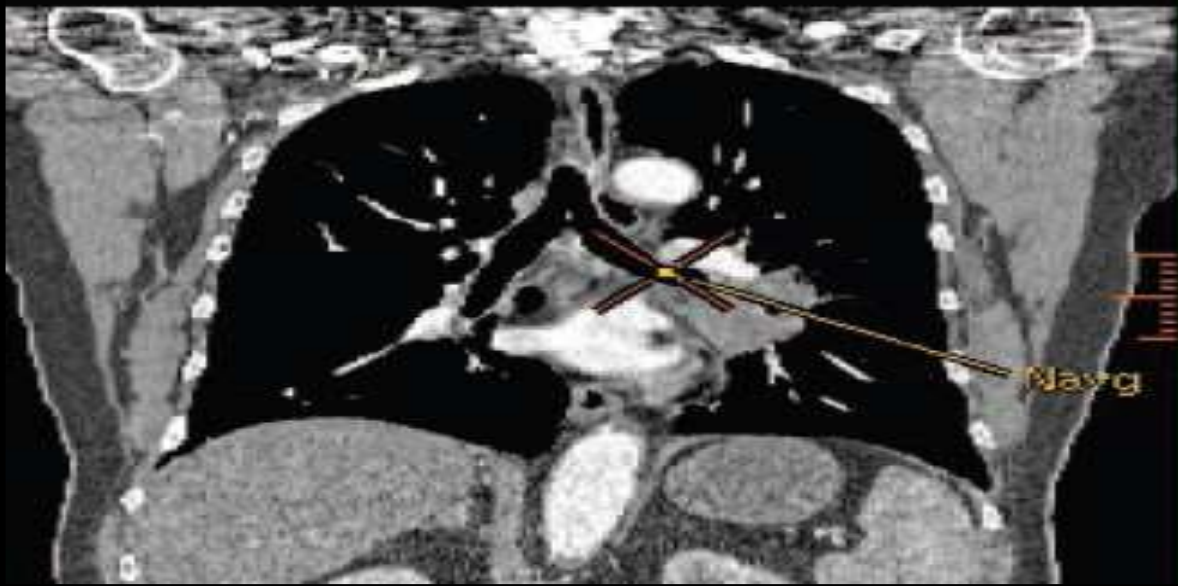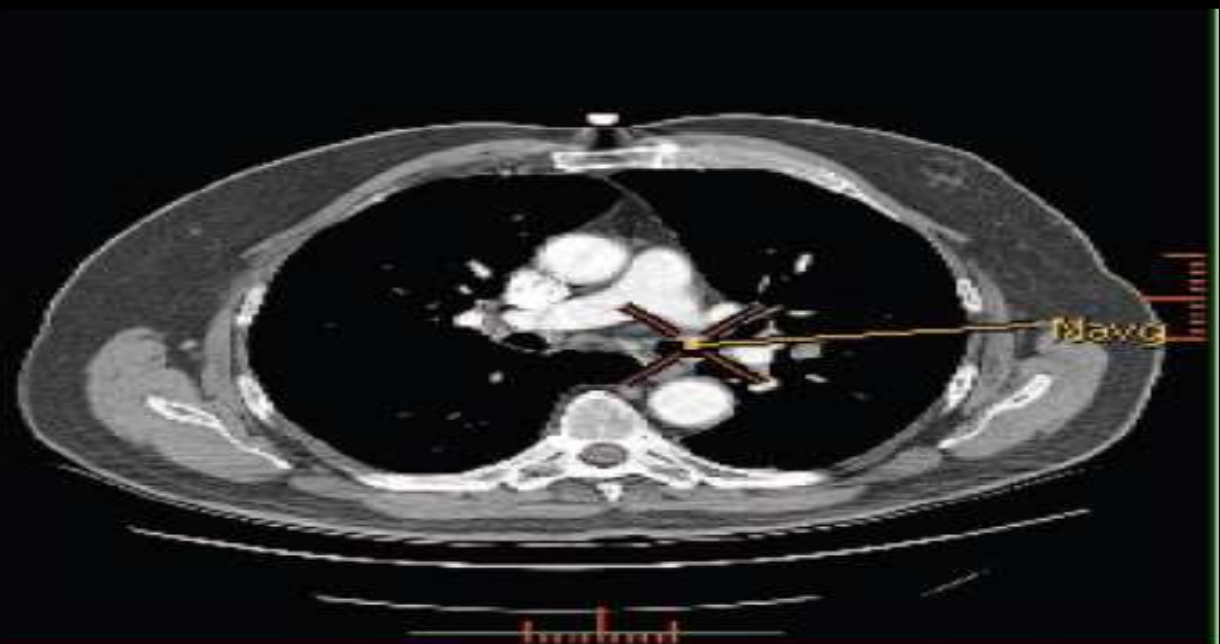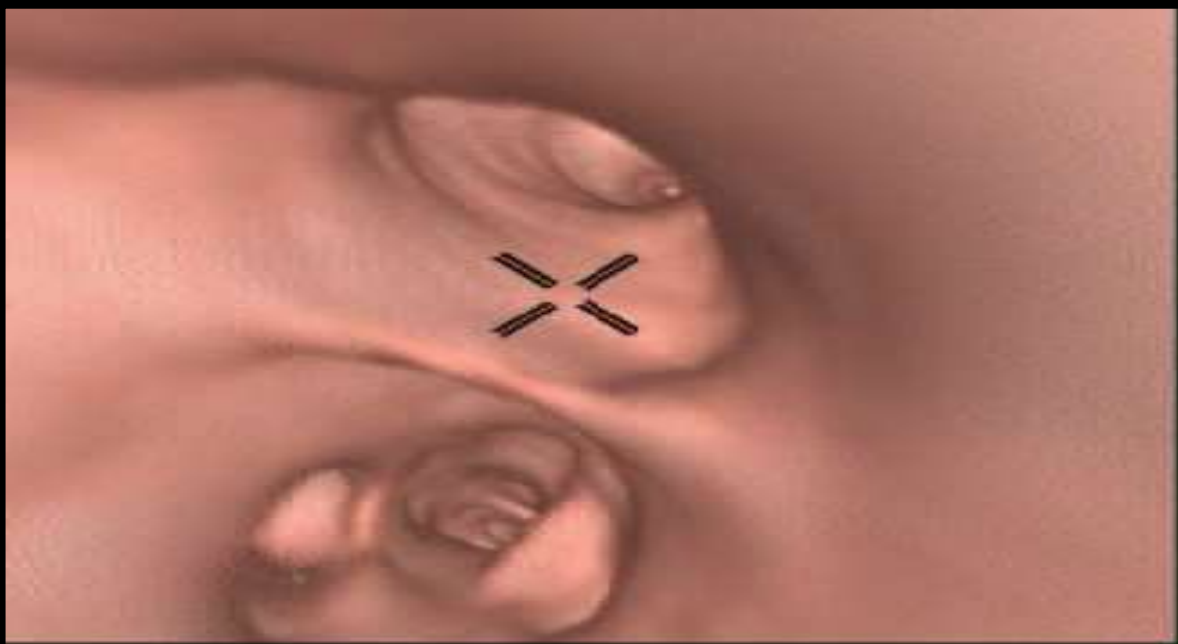
GUIDANCE

- The procedure performed during bronchoscopy is carried out to guide the bronchoscope to the target bronchus
- Bf-NAVI presents the bronchus to which the bronchoscope is advanced on the VB image at each branching.
- The operator advances the bronchoscope manually by collating the VB image with the real image
- By presenting VB images consistent with the real images on bronchoscopy, the position of the bronchoscope tip can be displayed on the CT images corresponding to the bronchial tree



Lung Point guidance screen. a Real bronchial image. b A VB image consistent with the real image is automatically selected and displayed. The bronchial route (blue line) to the lesion and the names of the bronchi are presented. These are also presented on the real image. Both images move in conjunction automatically.





VIRTUAL BRONCHOSCOPY

- Endoluminal & extraluminal views
- Many quantitative measurements can be taken
- Reduce complications (Infection & perforation) – Non-invasive
- Multiple simultaneous views and in unrestricted direction

REAL BRONCHOSCOPY

- Only endoluminal view
- Quantitation is limited
- Uncomfortable because of the physical device
- Only one view is possible at one time in frontal direction

TABLE 13-5 Comparison of Features of Virtual and Real Bronchoscopy

Virtual Bronchoscopy

Imaging environment is a virtual environment as captured in a 3D CT image

Awareness is enhanced by the many display tools

Many quantitative measurements can be taken

Viewing direction is unrestricted

Views inside and outside solid structures are possible

Viewing geometry is controllable

User can track 3D position during navigation

Multiple simultaneous views are possible

Cine sequences can be recorded

No information on the mucosal surface can be obtained

Performance of interventional procedures with views is not possible without linkage to a real bronchoscope

View quality is limited by image resolution

Real Bronchoscopy

Imaging environment is illuminated in in vivo endoluminal regions

Video is the only display tool

Quantitation is limited

Only frontal views are possible

Only endoluminal views are possible

Perspective is fixed

User must remember position of scope

User can see only one view at a time

High-quality video can be recorded

Detailed information on the mucosal surface can be obtained

Real intervention is possible

High-resolution video is used.

REFERENCES

- Seeram, Euclid, author. Computed tomography : physical principles, clinical applications, and quality control / Dr. Euclid Seeram. – Fourth edition. p. ; cm. Includes bibliographical references and index. ISBN 978-0-323-31288-2 (pbk. : alk. paper) I. Title. [DNLM: 1. Tomography, X Ray Computed. WN 206] RC78.7.T6 616.07'572--dc23
- Dhakshina Ganeshan, Khaled M Elsayes, David Vining; Virtual colonoscopy: Utility, impact and overview; World J Radiol 2013; 5(3): 61-67
- W. De Wever, V. Vandecaveye, S. Lanciotti, J.A. Verschakelen; Multidetector CT-generated virtual bronchoscopy: an illustrated review of the potential clinical indications; Eur Respir J 2004; 23: 776–782.

Thank you...