

# NCCT& CECT UPPER & LOWER EXTREMITY WITH IMAGE FILTER PROTOCOL

- ▶ NCCT Scan or a Non-contrast CT scan is a special X-ray test that generates cross-sectional images of the body through X-rays and a computer.

Purpose

Detail imaging of internal organs for better diagnosis.

Preparation

NCCT Scan: No Special Preparation Required,  
CECT Scan: 4-6 hours of fasting

### **CT Scan Extremities or Limbs**

It is done to detect fractures, mass, dislocations, and injury to the ligament.

# Protocol for Extremity imaging

- ▶ Indication - Suspected occult fracture , complex fracture , preoperative evaluation & postsurgical , bony or soft tissue masses.
- ▶ Patient positioning - Head first or feet first , supine or prone.
- ▶ Scan orientation - proximal to distal
- ▶ Starting location - 2-3cm above the superior limit of region of interest
- ▶ End location - 2-3cm above the superior limit of region of interest.
- ▶ Field of view - just fitting the region of interest including the soft tissue
- ▶ Contrast administration - IV ( optional - in case of mass lesions)

- ▶ Volume of contrast - 60-100ml
- ▶ Rate of injection of contrast - 2-3ml/sec.
- ▶ Slice thickness - 1-2mm
- ▶ Slice interval- 0.5- 1.0 mm.
- ▶ Reconstruction algorithm/ kernel- sharp for bone & medium smooth for soft tissue.
- ▶ 3D-R eonstructions - MPR, thick & thin MIP, SSD.

# Upper extremity imaging

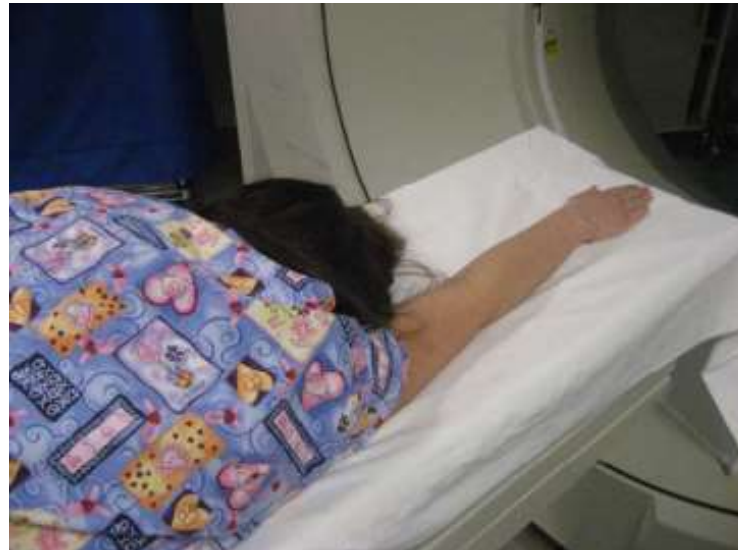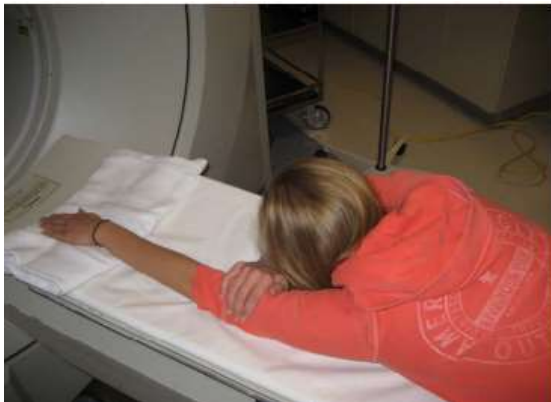## CT hand and wrist (protocol)

- ▶ The **CT hand and wrist protocol** serves as an examination for the bony assessment of the wrist and is often performed as a non-contrast study and less often as a contrast-enhanced study.

# Indications

- ▶ Typical indications include the following
  - complex distal radial fractures and ulnar fractures
  - scaphoid fractures or carpal fractures
  - carpal instability
  - foreign bodies
  - inflammatory or infectious processes
  - bone and soft tissue tumors (if MRI is contraindicated)
  - postoperative follow up, implants and their complications
  - CT arthrogram
    - ligamentous injury
    - triangular fibrocartilage complex injury

- ▶ Positioning
- ▶ ④ Patient prone
- ▶ ④ Arm over head (“Mighty Mouse Position”)
- ▶ ④ Arm as straight as possible
- ▶ ④ Wrist centered in gantry



# Patient preparation

- ▶ For contrast studies patient should be NPO for atleast 4 to 6 hrs.
- ▶ Patient's recent KFT is checked before contrast examination
- ▶ Informed consent is mandatory.



# protocol

- **tube voltage**

- $\leq 120$  kVp (100 kVp)

- **tube current**

- as suggested by the automated current adjustment mode

- **scout**

- whole hand to the distal third of the forearm

- **scan extent**

- wrist: including radial metaphysis and proximal third of the metacarpal bones

- hand: includes the entire hand to the radial metaphysis

- **scan direction**

- craniocaudal

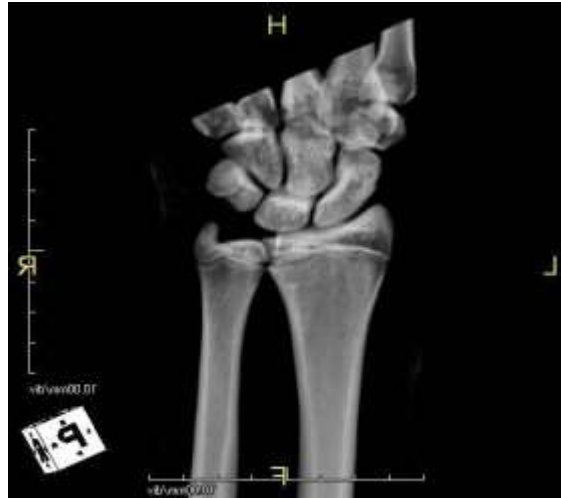- **scan geometry**

- field of view (FOV):  $\leq 150$  mm (should be adjusted to increase in-plane resolution)

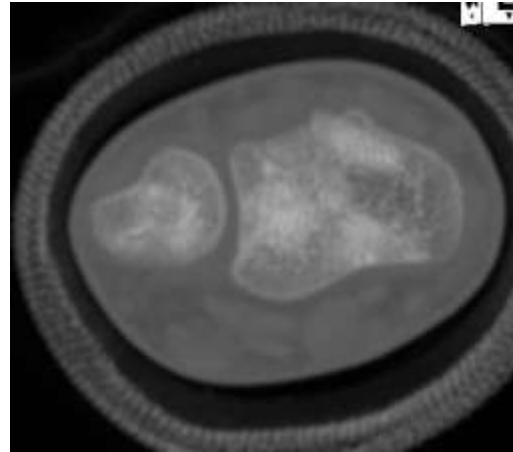
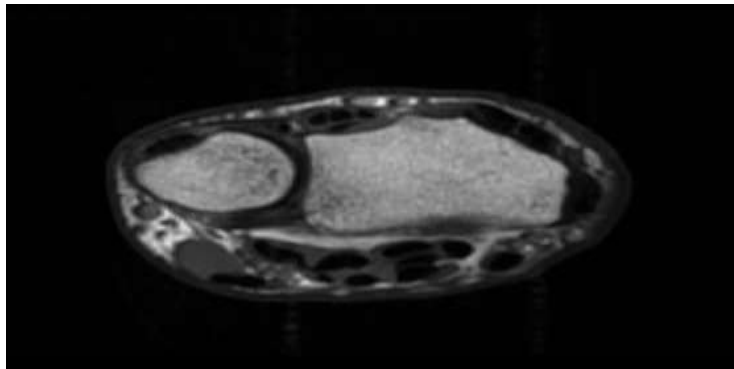
- slice thickness:  $\leq 0.625$  mm, interval:  $\leq 0.3$  mm

- reconstruction algorithm: bone, soft tissue

- ▶ Contrast Administration - intravenous ( optional - in case of mass lesions )
- ▶ Volume of contrast - 60 -100ml
- ▶ Rate of injection of contrast - 2-3 ml /sec.
- ▶ 3D -Reconstruction -MPR, thick and thin MIP ,SSD

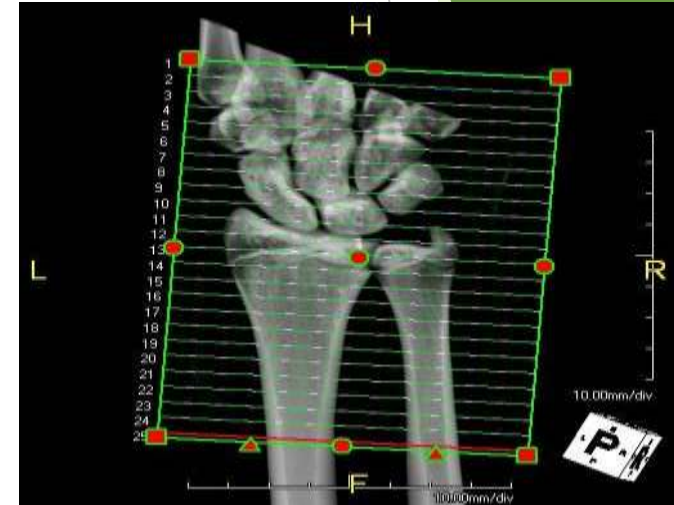


## Relevant Anatomy

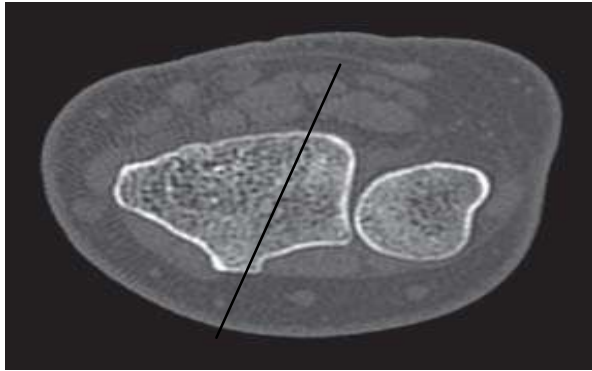


Prescribe plane parallel to line drawn from ulnar styloid through radial styloid.

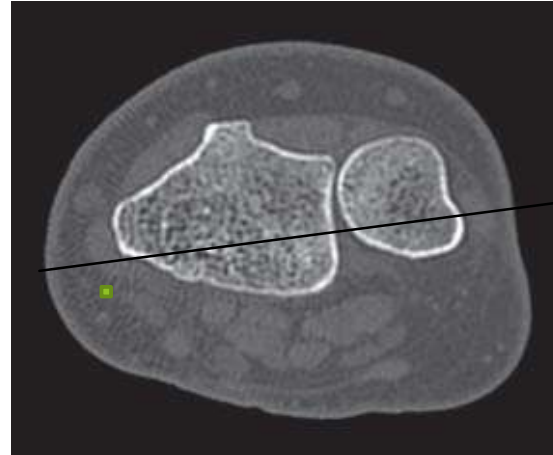
## Sagittal Imaging Plane



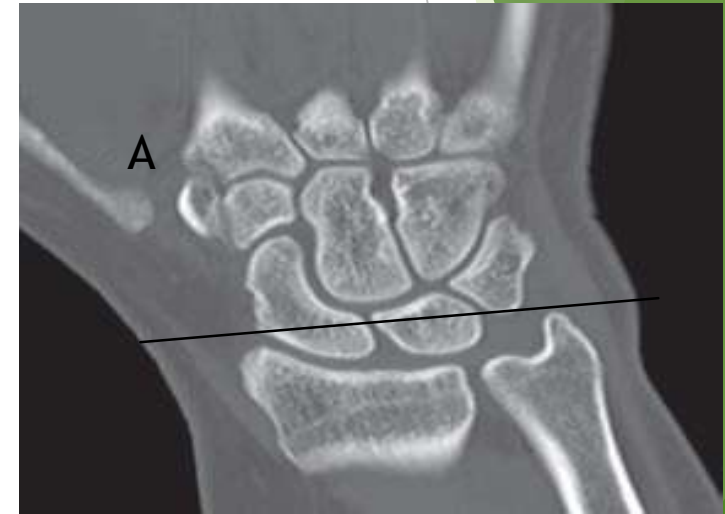Scan from proximal metacarpals through distal radial/ulnar metaphysis.



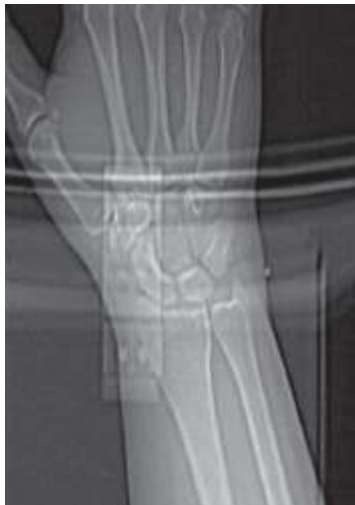C



B



A



D

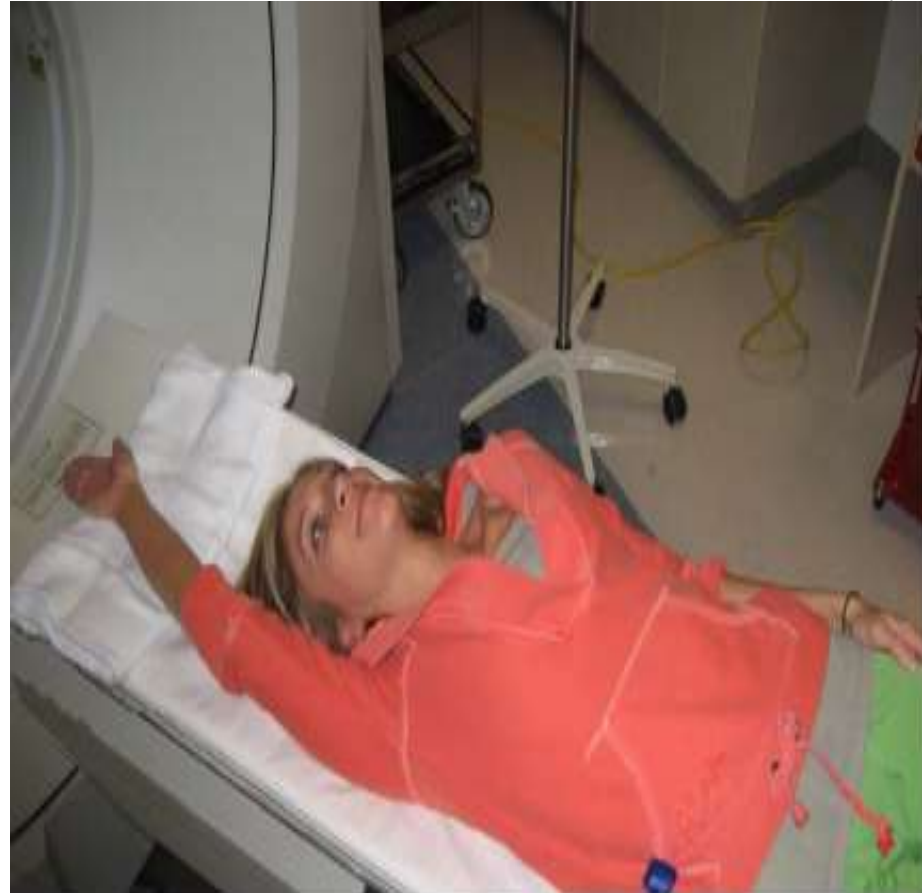**FIGURE 22-7** **A.** Axial MPR can be programmed from the scout image and should be perpendicular to the radius. **B.** Coronal MPR can be programmed from an axial image and should be centered at the distal radioulnar joint through the radial tuberosity. **C.** Sagittal MPR can be programmed from an axial image and should be perpendicular to the plane used in the coronal MPR. **D.** Oblique-sagittal MPR can be programmed from a coronal MRP image and should follow the long axis of the scaphoid (arrow).

# CT elbow (protocol)

- ▶ The **CT elbow protocol** serves as an examination for the bony assessment of the elbow and is usually performed as a non-contrast study. It can be also combined with a CT arthrogram for the evaluation of chondral and osteochondral injuries
- ▶ **Indications**
  - elbow trauma distal humeral fractures
  - proximal radial and ulnar fractures
  - elbow dislocation

# ELBOW

- ▶ Positioning
- ▶ ④ Patient supine
- ▶ ④ Arm by side or raised above head
- ▶ ④ Palm up



# protocol

- **tube voltage**
  - $\leq 120$  kVp
- **tube current**
  - as suggested by the automated current adjustment mode ( $\leq 150$  mAs)
- **scout**
  - mid-upper arm to mid-forearm
- **scan extent**
  - including the humeral metaphysis and the proximal third of the ulna and radius
  - might vary depending on the indication

- **scan direction**

- caudocranial

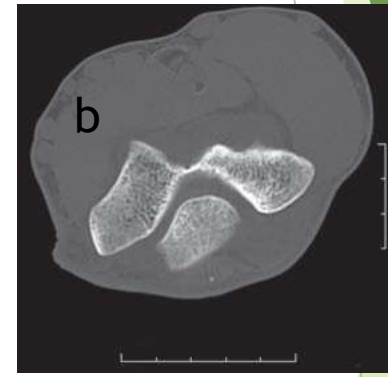
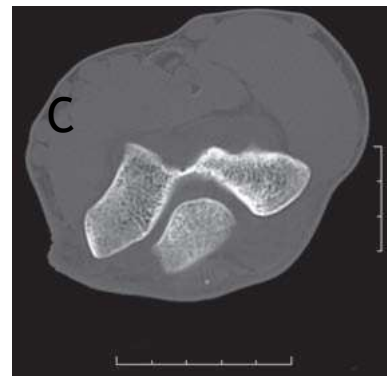
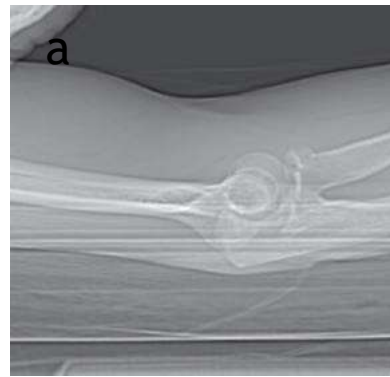
- **scan geometry**

- field of view (FOV):  $\leq 150$  mm (should be adjusted to increase in-plane resolution)

- slice thickness:  $\leq 0.625$  mm, interval:  $\leq 0.3$  mm

- reconstruction algorithm: bone, soft tissue





A. Axial MPR can be programmed from the scout , and should be parallel to the radial head. **B.** Oblique-coronal MPR can be pro-grammed from an axial image at the level of the humeru sepicondyles (arrows) and the olecranon (double arrow). **C .** Oblique-sagittal MPR can be programmed from an axial image and be perpendicular to the plane of the oblique-coronal MPR.

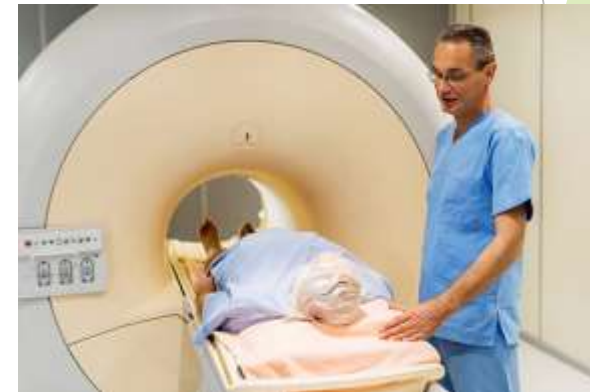# Lower Extremity imaging

## CT hip (protocol)

### ► Indications

► Typical indications include the following <sup>1-6</sup>:

- occult proximal femoral or acetabular fractures
- preoperative planning
  - osteoarthritis of the hip
  - femoroacetabular impingement
  - acetabular dysplasia
- complications of hip prostheses
- inflammatory or septic arthritis
- bone and soft tissue tumors



# protocol

- **patient position**

- supine position

- **tube voltage**

- $\leq 120$  kVp

- **scout**

- iliac crest to the proximal half of the femur

- **scan extent**

- might vary depending on the indication e.g. preoperative planning or implants

- should include the anterior inferior iliac spine and 3-5 cm below the lesser trochanter

- **scan direction**

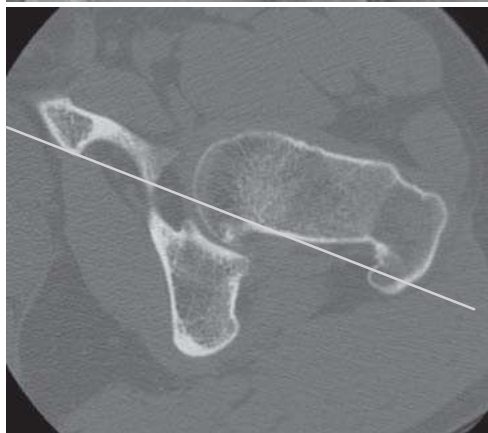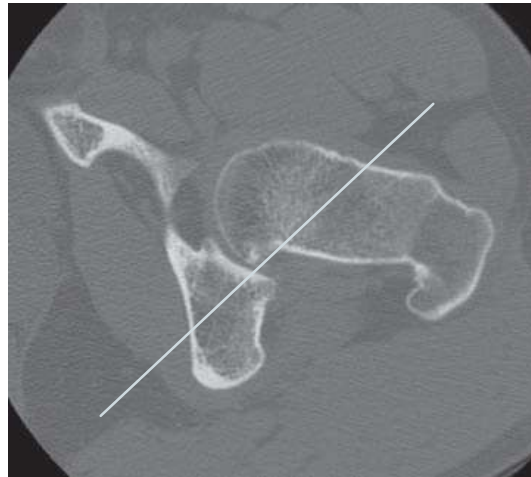
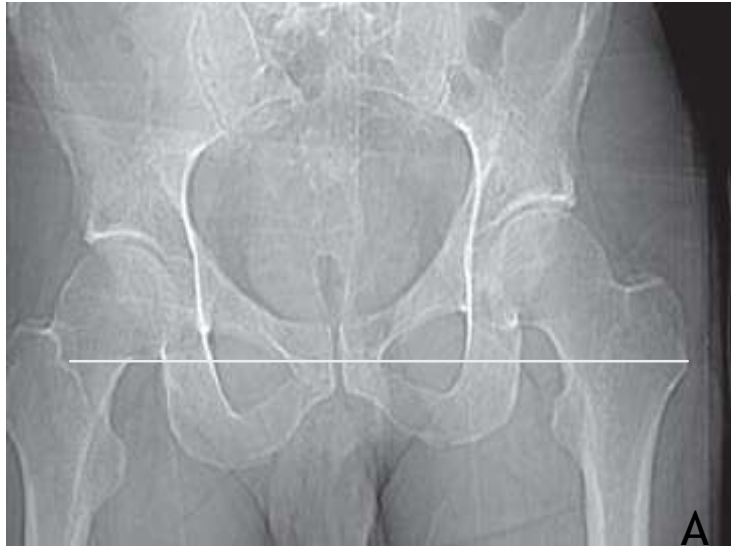- craniocaudal

- **scan geometry**

- field of view (FOV): 120-250 mm (should be adjusted to increase in-plane resolution)

- slice thickness:  $\leq 1.25$  mm, interval:  $\leq 0.625$  mm

- reconstruction algorithm: bone, soft tissue



B

- A.** Axial MPR can be programmed from an AP scout.
- B.** Coronal MPR can be programmed from an axial image and should follow the long axis of the femoral neck.
- C.** Sagittal MPR can be programmed from an axial image and should be perpendicular to the coronal MPR plane.

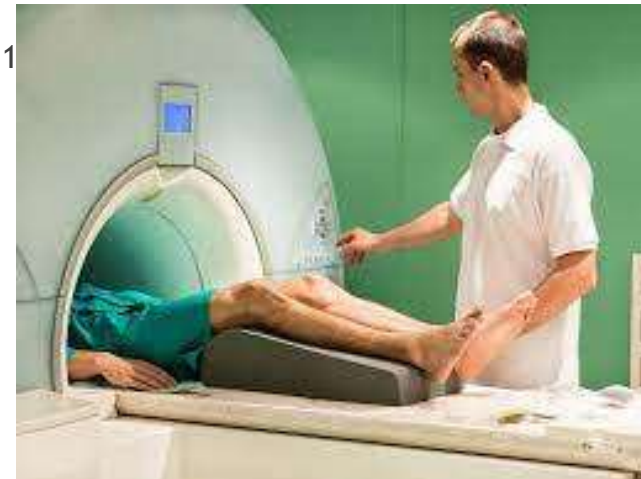# CT knee (protocol)

▶ The **CT knee protocol** serves as an examination for the bony assessment of the knee the femoral condyles or the tibial plateau and the proximal tibiofibular joint. It is often performed as a non-contrast study

▶ **Indications**

▶ Typical indications include imaging of the following <sup>1</sup>

- distal femoral fractures
- proximal tibial fractures
- preoperative planning
  - osteoarthritis
  - trochlear dysplasia
  - patellar translation
- knee implants and complications
- inflammatory or septic arthritis



- **patient position**

- supine position

- **tube voltage**

- $\leq 120$  kVp

- **scout**

- distal third of the femur and proximal half of the tibia

- **scan extent**

- the whole patella and the fibular head should be included

- **scan direction**

- craniocaudal

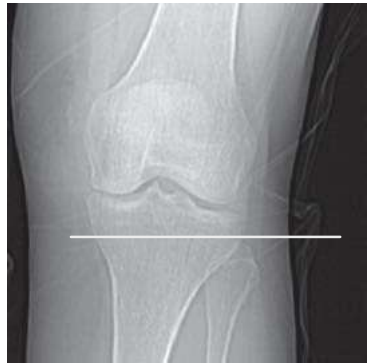- **scan geometry**

- field of view (FOV): 120-250 mm (should be adjusted to increase in-plane resolution)

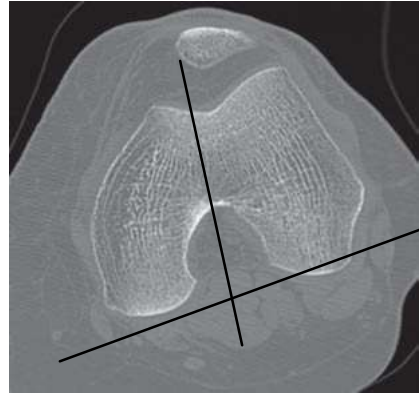
- slice thickness:  $\leq 1.25$  mm, interval:  $\leq 0.625$  mm

- reconstruction algorithm: bone, soft tissue

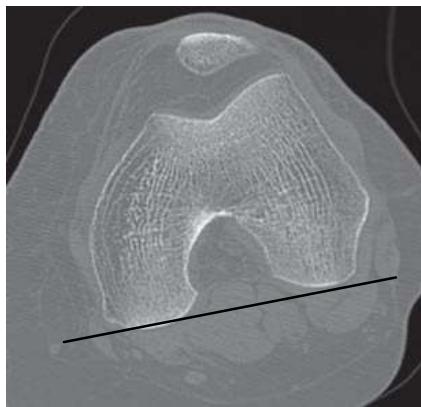
- **multiplanar reconstructions** axial images: parallel to the femorotibial joint line
- coronal images: parallel to the transepicondylar axis
- sagittal images: perpendicular to the transepicondylar or parallel to the anteroposterior axis



A



C



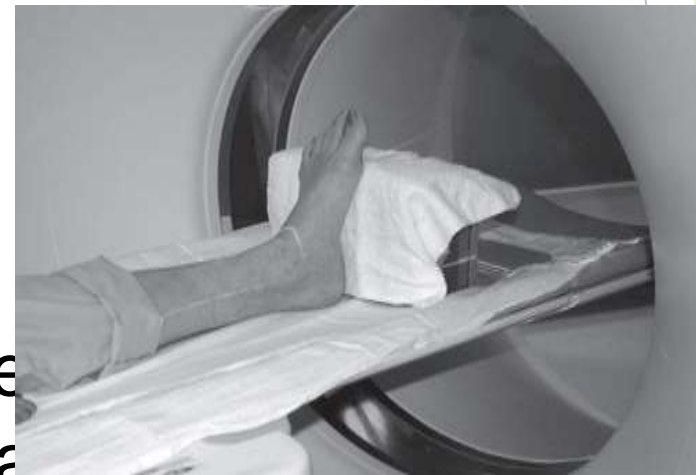B

**A.** Axial MPR can be programmed from an AP scout and should be parallel to the tibial plateau. **B.** Coronal MPR can be programmed from an axial image and should be parallel to the femoral condyles. **C .** Sagittal MPR can be programmed from an axial image and should be perpendicular to the coronal MPR.



# CT ankle (protocol)

- ▶ The **CT ankle protocol** serves as an examination for the bony assessment of the ankle and rearfoot and is almost always performed as a non-contrast study
- ▶ **Indications** Typical indications include foot and ankle trauma and or the depiction of bony lesions 1-7:
  - ▶ distal tibial fractures
  - malleolar fractures
  - talar and calcaneal fractures



When the patient is positioned with the foot up, data are acquired in the direct axial plane.

# Technique

- **patient position**

- supine position

- **scout**

- mid/distal third of lower leg to the skin of the heel

- **tube voltage** and **tube current**

- $\leq 120$  kV and  $\leq 100$  mAs

- **scan extent**

- variable depends on the proximal extent of the pathology

- minimum:  $\sim 2$  cm above the tibiotalar joint to the bottom of the calcaneus

- **scan direction**

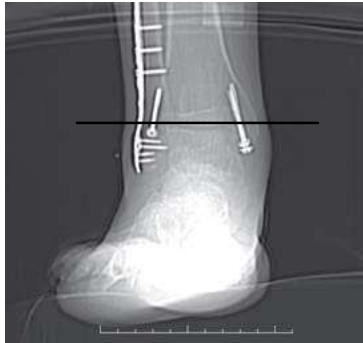- caudocranial

- **scan geometry**

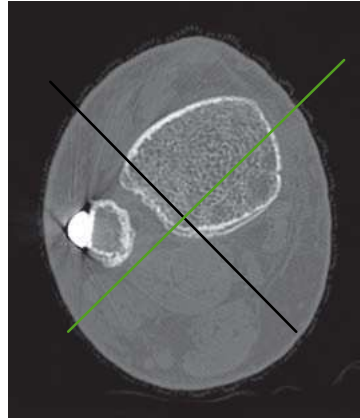
- field of view (FOV): 100-160 mm (should be adjusted to increase in-plane resolution)

- slice thickness:  $\leq 1.5$  mm, overlap  $\sim 50\%$

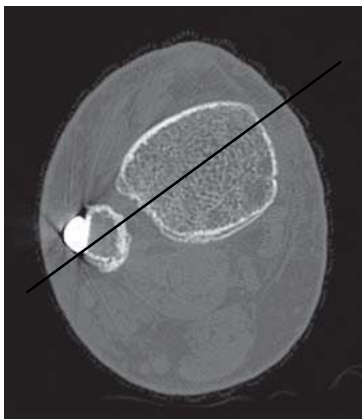
- reconstruction algorithm: bone, soft tissue



A



C



B

**FIGURE 22□11** **A.** Axial MPR can be programmed from an AP scout parallel to the top of the talus. **B.** Coronal MPR can be programmed from an axial image at the level of the distal tibia. **C.** Sagittal MPR can be programmed from an axial image at the level of the distal tibia. They are perpendicular to the coronal MPR plane.

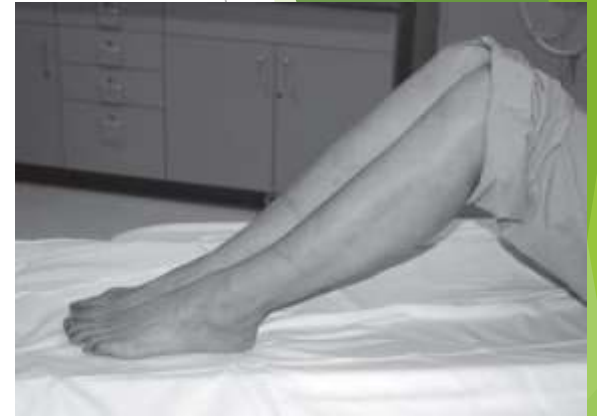# CT foot (protocol)

The **CT foot protocol** serves as an examination for the bony assessment of the fore and mid-foot and is almost always performed as a non-contrast study.

## Indications

Typical indications include trauma of the forefoot and or the depiction of bony lesions as e.g. in gout <sup>1-3</sup>:

- fractures or dislocations of the forefoot or midfoot
- Lisfranc injury
- foreign body
- inflammatory arthritis (e.g. gout)
- infectious processes
- postoperative evaluation
- bone and soft tissue tumors
- image guidance



- **patient position**

- supine position

- **tube voltage**

- $\leq 120$  kVp

- **tube current:**

- $\leq 100$  mAs

- **scout**

- whole foot

- **scan extent**

- variable depends on the proximal extent of the pathology

- **scan direction**

- craniocaudal

- **scan geometry**

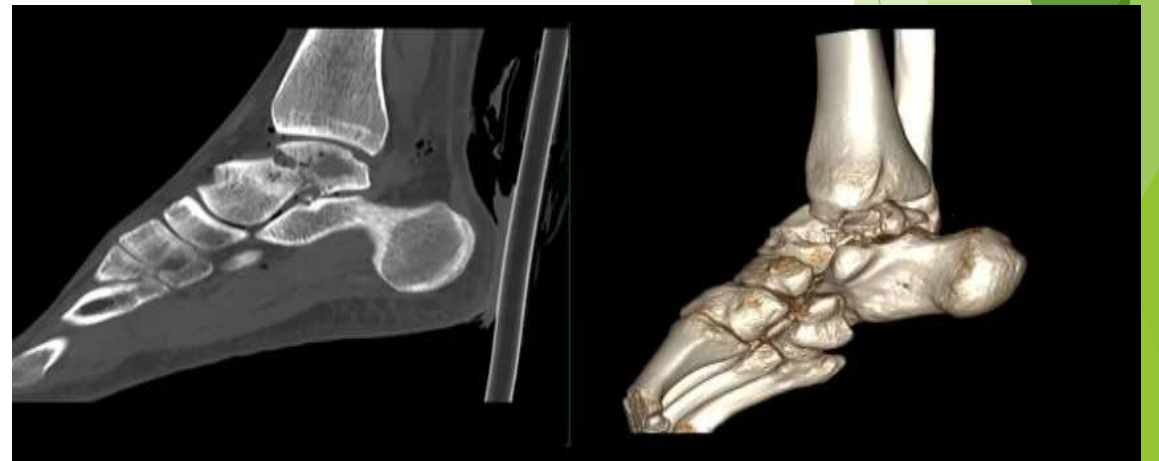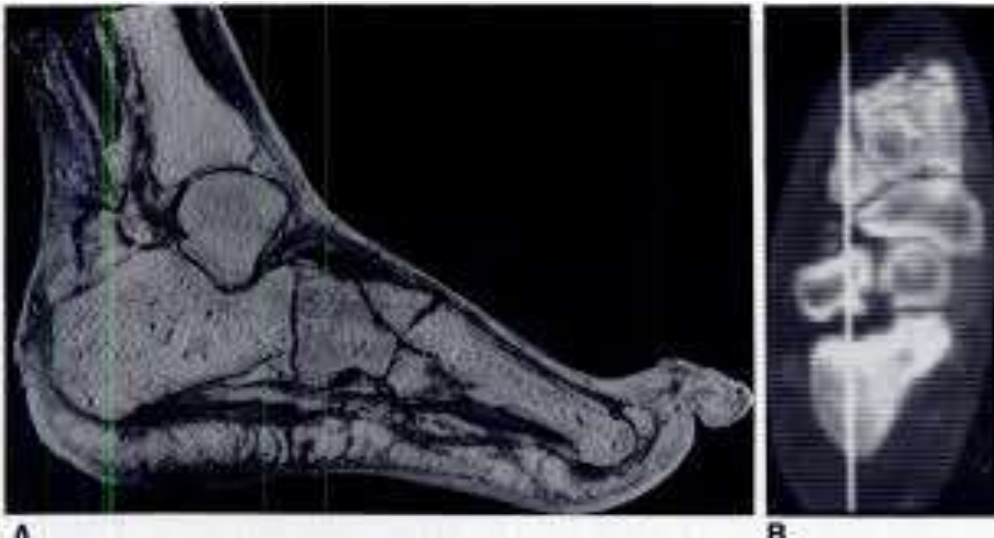
- field of view (FOV): 100-160 mm (should be adjusted to increase in-plane resolution)

- slice thickness:  $\leq 0.625$  mm, interval:  $\leq 0.3$  mm

- reconstruction algorithm: bone, soft

- **multiplanar reconstructions**

- axial images: parallel to the long axis of the metatarsal bones
- coronal images: perpendicular to the long axis 1st or 2nd and 3rd metatarsal bones
- sagittal images: parallel to the axis of 1st or the 2nd and 3rd metatarsal bones



Thank You

The text 'Thank You' is written in a highly decorative, calligraphic script. The letters are primarily black with a gold outline and a slight 3D effect. The 'T' is particularly large and features a long, sweeping tail that extends to the right. The 'Y' also has a long, elegant tail. The words are separated by a thin horizontal line. There are clusters of small gold stars and dots around the text, one cluster above the 'You' and one below the 'Thank'.

shutterstock.com • 1535896373