

Indications for prostate mri scan

- > Assessment of complications after pelvic surgery
- > Prior to biopsy for prostate cancer diagnosis
- > Post radiotherapy and chemotherapy assessment
- > Infection (prostatitis) or prostate abscess
- > Newly diagnosed prostate cancer staging
- > Diagnosis of recurrent prostate cancer
- > Post prostatectomy assessment
- > Pre surgical assessment
- > Tumor detection and staging
- > Congenital abnormalities.
- > Enlarged prostate
- > Rising PSA

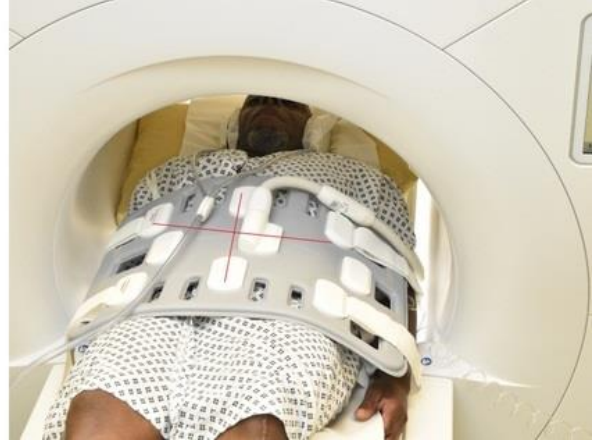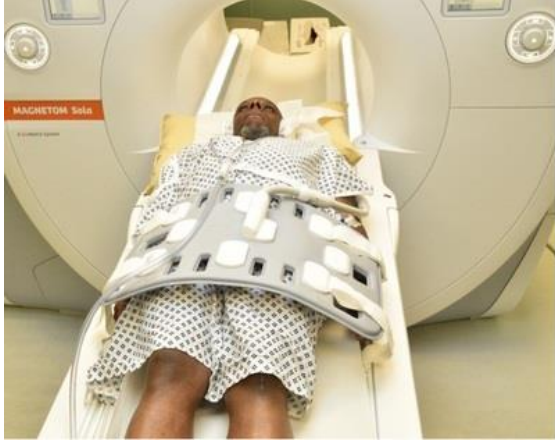Contraindications

- > Any electrically, magnetically or mechanically activated implant (e.g. cardiac pacemaker, insulin pump biostimulator, neurostimulator, cochlear implant, and hearing aids)
- > Intracranial aneurysm clips (unless made of titanium)
- > Pregnancy (risk vs benefit ratio to be assessed)
- > Ferromagnetic surgical clips or staples
- > Metallic foreign body in the eye
 - Metal shrapnel or bullet

Positioning

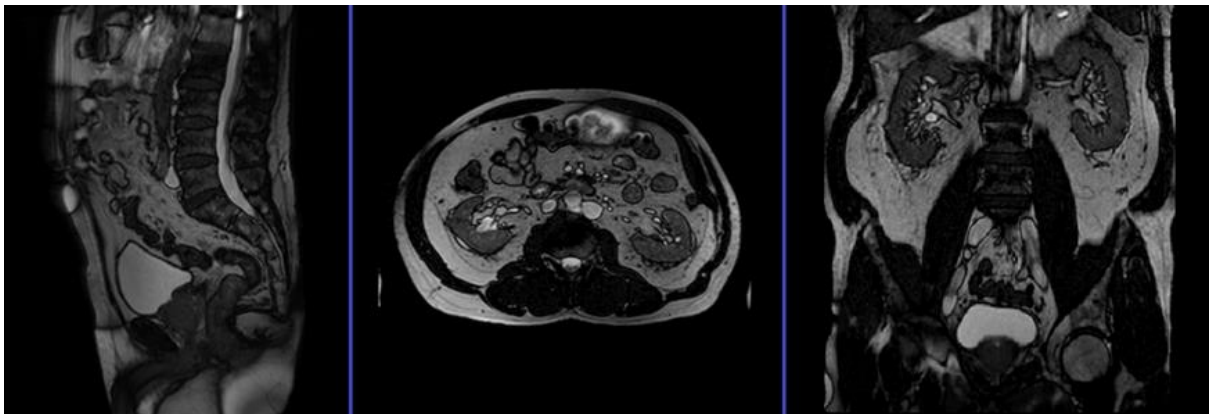
- > Position the patient in supine position with head pointing towards the magnet (head first supine).
 - Position the patient over the spine coil and place the body coils over abdomen and pelvis (nipple down to three inches below symphysis pubis).
- > Securely tighten the body coil using straps to prevent respiratory artefacts.
 - Give a pillow under the head and cushions under the legs for extra comfort.

Centre the laser beam localiser over the iliac crest.
Register the patient in the scanner as head first supine.



Suggested protocols, parameters and planning localiser

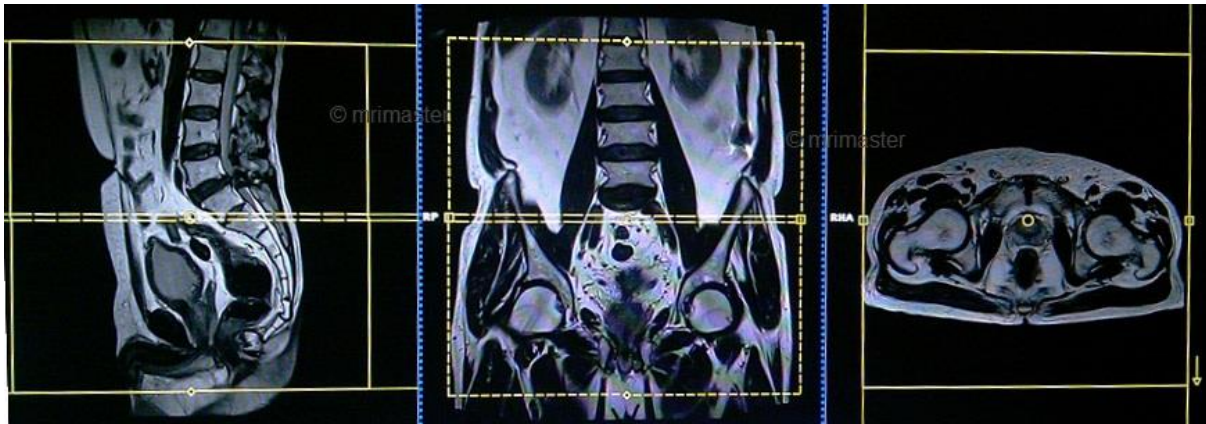
A three plane TrueFISP localiser must be taken initially to localise and plan the sequences. These are fast single shot localisers with under 25s acquisition time which are excellent for localising abdominal and pelvic structures.



T2 tse axial 6 mm big FOV

Plan the big FOV axial slices on the coronal plane; angle the position block parallel to the right and left iliac crest (i.e. perpendicular to

lumbar spine). Check the positioning block in the other two planes. An appropriate angle must be given in the sagittal plane (horizontally across the pelvis). Slices must be sufficient to cover the whole lower abdomen and pelvis from middle of the kidneys down to the symphysis pubis. FOV must be big enough to cover the whole pelvis (normally 350mm-400mm).Big FOV scans are normally taken to check the para-aortic and pre-sacral nodes.

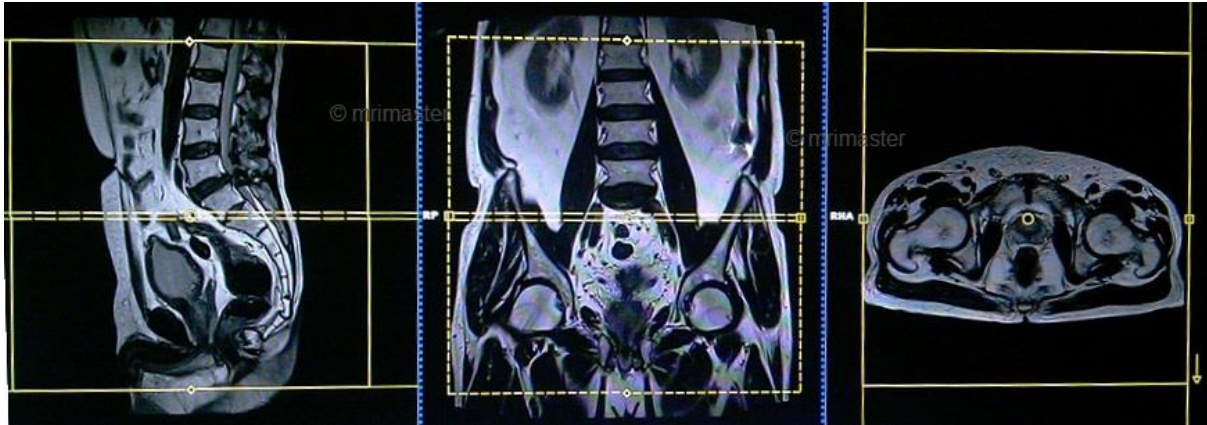


Parameters

TR	TE	SLICE	FLIP	PHASE	MATRIX	FOV	GAP	NEX(AVRAGE)
4000-5000	100-120	6 MM	130-150	A>P	384X384	350-400	10%	2

T1 tse axial 6 mm big FOV

Plan the big FOV axial slices on the coronal plane; angle the position block parallel to the right and left iliac crest (i.e. perpendicular to lumbar spine). Check the positioning block in the other two planes. An appropriate angle must be given in the sagittal plane (horizontally across the pelvis). Slices must be sufficient to cover the whole lower abdomen and pelvis from middle of the kidneys down to the symphysis pubis. FOV must be big enough to cover the whole pelvis (normally 350mm-400mm).Big FOV scans are normally taken to check the para-aortic and pre-sacral nodes.

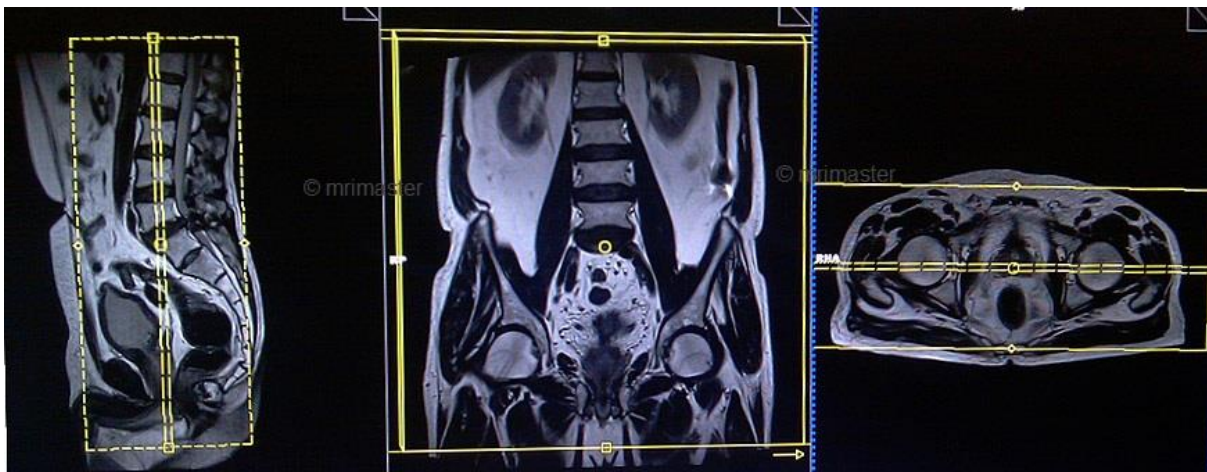


Parameters

TR	TE	SLICE	FLIP	PHASE	MATRIX	FOV	GAP	NEX(AVRAGE)
400-600	15-25	6 MM	130	R>L	384X384	350-400	10%	2

T2 stir coronal 5 mm big FOV

Plan the big FOV coronal slices on the sagittal plane; angle the position block parallel to the lumbar spine. Check the positioning block in the other two planes. An appropriate angle must be given in the axial plane (parallel to the line from right to left hip joint). Slices must be sufficient to cover the para aortic area from mid abdomen to the sacrum. FOV must be big enough to cover the abdomen and pelvis (normally 380mm-400mm). Big FOV scans are normally taken to check the Para-aortic and pre-sacral nodes.

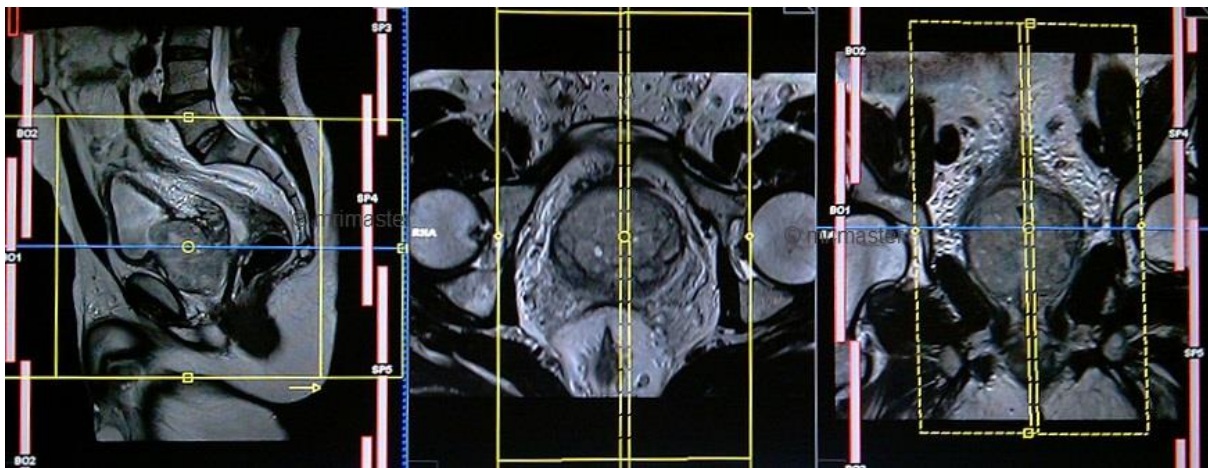


Parameters

TR	TE	FLIP	NEX	SLICE	MATRIX	FOV	PHASE	GAP	TI
4000-5000	110	130	2	5MM	384X320	380-400	R>L	10%	130

T2 tse sagittal 3mm SFOV prostate

Plan the sagittal slices on the axial plane; angle the position block parallel to the line along the interpubic fibrocartilage and the anal canal. Check the positioning block in the other two planes. An appropriate angle must be given in the coronal plane (parallel to the interpubic fibrocartilage). Slices must be sufficient to cover the whole pelvis from the right acetabulum to the left acetabulum. FOV must be big enough to cover the prostate and seminal vesicles (normally 180mm-200mm). Adding saturation bands on top and front of the sagittal block will reduce artefacts from arterial pulsation and breathing.

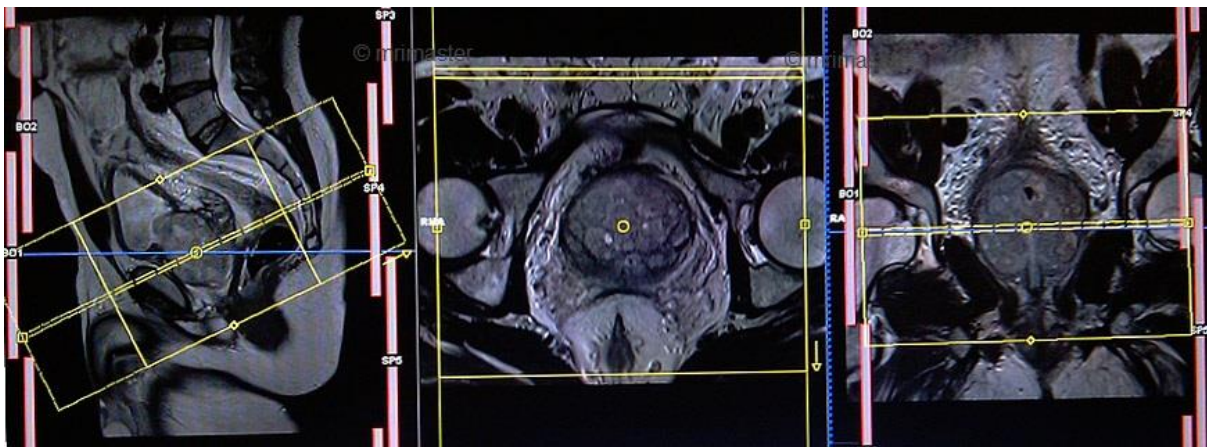


Parameters

TR	TE	SLICE	FLIP	PHASE	MATRIX	FOV	GAP	NEX(AVRAGE)
3000-4000	100-120	3 MM	130-150	A>P	320X320	180-200	10%	4

T2 tse axial oblique 3mm SFOV prostate

Plan the axial oblique slices on the sagittal plane; angle the position block perpendicular to the prostatic urethra (i.e. parallel to the base of urinary bladder). Check the positioning block in the other two planes. An appropriate angle must be given in the coronal plane (perpendicular to the prostatic urethra). Slices must be sufficient to cover the whole prostate and seminal vesicles. Adding saturation bands on top and front of the axial block will reduce artefacts from arterial pulsation and breathing.



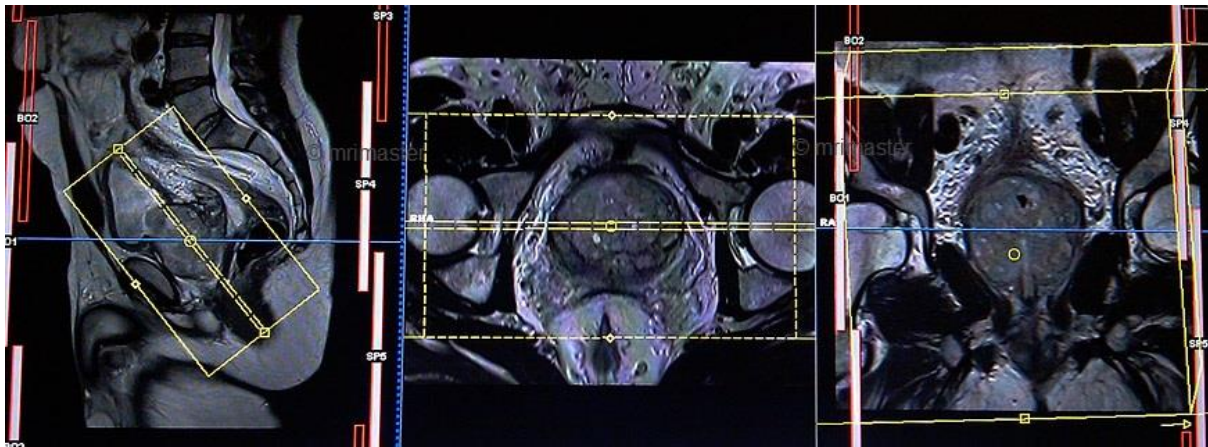
Parameters

TR	TE	SLICE	FLIP	PHASE	MATRIX	FOV	GA	NEX(AVRAGE)
3000	100							
-	-	3	130	A>P	320X25	180	10	5
4000	120	MM	-		6	-	%	
			150			230		

T2 tse coronal oblique 3mm SFOV

Plan the coronal oblique slices on the sagittal plane; angle the position block parallel to the prostatic urethra (i.e. perpendicular to the base of urinary bladder). Check the positioning block in the other two planes. An appropriate angle must be given in the axial plane (parallel to the line between right and left hip joints). Slices must be sufficient to cover the whole prostate and seminal vesicles. Adding saturation

bands on top and front of the coronal block will reduce artefacts from arterial pulsation and breathing.

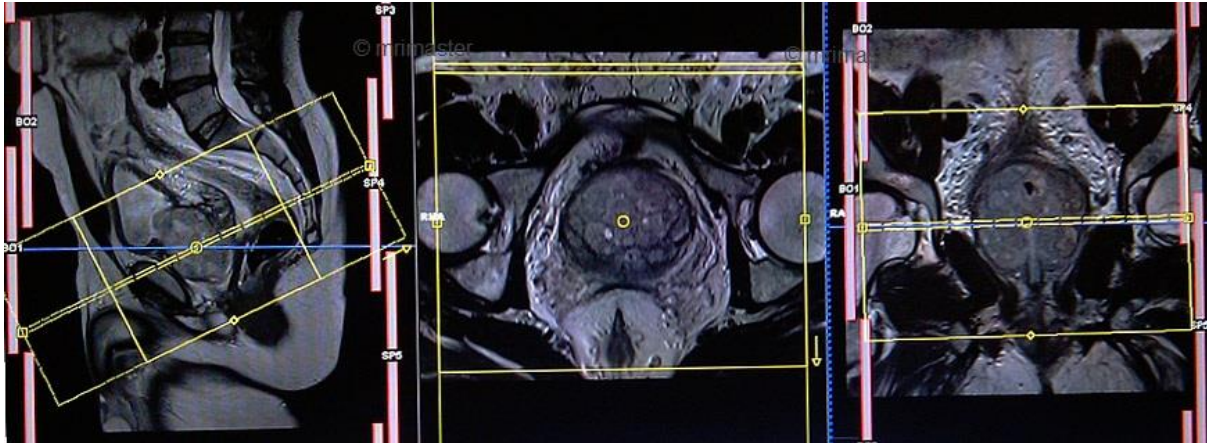


Parameters

TR	TE	SLICE	FLIP	PHASE	MATRIX	FOV	GAP	NEX(AVRAGE)
3000-4000	100-120	3 MM	130-150	R>L	320X256	180-230	10%	5

DWI epi3scan trace axial 3 mm SFOV

Plan the axial oblique slices on the sagittal plane; angle the position block perpendicular to the prostatic urethra (i.e. parallel to the base of urinary bladder). Check the positioning block in the other two planes. An appropriate angle must be given in the coronal plane (perpendicular to the prostatic urethra). Slices must be sufficient to cover the whole prostate and seminal vesicles. Adding saturation bands on top and front of the axial block will reduce artefacts from arterial pulsation and breathing.



Parameters

TR	TE	FLIP	NEX	SLICE	MATRIX	FOV	PHASE	GAP	B VALUE
5000-6000	110	130	10	4 MM	192X192	200-250	R>L	10%	0 500 1000

Post I.V. Contrast

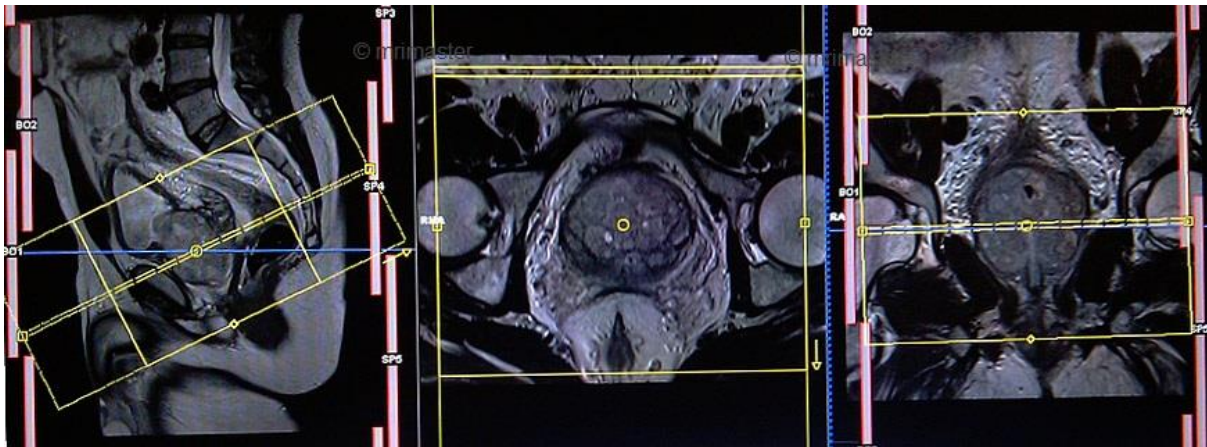
Most common indications for contrast enhanced pelvis scans

- > Post radiotherapy and chemotherapy assessment
- > MRI prior to biopsy for prostate cancer assessment
- > Pre surgical assessment
- > Infection (prostatitis) or prostate abscess
- > Post prostatectomy assessment

T1 flash 3D fat sat axial dynamic 1 pre 10 post

Plan the axial oblique slices on the sagittal plane; angle the position block perpendicular to the prostatic urethra (i.e. parallel to the base of urinary bladder). Check the positioning block in the other two planes. An appropriate angle must be given in the coronal plane (perpendicular to the prostatic urethra). Slices must be sufficient to

cover the whole prostate and seminal vesicles. Adding saturation bands on top and front of the axial block will reduce artefacts from arterial pulsation and breathing.

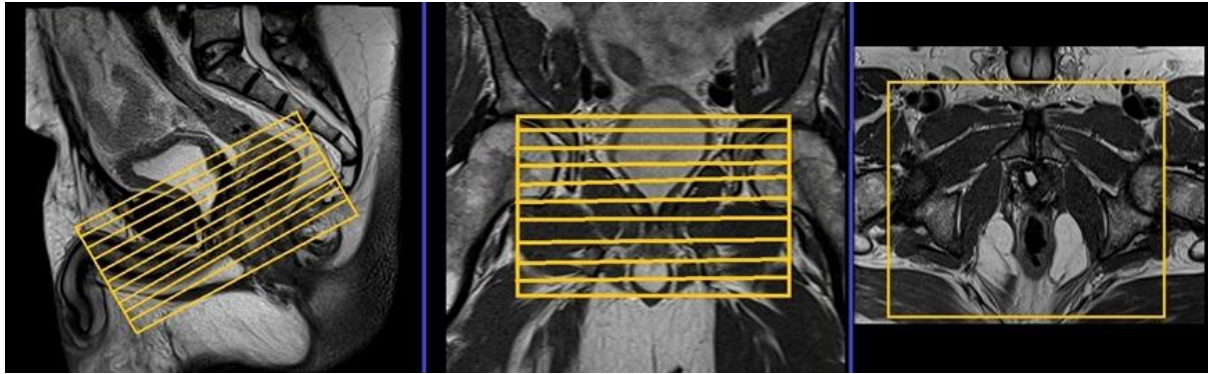


A dynamic flash 3D sequence consists of 16 flash 3mm 3D scans with 10s delay between the first and second scan for the contrast injection. Contrast injection must be administered after the first dynamic sequence.

TR	TE	FLIP	NEX	SLICE	MATRIX	FOV	PHASE	DYNAMIC	IPAT
4-5	2	12	1	3MM	256X192	180-200	A>P	11 SCAN	ON

T1 tse fat sat axial 3mm SFOV

Plan the axial slices on the sagittal plane; angle the position block perpendicular to the urethra (i.e. parallel to the base of urinary bladder). An appropriate angle must be given in the coronal plane parallel to the line between right and left hip joints). Slices must be sufficient to cover the pelvis from middle of the urinary bladder down to penile shaft. Adding saturation bands on top and front of the axial block will reduce artefacts from arterial pulsation and breathing. **T1 fat sat post contrast scans are only used in post prostatectomy patients.**



Parameters

TR	TE	SLICE	FLIP	PHASE	MATRIX	FOV	GAP	NEX(AVRAGE)
400-600	15-25	3 MM	130	R>L	256X256	180-230	10%	5