

*NCCT OF SINUSES,
MASTOID, ORBIT & FACE*

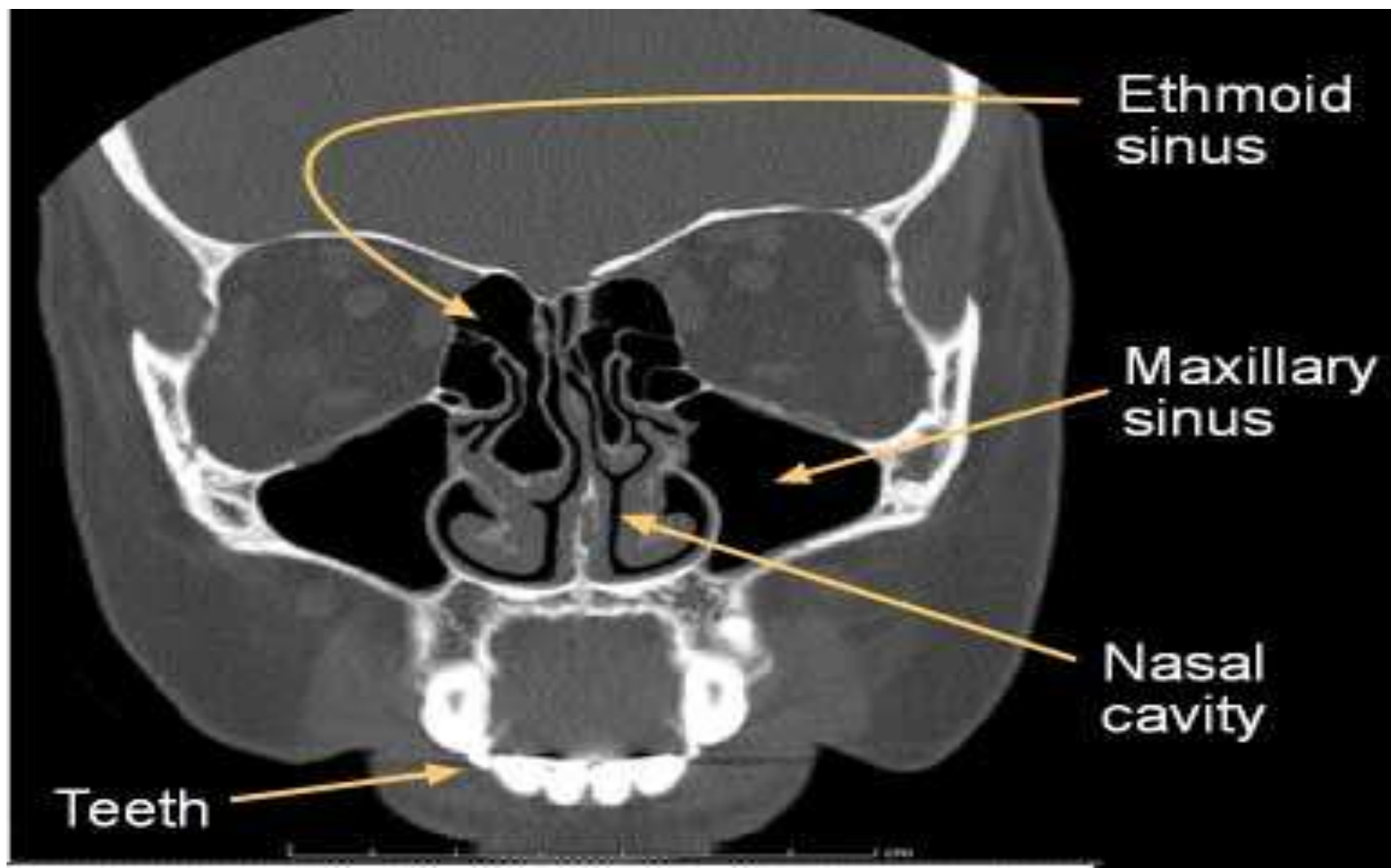
PARANASAL SINUSES

- The **CT paranasal sinus protocol** serves as an examination for the assessment of the study of the mucosa and bone system of the sinonasal cavities.
- It is usually performed as a non-contrast study.

Typical indications include the following:

- inflammatory disease
 - [acute rhinosinusitis](#)
 - gas-fluid levels
 - mucosal disease
 - [chronic sinusitis](#)
 - cysts and polyps
 - [mucoceles](#)

- foreign body
- malignancy
- preoperative assessment



Purpose

- The purpose of a CT scan of the paranasal sinuses is to visualize the possible presence of inflammatory or newly formed tissue in the context of the paranasal cavities.
- In neoplastic, inflammatory and infectious disorders, a CT scan of the paranasal sinuses is performed to demonstrate bony erosions, osteolytic lesions, and calcifications.
- If neoplasia is suspected, the use of an intravenous contrast medium is indicated.

CONTRAST ADMINISTRATION

- **Volume of contrast:**

According to patients body weight.

- **Rate of injection of contrast-**

2 – 3 ml/sec

- **Scan delay:**

30– 40 sec

Technique

- **patient position**
 - supine
- **tube voltage** and **tube current**
 - 125 kV and 80–160 mAs
- **scan extent**
 - from the hard palate to above the end of the frontal sinuses
- **scan direction**
 - caudocranial

- **scan geometry**

- field of view (FOV): 140–160 mm
- slice thickness: 5 mm

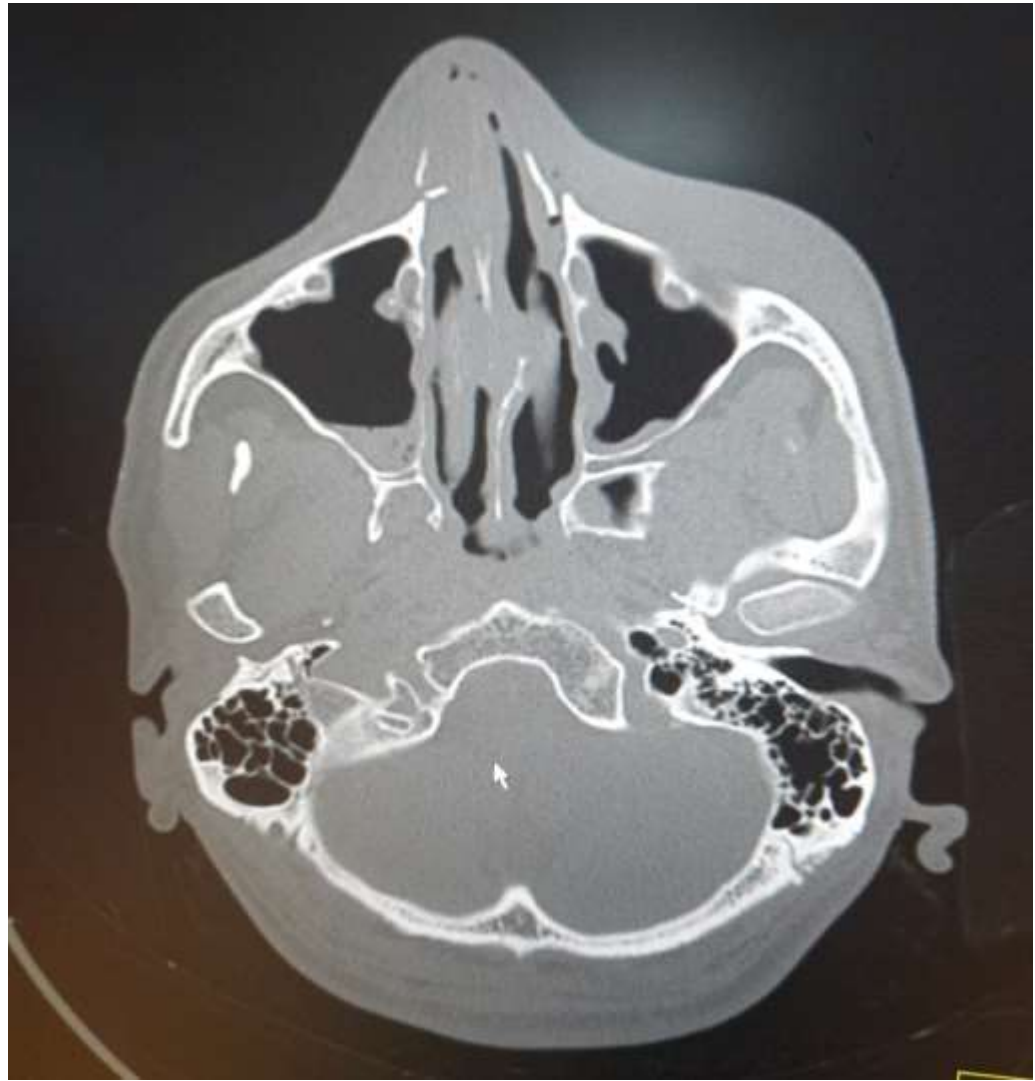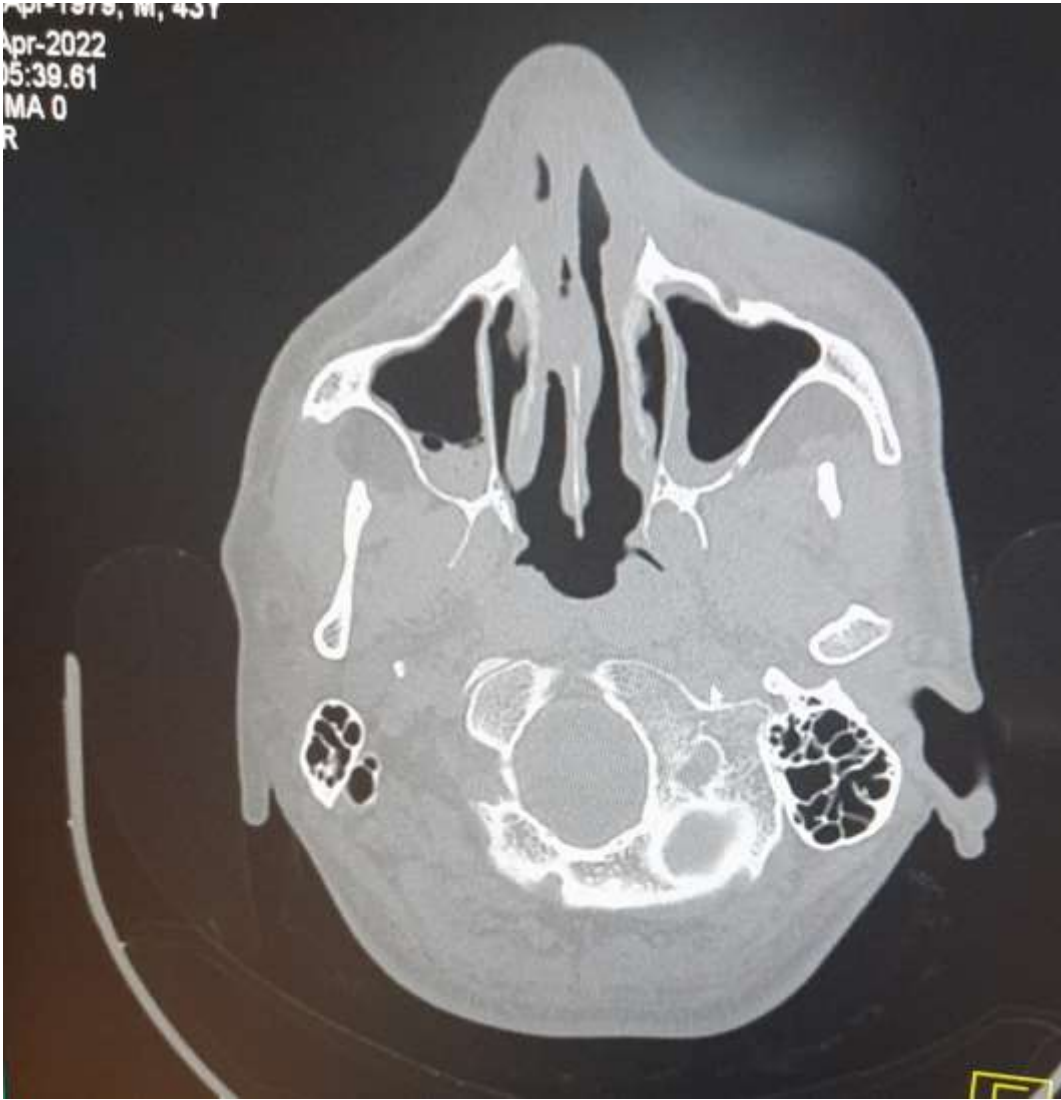- **reconstruction kernel**

- bone kernel (e.g. ≥ 4000 HU), soft tissue kernel (e.g. 150 to 400 HU)

- **multiplanar reconstructions(MPR)**

- coronal and sagittal images

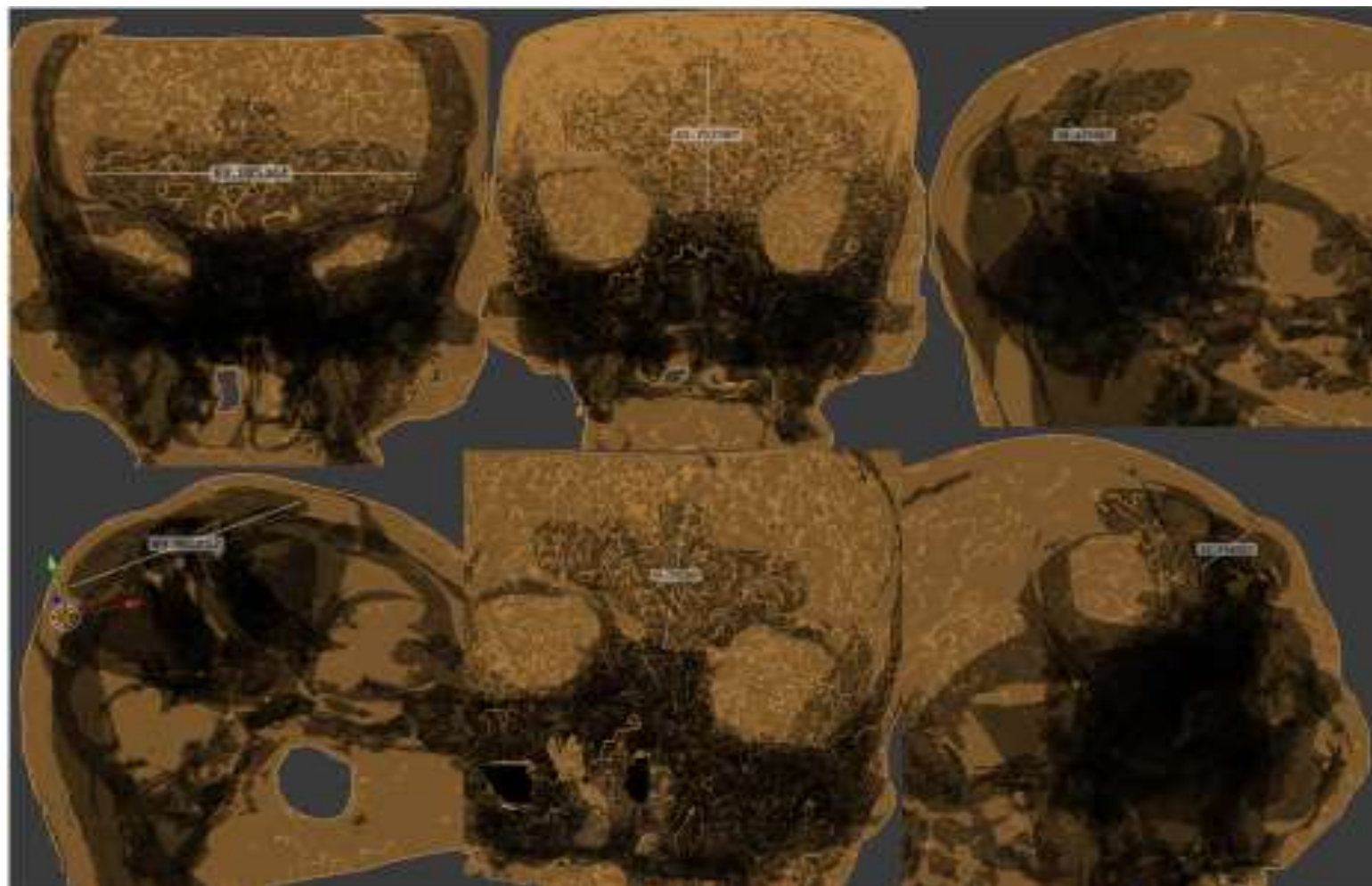
Apr-1978, Nr, 431
Apr-2022
05:39.61
MA 0
R



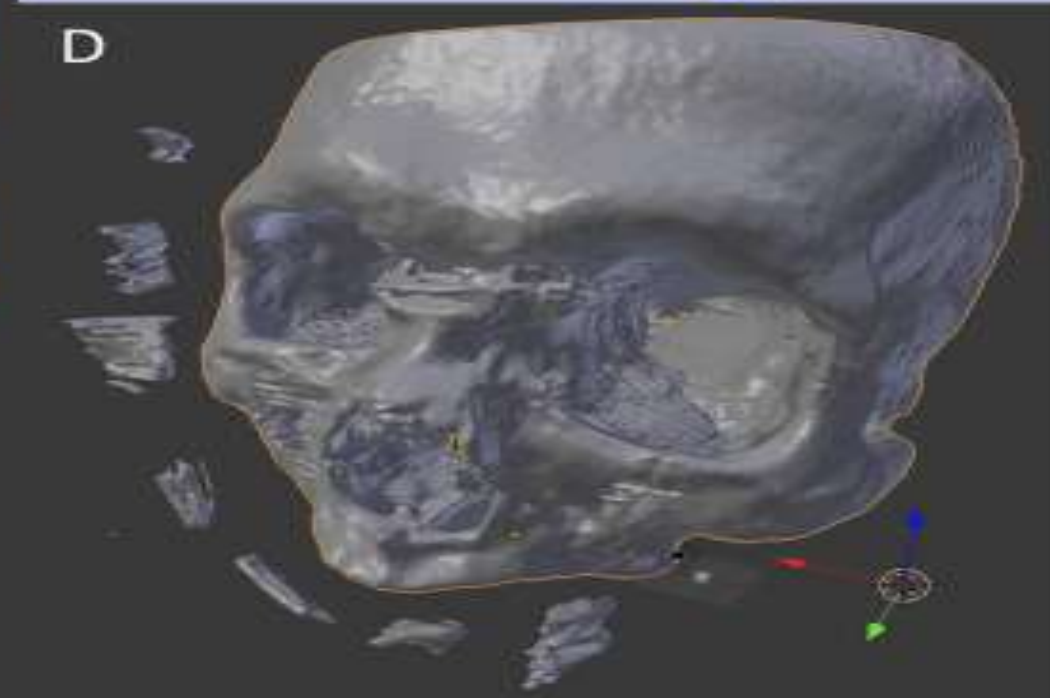
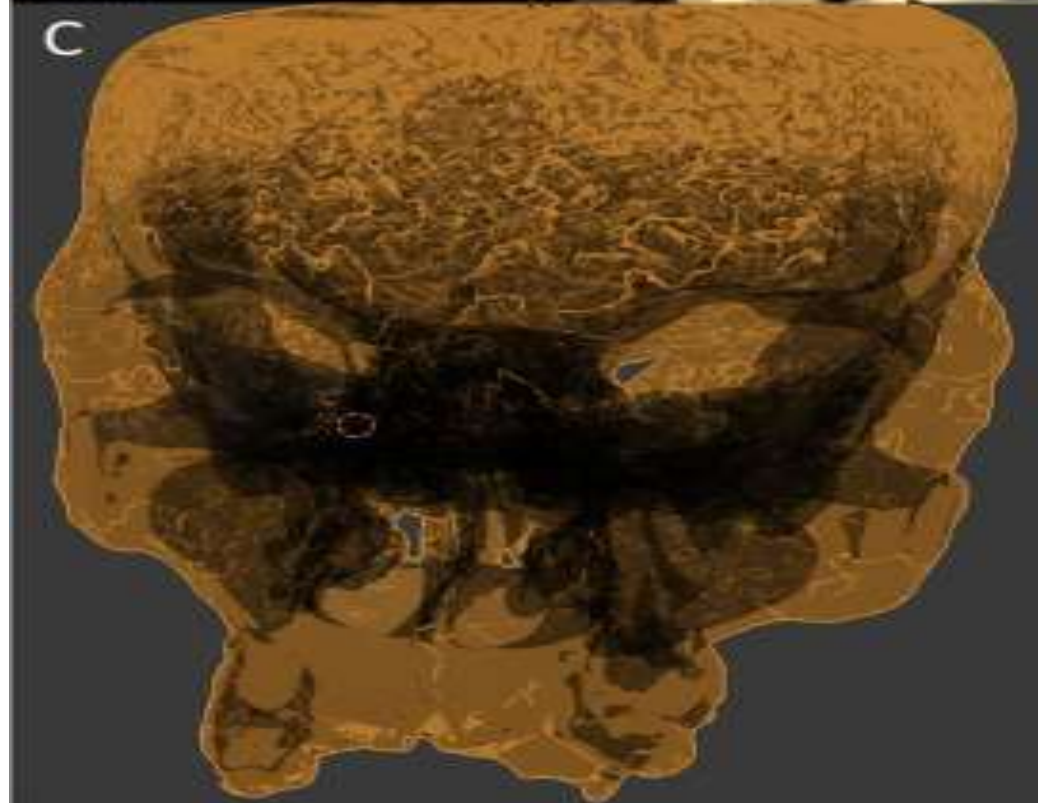
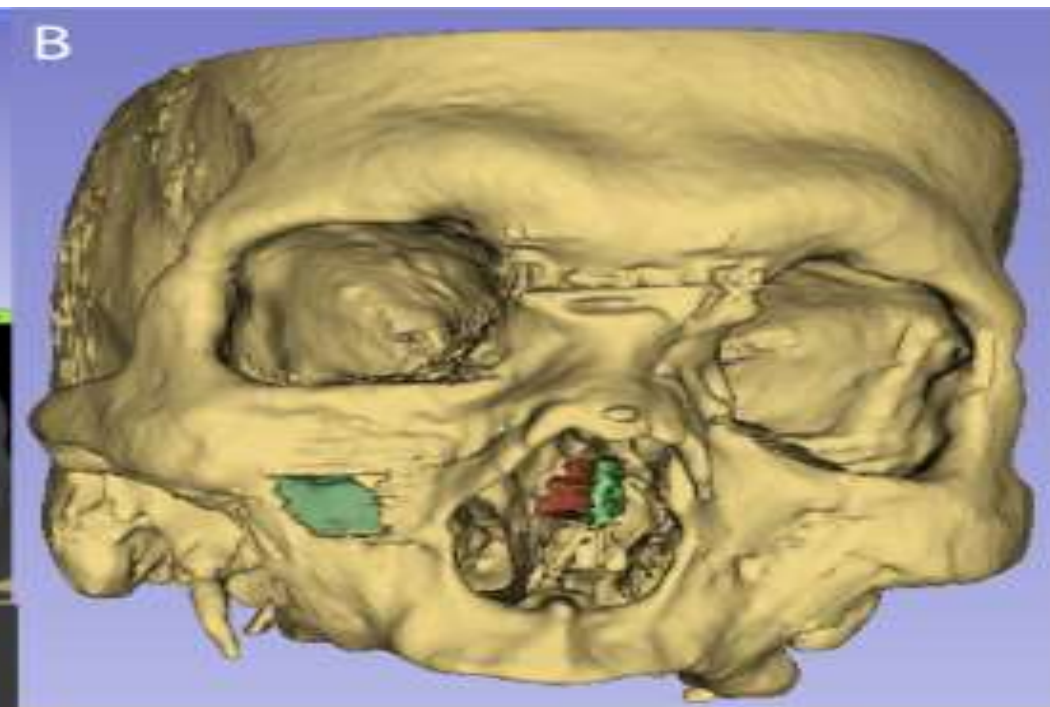
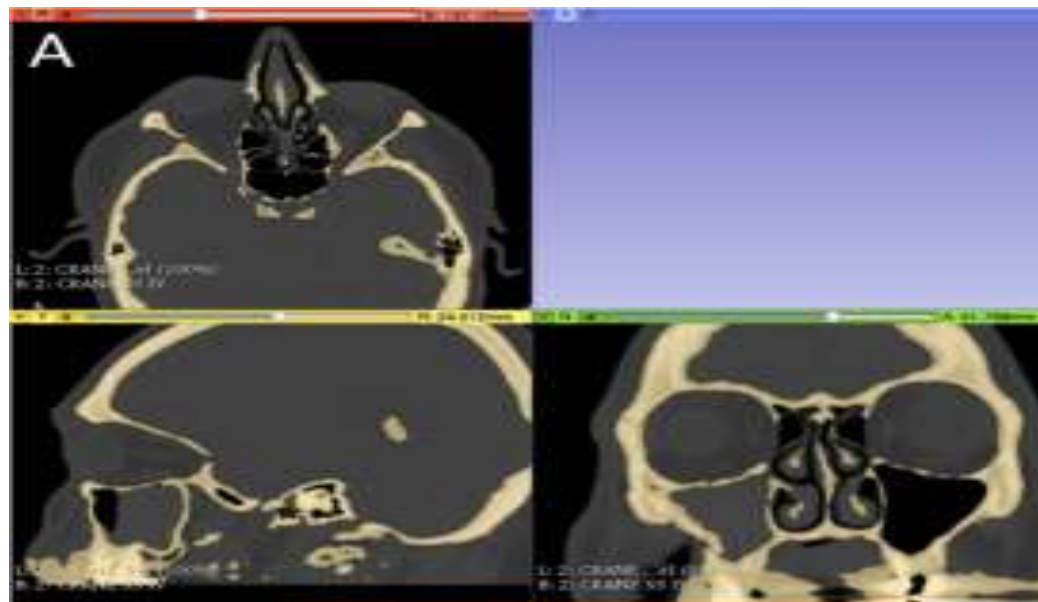
Blender software for sinus measurement

Patient B
7 fragments

Pre-fracture



Post-fracture





Practical aspect

- In addition, in the case of planned surgery, imaging can provide the surgeon with necessary information regarding any anatomical variants and allow the diagnosis of clinically silent diseases e.g. the possible presence of brain aneurysms, tumors, etc.

CT ORBITS

- **Scouts:**
AP and lateral
- **Scan type:**
Axial
- **Scan plane:**
Transverse
- **Start location:**
Just below orbital floor
- **End location:**
Just above orbital roof

Examples of clinical indications:

- **Without contrast:**

- trauma,
 - foreign body

- **With contrast:**

- intraorbital masses
 - thyroid ophthalmopathy
 - inflammation
 - infection

- **IV contrast** (if contrast is ordered):
100 mL at 1.0 mL/s.
- **Oral contrast:**
None
- **Reference angle:**
Angle gantry parallel to infraorbital meatal line
- **kVp/mA :**
120/200

Reconstruction

- **Algorithm:**

soft tissue

- **Slice thickness:**

2.5 mm

FACIAL BONES

- Examples of clinical indications:
Characterization of facial fractures and soft tissue injury
- **Topogram** is taken after positioning the patient.
- **Scan type:**
Helical
- **Start location:**
Just below mandible
- **End location:**
Just above frontal sinus

- **IV contrast:**

None

- **Oral contrast:**

None

- **Reference angle:**

Angle gantry parallel to infraorbital meatal line

- **Reconstruction (slice thickness/interval) :**

1.25 mm/0.625

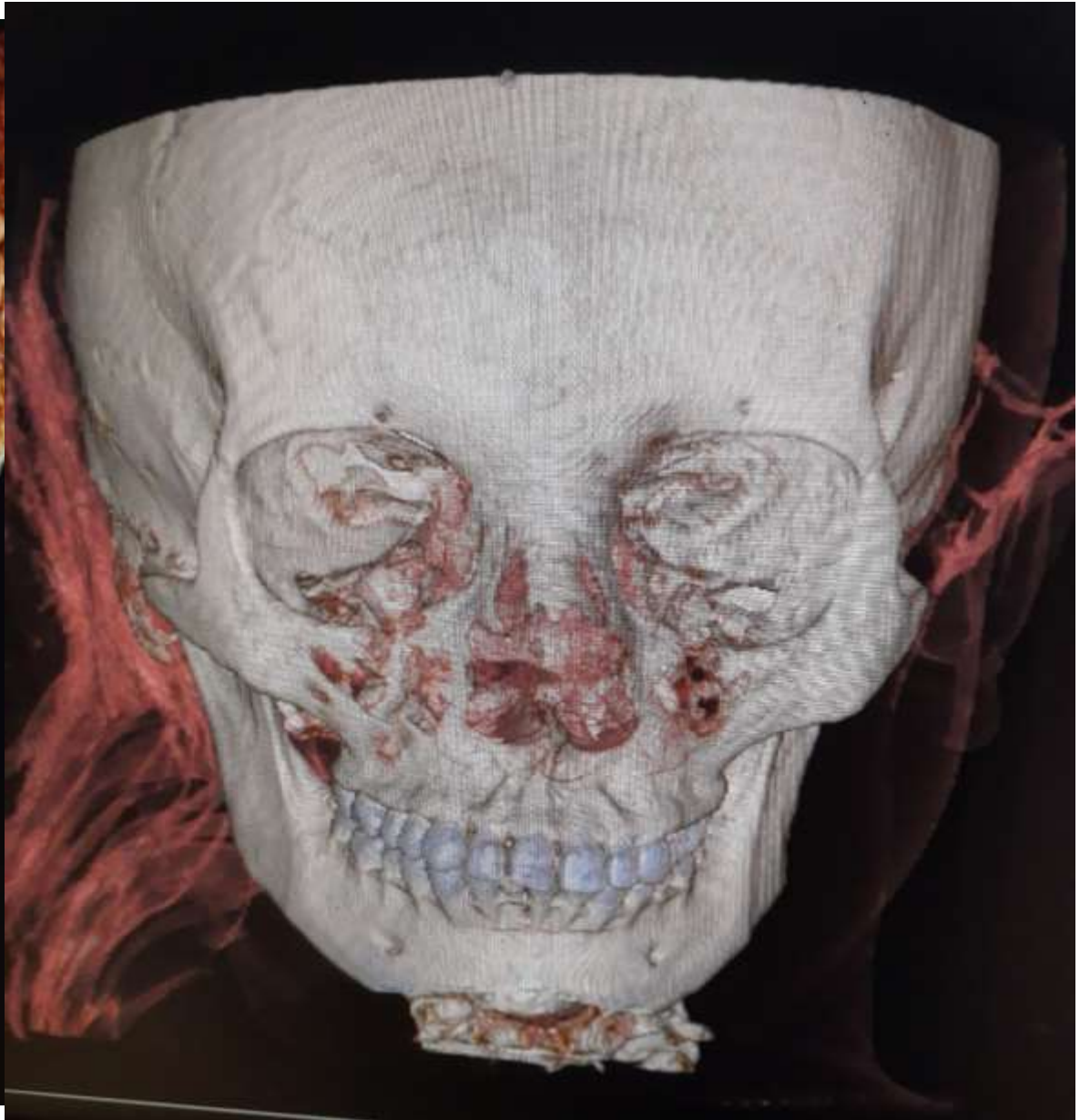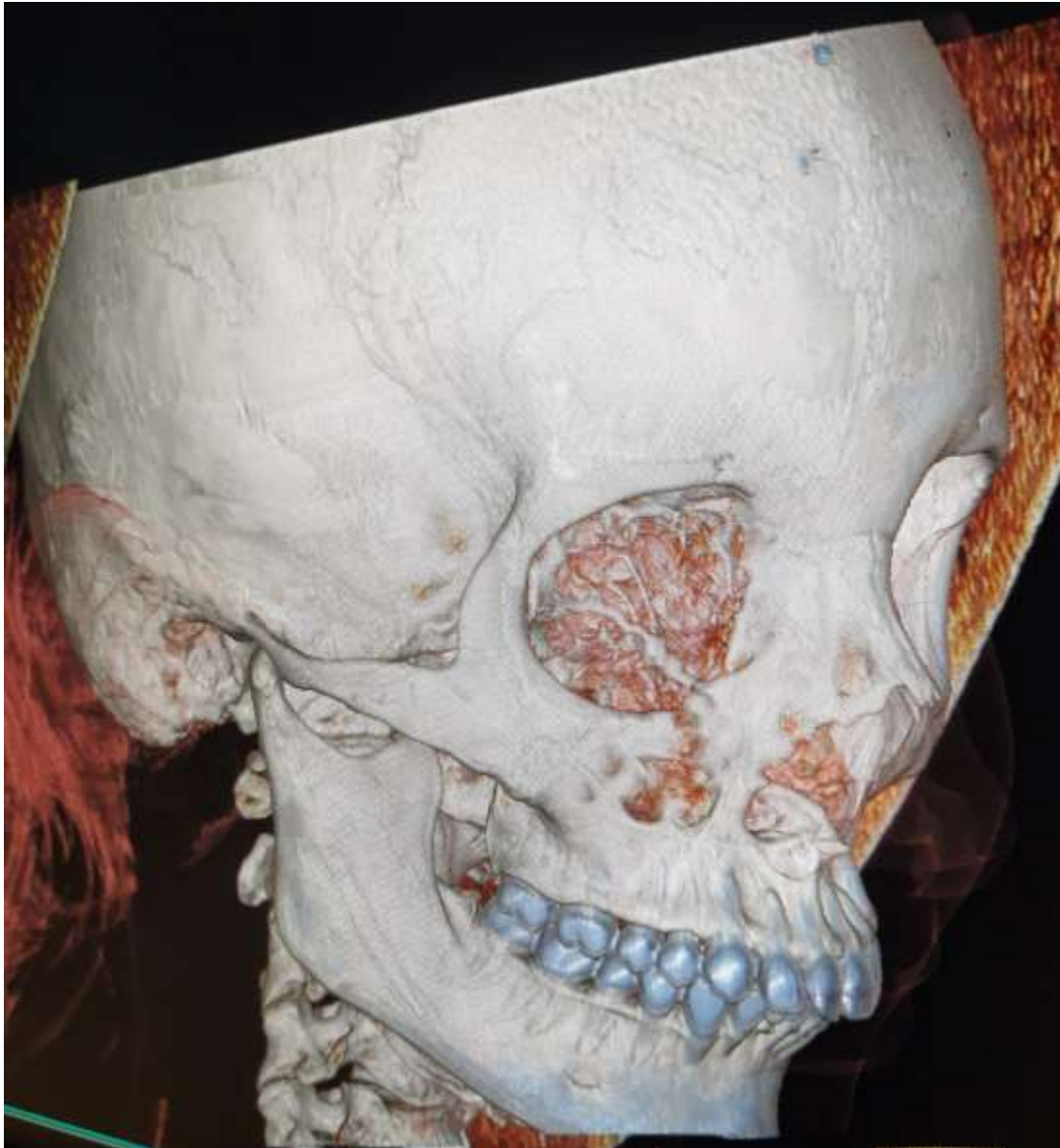- **kvp/mas** →

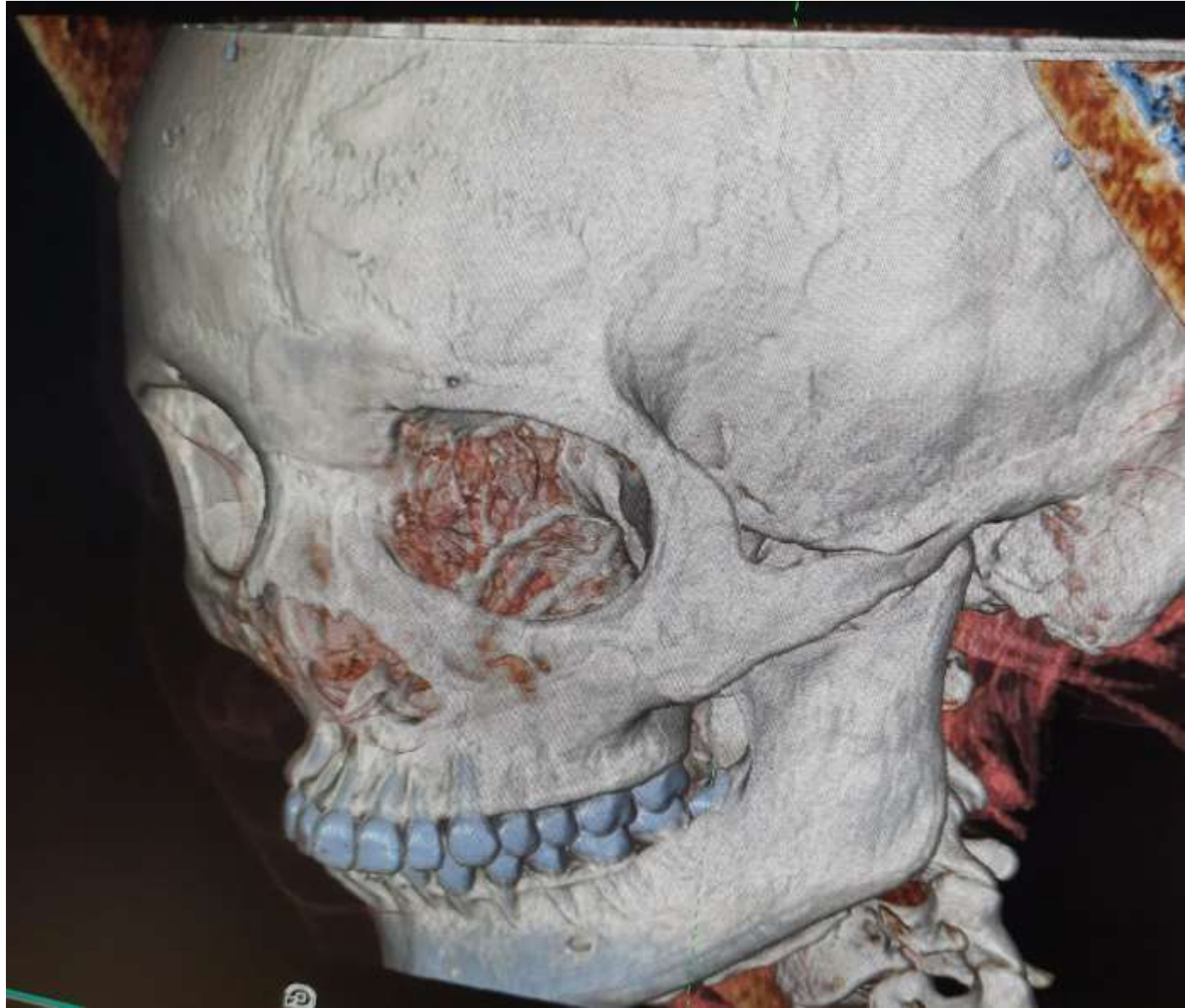120/250

REFORMATION (MPR)

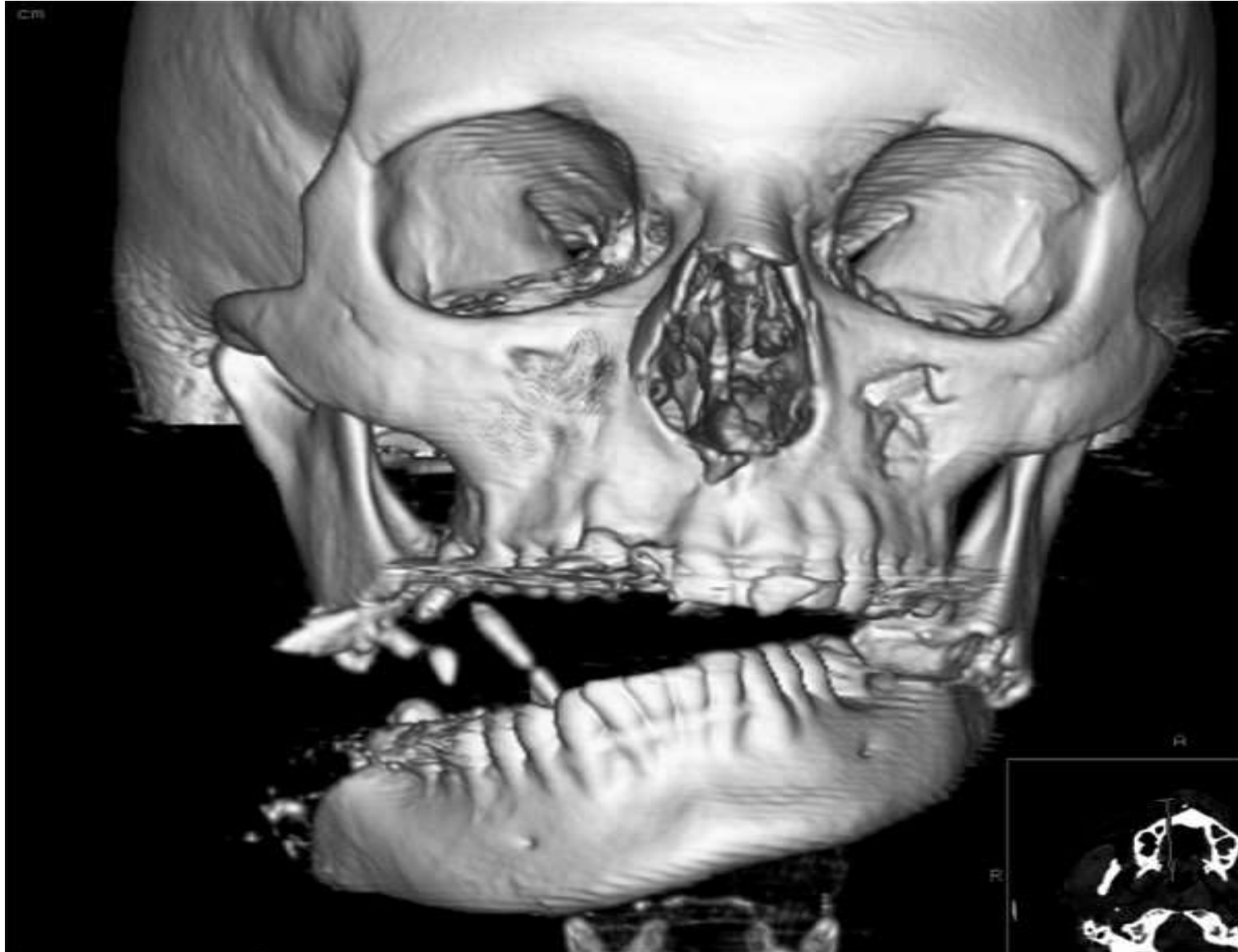- Coronal reformations using both standard and bone algorithm image data

VOLUME RENDERED IMAGES





Mandibular fracture



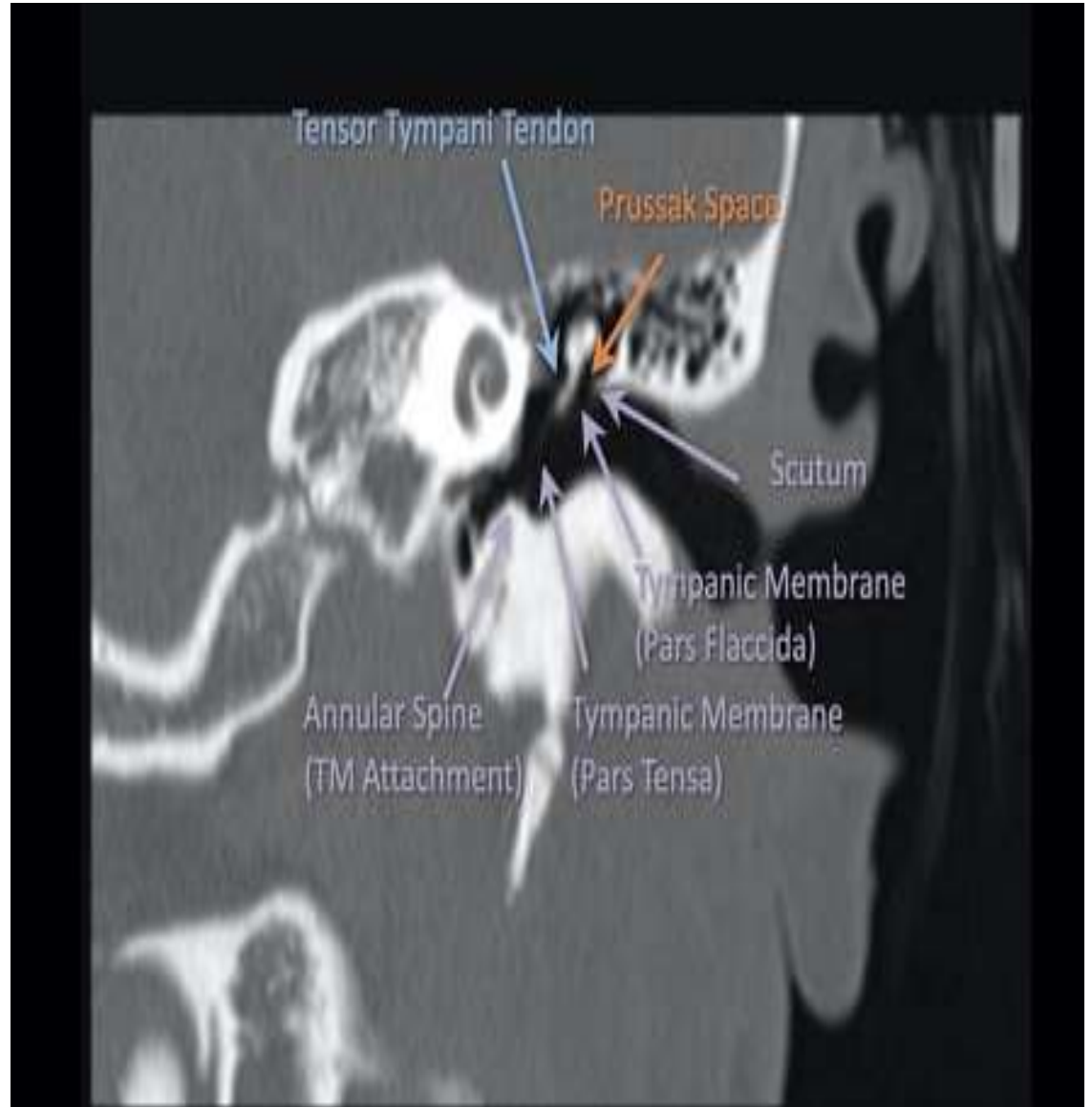
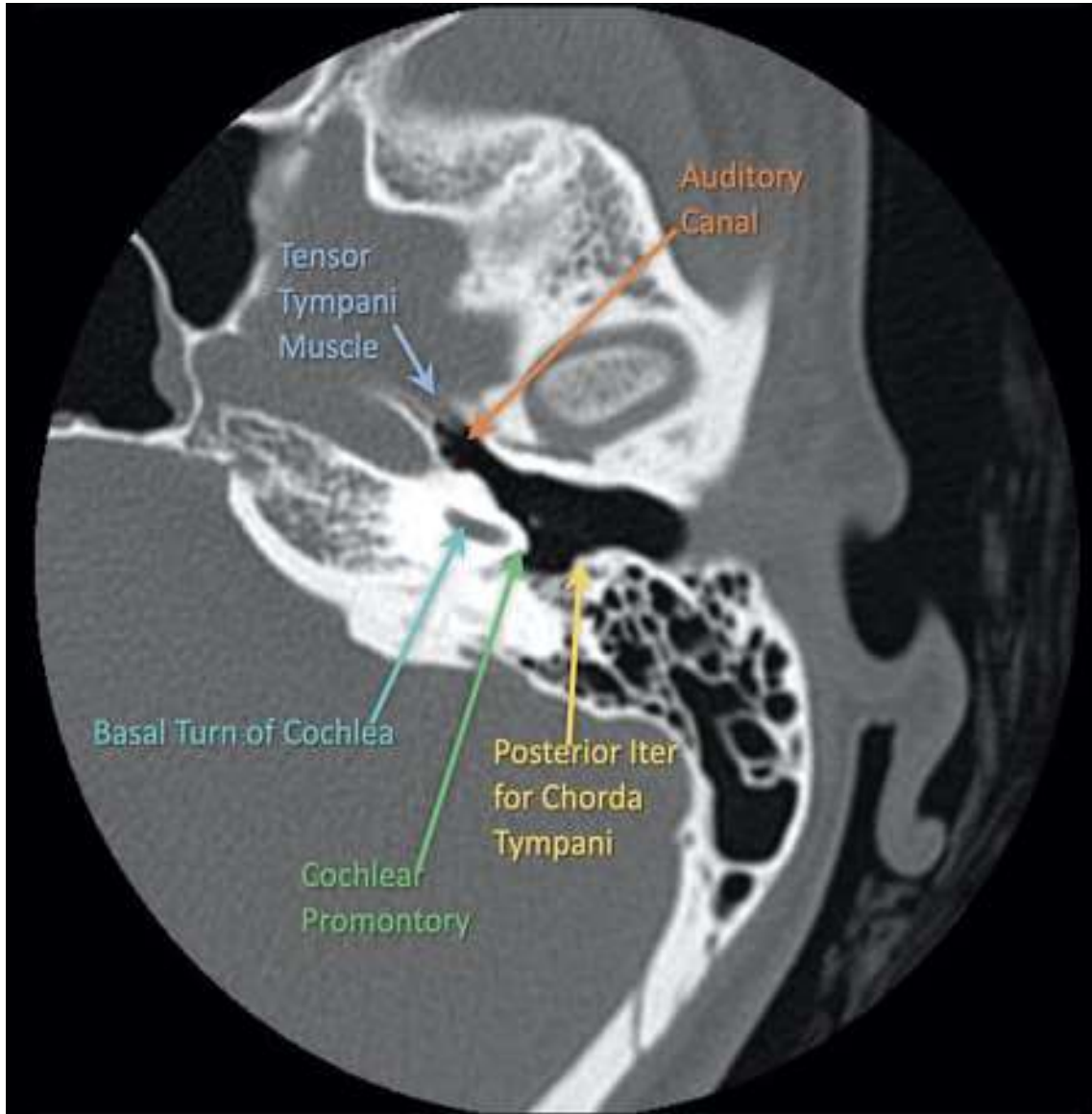
HRCT TEMPORAL BONE

- **Indications:**

- fractures
- preoperative evaluation of the cholesteatoma
- otosclerosis
- post operative followup
- prior to cochlear implant

- **Patient positioning**
Supine with head first, with arms besides the trunk
- **Topogram position/ landmark:**
lateral; level of vertex
- **Mode of scanning**
helical
- **Scan orientation**
craniocaudal
- **Start location:**
cranial limit of the petrous bone
- **End location:**
level of the mastoid tip

- **Gantry tilt:**
Nil
- **Field of view :**
Just fitting the temporal bone
- **Contrast administration:**
Nil
- **Slice thickness for reconstruction:**
0.5 – 1 mm
- **3D Reconstruction-**
MPR.



comments

- The use of head rest is recommended for head positioning
- it is important to avoid eye lens from unnecessary radiation exposure. So the position should be such that orbits are avoided with no need for the gantry tilt as well. However if such a position is not possible then gantry tilt can be given to avoid lens.

- 3D reconstruction are prepared for planning of cochlear implant surgery.

REFERENCES

1. CT AND MRI PROTOCOL (SATISH K BHARGAVA).
2. RADIOPAEDIA
3. Gach P, Tuchtan-Torrents L, Delteil C, Adalian P, Piercecchi MD, Ebert LC, Gorincour G. Virtual reconstruction of paranasal sinuses from CT data: A feasibility study for forensic application. *Diagn Interv Imaging*. 2019 Mar;100(3):163-168. doi: 10.1016/j.diii.2018.11.011. Epub 2018 Dec 12. PMID: 30553743.
4. Myga-Porosiło J, Skrzelewski S, Sraga W, Borowiak H, Jackowska Z, Kluczewska E. CT Imaging of facial trauma. Role of different types of reconstruction. Part I - bones. *Pol J Radiol*. 2011;76(1):41-51.