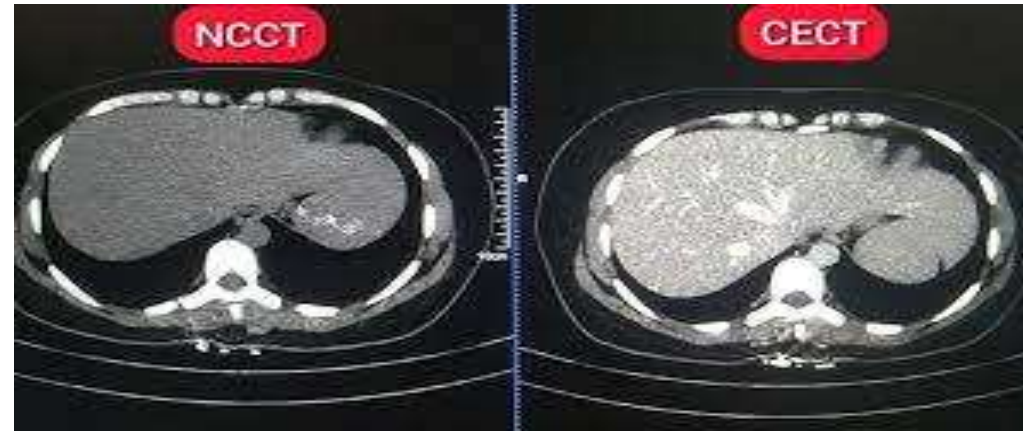



NCCT and CECT Abdomen with Pelvis with Image filters,3D,VR,MPR,MIP AND other filters



Abdominal and Pelvic CT

- Computed tomography (CT) of the abdomen and pelvis is a diagnostic imaging test.
 - Doctors use it to help detect diseases of the small bowel, colon, and other internal organs.
 - It is often used to determine the cause of unexplained pain. CT scanning is fast, painless, noninvasive and accurate.
 - A Non-contrast CT Scan is also called an **NCCT** scan and a CT scan with contrast is also called a **CECT** scan.
- 

Protocol:

Patient Position: Supine and Arms elevated above Head.

Topogram Direction: Craniocaudal.

Scan Start / End Locations: Superior to Diaphragm to Lesser Trochanters.

Breath Hold: SUSPENDED EXPIRATION

KV / effective mAs / Rotation time (sec): 120 kVp / 250 mAs / 0.75 sec

FOV: large 40 cm.

Slice Thickness: 5 – 7 mm.

Contrast:

Oral: Barium Sulfate (BaSO₄) or 30 mL Omnipaque in 1000 mL, 1-2 hours before scan.

IV: 300 Omni 100 ml.

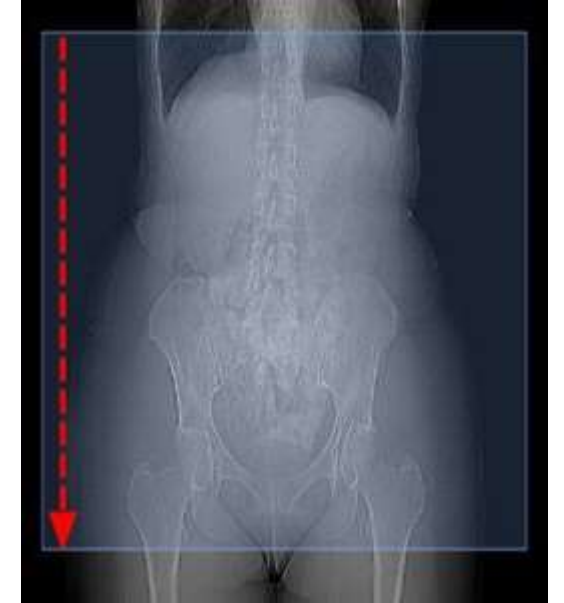350 Omni 100 ml, for Angiogram.

Contrast Rate: 2.5 to 4.0 cc per sec.

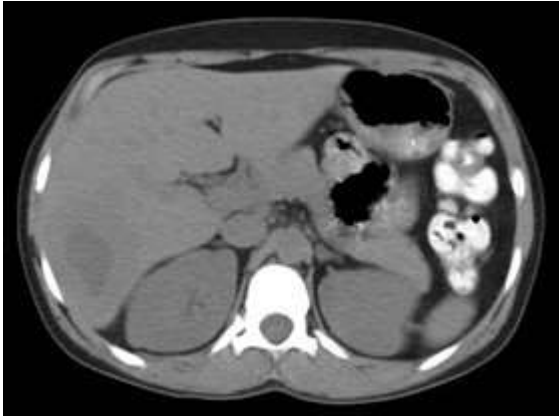
Arterial: 15 sec, or Bolus Tracking.

Portal Venous: 55 sec Delay.

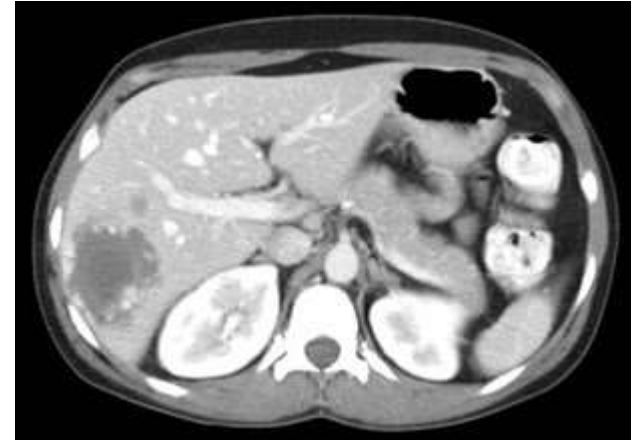
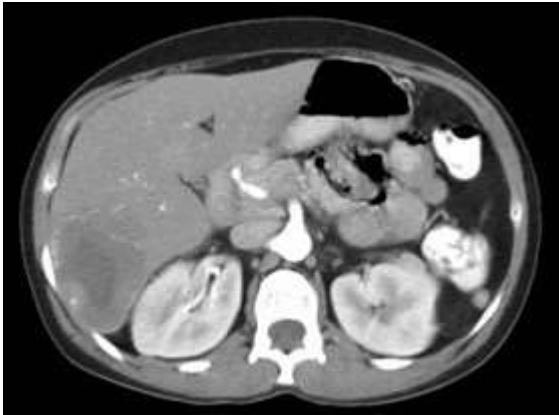Venous Only: 70 sec Delay.



NON-CONTRAST




ARTERIAL



PORTAL

.

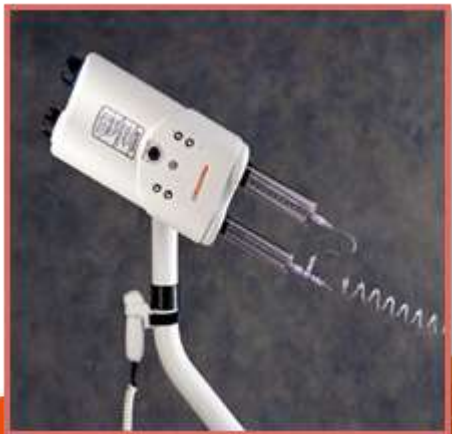Indications

- abdominal pain, pelvic pain
 - suspected abdominal or pelvic masses or fluid collections
 - primary abdominal tumors or metastatic spread
 - infections and inflammatory conditions of the abdomen and pelvis including abscesses
 - patients with fever of unknown origin
 - bowel obstruction
 - abdominal and pelvic organ manifestation in systemic disease
 - abdominal and pelvic trauma
 - postoperative follow-up
 - pre and posttransplant evaluation
 - congenital abnormalities
 - abdominal interventions (e.g. CT-guided biopsy, drainage)
- 

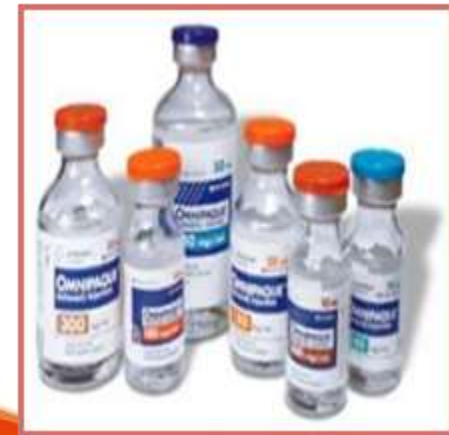PATIENT PREPARATION-

- If a Patient is going to have a Contrast Injection, he or she should not have anything to eat or drink for a few hours (4-6) before the CT scan because the injection may cause Stomach Upset.
- To receive the Contrast Injection, an IV canula is inserted into the Arm just prior to the scan.
- The Contrast then enters the Body through the IV.
- Prior to most CT scans of the Abdomen and Pelvis, it is important to drink an oral contrast agent that contains Dilute Barium.
- This Contrast Agent helps the radiologist identify the gastrointestinal tract (stomach, small and large bowel), detect abnormalities of these organs, and to separate these structures from other structures within the abdomen.
- The patient will be asked to drink Barium Sulfate (BaSO_4) or 30 mL Omnipaque (Iohexol 300 mgI/mL) in 1000 mL spread out over 1.5 to 2 hours.

CONTRAST INJECTOR



Barium Sulfate (BaSO_4)



Omnipaque

Different abdominal Protocols-

NCCT Abdomen-

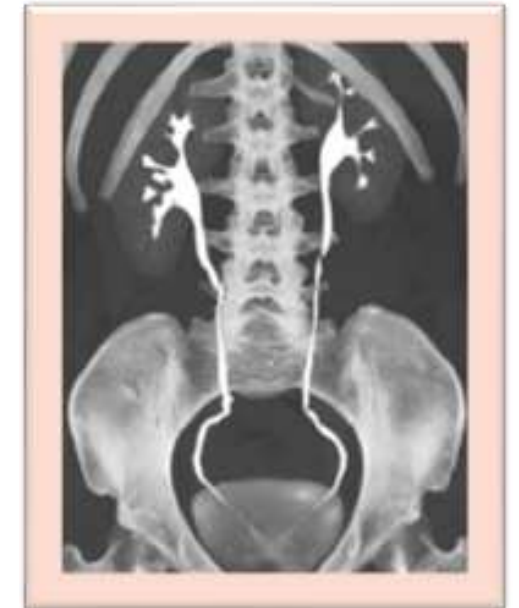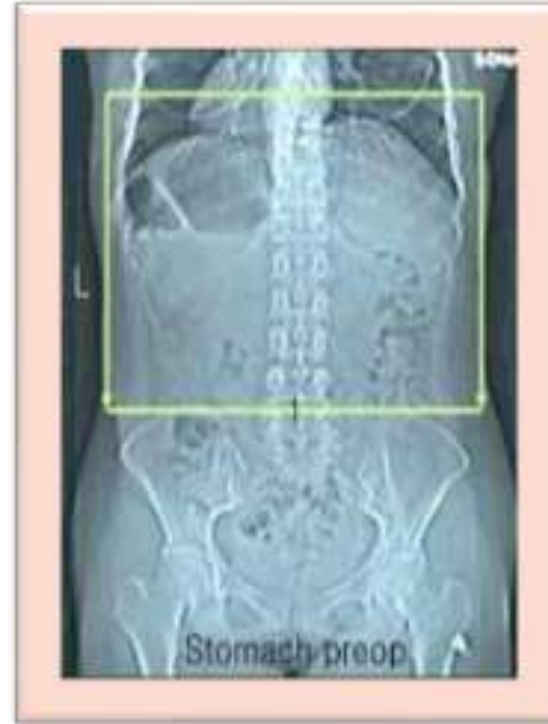BREATH HOLD: SUSPENDED EXPIRATION.

SLICE THICKNESS: 5mm.

Recon. Slice Thickness: 1-2 mm.

START LOCATION: ABOVE LIVER

END LOCATION: SYMPHYSIS PUBIS.



ABDOMEN- KIDNEYS (CECT)

ORAL CONTRAST: 500 ml 1 HOUR BEFORE SCAN, 200 ml JUST BEFORE SCAN

I.V. CONTRAST: 3-5 ml/sec

SCAN DELAY:

1. **NON CONTRAST.**

2. **ARTERIAL:** 15 SEC (Bolus Tracking)

3. **VENOUS:** 70 SEC.

4. **NEPHROGRAM:** 90 SEC.

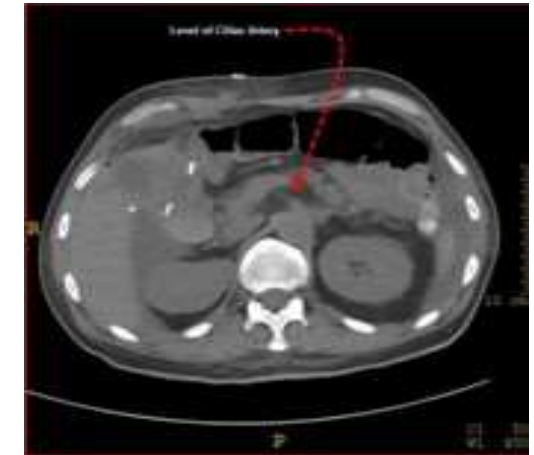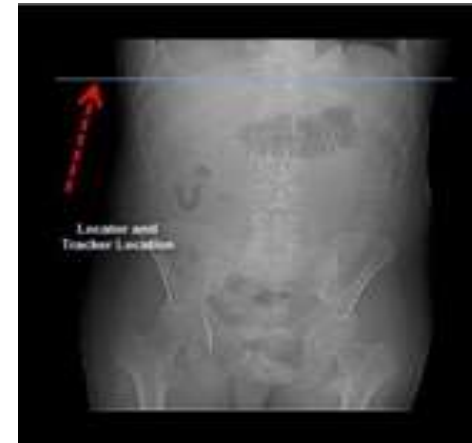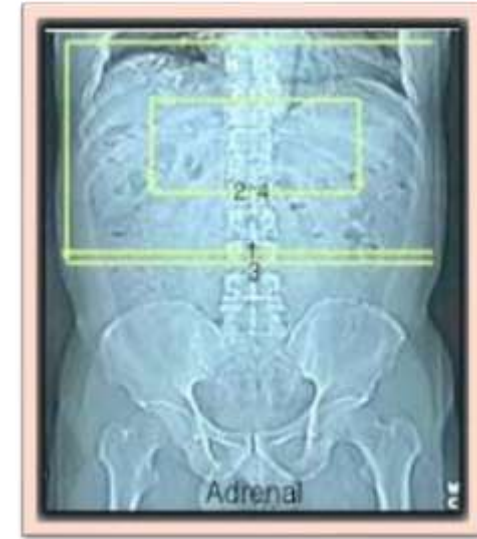5. **PYELOGRAM:** 3-5 MIN.

BREATH HOLD: SUSPENDED EXPIRATION

SLICE THICKNESS: 5- 7.5 mm.

START LOCATION: LUNG BASES.

END LOCATION: ILIAC CREST.



LIVER SINGLE PHASE

ORAL CONTRAST: 500 ml 1 HOUR BEFORE SCAN, 200 ML JUST BEFORE SCAN.

I.V. CONTRAST: 2.5 -3 ml / sec, 100-150 ml.

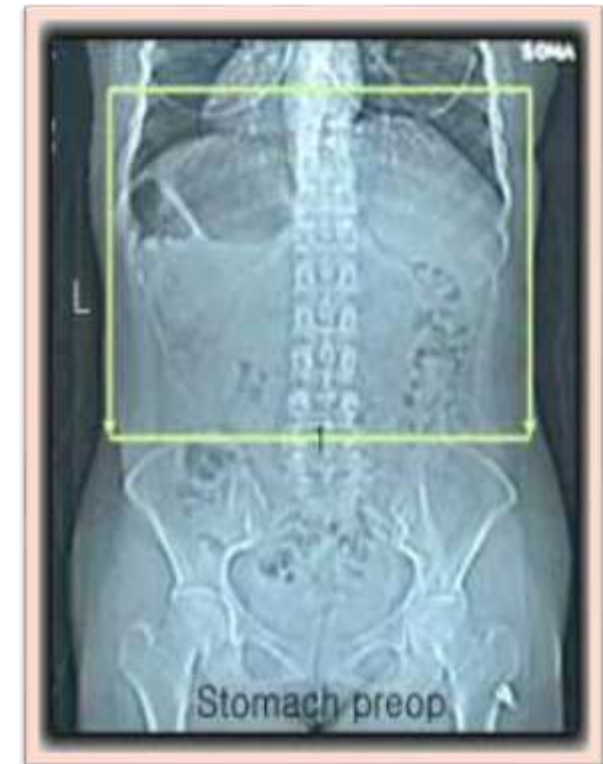SCAN DELAY: 55 sec.

BREATH HOLD: SUSPENDED EXPIRATION.

SLICE THICKNESS: 5 -7.5 mm

START LOCATION: LUNG BASES.

END LOCATION: ILIAC CREST.



ABDOMEN LIVER MASS-3 PHASE

ORAL CONTRAST: 500 ml 1 HOUR BEFORE SCAN, 200 ML JUST BEFORE SCAN

I.V. CONTRAST: 4-5ml/sec,100-150 ml.

SCAN DELAY:

1. **NON-CONTRAST.**

2. **ARTERIAL : 15 SEC,** (Bolus Tracking).

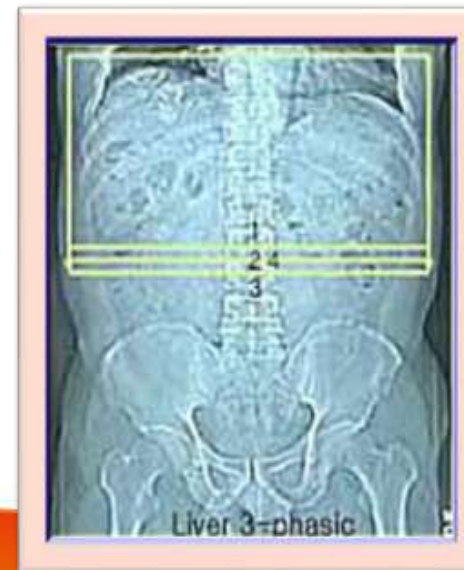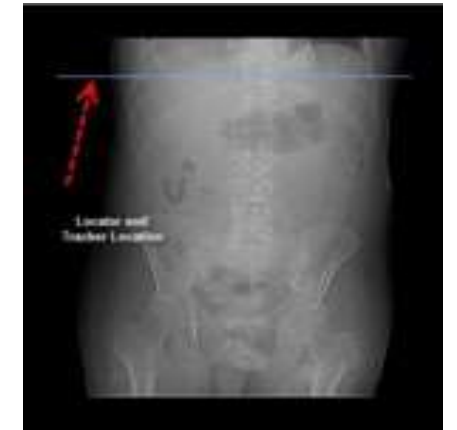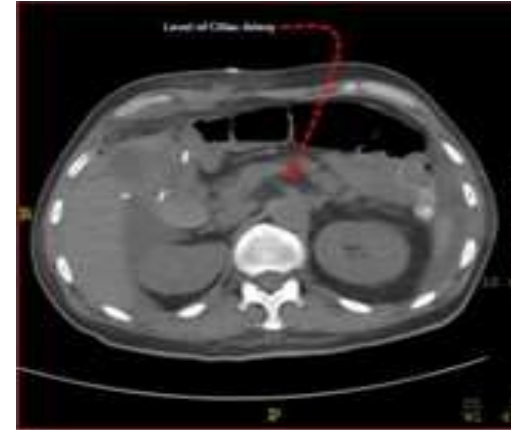3. **PORTAL: 55 SEC.**

BREATH HOLD: SUSPENDED EXPIRATION.

SLICE THICKNESS:4-5 mm.

START LOCATION: LUNG BASES.

END LOCATION: ILIAC CREST



ABDOMEN- PANCREAS

ORAL CONTRAST: 500 ml 1 HOUR BEFORE SCAN, 200 ml 15 MINUTES BEFORE SCAN.

I.V. CONTRAST: 2-4ml/sec, 100-150 ML.

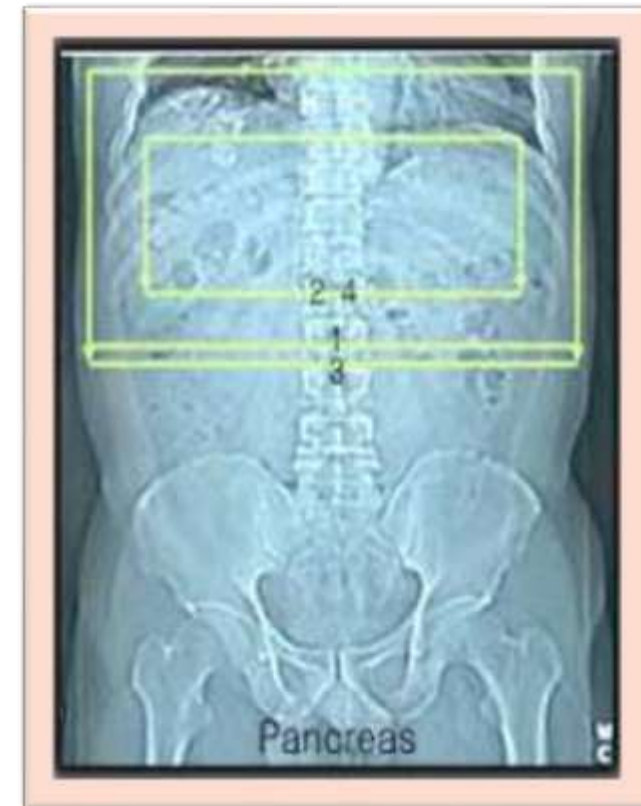
SCAN DELAY: 30-35 sec.

BREATH HOLD: SUSPENDED EXPIRATION.

SLICE THICKNESS: 3-5 mm THROUGH PANCREAS.

START LOCATION: LUNG BASES.

END LOCATION: ILIAC CREST



ABDOMEN + PELVIS APPENDICITIS OR DIVERTICULITIS

ORAL CONTRAST: 800 cc HOURS BEFORE SCAN, 200 ML JUST BEFORE SCAN.

I.V. CONTRAST: 1.5 - 2 ml/sec, 100-150 ml.

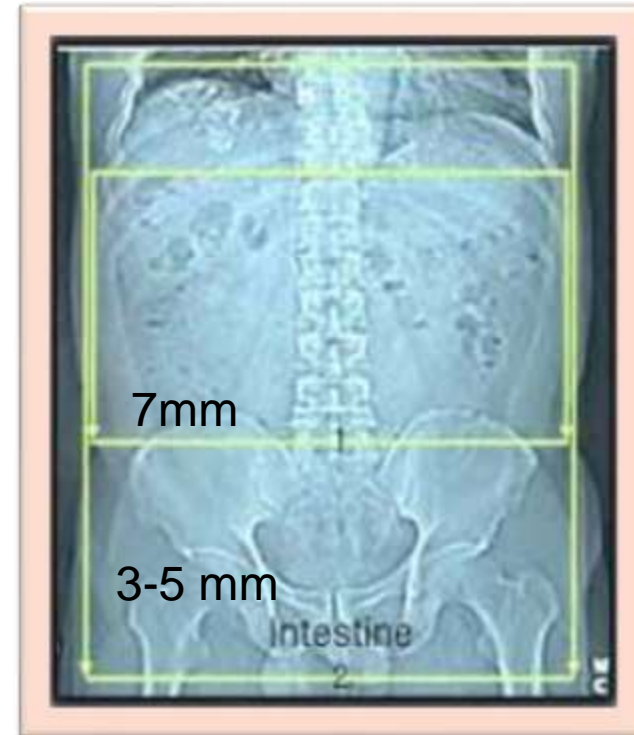
SCAN DELAY: 75-80 sec.

BREATH HOLD: SUSPENDED EXPIRATION.

SLICE THICKNESS: 7 mm + 3 – 5 mm LOWER

START LOCATION: LUNG BASES.

END LOCATION: SYMPHYSIS PUBIS.



CTA OF THE ABDOMEN

I.V. CONTRAST: 4 - 5 ml/sec, 100 - 150 ml.

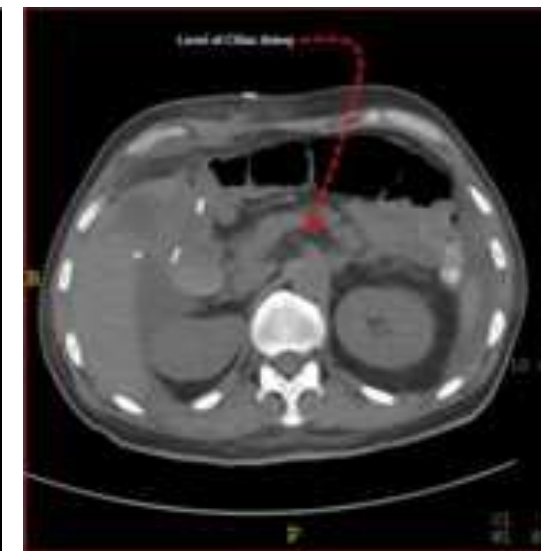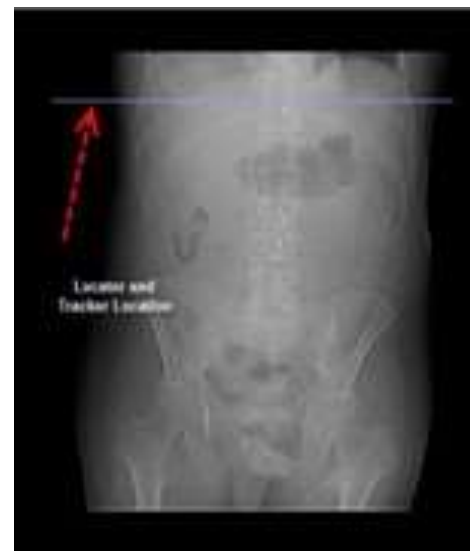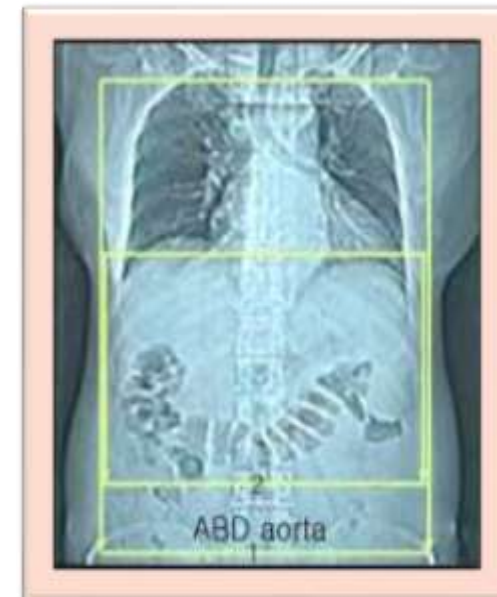SCAN DELAY: 15 sec, (Bolus Tracking).

BREATH HOLD: SUSPENDED EXPIRATION.

SLICE THICKNESS: 2.5 – 3ml.

START LOCATION: ABOVE AORTIC ARCH.

END LOCATION: BELOW ILIAC CREST.




Basic types of 2D & 3D image Formats


Two-dimensional (2D) formats

- Multiplanar reformations (MPR)
- Curved planar reformations
- Maximum intensity projection (MIP)
- Minimum intensity projection (MinIP)

Three-dimensional (3D)formats-

- Surface shaded displays (SSD)
 - Volume rendering (VR)
 - Perspective surface or volume rendering
 - Map projections
- 

Abdominal uses of 2D and 3D imaging

- CT / MR Angiography -
minimally invasive replacement for diagnostic angiography
 - Aortic and iliac artery aneurysms / stenosis
 - Living renal transplant donors
 - Mesenteric angiography
 - Renal artery stenosis
 - Nephron-sparing renal surgery
 - Liver transplant pre-op/post-op assessment
- 

Multiplanar and Curved Planar reformations

- Simplest 2D format
- Planes placed in any orientation through the volume

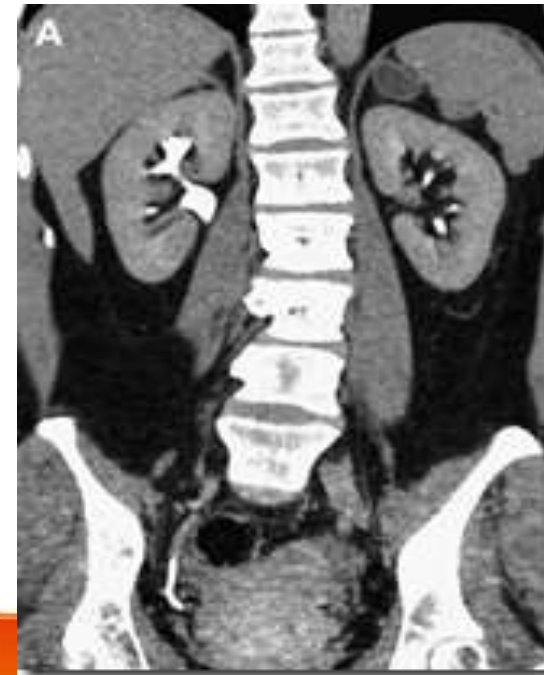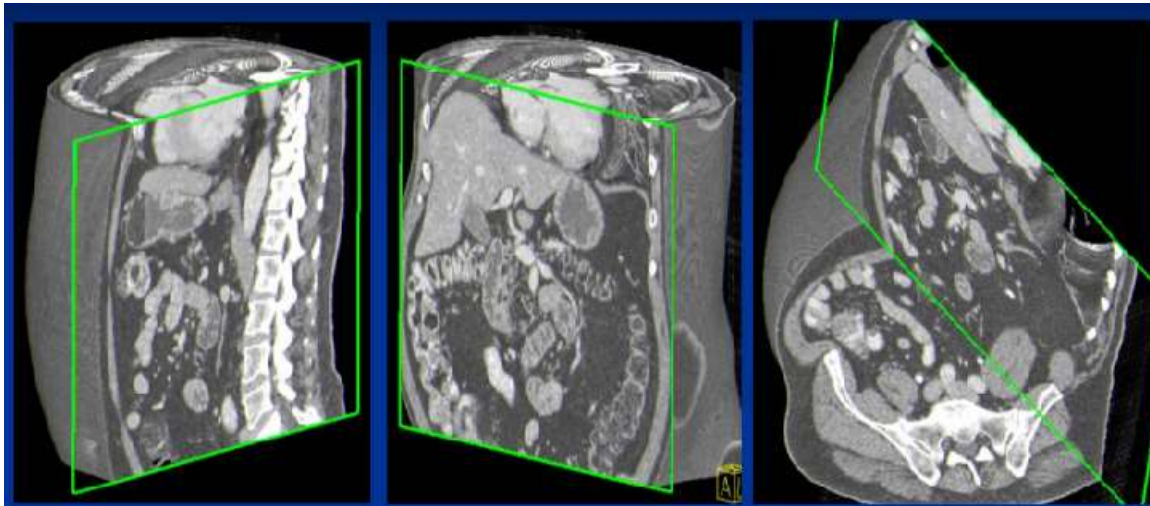
Advantages

- maintains all gray scale information (calcium and fat)
- Allows viewing along non-acquisition planes without additional imaging (radiation)

Disadvantages

- 2-Dimensional – need a series of images to retain all data
- No depth information
- Resolution traditionally less than non-axial planes

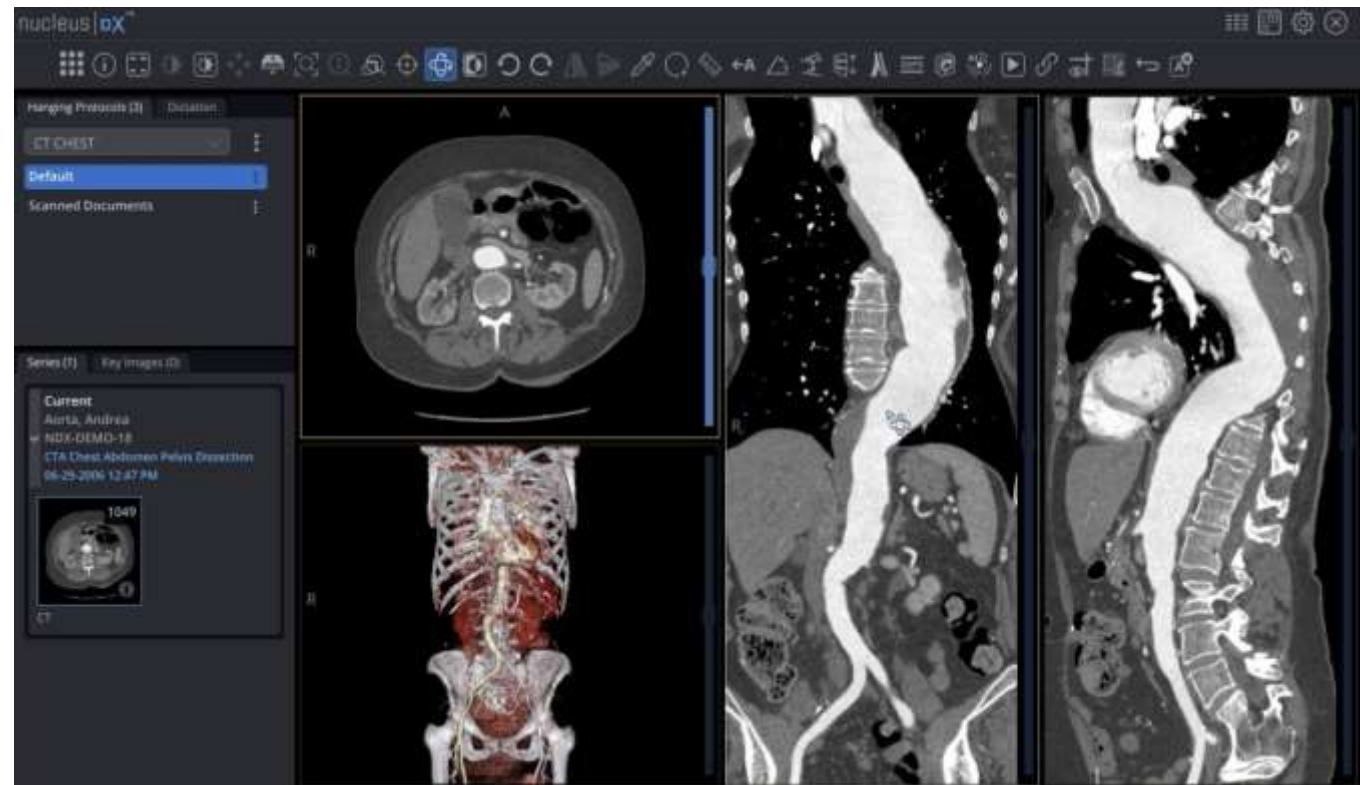
MPR cuts volume along any plane



Multiplanar reformation
of CT Scan Abdominal

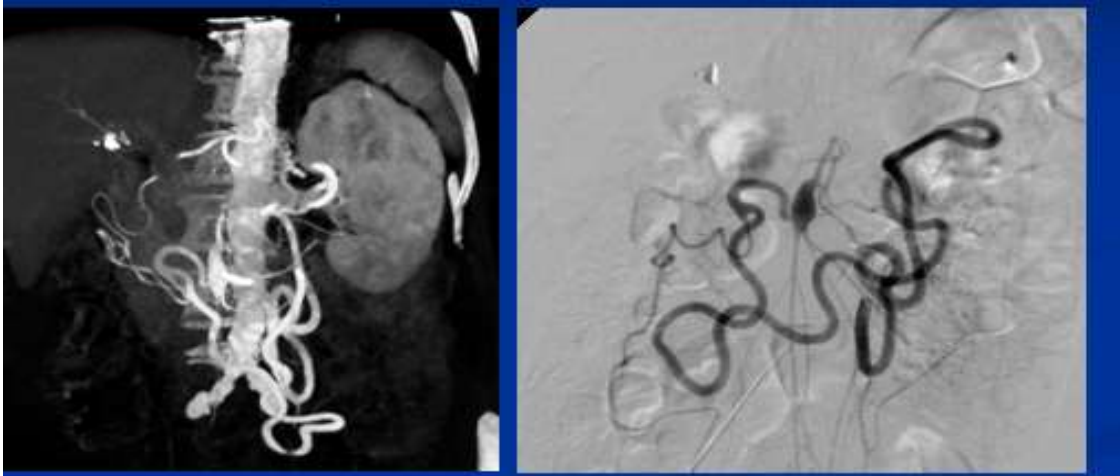
Curved planar reformations (CPR)

- Draw bendable plane from reference images
- Trace along vessels, spinal column, ureter
- Limitations
- Curved planar reformations have no restrictions
- Only include data “requested”
- Can be misleading



Volume rendering

- Each voxel assigned grayscale or RGB, brightness, and opacity
- Opacity “probability” CT density or MR signal intensity
- 0% - invisible
- 100% - opaque
- Brighter objects behind will shine through lucent ones
- Advantages: uses entire data set, real time display, 3D
- Disadvantages: more memory intensive, slower



VR and conventional Angio

Maximum Intensity Projection (MIP)

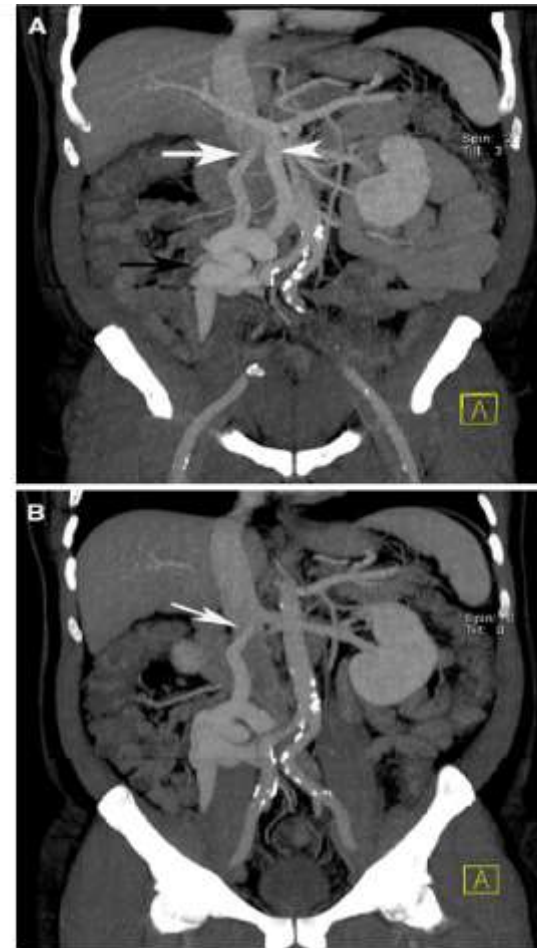
- Projects through the volume
- Displays only the highest HU value along line of 'sight'
- Uses data from the entire volume or a "slab" volume but selects only desired data (max on min HU)
- Common uses: CT/MR angiography, MRCP
- Typically combined with a series of rotating images to give '3d' location, but opposite views are similar not complimentary

Advantages

- Angiographic- or ERCP- like image
- Maintains gray scale info - calcium is visible

Disadvantages

- 2-dimensional
- Often need multiple projections
- Can require extensive image editing
- remove unwanted data
- "Slab" mips - MIP from only a few images



Coronal MIP
reconstruction of a
contrast enhanced
16-slice helical CT

THANK YOU

